

# World Journal of *Clinical Cases*

*World J Clin Cases* 2022 July 6; 10(19): 6341-6758



## Contents

Thrice Monthly Volume 10 Number 19 July 6, 2022

### MINIREVIEWS

- 6341** Review of clinical characteristics, immune responses and regulatory mechanisms of hepatitis E-associated liver failure  
*Chen C, Zhang SY, Chen L*
- 6349** Current guidelines for *Helicobacter pylori* treatment in East Asia 2022: Differences among China, Japan, and South Korea  
*Cho JH, Jin SY*
- 6360** Review of epidermal growth factor receptor-tyrosine kinase inhibitors administration to non-small-cell lung cancer patients undergoing hemodialysis  
*Lan CC, Hsieh PC, Huang CY, Yang MC, Su WL, Wu CW, Wu YK*

### ORIGINAL ARTICLE

#### Case Control Study

- 6370** Pregnancy-related psychopathology: A comparison between pre-COVID-19 and COVID-19-related social restriction periods  
*Chieffo D, Avallone C, Serio A, Kotzalidis GD, Balocchi M, De Luca I, Hirsch D, Gonzalez del Castillo A, Lanzotti P, Marano G, Rinaldi L, Lanzone A, Mercuri E, Mazza M, Sani G*
- 6385** Intestinal mucosal barrier in functional constipation: Does it change?  
*Wang JK, Wei W, Zhao DY, Wang HF, Zhang YL, Lei JP, Yao SK*

#### Retrospective Cohort Study

- 6399** Identification of risk factors for surgical site infection after type II and type III tibial pilon fracture surgery  
*Hu H, Zhang J, Xie XG, Dai YK, Huang X*

#### Retrospective Study

- 6406** Total knee arthroplasty in Ranawat II valgus deformity with enlarged femoral valgus cut angle: A new technique to achieve balanced gap  
*Lv SJ, Wang XJ, Huang JF, Mao Q, He BJ, Tong PJ*
- 6417** Preliminary evidence in treatment of eosinophilic gastroenteritis in children: A case series  
*Chen Y, Sun M*
- 6428** Self-made wire loop snare successfully treats gastric persimmon stone under endoscopy  
*Xu W, Liu XB, Li SB, Deng WP, Tong Q*
- 6437** Neoadjuvant transcatheter arterial chemoembolization and systemic chemotherapy for the treatment of undifferentiated embryonal sarcoma of the liver in children  
*He M, Cai JB, Lai C, Mao JQ, Xiong JN, Guan ZH, Li LJ, Shu Q, Ying MD, Wang JH*

- 6446** Effect of cold snare polypectomy for small colorectal polyps

*Meng QQ, Rao M, Gao PJ*

- 6456** Field evaluation of COVID-19 rapid antigen test: Are rapid antigen tests less reliable among the elderly?

*Tabain I, Cucevic D, Skreb N, Mrzljak A, Ferencak I, Hruskar Z, Misic A, Kuzle J, Skoda AM, Jankovic H, Vilibic-Cavlek T*

### Observational Study

- 6464** Tracheobronchial intubation using flexible bronchoscopy in children with Pierre Robin sequence: Nursing considerations for complications

*Ye YL, Zhang CF, Xu LZ, Fan HF, Peng JZ, Lu G, Hu XY*

- 6472** Family relationship of nurses in COVID-19 pandemic: A qualitative study

*Çelik MY, Kiliç M*

### META-ANALYSIS

- 6483** Diagnostic accuracy of  $\geq 16$ -slice spiral computed tomography for local staging of colon cancer: A systematic review and meta-analysis

*Liu D, Sun LM, Liang JH, Song L, Liu XP*

### CASE REPORT

- 6496** Delayed-onset endophthalmitis associated with *Achromobacter* species developed in acute form several months after cataract surgery: Three case reports

*Kim TH, Lee SJ, Nam KY*

- 6501** Sustained dialysis with misplaced peritoneal dialysis catheter outside peritoneum: A case report

*Shen QQ, Behera TR, Chen LL, Attia D, Han F*

- 6507** Arteriovenous thrombotic events in a patient with advanced lung cancer following bevacizumab plus chemotherapy: A case report

*Kong Y, Xu XC, Hong L*

- 6514** Endoscopic ultrasound radiofrequency ablation of pancreatic insulinoma in elderly patients: Three case reports

*Rossi G, Petrone MC, Capurso G, Partelli S, Falconi M, Arcidiacono PG*

- 6520** Acute choroidal involvement in lupus nephritis: A case report and review of literature

*Yao Y, Wang HX, Liu LW, Ding YL, Sheng JE, Deng XH, Liu B*

- 6529** Triple A syndrome-related achalasia treated by per-oral endoscopic myotomy: Three case reports

*Liu FC, Feng YL, Yang AM, Guo T*

- 6536** Choroidal thickening with serous retinal detachment in BRAF/MEK inhibitor-induced uveitis: A case report

*Kiraly P, Groznik AL, Valentinčič NV, Mekjavić PJ, Urbančič M, Ocvirk J, Mesti T*

- 6543** Esophageal granular cell tumor: A case report

*Chen YL, Zhou J, Yu HL*

- 6548** Hem-o-lok clip migration to the common bile duct after laparoscopic common bile duct exploration: A case report  
*Liu DR, Wu JH, Shi JT, Zhu HB, Li C*
- 6555** Chidamide and sintilimab combination in diffuse large B-cell lymphoma progressing after chimeric antigen receptor T therapy  
*Hao YY, Chen PP, Yuan XG, Zhao AQ, Liang Y, Liu H, Qian WB*
- 6563** Relapsing polychondritis with isolated tracheobronchial involvement complicated with Sjogren's syndrome: A case report  
*Chen JY, Li XY, Zong C*
- 6571** Acute methanol poisoning with bilateral diffuse cerebral hemorrhage: A case report  
*Li J, Feng ZJ, Liu L, Ma YJ*
- 6580** Immunoabsorption therapy for Klinefelter syndrome with antiphospholipid syndrome in a patient: A case report  
*Song Y, Xiao YZ, Wang C, Du R*
- 6587** Roxadustat for treatment of anemia in a cancer patient with end-stage renal disease: A case report  
*Zhou QQ, Li J, Liu B, Wang CL*
- 6595** Imaging-based diagnosis for extraskeletal Ewing sarcoma in pediatrics: A case report  
*Chen ZH, Guo HQ, Chen JJ, Zhang Y, Zhao L*
- 6602** Unusual course of congenital complete heart block in an adult: A case report  
*Su LN, Wu MY, Cui YX, Lee CY, Song JX, Chen H*
- 6609** Penile metastasis from rectal carcinoma: A case report  
*Sun JJ, Zhang SY, Tian JJ, Jin BY*
- 6617** Isolated cryptococcal osteomyelitis of the ulna in an immunocompetent patient: A case report  
*Ma JL, Liao L, Wan T, Yang FC*
- 6626** Magnetic resonance imaging features of intrahepatic extramedullary hematopoiesis: Three case reports  
*Luo M, Chen JW, Xie CM*
- 6636** Giant retroperitoneal liposarcoma treated with radical conservative surgery: A case report and review of literature  
*Lieto E, Cardella F, Erario S, Del Sorbo G, Reginelli A, Galizia G, Urraro F, Panarese I, Auricchio A*
- 6647** Transplanted kidney loss during colorectal cancer chemotherapy: A case report  
*Pośpiech M, Kolonko A, Nieszporek T, Kozak S, Kozaczka A, Karkoszka H, Winder M, Chudek J*
- 6656** Massive gastrointestinal bleeding after endoscopic rubber band ligation of internal hemorrhoids: A case report  
*Jiang YD, Liu Y, Wu JD, Li GP, Liu J, Hou XH, Song J*

- 6664** Mills' syndrome is a unique entity of upper motor neuron disease with N-shaped progression: Three case reports  
*Zhang ZY, Ouyang ZY, Zhao GH, Fang JJ*
- 6672** Entire process of electrocardiogram recording of Wellens syndrome: A case report  
*Tang N, Li YH, Kang L, Li R, Chu QM*
- 6679** Retroperitoneal tumor finally diagnosed as a bronchogenic cyst: A case report and review of literature  
*Gong YY, Qian X, Liang B, Jiang MD, Liu J, Tao X, Luo J, Liu HJ, Feng YG*
- 6688** Successful treatment of Morbihan disease with total glucosides of paeony: A case report  
*Zhou LF, Lu R*
- 6695** Ant sting-induced whole-body pustules in an inebriated male: A case report  
*Chen SQ, Yang T, Lan LF, Chen XM, Huang DB, Zeng ZL, Ye XY, Wan CL, Li LN*
- 6702** Plastic surgery for giant metastatic endometrioid adenocarcinoma in the abdominal wall: A case report and review of literature  
*Wang JY, Wang ZQ, Liang SC, Li GX, Shi JL, Wang JL*
- 6710** Delayed-release oral mesalamine tablet mimicking a small jejunal gastrointestinal stromal tumor: A case report  
*Frosio F, Rausa E, Marra P, Boutron-Ruault MC, Lucianetti A*
- 6716** Concurrent alcoholic cirrhosis and malignant peritoneal mesothelioma in a patient: A case report  
*Liu L, Zhu XY, Zong WJ, Chu CL, Zhu JY, Shen XJ*
- 6722** Two smoking-related lesions in the same pulmonary lobe of squamous cell carcinoma and pulmonary Langerhans cell histiocytosis: A case report  
*Gencer A, Ozcibik G, Karakas FG, Sarbay I, Batur S, Borekci S, Turna A*
- 6728** Proprotein convertase subtilisin/kexin type 9 inhibitor non responses in an adult with a history of coronary revascularization: A case report  
*Yang L, Xiao YY, Shao L, Ouyang CS, Hu Y, Li B, Lei LF, Wang H*
- 6736** Multimodal imaging study of lipemia retinalis with diabetic retinopathy: A case report  
*Zhang SJ, Yan ZY, Yuan LF, Wang YH, Wang LF*
- 6744** Primary squamous cell carcinoma of the liver: A case report  
*Kang LM, Yu DP, Zheng Y, Zhou YH*
- 6750** Tumor-to-tumor metastasis of clear cell renal cell carcinoma to contralateral synchronous pheochromocytoma: A case report  
*Wen HY, Hou J, Zeng H, Zhou Q, Chen N*

**ABOUT COVER**

Editorial Board Member of *World Journal of Clinical Cases*, Abdulqadir Jeprel Naswhan, MSc, RN, Director, Research Scientist, Senior Lecturer, Senior Researcher, Nursing for Education and Practice Development, Hamad Medical Corporation, Doha 576214, Qatar. anashwan@hamad.qa

**AIMS AND SCOPE**

The primary aim of *World Journal of Clinical Cases* (WJCC, *World J Clin Cases*) is to provide scholars and readers from various fields of clinical medicine with a platform to publish high-quality clinical research articles and communicate their research findings online.

WJCC mainly publishes articles reporting research results and findings obtained in the field of clinical medicine and covering a wide range of topics, including case control studies, retrospective cohort studies, retrospective studies, clinical trials studies, observational studies, prospective studies, randomized controlled trials, randomized clinical trials, systematic reviews, meta-analysis, and case reports.

**INDEXING/ABSTRACTING**

The WJCC is now indexed in Science Citation Index Expanded (also known as SciSearch®), Journal Citation Reports/Science Edition, Scopus, PubMed, and PubMed Central. The 2021 Edition of Journal Citation Reports® cites the 2020 impact factor (IF) for WJCC as 1.337; IF without journal self cites: 1.301; 5-year IF: 1.742; Journal Citation Indicator: 0.33; Ranking: 119 among 169 journals in medicine, general and internal; and Quartile category: Q3. The WJCC's CiteScore for 2020 is 0.8 and Scopus CiteScore rank 2020: General Medicine is 493/793.

**RESPONSIBLE EDITORS FOR THIS ISSUE**

Production Editor: Xu Guo; Production Department Director: Xiang Li; Editorial Office Director: Jin-Lai Wang.

**NAME OF JOURNAL**

*World Journal of Clinical Cases*

**ISSN**

ISSN 2307-8960 (online)

**LAUNCH DATE**

April 16, 2013

**FREQUENCY**

Thrice Monthly

**EDITORS-IN-CHIEF**

Bao-Gan Peng, Jerzy Tadeusz Chudek, George Kontogeorgos, Maurizio Serati, Ja Hyeon Ku

**EDITORIAL BOARD MEMBERS**

<https://www.wjgnet.com/2307-8960/editorialboard.htm>

**PUBLICATION DATE**

July 6, 2022

**COPYRIGHT**

© 2022 Baishideng Publishing Group Inc

**INSTRUCTIONS TO AUTHORS**

<https://www.wjgnet.com/bpg/gerinfo/204>

**GUIDELINES FOR ETHICS DOCUMENTS**

<https://www.wjgnet.com/bpg/GerInfo/287>

**GUIDELINES FOR NON-NATIVE SPEAKERS OF ENGLISH**

<https://www.wjgnet.com/bpg/gerinfo/240>

**PUBLICATION ETHICS**

<https://www.wjgnet.com/bpg/GerInfo/288>

**PUBLICATION MISCONDUCT**

<https://www.wjgnet.com/bpg/gerinfo/208>

**ARTICLE PROCESSING CHARGE**

<https://www.wjgnet.com/bpg/gerinfo/242>

**STEPS FOR SUBMITTING MANUSCRIPTS**

<https://www.wjgnet.com/bpg/GerInfo/239>

**ONLINE SUBMISSION**

<https://www.f6publishing.com>

# Successful treatment of Morbihan disease with total glucosides of paeony: A case report

Li-Feng Zhou, Rong Lu

**Specialty type:** Medicine, research and experimental

**Provenance and peer review:** Unsolicited article; Externally peer reviewed.

**Peer-review model:** Single blind

**Peer-review report's scientific quality classification**

Grade A (Excellent): 0

Grade B (Very good): B, B, B

Grade C (Good): C, C, C

Grade D (Fair): 0

Grade E (Poor): 0

**P-Reviewer:** Bugaj AM, Poland; Islamoglu MS, Turkey; Lambrecht NW, United States; Lim SC, South Korea; Sadighha A, Iran; Toyoshima O, Japan

**A-Editor:** Yao QG

**Received:** January 13, 2022

**Peer-review started:** January 13, 2022

**First decision:** April 8, 2022

**Revised:** April 15, 2022

**Accepted:** May 17, 2022

**Article in press:** May 17, 2022

**Published online:** July 6, 2022



**Li-Feng Zhou**, Department of Dermatology, The 942<sup>nd</sup> Hospital of the PLA Joint Logistic Support Force, Yinchuan 750004, Ningxia Hui Autonomous Region, China

**Rong Lu**, Department of Pathology, The 942<sup>nd</sup> Hospital of the PLA Joint Logistic Support Force, Yinchuan 750004, Ningxia Hui Autonomous Region, China

**Corresponding author:** Rong Lu, MMed, Director, Department of Pathology, The 942<sup>nd</sup> Hospital of the PLA Joint Logistic Support Force, No. 893 Shengli South Street, Xingqing District, Yinchuan 750004, Ningxia Hui Autonomous Region, China. [lrzlf@sohu.com](mailto:lrzlf@sohu.com)

## Abstract

### BACKGROUND

Morbihan disease is a rare cutaneous disorder characterized by non-pitting edema and erythema of the upper two-thirds of the face. In severe cases, orbital and facial contour changes may affect the visual field, and there is no guideline for the standard treatment of this disease. Existing treatment methods have been reported to be associated with long medication cycle, easy recurrence after drug withdrawal, and multiple adverse reactions.

### CASE SUMMARY

A 55-year-old Chinese woman presented to our hospital with non-pitting edema and erythema of the upper two thirds of her face for 5 mo. Physical examination showed obvious edema and erythema on the upper face. The boundary was unclear, the lesions were hard and non-pitting, and infiltration was obvious by touch. Pathological examination revealed mild hyperkeratosis of the epidermis, nodular inflammatory lesions in the dermis, epithelioid granuloma, and inflammatory cell infiltration with lymphocytes and histiocytes around skin appendages and blood vessels. Alcian blue staining, acid fast staining, silver staining and periodic acid-Schiff staining were negative. The patient was diagnosed with Morbihan disease. She was treated with prednisone acetate and tripterygium wilfordii polyglycoside tablets for 4 mo, and the edema was slightly reduced, but transaminase levels were significantly increased. Compound glycyrrhizin capsules were administered for liver protection for 1 mo; however, facial edema did not significantly improve and transaminase levels continued to increase. Total glucosides of paeony capsules were then administered for 4 mo, and transaminase level returned to normal and the patient's facial edema disappeared completely.

### CONCLUSION

Total glucosides of paeony has a remarkable effect in Morbihan disease, without

adverse reactions.

**Key Words:** Morbihan disease; Morbihan syndrome; Total glucosides of paeony; Prednisone acetate; *Tripterygium wilfordii*; Case report

©The Author(s) 2022. Published by Baishideng Publishing Group Inc. All rights reserved.

**Core Tip:** Morbihan disease is a rare skin disease characterized by non-pitting edema and erythema of the upper two-thirds of the face. The orbital and facial contour changes can affect the field of vision and cause disfiguring damage if not treated in time. The specific pathogenesis is unclear, and there is no standard treatment guideline for this disease. Thus, it is necessary to identify a safe and effective treatment. We treated a case of Morbihan disease with total glucosides of paeony and achieved very good results with no adverse reactions. The treatment of Morbihan disease with total glucosides of paeony has not previously been reported.

**Citation:** Zhou LF, Lu R. Successful treatment of Morbihan disease with total glucosides of paeony: A case report. *World J Clin Cases* 2022; 10(19): 6688-6694

**URL:** <https://www.wjgnet.com/2307-8960/full/v10/i19/6688.htm>

**DOI:** <https://dx.doi.org/10.12998/wjcc.v10.i19.6688>

## INTRODUCTION

Morbihan disease, also known as Morbihan syndrome, is a rare skin disease named by Gorin *et al*[1] in 1991, with only a few sporadic cases reported worldwide. The main clinical manifestations are edema and erythema of the upper two-thirds of the face without obvious discomfort. Development of the disease can cause malformation and visual field defects, affecting patients' quality of life[2]. Therefore, early diagnosis and treatment are of great significance. Currently, there is no standard treatment for Morbihan disease. We describe a 55-year-old female patient who received total glucosides of paeony for this rare disease with good efficacy and no adverse reactions.

## CASE PRESENTATION

### Chief complaints

A 55-year-old female patient presented to our Department of Dermatology with non-pitting edema and erythema of the upper two-thirds of the face for 5 mo.

### History of present illness

The patient had edema and erythema of the upper two-thirds of the face 5 mo ago, and there was no itching or discomfort related to the skin lesions. The patient had previously been treated in two hospitals, where the doctors considered her condition considered to be caused by an allergy and treated her with antihistamines, but this treatment was ineffective. The primary skin lesions gradually became worse.

### History of past illness

The patient was previously healthy and denied any history of acne, rosacea, erysipelas, allergies, diabetes, or other diseases.

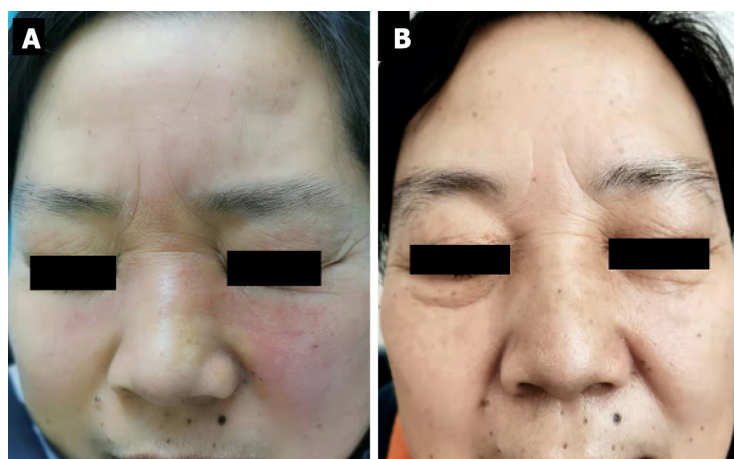
### Personal and family history

The patient denied genetic diseases, and there was no similar disease in the family.

### Physical examination

On physical examination, temperature, pulse, respiration, and blood pressure were normal. Examination of the heart, lungs, abdomen, and nervous system showed no abnormalities. Dermatological findings showed obvious edema and erythema on the forehead, between the eyebrows, and on both eyelids, nose, and both cheeks. The skin lesions were hard and non-pitting, and had unclear boundaries and obvious infiltration by touch (Figure 1A). The rest of the skin showed no abnormalities. No visual field damage was observed.





DOI: 10.12998/wjcc.v10.i19.6688 Copyright ©The Author(s) 2022.

**Figure 1** Facial lesions of the patient with Morbihan disease. A: Non-pitting edema and erythema of the upper two-thirds of the face; B: The lesions disappeared completely after 4 mo of treatment with total glucosides of paeony capsules, and follow-up of almost 1 yr showed no recurrence.

### Laboratory examinations

Routine blood tests, renal function, and electrolytes were all within the normal range. Routine urine test showed positive occult blood (1+), and other values were normal. The tuberculin test, antinuclear antibody spectrum, and anti-double stranded DNA antibody were negative. All immunological indicators were normal. Liver function analysis showed that alanine aminotransferase (ALA) was 44 U/L, and other values were normal. Histopathological examination of skin lesions on the left side of the face revealed mild hyperkeratosis of the epidermis, nodular inflammatory lesions in the dermis, epithelioid granuloma, and inflammatory cell infiltration dominated by lymphocytes and histiocytes around skin appendages and blood vessels (Figure 2A-C). Alcian blue staining, acid fast staining, silver staining, and periodic acid-Schiff (PAS) staining were all negative (Figure 2D-G).

### Imaging examinations

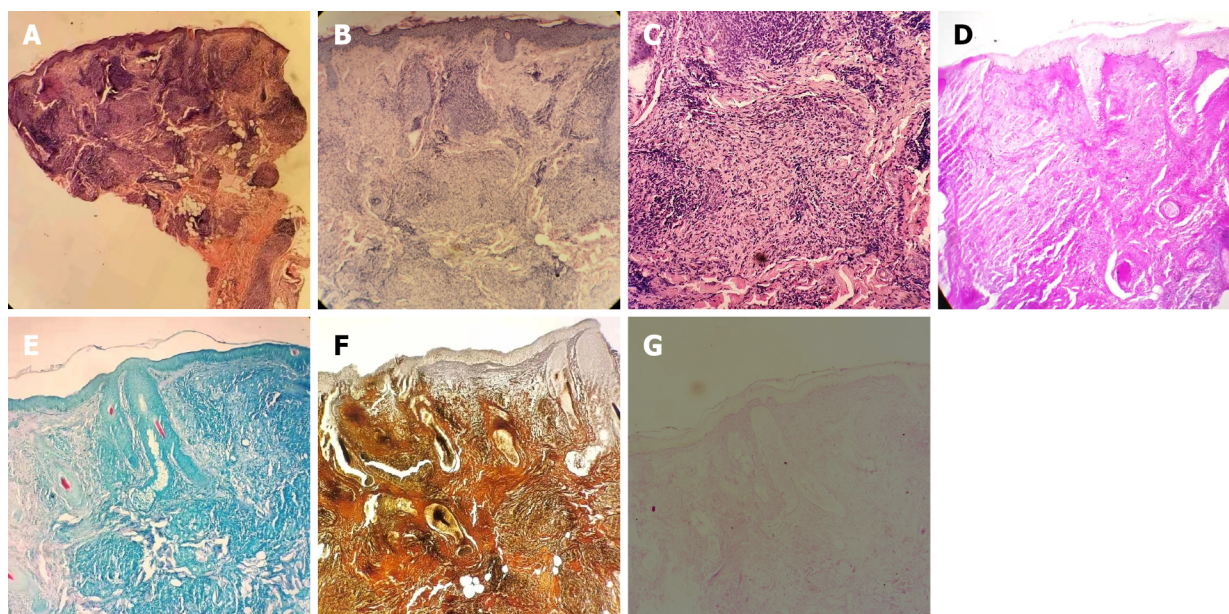
A chest X-ray showed no abnormalities.

## FINAL DIAGNOSIS

The patient was diagnosed with Morbihan disease.

## TREATMENT

Facial edema was significantly reduced after treatment with prednisone acetate tablets 20 mg/d for 1 mo. When prednisone acetate was reduced to 10 mg/d for 2 mo, facial edema increased. Prednisone acetate was discontinued, and tripterygium wilfordii polyglycoside tablets were prescribed at 6 tablets/d. After 4 mo of this treatment, facial edema was slightly relieved. Liver function examination showed that ALA was 73 U/L and aspartate aminotransferase (ASA) was 56 U/L, both of which were higher than the values before treatment. Elevated aminotransferase was found to be caused by tripterygium wilfordii polyglycoside, thus oral liver-protecting compound glycyrrhizin at 225 mg/d was initiated. After 1 mo of treatment, facial edema did not significantly improve, and liver function reexamination showed that ALA (86 U/L) and ASA (62 U/L) levels were still high. Therefore, oral administration of tripterygium wilfordii polyglycoside and compound glycyrrhizin was discontinued, and total glucosides of paeony capsules at 0.6 g 3 times/day were prescribed. After 1 mo of treatment, facial edema was significantly reduced. Liver function reexamination showed that ALA was 69 U/L and ASA was 58 U/L, both of which were decreased. After another mo of treatment with total glucosides of paeony capsules, liver function reexamination showed that ALA was 47.31 U/L and ASA was 37.35 U/L, both of which returned to normal and facial edema was further alleviated. After subsequent 2 mo of maintenance treatment with total glucosides of paeony capsules, facial edema completely disappeared (Figure 1B), and liver function indexes returned to normal.



DOI: 10.12998/wjcc.v10.i19.6688 Copyright ©The Author(s) 2022.

**Figure 2** Histopathology of the patient's facial skin lesions. A-C: Hyperkeratosis of the epidermis, nodular inflammatory lesions in the dermis, epithelioid granuloma, and inflammatory infiltrating cells dominated by lymphocytes and histiocytes around skin appendages and blood vessels (HE staining A: × 4; B: × 20; C: × 40); D: Negative for Alcian blue staining (× 20); E: Negative for acid fast staining (× 20); F: Negative for silver staining (× 20); G: Negative for periodic acid-Schiff staining (× 20).

## OUTCOME AND FOLLOW-UP

Facial edema disappeared completely after 4 mo of treatment with total glucosides of paeony. The patient was followed for almost 1 year and was in good physical condition without facial edema.

## DISCUSSION

The specific potential cause of Morbihan disease is unclear, and some scholars believe that it is a rare complication of acne[3]. Some researchers suggest that it is related to rosacea[4,5], and its pathogenesis may be related to chronic inflammation, which affects lymphatic reflux and leads to local skin edema [6]. Recent studies have suggested that edema may be associated with non-insulin-dependent diabetes mellitus[7,8]. Our patient had no history of acne, rosacea, or diabetes, and the specific cause of the disease was unclear.

The histopathology of this disease is mainly non-specific inflammation, which is manifested by telangiectasis and infiltration of inflammatory cells such as lymphocytes around hair follicles and blood vessels[9], and granulomatous tissue can also be seen in a few cases[2]. The histopathological findings of the skin lesions in the present patient were nodular inflammatory lesions in the dermis, epithelioid granuloma, and inflammatory cell infiltration dominated by lymphocytes and histiocytes around skin appendages and blood vessels. This is consistent with the existing case reports of Morbihan disease[4, 10-12].

This disease should be distinguished from angioedema, dermatomyositis, lupus erythematosus, chronic actinic dermatitis, skin tuberculosis, and sarcoidosis. The present patient had no history of allergy or family inheritance. The skin lesions showed infiltrating edema, which did not subside within a short time, and pruritus was not observed. Eosinophils were not increased, and antihistamine treatment was ineffective, which excluded angioedema. The patient had no violet erythema on the eyelids, no fatigue, no muscle soreness, no specific Gottron papules on the dorsal joints of the limbs, and no immunological positive indicators, and histopathology did not show liquefaction degeneration of basal cells or mucin deposition in the dermis, which excluded dermatomyositis. The patient's skin lesions were not butterfly erythema, without hair follicle horn plug and adherent scales, without light sensitivity, and with no abnormal immunological indicators and no mucin deposition in the dermis, which ruled out lupus erythematosus. The patient had no mossy lesions, no pruritus, no history of long-term outdoor exposure, and no light sensitivity; therefore, chronic actinic dermatitis was ruled out. The tuberculin test was negative, and lung examination showed no abnormalities; acid-fast staining, silver staining, and PAS staining were negative, and histopathology showed no caseous necrosis, thus excluding skin tuberculosis. The patient's lung was normal and histopathological findings showed no

tuberculous granuloma; therefore, sarcoidosis was ruled out. The patient presented with chronic non-pitting edema of the upper two-thirds of the face and no pruritus in the edematous area. Histopathology showed non-specific inflammation, and the final diagnosis was Morbihan disease.

In terms of the treatment of Morbihan disease, a review of the existing literature showed that most cases were treated with glucocorticoids and tetracycline antibiotics[10], and thalidomide treatment has also been reported[13]. The latest report shows that good results were achieved with isotretinoic acid combined with ketotifen for the treatment of Morbihan disease[14]. Glucocorticoids, tetracycline antibiotics, thalidomide, and isotretinoic acid agents have been reported to have direct or indirect anti-inflammatory effects, indicating that anti-inflammation is a very important treatment in this disease. The histopathological findings of nonspecific inflammation in Morbihan disease seem to support this.

Existing treatment methods for Morbihan disease have shortcomings such as long treatment cycle, disease recurrence after drug withdrawal, and multiple side effects. In the present case, the patient was treated with a glucocorticoid in the early stage, and inflammation was controlled within a short period. However, the disease recurred after reduction of the hormone, indicating that it is difficult to achieve a complete cure with only anti-inflammatory treatment. In addition to anti-inflammatory treatment, it is necessary to eliminate the initial factors causing inflammation. The clinical characteristics of this disease include chronic recurrence. Isotretinoic acid treatment of this disease has achieved good results, and analysis has found that isotretinoic acid has both anti-inflammatory and immunomodulatory effects, suggesting that inflammation in this disease may be related to immunity. The major disadvantages of isotretinoic acid are the occurrence of adverse reactions after long-term use, and patient's poor tolerance. There are reported cases of tripterygium wilfordii treatment achieving good results[15]. Our patient also received tripterygium wilfordii treatment, but developed elevated transaminase levels during treatment, and finally had to terminate tripterygium wilfordii. Therefore, it was necessary to identify an effective drug with few side effects.

Total glucosides of paeony is a Chinese patent medicine, which is extracted from *Radix paeoniae alba* and have anti-inflammatory[16], anti-organ injury[17], and immune regulation effects[18]. Total glucosides of paeony was approved by the China Food and Drug Administration for the treatment of rheumatoid arthritis in 1998, and its clinical therapeutic effect is remarkable[19]. In addition, total glucosides of paeony has been shown to be effective in the treatment of psoriasis[20], Sjogren's syndrome[21], and other autoimmune diseases. Studies have shown that total glucosides of paeony combined with other drugs has obvious advantages in treating autoimmune diseases, which can significantly alleviate the symptoms of patients and reduce the side effects of drugs. Some researchers used total glucosides of paeony combined with methotrexate (MTX) and leflunomide in the treatment of rheumatoid arthritis, which significantly reduced the toxic effect on the liver[22]. Feng *et al*[23] used total glucosides of paeony combined with MTX in the treatment of rheumatoid arthritis, and its efficacy was superior to that of MTX alone[23]. It has been shown that total glucosides of paeony plays an important role in multiple processes of autoimmune diseases, and inhibits the maturation of dendritic cells by selectively blocking the activation of the TLR4/5 signaling pathway in order to avoid immune-mediated inflammation[24]. In view of the significant effect of total glucosides of paeony on chronic inflammatory autoimmune diseases, the patient in this report was treated with total glucosides of paeony capsules, and the effect was obvious with no adverse reactions, and there was no recurrence after almost 1 year of drug withdrawal. The adverse reactions of total glucosides of paeony are rare, and the reported adverse reactions are only mild diarrhea[25]. According to the literature, diarrhea is the most likely adverse reaction of total glucosides of paeony in the treatment of Morbihan disease.

The pathophysiological mechanism of Morbihan disease is not fully understood. There is a relatively consistent view among researchers that edema in Morbihan disease is mainly caused by lymphatic obstruction or poor lymphatic return due to inflammation[26]. Studies have shown that the nitric oxide signaling pathway may be involved in the destruction of the integrity of lymphatic vessels[7], and total glucosides of paeony can effectively inhibit the production of nitric oxide and other inflammatory factors in macrophages in the rheumatoid arthritis model[27], and can play an anti-inflammatory role by inhibiting the activation and recruitment of inflammatory cells[28]. Therefore, it is speculated that the mechanism of total glucosides of paeony in the treatment of Morbihan disease is to maintain the integrity of lymphatic vessels and prevent the occurrence of edema through the similar anti-inflammatory mechanism mentioned above.

Morbihan disease is rare, and only one case has been reported in China to date. Therefore, it is difficult to carry out research on the multi-center large-sample treatment at present. However, the report of an effective treatment strategy in a single case may still be helpful in treating patients with Morbihan disease and in further study of this disease.

## CONCLUSION

Morbihan disease is rare, and no standard treatment is currently available. Reported treatments for Morbihan disease have shortcomings such as long medication cycle, disease recurrence after drug withdrawal, and many side effects. This patient was treated with total glucosides of paeony with good



effects and no adverse reactions. The patient was followed for almost 1 year without recurrence, suggesting that total glucoside of paeony is an effective agent for Morbihan disease. To our knowledge, this is the first reported case of Morbihan disease treated with total glucosides of paeony with good results.

## ACKNOWLEDGEMENTS

We sincerely thank all the medical staff who were involved in the treatment of this patient.

## FOOTNOTES

**Author contributions:** Zhou LF and Lu R contributed equally to this work; Zhou LF consulted and recorded the patient's medical history, reviewed the literature, collected the clinical data and images, and wrote the manuscript; Lu R participated in the formulation of the manuscript, literature search, collection of pathological images, image editing, and manuscript modification; all authors approved the final version for submission.

**Informed consent statement:** Informed consent was obtained from the patient for the publication of this case report.

**Conflict-of-interest statement:** All the authors report no relevant conflicts of interest for this article.

**CARE Checklist (2016) statement:** The authors have read the CARE Checklist (2016), and the manuscript was prepared and revised according to the CARE Checklist (2016).

**Open-Access:** This article is an open-access article that was selected by an in-house editor and fully peer-reviewed by external reviewers. It is distributed in accordance with the Creative Commons Attribution NonCommercial (CC BY-NC 4.0) license, which permits others to distribute, remix, adapt, build upon this work non-commercially, and license their derivative works on different terms, provided the original work is properly cited and the use is non-commercial. See: <https://creativecommons.org/licenses/by-nc/4.0/>

**Country/Territory of origin:** China

**ORCID number:** Li-Feng Zhou 0000-0003-0764-4151; Rong Lu 0000-0002-4153-045X.

**S-Editor:** Fan JR

**L-Editor:** Wang TQ

**P-Editor:** Fan JR

## REFERENCES

- 1 Gorin I, Gaitz JP, Chevrier C, Lessana-Leibowitch M, Fortier P, Escande JP. Maladie du Morbihan: Essais thérapeutiques. Deuxième présentation Paris: Abstract. Journées Dermatologiques de Paris 1991; 111
- 2 Lamparter J, Kottler U, Cursiefen C, Pfeiffer N, Pitz S. [Morbus Morbihan : A rare cause of edematous swelling of the eyelids]. *Ophthalmologie* 2010; **107**: 553-557 [PMID: 20024562 DOI: 10.1007/s00347-009-2083-1]
- 3 Connelly MG, Winkelmann RK. Solid facial edema as a complication of acne vulgaris. *Arch Dermatol* 1985; **121**: 87-90 [PMID: 3155606]
- 4 Nagasaka T, Koyama T, Matsumura K, Chen KR. Persistent lymphoedema in Morbihan disease: formation of perilymphatic epithelioid cell granulomas as a possible pathogenesis. *Clin Exp Dermatol* 2008; **33**: 764-767 [PMID: 18627384 DOI: 10.1111/j.1365-2230.2008.02892.x]
- 5 Scerri L, Saihan EM. Persistent facial swelling in a patient with rosacea. Rosacea lymphedema. *Arch Dermatol* 1995; **131**: 1071, 1074 [PMID: 7661614 DOI: 10.1001/archderm.131.9.1071]
- 6 Morales-Burgos A, Alvarez Del Manzano G, Sánchez JL, Cruz CL. Persistent eyelid swelling in a patient with rosacea. *P R Health Sci J* 2009; **28**: 80-82 [PMID: 19266745]
- 7 Scallan JP, Hill MA, Davis MJ. Lymphatic vascular integrity is disrupted in type 2 diabetes due to impaired nitric oxide signalling. *Cardiovasc Res* 2015; **107**: 89-97 [PMID: 25852084 DOI: 10.1093/cvr/cvv117]
- 8 Moriguchi P, Sannomiya P, Lara PF, Oliveira-Filho RM, Greco KV, Sudo-Hayashi LS. Lymphatic system changes in diabetes mellitus: role of insulin and hyperglycemia. *Diabetes Metab Res Rev* 2005; **21**: 150-157 [PMID: 15386809 DOI: 10.1002/dmrr.500]
- 9 Jungfer B, Jansen T, Przybilla B, Plewig G. Solid persistent facial edema of acne: successful treatment with isotretinoin and ketotifen. *Dermatology* 1993; **187**: 34-37 [PMID: 8324275 DOI: 10.1159/000247194]
- 10 Ranu H, Lee J, Hee TH. Therapeutic hotline: Successful treatment of Morbihan's disease with oral prednisolone and doxycycline. *Dermatol Ther* 2010; **23**: 682-685 [PMID: 21054712 DOI: 10.1111/j.1529-8019.2010.01373.x]
- 11 Hu SW, Robinson M, Meehan SA, Cohen DE. Morbihan disease. *Dermatol Online J* 2012; **18**: 27 [PMID: 23286817]
- 12 Vasconcelos RC, Eid NT, Eid RT, Moriya FS, Braga BB, Michalany AO. Morbihan syndrome: a case report and literature

- review. *An Bras Dermatol* 2016; **91**: 157-159 [PMID: 28300928 DOI: 10.1590/abd1806-4841.20164291]
- 13 **Laugier P**, Gilardi S. [Chronic erythematous oedema of the upper face (Degos). Morbihan disease (author's transl)]. *Ann Dermatol Venereol* 1981; **108**: 507-513 [PMID: 7305227]
- 14 **Mazzatenta C**, Giorgino G, Rubegni P, de Aloe G, Fimiani M. Solid persistent facial oedema (Morbihan's disease) following rosacea, successfully treated with isotretinoin and ketotifen. *Br J Dermatol* 1997; **137**: 1020-1021 [PMID: 9470933 DOI: 10.1111/j.1365-2133.1997.tb01577.x]
- 15 **Yu X**, Qu T, Jin H, Fang K. Morbihan disease treated with Tripterygium wilfordii successfully. *J Dermatol* 2018; **45**: e122-e123 [PMID: 29165836 DOI: 10.1111/1346-8138.14137]
- 16 **Wang C**, Yuan J, Wu HX, Chang Y, Wang QT, Wu YJ, Zhou P, Yang XD, Yu J, Wei W. Total glucosides of paeony inhibit the inflammatory responses of mice with allergic contact dermatitis by restoring the balanced secretion of pro-/anti-inflammatory cytokines. *Int Immunopharmacol* 2015; **24**: 325-334 [PMID: 25556068 DOI: 10.1016/j.intimp.2014.12.026]
- 17 **Su J**, Zhang P, Zhang JJ, Qi XM, Wu YG, Shen JJ. Effects of total glucosides of paeony on oxidative stress in the kidney from diabetic rats. *Phytomedicine* 2010; **17**: 254-260 [PMID: 19758795 DOI: 10.1016/j.phymed.2009.07.005]
- 18 **Deng H**, Yan C, Xiao T, Yuan D, Xu J. Total glucosides of Paeonia lactiflora Pall inhibit vascular endothelial growth factor-induced angiogenesis. *J Ethnopharmacol* 2010; **127**: 781-785 [PMID: 19914370 DOI: 10.1016/j.jep.2009.09.053]
- 19 **Luo J**, Jin DE, Yang GY, Zhang YZ, Wang JM, Kong WP, Tao QW. Total glucosides of paeony for rheumatoid arthritis: A systematic review of randomized controlled trials. *Complement Ther Med* 2017; **34**: 46-56 [PMID: 28917375 DOI: 10.1016/j.ctim.2017.07.010]
- 20 **Zheng Q**, Jiang W, Sun X, Ma T, Xu W, Shen F, Li H, Xie S, Li B, Li X. Total glucosides of paeony for the treatment of psoriasis: A systematic review and meta-analysis of randomized controlled trials. *Phytomedicine* 2019; **62**: 152940 [PMID: 31100680 DOI: 10.1016/j.phymed.2019.152940]
- 21 **Feng Z**, Zhang BQ, Zhu YM, Yu BB, Fu L, Zhou LL, Zhou XP, Lu Y. The Effectiveness and Safety of Total Glucosides of Paeony in Primary Sjögren's Syndrome: A Systematic Review and Meta-Analysis. *Front Pharmacol* 2019; **10**: 550 [PMID: 31178729 DOI: 10.3389/fphar.2019.00550]
- 22 **Xiang N**, Li XM, Zhang MJ, Zhao DB, Zhu P, Zuo XX, Yang M, Su Y, Li ZG, Chen Z, Li XP. Total glucosides of paeony can reduce the hepatotoxicity caused by Methotrexate and Leflunomide combination treatment of active rheumatoid arthritis. *Int Immunopharmacol* 2015; **28**: 802-807 [PMID: 26292180 DOI: 10.1016/j.intimp.2015.08.008]
- 23 **Feng ZT**, Xu J, He GC, Cai SJ, Li J, Mei ZG. A systemic review and meta-analysis of the clinical efficacy and safety of total glucosides of peony combined with methotrexate in rheumatoid arthritis. *Clin Rheumatol* 2018; **37**: 35-42 [PMID: 28748514 DOI: 10.1007/s10067-017-3770-y]
- 24 **Zhou Z**, Lin J, Huo R, Huang W, Zhang J, Wang L, Sun Y, Shen B, Li N. Total glucosides of paeony attenuated functional maturation of dendritic cells via blocking TLR4/5 signaling in vivo. *Int Immunopharmacol* 2012; **14**: 275-282 [PMID: 22846756 DOI: 10.1016/j.intimp.2012.07.012]
- 25 **Long JW**, Wang YY, Pi XM, Tu YT. Clinical observation on the treatment of chronic urticaria with total glucosides of paeony capsule combined with cetirizine. *Chin J Integr Med* 2010; **16**: 353-356 [PMID: 20697948 DOI: 10.1007/s11655-010-0504-2]
- 26 **Donthi D**, Nenow J, Samia A, Phillips C, Papalas J, Preshaw K. Morbihan disease: A diagnostic dilemma: two cases with successful resolution. *SAGE Open Med Case Rep* 2021; **9**: 2050313X211023655 [PMID: 34178345 DOI: 10.1177/2050313X211023655]
- 27 **He DY**, Dai SM. Anti-inflammatory and immunomodulatory effects of paeonia lactiflora pall., a traditional chinese herbal medicine. *Front Pharmacol* 2011; **2**: 10 [PMID: 21687505 DOI: 10.3389/fphar.2011.00010]
- 28 **Li H**, Cao XY, Dang WZ, Jiang B, Zou J, Shen XY. Total Glucosides of Paeony protects against collagen-induced mouse arthritis via inhibiting follicular helper T cell differentiation. *Phytomedicine* 2019; **65**: 153091 [PMID: 31654988 DOI: 10.1016/j.phymed.2019.153091]



Published by **Baishideng Publishing Group Inc**  
7041 Koll Center Parkway, Suite 160, Pleasanton, CA 94566, USA

**Telephone:** +1-925-3991568

**E-mail:** [bpgoffice@wjgnet.com](mailto:bpgoffice@wjgnet.com)

**Help Desk:** <https://www.f6publishing.com/helpdesk>

<https://www.wjgnet.com>

