

World Journal of *Clinical Cases*

World J Clin Cases 2022 January 14; 10(2): 397-752



Contents

Thrice Monthly Volume 10 Number 2 January 14, 2022

EDITORIAL

- 397 New trends in treatment of muscle fatigue throughout rehabilitation of elderlies with motor neuron diseases
Mohamed A

MINIREVIEWS

- 401 What emotion dimensions can affect working memory performance in healthy adults? A review
Hou TY, Cai WP
- 412 Quadrilateral plate fractures of the acetabulum: Classification, approach, implant therapy and related research progress
Zhou XF, Gu SC, Zhu WB, Yang JZ, Xu L, Fang SY

ORIGINAL ARTICLE

Case Control Study

- 426 Methylprednisolone accelerate chest computed tomography absorption in COVID-19: A three-centered retrospective case control study from China
Lin L, Xue D, Chen JH, Wei QY, Huang ZH

Retrospective Study

- 437 Analysis of photostimulable phosphor image plate artifacts and their prevalence
Elkhateeb SM, Aloyouny AY, Omer MMS, Mansour SM
- 448 N6-methyladenine-modified DNA was decreased in Alzheimer's disease patients
Lv S, Zhou X, Li YM, Yang T, Zhang SJ, Wang Y, Jia SH, Peng DT
- 458 Inflammation-related indicators to distinguish between gastric stromal tumors and leiomyomas: A retrospective study
Zhai YH, Zheng Z, Deng W, Yin J, Bai ZG, Liu XY, Zhang J, Zhang ZT
- 469 Relationship between Ki-67 and CD44 expression and microvascular formation in gastric stromal tumor tissues
Ma B, Huang XT, Zou GJ, Hou WY, Du XH
- 477 Modified surgical method of supra- and infratentorial epidural hematoma and the related anatomical study of the squamous part of the occipital bone
Li RC, Guo SW, Liang C
- 485 Combined molybdenum target X-ray and magnetic resonance imaging examinations improve breast cancer diagnostic efficacy
Gu WQ, Cai SM, Liu WD, Zhang Q, Shi Y, Du LJ

- 492 Value of thyroglobulin combined with ultrasound-guided fine-needle aspiration cytology for diagnosis of lymph node metastasis of thyroid carcinoma

Zhang LY, Chen Y, Ao YZ

- 502 Locking compression plate + T-type steel plate for postoperative weight bearing and functional recovery in complex tibial plateau fractures

Li HF, Yu T, Zhu XF, Wang H, Zhang YQ

- 511 Effect of Mirena placement on reproductive hormone levels at different time intervals after artificial abortion

Jin XX, Sun L, Lai XL, Li J, Liang ML, Ma X

- 518 Diagnostic value of artificial intelligence automatic detection systems for breast BI-RADS 4 nodules

Lyu SY, Zhang Y, Zhang MW, Zhang BS, Gao LB, Bai LT, Wang J

Clinical Trials Study

- 528 Analysis of 20 patients with laparoscopic extended right colectomy

Zheng HD, Xu JH, Liu YR, Sun YF

Observational Study

- 538 Knowledge, attitude, practice and factors that influence the awareness of college students with regards to breast cancer

Zhang QN, Lu HX

- 547 Diagnosing early scar pregnancy in the lower uterine segment after cesarean section by intracavitary ultrasound

Cheng XL, Cao XY, Wang XQ, Lin HL, Fang JC, Wang L

- 554 Impact of failure mode and effects analysis-based emergency management on the effectiveness of craniocerebral injury treatment

Shao XL, Wang YZ, Chen XH, Ding WJ

- 563 Predictive value of alarm symptoms in Rome IV irritable bowel syndrome: A multicenter cross-sectional study

Yang Q, Wei ZC, Liu N, Pan YL, Jiang XS, Tantai XX, Yang Q, Yang J, Wang JJ, Shang L, Lin Q, Xiao CL, Wang JH

Prospective Study

- 576 5-min mindfulness audio induction alleviates psychological distress and sleep disorders in patients with COVID-19

Li J, Zhang YY, Cong XY, Ren SR, Tu XM, Wu JF

META-ANALYSIS

- 585 Efficacy and safety of argatroban in treatment of acute ischemic stroke: A meta-analysis

Ly B, Guo FF, Lin JC, Jing F

SCIENTOMETRICS

- 594 Biologic therapy for Crohn's disease over the last 3 decades
Shen JL, Zhou Z, Cao JS, Zhang B, Hu JH, Li JY, Liu XM, Juengpanich S, Li MS, Feng X

CASE REPORT

- 607 Novel compound heterozygous GPR56 gene mutation in a twin with lissencephaly: A case report
Lin WX, Chai YY, Huang TT, Zhang X, Zheng G, Zhang G, Peng F, Huang YJ
- 618 Patients with SERPINC1 rs2227589 polymorphism found to have multiple cerebral venous sinus thromboses despite a normal antithrombin level: A case report
Liao F, Zeng JL, Pan JG, Ma J, Zhang ZJ, Lin ZJ, Lin LF, Chen YS, Ma XT
- 625 Successful management of delirium with dexmedetomidine in a patient with haloperidol-induced neuroleptic malignant syndrome: A case report
Yang CJ, Chiu CT, Yeh YC, Chao A
- 631 Malignant solitary fibrous tumor in the central nervous system treated with surgery, radiotherapy and anlotinib: A case report
Zhang DY, Su L, Wang YW
- 643 Anesthesia and perioperative management for giant adrenal Ewing's sarcoma with inferior vena cava and right atrium tumor thrombus: A case report
Wang JL, Xu CY, Geng CJ, Liu L, Zhang MZ, Wang H, Xiao RT, Liu L, Zhang G, Ni C, Guo XY
- 656 Full-endoscopic spine surgery treatment of lumbar foraminal stenosis after osteoporotic vertebral compression fractures: A case report
Zhao QL, Hou KP, Wu ZX, Xiao L, Xu HG
- 663 Ethambutol-induced optic neuropathy with rare bilateral asymmetry onset: A case report
Sheng WY, Wu SQ, Su LY, Zhu LW
- 671 Vitrectomy with residual internal limiting membrane covering and autologous blood for a secondary macular hole: A case report
Ying HF, Wu SQ, Hu WP, Ni LY, Zhang ZL, Xu YG
- 677 Intervertebral bridging ossification after kyphoplasty in a Parkinson's patient with Kummell's disease: A case report
Li J, Liu Y, Peng L, Liu J, Cao ZD, He M
- 685 Synovial chondromatosis of the hip joint in a 6 year-old child: A case report
Yi RB, Gong HL, Arthur DT, Wen J, Xiao S, Tang ZW, Xiang F, Wang KJ, Song ZQ
- 691 Orthodontic retreatment of an adult woman with mandibular backward positioning and temporomandibular joint disorder: A case report
Yu LY, Xia K, Sun WT, Huang XQ, Chi JY, Wang LJ, Zhao ZH, Liu J

- 703** Autosomal recessive spinocerebellar ataxia type 4 with a *VPS13D* mutation: A case report
Huang X, Fan DS
- 709** Primary adrenal diffuse large B-cell lymphoma with normal adrenal cortex function: A case report
Fan ZN, Shi HJ, Xiong BB, Zhang JS, Wang HF, Wang JS
- 717** Varicella-zoster virus-associated meningitis, encephalitis, and myelitis with sporadic skin blisters: A case report
Takami K, Kenzaka T, Kumabe A, Fukuzawa M, Eto Y, Nakata S, Shinohara K, Endo K
- 725** Tension pneumocephalus following endoscopic resection of a mediastinal thoracic spinal tumor: A case report
Chang CY, Hung CC, Liu JM, Chiu CD
- 733** Accelerated Infliximab Induction for Severe Lower Gastrointestinal Bleeding in a Young Patient with Crohn's Disease: A Case Report
Zeng J, Shen F, Fan JG, Ge WS
- 741** Occupational fibrotic hypersensitivity pneumonia in a halogen dishes manufacturer: A case report
Wang M, Fang HH, Jiang ZF, Ye W, Liu RY
- 747** Using a fretsaw in treating chronic penial incarceration: A case report
Zhao Y, Xue XQ, Huang HF, Xie Y, Ji ZG, Fan XR

ABOUT COVER

Associate Editor of *World Journal of Clinical Cases*, Bruno Ramos Chrcanovic, DDS, MSc, PhD, Associate Professor, Department of Prosthodontics, Malmö University, Malmö 241 21, Sweden. bruno.chrcanovic@mau.se

AIMS AND SCOPE

The primary aim of *World Journal of Clinical Cases* (WJCC, *World J Clin Cases*) is to provide scholars and readers from various fields of clinical medicine with a platform to publish high-quality clinical research articles and communicate their research findings online.

WJCC mainly publishes articles reporting research results and findings obtained in the field of clinical medicine and covering a wide range of topics, including case control studies, retrospective cohort studies, retrospective studies, clinical trials studies, observational studies, prospective studies, randomized controlled trials, randomized clinical trials, systematic reviews, meta-analysis, and case reports.

INDEXING/ABSTRACTING

The WJCC is now indexed in Science Citation Index Expanded (also known as SciSearch®), Journal Citation Reports/Science Edition, Scopus, PubMed, and PubMed Central. The 2021 Edition of Journal Citation Reports® cites the 2020 impact factor (IF) for WJCC as 1.337; IF without journal self cites: 1.301; 5-year IF: 1.742; Journal Citation Indicator: 0.33; Ranking: 119 among 169 journals in medicine, general and internal; and Quartile category: Q3. The WJCC's CiteScore for 2020 is 0.8 and Scopus CiteScore rank 2020: General Medicine is 493/793.

RESPONSIBLE EDITORS FOR THIS ISSUE

Production Editor: *Jia-Hui Li*; Production Department Director: *Xu Guo*; Editorial Office Director: *Jim-Lai Wang*.

NAME OF JOURNAL

World Journal of Clinical Cases

ISSN

ISSN 2307-8960 (online)

LAUNCH DATE

April 16, 2013

FREQUENCY

Thrice Monthly

EDITORS-IN-CHIEF

Bao-Gan Peng, Jerzy Tadeusz Chudek, George Kontogeorgos, Maurizio Serati, Ja Hyeon Ku

EDITORIAL BOARD MEMBERS

<https://www.wjgnet.com/2307-8960/editorialboard.htm>

PUBLICATION DATE

January 14, 2022

COPYRIGHT

© 2022 Baishideng Publishing Group Inc

INSTRUCTIONS TO AUTHORS

<https://www.wjgnet.com/bpg/gerinfo/204>

GUIDELINES FOR ETHICS DOCUMENTS

<https://www.wjgnet.com/bpg/GerInfo/287>

GUIDELINES FOR NON-NATIVE SPEAKERS OF ENGLISH

<https://www.wjgnet.com/bpg/gerinfo/240>

PUBLICATION ETHICS

<https://www.wjgnet.com/bpg/GerInfo/288>

PUBLICATION MISCONDUCT

<https://www.wjgnet.com/bpg/gerinfo/208>

ARTICLE PROCESSING CHARGE

<https://www.wjgnet.com/bpg/gerinfo/242>

STEPS FOR SUBMITTING MANUSCRIPTS

<https://www.wjgnet.com/bpg/GerInfo/239>

ONLINE SUBMISSION

<https://www.f6publishing.com>

Varicella-zoster virus-associated meningitis, encephalitis, and myelitis with sporadic skin blisters: A case report

Ken Takami, Tsuneaki Kenzaka, Ayako Kumabe, Megumi Fukuzawa, Yoko Eto, Shun Nakata, Katsuhiro Shinohara, Kazunori Endo

ORCID number: Ken Takami 0000-0002-6257-5163; Tsuneaki Kenzaka 0000-0002-3120-6605; Ayako Kumabe 0000-0002-2595-3487; Megumi Fukuzawa 0000-0001-5228-9430; Yoko Eto 0000-0001-6554-9887; Shun Nakata 0000-0002-8798-4617; Katsuhiro Shinohara 0000-0002-1776-4352; Kazunori Endo 0000-0002-0597-2162.

Author contributions: Takami K, Fukuzawa M, Eto Y, Nakata S, and Shinohara K managed the case, and prepared and revised the manuscript; Kenzaka T, Kumabe A, and Endo K assisted with the preparation and revision of the manuscript; all co-authors approved the final manuscript as submitted and agree to be accountable for all aspects of the work; all co-authors take full responsibility for the integrity of the study and the final manuscript.

Informed consent statement: Informed written consent was obtained from the patient for publication of this report and any accompanying images.

Conflict-of-interest statement: The authors declare that they have no conflict of interest.

CARE Checklist (2016) statement: The authors have read the CARE Checklist (2016), and the

Ken Takami, Kazunori Endo, Department of Internal Medicine, Sainokuni Higashiomiya Medical Center, Saitama 331-8577, Saitama, Japan

Tsuneaki Kenzaka, Ayako Kumabe, Division of Community Medicine and Career Development, Kobe University Graduate School of Medicine, Kobe 652-0032, Hyogo, Japan

Megumi Fukuzawa, Department of Neurology, Sainokuni Higashiomiya Medical Center, Saitama 331-8577, Saitama, Japan

Yoko Eto, Department of Dermatology, Sainokuni Higashiomiya Medical Center, Saitama 331-8577, Saitama, Japan

Shun Nakata, Katsuhiro Shinohara, Emergency Department, Sainokuni Higashiomiya Medical Center, Saitama 331-8577, Saitama, Japan

Corresponding author: Tsuneaki Kenzaka, MD, PhD, Professor, Division of Community Medicine and Career Development, Kobe University Graduate School of Medicine, No. 2-1-5 Arata-cho, Hyogo-ku, Kobe 652-0032, Hyogo, Japan. smile.kenzaka@jichi.ac.jp

Abstract

BACKGROUND

Varicella-zoster virus (VZV) generally causes chickenpox at first infection in childhood and then establishes latent infection in the dorsal root ganglia of the spinal cord or other nerves. Virus reactivation owing to an impaired immune system causes inflammation along spinal nerves from the affected spinal segment, leading to skin manifestations (herpes zoster). Viremia and subsequent hematogenous transmission and nerve axonal transport of the virus may lead to meningitis, encephalitis, and myelitis. One such case is described in this study.

CASE SUMMARY

A 64-year-old man presented with dysuria, pyrexia, and progressive disturbance in consciousness. He had signs of meningeal irritation, and cerebrospinal fluid (CSF) analysis revealed marked pleocytosis with mononuclear predominance and a CSF/serum glucose ratio of 0.64. Head magnetic resonance imaging revealed hyperintense areas in the frontal lobes. He had four isolated blisters with papules and halos on his right chest, right lumbar region, and left scapular region. Infected giant cells were detected using the Tzanck test. Degenerated epidermal cells with intranuclear inclusion bodies and ballooning degeneration were present on skin

manuscript was prepared and revised according to the CARE Checklist (2016).

Country/Territory of origin: Japan

Specialty type: Medicine, general and internal

Provenance and peer review: Unsolicited article; Externally peer reviewed.

Peer-review model: Single blind

Peer-review report's scientific quality classification

Grade A (Excellent): 0
Grade B (Very good): 0
Grade C (Good): C
Grade D (Fair): 0
Grade E (Poor): 0

Open-Access: This article is an open-access article that was selected by an in-house editor and fully peer-reviewed by external reviewers. It is distributed in accordance with the Creative Commons Attribution NonCommercial (CC BY-NC 4.0) license, which permits others to distribute, remix, adapt, build upon this work non-commercially, and license their derivative works on different terms, provided the original work is properly cited and the use is non-commercial. See: <https://creativecommons.org/licenses/by-nc/4.0/>

Received: August 18, 2021

Peer-review started: August 18, 2021

First decision: November 1, 2021

Revised: November 11, 2021

Accepted: December 11, 2021

Article in press: December 11, 2021

Published online: January 14, 2022

P-Reviewer: Sotelo J

S-Editor: Wang JL

L-Editor: A

P-Editor: Wang JL



biopsy. Serum VZV antibody titers suggested previous infection, and the CSF tested positive for VZV-DNA. He developed paraplegia, decreased temperature perception in the legs, urinary retention, and fecal incontinence. The patient was diagnosed with meningitis, encephalitis, and myelitis and was treated with acyclovir for 23 days and prednisolone for 14 days. Despite gradual improvement, the urinary retention and gait disturbances persisted as sequelae.

CONCLUSION

VZV reactivation should be considered in differential diagnoses of patients with sporadic blisters and unexplained central nervous system symptoms.

Key Words: Varicella-zoster virus; Encephalitis; Meningitis; Myelitis; Central nervous system; Case report

©The Author(s) 2022. Published by Baishideng Publishing Group Inc. All rights reserved.

Core Tip: We describe a rare case of multiple central nervous system (CNS) complications following varicella zoster virus (VZV) reactivation in an immunocompetent patient with mild diabetes. He had four isolated blisters with encephalitis, meningitis, and myelitis. VZV reactivation should be considered in the differential diagnosis of patients with sporadic blisters and unexplained CNS symptoms.

Citation: Takami K, Kenzaka T, Kumabe A, Fukuzawa M, Eto Y, Nakata S, Shinohara K, Endo K. Varicella-zoster virus-associated meningitis, encephalitis, and myelitis with sporadic skin blisters: A case report. *World J Clin Cases* 2022; 10(2): 717-724

URL: <https://www.wjgnet.com/2307-8960/full/v10/i2/717.htm>

DOI: <https://dx.doi.org/10.12998/wjcc.v10.i2.717>

INTRODUCTION

The varicella-zoster virus (VZV) generally causes chickenpox at its first infection in childhood and then establishes latent infection in the dorsal root ganglia of the spinal cord or other nerves[1]. When reactivated owing to impaired systemic immune function, the virus causes inflammation along the spinal nerves from the spinal segment affected by the latent infection, leading to skin manifestations (herpes zoster) [1]. Viremia and subsequent hematogenous transmission and nerve axonal transport of the virus may lead to meningitis, encephalitis, and myelitis[2].

Upon VZV reactivation, viremia is usually absent[3], and viral particles are transported *via* the nerves. However, in immunocompromised hosts, skin lesions can be more extensive and severe, and viral replication in epithelial cells may result in viremia[4]. In severely immunocompromised hosts, VZV can be disseminated to the lungs, liver, central nervous system (CNS), and other tissues. Myelitis is a relatively common complication of herpes zoster[5] and is considered to be caused by the spread of VZV from the dorsal root ganglia to the spinal cord at the spinal level affected by skin rashes[6].

Here, we report about a very rare case of concurrent meningitis, encephalitis, and myelitis caused by VZV reactivation in a patient with just a few blisters.

CASE PRESENTATION

Chief complaints

Fever, progressive disturbance in consciousness.

History of present illness

The patient was a 64-year-old man. He was transported by ambulance with urinary retention and pyrexia of > 38 °C that persisted for several days as well as progressive disturbance in consciousness.

History of past illness

He did not have regular health checkups and there was no significant medical history. He had an uncertain history of chickenpox in childhood and no history of varicella vaccination. He tested negative for human immunodeficiency virus (HIV) and had no history of bone marrow transplantation or other known conditions associated with immunosuppression.

Personal and family history

He had consumed 540 mL of Japanese sake (60 g of alcohol) and smoked 20 cigarettes per day since the age of 20 years.

Physical examination

The patient's body temperature was 37.2 °C, blood pressure was 182/107 mmHg, heart rate was 106 beats/min and regular, and his respiratory rate was 21 breaths/min; and SpO₂ of 99% in room air. Neurological examination showed a Glasgow Coma Scale score of E4V3M5, pupils equal in size (3 mm/3 mm), round, and reactive to light (+/+), positive nuchal rigidity, and negative Kernig's sign. The tendon reflexes were markedly increased, predominantly in the lower extremities, with a positive Babinski sign bilaterally. There was no obvious quadriplegia.

Skin findings included four isolated and sporadic blisters with red papules and a red halo in the right anterior/Lateral chest, right lumbar region, and left scapular region (Figure 1).

Laboratory examinations

We detected infected giant cells using the Tzanck test and degenerated epidermal cells with intranuclear inclusion bodies and ballooning degeneration on skin biopsy of blisters in the right chest (Figure 2); these findings were consistent with VZV infection.

Mild increase in blood glucose levels (174 mg/dL) and HbA1c level (6.8%) suggestive of diabetes were noted. No increase in inflammatory response was observed (White blood cell count 5800 cells/ μ L, C-reactive protein 0.15 mg/L). There was no evidence of impaired humoral immunity with a negative HIV antibody test. Serum VZV antibody titers were 75.9 (+) for VZV immunoglobulin G (IgG) (EIA) and 0.49 (–) for VZV immunoglobulin M (IgM) (EIA), which is a pattern indicative of a previous infection. Cerebrospinal fluid (CSF) analysis (Table 1) showed marked pleocytosis with mononuclear predominance, with no decrease in the CSF/serum glucose ratio (0.64). The CSF tested positive for VZV-DNA with 1.4×10^6 copies/mL.

Imaging examinations

For symptoms associated with frontal lobe disorders such as altered personality and talkativeness that occurred after admission, the patient underwent plain head magnetic resonance imaging (MRI) on hospital day 3 (Figure 3). Diffusion-weighted imaging revealed hyperintensities in the bilateral frontal lobes. Although not evident immediately after admission, paraplegia became apparent after private room isolation was discontinued and rehabilitation was started. Decreased thermal nociception and urinary retention and rectal disturbances were also noted.

Contrast-enhanced thoracolumbar MRI (Figure 3) performed on hospital day 14 showed diffuse enhancement of the meninges at Th9 to L5 with lumbar predominance and no enhancement of the cord itself. Concurrent myelitis was diagnosed based on the diagnostic criteria proposed by the Transverse Myelitis Consortium Working Group[7] although contrast-enhanced MRI of the thoracolumbar spine showed no clear enhancement of the spinal cord.

FINAL DIAGNOSIS

Based on these findings, we diagnosed meningitis, encephalitis, and myelitis caused by VZV reactivation.

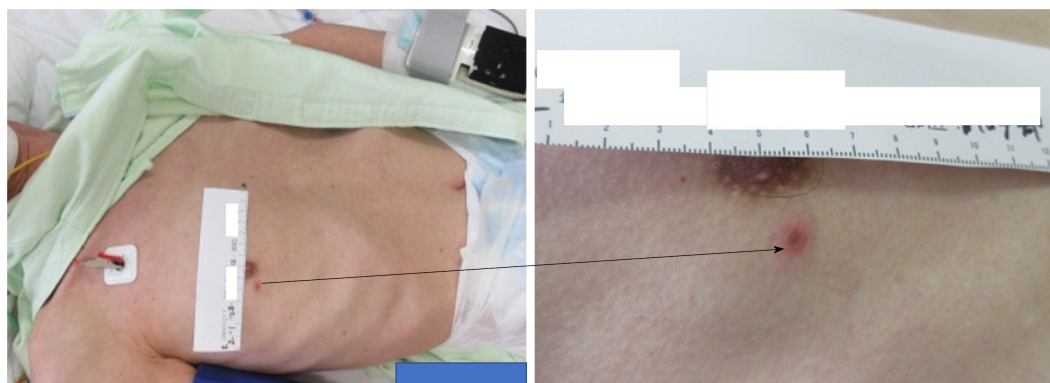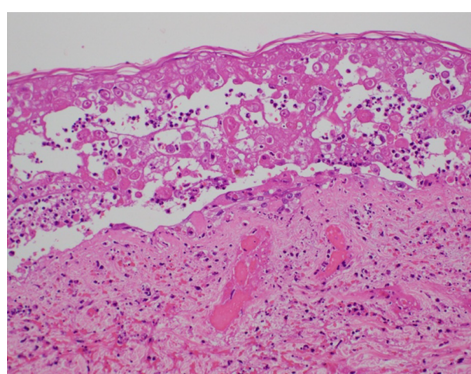
TREATMENT

Treatment was initiated with 500 mg acyclovir intravenously three times a day (for 23 days) and prednisolone at 60 mg (1.5 mg/kg)/d (tapered, for 14 days), resulting in a gradual improvement of symptoms.

Table 1 Results of cerebrospinal fluid analysis on admission

Parameter	Patient's value	Reference value
Color	Light yellow	Clear
Xanthochromia	Positive	Negative
Cell count (cells/ μ L)	484	0–3
Monocyte count (cells/ μ L)	448	0–3
Neutrophil count (cells/ μ L)	36	0–3
Total protein (mg/dL)	788	10–40
Glucose (mg/dL)	111	50–75
HSV antibody titer (CFT)	Negative	Negative
HSV-DNA (PCR) (copies/mL)	Negative	Negative
VZV antibody titer (CFT)	4	Negative
VZV-DNA (PCR) (copies/mL)	1.4×10^6	Negative

CFT: Complement fixation test; HSV: Herpes simplex virus; PCR: Polymerase chain reaction; VZV: Varicella-zoster virus.

**Figure 1** The skin lesion on the right chest.**Figure 2** Skin biopsy of the lesion on the right chest. The lesion shows intranuclear inclusion bodies and ballooning degeneration.

Changes in the serum VZV antibody titer and CSF analysis results are shown in [Table 2](#). Results of the CSF analysis showed a steady decrease in cell count, and on hospital day 16, the CSF was confirmed to be negative for VZV-DNA. The CSF VZV antibody titer increased more than 8-fold. Regarding serum VZV antibody titers, a significant increase in IgG was noted, whereas no apparent IgM seroconversion was observed. Symptoms of frontal lobe disorders improved with treatment. Plain head MRI performed on hospital day 39 revealed the disappearance of the frontal lobe

Table 2 The patient's clinical course

Day	1	9	16	23
CSF cell count (cells/ μ L)	484	112	119	29
CSF VZV antibody titer (CFT)	4		32	
CSF VZV-DNA (PCR) (copies/mL)	1.4×10^6	3.2×10^2	(-)	(-)
Serum VZV-IgM (EIA)	0.49 (-)	0.95 (\pm)	0.44 (-)	
Serum VZV-IgG (EIA)	75.9 (+)	> 128 (+)	> 128 (+)	

CSF: Cerebrospinal fluid; VZV: Varicella-zoster virus; CFT: Complement fixation test; PCR: Polymerase chain reaction; IgM: Immunoglobulin M; EIA: Enzyme immunoassay; IgG: Immunoglobulin G.

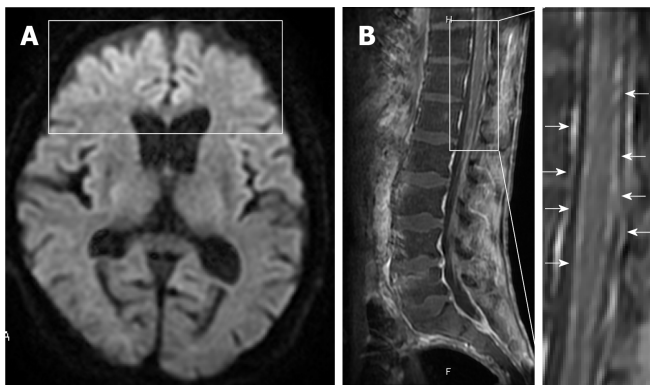


Figure 3 Axial diffusion-weighted magnetic resonance imaging on day 3 and sagittal contrast-enhanced T1-weighted magnetic resonance imaging on day 14. A: The images show hyperintensities in the bilateral frontal lobes (block); B: Diffuse enhancement of meninges (arrows) with lumbar predominance and no cord enhancement.

hyperintensities. The patient continued rehabilitation and showed a slight improvement in condition. However, the urge to urinate did not recover. In addition, gait disturbance and urinary retention associated with myelitis persisted as sequelae.

OUTCOME AND FOLLOW-UP

On hospital day 60, the patient was transferred to another hospital for continued rehabilitation. Two months after the transfer, the patient developed lacunar infarction which was treated conservatively. Thereafter, he continued rehabilitation and was discharged home with an activities of daily living grade corresponding to independent wheelchair operation.

DISCUSSION

In this case report, the patient with mild diabetes but no apparent immunodeficiency developed meningitis, encephalitis, and myelitis owing to VZV reactivation. This was a very rare case with only sporadic blisters accompanied by multiple CNS complications. CNS involvement has been reported as a rare complication of VZV infection, with an incidence of 0.1%–0.3% and 35% in immunocompetent and immunocompromised individuals, respectively[8]. Our literature search found only a few cases of multiple CNS complications caused by VZV, including eight cases of concurrent meningitis, encephalitis, and myelitis[8–14].

The early detection of blisters on emergency arrival led to a strong suspicion and early diagnosis of VZV meningitis in our case. Concurrent myelitis was diagnosed based on the diagnostic criteria proposed by the Transverse Myelitis Consortium Working Group[7] although contrast-enhanced MRI of the thoracolumbar spine showed no clear enhancement of the spinal cord. Despite the prompt initiation of

treatment with acyclovir and steroid, gait disturbance and urinary retention associated with myelitis persisted as sequelae.

The reported risk factors for herpes zoster include advanced age, cellular immunodeficiency (an immunocompromised host), diabetes, female sex, genetic susceptibility, mechanical trauma, recent mental stress, and white race, with the most important risk factor being advanced age[16]. A study examining the correlation between age, herpes zoster incidence, and VZV-specific cellular immunity showed a gradual decline in VZV-specific cellular immunity and increased incidence of herpes zoster with increasing age[17]. Studies also showed that diabetes patients have lower VZV-specific cellular immunity than healthy individuals[18]. NK cells[19], ADCC activity[20], and cytotoxic T lymphocytes[21] are considered to play more important roles than humoral immunity in suppressing viral growth. A decrease in these cellular immunity components appears to contribute to the development of severe infection [22]. In our case, it is also likely that decreased cellular immunity owing to aging and mild diabetes played a role in the development of severe illness.

VZV reaches the nervous system either *via* the bloodstream or by spreading directly from the sensory ganglia, where the virus establishes latent infection, causing CNS complications[23]. In herpes zoster, VZV that is reactivated in the dorsal root ganglia can spread to the spinal cord at the level affected by skin rashes, resulting in myelitis [6]. In our case, the skin rash did not occur along the dermatome as it does in herpes zoster. It appeared in a similar way to chickenpox where the skin areas innervated by the spinal cord, and the level of rash did not match.

Table 3 compares the eight previously reported cases[8-14] of concurrent meningitis, encephalitis, and myelitis caused by VZV reactivation with our case. Although CNS complications of VZV infection are more common in immunocompromised individuals, no underlying disease was identified in three cases. These patients had no predisposing factors for immunosuppression, such as acquired immunodeficiency syndrome, prior organ transplant, or use of oral immunosuppressants. Therefore, it is likely that decreased immunity caused by aging and other factors led to the reactivation of VZV. Among the previously reported cases, only one patient had a skin rash with C8-Th3 distribution[9]. The other seven patients presented neurological complications of VZV without skin symptoms, which is consistent with zoster sine herpete (ZSH)[24]. Our patient had only four sporadic blisters with no band-like cluster of skin eruptions. Bilateral blisters are an uncommon dermic manifestation of VZV in geriatrics, but his disseminated herpes zoster caused bilateral sporadic skin eruptions. The simultaneous onset of meningitis, encephalitis, and myelitis could occur in immunocompetent patients, with none or a few eruptions rather than typical herpes zoster.

The skin rash in our patient appeared like a chickenpox rash, and the possibility of reinfection with VZV was also considered. However, a high serum VZV-IgG level on admission and the absence of VZV-IgM seroconversion over time suggested that VZV reactivation was more likely the cause. Generally, herpes zoster does not manifest itself in an immunocompetent host, and whether lesions are formed depends on the host's immune status. In the event of virus reactivation, individuals with an active immune system may develop ZSH with only prodromal pain and no skin lesions. A previous report documented that 44% of patients with VZV infection in the CNS had no skin rash[25]. In ZSH, CD4+ T cells and CD8+ memory T cells expressing skin-homing receptors are considered to provide innate immunity to suppress the spread of VZV between skin cells, thereby preventing skin rash manifestation[26]. The number of skin eruptions caused by VZV correlates with the amount of virus in circulation before their manifestation[27], and therefore, delayed occurrence of an immune response can lead to the deeper and broader spread of the viral infection and severe lesions. The number and severity of skin eruptions were low in our patient, probably owing to the low viral load in circulation because the skin eruptions were caused by reactivation, not reinfection, of the virus from the previous infection.

Patients with mild skin rash may develop severe illness, similar to our patient. This highlights the importance of early recognition of blisters through skin examination of the entire body and considering VZV infection as a differential diagnosis even if the patient has isolated and sporadic blisters. It is also important to consider VZV infection when diagnosing a patient with unexplained CNS symptoms.

CONCLUSION

We reported a rare case of concurrent meningitis, encephalitis, and myelitis owing to

Table 3 Summary of studies on VZV-associated meningitis, encephalitis, and myelitis

Case	First Author (yr)	Ref	Age (yr)	Sex	Underlying diseases	Rash	Treatment	Outcome
1	Mancardi (1987)	8	32	F	None	None	Acyclovir	Survived
2	Kleinschmidt-DeMasters (1996)	9	69	F	Steroid dependent asthma	C8-Th3 distribution zoster	Not reported	Died
3	Kleinschmidt-DeMasters (1996)	9	36	M	HIV	None	Not reported	Died
4	Cinque (1997)	10	Not reported	Not reported	HIV	None	Acyclovir	Died
5	Sissoko (1998)	11	75	M	None	None	Acyclovir	Survived
6	Russman (2003)	12	51	F	Steroid dependent CREST syndrome	None	Acyclovir	Survived
7	Tavazzi (2008)	13	85	F	None	None	Acyclovir	Died
8	Tizazu (2020)	14	53	F	Steroid dependent SLE	None	Acyclovir	Survived
9	Takami (2021)	Present case	64	M	Mild diabetes mellitus	Four sporadic blisters	Acyclovir	Survived

HIV: Human immunodeficiency virus; SLE: Systemic lupus erythematosus; F: Female; M: Male.

VZV reactivation in a 64-year-old patient with mild diabetes but with no apparent immunodeficiency. The patient had a small number of blisters. Based on our case findings, VZV infection should be considered a differential diagnosis in patients with sporadic blisters or unexplained CNS symptoms.

REFERENCES

- 1 Arvin AM. Varicella-zoster virus. *Clin Microbiol Rev* 1996; **9**: 361-381 [PMID: 8809466 DOI: 10.1128/CMR.9.3.361]
- 2 Nagel MA, Gilden D. Neurological complications of varicella zoster virus reactivation. *Curr Opin Neurol* 2014; **27**: 356-360 [PMID: 24792344 DOI: 10.1097/WCO.0000000000000092]
- 3 Kimura H, Kido S, Ozaki T, Tanaka N, Ito Y, Williams RK, Morishima T. Comparison of quantitations of viral load in varicella and zoster. *J Clin Microbiol* 2000; **38**: 2447-2449 [PMID: 10835029 DOI: 10.1128/JCM.38.6.2447-2449.2000]
- 4 Vafai A, Wroblewska Z, Graf L. Antigenic cross-reaction between a varicella-zoster virus nucleocapsid protein encoded by gene 40 and a herpes simplex virus nucleocapsid protein. *Virus Res* 1990; **15**: 163-174 [PMID: 2157317 DOI: 10.1016/0168-1702(90)90006-w]
- 5 Steiner I, Steiner-Birmanns B, Levin N, Hershko K, Korn-Lubetzki I, Biran I. Spinal cord involvement in uncomplicated herpes zoster. *Clin Diagn Lab Immunol* 2001; **8**: 850-851 [PMID: 11427442 DOI: 10.1128/CDLI.8.4.850-851.2001]
- 6 Steiner I, Kennedy PG, Pachner AR. The neurotropic herpes viruses: herpes simplex and varicella-zoster. *Lancet Neurol* 2007; **6**: 1015-1028 [PMID: 17945155 DOI: 10.1016/S1474-4422(07)70267-3]
- 7 De La Blanchardiere A, Rozenberg F, Caumes E, Picard O, Lionnet F, Livartowski J, Coste J, Sicard D, Lebon P, Salmon-Ceron D. Neurological complications of varicella-zoster virus infection in adults with human immunodeficiency virus infection. *Scand J Infect Dis* 2000; **32**: 263-269 [PMID: 10879596 DOI: 10.1080/00365540050165893]
- 8 Mancardi GL, Melioli G, Traverso F, Tabaton M, Farinelli M, Terragna A. Zoster sine herpete causing encephalomyelitis. *Ital J Neurol Sci* 1987; **8**: 67-70 [PMID: 3032844 DOI: 10.1007/BF02361439]
- 9 Kleinschmidt-DeMasters BK, Amlie-Lefond C, Gilden DH. The patterns of varicella zoster virus encephalitis. *Hum Pathol* 1996; **27**: 927-938 [PMID: 8816888 DOI: 10.1016/s0046-8177(96)90220-8]
- 10 Cinque P, Bossolasco S, Vago L, Fornara C, Lipari S, Racca S, Lazzarin A, Linde A. Varicella-zoster virus (VZV) DNA in cerebrospinal fluid of patients infected with human immunodeficiency virus: VZV disease of the central nervous system or subclinical reactivation of VZV infection? *Clin Infect Dis* 1997; **25**: 634-639 [PMID: 9314452 DOI: 10.1086/513754]
- 11 Sissoko D, Bellagra N, Dewilde A, Rogelet P, Hober D, Wattré P. [Varicella-zoster virus meningo-encephalomyelitis without skin eruption]. *Ann Biol Clin (Paris)* 1998; **56**: 211-212 [PMID: 9754250]
- 12 Russman AN, Lederman RJ, Calabrese LH, Embi PJ, Forghani B, Gilden DH. Multifocal varicella-zoster virus vasculopathy without rash. *Arch Neurol* 2003; **60**: 1607-1609 [PMID: 14623735 DOI: 10.1001/archneur.60.11.1607]

- 13 **Tavazzi E**, Minoli L, Ferrante P, Scagnelli P, Del Bue S, Romani A, Ravaglia S, Marchioni E. Varicella zoster virus meningo-encephalo-myelitis in an immunocompetent patient. *Neurol Sci* 2008; **29**: 279-283 [PMID: [18810606](#) DOI: [10.1007/s10072-008-0982-6](#)]
- 14 **Tizazu EF**, Chang G, Berger JR. Varicella zoster virus (VZV) oculomeningoencephalomyelorradiculitis: a previously undescribed constellation. *J Neurovirol* 2020; **26**: 433-436 [PMID: [31858485](#) DOI: [10.1007/s13365-019-00820-4](#)]
- 15 **Transverse Myelitis Consortium Working Group**. Proposed diagnostic criteria and nosology of acute transverse myelitis. *Neurology* 2002; **59**: 499-505 [PMID: [12236201](#) DOI: [10.1212/wnl.59.4.499](#)]
- 16 **Gershon AA**, Gershon MD, Breuer J, Levin MJ, Oaklander AL, Griffiths PD. Advances in the understanding of the pathogenesis and epidemiology of herpes zoster. *J Clin Virol* 2010; **48**: S2-S7 [PMID: [20510263](#) DOI: [10.1016/S1386-6532\(10\)70002-0](#)]
- 17 **Takao Y**, Miyazaki Y, Onishi F, Kumihashi H, Gomi Y, Ishikawa T, Okuno Y, Mori Y, Asada H, Yamanishi K, Iso H; SHEZ Study group. The Shozu Herpes Zoster (SHEZ) study: rationale, design, and description of a prospective cohort study. *J Epidemiol* 2012; **22**: 167-174 [PMID: [22343323](#) DOI: [10.2188/jea.je20110035](#)]
- 18 **Okamoto S**, Hata A, Sadaoka K, Yamanishi K, Mori Y. Comparison of varicella-zoster virus-specific immunity of patients with diabetes mellitus and healthy individuals. *J Infect Dis* 2009; **200**: 1606-1610 [PMID: [19821719](#) DOI: [10.1086/644646](#)]
- 19 **Ito M**, Bandyopadhyay S, Matsumoto-Kobayashi M, Clark SC, Miller D, Starr SE. Interleukin 2 enhances natural killing of varicella-zoster virus-infected targets. *Clin Exp Immunol* 1986; **65**: 182-189 [PMID: [3098472](#)]
- 20 **Ihara T**, Ito M, Starr SE. Human lymphocyte, monocyte and polymorphonuclear leucocyte mediated antibody-dependent cellular cytotoxicity against varicella-zoster virus-infected targets. *Clin Exp Immunol* 1986; **63**: 179-187 [PMID: [3955882](#)]
- 21 **Diaz PS**, Smith S, Hunter E, Arvin AM. T lymphocyte cytotoxicity with natural varicella-zoster virus infection and after immunization with live attenuated varicella vaccine. *J Immunol* 1989; **142**: 636-641 [PMID: [2536059](#)]
- 22 **Ihara T**, Oitani K, Torigoe S, Kitamura K, Ito M, Kamiya H, Sakurai M. Cytotoxicity against varicella zoster virus infected targets in children with acute leukemia. *Acta Paediatr Jpn* 1994; **36**: 53-56 [PMID: [8165909](#) DOI: [10.1111/j.1442-200x.1994.tb03129.x](#)]
- 23 **Echevarría JM**, Casas I, Martínez-Martín P. Infections of the nervous system caused by varicella-zoster virus: a review. *Intervirology* 1997; **40**: 72-84 [PMID: [9450225](#) DOI: [10.1159/000150535](#)]
- 24 **LEWIS GW**. Zoster sine herpette. *Br Med J* 1958; **2**: 418-421 [PMID: [13560886](#) DOI: [10.1136/bmj.2.5093.418](#)]
- 25 **Koskiniemi M**, Piiparinen H, Rantalaiho T, Eränkö P, Färkkilä M, Räihä K, Salonen EM, Ukkonen P, Vaheri A. Acute central nervous system complications in varicella zoster virus infections. *J Clin Virol* 2002; **25**: 293-301 [PMID: [12423693](#) DOI: [10.1016/S1386-6532\(02\)00020-3](#)]
- 26 **Drago F**, Herzum A, Ciccarese G, Broccolo F, Rebora A, Parodi A. Acute pain and postherpetic neuralgia related to Varicella zoster virus reactivation: Comparison between typical herpes zoster and zoster sine herpette. *J Med Virol* 2019; **91**: 287-295 [PMID: [30179265](#) DOI: [10.1002/jmv.25304](#)]
- 27 **Asano Y**, Itakura N, Kajita Y, Suga S, Yoshikawa T, Yazaki T, Ozaki T, Yamanishi K, Takahashi M. Severity of viremia and clinical findings in children with varicella. *J Infect Dis* 1990; **161**: 1095-1098 [PMID: [2161037](#) DOI: [10.1093/infdis/161.6.1095](#)]



Published by **Baishideng Publishing Group Inc**
7041 Koll Center Parkway, Suite 160, Pleasanton, CA 94566, USA

Telephone: +1-925-3991568

E-mail: bpgoffice@wjgnet.com

Help Desk: <https://www.f6publishing.com/helpdesk>

<https://www.wjgnet.com>

