

World Journal of *Clinical Cases*

World J Clin Cases 2022 July 16; 10(20): 6759-7186



Contents

Thrice Monthly Volume 10 Number 20 July 16, 2022

OPINION REVIEW

- 6759 Semaglutide might be a key for breaking the vicious cycle of metabolically associated fatty liver disease spectrum?

Cigrovski Berkovic M, Rezić T, Bilic-Curcic I, Mrzljak A

MINIREVIEWS

- 6769 Drainage of pancreatic fluid collections in acute pancreatitis: A comprehensive overview
- Bansal A, Gupta P, Singh AK, Shah J, Samanta J, Mandavdhare HS, Sharma V, Sinha SK, Dutta U, Sandhu MS, Kochhar R*

- 6784 Frontiers of COVID-19-related myocarditis as assessed by cardiovascular magnetic resonance

Luo Y, Liu BT, Yuan WF, Zhao CX

ORIGINAL ARTICLE

Case Control Study

- 6794 Urinary and sexual function changes in benign prostatic hyperplasia patients before and after transurethral columnar balloon dilatation of the prostate

Zhang DP, Pan ZB, Zhang HT

- 6803 Effects of the information-knowledge-attitude-practice nursing model combined with predictability intervention on patients with cerebrovascular disease

Huo HL, Gui YY, Xu CM, Zhang Y, Li Q

Retrospective Cohort Study

- 6811 Effects of Kampo medicine hangebyakujutsutemmato on persistent postural-perceptual dizziness: A retrospective pilot study

Miwa T, Kanemaru SI

Retrospective Study

- 6825 Longitudinal changes in personalized platelet count metrics are good indicators of initial 3-year outcome in colorectal cancer

Herold Z, Herold M, Lohinszky J, Szasz AM, Dank M, Somogyi A

- 6845 Efficacy of Kegel exercises in preventing incontinence after partial division of internal anal sphincter during anal fistula surgery

Garg P, Yagnik VD, Kaur B, Menon GR, Dawka S

Observational Study

- 6855 Influence of the water jet system vs cavitron ultrasonic surgical aspirator for liver resection on the remnant liver

Hanaki T, Tsuda A, Sunaguchi T, Goto K, Morimoto M, Murakami Y, Kihara K, Matsunaga T, Yamamoto M, Tokuyasu N, Sakamoto T, Hasegawa T, Fujiwara Y

- 6865** Critical values of monitoring indexes for perioperative major adverse cardiac events in elderly patients with biliary diseases

Zhang ZM, Xie XY, Zhao Y, Zhang C, Liu Z, Liu LM, Zhu MW, Wan BJ, Deng H, Tian K, Guo ZT, Zhao XZ

- 6876** Comparative study of surface electromyography of masticatory muscles in patients with different types of bruxism

Lan KW, Jiang LL, Yan Y

Randomized Controlled Trial

- 6890** Dural puncture epidural technique provides better anesthesia quality in repeat cesarean delivery than epidural technique: Randomized controlled study

Wang SY, He Y, Zhu HJ, Han B

SYSTEMATIC REVIEWS

- 6900** Network pharmacology-based strategy for predicting therapy targets of Sanqi and Huangjing in diabetes mellitus

Cui XY, Wu X, Lu D, Wang D

META-ANALYSIS

- 6915** Endoscopic submucosal dissection for early signet ring cell gastric cancer: A systematic review and meta-analysis

Weng CY, Sun SP, Cai C, Xu JL, Lv B

- 6927** Prognostic value of computed tomography derived skeletal muscle mass index in lung cancer: A meta-analysis

Pan XL, Li HJ, Li Z, Li ZL

CASE REPORT

- 6936** Autosomal dominant osteopetrosis type II resulting from a *de novo* mutation in the *CLCN7* gene: A case report

Song XL, Peng LY, Wang DW, Wang H

- 6944** Clinical expression and mitochondrial deoxyribonucleic acid study in twins with 14484 Leber's hereditary optic neuropathy: A case report

Chuenkongkaew WL, Chinkulkitnivat B, Lertrit P, Chirapapaisan N, Kaewsutthi S, Suktitipat B, Mitrpant C

- 6954** Management of the enteroatmospheric fistula: A case report

Cho J, Sung K, Lee D

- 6960** Lower lip recurrent keratoacanthoma: A case report

Liu XG, Liu XG, Wang CJ, Wang HX, Wang XX

- 6966** Optic disc coloboma associated with macular retinoschisis: A case report

Zhang W, Peng XY

- 6974** A 7-year-old boy with recurrent cyanosis and tachypnea: A case report
Li S, Chen LN, Zhong L
- 6981** Schwannomatosis patient who was followed up for fifteen years: A case report
Li K, Liu SJ, Wang HB, Yin CY, Huang YS, Guo WT
- 6991** Intentional replantation combined root resection therapy for the treatment of type III radicular groove with two roots: A case report
Tan D, Li ST, Feng H, Wang ZC, Wen C, Nie MH
- 6999** Clinical features and genetic variations of severe neonatal hyperbilirubinemia: Five case reports
Lin F, Xu JX, Wu YH, Ma YB, Yang LY
- 7006** Percutaneous transhepatic access for catheter ablation of a patient with heterotaxy syndrome complicated with atrial fibrillation: A case report
Wang HX, Li N, An J, Han XB
- 7013** Secondary positioning of rotationally asymmetric refractive multifocal intraocular lens in a patient with glaucoma: A case report
Fan C, Zhou Y, Jiang J
- 7020** Laparoscopic repair of diaphragmatic hernia associating with radiofrequency ablation for hepatocellular carcinoma: A case report
Tsunoda J, Nishi T, Ito T, Inaguma G, Matsuzaki T, Seki H, Yasui N, Sakata M, Shimada A, Matsumoto H
- 7029** Hypopituitary syndrome with pituitary crisis in a patient with traumatic shock: A case report
Zhang XC, Sun Y
- 7037** Solitary plasmacytoma of the left rib misdiagnosed as angina pectoris: A case report
Yao J, He X, Wang CY, Hao L, Tan LL, Shen CJ, Hou MX
- 7045** Secondary coronary artery ostial lesions: Three case reports
Liu XP, Wang HJ, Gao JL, Ma GL, Xu XY, Ji LN, He RX, Qi BYE, Wang LC, Li CQ, Zhang YJ, Feng YB
- 7054** Bladder perforation injury after percutaneous peritoneal dialysis catheterization: A case report
Shi CX, Li ZX, Sun HT, Sun WQ, Ji Y, Jia SJ
- 7060** Myotonic dystrophy type 1 presenting with dyspnea: A case report
Jia YX, Dong CL, Xue JW, Duan XQ, Xu MY, Su XM, Li P
- 7068** Novel mutation in the *SALL1* gene in a four-generation Chinese family with uraemia: A case report
Fang JX, Zhang JS, Wang MM, Liu L
- 7076** Malignant transformation of primary mature teratoma of colon: A case report
Liu J

- 7082** Treatment of pyogenic liver abscess by surgical incision and drainage combined with platelet-rich plasma: A case report
Wang JH, Gao ZH, Qian HL, Li JS, Ji HM, Da MX
- 7090** Left bundle branch pacing in a ventricular pacing dependent patient with heart failure: A case report
Song BX, Wang XX, An Y, Zhang YY
- 7097** Solitary fibrous tumor of the liver: A case report and review of the literature
Xie GY, Zhu HB, Jin Y, Li BZ, Yu YQ, Li JT
- 7105** MutL homolog 1 germline mutation c.(453+1_454-1)_(545+1_546-1)del identified in lynch syndrome: A case report and review of literature
Zhang XW, Jia ZH, Zhao LP, Wu YS, Cui MH, Jia Y, Xu TM
- 7116** Malignant histiocytosis associated with mediastinal germ cell tumor: A case report
Yang PY, Ma XL, Zhao W, Fu LB, Zhang R, Zeng Q, Qin H, Yu T, Su Y
- 7124** Immunoglobulin G4 associated autoimmune cholangitis and pancreatitis following the administration of nivolumab: A case report
Agrawal R, Guzman G, Karimi S, Giulianotti PC, Lora AJM, Jain S, Khan M, Boulay BR, Chen Y
- 7130** Portal vein thrombosis in a noncirrhotic patient after hemihepatectomy: A case report and review of literature
Zhang SB, Hu ZX, Xing ZQ, Li A, Zhou XB, Liu JH
- 7138** Microvascular decompression for a patient with oculomotor palsy caused by posterior cerebral artery compression: A case report and literature review
Zhang J, Wei ZJ, Wang H, Yu YB, Sun HT
- 7147** Topical halometasone cream combined with fire needle pre-treatment for treatment of primary cutaneous amyloidosis: Two case reports
Su YQ, Liu ZY, Wei G, Zhang CM
- 7153** Simultaneous robot-assisted approach in a super-elderly patient with urothelial carcinoma and synchronous contralateral renal cell carcinoma: A case report
Yun JK, Kim SH, Kim WB, Kim HK, Lee SW
- 7163** Nursing a patient with latent autoimmune diabetes in adults with insulin-related lipodystrophy, allergy, and exogenous insulin autoimmune syndrome: A case report
He F, Xu LL, Li YX, Dong YX
- 7171** Incidental diagnosis of medullary thyroid carcinoma due to persistently elevated procalcitonin in a patient with COVID-19 pneumonia: A case report
Saha A, Mukhopadhyay M, Paul S, Bera A, Bandyopadhyay T
- 7178** Macular hole following phakic intraocular lens implantation: A case report
Li XJ, Duan JL, Ma JX, Shang QL

LETTER TO THE EDITOR

- 7184** Is every microorganism detected in the intensive care unit a nosocomial infection? Isn't prevention more important than detection?

Yildirim F, Karaman I, Yildirim M

ABOUT COVER

Editorial Board Member of *World Journal of Clinical Cases*, Jie-Feng Huang, PhD, Associate Chief Physician, Associate Professor, Department of Orthopaedics and Traumatology, The First Affiliated Hospital of Zhejiang Chinese Medical University, Hangzhou 310006, Zhejiang Province, China. 40983285@qq.com

AIMS AND SCOPE

The primary aim of *World Journal of Clinical Cases* (WJCC, *World J Clin Cases*) is to provide scholars and readers from various fields of clinical medicine with a platform to publish high-quality clinical research articles and communicate their research findings online.

WJCC mainly publishes articles reporting research results and findings obtained in the field of clinical medicine and covering a wide range of topics, including case control studies, retrospective cohort studies, retrospective studies, clinical trials studies, observational studies, prospective studies, randomized controlled trials, randomized clinical trials, systematic reviews, meta-analysis, and case reports.

INDEXING/ABSTRACTING

The WJCC is now abstracted and indexed in Science Citation Index Expanded (SCIE, also known as SciSearch®), Journal Citation Reports/Science Edition, Current Contents®/Clinical Medicine, PubMed, PubMed Central, Scopus, Reference Citation Analysis, China National Knowledge Infrastructure, China Science and Technology Journal Database, and Superstar Journals Database. The 2022 Edition of Journal Citation Reports® cites the 2021 impact factor (IF) for WJCC as 1.534; IF without journal self cites: 1.491; 5-year IF: 1.599; Journal Citation Indicator: 0.28; Ranking: 135 among 172 journals in medicine, general and internal; and Quartile category: Q4. The WJCC's CiteScore for 2021 is 1.2 and Scopus CiteScore rank 2021: General Medicine is 443/826.

RESPONSIBLE EDITORS FOR THIS ISSUE

Production Editor: *Hua-Ge Yin*; Production Department Director: *Xu Guo*; Editorial Office Director: *Jin-Lei Wang*.

NAME OF JOURNAL

World Journal of Clinical Cases

ISSN

ISSN 2307-8960 (online)

LAUNCH DATE

April 16, 2013

FREQUENCY

Thrice Monthly

EDITORS-IN-CHIEF

Bao-Gan Peng, Jerzy Tadeusz Chudek, George Kontogeorgos, Maurizio Serati, Ja Hyeon Ku

EDITORIAL BOARD MEMBERS

<https://www.wjgnet.com/2307-8960/editorialboard.htm>

PUBLICATION DATE

July 16, 2022

COPYRIGHT

© 2022 Baishideng Publishing Group Inc

INSTRUCTIONS TO AUTHORS

<https://www.wjgnet.com/bpg/gerinfo/204>

GUIDELINES FOR ETHICS DOCUMENTS

<https://www.wjgnet.com/bpg/GerInfo/287>

GUIDELINES FOR NON-NATIVE SPEAKERS OF ENGLISH

<https://www.wjgnet.com/bpg/gerinfo/240>

PUBLICATION ETHICS

<https://www.wjgnet.com/bpg/GerInfo/288>

PUBLICATION MISCONDUCT

<https://www.wjgnet.com/bpg/gerinfo/208>

ARTICLE PROCESSING CHARGE

<https://www.wjgnet.com/bpg/gerinfo/242>

STEPS FOR SUBMITTING MANUSCRIPTS

<https://www.wjgnet.com/bpg/GerInfo/239>

ONLINE SUBMISSION

<https://www.f6publishing.com>



Portal vein thrombosis in a noncirrhotic patient after hemihepatectomy: A case report and review of literature

Shu-Bin Zhang, Zi-Xuan Hu, Zhong-Qiang Xing, Ang Li, Xin-Bo Zhou, Jian-Hua Liu

Specialty type: Gastroenterology and hepatology

Provenance and peer review: Unsolicited article; Externally peer reviewed.

Peer-review model: Single blind

Peer-review report's scientific quality classification

Grade A (Excellent): 0
Grade B (Very good): 0
Grade C (Good): C
Grade D (Fair): D
Grade E (Poor): 0

P-Reviewer: Singh N, United States; Tadros M, United States

A-Editor: Lin FY, China

Received: January 5, 2022

Peer-review started: January 5, 2022

First decision: February 21, 2022

Revised: March 6, 2022

Accepted: May 27, 2022

Article in press: May 27, 2022

Published online: July 16, 2022



Shu-Bin Zhang, Zi-Xuan Hu, Zhong-Qiang Xing, Xin-Bo Zhou, Jian-Hua Liu, Department of Hepatobiliary Surgery, The Second Hospital of Hebei Medical University, Shijiazhuang 050000, Hebei Province, China

Ang Li, Department of Hepatobiliary Surgery, The First Hospital of Hebei Medical University, Shijiazhuang 050000, Hebei Province, China

Corresponding author: Jian-Hua Liu, MD, Chief Doctor, Department of Hepatobiliary Surgery, The Second Hospital of Hebei Medical University, No. 215 Heping West Road, Xinhua District, Shijiazhuang 050000, Hebei Province, China. dr.ljh@outlook.com

Abstract

BACKGROUND

Portal vein thrombosis (PVT) is a condition caused by hemodynamic disorders. It may be noted in the portal vein system when there is an inflammatory stimulus in the abdominal cavity. However, PVT is rarely reported after hepatectomy. At present, related guidelines and major expert opinions tend to consider vitamin K antagonists or low-molecular weight heparin (LMWH) as the standard treatment. But based on research, direct oral anticoagulants may be more effective and safe for noncirrhotic PVT and are also beneficial by reducing the recurrence rate of PVT.

CASE SUMMARY

A 51-year-old woman without any history of disease felt discomfort in her right upper abdomen for 20 d, with worsening for 7 d. Contrast-enhanced computed tomography (CECT) of the upper abdomen showed right liver intrahepatic cholangiocarcinoma with multiple intrahepatic metastases but not to the left liver. Therefore, she underwent right hepatic and caudate lobectomy. One week after surgery, the patient underwent a CECT scan, due to nausea, vomiting, and abdominal distension. Thrombosis in the left branch and main trunk of the portal vein and near the confluence of the splenic vein was found. After using LMWH for 22 d, CECT showed no filling defect in the portal vein system.

CONCLUSION

Although PVT after hepatectomy is rare, it needs to be prevented during the perioperative period.

Key Words: Portal vein thrombosis; Hemihpatectomy; Anticoagulation; Noncirrhosis;

Low-molecular weight heparin; Case report

©The Author(s) 2022. Published by Baishideng Publishing Group Inc. All rights reserved.

Core Tip: We present a case of portal vein thrombosis (PVT) after hemihepatectomy. It is most common in liver cirrhosis, postsplenectomy, and liver transplantation, but is relatively rare after hepatectomy. This case verified the safety and effectiveness of low-molecular weight heparin in this condition. In the perioperative period, attention should be given to the prevention, early diagnosis, and systemic treatment of PVT.

Citation: Zhang SB, Hu ZX, Xing ZQ, Li A, Zhou XB, Liu JH. Portal vein thrombosis in a noncirrhotic patient after hemihepatectomy: A case report and review of literature. *World J Clin Cases* 2022; 10(20): 7130-7137

URL: <https://www.wjgnet.com/2307-8960/full/v10/i20/7130.htm>

DOI: <https://dx.doi.org/10.12998/wjcc.v10.i20.7130>

INTRODUCTION

Portal vein thrombosis (PVT) is often detected in the extrahepatic portal vein, such as the superior mesenteric vein and spleen vein. Vitamin K antagonists (VKAs) or low-molecular weight heparin (LMWH) are considered as the standard treatment[1,2]. But direct oral anticoagulants (DOACs) may be more effective and safe for noncirrhotic PVT (ncPVT) and are also beneficial by reducing the recurrence rate of PVT[3,4]. Portal vein tumor thrombosis is significantly different from PVT[5,6]. Studies show that 2.1%-9.1% [7,8] of patients have PVT after hepatectomy, with a rate of 10%-40% [9-11] among patients with hepatocellular carcinoma. Anticoagulation is widely accepted as the standard treatment option for ncPVT[12-14]. According to the Child-Pugh classification principle, thrombectomy and interventional therapy may have great disadvantages.

CASE PRESENTATION

Chief complaints

A 51-year-old woman without any history of disease felt discomfort in the right upper abdomen for 20 d with worsening for 7 d.

History of present illness

The symptoms were unrelated to feeding behavior, and the patient had not undergone any treatment.

History of past illness

The patient was in good health.

Personal and family history

The patient had no medical history or family history of malignant tumors.

Physical examination

The physical examinations were roughly normal.

Laboratory examinations

CA-199 was over 1000 U/mL on admission.

Imaging examinations

Contrast-enhanced computed tomography (CECT) of the upper abdomen showed right liver intrahepatic cholangiocarcinoma (ICC) with multiple intrahepatic metastases, which were confined to the right liver and caudate lobe.

FINAL DIAGNOSIS

ICC with multiple intrahepatic metastases in the right liver and caudate lobe.

TREATMENT

After three-dimensional reconstruction of the liver, we found that the middle hepatic vein (Figure 1) and the right branch of the portal vein (Figure 2) were located close to the tumor. Therefore, we decided to perform laparoscopic left-liver-first anterior radical modular orthotopic right hemihepatectomy (Lap-larmorh) (Figure 3). The right liver and caudate lobe, which accounted for 62% of the liver volume, were resected. After the operation, in addition to antibiotics, hepatic protectants, and proton pump inhibitors, we also intermittently administered fibrinogen, human prothrombin complex concentrates, and ordinary frozen plasma to avoid hemorrhage from the liver wounds. However, one week after surgery, nausea, vomiting, and abdominal distension occurred, and she underwent a CECT scan. Thrombosis was distributed in the left branch and main trunk of the portal vein and near the confluence of the splenic vein. Moreover, the main trunk was almost occluded (Figure 4A). To prevent further progression, we began to inject 6400 IU LMWH twice a day until the PVT disappeared and stopped procoagulant therapy. After the above treatments, the patient's discomfort was significantly relieved. In addition, CECT and color Doppler ultrasound indicated that the thrombosis was smaller than before (Figure 4B and C). On day 22, CECT showed that there was no filling defect in the portal vein (Figure 4D).

OUTCOME AND FOLLOW-UP

This patient was discharged uneventfully 1 mo after the operation. Nine months of follow-up by telephone showed that there were no recurrent thromboembolic events without anticoagulation therapy. Moreover, there were no symptoms of digestive system discomfort.

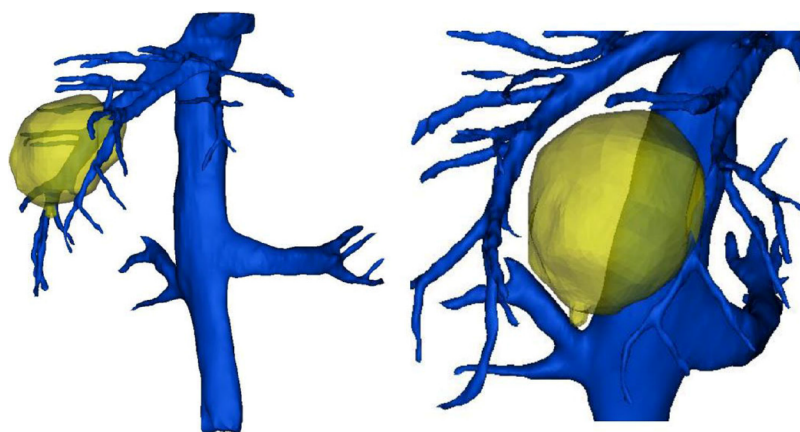
DISCUSSION

As a deep vascular complication, PVT is not common in clinical work. It usually occurs in patients with liver cirrhosis, with an incidence of 10-25% [15-17]. The incidence is closely related to surgery, ranging from 1% to 3% [18] after liver transplantation, and from 1.6 to 11% [19,20] after splenectomy. At present, our department does not provide preventive treatment for thrombosis during the perioperative period. Anticoagulation therapy has no significant effect on the incidence of thrombosis [21].

According to the location of the thrombus, the degree of obstruction, and the speed of obstruction formation, PVT can be divided into the acute phase, subacute phase, and chronic phase. At the onset of the acute phase, the patient will suddenly show symptoms such as nausea, vomiting, abdominal pain, or fever. After hepatectomy, without undergoing portal vein color Doppler ultrasound and CECT, it is difficult to associate these symptoms with acute PVT and make an early diagnosis or start treatment early. If the portal vein is not completely blocked in the acute phase, these symptoms will continue for several weeks and progress to the subacute phase, eventually entering the chronic phase after the formation of venous collateral circulation. The patient gradually developed gastrointestinal symptoms 1 wk after right hepatectomy, which proved that the PVT did not suddenly block most of the main portal vein, which created the possibility for subsequent treatment.

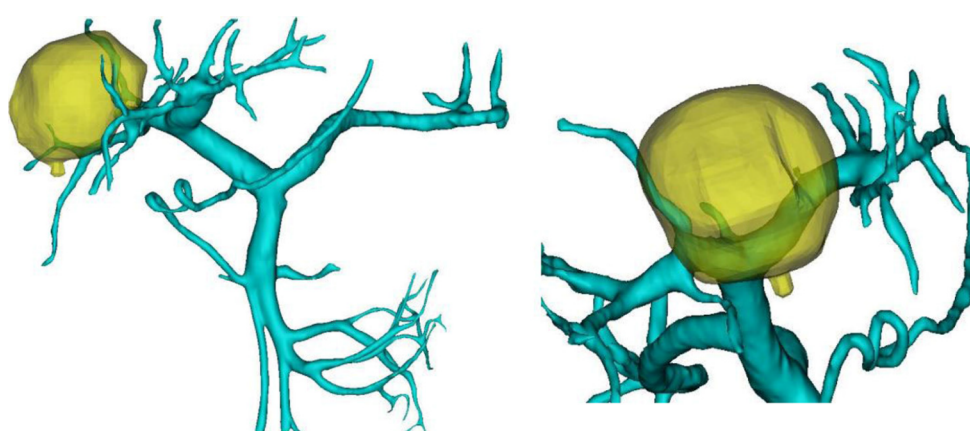The three basic risk factors for the formation of PVT are vascular endothelial cell damage, blood hypercoagulability, and portal vein blood flow disorder. Reviewing the patient's perioperative treatment, there were the following risk factors that may have led to PVT: (1) Surgical factors, such as intraoperative laparoscopic equipment pulling the portal vein and damaging the vascular endothelial cells, 20 min of treatment by the first hepatic portal blood flow occlusion method causing prolonged hypoxia, and high pneumoperitoneal pressure (15 mmHg) [22,23] causing a reduction in portal blood flow velocity; and (2) After the operation, the patient's effective circulating blood volume was insufficient, and the blood hypercoagulable state was caused by an inflammatory reaction. In addition, an insufficient remaining liver volume after hepatectomy resulted in a fragile balance of the coagulation system. Frozen plasma and other procoagulant drugs infused to prevent hemorrhage from the wound may also have promoted the development of PVT.

At present, the early diagnosis of PVT is based on clinical symptoms and the detection of thrombi through imaging examination. However, approximately 67% [24] of patients have no special clinical manifestations after the formation of PVT. CECT is still the first choice for a clear diagnosis [21,25]. The diagnosis of this patient was achieved through CECT, and in the follow-up process, the combination of CECT and ultrasound also achieved good results.



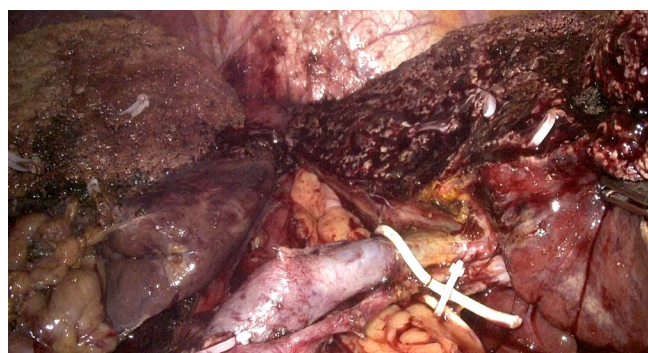DOI: 10.12998/wjcc.v10.i20.7130 Copyright ©The Author(s) 2022.

Figure 1 The tumor was closed to the middle hepatic vein.



DOI: 10.12998/wjcc.v10.i20.7130 Copyright ©The Author(s) 2022.

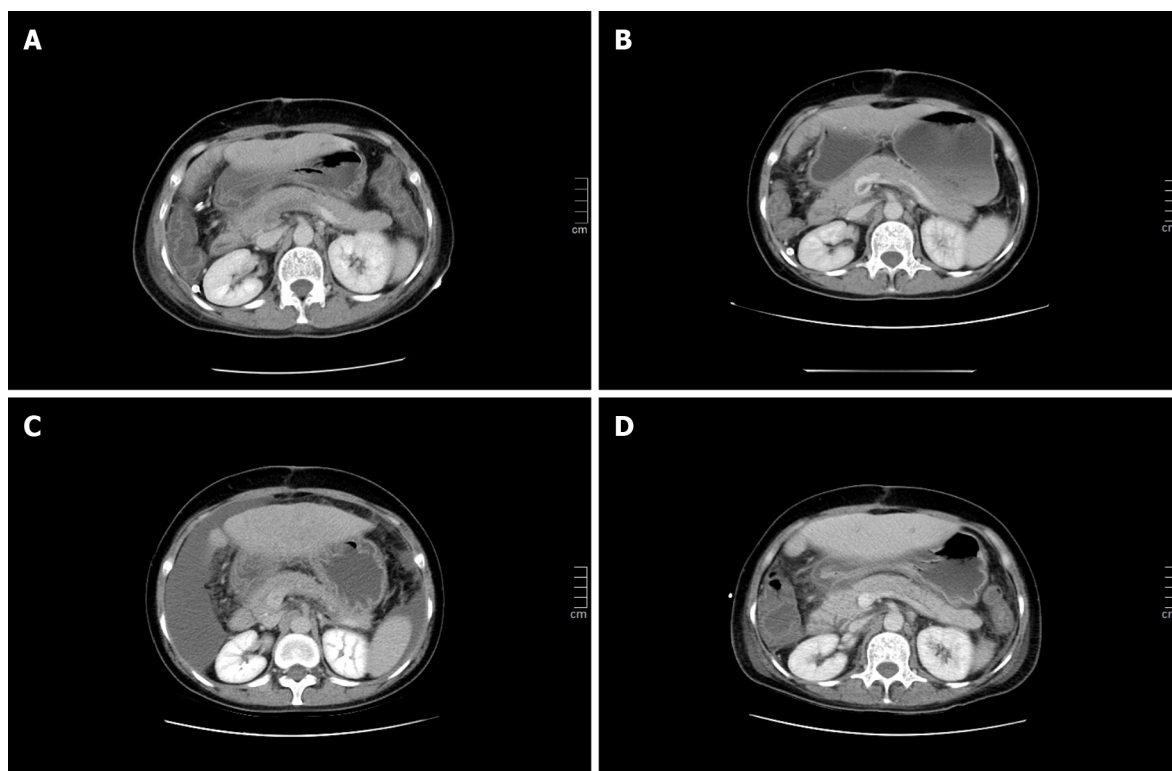
Figure 2 The tumor was closed to the right branch of the portal vein.



DOI: 10.12998/wjcc.v10.i20.7130 Copyright ©The Author(s) 2022.

Figure 3 The right liver and caudate lobe were removed.

The purpose of PVT treatment is to prevent the further development of the thrombus and recanalization of blood vessels. Generally, there are three treatment methods. First, thrombectomy can immediately relieve blood vessel obstruction and prevent acute intestinal necrosis or related complications. However, new portal vein injuries and other surgical trauma often lead to the recurrence of PVT. In particular, patients cannot withstand the traumatic stimulation of reoperation. Therefore, this method is only suitable for patients in whom there are signs of peritonitis or the thrombus has been confirmed to come from the portal venous system. Second, interventional therapy can accurately deliver thrombolytic drugs to the obstruction with less damage and fewer complications. In addition, it



DOI: 10.12998/wjcc.v10.i20.7130 Copyright ©The Author(s) 2022.

Figure 4 Photographs of change in the portal vein thrombosis. A: Thrombosis distributed in the left branch and main trunk of the portal vein and near the confluence of the splenic vein; B and C: The portal vein was partially recanalized; D: There was no filling defect in the portal vein.

provides an option for patients in whom liver function is decompensated, the PVT lasts for a long time, and conservative treatment was not effective. Although nonsurgical treatment is minimally invasive, effective, and reproducible, its risks still require our attention. For example, percutaneous portal vein thrombolysis can induce bleeding in the puncture tract. During the process of thrombolysis, it is necessary to monitor coagulation function and blood cell count over time. Therefore, it is contraindicated in patients with Child-Pugh class C who have large amounts of ascites and poor coagulation. Finally, anticoagulation and thrombolysis are the basic principles of noninvasive treatment[26]. Patients with primary blood hypercoagulability and early thrombosis will benefit more from anticoagulation therapy. Eighty percent of acute PVT cases can be completely or partially recanalized after anticoagulation therapy[27]. Compared with heparin, LMWH is the best anticoagulant. Because there is no obvious difference between the two anticoagulant drugs in terms of causing bleeding, LMWH can better improve the survival rate[25,28]. Studies have shown that LMWH is safe and effective in the treatment of PVT caused by liver cirrhosis[29], and changes in thrombus volume can be seen on imaging after 2 wk of anticoagulation therapy[28]. This is also consistent with the therapeutic effect of this patient after hepatectomy. If anticoagulation is not continued after recanalization, approximately 38%[30] of patients will develop PVT again. Some experts suggest that after 20 d of intravenous infusion of anticoagulant, it is best for patients to continue oral anticoagulant for 3 to 6 mo instead of subcutaneous LMWH[19,21]. Because long-term subcutaneous injection of LMWH after discharge can lead to decreased patient compliance, and standard treatment represented by VKAs and LMWH requires continuous monitoring of renal function and INR to adjust the dosage[31]. However, related foundational trials included no patients with PVT[32-35]. DOACs for the treatment of PVT are still not widely accepted, and further research is needed[36].

In addition to the treatment of PVT and prevention of recurrence mentioned above, prevention during the perioperative period is crucial. First, adequate portal blood flow should be ensured. Ultrasound can be used to measure portal vein blood flow, and less than 15 cm/s is an important risk factor[37]. Second, damage to the vascular intima should be avoided, for example, preventing violent pulling of the portal vein system during surgery, and reducing the time and frequency of portal occlusion. Finally, if symptoms such as nausea and vomiting occur after surgery, it is necessary to promptly confirm whether PVT occurred[21].

CONCLUSION

PVT is common in patients with liver cirrhosis or after liver transplantation and splenectomy. Surgeons should improve their understanding of this complication and use color Doppler ultrasound and CECT to confirm the appearance of PVT in a timely manner.

FOOTNOTES

Author contributions: Zhang SB, Li A, Liu JH, and Xing ZQ equally contributed to the patient's management, and drafting and revising of the manuscript including literature search, figures, and references; Zhou XB, Zhang SB, and Hu ZX critically reviewed and revised the manuscript for important intellectual content; all authors approved the final manuscript as submitted and agree to be accountable for all aspects of the work.

Informed consent statement: Informed written consent was obtained from the patient for publication of this case report.

Conflict-of-interest statement: The authors declare that they have no conflict of interest to disclose.

CARE Checklist (2016) statement: The authors have read the CARE Checklist (2016), and the manuscript was prepared and revised according to the CARE Checklist (2016).

Open-Access: This article is an open-access article that was selected by an in-house editor and fully peer-reviewed by external reviewers. It is distributed in accordance with the Creative Commons Attribution NonCommercial (CC BY-NC 4.0) license, which permits others to distribute, remix, adapt, build upon this work non-commercially, and license their derivative works on different terms, provided the original work is properly cited and the use is non-commercial. See: <https://creativecommons.org/licenses/by-nc/4.0/>

Country/Territory of origin: China

ORCID number: Shu-Bin Zhang 0000-0003-2618-5640; Zi-Xuan Hu 0000-0002-8808-0425; Zhong-Qiang Xing 0000-0002-2378-8254; Ang Li 0000-0002-2522-9923; Xin-Bo Zhou 0000-0002-1838-8651; Jian-Hua Liu 0000-0001-9544-8745.

S-Editor: Yan JP

L-Editor: Wang TQ

P-Editor: Yan JP

REFERENCES

- 1 Agno W, Beyer-Westendorf J, Garcia DA, Lazo-Langner A, McBane RD, Paciaroni M. Guidance for the management of venous thrombosis in unusual sites. *J Thromb Thrombolysis* 2016; **41**: 129-143 [PMID: 26780742 DOI: 10.1007/s11239-015-1308-1]
- 2 Kearon C, Akl EA, Comerota AJ, Prandoni P, Bounameaux H, Goldhaber SZ, Nelson ME, Wells PS, Gould MK, Dentali F, Crowther M, Kahn SR. Antithrombotic therapy for VTE disease: Antithrombotic Therapy and Prevention of Thrombosis, 9th ed: American College of Chest Physicians Evidence-Based Clinical Practice Guidelines. *Chest* 2012; **141**: e419S-e496S [PMID: 22315268 DOI: 10.1378/chest.11-2301]
- 3 Naymagon L, Tremblay D, Zubizarreta N, Moshier E, Troy K, Schiano T, Mascarenhas J. The efficacy and safety of direct oral anticoagulants in noncirrhotic portal vein thrombosis. *Blood Adv* 2020; **4**: 655-666 [PMID: 32078681 DOI: 10.1182/bloodadvances.2019001310]
- 4 De Gottardi A, Trebicka J, Klinger C, Plessier A, Seijo S, Terziroli B, Magenta L, Semela D, Buscarini E, Langlet P, Görtzen J, Puente A, Müllhaupt B, Navascués C, Nery F, Deltenre P, Turon F, Engelmann C, Arya R, Caca K, Peck-Radosavljevic M, Leebeek FWG, Valla D, Garcia-Pagan JC, VALDIG Investigators. Antithrombotic treatment with direct-acting oral anticoagulants in patients with splanchnic vein thrombosis and cirrhosis. *Liver Int* 2017; **37**: 694-699 [PMID: 27778440 DOI: 10.1111/liv.13285]
- 5 European Association for the Study of the Liver. EASL Clinical Practice Guidelines: Management of hepatocellular carcinoma. *J Hepatol* 2018; **69**: 182-236 [PMID: 29628281 DOI: 10.1016/j.jhep.2018.03.019]
- 6 Cheng S, Chen M, Cai J, Sun J, Guo R, Bi X, Lau WY, Wu M. Chinese Expert Consensus on Multidisciplinary Diagnosis and Treatment of Hepatocellular Carcinoma with Portal Vein Tumor Thrombus (2018 Edition). *Liver Cancer* 2020; **9**: 28-40 [PMID: 32071907 DOI: 10.1159/000503685]
- 7 Yoshiya S, Shirabe K, Nakagawara H, Soejima Y, Yoshizumi T, Ikegami T, Yamashita Y, Harimoto N, Nishie A, Yamanaka T, Maehara Y. Portal vein thrombosis after hepatectomy. *World J Surg* 2014; **38**: 1491-1497 [PMID: 24407940 DOI: 10.1007/s00268-013-2440-8]
- 8 Kuboki S, Shimizu H, Ohtsuka M, Kato A, Yoshitomi H, Furukawa K, Takayashiki T, Takano S, Okamura D, Suzuki D, Sakai N, Kagawa S, Miyazaki M. Incidence, risk factors, and management options for portal vein thrombosis after hepatectomy: a 14-year, single-center experience. *Am J Surg* 2015; **210**: 878-85.e2 [PMID: 26307424 DOI: 10.1016/j.amjsurg.2014.11.021]

- 9 **Minagawa M**, Makuuchi M. Treatment of hepatocellular carcinoma accompanied by portal vein tumor thrombus. *World J Gastroenterol* 2006; **12**: 7561-7567 [PMID: [17171782](#) DOI: [10.3748/wjg.v12.i47.7561](#)]
- 10 **Llovet JM**, Bustamante J, Castells A, Vilana R, Ayuso Mdel C, Sala M, Brú C, Rodés J, Bruix J. Natural history of untreated nonsurgical hepatocellular carcinoma: rationale for the design and evaluation of therapeutic trials. *Hepatology* 1999; **29**: 62-67 [PMID: [9862851](#) DOI: [10.1002/hep.510290145](#)]
- 11 **Cheung TK**, Lai CL, Wong BC, Fung J, Yuen MF. Clinical features, biochemical parameters, and virological profiles of patients with hepatocellular carcinoma in Hong Kong. *Aliment Pharmacol Ther* 2006; **24**: 573-583 [PMID: [16907890](#) DOI: [10.1111/j.1365-2036.2006.03029.x](#)]
- 12 **Ponziani FR**, Zocco MA, Campanale C, Rinninella E, Tortora A, Di Maurizio L, Bombardieri G, De Cristofaro R, De Gaetano AM, Landolfi R, Gasbarrini A. Portal vein thrombosis: insight into physiopathology, diagnosis, and treatment. *World J Gastroenterol* 2010; **16**: 143-155 [PMID: [20066733](#) DOI: [10.3748/wjg.v16.i2.143](#)]
- 13 **Parikh S**, Shah R, Kapoor P. Portal vein thrombosis. *Am J Med* 2010; **123**: 111-119 [PMID: [20103016](#) DOI: [10.1016/j.amjmed.2009.05.023](#)]
- 14 **Intagliata NM**, Caldwell SH, Tripodi A. Diagnosis, Development, and Treatment of Portal Vein Thrombosis in Patients With and Without Cirrhosis. *Gastroenterology* 2019; **156**: 1582-1599.e1 [PMID: [30771355](#) DOI: [10.1053/j.gastro.2019.01.265](#)]
- 15 **Tsochatzis EA**, Senzolo M, Germani G, Gatt A, Burroughs AK. Systematic review: portal vein thrombosis in cirrhosis. *Aliment Pharmacol Ther* 2010; **31**: 366-374 [PMID: [19863496](#) DOI: [10.1111/j.1365-2036.2009.04182.x](#)]
- 16 **Nery F**, Chevret S, Condat B, de Raucourt E, Boudaoud L, Rautou PE, Plessier A, Roulot D, Chaffaut C, Bourcier V, Trinchet JC, Valla DC; Groupe d'Etude et de Traitement du Carcinome Hépatocellulaire. Causes and consequences of portal vein thrombosis in 1,243 patients with cirrhosis: results of a longitudinal study. *Hepatology* 2015; **61**: 660-667 [PMID: [25284616](#) DOI: [10.1002/hep.27546](#)]
- 17 **Grando-Lemaire V**, Guettier C, Chevret S, Beaugrand M, Trinchet JC. Hepatocellular carcinoma without cirrhosis in the West: epidemiological factors and histopathology of the non-tumorous liver. Groupe d'Etude et de Traitement du Carcinome Hépatocellulaire. *J Hepatol* 1999; **31**: 508-513 [PMID: [10488711](#) DOI: [10.1016/s0168-8278\(99\)80044-0](#)]
- 18 **Sainz-Barriga M**, Baccarani U, Risaliti A, Gasparini D, Sponza M, Adani GL, Toniutto PL, Avellini C, Ramacciato G, Bresadola F. Successful minimally invasive management of late portal vein thrombosis after splenectomy due to splenic artery steal syndrome following liver transplantation: a case report. *Transplant Proc* 2004; **36**: 558-559 [PMID: [15110593](#) DOI: [10.1016/j.transproceed.2004.02.040](#)]
- 19 **Chaffanjon PC**, Brichon PY, Ranchoup Y, Gressin R, Sotto JJ. Portal vein thrombosis following splenectomy for hematologic disease: prospective study with Doppler color flow imaging. *World J Surg* 1998; **22**: 1082-1086 [PMID: [9747171](#) DOI: [10.1007/s002689900521](#)]
- 20 **Péré G**, Basselerie H, Maulat C, Pitocco A, Leblanc P, Philis A, Julio CH, Tuyeras G, Buscail E, Carrere N. Splenic volume and splenic vein diameter are independent pre-operative risk factors of portal vein thrombosis after splenectomy: a retrospective cohort study. *BMC Surg* 2021; **21**: 366 [PMID: [34641842](#) DOI: [10.1186/s12893-021-01364-3](#)]
- 21 **Skarsgard E**, Doski J, Jaksic T, Wesson D, Shandling B, Ein S, Babyn P, Heiss K, Hu X. Thrombosis of the portal venous system after splenectomy for pediatric hematologic disease. *J Pediatr Surg* 1993; **28**: 1109-1112 [PMID: [8308671](#) DOI: [10.1016/0022-3468\(93\)90141-7](#)]
- 22 **Ikeda M**, Sekimoto M, Takiguchi S, Kubota M, Ikenaga M, Yamamoto H, Fujiwara Y, Ohue M, Yasuda T, Imamura H, Tatsuta M, Yano M, Furukawa H, Monden M. High incidence of thrombosis of the portal venous system after laparoscopic splenectomy: a prospective study with contrast-enhanced CT scan. *Ann Surg* 2005; **241**: 208-216 [PMID: [15650628](#) DOI: [10.1097/01.sla.0000151794.28392.a6](#)]
- 23 **Klopfenstein CE**, Morel DR, Clergue F, Pastor CM. Effects of abdominal CO₂ insufflation and changes of position on hepatic blood flow in anesthetized pigs. *Am J Physiol* 1998; **275**: H900-H905 [PMID: [9724294](#) DOI: [10.1152/ajpheart.1998.275.3.H900](#)]
- 24 **Ruiz-Tovar J**, Priego P. Portal Vein Thrombosis After Splenic and Pancreatic Surgery. *Adv Exp Med Biol* 2017; **906**: 241-251 [PMID: [27638624](#) DOI: [10.1007/5584_2016_119](#)]
- 25 **Hanafy AS**, Abd-Elsalam S, Dawoud MM. Randomized controlled trial of rivaroxaban versus warfarin in the management of acute non-neoplastic portal vein thrombosis. *Vascul Pharmacol* 2019; **113**: 86-91 [PMID: [29886103](#) DOI: [10.1016/j.vph.2018.05.002](#)]
- 26 **Sogaard KK**, Astrup LB, Vilstrup H, Gronbaek H. Portal vein thrombosis; risk factors, clinical presentation and treatment. *BMC Gastroenterol* 2007; **7**: 34 [PMID: [17697371](#) DOI: [10.1186/1471-230X-7-34](#)]
- 27 **Valla DC**, Condat B. Portal vein thrombosis in adults: pathophysiology, pathogenesis and management. *J Hepatol* 2000; **32**: 865-871 [PMID: [10845677](#) DOI: [10.1016/s0168-8278\(00\)80259-7](#)]
- 28 **Nagaoki Y**, Aikata H, Daijyo K, Teraoka Y, Shinohara F, Nakamura Y, Hatooka M, Morio K, Nakahara T, Kawaoka T, Tsuge M, Hiramatsu A, Imamura M, Kawakami Y, Ochi H, Chayama K. Efficacy and safety of edoxaban for treatment of portal vein thrombosis following danaparoid sodium in patients with liver cirrhosis. *Hepatol Res* 2018; **48**: 51-58 [PMID: [28342265](#) DOI: [10.1111/hepr.12895](#)]
- 29 **Loffredo L**, Pastori D, Farcomeni A, Violi F. Effects of Anticoagulants in Patients With Cirrhosis and Portal Vein Thrombosis: A Systematic Review and Meta-analysis. *Gastroenterology* 2017; **153**: 480-487.e1 [PMID: [28479379](#) DOI: [10.1053/j.gastro.2017.04.042](#)]
- 30 **Delgado MG**, Seijo S, Yepes I, Achécar L, Catalina MV, García-Criado A, Abalde JG, de la Peña J, Bañares R, Albillos A, Bosch J, García-Pagán JC. Efficacy and safety of anticoagulation on patients with cirrhosis and portal vein thrombosis. *Clin Gastroenterol Hepatol* 2012; **10**: 776-783 [PMID: [22289875](#) DOI: [10.1016/j.cgh.2012.01.012](#)]
- 31 **Rugivardom M**, Charatcharoenwithaya P, Nontumoral Portal Vein Thrombosis: A Challenging Consequence of Liver Cirrhosis. *J Clin Transl Hepatol* 2020; **8**: 432-444 [PMID: [33447527](#) DOI: [10.14218/JCTH.2020.00067](#)]
- 32 **EINSTEIN-PE Investigators**, Büller HR, Prins MH, Lensin AW, Decousus H, Jacobson BF, Minar E, Chlumsky J, Verhamme P, Wells P, Agnelli G, Cohen A, Berkowitz SD, Bounameaux H, Davidson BL, Misselwitz F, Gallus AS, Raskob GE, Schellong S, Segers A. Oral rivaroxaban for the treatment of symptomatic pulmonary embolism. *N Engl J Med*

- 2012; **366**: 1287-1297 [PMID: [22449293](#) DOI: [10.1056/NEJMoa1113572](#)]
- 33 **EINSTEIN Investigators**, Bauersachs R, Berkowitz SD, Brenner B, Buller HR, Decousus H, Gallus AS, Lensing AW, Misselwitz F, Prins MH, Raskob GE, Segers A, Verhamme P, Wells P, Agnelli G, Bounameaux H, Cohen A, Davidson BL, Piovella F, Schellong S. Oral rivaroxaban for symptomatic venous thromboembolism. *N Engl J Med* 2010; **363**: 2499-2510 [PMID: [21128814](#) DOI: [10.1056/NEJMoa1007903](#)]
 - 34 **Agnelli G**, Buller HR, Cohen A, Curto M, Gallus AS, Johnson M, Masiukiewicz U, Pak R, Thompson J, Raskob GE, Weitz JI; AMPLIFY Investigators. Oral apixaban for the treatment of acute venous thromboembolism. *N Engl J Med* 2013; **369**: 799-808 [PMID: [23808982](#) DOI: [10.1056/NEJMoa1302507](#)]
 - 35 **Schulman S**, Kearon C, Kakkar AK, Mismetti P, Schellong S, Eriksson H, Baanstra D, Schnee J, Goldhaber SZ; RECOVER Study Group. Dabigatran versus warfarin in the treatment of acute venous thromboembolism. *N Engl J Med* 2009; **361**: 2342-2352 [PMID: [19966341](#) DOI: [10.1056/NEJMoa0906598](#)]
 - 36 **Priyanka P**, Kupec JT, Krafft M, Shah NA, Reynolds GJ. Newer Oral Anticoagulants in the Treatment of Acute Portal Vein Thrombosis in Patients with and without Cirrhosis. *Int J Hepatol* 2018; **2018**: 8432781 [PMID: [29973997](#) DOI: [10.1155/2018/8432781](#)]
 - 37 **Zocco MA**, Di Stasio E, De Cristofaro R, Novi M, Ainora ME, Ponziani F, Riccardi L, Lancellotti S, Santoliquido A, Flore R, Pompili M, Rapaccini GL, Tondi P, Gasbarrini GB, Landolfi R, Gasbarrini A. Thrombotic risk factors in patients with liver cirrhosis: correlation with MELD scoring system and portal vein thrombosis development. *J Hepatol* 2009; **51**: 682-689 [PMID: [19464747](#) DOI: [10.1016/j.jhep.2009.03.013](#)]



Published by **Baishideng Publishing Group Inc**
7041 Koll Center Parkway, Suite 160, Pleasanton, CA 94566, USA

Telephone: +1-925-3991568

E-mail: bpgoffice@wjgnet.com

Help Desk: <https://www.f6publishing.com/helpdesk>

<https://www.wjgnet.com>

