

World Journal of *Clinical Cases*

World J Clin Cases 2022 July 16; 10(20): 6759-7186



Contents

Thrice Monthly Volume 10 Number 20 July 16, 2022

OPINION REVIEW

- 6759** Semaglutide might be a key for breaking the vicious cycle of metabolically associated fatty liver disease spectrum?
Cigrovski Berkovic M, Rezić T, Bilic-Curcic I, Mrzljak A

MINIREVIEWS

- 6769** Drainage of pancreatic fluid collections in acute pancreatitis: A comprehensive overview
Bansal A, Gupta P, Singh AK, Shah J, Samanta J, Mandavdhare HS, Sharma V, Sinha SK, Dutta U, Sandhu MS, Kochhar R
- 6784** Frontiers of COVID-19-related myocarditis as assessed by cardiovascular magnetic resonance
Luo Y, Liu BT, Yuan WF, Zhao CX

ORIGINAL ARTICLE

Case Control Study

- 6794** Urinary and sexual function changes in benign prostatic hyperplasia patients before and after transurethral columnar balloon dilatation of the prostate
Zhang DP, Pan ZB, Zhang HT
- 6803** Effects of the information-knowledge-attitude-practice nursing model combined with predictability intervention on patients with cerebrovascular disease
Huo HL, Gui YY, Xu CM, Zhang Y, Li Q

Retrospective Cohort Study

- 6811** Effects of Kampo medicine hangebyakujutsutemmato on persistent postural-perceptual dizziness: A retrospective pilot study
Miwa T, Kanemaru SI

Retrospective Study

- 6825** Longitudinal changes in personalized platelet count metrics are good indicators of initial 3-year outcome in colorectal cancer
Herold Z, Herold M, Lohinszky J, Szasz AM, Dank M, Somogyi A
- 6845** Efficacy of Kegel exercises in preventing incontinence after partial division of internal anal sphincter during anal fistula surgery
Garg P, Yagnik VD, Kaur B, Menon GR, Dawka S

Observational Study

- 6855** Influence of the water jet system vs cavitron ultrasonic surgical aspirator for liver resection on the remnant liver
Hanaki T, Tsuda A, Sunaguchi T, Goto K, Morimoto M, Murakami Y, Kihara K, Matsunaga T, Yamamoto M, Tokuyasu N, Sakamoto T, Hasegawa T, Fujiwara Y

- 6865** Critical values of monitoring indexes for perioperative major adverse cardiac events in elderly patients with biliary diseases

Zhang ZM, Xie XY, Zhao Y, Zhang C, Liu Z, Liu LM, Zhu MW, Wan BJ, Deng H, Tian K, Guo ZT, Zhao XZ

- 6876** Comparative study of surface electromyography of masticatory muscles in patients with different types of bruxism

Lan KW, Jiang LL, Yan Y

Randomized Controlled Trial

- 6890** Dural puncture epidural technique provides better anesthesia quality in repeat cesarean delivery than epidural technique: Randomized controlled study

Wang SY, He Y, Zhu HJ, Han B

SYSTEMATIC REVIEWS

- 6900** Network pharmacology-based strategy for predicting therapy targets of Sanqi and Huangjing in diabetes mellitus

Cui XY, Wu X, Lu D, Wang D

META-ANALYSIS

- 6915** Endoscopic submucosal dissection for early signet ring cell gastric cancer: A systematic review and meta-analysis

Weng CY, Sun SP, Cai C, Xu JL, Lv B

- 6927** Prognostic value of computed tomography derived skeletal muscle mass index in lung cancer: A meta-analysis

Pan XL, Li HJ, Li Z, Li ZL

CASE REPORT

- 6936** Autosomal dominant osteopetrosis type II resulting from a *de novo* mutation in the *CLCN7* gene: A case report

Song XL, Peng LY, Wang DW, Wang H

- 6944** Clinical expression and mitochondrial deoxyribonucleic acid study in twins with 14484 Leber's hereditary optic neuropathy: A case report

Chuenkongkaew WL, Chinkulkitnivat B, Lertrit P, Chirapapaisan N, Kaewsutthi S, Suktitipat B, Mitrpant C

- 6954** Management of the enteroatmospheric fistula: A case report

Cho J, Sung K, Lee D

- 6960** Lower lip recurrent keratoacanthoma: A case report

Liu XG, Liu XG, Wang CJ, Wang HX, Wang XX

- 6966** Optic disc coloboma associated with macular retinoschisis: A case report

Zhang W, Peng XY

- 6974** A 7-year-old boy with recurrent cyanosis and tachypnea: A case report
Li S, Chen LN, Zhong L
- 6981** Schwannomatosis patient who was followed up for fifteen years: A case report
Li K, Liu SJ, Wang HB, Yin CY, Huang YS, Guo WT
- 6991** Intentional replantation combined root resection therapy for the treatment of type III radicular groove with two roots: A case report
Tan D, Li ST, Feng H, Wang ZC, Wen C, Nie MH
- 6999** Clinical features and genetic variations of severe neonatal hyperbilirubinemia: Five case reports
Lin F, Xu JX, Wu YH, Ma YB, Yang LY
- 7006** Percutaneous transhepatic access for catheter ablation of a patient with heterotaxy syndrome complicated with atrial fibrillation: A case report
Wang HX, Li N, An J, Han XB
- 7013** Secondary positioning of rotationally asymmetric refractive multifocal intraocular lens in a patient with glaucoma: A case report
Fan C, Zhou Y, Jiang J
- 7020** Laparoscopic repair of diaphragmatic hernia associating with radiofrequency ablation for hepatocellular carcinoma: A case report
Tsunoda J, Nishi T, Ito T, Inaguma G, Matsuzaki T, Seki H, Yasui N, Sakata M, Shimada A, Matsumoto H
- 7029** Hypopituitary syndrome with pituitary crisis in a patient with traumatic shock: A case report
Zhang XC, Sun Y
- 7037** Solitary plasmacytoma of the left rib misdiagnosed as angina pectoris: A case report
Yao J, He X, Wang CY, Hao L, Tan LL, Shen CJ, Hou MX
- 7045** Secondary coronary artery ostial lesions: Three case reports
Liu XP, Wang HJ, Gao JL, Ma GL, Xu XY, Ji LN, He RX, Qi BYE, Wang LC, Li CQ, Zhang YJ, Feng YB
- 7054** Bladder perforation injury after percutaneous peritoneal dialysis catheterization: A case report
Shi CX, Li ZX, Sun HT, Sun WQ, Ji Y, Jia SJ
- 7060** Myotonic dystrophy type 1 presenting with dyspnea: A case report
Jia YX, Dong CL, Xue JW, Duan XQ, Xu MY, Su XM, Li P
- 7068** Novel mutation in the *SALL1* gene in a four-generation Chinese family with uraemia: A case report
Fang JX, Zhang JS, Wang MM, Liu L
- 7076** Malignant transformation of primary mature teratoma of colon: A case report
Liu J

- 7082** Treatment of pyogenic liver abscess by surgical incision and drainage combined with platelet-rich plasma: A case report
Wang JH, Gao ZH, Qian HL, Li JS, Ji HM, Da MX
- 7090** Left bundle branch pacing in a ventricular pacing dependent patient with heart failure: A case report
Song BX, Wang XX, An Y, Zhang YY
- 7097** Solitary fibrous tumor of the liver: A case report and review of the literature
Xie GY, Zhu HB, Jin Y, Li BZ, Yu YQ, Li JT
- 7105** MutL homolog 1 germline mutation c.(453+1_454-1)_(545+1_546-1)del identified in lynch syndrome: A case report and review of literature
Zhang XW, Jia ZH, Zhao LP, Wu YS, Cui MH, Jia Y, Xu TM
- 7116** Malignant histiocytosis associated with mediastinal germ cell tumor: A case report
Yang PY, Ma XL, Zhao W, Fu LB, Zhang R, Zeng Q, Qin H, Yu T, Su Y
- 7124** Immunoglobulin G4 associated autoimmune cholangitis and pancreatitis following the administration of nivolumab: A case report
Agrawal R, Guzman G, Karimi S, Giulianotti PC, Lora AJM, Jain S, Khan M, Boulay BR, Chen Y
- 7130** Portal vein thrombosis in a noncirrhotic patient after hemihepatectomy: A case report and review of literature
Zhang SB, Hu ZX, Xing ZQ, Li A, Zhou XB, Liu JH
- 7138** Microvascular decompression for a patient with oculomotor palsy caused by posterior cerebral artery compression: A case report and literature review
Zhang J, Wei ZJ, Wang H, Yu YB, Sun HT
- 7147** Topical halometasone cream combined with fire needle pre-treatment for treatment of primary cutaneous amyloidosis: Two case reports
Su YQ, Liu ZY, Wei G, Zhang CM
- 7153** Simultaneous robot-assisted approach in a super-elderly patient with urothelial carcinoma and synchronous contralateral renal cell carcinoma: A case report
Yun JK, Kim SH, Kim WB, Kim HK, Lee SW
- 7163** Nursing a patient with latent autoimmune diabetes in adults with insulin-related lipodystrophy, allergy, and exogenous insulin autoimmune syndrome: A case report
He F, Xu LL, Li YX, Dong YX
- 7171** Incidental diagnosis of medullary thyroid carcinoma due to persistently elevated procalcitonin in a patient with COVID-19 pneumonia: A case report
Saha A, Mukhopadhyay M, Paul S, Bera A, Bandyopadhyay T
- 7178** Macular hole following phakic intraocular lens implantation: A case report
Li XJ, Duan JL, Ma JX, Shang QL

LETTER TO THE EDITOR

- 7184** Is every microorganism detected in the intensive care unit a nosocomial infection? Isn't prevention more important than detection?

Yildirim F, Karaman I, Yildirim M

ABOUT COVER

Editorial Board Member of *World Journal of Clinical Cases*, Jie-Feng Huang, PhD, Associate Chief Physician, Associate Professor, Department of Orthopaedics and Traumatology, The First Affiliated Hospital of Zhejiang Chinese Medical University, Hangzhou 310006, Zhejiang Province, China. 40983285@qq.com

AIMS AND SCOPE

The primary aim of *World Journal of Clinical Cases* (WJCC, *World J Clin Cases*) is to provide scholars and readers from various fields of clinical medicine with a platform to publish high-quality clinical research articles and communicate their research findings online.

WJCC mainly publishes articles reporting research results and findings obtained in the field of clinical medicine and covering a wide range of topics, including case control studies, retrospective cohort studies, retrospective studies, clinical trials studies, observational studies, prospective studies, randomized controlled trials, randomized clinical trials, systematic reviews, meta-analysis, and case reports.

INDEXING/ABSTRACTING

The WJCC is now indexed in Science Citation Index Expanded (also known as SciSearch®), Journal Citation Reports/Science Edition, Scopus, PubMed, and PubMed Central. The 2021 Edition of Journal Citation Reports® cites the 2020 impact factor (IF) for WJCC as 1.337; IF without journal self cites: 1.301; 5-year IF: 1.742; Journal Citation Indicator: 0.33; Ranking: 119 among 169 journals in medicine, general and internal; and Quartile category: Q3. The WJCC's CiteScore for 2020 is 0.8 and Scopus CiteScore rank 2020: General Medicine is 493/793.

RESPONSIBLE EDITORS FOR THIS ISSUE

Production Editor: Hua-Ge Yin, Production Department Director: Xu Guo, Editorial Office Director: Jin-Lei Wang.

NAME OF JOURNAL

World Journal of Clinical Cases

ISSN

ISSN 2307-8960 (online)

LAUNCH DATE

April 16, 2013

FREQUENCY

Thrice Monthly

EDITORS-IN-CHIEF

Bao-Gan Peng, Jerzy Tadeusz Chudek, George Kontogeorgos, Maurizio Serati, Ja Hyeon Ku

EDITORIAL BOARD MEMBERS

<https://www.wjgnet.com/2307-8960/editorialboard.htm>

PUBLICATION DATE

July 16, 2022

COPYRIGHT

© 2022 Baishideng Publishing Group Inc

INSTRUCTIONS TO AUTHORS

<https://www.wjgnet.com/bpg/gerinfo/204>

GUIDELINES FOR ETHICS DOCUMENTS

<https://www.wjgnet.com/bpg/GerInfo/287>

GUIDELINES FOR NON-NATIVE SPEAKERS OF ENGLISH

<https://www.wjgnet.com/bpg/gerinfo/240>

PUBLICATION ETHICS

<https://www.wjgnet.com/bpg/GerInfo/288>

PUBLICATION MISCONDUCT

<https://www.wjgnet.com/bpg/gerinfo/208>

ARTICLE PROCESSING CHARGE

<https://www.wjgnet.com/bpg/gerinfo/242>

STEPS FOR SUBMITTING MANUSCRIPTS

<https://www.wjgnet.com/bpg/GerInfo/239>

ONLINE SUBMISSION

<https://www.f6publishing.com>



Macular hole following phakic intraocular lens implantation: A case report

Xue-Jing Li, Jia-Liang Duan, Jing-Xue Ma, Qing-Li Shang

Specialty type: Ophthalmology

Provenance and peer review:

Unsolicited article; Externally peer reviewed.

Peer-review model: Single blind

Peer-review report's scientific quality classification

Grade A (Excellent): 0
Grade B (Very good): B, B
Grade C (Good): 0
Grade D (Fair): 0
Grade E (Poor): 0

P-Reviewer: Gálvez Salazar P, Ecuador; Sheikh Hassan M, Somalia

A-Editor: Zhu JQ, China

Received: March 16, 2022

Peer-review started: March 16, 2022

First decision: April 8, 2022

Revised: April 27, 2022

Accepted: May 27, 2022

Article in press: May 27, 2022

Published online: July 16, 2022



Xue-Jing Li, Jia-Liang Duan, Jing-Xue Ma, Qing-Li Shang, Department of Ophthalmology, The Second Hospital of Hebei Medical University, Shijiazhuang 050000, Hebei Province, China

Corresponding author: Qing-Li Shang, MD, Associate Specialist, Department of Ophthalmology, The Second Hospital of Hebei Medical University, No. 215 Heping West Road, Xinhua District, Shijiazhuang 050000, Hebei Province, China. zhangp_w@163.com

Abstract

BACKGROUND

Phakic intraocular lens (pIOL) implantation has been commonly prescribed and is considered as a safe and effective option for correcting high myopia. However, it is associated with multiple complications.

CASE SUMMARY

This report describes a case of full-thickness macular hole (MH) in a patient with a history of bilateral pIOL implantation for the correction of myopia of -12.00 diopters in both eyes 7 mo ago. The MH closed after pars plana vitrectomy with internal limiting membrane removal and the best-corrected visual acuity improved to 20/40 in the left eye.

CONCLUSION

In rare cases, MH can occur following pIOL. In this present case report, we analyzed the formation process of MH following the surgery and emphasized that it is important to inform highly myopic patients about the risk of MH occurrence while being aware of the symptoms of this complication.

Key Words: Case report; Macular hole; Phakic intraocular lens; Pars plana vitrectomy; High myopia; Impaired visual acuity

©The Author(s) 2022. Published by Baishideng Publishing Group Inc. All rights reserved.

Core Tip: Although phakic intraocular lenses have been commonly prescribed and are safe and effective, they are still associated with multiple complications. One of the rare complications is a full-thickness macular hole occurring after phakic intraocular lens implantation. Therefore, it is important to inform highly myopic patients about the risk of MH occurrence and be attentive to the symptoms of this complication.

Citation: Li XJ, Duan JL, Ma JX, Shang QL. Macular hole following phakic intraocular lens implantation: A case report. *World J Clin Cases* 2022; 10(20): 7178-7183

URL: <https://www.wjgnet.com/2307-8960/full/v10/i20/7178.htm>

DOI: <https://dx.doi.org/10.12998/wjcc.v10.i20.7178>

INTRODUCTION

Phakic intraocular lens (pIOL) implantation has been commonly prescribed since the 1980s. It is accepted as a safe and effective option for correcting high myopia in patient's ineligible for corneal refractive surgery[1]. However, complications associated with pIOL include the reduced density of central endothelial cells, development of pigmentary dispersion, cataracts and glaucoma[1]. In addition, a few cases of vitreoretinal complications such as giant retinal tears and retinal detachment have been reported[2]. We present a rare occurrence of macular hole (MH) as a complication of pIOL implantation for the treatment of high myopia.

CASE PRESENTATION

Chief complaints

A 29-year-old female presented with a 10-day history of impaired visual acuity (VA) and distorted vision in the left eye.

History of present illness

The patient had undergone pIOL implantation in the posterior chamber for the correction of myopia of -12.00 diopters in both eyes 7 mo prior to the onset of symptoms described above. PIOL implantation improved the vision of the patient whose VA was 20/20 in both eyes after the treatment.

History of past illness

The patient had no history of systemic illness or obvious changes in the retina or vitreous before the pIOL implantation.

Physical examination

The initial examination showed that the best corrected visual acuity (BCVA) of this patient was 20/20 in the right eye and 20/100 in the left eye with normal intraocular pressure. The axial length was 27.18 mm in the right eye and 27.00 mm in the left eye. The slit-lamp examination showed that the pIOL was present in both eyes with an unremarkable anterior segment in the rest of the area. The funduscopic examination revealed a round-shaped MH in the left eye (Figure 1A) and the appearance of a tessellated fundus with a tilted disc in bilateral eyes.

Imaging examinations

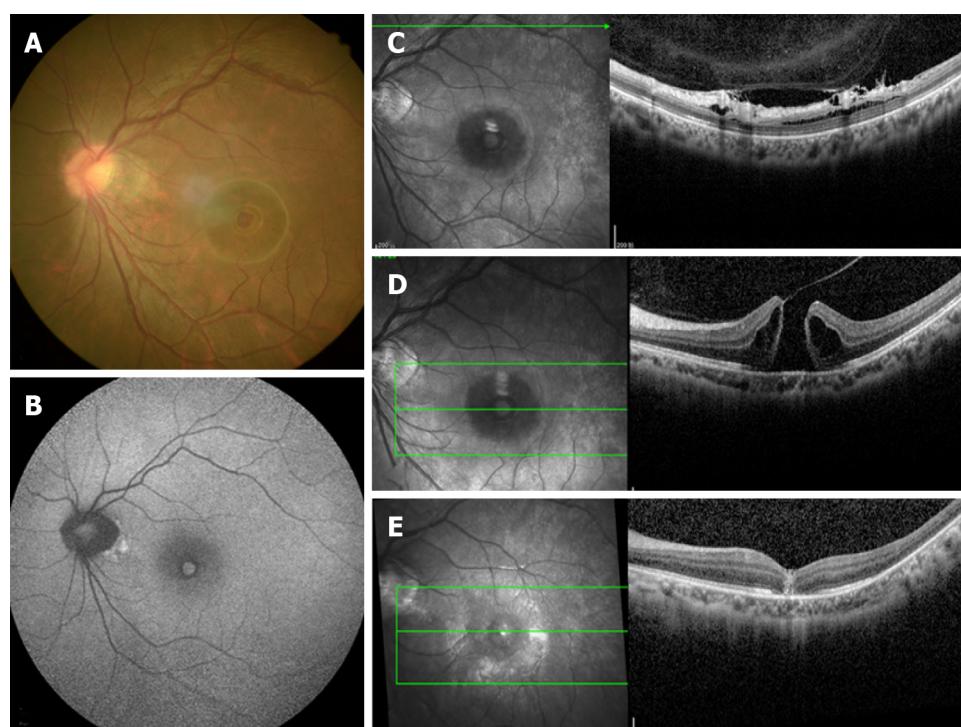
An optical coherence tomography (OCT) revealed a full-thickness MH in the left eye with surrounding subretinal fluid and perifoveal cystic changes at the rim of the hole (Figure 1D), which had a diameter of 520 mm horizontally and 482 mm vertically. In addition, vitreoretinal traction that was induced by partial posterior vitreous detachment (PVD) was documented at the fovea as well as in the area close to the superior vascular arcade, with an increased retinal thickness and retinal layer splitting (Figure 1C). It should be noted that these findings were not present in the preoperative OCT examination of both eyes (Figure 2). The fundus autofluorescence image of the left eye revealed hyper-autofluorescence surrounding the MH (Figure 1B).

FINAL DIAGNOSIS

Full-thickness MH following bilateral pIOL implantation.

TREATMENT

The patient underwent 23-gauge three-port pars plana vitrectomy with triamcinolone-assisted PVD induction. Subsequently, the internal limiting membrane was removed by staining with 0.5% indocyanine green followed by gas tamponade (12% C3F8).



DOI: 10.12998/wjcc.v10.i20.7178 Copyright ©The Author(s) 2022.

Figure 1 Examination of the left eye. A: Color photograph revealed a round-shaped macular hole (MH), appearance of temporal crescent and tessellated fundus with a tilted disc; B: Fundus autofluorescence image showing hyper-autofluorescence corresponding to the MH and a circumferential hypo-autofluorescence; C: Optical coherence tomography (OCT) pre-operatively revealed vitreoretinal traction that was induced by partial posterior vitreous detachment in the area close to the superior vascular arcade; D: OCT pre-operatively revealed a complete thickness MH bordered by cystic spaces; E: Post-operatively at 2 wk showing anatomical closure of the MH.

OUTCOME AND FOLLOW-UP

The MH closed at 2 wk after the operation (Figure 1E) and the BCVA had improved to 20/40.

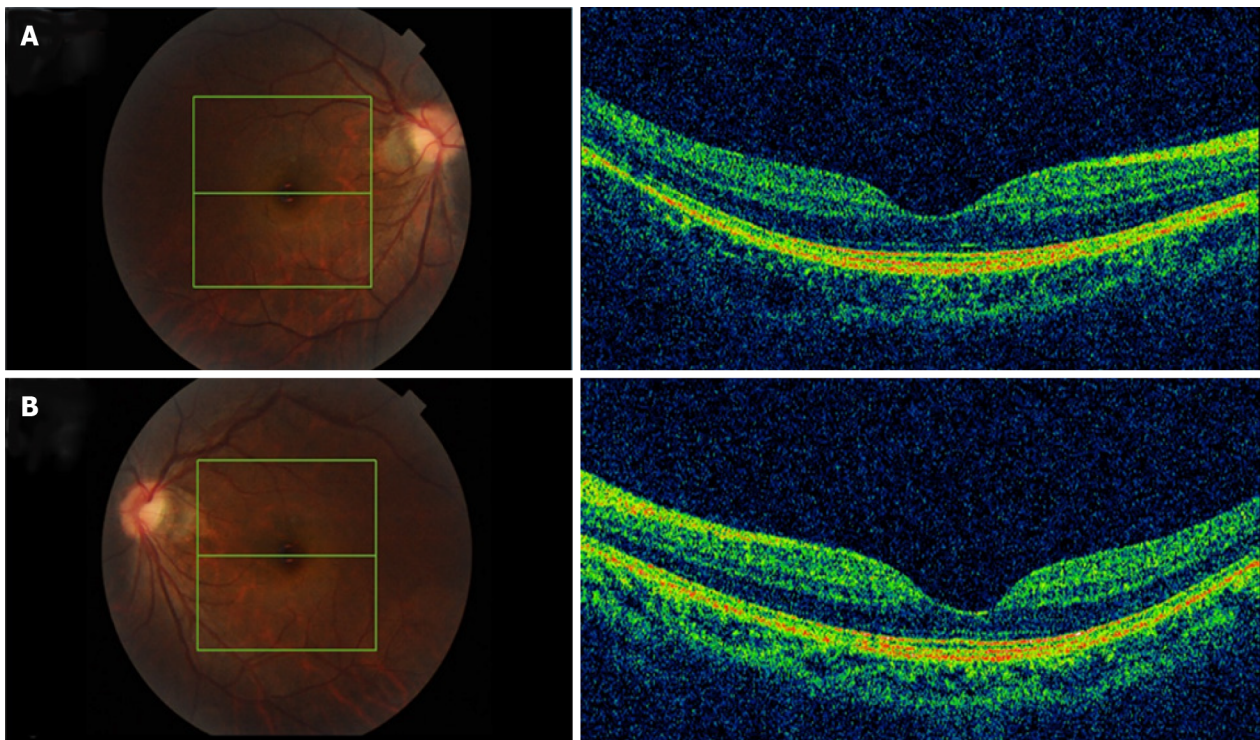
DISCUSSION

Most MHs are idiopathic and frequently occur in the elderly and women. However, they may also be correlated to high myopia, trauma, and surgeries, including vitrectomy, pneumatic retinopexy, scleral buckling, laser-assisted *in situ* keratomileusis and cataract surgery[3,4]. In rare cases, MH can occur following pIOL[5,6].

To our knowledge, three cases have been described in two previous reports[5,6]. In one of these cases, the MH had a similar morphology as the traumatic MH with a rhomboid-shaped appearance. In addition, defects in the internal limiting membrane were present and a lack of subretinal fluid and cystic formation was observed. The remaining two cases had similar features as an idiopathic MH with a round-shaped appearance and edema in the perifoveal retina surrounded by subretinal fluid. The present case had characteristics similar to the latter MHs.

Previous case reports have proposed that a MH might have already existed and was misdiagnosed before pIOL implantation; otherwise, it might be a part of the natural course of high myopic change or induced by the surgery[7]. In the present case, preoperative OCT examination revealed normal morphology at the fovea in both eyes, without PVD, posterior staphyloma or foveoschisis, which differs from myopic MH. Therefore, it is likely that the PVD formation was related to the surgery and subsequently led to the occurrence of MH[8,9].

As suggested by Gass, during the PVD process, MH formation is initiated by the tangential traction of the premacular vitreous cortex at the retinal interface which then leads to foveal dehiscence that progresses from foveolar detachment to a mature full-thickness MH[10]. Highly myopic patients tend to show PVD at a younger age and the surgery might accelerate the process. Luna *et al*[11] have demonstrated that PVD with vitreous liquefaction was not present prior to LASIK but was documented afterwards in 24%–50% of highly myopic eyes. In recent years, in-depth research on posterior precortical vitreous pocket (PPVP) has proved that the aqueous can flow into the PPVP through the Cloquet's canal[10], therefore, we speculated that the flow of aqueous humor caused by fluctuation of intraocular pressure during the surgery was drained into the premacular space which initiated the



DOI: 10.12998/wjcc.v10.i20.7178 Copyright ©The Author(s) 2022.

Figure 2 Optical coherence tomography examination of both eyes before phakic intraocular lens surgery revealed a normal macula, without posterior vitreous detachment, posterior staphyloma, or foveoschisis. A: Right eye; B: Left eye.

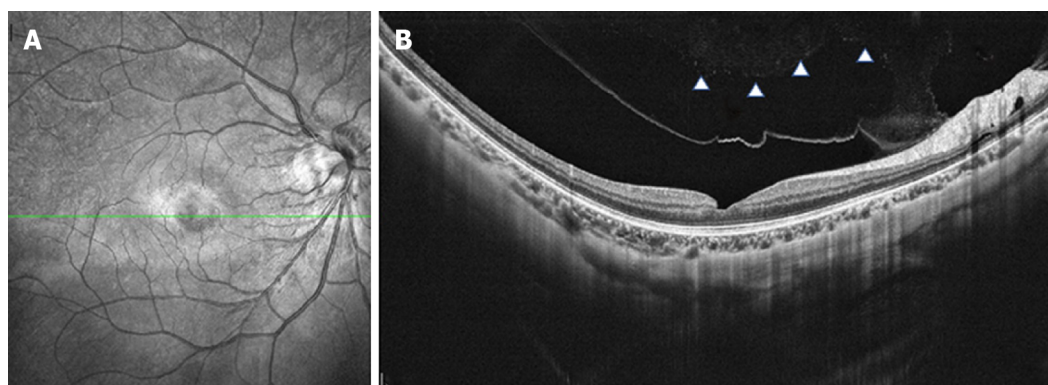
process of PVD.

Early in the PVD process, the vitreous detaches from the perifoveal area but maintains attachment at the central fovea, the optic disc and the vascular arcade area where vitreoretinal attachments are stronger. Over time, assisted by vitreous movement, anteroposterior tractional forces at the fovea were generated leading to pathogenic vitreous traction. Mori *et al*[12] presented the hypothesis that dynamic traction attributable to vitreous movement associated with ocular saccades is the most important type of vitreomacular traction in MH formation. A larger PPVP in highly myopic eyes is associated with a greater level of concentrated force and a more pronounced shift in the force vector direction of the anteroposterior tensile stress[10]. The traction force varies depending on the configuration and angle of vitreous insertion into the peripheral retina[12]. Therefore, as the OCT revealed, the vitreofoveal attachment was released in the right eye (Figure 3) which led to a slight abnormality of retinal morphology. In contrast, the MH was formed in the left eye.

Furthermore, focal cellular proliferation of the vitreous face and weak adherence of the retinal pigment epithelium-photoreceptor should not be neglected. In addition, the effect of various refractive surgeries on choroidal thickness (CT) has been reported in recent years. Fang *et al*[13] evaluated the changes in choroid thickness after pIOL surgery and found that the CT in the foveal was significantly increased at 3 mo after the surgery and then gradually recovered. In all three cases, which had similar features as the present case, the MH formed at 4, 7, and 18 mo after the surgery. Zeng *et al*[14] considered that choroidal thinning might be one of the reasons for the development of MH. Therefore, the fluctuation of CT might play a role in the formation of MHs; however, the precise relationship needs to be elucidated by more clinical studies.

CONCLUSION

It remains difficult to determine the risk factors for MH formation after refractive surgery. Thus, further case-control studies are needed to address this question. Although the incidence rate of MH occurrence is low, the present case report emphasizes that it is important to inform patients about the risk of MH occurrence and be aware of the symptoms of this complication. The patients can then receive assistance promptly and efficiently after the onset of MH formation.



DOI: 10.12998/wjcc.v10.i20.7178 Copyright ©The Author(s) 2022.

Figure 3 Optical coherence tomography examination of the right eye. A: Partial posterior vitreous detachment 7 mo after phakic intraocular lens (pIOL) surgery; B: Complete posterior vitreous detachment 1 yr after pIOL surgery with a slight abnormality in retinal morphology.

FOOTNOTES

Author contributions: Li XJ and Duan JL reviewed the literature and wrote the manuscript draft; Ma JX and Shang QL performed the microbiological analyses and interpretation and contributed to manuscript drafting; Li XJ analyzed and interpreted the imaging findings; Duan JL and Ma JX performed the infectious diseases consultation, reviewed the literature and drafted the manuscript; All authors were responsible for the revision of the manuscript for important intellectual content, and approved the final version for submission.

Informed consent statement: Informed written consent was obtained from the patient for publication of this report and any accompanying images.

Conflict-of-interest statement: The authors declare that they have no conflict of interest.

CARE Checklist (2016) statement: The authors have read the CARE Checklist (2016), and the manuscript was prepared and revised according to the CARE Checklist (2016).

Open-Access: This article is an open-access article that was selected by an in-house editor and fully peer-reviewed by external reviewers. It is distributed in accordance with the Creative Commons Attribution NonCommercial (CC BY-NC 4.0) license, which permits others to distribute, remix, adapt, build upon this work non-commercially, and license their derivative works on different terms, provided the original work is properly cited and the use is non-commercial. See: <https://creativecommons.org/licenses/by-nc/4.0/>

Country/Territory of origin: China

ORCID number: Qing-Li Shang 0000-0003-4181-6703.

S-Editor: Ma YJ

L-Editor: Filipodia

P-Editor: Ma YJ

REFERENCES

- 1 Jiménez-Alfaro I, Benítez del Castillo JM, García-Feijó J, Gil de Bernabé JG, Serrano de La Iglesia JM. Safety of posterior chamber phakic intraocular lenses for the correction of high myopia: anterior segment changes after posterior chamber phakic intraocular lens implantation. *Ophthalmology* 2001; **108**: 90-99 [PMID: 11150270 DOI: 10.1016/s0161-6420(00)00403-6]
- 2 Jiang T, Chang Q, Wang X, Huang X. Retinal detachment after phakic intraocular lens implantation in severe myopic eyes. *Graefes Arch Clin Exp Ophthalmol* 2012; **250**: 1725-1730 [PMID: 22476574 DOI: 10.1007/s00417-012-2002-z]
- 3 Arevalo JF, Mendoza AJ, Velez-Vazquez W, Rodriguez FJ, Rodriguez A, Rosales-Meneses JL, Yopez JB, Ramirez E, Dessouki A, Chan CK, Mitra RA, Ramsay RC, Garcia RA, Ruiz-Moreno JM. Full-thickness macular hole after LASIK for the correction of myopia. *Ophthalmology* 2005; **112**: 1207-1212 [PMID: 15921746 DOI: 10.1016/j.ophtha.2005.01.046]
- 4 Papathanassiou M, Alonistiotis D, Petrou P, Theodossiadis P, Vergados I. Macular hole formation following phacoemulsification cataract surgery. *Clin Exp Optom* 2011; **94**: 112-114 [PMID: 21198840 DOI: 10.1111/j.1444-0938.2010.00525.x]
- 5 Jun JH, Kim YC, Kim KS. Macular hole after phakic intraocular lens implantation: two cases with divergent manifestations. *Semin Ophthalmol* 2014; **29**: 213-217 [PMID: 24171834 DOI: 10.3109/08820538.2013.835839]
- 6 Kumar A, Padhy SK, Dhiman R, Kumar P, Parekh T, Varshney T. Macular hole following phakic intraocular lens

- implantation and its management. *Indian J Ophthalmol* 2019; **67**: 1758-1760 [PMID: [31546556](#) DOI: [10.4103/ijo.IJO_126_19](#)]
- 7 **Hayashi K**, Manabe SI, Hirata A, Yoshimura K. Posterior Vitreous Detachment in Highly Myopic Patients. *Invest Ophthalmol Vis Sci* 2020; **61**: 33 [PMID: [32334432](#) DOI: [10.1167/iovs.61.4.33](#)]
 - 8 **Kishi S**, Shimizu K. Posterior precortical vitreous pocket. *Arch Ophthalmol* 1990; **108**: 979-982 [PMID: [2369358](#) DOI: [10.1001/archophth.1990.01070090081044](#)]
 - 9 **Itakura H**, Kishi S, Li D, Akiyama H. Observation of posterior precortical vitreous pocket using swept-source optical coherence tomography. *Invest Ophthalmol Vis Sci* 2013; **54**: 3102-3107 [PMID: [23599325](#) DOI: [10.1167/iovs.13-11769](#)]
 - 10 **Gass JD**. Idiopathic senile macular hole. Its early stages and pathogenesis. *Arch Ophthalmol* 1988; **106**: 629-639 [PMID: [3358729](#) DOI: [10.1001/archophth.1988.01060130683026](#)]
 - 11 **Luna JD**, Artal MN, Reviglio VE, Pelizzari M, Diaz H, Juarez CP. Vitreoretinal alterations following laser in situ keratomileusis: clinical and experimental studies. *Graefes Arch Clin Exp Ophthalmol* 2001; **239**: 416-423 [PMID: [11561789](#) DOI: [10.1007/s004170100295](#)]
 - 12 **Mori K**, Gehlbach PL, Kishi S. Posterior vitreous mobility delineated by tracking of optical coherence tomography images in eyes with idiopathic macular holes. *Am J Ophthalmol* 2015; **159**: 1132-1141.e1 [PMID: [25743339](#) DOI: [10.1016/j.ajo.2015.02.016](#)]
 - 13 **Fang D**, Li Q, Yan K, Xu S, Jiang J, Che X, Zhang Y, Qian Y, Wang Z. Retinal and Choroidal Thickness in relation to C-Reactive Protein on Swept-Source Optical Coherence Tomography. *J Immunol Res* 2021; **2021**: 6628224 [PMID: [33564690](#) DOI: [10.1155/2021/6628224](#)]
 - 14 **Zeng J**, Li J, Liu R, Chen X, Pan J, Tang S, Ding X. Choroidal thickness in both eyes of patients with unilateral idiopathic macular hole. *Ophthalmology* 2012; **119**: 2328-2333 [PMID: [22892154](#) DOI: [10.1016/j.ophtha.2012.06.008](#)]



Published by **Baishideng Publishing Group Inc**
7041 Koll Center Parkway, Suite 160, Pleasanton, CA 94566, USA

Telephone: +1-925-3991568

E-mail: bpgoffice@wjgnet.com

Help Desk: <https://www.f6publishing.com/helpdesk>

<https://www.wjgnet.com>

