

World Journal of *Clinical Cases*

World J Clin Cases 2022 July 26; 10(21): 7187-7619



Contents

Thrice Monthly Volume 10 Number 21 July 26, 2022

OPINION REVIEW

- 7187 Effects of glucocorticoids on leukocytes: Genomic and non-genomic mechanisms
Jia WY, Zhang JJ

MINIREVIEWS

- 7195 Apheresis: A cell-based therapeutic tool for the inflammatory bowel disease
Yasmin F, Najeeb H, Naeem U, Moeed A, Koritala T, Surani S
- 7209 *Helicobacter pylori* infection and small intestinal bacterial overgrowth—more than what meets the eye
Dharan M, Wozny D
- 7215 Anatomy of the anterolateral ligament of the knee joint
Park JG, Han SB, Rhim HC, Jeon OH, Jang KM

ORIGINAL ARTICLE

Clinical and Translational Research

- 7224 Molecular mechanisms of Biyu decoction as treatment for psoriasis: A network pharmacology and molecular docking study
Wang Z, Zhang HM, Guo YR, Li LL
- 7242 Expression of hepatocyte nuclear factor 4 alpha, wingless-related integration site, and β -catenin in clinical gastric cancer
Hu Q, Li LL, Peng Z, Yi P

Case Control Study

- 7256 Improved Pittsburgh Sleep Quality Index scores on first postoperative night achieved by propofol anesthesia in patients undergoing ambulatory gynecologic surgery
Hu CH, Chou WY
- 7265 Efficacy of Guhong injection *versus* Butylphthalide injection for mild ischemic stroke: A multicenter controlled study
Zhang WW, Xin J, Zhang GY, Zhai QJ, Zhang HM, Wu CS

Retrospective Study

- 7275 Clinical values of Barcelona Clinic Liver Cancer subgroup and up-to-7 criteria in intermediate stage hepatocellular carcinoma with transcatheter arterial chemoembolization
Lee SW, Peng YC, Lien HC, Ko CW, Tung CF, Chang CS
- 7285 Intervention effect of encouraging mental and programmed nursing of patients in interventional operating room on their compliance and bad moods
Chi RB, Cai YY, Mao HP

- 7293** Preoperative neoadjuvant chemotherapy in patients with breast cancer evaluated using strain ultrasonic elastography
Pan HY, Zhang Q, Wu WJ, Li X
- 7302** Risk factors for delayed intracranial hemorrhage secondary to ventriculoperitoneal shunt: A retrospective study
Chen JC, Duan SX, Xue ZB, Yang SY, Li Y, Lai RL, Tan DH
- 7314** Sequential treatment of severe pneumonia with respiratory failure and its influence on respiratory mechanical parameters and hemodynamics
Niu BY, Wang G, Li B, Zhen GS, Weng YB
- 7324** Effects of alendronate sodium combined with InterTan on osteoporotic femoral intertrochanteric fractures and fracture recurrence
Wang KM, Wei SP, Yin XY, Meng QJ, Kong YM
- 7333** Correlation of magnetic resonance imaging quantitative parameters and apparent diffusion coefficient value with pathological breast cancer
Wang Z, Ren GY, Yin Q, Wang Q
- 7341** Risk factors for delirium after surgery for craniocerebral injury in the neurosurgical intensive care unit
Chen RY, Zhong CH, Chen W, Lin M, Feng CF, Chen CN

Observational Study

- 7348** Effect of osteoarthritic knee flexion deformity correction by total knee arthroplasty on sagittal spinopelvic alignment in Indian population
Puthiyapura LK, Jain M, Tripathy SK, Puliappadamb HM
- 7356** Imaging characteristics of orbital peripheral nerve sheath tumors: Analysis of 34 cases
Dai M, Wang T, Wang JM, Fang LP, Zhao Y, Thakur A, Wang D

Randomized Controlled Trial

- 7365** Comparison of involved-field intensity-modulated radiotherapy combined with S-1 *vs* radiotherapy alone for elderly patients with esophageal cancer
Liu LH, Yan MH, Di YP, Fu ZG, Zhang XD, Li HQ

Randomized Clinical Trial

- 7376** Dexmedetomidine in pediatric unilateral internal inguinal ring ligation
Liu G, Zhang L, Wang HS, Lin Y, Jin HQ, Wang XD, Qiao WN, Zhang YT, Sun JQ, Liu ZN

META-ANALYSIS

- 7386** Impact of cancer on mortality rates in patients with sepsis: A meta-analysis and meta-regression of current studies
Xiang MJ, Chen GL

CASE REPORT

- 7397** Updated clinical and glycomic features of mannosyl-oligosaccharide glucosidase deficiency: Two case reports
Abuduxikuer K, Wang L, Zou L, Cao CY, Yu L, Guo HM, Liang XM, Wang JS, Chen L
- 7409** Solitary necrotic nodules of the liver with "ring"-like calcification: A case report
Bao JP, Tian H, Wang HC, Wang CC, Li B
- 7415** Corticosteroid-induced bradycardia in multiple sclerosis and maturity-onset diabetes of the young due to hepatocyte nuclear factor 4-alpha mutation: A case report
Sohn SY, Kim SY, Joo IS
- 7422** Essential thrombocythemia with non-ST-segment elevation myocardial infarction as the first manifestation: A case report
Wang ZM, Chen WH, Wu YM, Wang LQ, Ye FL, Yin RL
- 7429** Extranasopharyngeal angiofibroma in children: A case report
Yan YY, Lai C, Wu L, Fu Y
- 7438** Deep Sylvian fissure meningiomas: A case report
Wang A, Zhang X, Sun KK, Li C, Song ZM, Sun T, Wang F
- 7445** Acute pulmonary embolism originating from upper limb venous thrombosis following breast cancer surgery: Two case reports
Duan Y, Wang GL, Guo X, Yang LL, Tian FG
- 7451** Managing spondylitis tuberculosis in a patient with underlying diabetes and hypothyroidism: A case report
Novita BD, Muliono AC, Wijaya S, Theodora I, Tjahjono Y, Supit VD, Willianto VM
- 7459** Ovarian mucinous tumor with mural nodules of anaplastic carcinoma: Three case reports
Wang XJ, Wang CY, Xi YF, Bu P, Wang P
- 7467** Transcatheter arterial infusion chemotherapy and embolization for primary lacrimal sac squamous cell carcinoma: A case report
Sun MH, Yi WD, Shen L, Zhou L, Lu JX
- 7474** Programmed cell death-1 inhibitor combination treatment for recurrent proficient mismatch repair/microsatellite-stable type endometrial cancer: A case report
Zhai CY, Yin LX, Han WD
- 7483** Novel compound heterozygous mutation of *SLC12A3* in Gitelman syndrome co-existent with hyperthyroidism: A case report and literature review
Qin YZ, Liu YM, Wang Y, You C, Li LN, Zhou XY, Lv WM, Hong SH, Xiao LX
- 7495** Successful treatment of hyperglycemia with liraglutide in a hospitalized 27-year-old patient with schizophrenia: A case report
Zhang L, Yu WJ, Zhu H, Li HF, Qiao J

- 7502** Refractory lymphoma treated with chimeric antigen receptor T cells combined with programmed cell death-1 inhibitor: A case report
Zhang CJ, Zhang JY, Li LJ, Xu NW
- 7509** Median arcuate ligament syndrome with retroperitoneal haemorrhage: A case report
Lu XC, Pei JG, Xie GH, Li YY, Han HM
- 7517** Novel frameshift mutation in the *AHDC1* gene in a Chinese global developmental delay patient: A case report
Lin SZ, Xie HY, Qu YL, Gao W, Wang WQ, Li JY, Feng XC, Jin CQ
- 7523** Selective nerve block for the treatment of neuralgia in Kummell's disease: A case report
Zhang X, Li ZX, Yin LJ, Chen H
- 7531** Traditional Chinese medicine manipulative reduction combined with percutaneous vertebroplasty for treating type III Kummell's disease: A case report
Hao SS, Zhang RJ, Dong SL, Li HK, Liu S, Li RF, Ren HH, Zhang LY
- 7539** Differential diagnosis and treatment of foot drop caused by an extraneural ganglion cyst above the knee: A case report
Won KH, Kang EY
- 7545** Effect of hydrogen intervention on refractory wounds after radiotherapy: A case report
Zhao PX, Luo RL, Dang Z, Wang YB, Zhang XJ, Liu ZY, Wen XH, Liu MY, Zhang MZ, Adzavon YM, Ma XM
- 7553** Chronic urticaria associated with lung adenocarcinoma — a paraneoplastic manifestation: A case report and literature review
Jiménez LF, Castellón EA, Marengo JD, Mejía JM, Rojas CA, Jiménez FT, Coronell L, Osorio-Llanes E, Mendoza-Torres E
- 7565** Spinal giant cell-rich osteosarcoma-diagnostic dilemma and treatment strategy: A case report
Tseng CS, Wong CE, Huang CC, Hsu HH, Lee JS, Lee PH
- 7571** Primary clear cell sarcoma of soft tissue in the posterior cervical spine invading the medulla oblongata: A case report
Liu CC, Huang WP, Gao JB
- 7577** *Pseudomonas aeruginosa*-related effusive-constrictive pericarditis diagnosed with echocardiography: A case report
Chen JL, Mei DE, Yu CG, Zhao ZY
- 7585** Maternal peripartum bacteremia caused by intrauterine infection with *Comamonas kerstersii*: A case report
Qu H, Zhao YH, Zhu WM, Liu L, Zhu M
- 7592** Considerations of single-lung ventilation in neonatal thoracoscopic surgery with cardiac arrest caused by bilateral pneumothorax: A case report
Zhang X, Song HC, Wang KL, Ren YY

- 7599** Rare primary rectal mucosa-associated lymphoid tissue lymphoma with curative resection by endoscopic submucosal dissection: A case report and review of literature

Tao Y, Nan Q, Lei Z, Miao YL, Niu JK

- 7609** Differences in examination results of small anastomotic fistula after radical gastrectomy with afterward treatments: A case report

Lu CY, Liu YL, Liu KJ, Xu S, Yao HL, Li L, Guo ZS

LETTER TO THE EDITOR

- 7617** Baseline differences may impact on relationship between dietary tryptophan and risk of obesity and type 2 diabetes

Ren XH, Ye YW, He LP

ABOUT COVER

Editorial Board Member of *World Journal of Clinical Cases*, Rajesh Kumar Rajnish, MBBS, MS, Assistant Professor, Department of Orthopaedics, All India Institute of Medical Sciences, Bilaspur, Bilaspur 174001, Himachal Pradesh, India. duktiraj@gmail.com

AIMS AND SCOPE

The primary aim of *World Journal of Clinical Cases* (WJCC, *World J Clin Cases*) is to provide scholars and readers from various fields of clinical medicine with a platform to publish high-quality clinical research articles and communicate their research findings online.

WJCC mainly publishes articles reporting research results and findings obtained in the field of clinical medicine and covering a wide range of topics, including case control studies, retrospective cohort studies, retrospective studies, clinical trials studies, observational studies, prospective studies, randomized controlled trials, randomized clinical trials, systematic reviews, meta-analysis, and case reports.

INDEXING/ABSTRACTING

The WJCC is now abstracted and indexed in Science Citation Index Expanded (SCIE, also known as SciSearch®), Journal Citation Reports/Science Edition, Current Contents®/Clinical Medicine, PubMed, PubMed Central, Scopus, Reference Citation Analysis, China National Knowledge Infrastructure, China Science and Technology Journal Database, and Superstar Journals Database. The 2022 Edition of Journal Citation Reports® cites the 2021 impact factor (IF) for WJCC as 1.534; IF without journal self cites: 1.491; 5-year IF: 1.599; Journal Citation Indicator: 0.28; Ranking: 135 among 172 journals in medicine, general and internal; and Quartile category: Q4. The WJCC's CiteScore for 2021 is 1.2 and Scopus CiteScore rank 2021: General Medicine is 443/826.

RESPONSIBLE EDITORS FOR THIS ISSUE

Production Editor: *Ying-Yi Yuan*; Production Department Director: *Xiang Li*; Editorial Office Director: *Jin-Lei Wang*.

NAME OF JOURNAL

World Journal of Clinical Cases

ISSN

ISSN 2307-8960 (online)

LAUNCH DATE

April 16, 2013

FREQUENCY

Thrice Monthly

EDITORS-IN-CHIEF

Bao-Gan Peng, Jerzy Tadeusz Chudek, George Kontogeorgos, Maurizio Serati, Ja Hyeon Ku

EDITORIAL BOARD MEMBERS

<https://www.wjnet.com/2307-8960/editorialboard.htm>

PUBLICATION DATE

July 26, 2022

COPYRIGHT

© 2022 Baishideng Publishing Group Inc

INSTRUCTIONS TO AUTHORS

<https://www.wjnet.com/bpg/gerinfo/204>

GUIDELINES FOR ETHICS DOCUMENTS

<https://www.wjnet.com/bpg/GerInfo/287>

GUIDELINES FOR NON-NATIVE SPEAKERS OF ENGLISH

<https://www.wjnet.com/bpg/gerinfo/240>

PUBLICATION ETHICS

<https://www.wjnet.com/bpg/GerInfo/288>

PUBLICATION MISCONDUCT

<https://www.wjnet.com/bpg/gerinfo/208>

ARTICLE PROCESSING CHARGE

<https://www.wjnet.com/bpg/gerinfo/242>

STEPS FOR SUBMITTING MANUSCRIPTS

<https://www.wjnet.com/bpg/GerInfo/239>

ONLINE SUBMISSION

<https://www.f6publishing.com>



Corticosteroid-induced bradycardia in multiple sclerosis and maturity-onset diabetes of the young due to hepatocyte nuclear factor 4-alpha mutation: A case report

Sung-Yeon Sohn, Shin Yeop Kim, In Soo Joo

Specialty type: Clinical neurology

Provenance and peer review:

Unsolicited article; Externally peer reviewed.

Peer-review model: Single blind

Peer-review report's scientific quality classification

Grade A (Excellent): 0
Grade B (Very good): 0
Grade C (Good): C, C
Grade D (Fair): 0
Grade E (Poor): 0

P-Reviewer: MASARU T, Hungary;
Zhao GH, China

A-Editor: Liu X, China

Received: September 24, 2021

Peer-review started: September 24, 2021

First decision: March 3, 2022

Revised: April 8, 2022

Accepted: June 4, 2022

Article in press: June 4, 2022

Published online: July 26, 2022



Sung-Yeon Sohn, Shin Yeop Kim, In Soo Joo, Department of Neurology, Ajou University School of Medicine, Ajou University Medical Center, Suwon 16499, South Korea

Corresponding author: In Soo Joo, MD, Professor, Department of Neurology, Ajou University School of Medicine, Ajou University Medical Center, No.164 World Cup Road, Yongtong District, Suwon 16499, South Korea. isjoo@ajou.ac.kr

Abstract

BACKGROUND

Intravenous steroid pulse therapy is the treatment of choice for acute exacerbation of multiple sclerosis (MS). Although steroid administration is generally well-tolerated, cases of cardiac arrhythmia have been reported. Herein, we describe a young woman who developed marked sinus bradycardia and T-wave abnormalities after corticosteroid administration. We also present plausible explanations for the abnormalities observed in this patient.

CASE SUMMARY

An 18-year-old woman experienced vertiginous dizziness and binocular diplopia 1 wk prior to admission. Neurological examination revealed left internuclear ophthalmoplegia with left peripheral-type facial palsy. The initial laboratory results were consistent with those of type 2 diabetes. Brain magnetic resonance imaging revealed multifocal, non-enhancing, symptomatic lesions and multiple enhancing lesions. She was diagnosed with MS and maturity-onset diabetes of the young. Intravenous methylprednisolone was administered. On day 5 after methylprednisolone infusion, marked bradycardia with T-wave abnormalities were observed. Genetic evaluation to elucidate the underlying conditions revealed a hepatocyte nuclear factor 4-alpha (HNF4A) gene mutation. Steroid treatment was discontinued under suspicion of corticosteroid-induced bradycardia. Her electrocardiogram changes returned to normal without complications two days after steroid discontinuation.

CONCLUSION

Corticosteroid-induced bradycardia may have a significant clinical impact, especially in patients with comorbidities, such as HNF4A mutations.

Key Words: Steroids; Bradycardia; Multiple sclerosis; Maturity-onset diabetes of the

young; Hepatocyte nuclear factor 4-alpha; Case report

©The Author(s) 2022. Published by Baishideng Publishing Group Inc. All rights reserved.

Core Tip: Corticosteroid administration may cause cardiac arrhythmias including severe bradycardia. The accompanying T-wave abnormalities may provide clues regarding the pathophysiology of corticosteroid-induced bradycardia. This case report highlights the need for clinical vigilance during high-dose corticosteroid administration, particularly in potentially vulnerable patients harboring genetic variants.

Citation: Sohn SY, Kim SY, Joo IS. Corticosteroid-induced bradycardia in multiple sclerosis and maturity-onset diabetes of the young due to hepatocyte nuclear factor 4-alpha mutation: A case report. *World J Clin Cases* 2022; 10(21): 7415-7421

URL: <https://www.wjgnet.com/2307-8960/full/v10/i21/7415.htm>

DOI: <https://dx.doi.org/10.12998/wjcc.v10.i21.7415>

INTRODUCTION

Multiple sclerosis (MS) is an immune-mediated demyelinating disorder of the central nervous system. Treatment strategies for MS can be divided into two categories: disease-modifying therapies (DMT) and treatment of acute relapses[1]. High-dose pulsed intravenous methylprednisolone infusion is the treatment of choice for acute exacerbation of MS, although other options such as oral methylprednisolone or plasma exchange can sometimes be considered[1]. Generally, there is no absolute contraindication for intravenous steroid pulse therapy, except for rare cases of documented hypersensitivity to methylprednisolone succinate or fulminant systemic fungal infections[2]. However, sinus bradycardia may occur because of steroid administration, especially in specific groups of patients with rheumatoid diseases[3-5], nephrotic syndrome[6], and MS[7].

Comorbid conditions may affect MS patients in terms of disease activity[8], quality of life, and treatment choice[9]. To date, the effects of comorbidities on treatment-related topics have been mainly investigated during DMT[10,11]. Herein, we describe a young woman who was diagnosed with MS and maturity-onset diabetes of the young (MODY) due to a hepatocyte nuclear factor 4-alpha (HNF4A) gene mutation. She developed marked sinus bradycardia and T-wave abnormalities during acute management with high-dose corticosteroids. Thus, the possible role of comorbid genetic disorders in the development of corticosteroid-induced bradycardia in this patient is explored.

CASE PRESENTATION

Chief complaints

An 18-year-old woman experienced vertiginous dizziness and binocular diplopia 1 wk before admission.

History of present illness

The patient's symptoms started 1 wk ago. Diplopia was more pronounced in her right gaze. She was admitted to our hospital for evaluation of diabetes, which was confirmed at a local clinic. The patient was not overweight, and her body mass index was 20.5 kg/m².

History of past illness

She was born by cesarean section at 36 6/7 wk. Her birthweight was 3800 g, which was significantly higher than that of her discordant twin sister, who weighed 2600 g. The patient was admitted to the Department of Pediatrics at the age of 3 and 5 years because of recurrent seizures with hypoglycemic events. Subsequent evaluations including brain magnetic resonance imaging (MRI) and extensive laboratory testing failed to ascertain the cause. However, she successfully attained developmental milestones during infancy and childhood.

Personal and family history

Her paternal grandfather and maternal grandmother had diabetes. Other family members, including parents and twin sibling, did not have diabetes. She did not have a relevant family history of MS or other neurological disorders.

Physical examination

Neurological examination revealed an adduction deficit of the left eye with abducting horizontal nystagmus of the right eye on attempting right gaze, which was compatible with left internuclear ophthalmoplegia. Mild left peripheral-type facial palsy (House-Brackmann grade I) was noted. Other cranial nerve functions; facial sensory examination; motor, sensory, and cerebellar function tests were unremarkable.

Laboratory examinations

Subsequent laboratory test results were consistent with those of type 2 diabetes. Serum C-peptide level was normal, while insulin level was increased at 13.7 μ IU (reference range: 1.1-11.6 μ IU). Glycated hemoglobin was 10.4% (reference range: 4.3%-6.1%). Her anti-glutamic acid decarboxylase antibody levels were normal. Other laboratory evaluations, including anti-nuclear antibody, viral and parasite markers, anti-aquaporin 4 antibody, and anti-myelin oligodendrocyte glycoprotein antibody, were all negative. Cerebrospinal fluid-specific oligoclonal bands were identified by isoelectric focusing technique.

Imaging examinations

Brain MRI revealed a symptomatic lesion involving the left medial longitudinal fasciculus and facial colliculus in the posterior pons (Figure 1A), accompanied by multiple enhancing lesions in the left parietal, right occipital, and right temporal lobes.

Subsequent clinical course of the patient and further diagnostic work-up

The diagnosis of MS was made based on the McDonald criteria 2017 revision. Intravenous methylprednisolone pulse therapy at a daily dosage of 1 g was initiated. On day 5 after methylprednisolone infusion, bradycardia was observed (Figure 1B). Electrocardiography (ECG) revealed marked sinus bradycardia with a heart rate (HR) of 35 beats per minute, T-wave flattening, and T-wave inversion (Figure 2A). The serum potassium level measured at the time of bradycardia was 4.0 mmol/L (reference range: 3.5-5.1 mmol/L) (Figure 1B). As steroid-induced bradycardia was suspected, oral prednisolone was discontinued. Echocardiography and Holter monitoring were unremarkable, except for sinus bradycardia. The cardiac enzyme levels were normal. Her ECG changes returned to baseline 2 days after steroid discontinuation (Figure 2B). Further evaluation was conducted to elucidate the underlying conditions. Diagnostic exome sequencing revealed a heterozygous variant of the HNF4A gene (NM_175914.4: c.1045C>T [p.Gln349*]). It was classified as a pathogenic variant according to the American College of Medical Genetics and Genomics guidelines[12], with evidence levels of PVS1 (null variant), PM2 (absent from population databases), and PP3 (deleterious in silico predictions). The same heterozygous mutation was reported in a study involving a large cohort of MODY[13].

FINAL DIAGNOSIS

The final diagnosis was MS, MODY, and corticosteroid-induced bradycardia with T-wave abnormalities associated with a HNF4A mutation.

TREATMENT

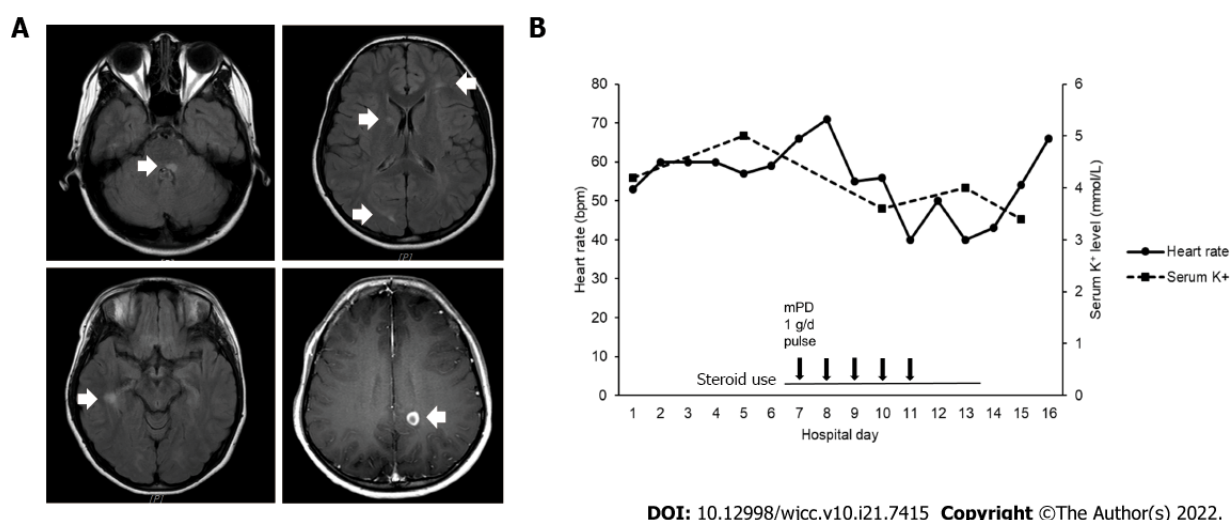
She was treated with daily doses of dimethyl fumarate (480 mg), vitamin D (1000 IU), and metformin (1700 mg).

OUTCOME AND FOLLOW-UP

After 1 mo, the patient was neurologically free of symptoms. Follow-up imaging after 3 mo showed resolution of previous demyelinating lesions.

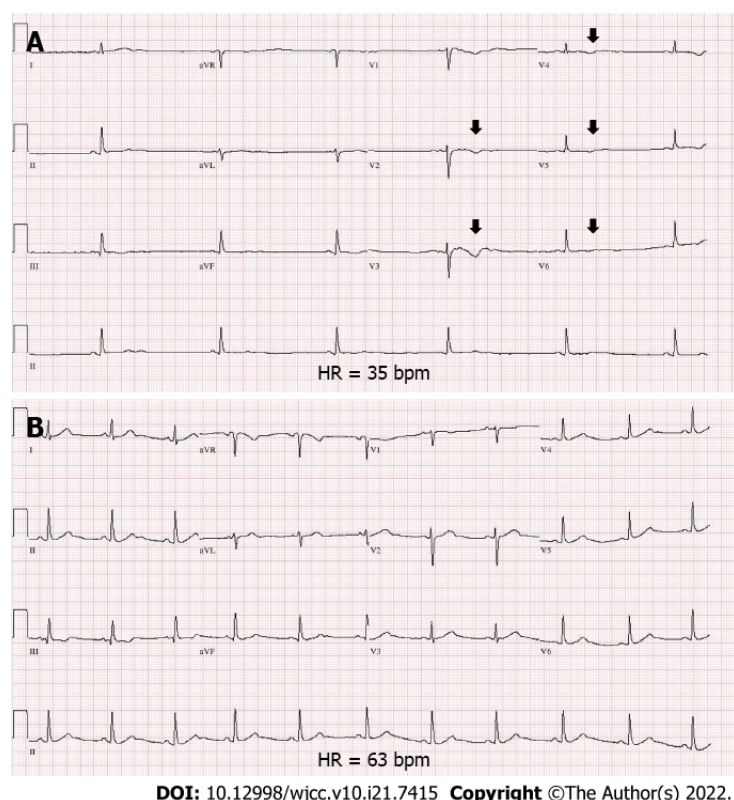
DISCUSSION

Loss of function of HNF4A is associated with MODY[14], congenital hyperinsulinemic hypoglycemia (HH)[13], and Fanconi renal tubular syndrome[15]. MODY due to HNF4A mutation (formerly MODY1) is inherited in an autosomal dominant fashion[14,16]. HNF4A haploinsufficiency due to heterozygous mutations results in pancreatic β -cell dysfunction and impairs insulin secretion[16,17]. Although the patient's parents did not have diabetes, her paternal grandfather and maternal grandmother did. The



DOI: 10.12998/wjcc.v10.i21.7415 Copyright ©The Author(s) 2022.

Figure 1 Brain imaging and clinical course of the patient. A: Axial brain magnetic resonance imaging obtained with T2- fluid-attenuated inversion recovery image and T1-weighted gadolinium enhanced sequences reveals multifocal high signal intensity lesions (white arrows); B: Heart rate and potassium level during hospitalization. Heart rate decreased on day 5 after initiation of intravenous methylprednisolone infusion.



DOI: 10.12998/wjcc.v10.i21.7415 Copyright ©The Author(s) 2022.

Figure 2 Electrocardiogram of the patient. A: Initial electrocardiogram (ECG) reveals marked sinus bradycardia (heart rate of 35 bpm) with flattening and inversion of T-waves (black arrows), mainly in the precordial leads (V1–V5); B: Follow-up ECG showing normalized heart rate and T-wave configuration after steroid discontinuation. ECG: Electrocardiogram; MRI: Magnetic resonance imaging; FLAIR: Fluid-attenuated inversion recovery image; mPD: Methylprednisolone; bpm: Beats per minute.

patient had been admitted to the Department of Pediatrics and had been evaluated for recurrent provoked seizure attacks with hypoglycemic events at the ages of 3 and 5 years (blood sugar level 0.8325 mmol/L and 1.4985 mmol/L, respectively). It is now evident that the HNF4A gene defect is the causative factor for these previous hypoglycemic events. Besides, HNF4A mutations are most common in exons 7 and 8 in the transactivation domain[14]. The nonsense variant in our patient was also predicted to be in a highly conserved position in exon 8.

Although corticosteroid-induced bradycardia was first reported in 1986[5], its precise pathological mechanism remains unclear. An early study by Fujimoto *et al*[6] showed that the fractional excretion of potassium and serum potassium significantly increased after methylprednisolone pulse therapy. The authors suspected that potassium efflux from the myocardial cells and the subsequent decrease in intracellular concentration might cause cardiac arrhythmia[6]. Other studies have suggested reflex bradycardia by activation of low-pressure baroreceptors or possible long QT syndrome gene mutations as possible mechanisms[4]. According to a recent literature review[7], corticosteroid-induced bradycardia seems to occur even with oral steroid administration, and a dose-dependent risk has also been reported[18]. In this patient, the HR decreased as corticosteroid was administered, and the baseline HR recovered after corticosteroid discontinuation. Regarding MS treatment, there was no choice but to quickly initiate DMT, since the use of high-dose corticosteroids—an essential therapy that helps alleviate acute flare-ups of MS[19]—should be avoided.

It is noteworthy that sinus bradycardia was accompanied by T-wave changes despite normokalemia in the present case. Flattening and inversion of T-waves have been known to be associated with hypokalemia. Patients with HNF4A mutations have defective proximal tubule function[20,21] and are prone to urinary loss of serum potassium[21]. Moreover, despite methylprednisolone generally having a minimal mineralocorticoid effect[22], serum potassium may decrease in response to a pulsed dose of methylprednisolone[23]. A sudden change in serum potassium levels in vulnerable patients may result in potassium efflux from myocardial cells[6] to maintain potassium homeostasis. Another explanation for T-wave morphological changes in the clinical setting of normokalemia is the possibility of a dysfunctional potassium channel[24]. In fact, HNF4A mutation is known to cause a reduction in the expression of the inwardly rectifying potassium (Kir) channel subunit 6.2 in pancreatic beta cells[25,26]. Although the role of HNF4A in the heart is largely unknown, there is some anecdotal evidence of HNF4a activity during cardiac development[27], and one can speculate that Kir channels may also show some degree of dysfunction in myocardial cells. Kir allows potassium ions to move easily into rather than out of the cell [28] and is expressed at high density in the cardiac sarcolemma[29]. Mineralocorticoid-induced hypertensive challenge in Kir 6.2 knockout mice resulted in atrioventricular conduction delay, heart failure, and bradycardia[29] which resembled corticosteroid-induced bradycardia. T-wave inversion after methylprednisolone pulse therapy seems to be extremely rare, according to a previous report[30]. An episode of cardiac arrhythmia with U waves on ECG after corticosteroid intake was previously reported in a case series study of Anderson-Tawil syndrome, a rare disease caused by defective Kir 2.1 protein due to KCNJ2 gene mutation[31].

The limitations of this study are briefly described below. Firstly, the genetic evaluation of other family members could not be performed because of non-medical issues. Secondly, the urinary excretion of potassium at the time of the cardiac event was not assessed. The patient's HNF4A variant was not known during the admission period since the results of genetic testing only became available after 1 mo at the outpatient clinic. Thirdly, functional studies to confirm the arrhythmogenic effect of corticosteroids using Hnf4a knockout mouse models were not performed in this case. Lastly, the fact that this report is based on an observation of a single patient makes it difficult to generalize.

The potential genetic susceptibility for the development of drug-induced bradycardia has not been incorporated in recent guidelines[32]. To our knowledge, corticosteroid-induced bradycardia due to comorbid genetic disorders has not been previously described. We believe that our observations provide a direction for future research. One of the first steps would be to use mice models to explore the role of HNF4A mutation during corticosteroid administration. Systematic investigations are needed in the long run, to clarify the role of genetic comorbidities in patients with drug-induced bradyarrhythmia.

CONCLUSION

Corticosteroid-induced bradycardia may have a significant clinical impact, especially in MS patients with comorbid conditions, such as MODY due to HNF4A mutations. The present case is exceptional in that the T-wave abnormalities were accompanied by marked bradycardia. Considering that T-wave changes coincided with bradycardia events, abnormal potassium efflux or dysfunctional potassium channels due to HNF4A mutation might have contributed to the occurrence of corticosteroid-induced bradycardia. Patients with comorbid genetic mutations require special clinical attention, as in the present case.

FOOTNOTES

Author contributions: Sohn S-Y conceptualized, investigated and wrote the manuscript; Kim SY investigated and reviewed the manuscript; Joo IS supervised, reviewed and edited the manuscript.

Informed consent statement: Written informed consent was obtained from the patient.

Conflict-of-interest statement: All authors report no relevant conflict of interest for this article.

CARE Checklist (2016) statement: The authors have read the CARE Checklist (2016), and the manuscript was prepared and revised according to the CARE Checklist (2016).

Open-Access: This article is an open-access article that was selected by an in-house editor and fully peer-reviewed by external reviewers. It is distributed in accordance with the Creative Commons Attribution NonCommercial (CC BY-NC 4.0) license, which permits others to distribute, remix, adapt, build upon this work non-commercially, and license their derivative works on different terms, provided the original work is properly cited and the use is non-commercial. See: <https://creativecommons.org/licenses/by-nc/4.0/>

Country/Territory of origin: South Korea

ORCID number: Sung-Yeon Sohn 0000-0003-4928-2398; Shin Yeop Kim 0000-0003-4035-3508; In Soo Joo 0000-0002-8686-5229.

S-Editor: Wu YXJ

L-Editor: A

P-Editor: Wu YXJ

REFERENCES

- 1 **Thompson AJ**, Baranzini SE, Geurts J, Hemmer B, Ciccarelli O. Multiple sclerosis. *Lancet* 2018; **391**: 1622-1636 [PMID: 29576504 DOI: 10.1016/S0140-6736(18)30481-1]
- 2 **Ocejo A**, Correa R. Methylprednisolone. StatPearls. Treasure Island (FL): StatPearls Publishing. Copyright © 2021, StatPearls Publishing LLC., 2021
- 3 **Pudil R**, Hrnčir Z. Severe bradycardia after a methylprednisolone "minipulse" treatment. *Arch Intern Med* 2001; **161**: 1778-1779 [PMID: 11485514 DOI: 10.1001/archinte.161.14.1778-a]
- 4 **Akikusa JD**, Feldman BM, Gross GJ, Silverman ED, Schneider R. Sinus bradycardia after intravenous pulse methylprednisolone. *Pediatrics* 2007; **119**: e778-e782 [PMID: 17308245 DOI: 10.1542/peds.2006-0029]
- 5 **Tvede N**, Nielsen LP, Andersen V. Bradycardia after high-dose intravenous methylprednisolone therapy. *Scand J Rheumatol* 1986; **15**: 302-304 [PMID: 3798047 DOI: 10.3109/03009748609092597]
- 6 **Fujimoto S**, Kondoh H, Yamamoto Y, Hisanaga S, Tanaka K. Holter electrocardiogram monitoring in nephrotic patients during methylprednisolone pulse therapy. *Am J Nephrol* 1990; **10**: 231-236 [PMID: 1696428 DOI: 10.1159/000168087]
- 7 **Stroeder J**, Evans C, Mansell H. Corticosteroid-induced bradycardia: Case report and review of the literature. *Can Pharm J (Ott)* 2015; **148**: 235-240 [PMID: 26445579 DOI: 10.1177/1715163515597451]
- 8 **Salter A**, Kowalec K, Fitzgerald KC, Cutter G, Marrie RA. Comorbidity is associated with disease activity in MS: Findings from the CombiRx trial. *Neurology* 2020; **95**: e446-e456 [PMID: 32554770 DOI: 10.1212/WNL.00000000000010024]
- 9 **Magyari M**, Sorensen PS. Comorbidity in Multiple Sclerosis. *Front Neurol* 2020; **11**: 851 [PMID: 32973654 DOI: 10.3389/fneur.2020.00851]
- 10 **Zhang T**, Tremlett H, Leung S, Zhu F, Kingwell E, Fisk JD, Bhan V, Campbell TL, Stadnyk K, Yu BN, Marrie RA; CIHR Team in the Epidemiology and Impact of Comorbidity on Multiple Sclerosis. Examining the effects of comorbidities on disease-modifying therapy use in multiple sclerosis. *Neurology* 2016; **86**: 1287-1295 [PMID: 26944268 DOI: 10.1212/WNL.0000000000002543]
- 11 **Laroni A**, Signori A, Maniscalco GT, Lanzillo R, Russo CV, Binello E, Lo Fermo S, Repice A, Annovazzi P, Bonavita S, Clerico M, Baroncini D, Prosperini L, La Gioia S, Rossi S, Cocco E, Frau J, Torri Clerici V, Signoriello E, Sartori A, Zarbo IR, Rasia S, Cordioli C, Cerqua R, Di Sapio A, Lavoragna L, Pontecorvo S, Barrilà C, Saccà F, Frigeni B, Esposito S, Ippolito D, Gallo F, Sormani MP; iMUST group. Assessing association of comorbidities with treatment choice and persistence in MS: A real-life multicenter study. *Neurology* 2017; **89**: 2222-2229 [PMID: 29093064 DOI: 10.1212/WNL.0000000000004686]
- 12 **Richards S**, Aziz N, Bale S, Bick D, Das S, Gastier-Foster J, Grody WW, Hegde M, Lyon E, Spector E, Voelkerding K, Rehm HL; ACMG Laboratory Quality Assurance Committee. Standards and guidelines for the interpretation of sequence variants: a joint consensus recommendation of the American College of Medical Genetics and Genomics and the Association for Molecular Pathology. *Genet Med* 2015; **17**: 405-424 [PMID: 25741868 DOI: 10.1038/gim.2015.30]
- 13 **Flanagan SE**, Kapoor RR, Mali G, Cody D, Murphy N, Schwahn B, Siahaniidou T, Banerjee I, Akcay T, Rubio-Cabezas O, Shield JP, Hussain K, Ellard S. Diazoxide-responsive hyperinsulinemic hypoglycemia caused by HNF4A gene mutations. *Eur J Endocrinol* 2010; **162**: 987-992 [PMID: 20164212 DOI: 10.1530/EJE-09-0861]
- 14 **Colclough K**, Bellanne-Chantelot C, Saint-Martin C, Flanagan SE, Ellard S. Mutations in the genes encoding the transcription factors hepatocyte nuclear factor 1 alpha and 4 alpha in maturity-onset diabetes of the young and hyperinsulinemic hypoglycemia. *Hum Mutat* 2013; **34**: 669-685 [PMID: 23348805 DOI: 10.1002/humu.22279]
- 15 **Clemente M**, Vargas A, Ariceta G, Martínez R, Campos A, Yeste D. Hyperinsulinaemic hypoglycaemia, renal Fanconi syndrome and liver disease due to a mutation in the HNF4A gene. *Endocrinol Diabetes Metab Case Rep* 2017; **2017** [PMID: 28458902 DOI: 10.1530/edm-16-0133]
- 16 **Ferrer J**. A genetic switch in pancreatic beta-cells: implications for differentiation and haploinsufficiency. *Diabetes* 2002; **51**: 2355-2362 [PMID: 12145145 DOI: 10.2337/diabetes.51.8.2355]

- 17 **Marucci A**, Rutigliano I, Fini G, Pezzilli S, Menzaghi C, Di Paola R, Trischitta V. Role of Actionable Genes in Pursuing a True Approach of Precision Medicine in Monogenic Diabetes. *Genes (Basel)* 2022; **13** [PMID: [35052457](#) DOI: [10.3390/genes13010117](#)]
- 18 **Üsküdar Cansu D**, Bodakçi E, Korkmaz C. Dose-dependent bradycardia as a rare side effect of corticosteroids: a case report and review of the literature. *Rheumatol Int* 2018; **38**: 2337-2343 [PMID: [30276424](#) DOI: [10.1007/s00296-018-4167-1](#)]
- 19 **Tanaka M**, Vécsei L. Monitoring the Redox Status in Multiple Sclerosis. *Biomedicines* 2020; **8** [PMID: [33053739](#) DOI: [10.3390/biomedicines8100406](#)]
- 20 **Hamilton AJ**, Bingham C, McDonald TJ, Cook PR, Caswell RC, Weedon MN, Oram RA, Shields BM, Shepherd M, Inward CD, Hamilton-Shield JP, Kohlhasse J, Ellard S, Hattersley AT. The HNF4A R76W mutation causes atypical dominant Fanconi syndrome in addition to a β cell phenotype. *J Med Genet* 2014; **51**: 165-169 [PMID: [24285859](#) DOI: [10.1136/jmedgenet-2013-102066](#)]
- 21 **Anyiam O**, Wallin E, Kaplan F, Lawrence C. A Complicated Pregnancy in an Adult with HNF4A p.R63W-Associated Fanconi Syndrome. *Case Rep Med* 2019; **2019**: 2349470 [PMID: [31949432](#) DOI: [10.1155/2019/2349470](#)]
- 22 **Heming N**, Sivanandamoorthy S, Meng P, Bounab R, Annane D. Immune Effects of Corticosteroids in Sepsis. *Front Immunol* 2018; **9**: 1736 [PMID: [30105022](#) DOI: [10.3389/fimmu.2018.01736](#)]
- 23 **Yong KL**, Chng CL, Htoon HM, Lim LH, Seah LL. Safety Profile and Effects of Pulsed Methylprednisolone on Vital Signs in Thyroid Eye Disease. *Int J Endocrinol* 2015; **2015**: 457123 [PMID: [26681940](#) DOI: [10.1155/2015/457123](#)]
- 24 **Morita H**, Wu J, Zipes DP. The QT syndromes: long and short. *Lancet* 2008; **372**: 750-763 [PMID: [18761222](#) DOI: [10.1016/S0140-6736\(08\)61307-0](#)]
- 25 **Qi L**, van Dam RM, Asselbergs FW, Hu FB. Gene-gene interactions between HNF4A and KCNJ11 in predicting Type 2 diabetes in women. *Diabet Med* 2007; **24**: 1187-1191 [PMID: [17894829](#) DOI: [10.1111/j.1464-5491.2007.02255.x](#)]
- 26 **Gupta RK**, Vatamaniuk MZ, Lee CS, Flaschen RC, Fulmer JT, Matschinsky FM, Duncan SA, Kaestner KH. The MODY1 gene HNF-4 α regulates selected genes involved in insulin secretion. *J Clin Invest* 2005; **115**: 1006-1015 [PMID: [15761495](#) DOI: [10.1172/jci22365](#)]
- 27 **Harris AP**, Ismail KA, Nunez M, Martopullo I, Lencinas A, Selmin OI, Runyan RB. Trichloroethylene perturbs HNF4 α expression and activity in the developing chick heart. *Toxicol Lett* 2018; **285**: 113-120 [PMID: [29306027](#) DOI: [10.1016/j.toxlet.2017.12.027](#)]
- 28 **Hibino H**, Inanobe A, Furutani K, Murakami S, Findlay I, Kurachi Y. Inwardly rectifying potassium channels: their structure, function, and physiological roles. *Physiol Rev* 2010; **90**: 291-366 [PMID: [20086079](#) DOI: [10.1152/physrev.00021.2009](#)]
- 29 **Kane GC**, Behfar A, Dyer RB, O'Coilain DF, Liu XK, Hodgson DM, Reyes S, Miki T, Seino S, Terzic A. KCNJ11 gene knockout of the Kir6.2 KATP channel causes maladaptive remodeling and heart failure in hypertension. *Hum Mol Genet* 2006; **15**: 2285-2297 [PMID: [16782803](#) DOI: [10.1093/hmg/ddl154](#)]
- 30 **Rottensteiner J**, Kaneppele A, Stockner I, Ladurner C, Panizza G, Wiedermann CJ. Precordial T-wave inversion of "cardiac memory" pattern after high-dose methylprednisolone pulse therapy. *Intern Emerg Med* 2008; **3**: 375-378 [PMID: [18274710](#) DOI: [10.1007/s11739-008-0121-7](#)]
- 31 **Bendahhou S**, Fournier E, Gallet S, Ménard D, Larroque MM, Barhanin J. Corticosteroid-exacerbated symptoms in an Andersen's syndrome kindred. *Hum Mol Genet* 2007; **16**: 900-906 [PMID: [17324964](#) DOI: [10.1093/hmg/ddm034](#)]
- 32 **Tisdale JE**, Chung MK, Campbell KB, Hammadah M, Joglar JA, Leclerc J, Rajagopalan B; American Heart Association Clinical Pharmacology Committee of the Council on Clinical Cardiology and Council on Cardiovascular and Stroke Nursing. Drug-Induced Arrhythmias: A Scientific Statement From the American Heart Association. *Circulation* 2020; **142**: e214-e233 [PMID: [32929996](#) DOI: [10.1161/CIR.0000000000000905](#)]



Published by **Baishideng Publishing Group Inc**
7041 Koll Center Parkway, Suite 160, Pleasanton, CA 94566, USA

Telephone: +1-925-3991568

E-mail: bpgoffice@wjgnet.com

Help Desk: <https://www.f6publishing.com/helpdesk>

<https://www.wjgnet.com>

