

World Journal of *Clinical Cases*

World J Clin Cases 2022 July 26; 10(21): 7187-7619



Contents

Thrice Monthly Volume 10 Number 21 July 26, 2022

OPINION REVIEW

- 7187 Effects of glucocorticoids on leukocytes: Genomic and non-genomic mechanisms
Jia WY, Zhang JJ

MINIREVIEWS

- 7195 Apheresis: A cell-based therapeutic tool for the inflammatory bowel disease
Yasmin F, Najeeb H, Naeem U, Moeed A, Koritala T, Surani S
- 7209 *Helicobacter pylori* infection and small intestinal bacterial overgrowth—more than what meets the eye
Dharan M, Wozny D
- 7215 Anatomy of the anterolateral ligament of the knee joint
Park JG, Han SB, Rhim HC, Jeon OH, Jang KM

ORIGINAL ARTICLE

Clinical and Translational Research

- 7224 Molecular mechanisms of Biyu decoction as treatment for psoriasis: A network pharmacology and molecular docking study
Wang Z, Zhang HM, Guo YR, Li LL
- 7242 Expression of hepatocyte nuclear factor 4 alpha, wingless-related integration site, and β -catenin in clinical gastric cancer
Hu Q, Li LL, Peng Z, Yi P

Case Control Study

- 7256 Improved Pittsburgh Sleep Quality Index scores on first postoperative night achieved by propofol anesthesia in patients undergoing ambulatory gynecologic surgery
Hu CH, Chou WY
- 7265 Efficacy of Guhong injection *versus* Butylphthalide injection for mild ischemic stroke: A multicenter controlled study
Zhang WW, Xin J, Zhang GY, Zhai QJ, Zhang HM, Wu CS

Retrospective Study

- 7275 Clinical values of Barcelona Clinic Liver Cancer subgroup and up-to-7 criteria in intermediate stage hepatocellular carcinoma with transcatheter arterial chemoembolization
Lee SW, Peng YC, Lien HC, Ko CW, Tung CF, Chang CS
- 7285 Intervention effect of encouraging mental and programmed nursing of patients in interventional operating room on their compliance and bad moods
Chi RB, Cai YY, Mao HP

- 7293** Preoperative neoadjuvant chemotherapy in patients with breast cancer evaluated using strain ultrasonic elastography
Pan HY, Zhang Q, Wu WJ, Li X
- 7302** Risk factors for delayed intracranial hemorrhage secondary to ventriculoperitoneal shunt: A retrospective study
Chen JC, Duan SX, Xue ZB, Yang SY, Li Y, Lai RL, Tan DH
- 7314** Sequential treatment of severe pneumonia with respiratory failure and its influence on respiratory mechanical parameters and hemodynamics
Niu BY, Wang G, Li B, Zhen GS, Weng YB
- 7324** Effects of alendronate sodium combined with InterTan on osteoporotic femoral intertrochanteric fractures and fracture recurrence
Wang KM, Wei SP, Yin XY, Meng QJ, Kong YM
- 7333** Correlation of magnetic resonance imaging quantitative parameters and apparent diffusion coefficient value with pathological breast cancer
Wang Z, Ren GY, Yin Q, Wang Q
- 7341** Risk factors for delirium after surgery for craniocerebral injury in the neurosurgical intensive care unit
Chen RY, Zhong CH, Chen W, Lin M, Feng CF, Chen CN

Observational Study

- 7348** Effect of osteoarthritic knee flexion deformity correction by total knee arthroplasty on sagittal spinopelvic alignment in Indian population
Puthiyapura LK, Jain M, Tripathy SK, Puliappadamb HM
- 7356** Imaging characteristics of orbital peripheral nerve sheath tumors: Analysis of 34 cases
Dai M, Wang T, Wang JM, Fang LP, Zhao Y, Thakur A, Wang D

Randomized Controlled Trial

- 7365** Comparison of involved-field intensity-modulated radiotherapy combined with S-1 *vs* radiotherapy alone for elderly patients with esophageal cancer
Liu LH, Yan MH, Di YP, Fu ZG, Zhang XD, Li HQ

Randomized Clinical Trial

- 7376** Dexmedetomidine in pediatric unilateral internal inguinal ring ligation
Liu G, Zhang L, Wang HS, Lin Y, Jin HQ, Wang XD, Qiao WN, Zhang YT, Sun JQ, Liu ZN

META-ANALYSIS

- 7386** Impact of cancer on mortality rates in patients with sepsis: A meta-analysis and meta-regression of current studies
Xiang MJ, Chen GL

CASE REPORT

- 7397 Updated clinical and glycomic features of mannosyl-oligosaccharide glucosidase deficiency: Two case reports
Abuduxikuer K, Wang L, Zou L, Cao CY, Yu L, Guo HM, Liang XM, Wang JS, Chen L
- 7409 Solitary necrotic nodules of the liver with "ring"-like calcification: A case report
Bao JP, Tian H, Wang HC, Wang CC, Li B
- 7415 Corticosteroid-induced bradycardia in multiple sclerosis and maturity-onset diabetes of the young due to hepatocyte nuclear factor 4- α mutation: A case report
Sohn SY, Kim SY, Joo IS
- 7422 Essential thrombocythemia with non-ST-segment elevation myocardial infarction as the first manifestation: A case report
Wang ZM, Chen WH, Wu YM, Wang LQ, Ye FL, Yin RL
- 7429 Extranasopharyngeal angiofibroma in children: A case report
Yan YY, Lai C, Wu L, Fu Y
- 7438 Deep Sylvian fissure meningiomas: A case report
Wang A, Zhang X, Sun KK, Li C, Song ZM, Sun T, Wang F
- 7445 Acute pulmonary embolism originating from upper limb venous thrombosis following breast cancer surgery: Two case reports
Duan Y, Wang GL, Guo X, Yang LL, Tian FG
- 7451 Managing spondylitis tuberculosis in a patient with underlying diabetes and hypothyroidism: A case report
Novita BD, Muliono AC, Wijaya S, Theodora I, Tjahjono Y, Supit VD, Willianto VM
- 7459 Ovarian mucinous tumor with mural nodules of anaplastic carcinoma: Three case reports
Wang XJ, Wang CY, Xi YF, Bu P, Wang P
- 7467 Transcatheter arterial infusion chemotherapy and embolization for primary lacrimal sac squamous cell carcinoma: A case report
Sun MH, Yi WD, Shen L, Zhou L, Lu JX
- 7474 Programmed cell death-1 inhibitor combination treatment for recurrent proficient mismatch repair/microsatellite-stable type endometrial cancer: A case report
Zhai CY, Yin LX, Han WD
- 7483 Novel compound heterozygous mutation of *SLC12A3* in Gitelman syndrome co-existent with hyperthyroidism: A case report and literature review
Qin YZ, Liu YM, Wang Y, You C, Li LN, Zhou XY, Lv WM, Hong SH, Xiao LX
- 7495 Successful treatment of hyperglycemia with liraglutide in a hospitalized 27-year-old patient with schizophrenia: A case report
Zhang L, Yu WJ, Zhu H, Li HF, Qiao J

- 7502** Refractory lymphoma treated with chimeric antigen receptor T cells combined with programmed cell death-1 inhibitor: A case report
Zhang CJ, Zhang JY, Li LJ, Xu NW
- 7509** Median arcuate ligament syndrome with retroperitoneal haemorrhage: A case report
Lu XC, Pei JG, Xie GH, Li YY, Han HM
- 7517** Novel frameshift mutation in the *AHDC1* gene in a Chinese global developmental delay patient: A case report
Lin SZ, Xie HY, Qu YL, Gao W, Wang WQ, Li JY, Feng XC, Jin CQ
- 7523** Selective nerve block for the treatment of neuralgia in Kummell's disease: A case report
Zhang X, Li ZX, Yin LJ, Chen H
- 7531** Traditional Chinese medicine manipulative reduction combined with percutaneous vertebroplasty for treating type III Kummell's disease: A case report
Hao SS, Zhang RJ, Dong SL, Li HK, Liu S, Li RF, Ren HH, Zhang LY
- 7539** Differential diagnosis and treatment of foot drop caused by an extraneural ganglion cyst above the knee: A case report
Won KH, Kang EY
- 7545** Effect of hydrogen intervention on refractory wounds after radiotherapy: A case report
Zhao PX, Luo RL, Dang Z, Wang YB, Zhang XJ, Liu ZY, Wen XH, Liu MY, Zhang MZ, Adzavon YM, Ma XM
- 7553** Chronic urticaria associated with lung adenocarcinoma — a paraneoplastic manifestation: A case report and literature review
Jiménez LF, Castellón EA, Marengo JD, Mejía JM, Rojas CA, Jiménez FT, Coronell L, Osorio-Llanes E, Mendoza-Torres E
- 7565** Spinal giant cell-rich osteosarcoma-diagnostic dilemma and treatment strategy: A case report
Tseng CS, Wong CE, Huang CC, Hsu HH, Lee JS, Lee PH
- 7571** Primary clear cell sarcoma of soft tissue in the posterior cervical spine invading the medulla oblongata: A case report
Liu CC, Huang WP, Gao JB
- 7577** *Pseudomonas aeruginosa*-related effusive-constrictive pericarditis diagnosed with echocardiography: A case report
Chen JL, Mei DE, Yu CG, Zhao ZY
- 7585** Maternal peripartum bacteremia caused by intrauterine infection with *Comamonas kerstersii*: A case report
Qu H, Zhao YH, Zhu WM, Liu L, Zhu M
- 7592** Considerations of single-lung ventilation in neonatal thoracoscopic surgery with cardiac arrest caused by bilateral pneumothorax: A case report
Zhang X, Song HC, Wang KL, Ren YY

- 7599** Rare primary rectal mucosa-associated lymphoid tissue lymphoma with curative resection by endoscopic submucosal dissection: A case report and review of literature

Tao Y, Nan Q, Lei Z, Miao YL, Niu JK

- 7609** Differences in examination results of small anastomotic fistula after radical gastrectomy with afterward treatments: A case report

Lu CY, Liu YL, Liu KJ, Xu S, Yao HL, Li L, Guo ZS

LETTER TO THE EDITOR

- 7617** Baseline differences may impact on relationship between dietary tryptophan and risk of obesity and type 2 diabetes

Ren XH, Ye YW, He LP

ABOUT COVER

Editorial Board Member of *World Journal of Clinical Cases*, Rajesh Kumar Rajnish, MBBS, MS, Assistant Professor, Department of Orthopaedics, All India Institute of Medical Sciences, Bilaspur, Bilaspur 174001, Himachal Pradesh, India. duktiraj@gmail.com

AIMS AND SCOPE

The primary aim of *World Journal of Clinical Cases* (WJCC, *World J Clin Cases*) is to provide scholars and readers from various fields of clinical medicine with a platform to publish high-quality clinical research articles and communicate their research findings online.

WJCC mainly publishes articles reporting research results and findings obtained in the field of clinical medicine and covering a wide range of topics, including case control studies, retrospective cohort studies, retrospective studies, clinical trials studies, observational studies, prospective studies, randomized controlled trials, randomized clinical trials, systematic reviews, meta-analysis, and case reports.

INDEXING/ABSTRACTING

The WJCC is now abstracted and indexed in Science Citation Index Expanded (SCIE, also known as SciSearch®), Journal Citation Reports/Science Edition, Current Contents®/Clinical Medicine, PubMed, PubMed Central, Scopus, Reference Citation Analysis, China National Knowledge Infrastructure, China Science and Technology Journal Database, and Superstar Journals Database. The 2022 Edition of Journal Citation Reports® cites the 2021 impact factor (IF) for WJCC as 1.534; IF without journal self cites: 1.491; 5-year IF: 1.599; Journal Citation Indicator: 0.28; Ranking: 135 among 172 journals in medicine, general and internal; and Quartile category: Q4. The WJCC's CiteScore for 2021 is 1.2 and Scopus CiteScore rank 2021: General Medicine is 443/826.

RESPONSIBLE EDITORS FOR THIS ISSUE

Production Editor: *Ying-Yi Yuan*; Production Department Director: *Xiang Li*; Editorial Office Director: *Jin-Lei Wang*.

NAME OF JOURNAL

World Journal of Clinical Cases

ISSN

ISSN 2307-8960 (online)

LAUNCH DATE

April 16, 2013

FREQUENCY

Thrice Monthly

EDITORS-IN-CHIEF

Bao-Gan Peng, Jerzy Tadeusz Chudek, George Kontogeorgos, Maurizio Serati, Ja Hyeon Ku

EDITORIAL BOARD MEMBERS

<https://www.wjgnet.com/2307-8960/editorialboard.htm>

PUBLICATION DATE

July 26, 2022

COPYRIGHT

© 2022 Baishideng Publishing Group Inc

INSTRUCTIONS TO AUTHORS

<https://www.wjgnet.com/bpg/gerinfo/204>

GUIDELINES FOR ETHICS DOCUMENTS

<https://www.wjgnet.com/bpg/GerInfo/287>

GUIDELINES FOR NON-NATIVE SPEAKERS OF ENGLISH

<https://www.wjgnet.com/bpg/gerinfo/240>

PUBLICATION ETHICS

<https://www.wjgnet.com/bpg/GerInfo/288>

PUBLICATION MISCONDUCT

<https://www.wjgnet.com/bpg/gerinfo/208>

ARTICLE PROCESSING CHARGE

<https://www.wjgnet.com/bpg/gerinfo/242>

STEPS FOR SUBMITTING MANUSCRIPTS

<https://www.wjgnet.com/bpg/GerInfo/239>

ONLINE SUBMISSION

<https://www.f6publishing.com>

Effect of hydrogen intervention on refractory wounds after radiotherapy: A case report

Peng-Xiang Zhao, Rui-Liu Luo, Zheng Dang, You-Bin Wang, Xu-Juan Zhang, Zi-Yi Liu, Xiao-Hu Wen, Meng-Yu Liu, Ming-Zi Zhang, Yao Mawulikplimi Adzavon, Xue-Mei Ma

Specialty type: Medicine, research and experimental

Provenance and peer review:

Unsolicited article; Externally peer reviewed.

Peer-review model: Single blind

Peer-review report's scientific quality classification

Grade A (Excellent): A

Grade B (Very good): 0

Grade C (Good): C

Grade D (Fair): 0

Grade E (Poor): 0

P-Reviewer: Kim YJ, Malaysia; Sandoval C, Chile

A-Editor: Lin FY, China

Received: February 6, 2022

Peer-review started: February 6, 2022

First decision: March 23, 2022

Revised: April 1, 2022

Accepted: May 27, 2022

Article in press: May 27, 2022

Published online: July 26, 2022



Peng-Xiang Zhao, Rui-Liu Luo, Zheng Dang, Xu-Juan Zhang, Zi-Yi Liu, Xiao-Hu Wen, Meng-Yu Liu, Yao Mawulikplimi Adzavon, Xue-Mei Ma, Faculty of Environment and Life Science, Beijing International Science and Technology, Cooperation Base of Antivirus Drug, Beijing University of Technology, Beijing 100124, China

You-Bin Wang, Ming-Zi Zhang, Department of Plastic Surgery, Peking Union Medical College Hospital, Beijing 100032, China

Corresponding author: Xue-Mei Ma, PhD, Professor, Faculty of Environment and Life Science, Beijing International Science and Technology, Cooperation Base of Antivirus Drug, Beijing University of Technology, No. 100 Pingleyuan, Chaoyang District, Beijing 100124, China. xmma@bjut.edu.cn

Abstract

BACKGROUND

Patients with keloids who receive radiotherapy (RT) after surgery can develop refractory wounds that cannot be healed by the patient's own repair system. Such chronic wounds are uneven and complex due to persistent abscess and ulceration. Without external intervention, they can easily result in local tissue necrosis or, in severe cases, large area tissue resection, amputation, and even death.

CASE SUMMARY

This article describes the use of hydrogen to treat a 42-year-old female patient with a chronic wound on her left shoulder. The patient had a skin graft that involved implanting a dilator under the skin of her left shoulder, and then transferring excess skin from her shoulder onto scar tissue on her chest. The skin grafting was followed by two rounds of RT, after which the shoulder wound had difficulty healing. For six months, the patient was treated with 2 h of hydrogen inhalation (HI) therapy per day, in addition to application of sterile gauze on the wound and periodic debridement. We also performed one deep, large, sharp debridement to enlarge the wound area. The wound healed completely within 6 mo of beginning the HI treatment.

CONCLUSION

After HI therapy, the patient showed superior progress in reepithelialization and wound repair, with eventual wound closure in 6 mo, in comparison with the previous failures of hyperbaric oxygen and recombinant bovine basic fibroblast

growth factor therapies. Our work showed that HI therapy could be a new strategy for wound healing that is cleaner, more convenient, and less expensive than other therapies, as well as easily accessible for further application in clinical wound care.

Key Words: Hydrogen; Inhalation therapy; Wound healing; Reepithelialization; Refractory wounds; Case report

©The Author(s) 2022. Published by Baishideng Publishing Group Inc. All rights reserved.

Core Tip: A keloid is a benign protuberance of scar tissue formed after a skin wound. Radiotherapy (RT) immediately after surgical resection can effectively reduce the recurrence rate of keloids, but can also disrupt the ordered sequence of cell interactions, leading to repeated inflammatory responses and inadequate healing, thus resulting in a chronic wound. We aimed to test the efficacy of hydrogen inhalation (HI) therapy in the treatment of a patient who developed a chronic wound after skin grafting and RT. The novel adjuvant therapy of HI resulted in effective reepithelialization and successful healing.

Citation: Zhao PX, Luo RL, Dang Z, Wang YB, Zhang XJ, Liu ZY, Wen XH, Liu MY, Zhang MZ, Adzavon YM, Ma XM. Effect of hydrogen intervention on refractory wounds after radiotherapy: A case report. *World J Clin Cases* 2022; 10(21): 7545-7552

URL: <https://www.wjgnet.com/2307-8960/full/v10/i21/7545.htm>

DOI: <https://dx.doi.org/10.12998/wjcc.v10.i21.7545>

INTRODUCTION

A keloid is a benign raised scar that sometimes results from postoperative radiotherapy (RT) immediately after surgical resection. Repeated inflammatory responses can cause delayed and inadequate wound healing. Current strategies for treating radiation-delayed wound healing typically include standard wound care and measures to optimize blood and oxygen supply[1]. Chronic wound healing is a complex process with a series of interrupted cascade events and the blocking of cellular interactions.

Cutaneous wounds always proceed through three independent but overlapping stages[2-5]. The inflammation stage starts immediately and is associated with the formation of blood clots and the recruitment of inflammatory cells. The second stage involves regeneration, characterized by reepithelialization of the wound, the creation of new epidermal cells, and the formation of granulation tissue. The last stage is the remodeling stage, in which the epidermis, dermis, and extracellular matrix (ECM) are rearranged. Defects in any of these stages will cause chronic wounds. Chronic wounds fail to heal despite the use of current therapies because they become stalled in the inflammation stage of wound healing[6]. In contrast, acute wounds progress through all three stages in a timely manner as they heal.

Human wounds add a substantial burden to worldwide clinical, social, and economic resources. A 2018 retrospective analysis of United States Medicare beneficiaries identified that about 8.2 million people had wounds with or without infections. Medicare cost estimates for acute and chronic wound treatment were \$28.1–96.8 billion for the year 2014 alone[7]. Although various therapies have been developed, more efficient, cleaner, and more advanced treatments are still needed in dealing with both acute and chronic wounds.

Since 2007[8], increased attention has been paid to the physiological functions and signal transduction pathways of hydrogen as a gaseous signaling molecule. Hydrogen is not only environmentally friendly, with no other metabolites *in vivo* except water, but also easy to obtain *via* simple electrolysis of water[8]. Its antioxidant[9], anti-inflammatory[10], and anti-apoptotic[11] effects have been discovered in studies using multiple animal models and, thereafter, in some clinical trials. It has been reported that hydrogen has beneficial effects on skin diseases such as pressure ulcers, burns, and psoriasis[12]. Hydrogen can reduce oxidative stress, alleviate inflammation in local wounds, and accelerate wound healing.

Our clinical study showed that hydrogen inhalation (HI) therapy improved the adhesion between skin and muscle tissues and promoted the reepithelialization process and wound healing speed. Therefore, we believe that HI therapy may be a clean, inexpensive, convenient, and readily available new wound-healing strategy that can be further applied to clinical wound care.

CASE PRESENTATION

Chief complaints

A 42-year-old woman with a chronic wound on the left shoulder was advised to try HI therapy (Figure 1). Because of her scar diathesis, we transplanted excess skin from the back of her left shoulder to scar tissue on her chest by implanting a dilator under the skin of her left shoulder on April 3, 2019. After skin grafting on April 25, 2019, two rounds of RT were performed. The first round was given 1 d after the first surgery, and the second occurred 1 wk after the first round; the dose was 900 centigrade. However, the defective shoulder skin became difficult to heal.

History of present illness

After 4 mo of other treatments in which no progress in healing was observed, the patient volunteered to take HI therapy for 6 mo. During the first month, we also performed mild sharp debridement weekly. On October 14, 2019, we performed a deep, large, sharp debridement, enlarging the wound area. Within 6 mo of the start of HI therapy, the wound tissue was completely healed.

History of past illness

No other positive history of past illness was known.

Personal and family history

The patient declared no smoking or alcohol history, nor any other noteworthy family medical history.

Physical examination

A round chronic wound with a diameter of about 2 cm was found in the patient's left shoulder.

Laboratory examinations

Blood tests showed no obvious abnormality.

Imaging examinations

No imaging examinations were performed as the patient displayed good conditions except the wound on the patient's left shoulder.

FINAL DIAGNOSIS

The final diagnosis of the case was chronic wound.

TREATMENT

In the first surgery, the wound was sutured after implantation of the dilator under skin at the back of the patient's shoulder. In the second surgery, we removed the dilator and transplanted the expanded shoulder skin to the chest.

Two rounds of RT followed surgery. The first round was given 1 d after the first surgery, and the second occurred 1 wk after the first round. The dose was 900 centigrade.

No progress in healing was observed during the first 4 mo of treatments, which included topical spray of recombinant bovine basic fibroblast growth factor (rbFGF) and hyperbaric oxygen (HBO) therapy, together with topical application of sterile gauze. Then, the patient volunteered to take HI therapy, along with topical application of sterile gauze for 6 mo. During the first month of HI therapy, we also performed mild sharp debridement weekly. On October 14, 2019, we performed a deep, large, sharp debridement, enlarging the wound area (Figure 1).

HBO therapy was provided with 82% oxygen at a pressure of 1.5 atm. Pressure was increased from 1.0 to 1.5 atm over the course of 15 min, after which it was sustained at the latter level for exactly 1 h. The decrease of oxygen pressure took another 15 min, after which the patient exited the chamber.

rbFGF therapy involved daily topical spray of rbFGF at 150 AU/cm² three times per day.

HI therapy involved inhalation of a mix of hydrogen (66%) and oxygen (33%) gas at a flow rate of 3 L/min using KLE-H7 hydrogen generator (Kelieng Biomedical Co. Ltd., Shenzhen, China) for 2 h/d.

Manifestations of chronic wound healing process after HI therapy

During the first 40 d of HI treatment before sharp debridement on October 14, 2019, the patient's wound showed improvements, though we saw no significant wound closure resulting from the weekly mild sharp debridement. Due to the early subcutaneous implantation of the dilator, the skin and muscle layers at the wound were severely separated. One week after HI treatment, the wound bed became

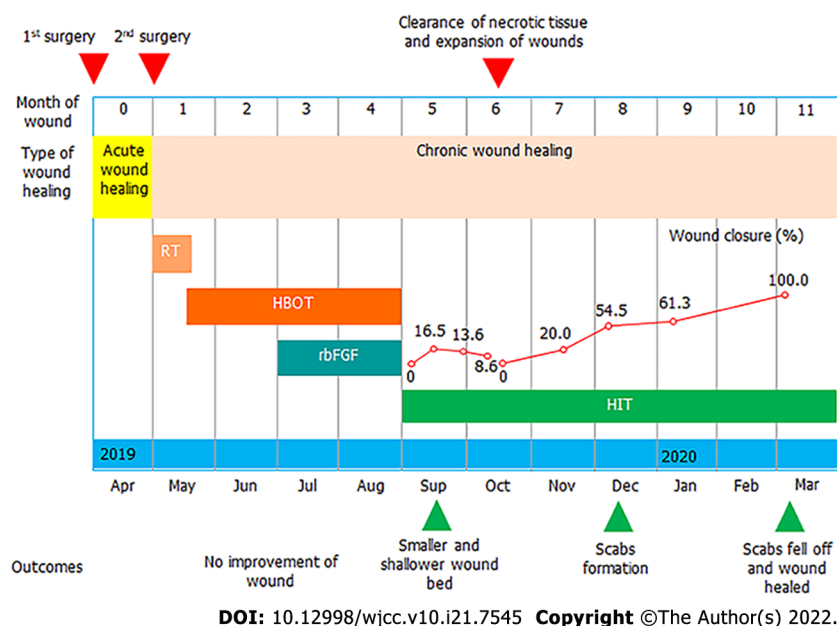


Figure 1 Clinical course, treatments, and outcomes of the case.

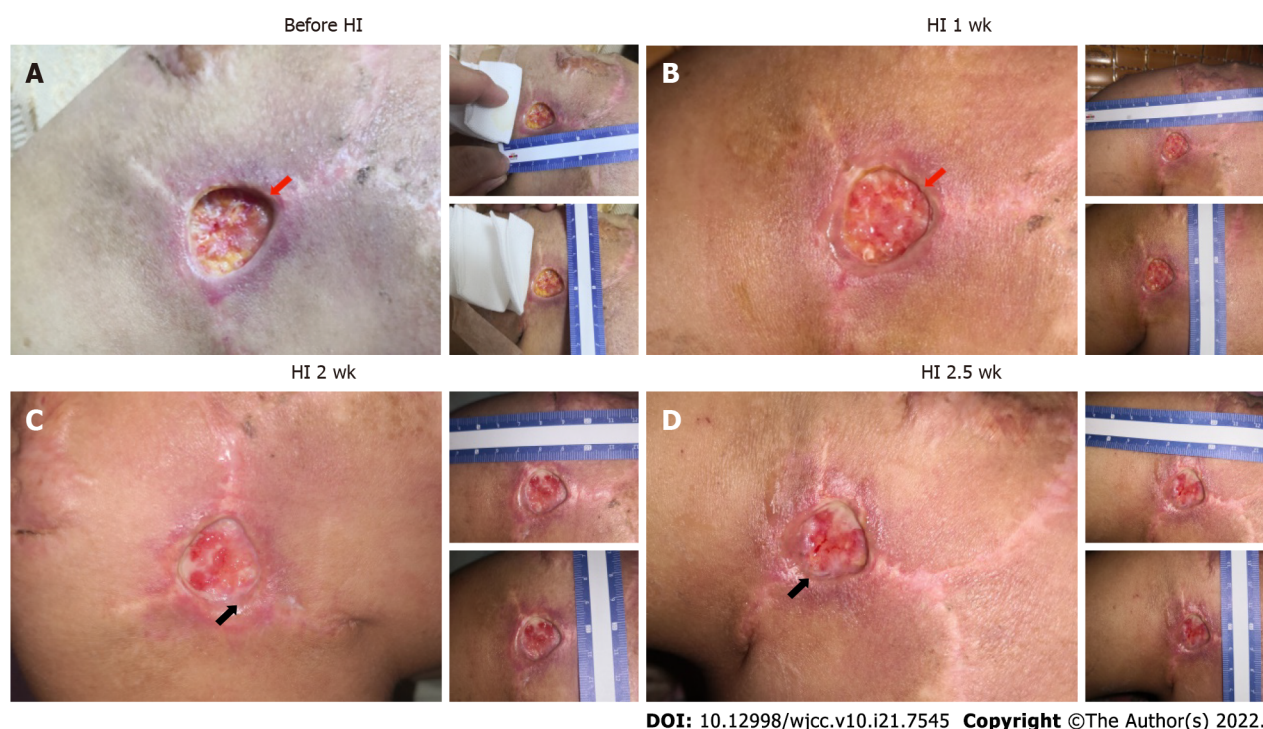
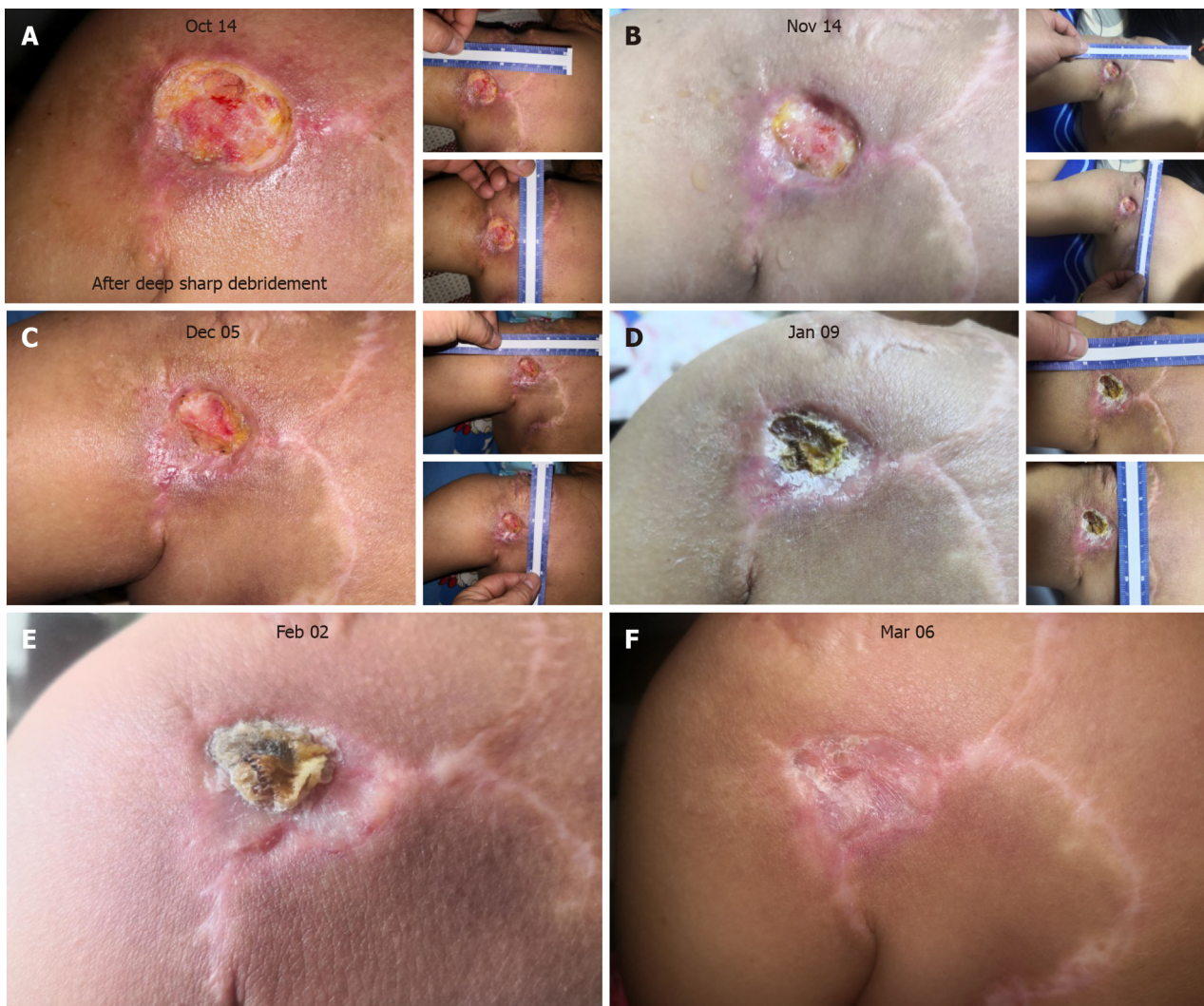

Figure 2 Outcomes of the patient after hydrogen inhalation therapy in the first 3 wk. A: Deep wound (red arrow) before hydrogen inhalation therapy, with the skin separated from the subcutaneous tissue; B: The wound grew shallower (red arrow), and the skin adhered better to the subcutaneous tissue; C: Wound edge migration was initiated (black arrow), and more blood vessels were visible in the wound bed; D: More migration around the wound edge (black arrow).

shallower, and adhesion between the skin and wound bed was tighter (Figure 2A and B). From week two onward, fresh granulation tissue was seen around the wound edge, which could have reflected the start of reepithelialization. In addition, more blood vessels were observed at week two and after two and a half weeks, which was another sign of improved healing (Figure 2C and D).

HI therapy aided chronic wound closure

After the final sharp debridement on October 14, 2019, although the wound area was enlarged due to the removal of slough tissue (Figure 3A), wound closure changes became visible. Wound closure reached 20% in the following month and 54% in the subsequent month compared to the area on October



DOI: 10.12998/wjcc.v10.i21.7545 Copyright ©The Author(s) 2022.

Figure 3 Healing process of the patient's chronic wound in the 5 mo following hyperbaric oxygen therapy. A: On the first day after deep, sharp debridement (October 14, 2019), the wound was enlarged to 2.5 cm × 2.3 cm; B: One month later (November 14, 2019), rapid reepithelialization had occurred, and wound edge migration was observed; C: The wound closed further (December 5, 2019), and a small amount of exudate was secreted around the wound edge; D: A scab formed on top of the wound bed (January 9, 2020); E: Tissue beneath the wound was further remodeled and repaired, with a scab covering the wound bed (February 2, 2020); F: The scab fell off and the wound was healed.

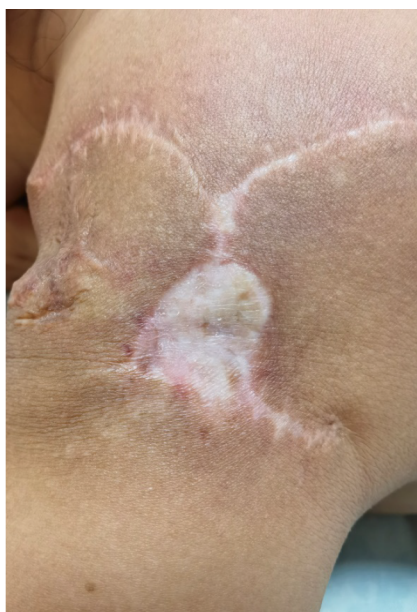14, 2019 (Figure 3B and C); no infection was observed. From January of 2020 onward, a scab began to form, covering the wound bed (Figure 3D). On February 2, the skin around the scab was better remodeled, with thickening of the epidermis (Figure 3E). The scab fell off on March 6, and the wound closure process was finished (Figure 3F), although further remodeling was still ongoing.

OUTCOME AND FOLLOW-UP

The operation went smoothly, and the patient recovered and was discharged. Examinations immediately after surgery and 6 mo later showed that the surgical incision healed well without obvious scarring (Figure 4). The patient was satisfied with the effectiveness of treatment.

DISCUSSION

Keloids are benign raised scars resulting from excessive tissue proliferation and excess collagen deposit during wound healing[13]. Surgical excision followed by immediate postoperative RT is one of the most effective treatments in reducing the recurrence rate of keloids[14,15]. However, RT can also disrupt the ordered sequence of cellular interactions, resulting in repetitive inflammatory responses and delayed and inadequate wound healing[16]. Current strategies for treating irradiated delayed wounds always



DOI: 10.12998/wjcc.v10.i21.7545 Copyright ©The Author(s) 2022.

Figure 4 The patient's facial appearance at the 1-yr follow-up after surgery.

include standard wound care, vacuum-assisted devices, supplementation for nutritional deficiencies, and measures to optimize blood and oxygen supply. HBO, growth factors, special dressings, and even injections of cells are used in clinical treatment[1].

It is hard to determine whether HBO or rbFGF combination treatments have a significant influence on the healing of irradiated chronic wounds because of the inability to compare with controls. These treatments also have some limitations. For example, HBO therapy is more effective for hypoxic wounds so it has the disadvantage of limited treatment scope[16,17]. Patients with complications such as untreated pneumothorax, multiple fractures, retinal detachment, internal bleeding, severe cold and rhinitis, high fever, high blood pressure, and early pregnancy and menstrual period are not suitable for the HBO therapy[18]. Due to their side effects, growth factors have seen little use in clinical practice until now. This involves the safety of recombinant products. It is necessary to establish a variety of quality control standards and toxicity inspection[19].

In our case study, at least within the first 4 mo, we saw very little progress in wound healing. Healing of chronic wounds is a complex process, with a disrupted cascade of events and blocked cellular interaction[20]. Our findings showed that HI treatment promoted better adhesion between skin and muscle tissues that had been separated by dilator implantation and flap surgery (Figure 2), and it improved the process of reepithelialization (growth of wound edge; Figure 2) and wound closure speed (Figure 3).

Most chronic wounds share common inflammatory disorders[21]. The skin is composed of cells (mainly fibroblasts, endothelial cells, and keratinocytes) and ECM[22]. The migration of fibroblasts and related cells is responsible for wound bed closure, and the deposition of ECM has many key functions, including providing structure, organization, and orientation to cells and tissues, as well as strengthening and binding tissues. The successful outcome for our patient after HI treatment could have been related to the suppression of inflammation, as well as to better ECM deposit and cell migration. Further experimental evidence is still needed, however.

Hydrogen plays an important role in many disease models due to its antioxidant, anti-apoptotic, and anti-inflammatory properties. Previous studies have proven that hydrogen therapy promotes the process of burn tissue recovery[9,23]. Molecular hydrogen has been used in a variety of novel therapeutic applications[9,10,24,25]. There are many ways to give hydrogen, such as intraperitoneal and intravenous injection of hydrogen-rich water, drinking hydrogen-rich water, and inhaling a mixture of hydrogen with the help of a ventilator[24,26,27].

Some studies have shown that one-time hydrogen preconditioning did not reduce the ischemia-reperfusion injury of a rat skin flap, but this may be related to the short treatment time or the short residence time of hydrogen[26]. Therefore, the selection of treatment time and administration mode of hydrogen also is very important. In previous studies, the hydrogen absorption concentration was below 5% in low concentration treatments and in high concentration treatments[28]. Administration times also differed, which may affect the treatment outcome. Further exploration is needed to find the most appropriate hydrogen delivery mode, dosage, and treatment time to achieve the best outcome.

CONCLUSION

Patients with keloids who undergo radiation after skin graft surgery can develop refractory, or chronic, wounds. Our case study found that HI was effective in healing a chronic shoulder skin wound, with better treatment results than HBO and growth factor therapy. The HI therapy accelerated the reepithelialization process and probably also the accumulation of ECM deposit. Therefore, HI therapy shows promise as a less expensive, cleaner, and more available option for future clinical wound care.

FOOTNOTES

Author contributions: Zhao PX and Luo RL designed the study; Luo RL and Dang Z collected, analyzed, and interpreted the data, wrote the manuscript, and reviewed the literature; Dang Z, Wang YB, and Zhang XJ performed the surgery, and collected, analyzed, and interpreted the data; Liu ZY and Wen XH made critical revisions to the manuscript, and approved the final version; Liu MY and Adzavon YM collected, analyzed, and interpreted the data; Zhang MZ and Ma XM made critical revisions to the manuscript for important intellectual content, approved the final version, and agreed to be accountable for all aspects of the work in ensuring that questions related to the accuracy or integrity of any part of the work are appropriately investigated and resolved; and all authors agreed to be accountable for the content of the work.

Supported by National Natural Science Foundation of China, No. 81602408; and Military Logistics Key Open Research Projects, China, No. BHJ17L018.

Informed consent statement: Informed written consent was obtained from the patient for publication of this report and any accompanying images.

Conflict-of-interest statement: The authors declare that there is no conflict of interest related to this manuscript.

CARE Checklist (2016) statement: The authors have read the CARE Checklist (2016), and the manuscript was prepared and revised according to the CARE Checklist (2016).

Open-Access: This article is an open-access article that was selected by an in-house editor and fully peer-reviewed by external reviewers. It is distributed in accordance with the Creative Commons Attribution NonCommercial (CC BY-NC 4.0) license, which permits others to distribute, remix, adapt, build upon this work non-commercially, and license their derivative works on different terms, provided the original work is properly cited and the use is non-commercial. See: <https://creativecommons.org/licenses/by-nc/4.0/>

Country/Territory of origin: China

ORCID number: Peng-Xiang Zhao 0000-0003-2432-6120; Rui-Liu Luo 0000-0003-3216-6550; Zheng Dang 0000-0001-9922-6840; You-Bin Wang 0000-0001-7822-6251; Xu-Juan Zhang 0000-0001-5061-0913; Zi-Yi Liu 0000-0002-5660-9187; Xiao-Hu Wen 0000-0002-5749-430X; Meng-Yu Liu 0000-0002-4024-0629; Ming-Zi Zhang 0000-0003-0250-1872; Xue-Mei Ma 0000-0002-9307-066X.

S-Editor: Ma YJ

L-Editor: Wang TQ

P-Editor: Ma YJ

REFERENCES

- 1 **Haubner F**, Ohmann E, Pohl F, Strutz J, Gassner HG. Wound healing after radiation therapy: review of the literature. *Radiat Oncol* 2012; **7**: 162 [PMID: 23006548 DOI: 10.1186/1748-717X-7-162]
- 2 **Arwert EN**, Hoste E, Watt FM. Epithelial stem cells, wound healing and cancer. *Nat Rev Cancer* 2012; **12**: 170-180 [PMID: 22362215 DOI: 10.1038/nrc3217]
- 3 **Gurtner GC**, Werner S, Barrandon Y, Longaker MT. Wound repair and regeneration. *Nature* 2008; **453**: 314-321 [PMID: 18480812 DOI: 10.1038/nature07039]
- 4 **Coulombe PA**. Wound epithelialization: accelerating the pace of discovery. *J Invest Dermatol* 2003; **121**: 219-230 [PMID: 12880412 DOI: 10.1046/j.1523-1747.2003.12387.x]
- 5 **Plikus MV**, Gay DL, Treffeisen E, Wang A, Supannachart RJ, Cotsarelis G. Epithelial stem cells and implications for wound repair. *Semin Cell Dev Biol* 2012; **23**: 946-953 [PMID: 23085626 DOI: 10.1016/j.semcdb.2012.10.001]
- 6 **Krzyszczak P**, Schloss R, Palmer A, Berthiaume F. The Role of Macrophages in Acute and Chronic Wound Healing and Interventions to Promote Pro-wound Healing Phenotypes. *Front Physiol* 2018; **9**: 419 [PMID: 29765329 DOI: 10.3389/fphys.2018.00419]
- 7 **Nussbaum SR**, Carter MJ, Fife CE, DaVanzo J, Haught R, Nusgart M, Cartwright D. An Economic Evaluation of the Impact, Cost, and Medicare Policy Implications of Chronic Nonhealing Wounds. *Value Health* 2018; **21**: 27-32 [PMID: 29304937 DOI: 10.1016/j.jval.2017.07.007]

- 8 **Shirahata S**, Li Y, Hamasaki T, Gadek Z, Teruya K, Kabayama S, Otsubo K, Morisawa S, Ishii Y, Katakura Y. Redox regulation by reduced waters as active hydrogen donors and intracellular ROS scavengers for prevention of type 2 diabetes. In: Smith R (eds) *Cell Technology for Cell Products*. Springer, Dordrecht, 2007: 99-101 [DOI: [10.1007/978-1-4020-5476-1_15](https://doi.org/10.1007/978-1-4020-5476-1_15)]
- 9 **Ohsawa I**, Ishikawa M, Takahashi K, Watanabe M, Nishimaki K, Yamagata K, Katsura K, Katayama Y, Asoh S, Ohta S. Hydrogen acts as a therapeutic antioxidant by selectively reducing cytotoxic oxygen radicals. *Nat Med* 2007; **13**: 688-694 [PMID: [17486089](https://pubmed.ncbi.nlm.nih.gov/17486089/) DOI: [10.1038/nm1577](https://doi.org/10.1038/nm1577)]
- 10 **Zhao L**, Wang YB, Qin SR, Ma XM, Sun XJ, Wang ML, Zhong RG. Protective effect of hydrogen-rich saline on ischemia/reperfusion injury in rat skin flap. *J Zhejiang Univ Sci B* 2013; **14**: 382-391 [PMID: [23645175](https://pubmed.ncbi.nlm.nih.gov/23645175/) DOI: [10.1631/jzus.B1200317](https://doi.org/10.1631/jzus.B1200317)]
- 11 **Liu YQ**, Liu YF, Ma XM, Xiao YD, Wang YB, Zhang MZ, Cheng AX, Wang TT, Li JL, Zhao PX, Xie F, Zhang X. Hydrogen-rich saline attenuates skin ischemia/reperfusion induced apoptosis via regulating Bax/Bcl-2 ratio and ASK-1/JNK pathway. *J Plast Reconstr Aesthet Surg* 2015; **68**: e147-e156 [PMID: [26003800](https://pubmed.ncbi.nlm.nih.gov/26003800/) DOI: [10.1016/j.bjps.2015.03.001](https://doi.org/10.1016/j.bjps.2015.03.001)]
- 12 **Ichihara M**, Sobue S, Ito M, Hirayama M, Ohno K. Beneficial biological effects and the underlying mechanisms of molecular hydrogen - comprehensive review of 321 original articles. *Med Gas Res* 2015; **5**: 12 [PMID: [26483953](https://pubmed.ncbi.nlm.nih.gov/26483953/) DOI: [10.1186/s13618-015-0035-1](https://doi.org/10.1186/s13618-015-0035-1)]
- 13 **Slemp AE**, Kirschner RE. Keloids and scars: a review of keloids and scars, their pathogenesis, risk factors, and management. *Curr Opin Pediatr* 2006; **18**: 396-402 [PMID: [16914994](https://pubmed.ncbi.nlm.nih.gov/16914994/) DOI: [10.1097/01.mop.0000236389.41462.ef](https://doi.org/10.1097/01.mop.0000236389.41462.ef)]
- 14 **Hou C**, Peng Y, Qin C, Fan F, Liu J, Long J. Hydrogen-rich water improves cognitive impairment gender-dependently in APP/PS1 mice without affecting A β clearance. *Free Radic Res* 2018; **52**: 1311-1322 [PMID: [29683360](https://pubmed.ncbi.nlm.nih.gov/29683360/) DOI: [10.1080/10715762.2018.1460749](https://doi.org/10.1080/10715762.2018.1460749)]
- 15 **Song G**, Tian H, Qin S, Sun X, Yao S, Zong C, Luo Y, Liu J, Yu Y, Sang H, Wang X. Hydrogen decreases atherosusceptibility in apolipoprotein B-containing lipoproteins and aorta of apolipoprotein E knockout mice. *Atherosclerosis* 2012; **221**: 55-65 [PMID: [22209213](https://pubmed.ncbi.nlm.nih.gov/22209213/) DOI: [10.1016/j.atherosclerosis.2011.11.043](https://doi.org/10.1016/j.atherosclerosis.2011.11.043)]
- 16 **Ogawa R**, Akaishi S, Kuribayashi S, Miyashita T. Keloids and Hypertrophic Scars Can Now Be Cured Completely: Recent Progress in Our Understanding of the Pathogenesis of Keloids and Hypertrophic Scars and the Most Promising Current Therapeutic Strategy. *J Nippon Med Sch* 2016; **83**: 46-53 [PMID: [27180789](https://pubmed.ncbi.nlm.nih.gov/27180789/) DOI: [10.1272/jnms.83.46](https://doi.org/10.1272/jnms.83.46)]
- 17 **Kim K**, Son D, Kim J. Radiation Therapy Following Total Keloidectomy: A Retrospective Study over 11 Years. *Arch Plast Surg* 2015; **42**: 588-595 [PMID: [26430630](https://pubmed.ncbi.nlm.nih.gov/26430630/) DOI: [10.5999/aps.2015.42.5.588](https://doi.org/10.5999/aps.2015.42.5.588)]
- 18 **Guest JF**, Ayoub N, McIlwraith T, Uchegbu I, Gerrish A, Weidlich D, Vowden K, Vowden P. Health economic burden that different wound types impose on the UK's National Health Service. *Int Wound J* 2017; **14**: 322-330 [PMID: [27229943](https://pubmed.ncbi.nlm.nih.gov/27229943/) DOI: [10.1111/iwj.12603](https://doi.org/10.1111/iwj.12603)]
- 19 **Morris RJ**, Liu Y, Marles L, Yang Z, Trempus C, Li S, Lin JS, Sawicki JA, Cotsarelis G. Capturing and profiling adult hair follicle stem cells. *Nat Biotechnol* 2004; **22**: 411-417 [PMID: [15024388](https://pubmed.ncbi.nlm.nih.gov/15024388/) DOI: [10.1038/nbt950](https://doi.org/10.1038/nbt950)]
- 20 **Jee JP**, Pangeni R, Jha SK, Byun Y, Park JW. Preparation and in vivo evaluation of a topical hydrogel system incorporating highly skin-permeable growth factors, quercetin, and oxygen carriers for enhanced diabetic wound-healing therapy. *Int J Nanomedicine* 2019; **14**: 5449-5475 [PMID: [31409998](https://pubmed.ncbi.nlm.nih.gov/31409998/) DOI: [10.2147/IJN.S213883](https://doi.org/10.2147/IJN.S213883)]
- 21 **Kaur P**, Gondil VS, Chhibber S. A novel wound dressing consisting of PVA-SA hybrid hydrogel membrane for topical delivery of bacteriophages and antibiotics. *Int J Pharm* 2019; **572**: 118779 [PMID: [31740093](https://pubmed.ncbi.nlm.nih.gov/31740093/) DOI: [10.1016/j.ijpharm.2019.118779](https://doi.org/10.1016/j.ijpharm.2019.118779)]
- 22 **Han G**, Ceilley R. Chronic Wound Healing: A Review of Current Management and Treatments. *Adv Ther* 2017; **34**: 599-610 [PMID: [28108895](https://pubmed.ncbi.nlm.nih.gov/28108895/) DOI: [10.1007/s12325-017-0478-y](https://doi.org/10.1007/s12325-017-0478-y)]
- 23 **Guo SX**, Jin YY, Fang Q, You CG, Wang XG, Hu XL, Han CM. Beneficial effects of hydrogen-rich saline on early burn-wound progression in rats. *PLoS One* 2015; **10**: e0124897 [PMID: [25874619](https://pubmed.ncbi.nlm.nih.gov/25874619/) DOI: [10.1371/journal.pone.0124897](https://doi.org/10.1371/journal.pone.0124897)]
- 24 **Fang Y**, Fu XJ, Gu C, Xu P, Wang Y, Yu WR, Sun Q, Sun XJ, Yao M. Hydrogen-rich saline protects against acute lung injury induced by extensive burn in rat model. *J Burn Care Res* 2011; **32**: e82-e91 [PMID: [21436720](https://pubmed.ncbi.nlm.nih.gov/21436720/) DOI: [10.1097/BCR.0b013e318217f84f](https://doi.org/10.1097/BCR.0b013e318217f84f)]
- 25 **Liu C**, Kurokawa R, Fujino M, Hirano S, Sato B, Li XK. Estimation of the hydrogen concentration in rat tissue using an airtight tube following the administration of hydrogen via various routes. *Sci Rep* 2014; **4**: 5485 [PMID: [24975958](https://pubmed.ncbi.nlm.nih.gov/24975958/) DOI: [10.1038/srep05485](https://doi.org/10.1038/srep05485)]
- 26 **Hao Y**, Dong X, Liu H, Wang Y. Preconditioning with one-time hydrogen gas does not attenuate skin flap ischemia-reperfusion injury in rat models. *J Plast Reconstr Aesthet Surg* 2019; **72**: 1661-1668 [PMID: [31350216](https://pubmed.ncbi.nlm.nih.gov/31350216/) DOI: [10.1016/j.bjps.2019.06.006](https://doi.org/10.1016/j.bjps.2019.06.006)]
- 27 **Tian R**, Hou Z, Hao S, Wu W, Mao X, Tao X, Lu T, Liu B. Hydrogen-rich water attenuates brain damage and inflammation after traumatic brain injury in rats. *Brain Res* 2016; **1637**: 1-13 [PMID: [26826009](https://pubmed.ncbi.nlm.nih.gov/26826009/) DOI: [10.1016/j.brainres.2016.01.029](https://doi.org/10.1016/j.brainres.2016.01.029)]
- 28 **Chen O**, Cao Z, Li H, Ye Z, Zhang R, Zhang N, Huang J, Zhang T, Wang L, Han L, Liu W, Sun X. High-concentration hydrogen protects mouse heart against ischemia/reperfusion injury through activation of the PI3K/Akt1 pathway. *Sci Rep* 2017; **7**: 14871 [PMID: [29093541](https://pubmed.ncbi.nlm.nih.gov/29093541/) DOI: [10.1038/s41598-017-14072-x](https://doi.org/10.1038/s41598-017-14072-x)]



Published by **Baishideng Publishing Group Inc**
7041 Koll Center Parkway, Suite 160, Pleasanton, CA 94566, USA

Telephone: +1-925-3991568

E-mail: bpgoffice@wjgnet.com

Help Desk: <https://www.f6publishing.com/helpdesk>

<https://www.wjgnet.com>

