

# World Journal of *Clinical Cases*

*World J Clin Cases* 2022 July 26; 10(21): 7187-7619



## Contents

Thrice Monthly Volume 10 Number 21 July 26, 2022

## OPINION REVIEW

- 7187 Effects of glucocorticoids on leukocytes: Genomic and non-genomic mechanisms  
*Jia WY, Zhang JJ*

## MINIREVIEWS

- 7195 Apheresis: A cell-based therapeutic tool for the inflammatory bowel disease  
*Yasmin F, Najeeb H, Naeem U, Moeed A, Koritala T, Surani S*
- 7209 *Helicobacter pylori* infection and small intestinal bacterial overgrowth—more than what meets the eye  
*Dharan M, Wozny D*
- 7215 Anatomy of the anterolateral ligament of the knee joint  
*Park JG, Han SB, Rhim HC, Jeon OH, Jang KM*

## ORIGINAL ARTICLE

## Clinical and Translational Research

- 7224 Molecular mechanisms of Biyu decoction as treatment for psoriasis: A network pharmacology and molecular docking study  
*Wang Z, Zhang HM, Guo YR, Li LL*
- 7242 Expression of hepatocyte nuclear factor 4 alpha, wingless-related integration site, and  $\beta$ -catenin in clinical gastric cancer  
*Hu Q, Li LL, Peng Z, Yi P*

## Case Control Study

- 7256 Improved Pittsburgh Sleep Quality Index scores on first postoperative night achieved by propofol anesthesia in patients undergoing ambulatory gynecologic surgery  
*Hu CH, Chou WY*
- 7265 Efficacy of Guhong injection *versus* Butylphthalide injection for mild ischemic stroke: A multicenter controlled study  
*Zhang WW, Xin J, Zhang GY, Zhai QJ, Zhang HM, Wu CS*

## Retrospective Study

- 7275 Clinical values of Barcelona Clinic Liver Cancer subgroup and up-to-7 criteria in intermediate stage hepatocellular carcinoma with transcatheter arterial chemoembolization  
*Lee SW, Peng YC, Lien HC, Ko CW, Tung CF, Chang CS*
- 7285 Intervention effect of encouraging mental and programmed nursing of patients in interventional operating room on their compliance and bad moods  
*Chi RB, Cai YY, Mao HP*

- 7293** Preoperative neoadjuvant chemotherapy in patients with breast cancer evaluated using strain ultrasonic elastography  
*Pan HY, Zhang Q, Wu WJ, Li X*
- 7302** Risk factors for delayed intracranial hemorrhage secondary to ventriculoperitoneal shunt: A retrospective study  
*Chen JC, Duan SX, Xue ZB, Yang SY, Li Y, Lai RL, Tan DH*
- 7314** Sequential treatment of severe pneumonia with respiratory failure and its influence on respiratory mechanical parameters and hemodynamics  
*Niu BY, Wang G, Li B, Zhen GS, Weng YB*
- 7324** Effects of alendronate sodium combined with InterTan on osteoporotic femoral intertrochanteric fractures and fracture recurrence  
*Wang KM, Wei SP, Yin XY, Meng QJ, Kong YM*
- 7333** Correlation of magnetic resonance imaging quantitative parameters and apparent diffusion coefficient value with pathological breast cancer  
*Wang Z, Ren GY, Yin Q, Wang Q*
- 7341** Risk factors for delirium after surgery for craniocerebral injury in the neurosurgical intensive care unit  
*Chen RY, Zhong CH, Chen W, Lin M, Feng CF, Chen CN*

**Observational Study**

- 7348** Effect of osteoarthritic knee flexion deformity correction by total knee arthroplasty on sagittal spinopelvic alignment in Indian population  
*Puthiyapura LK, Jain M, Tripathy SK, Puliappadamb HM*
- 7356** Imaging characteristics of orbital peripheral nerve sheath tumors: Analysis of 34 cases  
*Dai M, Wang T, Wang JM, Fang LP, Zhao Y, Thakur A, Wang D*

**Randomized Controlled Trial**

- 7365** Comparison of involved-field intensity-modulated radiotherapy combined with S-1 *vs* radiotherapy alone for elderly patients with esophageal cancer  
*Liu LH, Yan MH, Di YP, Fu ZG, Zhang XD, Li HQ*

**Randomized Clinical Trial**

- 7376** Dexmedetomidine in pediatric unilateral internal inguinal ring ligation  
*Liu G, Zhang L, Wang HS, Lin Y, Jin HQ, Wang XD, Qiao WN, Zhang YT, Sun JQ, Liu ZN*

**META-ANALYSIS**

- 7386** Impact of cancer on mortality rates in patients with sepsis: A meta-analysis and meta-regression of current studies  
*Xiang MJ, Chen GL*

## CASE REPORT

- 7397** Updated clinical and glycomic features of mannosyl-oligosaccharide glucosidase deficiency: Two case reports  
*Abuduxikuer K, Wang L, Zou L, Cao CY, Yu L, Guo HM, Liang XM, Wang JS, Chen L*
- 7409** Solitary necrotic nodules of the liver with "ring"-like calcification: A case report  
*Bao JP, Tian H, Wang HC, Wang CC, Li B*
- 7415** Corticosteroid-induced bradycardia in multiple sclerosis and maturity-onset diabetes of the young due to hepatocyte nuclear factor 4-alpha mutation: A case report  
*Sohn SY, Kim SY, Joo IS*
- 7422** Essential thrombocythemia with non-ST-segment elevation myocardial infarction as the first manifestation: A case report  
*Wang ZM, Chen WH, Wu YM, Wang LQ, Ye FL, Yin RL*
- 7429** Extranasopharyngeal angiofibroma in children: A case report  
*Yan YY, Lai C, Wu L, Fu Y*
- 7438** Deep Sylvian fissure meningiomas: A case report  
*Wang A, Zhang X, Sun KK, Li C, Song ZM, Sun T, Wang F*
- 7445** Acute pulmonary embolism originating from upper limb venous thrombosis following breast cancer surgery: Two case reports  
*Duan Y, Wang GL, Guo X, Yang LL, Tian FG*
- 7451** Managing spondylitis tuberculosis in a patient with underlying diabetes and hypothyroidism: A case report  
*Novita BD, Muliono AC, Wijaya S, Theodora I, Tjahjono Y, Supit VD, Willianto VM*
- 7459** Ovarian mucinous tumor with mural nodules of anaplastic carcinoma: Three case reports  
*Wang XJ, Wang CY, Xi YF, Bu P, Wang P*
- 7467** Transcatheter arterial infusion chemotherapy and embolization for primary lacrimal sac squamous cell carcinoma: A case report  
*Sun MH, Yi WD, Shen L, Zhou L, Lu JX*
- 7474** Programmed cell death-1 inhibitor combination treatment for recurrent proficient mismatch repair/microsatellite-stable type endometrial cancer: A case report  
*Zhai CY, Yin LX, Han WD*
- 7483** Novel compound heterozygous mutation of *SLC12A3* in Gitelman syndrome co-existent with hyperthyroidism: A case report and literature review  
*Qin YZ, Liu YM, Wang Y, You C, Li LN, Zhou XY, Lv WM, Hong SH, Xiao LX*
- 7495** Successful treatment of hyperglycemia with liraglutide in a hospitalized 27-year-old patient with schizophrenia: A case report  
*Zhang L, Yu WJ, Zhu H, Li HF, Qiao J*

- 7502** Refractory lymphoma treated with chimeric antigen receptor T cells combined with programmed cell death-1 inhibitor: A case report  
*Zhang CJ, Zhang JY, Li LJ, Xu NW*
- 7509** Median arcuate ligament syndrome with retroperitoneal haemorrhage: A case report  
*Lu XC, Pei JG, Xie GH, Li YY, Han HM*
- 7517** Novel frameshift mutation in the *AHDC1* gene in a Chinese global developmental delay patient: A case report  
*Lin SZ, Xie HY, Qu YL, Gao W, Wang WQ, Li JY, Feng XC, Jin CQ*
- 7523** Selective nerve block for the treatment of neuralgia in Kummell's disease: A case report  
*Zhang X, Li ZX, Yin LJ, Chen H*
- 7531** Traditional Chinese medicine manipulative reduction combined with percutaneous vertebroplasty for treating type III Kummell's disease: A case report  
*Hao SS, Zhang RJ, Dong SL, Li HK, Liu S, Li RF, Ren HH, Zhang LY*
- 7539** Differential diagnosis and treatment of foot drop caused by an extraneural ganglion cyst above the knee: A case report  
*Won KH, Kang EY*
- 7545** Effect of hydrogen intervention on refractory wounds after radiotherapy: A case report  
*Zhao PX, Luo RL, Dang Z, Wang YB, Zhang XJ, Liu ZY, Wen XH, Liu MY, Zhang MZ, Adzavon YM, Ma XM*
- 7553** Chronic urticaria associated with lung adenocarcinoma — a paraneoplastic manifestation: A case report and literature review  
*Jiménez LF, Castellón EA, Marengo JD, Mejía JM, Rojas CA, Jiménez FT, Coronell L, Osorio-Llanes E, Mendoza-Torres E*
- 7565** Spinal giant cell-rich osteosarcoma-diagnostic dilemma and treatment strategy: A case report  
*Tseng CS, Wong CE, Huang CC, Hsu HH, Lee JS, Lee PH*
- 7571** Primary clear cell sarcoma of soft tissue in the posterior cervical spine invading the medulla oblongata: A case report  
*Liu CC, Huang WP, Gao JB*
- 7577** *Pseudomonas aeruginosa*-related effusive-constrictive pericarditis diagnosed with echocardiography: A case report  
*Chen JL, Mei DE, Yu CG, Zhao ZY*
- 7585** Maternal peripartum bacteremia caused by intrauterine infection with *Comamonas kerstersii*: A case report  
*Qu H, Zhao YH, Zhu WM, Liu L, Zhu M*
- 7592** Considerations of single-lung ventilation in neonatal thoracoscopic surgery with cardiac arrest caused by bilateral pneumothorax: A case report  
*Zhang X, Song HC, Wang KL, Ren YY*

- 7599** Rare primary rectal mucosa-associated lymphoid tissue lymphoma with curative resection by endoscopic submucosal dissection: A case report and review of literature

*Tao Y, Nan Q, Lei Z, Miao YL, Niu JK*

- 7609** Differences in examination results of small anastomotic fistula after radical gastrectomy with afterward treatments: A case report

*Lu CY, Liu YL, Liu KJ, Xu S, Yao HL, Li L, Guo ZS*

### **LETTER TO THE EDITOR**

- 7617** Baseline differences may impact on relationship between dietary tryptophan and risk of obesity and type 2 diabetes

*Ren XH, Ye YW, He LP*

**ABOUT COVER**

Editorial Board Member of *World Journal of Clinical Cases*, Rajesh Kumar Rajnish, MBBS, MS, Assistant Professor, Department of Orthopaedics, All India Institute of Medical Sciences, Bilaspur, Bilaspur 174001, Himachal Pradesh, India. [duktiraj@gmail.com](mailto:duktiraj@gmail.com)

**AIMS AND SCOPE**

The primary aim of *World Journal of Clinical Cases* (WJCC, *World J Clin Cases*) is to provide scholars and readers from various fields of clinical medicine with a platform to publish high-quality clinical research articles and communicate their research findings online.

WJCC mainly publishes articles reporting research results and findings obtained in the field of clinical medicine and covering a wide range of topics, including case control studies, retrospective cohort studies, retrospective studies, clinical trials studies, observational studies, prospective studies, randomized controlled trials, randomized clinical trials, systematic reviews, meta-analysis, and case reports.

**INDEXING/ABSTRACTING**

The WJCC is now abstracted and indexed in Science Citation Index Expanded (SCIE, also known as SciSearch®), Journal Citation Reports/Science Edition, Current Contents®/Clinical Medicine, PubMed, PubMed Central, Scopus, Reference Citation Analysis, China National Knowledge Infrastructure, China Science and Technology Journal Database, and Superstar Journals Database. The 2022 Edition of Journal Citation Reports® cites the 2021 impact factor (IF) for WJCC as 1.534; IF without journal self cites: 1.491; 5-year IF: 1.599; Journal Citation Indicator: 0.28; Ranking: 135 among 172 journals in medicine, general and internal; and Quartile category: Q4. The WJCC's CiteScore for 2021 is 1.2 and Scopus CiteScore rank 2021: General Medicine is 443/826.

**RESPONSIBLE EDITORS FOR THIS ISSUE**

Production Editor: *Ying-Yi Yuan*; Production Department Director: *Xiang Li*; Editorial Office Director: *Jin-Lei Wang*.

**NAME OF JOURNAL**

*World Journal of Clinical Cases*

**ISSN**

ISSN 2307-8960 (online)

**LAUNCH DATE**

April 16, 2013

**FREQUENCY**

Thrice Monthly

**EDITORS-IN-CHIEF**

Bao-Gan Peng, Jerzy Tadeusz Chudek, George Kontogeorgos, Maurizio Serati, Ja Hyeon Ku

**EDITORIAL BOARD MEMBERS**

<https://www.wjnet.com/2307-8960/editorialboard.htm>

**PUBLICATION DATE**

July 26, 2022

**COPYRIGHT**

© 2022 Baishideng Publishing Group Inc

**INSTRUCTIONS TO AUTHORS**

<https://www.wjnet.com/bpg/gerinfo/204>

**GUIDELINES FOR ETHICS DOCUMENTS**

<https://www.wjnet.com/bpg/GerInfo/287>

**GUIDELINES FOR NON-NATIVE SPEAKERS OF ENGLISH**

<https://www.wjnet.com/bpg/gerinfo/240>

**PUBLICATION ETHICS**

<https://www.wjnet.com/bpg/GerInfo/288>

**PUBLICATION MISCONDUCT**

<https://www.wjnet.com/bpg/gerinfo/208>

**ARTICLE PROCESSING CHARGE**

<https://www.wjnet.com/bpg/gerinfo/242>

**STEPS FOR SUBMITTING MANUSCRIPTS**

<https://www.wjnet.com/bpg/GerInfo/239>

**ONLINE SUBMISSION**

<https://www.f6publishing.com>



## Considerations of single-lung ventilation in neonatal thoracoscopic surgery with cardiac arrest caused by bilateral pneumothorax: A case report

Xu Zhang, Hai-Cheng Song, Kui-Liang Wang, Yue-Yi Ren

**Specialty type:** Anesthesiology

**Provenance and peer review:**

Unsolicited article; Externally peer reviewed.

**Peer-review model:** Single blind

**Peer-review report's scientific quality classification**

Grade A (Excellent): 0  
Grade B (Very good): B  
Grade C (Good): C  
Grade D (Fair): D  
Grade E (Poor): 0

**P-Reviewer:** Lee S, South Korea;  
Tajiri K, Japan

**Received:** February 23, 2022

**Peer-review started:** February 23, 2022

**First decision:** March 25, 2022

**Revised:** March 29, 2022

**Accepted:** June 18, 2022

**Article in press:** June 18, 2022

**Published online:** July 26, 2022



**Xu Zhang, Hai-Cheng Song, Kui-Liang Wang, Yue-Yi Ren**, Department of Heart Center, Women's and Children's Hospital Affiliated to Qingdao University, Qingdao 266034, Shandong Province, China

**Corresponding author:** Yue-Yi Ren, MD, Associate Chief Physician, Associate Professor, Department of Heart Center, Women's and Children's Hospital Affiliated to Qingdao University, No. 217 Liaoyang West Road, Shibei District, Qingdao 266034, Shandong Province, China. [xxgmz1173@126.com](mailto:xxgmz1173@126.com)

### Abstract

#### BACKGROUND

Tension pneumothorax of the contralateral lung during single-lung ventilation (SLV) combined with artificial pneumothorax can cause cardiac arrest due to bilateral pneumothorax. If not rapidly diagnosed and managed, this condition can lead to sudden death. We describe the emergency handling procedures and rapid diagnostic methods for this critical emergency situation.

#### CASE SUMMARY

We report a case of bilateral pneumothorax in a neonatal patient who underwent thoracoscopic esophageal atresia and tracheoesophageal fistula repair under the combined application of SLV and artificial pneumothorax. The patient suffered sudden cardiac arrest and received emergency treatment to revive her. The recognition of dangerous vital sign parameters, rapid evacuation of the artificial pneumothorax, and initiation of lateral position cardiopulmonary resuscitation while simultaneously removing the endotracheal tube to the main airway are critically important. Moreover, even though the sinus rhythm was restored, the patient's continued tachycardia, reduced pulse pressure, and depressed pulse oximeter waveform were worrisome. We should highly suspect the possibility of pneumothorax and use rapid diagnostic methods to make judgment calls. Sometimes thoracoscopy can be used for rapid examination; if the mediastinum is observed to be shifted to the right, it may indicate tension pneumothorax. This condition can be immediately relieved by needle thoracentesis, ultimately allowing the safe completion of the surgical procedure.

#### CONCLUSION

Bilateral pneumothorax during SLV combined with artificial pneumothorax is



rare but can occur at any time in neonatal thoracoscopic surgery. Therefore, anesthesiologists should consider this possibility, be alert, and address this rare but critical complication in a timely manner.

**Key Words:** Neonatal thoracoscopic surgery; Bilateral pneumothorax; Single-lung ventilation; Cardiac arrest; Case report

©The Author(s) 2022. Published by Baishideng Publishing Group Inc. All rights reserved.

**Core Tip:** Tension pneumothorax on the contralateral lung during single-lung ventilation (SLV) combined with artificial pneumothorax can lead to cardiac arrest due to bilateral pneumothorax. If not rapidly diagnosed and managed, it can lead to sudden death. Bilateral pneumothorax during SLV combined with artificial pneumothorax is rare but can occur at any time in neonatal thoracoscopic surgery. We describe the emergency handling procedures and rapid diagnostic methods for this critical emergency situation.

**Citation:** Zhang X, Song HC, Wang KL, Ren YY. Considerations of single-lung ventilation in neonatal thoracoscopic surgery with cardiac arrest caused by bilateral pneumothorax: A case report. *World J Clin Cases* 2022; 10(21): 7592-7598

**URL:** <https://www.wjgnet.com/2307-8960/full/v10/i21/7592.htm>

**DOI:** <https://dx.doi.org/10.12998/wjcc.v10.i21.7592>

## INTRODUCTION

The thoracoscopic repair of esophageal atresia (EA) and tracheoesophageal fistula (TEF) has gained increased acceptance, but it is a highly technical and challenging procedure[1]. To expand the surgical space, the nondependent lung is intentionally collapsed using surgically guided intrathoracic carbon dioxide (CO<sub>2</sub>) insufflation (artificial pneumothorax, AP) combined with single-lung ventilation (SLV) [2]. However, for neonates, the combination of these two approaches can potentially pose serious pathophysiological changes. The most common complications of thoracoscopic repair include the development of high airway pressure, hypoxemia and hypercapnia[3]. The present case report details a neonatal patient who underwent thoracoscopic EA/TEF repair using the combination of AP and SLV, which was complicated by the development of bilateral pneumothorax and cardiac arrest.

## CASE PRESENTATION

### Chief complaints

A preterm female born at 36 wk gestation received nCPAP-assisted ventilation due to dyspnea, during which it was difficult to place an indwelling nasogastric tube.

### History of present illness

The neonatal patient was delivered by cesarean section at 36 wk due to intrauterine distress and reduced flow in the umbilical artery. The patient gradually developed dyspnea for 10 min after birth, which was characterized by shortness of breath and cyanosis, and the neonate was then transferred to the Neonatal Intensive Care Unit (NICU). She was given nCPAP-assisted ventilation, during which it was difficult to place an indwelling nasogastric tube. Due to the history of amniotic fluid, EA was not excluded.

### History of past illness

The patient had no history of other illnesses.

### Personal and family history

The patient had no family history of illness.

### Physical examination

The physical examination revealed a premature infant's appearance and poor physical development (height, 40 cm; weight, 1.93 kg), a blood pressure of 75/45 mmHg, a pulse rate of 140 beats per min, and a respiratory rate (RR) of 46 breaths/min. Her oxygen saturation on a pulse oximeter was 93% in room

air.

### Laboratory examinations

Blood tests showed an Hb level of 14.5 g/dL, hematocrit (Hct) of 75%, platelet count of  $187 \times 10^9$  cells/L, leukocyte count of  $16.83 \times 10^9$ /L, and C-reactive protein of 5.68 mg/L. Other blood tests showed no significant abnormalities.

### Imaging examinations

Upper gastrointestinal radiography (a small amount of contrast agent was injected through the orogastric tube) showed that the middle and upper esophagus was markedly dilated, the proximal blind end of the esophagus was located at the level of the third thoracic vertebra, and there was significantly less physiological gas accumulation in the abdomen (Figure 1). Chest computed tomography suggested neonatal pneumonia and no pleural effusion. Echocardiography showed no obvious abnormalities.

## FINAL DIAGNOSIS

She was initially diagnosed with type III EA, which is the most common proximal EA, with a distal TEF.

## TREATMENT

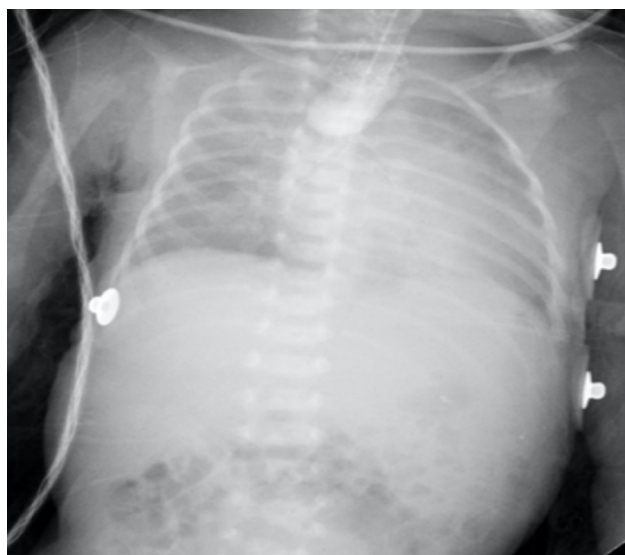The patient underwent surgery on the third day after her birth. In preparation for thoracoscopic repair, the patient first was allowed to continue to spontaneously breathe during general anesthesia with 6% sevoflurane carried by 100% oxygen through a face mask. A 2.8-mm fiberoptic bronchoscope (FOB) was inserted into the airway orally through a swivel adaptor connected to the mask. The fistula was located proximal to the carina and trifurcation (Figure 2A). Then, a bougie was introduced into the left mainstem bronchus under the FOB (Figure 2B), and a 3.0 mm cuffed endotracheal tube (ETT) was positioned into the left mainstem bronchus using the bougie as a guide. We confirmed the SLV by chest auscultation, as the 2.8-mm FOB could not pass through the ETT. One milligram of rocuronium was then administered intravenously, left radial artery cannulation and right internal jugular vein catheterization were performed, and she was placed in the left lateral decubitus position. AP was established by insufflation of CO<sub>2</sub> into the right thoracic cavity at a pressure of 4 mmHg. Mechanical ventilation was conducted with a pressure control of 24 cmH<sub>2</sub>O, a RR of 28 breaths/min, and a positive end expiratory pressure 3 cmH<sub>2</sub>O.

The end-tidal CO<sub>2</sub> (ETCO<sub>2</sub>) level continuously rose during surgery. When the operative procedure started at 1 h, the arterial partial pressure of CO<sub>2</sub> (PaCO<sub>2</sub>) was 62 mmHg. The control pressure was gradually increased to 30 mmHg, and the AP pressure was reduced to 2 mmHg to meet the tidal volume requirements. Two hours into the operation, a further increase in the PaCO<sub>2</sub> to 85 mmHg prompted communication with the surgeon. At this time, the fistula was ligated, and the surgeon performed an end-to-end anastomosis during the operation.

The surgeon thought that the distance between the two ends of the esophagus was small, so the success rate of the operation was very high. To increase the tidal volume and RR, manual ventilation with 100% oxygen was instituted, which also washed out the retained CO<sub>2</sub> after two minutes of using recruitment maneuvering techniques. During the establishment of AP and CO<sub>2</sub> insufflation, the patient suffered sudden cardiac arrest, with her heart rate, arterial blood pressure and pulse oximeter suddenly flattening on the monitor.

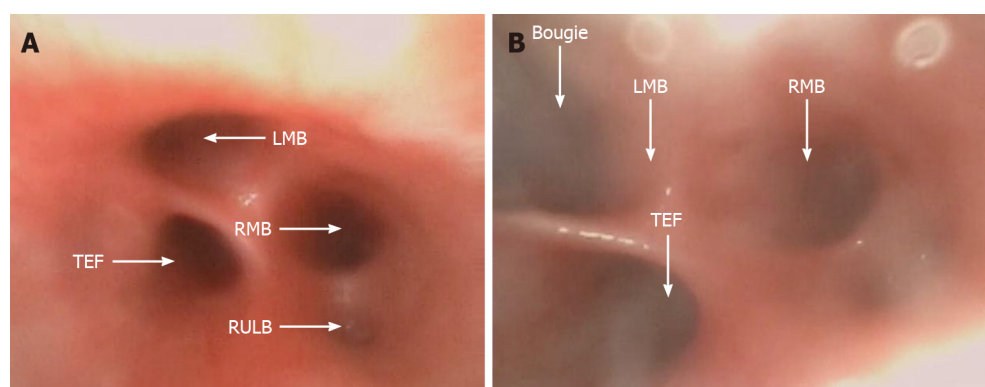
The CO<sub>2</sub> in the right thoracic cavity was immediately evacuated by opening the trocar, and the surgeon initiated lateral cardiac compressions, with one palm against the child's back and by using two-finger anterior chest compressions. With an intravenous injection of 10 µg of epinephrine, a normal sinus heart rhythm was restored. However, the monitor showed an HR of 180 beats/min, an ABP of 53/47 mmHg with reduced pulse pressure, and a poor pulse oximetry waveform. Thoracoscopy showed that the mediastinal structures were shifted to the right, strongly indicating the presence of a left tension pneumothorax.

We examined the ETT and anesthesia breathing circuit and then removed the ETT from the main airway. Auscultation of bilateral lung breath sounds showed that the breath sounds on the left were weak, while the breath sounds on the right were strong. The right thoracoscopic incision was covered with gauze, and the patient was moved to the supine position. A needle thoracocentesis was performed with a 22 G intravenous indwelling needle in the second left interspace midclavicular line, which caused immediate improvement in the ABP and pulse oximeter waveforms. After approximately 50 mL of gas had been extracted, the indwelling needle was replaced with a standard chest drain. The patient's vital signs then returned to normal, with an ABP of 58/39 mmHg, a HR of 165 beats/min, and a pulse oximeter reading of 93%. With the restoration of stable hemodynamics, the thoracoscopy was converted to thoracotomy and was successfully completed.



DOI: 10.12998/wjcc.v10.i21.7592 Copyright ©The Author(s) 2022.

Figure 1 The preoperative upper gastrointestinal radiography.



DOI: 10.12998/wjcc.v10.i21.7592 Copyright ©The Author(s) 2022.

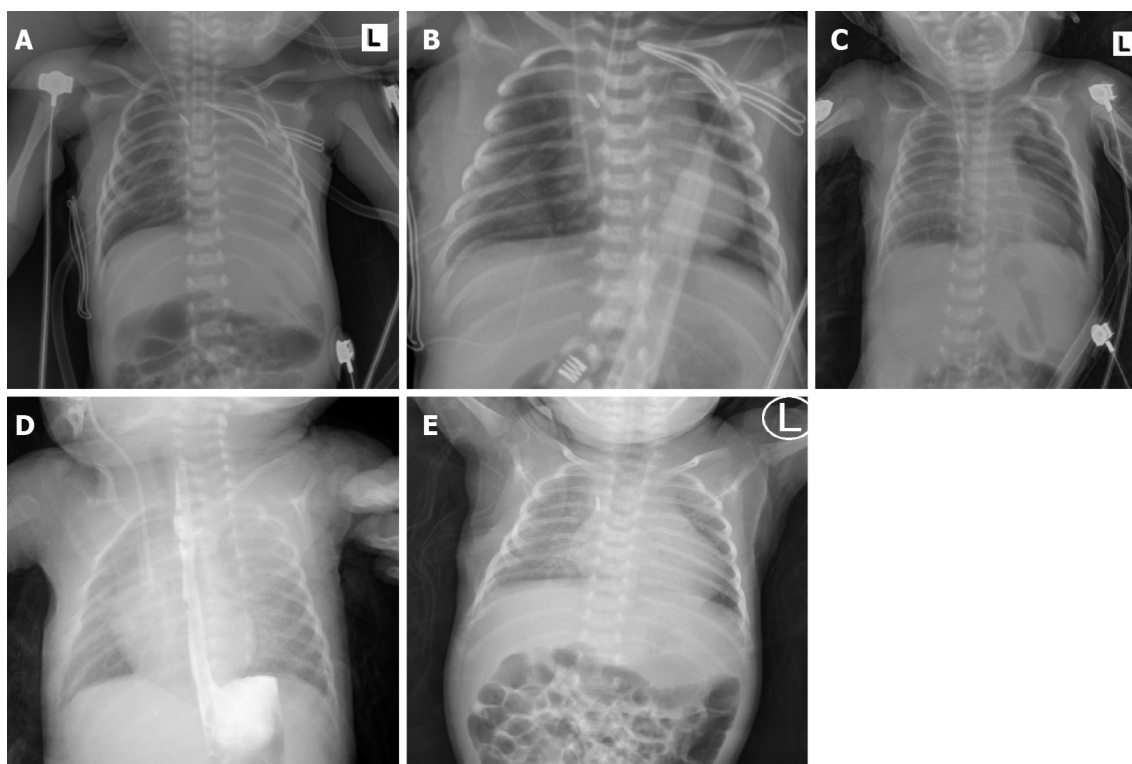
**Figure 2 Fiberoptic bronchoscopy.** A: The thick fistula was located proximal as a trifurcation at the carina; B: The bougie was introduced into the left mainstem bronchus under fiberoptic bronchoscopy. LMB: Left mainstem bronchus; RMB: Right mainstem bronchus; RULB: Right upper lobe bronchus; TEF: Tracheoesophageal fistula.

## OUTCOME AND FOLLOW-UP

After surgery, the patient was immediately transferred to the cardiac intensive care unit under endotracheal intubation. The chest X-ray revealed partial atelectasis of the left lung after the operation (Figure 3A). The patient was treated with positive pressure ventilation. The chest X-ray taken on the first postoperative day revealed good re-expansion of the left lung (Figure 3B). Bedside ultrasonography was performed, and no pleural effusion was found. The ETT was removed on the fifth postoperative day. Because the patient developed recurrent pneumothorax and pulmonary exudation, the air leakage persisted, and the patient's right chest tube was removed on the 12th day after the operation. The chest X-ray taken on the 13th postoperative day showed that a pneumothorax had developed again on the left side (Figure 3C); therefore, the left chest tube was not removed until the 15th postoperative day. Then, she was transferred out of the NICU. Postoperative upper gastrointestinal radiography showed that the surgical effect was good (Figure 3D). The patient had a repeat chest X-ray, which showed marked improvement, and she was subsequently discharged (Figure 3E).

## DISCUSSION

Neonatal pneumothorax is an uncommon event during the perioperative period. There are many risk factors for pneumothorax in neonates, such as prematurity, neonatal respiratory distress syndrome, pneumonia and positive pressure ventilation[4]. In the present case, the patient care was complicated by



DOI: 10.12998/wjcc.v10.i21.7592 Copyright ©The Author(s) 2022.

**Figure 3 The chest X-ray images.** A: The chest X-ray revealed partial atelectasis of the left lung after the operation; B: The chest X-ray taken on the first postoperative day revealed good re-expansion of the left lung; C: The chest X-ray taken on the 13<sup>th</sup> postoperative day revealed pneumothorax reappearing on the left; D: The postoperative upper gastrointestinal radiography showed that the operation effect was good; E: The chest X-ray before discharge showed marked improvement.

congenital pneumonia, and she received CPAP treatment before surgery. To expand the surgical space, we used a combination of AP and SLV. The methods available for neonatal SLV are limited[5]. The smallest FOB (2.8 mm) available in our hospital was too thick to use the ETT. We chose a compromise method, by using the fiberoptic bronchoscope to guide the bougie into the left main bronchus and then through the bougie into the ETT. It can be more accurate to place the ETT into the left main bronchus in order to avoid the fistula. At the start of surgery, the patient was placed in the left lateral decubitus position with AP in the right lung and left SLV. Unexpectedly, she developed bilateral pneumothorax, which resulted in cardiac arrest. If right-sided AP was not used, the tension pneumothorax on the left may not have led to sudden cardiac arrest. A possible cause of the left pneumothorax was the higher-pressure ventilation from the single bronchus intubation and SLV. Niwas *et al*[6] reported that neonatal pneumothorax cases mainly occurred on the right side (72.5%), and 67% of these cases were related to endotracheal intubation of the single bronchus. Another potential cause was the use of intraoperative manual ventilation and continuous strong positive pressure ventilation with the consequent rupture of the left pulmonary alveoli, leading to a tension pneumothorax. In previous case reports, many cases of tension pneumothorax during SLV in adults have been associated with barotrauma[7]. During SLV, the use of recruitment maneuvering techniques at high pressures can lead to barotraumatic and even contralateral tension pneumothorax[8]. In addition, another possible cause was the use of an intubation bougie to guide single bronchus intubation. Literature reports have indicated that the use of intubation bougies in neonates may cause a pneumothorax. Kumar and Walker reported a case of pneumothorax as a result of airway perforation by using a bougie[9]. Two other cases of neonatal pneumothorax reported by Parekh *et al*[10] were suspected to be caused by trauma when a bougie is used to guide endotracheal intubation.

Normally, the clinical manifestations of tension pneumothorax in neonates receiving mechanical ventilation include immediate increased airway pressure, progressively decreased pulse oximeter readings, decreased heart rate, sometimes decreased or disappearing end tidal CO<sub>2</sub> concentrations, and loss of breath sounds of the affected side[11]. However, some findings are generally considered to be reasonable in neonatal thoracoscopy, such as decreased HR, ABP, pulse oximeter readings, and a narrowing of pulse pressure. In this case, the patient developed tension pneumothorax and immediately experienced cardiac arrest. If the situation permits, in addition to auscultation, chest transillumination and lung ultrasound are also fast and effective methods for the diagnosis of pneumothorax[12,13].



In this case, the blood gas analysis of the patient showed that her PaCO<sub>2</sub> exceeded 85 mmHg and that she developed hypercapnia. By suspending the surgery, we increased the RR and tidal volume to quickly expel CO<sub>2</sub> from the alveolar spaces. Severe acidosis, mainly due to hypercapnia caused by the application of CO<sub>2</sub> to develop an AP, is a common feature and regarded as a significant drawback of neonatal thoracoscopy[14,15]. However, several studies have shown that the decrease in SaO<sub>2</sub> and pH and the increase in PaCO<sub>2</sub> are reversible during neonatal thoracoscopy and AP[14,15,16]. The regional cerebral oxygen saturation (rSO<sub>2</sub>) remained stable, suggesting no hampering of cerebral oxygenation by thoracoscopic surgery. In one study, further follow-up showed that neurodevelopmental outcomes of these neonates were favorable in the first 24 months[14]. In general, no matter what happens to the other blood gas parameters, maintaining a normal rSO<sub>2</sub> is very important to prevent brain injury.

The cause of cardiac arrest in this patient was mediastinal displacement and compression of the heart and large blood vessels due to bilateral tension pneumothorax. We immediately started chest compressions with the patient in the lateral position and gave the patient an intravenous injection of epinephrine. At the same time, rapid evacuation of CO<sub>2</sub> and removal of the ETT in the main airway were also critically important. Moreover, even though a normal sinus rhythm was restored, the patient's continued tachycardia, reduced pulse pressure, and depressed pulse oximeter waveform were still worrisome. In these types of cases should highly suspect the possibility of pneumothorax and use rapid diagnostic methods to make judgment calls. Sometimes thoracoscopy can be used for rapid examination; if the mediastinum is observed to have shifted to the right, tension pneumothorax may be present. This condition is immediately relieved by needle thoracentesis, which ultimately allows for safe completion of the surgical procedure.

## CONCLUSION

Pneumothorax is rare but can occur at any time during neonatal thoracoscopic surgery. In addition to the common risk factors for neonatal pneumothorax, AP and SLV are two special risk factors that can lead to the possibility of bilateral pneumothorax. Therefore, anesthesiologists should consider and be alert to the occurrence of bilateral pneumothorax in neonatal thoracoscopic surgery. If not found and managed adequately in a rapid manner, the conditions can lead to cardiac arrest and sudden death.

## FOOTNOTES

**Author contributions:** Zhang X and Ren YY, the patient's anesthesiologists, acquired the patient consent, and drafted and revised the manuscript; Wang KL and Song HC took responsibility for investigation and data curation; all authors read and approved the final manuscript.

**Informed consent statement:** Written informed consent was obtained from the patient's parent or guardian for publication of this case report and any accompanying images.

**Conflict-of-interest statement:** No conflict of interest exists in the submission of this manuscript, and manuscript is approved by all authors for publication.

**CARE Checklist (2016) statement:** The authors have read the CARE Checklist (2016), and the manuscript was prepared and revised according to the CARE Checklist (2016).

**Open-Access:** This article is an open-access article that was selected by an in-house editor and fully peer-reviewed by external reviewers. It is distributed in accordance with the Creative Commons Attribution NonCommercial (CC BY-NC 4.0) license, which permits others to distribute, remix, adapt, build upon this work non-commercially, and license their derivative works on different terms, provided the original work is properly cited and the use is non-commercial. See: <https://creativecommons.org/licenses/by-nc/4.0/>

**Country/Territory of origin:** China

**ORCID number:** Xu Zhang 0000-0002-6481-2505; Hai-Cheng Song 0000-0002-4444-3562; Kui-Liang Wang 0000-0002-0873-6413; Yue-Yi Ren 0000-0002-0410-7978.

**S-Editor:** Yan JP

**L-Editor:** A

**P-Editor:** Yan JP

## REFERENCES

- 1 **Wu Y**, Kuang H, Lv T, Wu C. Comparison of clinical outcomes between open and thoracoscopic repair for esophageal atresia with tracheoesophageal fistula: a systematic review and meta-analysis. *Pediatr Surg Int* 2017; **33**: 1147-1157 [PMID: [28914345](#) DOI: [10.1007/s00383-017-4153-9](#)]
- 2 **Kashyap L**, Nisa N, Chowdhury AR, Khanna P. Safety issues of endobronchial intubation for one-lung ventilation in video-assisted thoracoscopic surgery in neonates: Can we extubate on the table? *Saudi J Anaesth* 2017; **11**: 254-255 [PMID: [28442980](#) DOI: [10.4103/1658-354X.203058](#)]
- 3 **Zani A**, Lamas-Pinheiro R, Paraboschi I, King SK, Wolinska J, Zani-Ruttenstock E, Eaton S, Pierro A. Intraoperative acidosis and hypercapnia during thoracoscopic repair of congenital diaphragmatic hernia and esophageal atresia/tracheoesophageal fistula. *Paediatr Anaesth* 2017; **27**: 841-848 [PMID: [28631351](#) DOI: [10.1111/pan.13178](#)]
- 4 **Vibede L**, Vibede E, Bendtsen M, Pedersen L, Ebbesen F. Neonatal Pneumothorax: A Descriptive Regional Danish Study. *Neonatology* 2017; **111**: 303-308 [PMID: [28013308](#) DOI: [10.1159/000453029](#)]
- 5 **Schmidt C**, Rellensmann G, Van Aken H, Semik M, Bruessel T, Enk D. Single-lung ventilation for pulmonary lobe resection in a newborn. *Anesth Analg* 2005; **101**: 362-364 [PMID: [16037144](#) DOI: [10.1213/01.ANE.0000156007.97090.DA](#)]
- 6 **Niwas R**, Nadroo AM, Sutija VG, Gudavalli M, Narula P. Malposition of endotracheal tube: association with pneumothorax in ventilated neonates. *Arch Dis Child Fetal Neonatal Ed* 2007; **92**: F233-F234 [PMID: [17449860](#) DOI: [10.1136/adc.2006.106245](#)]
- 7 **Lee SK**, Seo KH, Kim YJ, Youn EJ, Lee JS, Park J, Moon HS. Cardiac arrest caused by contralateral tension pneumothorax during one-lung ventilation: - A case report. *Anesth Pain Med (Seoul)* 2020; **15**: 78-82 [PMID: [33329794](#) DOI: [10.17085/apm.2020.15.1.78](#)]
- 8 **Hoechter DJ**, Speck E, Siegl D, Laven H, Zwissler B, Kammerer T. Tension Pneumothorax During One-Lung Ventilation - An Underestimated Complication? *J Cardiothorac Vasc Anesth* 2018; **32**: 1398-1402 [PMID: [29361455](#) DOI: [10.1053/j.jvca.2017.07.022](#)]
- 9 **Sakhuja P**, Ferenc BA, Fierens I, Garg A, Ratnavel N. Association of pneumothorax with use of a bougie for endotracheal intubation in a neonate. *J Paediatr Child Health* 2019; **55**: 376 [PMID: [30828942](#) DOI: [10.1111/jpc.14383](#)]
- 10 **Parekh UR**, Maguire AM, Emery J, Martin PH. Pneumothorax in neonates: Complication during endotracheal intubation, diagnosis, and management. *J Anaesthesiol Clin Pharmacol* 2016; **32**: 397-399 [PMID: [27625498](#) DOI: [10.4103/0970-9185.188820](#)]
- 11 **Huang TJ**, Ahmed A, D'Souza D, Awad H. Delayed diagnosis of contralateral tension pneumothorax during robotic lung wedge resection. *J Clin Anesth* 2018; **45**: 30-31 [PMID: [29272756](#) DOI: [10.1016/j.jclinane.2017.11.023](#)]
- 12 **Sharma D**, Murki S, Pratap T. Point of care in nursery to diagnose pneumothorax in neonates by new use of LED torch. *Med Dr. D.Y. Patil Univers* 2016; **9**: 124-126 [DOI: [10.4103/0975-2870.167973](#)]
- 13 **Fei Q**, Lin Y, Yuan TM. Lung Ultrasound, a Better Choice for Neonatal Pneumothorax: A Systematic Review and Meta-analysis. *Ultrasound Med Biol* 2021; **47**: 359-369 [PMID: [33341304](#) DOI: [10.1016/j.ultrasmedbio.2020.11.011](#)]
- 14 **Bishay M**, Giacomello L, Retrosi G, Thyoka M, Garriboli M, Brierley J, Harding L, Scuplak S, Cross KM, Curry JI, Kiely EM, De Coppi P, Eaton S, Pierro A. Hypercapnia and acidosis during open and thoracoscopic repair of congenital diaphragmatic hernia and esophageal atresia: results of a pilot randomized controlled trial. *Ann Surg* 2013; **258**: 895-900 [PMID: [23604057](#) DOI: [10.1097/SLA.0b013e31828fab55](#)]
- 15 **Costerus S**, Vlot J, van Rosmalen J, Wijnen R, Weber F. Effects of Neonatal Thoracoscopic Surgery on Tissue Oxygenation: A Pilot Study on (Neuro-) Monitoring and Outcomes. *Eur J Pediatr Surg* 2019; **29**: 166-172 [PMID: [29270947](#) DOI: [10.1055/s-0037-1615277](#)]
- 16 **Tytgat SH**, van Herwaarden MY, Stolwijk LJ, Keunen K, Benders MJ, de Graaff JC, Milstein DM, van der Zee DC, Lemmers PM. Neonatal brain oxygenation during thoracoscopic correction of esophageal atresia. *Surg Endosc* 2016; **30**: 2811-2817 [PMID: [26490769](#) DOI: [10.1007/s00464-015-4559-1](#)]



Published by **Baishideng Publishing Group Inc**  
7041 Koll Center Parkway, Suite 160, Pleasanton, CA 94566, USA

**Telephone:** +1-925-3991568

**E-mail:** [bpgoffice@wjgnet.com](mailto:bpgoffice@wjgnet.com)

**Help Desk:** <https://www.f6publishing.com/helpdesk>

<https://www.wjgnet.com>

