

# World Journal of *Clinical Cases*

*World J Clin Cases* 2022 August 6; 10(22): 7620-8056



## Contents

Thrice Monthly Volume 10 Number 22 August 6, 2022

## OPINION REVIEW

- 7620 Whipple's operation with a modified centralization concept: A model in low-volume Caribbean centers  
*Cawich SO, Pearce NW, Naraynsingh V, Shukla P, Deshpande RR*

## REVIEW

- 7631 Role of micronutrients in Alzheimer's disease: Review of available evidence  
*Fei HX, Qian CF, Wu XM, Wei YH, Huang JY, Wei LH*

## MINIREVIEWS

- 7642 Application of imaging techniques in pancreaticobiliary maljunction  
*Wang JY, Mu PY, Xu YK, Bai YY, Shen DH*
- 7653 Update on gut microbiota in gastrointestinal diseases  
*Nishida A, Nishino K, Ohno M, Sakai K, Owaki Y, Noda Y, Imaeda H*
- 7665 Vascular complications of pancreatitis  
*Kalas MA, Leon M, Chavez LO, Canalizo E, Surani S*

## ORIGINAL ARTICLE

## Clinical and Translational Research

- 7674 Network pharmacology and molecular docking reveal zedoary turmeric-trisomes in Inflammatory bowel disease with intestinal fibrosis  
*Zheng L, Ji YY, Dai YC, Wen XL, Wu SC*

## Case Control Study

- 7686 Comprehensive proteomic signature and identification of CDKN2A as a promising prognostic biomarker and therapeutic target of colorectal cancer  
*Wang QQ, Zhou YC, Zhou Ge YJ, Qin G, Yin TF, Zhao DY, Tan C, Yao SK*

## Retrospective Cohort Study

- 7698 Is anoplasty superior to scar revision surgery for post-hemorrhoidectomy anal stenosis? Six years of experience  
*Weng YT, Chu KJ, Lin KH, Chang CK, Kang JC, Chen CY, Hu JM, Pu TW*

## Retrospective Study

- 7708 Short- (30-90 days) and mid-term (1-3 years) outcomes and prognostic factors of patients with esophageal cancer undergoing surgical treatments  
*Shi MK, Mei YQ, Shi JL*

- 7720** Effectiveness of pulsed radiofrequency on the medial cervical branches for cervical facet joint pain  
*Chang MC, Yang S*
- 7728** Clinical performance evaluation of O-Ring Halcyon Linac: A real-world study  
*Wang GY, Zhu QZ, Zhu HL, Jiang LJ, Zhao N, Liu ZK, Zhang FQ*
- 7738** Correlation between the warning symptoms and prognosis of cardiac arrest  
*Zheng K, Bai Y, Zhai QR, Du LF, Ge HX, Wang GX, Ma QB*
- 7749** Serum ferritin levels in children with attention deficit hyperactivity disorder and tic disorder  
*Tang CY, Wen F*
- 7760** Application of metagenomic next-generation sequencing in the diagnosis of infectious diseases of the central nervous system after empirical treatment  
*Chen YY, Guo Y, Xue XH, Pang F*
- 7772** Prognostic role of multiple abnormal genes in non-small-cell lung cancer  
*Yan LD, Yang L, Li N, Wang M, Zhang YH, Zhou W, Yu ZQ, Peng XC, Cai J*
- 7785** Prospective single-center feasible study of innovative autorelease bile duct supporter to delay adverse events after endoscopic papillectomy  
*Liu SZ, Chai NL, Li HK, Feng XX, Zhai YQ, Wang NJ, Gao Y, Gao F, Wang SS, Linghu EQ*

**Clinical Trials Study**

- 7794** Performance of Dexcom G5 and FreeStyle Libre sensors tested simultaneously in people with type 1 or 2 diabetes and advanced chronic kidney disease  
*Ólafsdóttir AF, Andelin M, Saeed A, Sofizadeh S, Hamoodi H, Jansson PA, Lind M*

**Observational Study**

- 7808** Complications of chronic pancreatitis prior to and following surgical treatment: A proposal for classification  
*Murruste M, Kirsimägi Ü, Kase K, Veršinina T, Talving P, Lepner U*
- 7825** Effects of comprehensive nursing on postoperative complications, mental status and quality of life in patients with glioma  
*Dong H, Zhang XL, Deng CX, Luo B*

**Prospective Study**

- 7832** Predictors of long-term anxiety and depression in discharged COVID-19 patients: A follow-up study  
*Boyraz RK, Şahan E, Boylu ME, Kırpınar İ*

**META-ANALYSIS**

- 7844** Same-day single-dose vs large-volume split-dose regimens of polyethylene glycol for bowel preparation: A systematic review and meta-analysis  
*Pan H, Zheng XL, Fang CY, Liu LZ, Chen JS, Wang C, Chen YD, Huang JM, Zhou YS, He LP*

- 7859** Rectal nonsteroidal anti-inflammatory drugs, glyceryl trinitrate, or combinations for prophylaxis of post-endoscopic retrograde cholangiopancreatography pancreatitis: A network meta-analysis

*Shi QQ, Huang GX, Li W, Yang JR, Ning XY*

- 7872** Effect of celecoxib on improving depression: A systematic review and meta-analysis

*Wang Z, Wu Q, Wang Q*

### CASE REPORT

- 7883** Rectal mature teratoma: A case report

*Liu JL, Sun PL*

- 7890** Antibiotic and glucocorticoid-induced recapitulated hematological remission in acute myeloid leukemia: A case report and review of literature

*Sun XY, Yang XD, Yang XQ, Ju B, Xiu NN, Xu J, Zhao XC*

- 7899** Non-secretory multiple myeloma expressed as multiple extramedullary plasmacytoma with an endobronchial lesion mimicking metastatic cancer: A case report

*Lee SB, Park CY, Lee HJ, Hong R, Kim WS, Park SG*

- 7906** Latamoxef-induced severe thrombocytopenia during the treatment of pulmonary infection: A case report

*Zhang RY, Zhang JJ, Li JM, Xu YY, Xu YH, Cai XJ*

- 7913** Multicentric reticulohistiocytosis with prominent skin lesions and arthritis: A case report

*Xu XL, Liang XH, Liu J, Deng X, Zhang L, Wang ZG*

- 7924** Brainstem abscesses caused by *Listeria monocytogenes*: A case report

*Wang J, Li YC, Yang KY, Wang J, Dong Z*

- 7931** Primary hypertension in a postoperative paraganglioma patient: A case report

*Wei JH, Yan HL*

- 7936** Long-term survival of gastric mixed neuroendocrine-non-neuroendocrine neoplasm: Two case reports

*Woo LT, Ding YF, Mao CY, Qian J, Zhang XM, Xu N*

- 7944** Percutaneous transforaminal endoscopic decompression combined with percutaneous vertebroplasty in treatment of lumbar vertebral body metastases: A case report

*Ran Q, Li T, Kuang ZP, Guo XH*

- 7950** Atypical imaging features of the primary spinal cord glioblastoma: A case report

*Liang XY, Chen YP, Li Q, Zhou ZW*

- 7960** Resection with limb salvage in an Asian male adolescent with Ewing's sarcoma: A case report

*Lai CY, Chen KJ, Ho TY, Li LY, Kuo CC, Chen HT, Fong YC*

- 7968** Early detection of circulating tumor DNA and successful treatment with osimertinib in thr790met-positive leptomeningeal metastatic lung cancer: A case report

*Xu LQ, Wang YJ, Shen SL, Wu Y, Duan HZ*

- 7973** Delayed arterial symptomatic epidural hematoma on the 14<sup>th</sup> day after posterior lumbar interbody fusion: A case report  
*Hao SS, Gao ZF, Li HK, Liu S, Dong SL, Chen HL, Zhang ZF*
- 7982** Clinical and genetic analysis of nonketotic hyperglycinemia: A case report  
*Ning JJ, Li F, Li SQ*
- 7989** Ectopic Cushing's syndrome in a patient with metastatic Merkel cell carcinoma: A case report  
*Ishay A, Touma E, Vornicova O, Dodiuk-Gad R, Goldman T, Bisharat N*
- 7994** Occurrence of MYD88L265P and CD79B mutations in diffuse large b cell lymphoma with bone marrow infiltration: A case report  
*Huang WY, Weng ZY*
- 8003** Rare case of compartment syndrome provoked by inhalation of polyurethane agent: A case report  
*Choi JH, Oh HM, Hwang JH, Kim KS, Lee SY*
- 8009** Acute ischemic Stroke combined with Stanford type A aortic dissection: A case report and literature review  
*He ZY, Yao LP, Wang XK, Chen NY, Zhao JJ, Zhou Q, Yang XF*
- 8018** Compound-honeysuckle-induced drug eruption with special manifestations: A case report  
*Zhou LF, Lu R*
- 8025** Spontaneous internal carotid artery pseudoaneurysm complicated with ischemic stroke in a young man: A case report and review of literature  
*Zhong YL, Feng JP, Luo H, Gong XH, Wei ZH*
- 8034** Microcystic adnexal carcinoma misdiagnosed as a "recurrent epidermal cyst": A case report  
*Yang SX, Mou Y, Wang S, Hu X, Li FQ*
- 8040** Accidental discovery of appendiceal carcinoma during gynecological surgery: A case report  
*Wang L, Dong Y, Chen YH, Wang YN, Sun L*
- 8045** Intra-ampullary papillary-tubular neoplasm combined with ampullary neuroendocrine carcinoma: A case report  
*Zavrtanik H, Luzar B, Tomažič A*

**LETTER TO THE EDITOR**

- 8054** Commentary on "Primary orbital monophasic synovial sarcoma with calcification: A case report"  
*Tokur O, Aydin S, Karavas E*

**ABOUT COVER**

Editorial Board Member of *World Journal of Clinical Cases*, Bennete Aloysius Fernandes, MDS, Professor, Faculty of Dentistry, SEGi University, Kota Damansara 47810, Selangor, Malaysia. drben17@yahoo.com

**AIMS AND SCOPE**

The primary aim of *World Journal of Clinical Cases* (WJCC, *World J Clin Cases*) is to provide scholars and readers from various fields of clinical medicine with a platform to publish high-quality clinical research articles and communicate their research findings online.

WJCC mainly publishes articles reporting research results and findings obtained in the field of clinical medicine and covering a wide range of topics, including case control studies, retrospective cohort studies, retrospective studies, clinical trials studies, observational studies, prospective studies, randomized controlled trials, randomized clinical trials, systematic reviews, meta-analysis, and case reports.

**INDEXING/ABSTRACTING**

The WJCC is now abstracted and indexed in Science Citation Index Expanded (SCIE, also known as SciSearch®), Journal Citation Reports/Science Edition, Current Contents®/Clinical Medicine, PubMed, PubMed Central, Scopus, Reference Citation Analysis, China National Knowledge Infrastructure, China Science and Technology Journal Database, and Superstar Journals Database. The 2022 Edition of Journal Citation Reports® cites the 2021 impact factor (IF) for WJCC as 1.534; IF without journal self cites: 1.491; 5-year IF: 1.599; Journal Citation Indicator: 0.28; Ranking: 135 among 172 journals in medicine, general and internal; and Quartile category: Q4. The WJCC's CiteScore for 2021 is 1.2 and Scopus CiteScore rank 2021: General Medicine is 443/826.

**RESPONSIBLE EDITORS FOR THIS ISSUE**

Production Editor: *Xu Guo*; Production Department Director: *Xiang Li*; Editorial Office Director: *Jin-Lei Wang*.

**NAME OF JOURNAL**

*World Journal of Clinical Cases*

**ISSN**

ISSN 2307-8960 (online)

**LAUNCH DATE**

April 16, 2013

**FREQUENCY**

Thrice Monthly

**EDITORS-IN-CHIEF**

Bao-Gan Peng, Jerzy Tadeusz Chudek, George Kontogeorgos, Maurizio Serati, Ja Hyeon Ku

**EDITORIAL BOARD MEMBERS**

<https://www.wjgnet.com/2307-8960/editorialboard.htm>

**PUBLICATION DATE**

August 6, 2022

**COPYRIGHT**

© 2022 Baishideng Publishing Group Inc

**INSTRUCTIONS TO AUTHORS**

<https://www.wjgnet.com/bpg/gerinfo/204>

**GUIDELINES FOR ETHICS DOCUMENTS**

<https://www.wjgnet.com/bpg/GerInfo/287>

**GUIDELINES FOR NON-NATIVE SPEAKERS OF ENGLISH**

<https://www.wjgnet.com/bpg/gerinfo/240>

**PUBLICATION ETHICS**

<https://www.wjgnet.com/bpg/GerInfo/288>

**PUBLICATION MISCONDUCT**

<https://www.wjgnet.com/bpg/gerinfo/208>

**ARTICLE PROCESSING CHARGE**

<https://www.wjgnet.com/bpg/gerinfo/242>

**STEPS FOR SUBMITTING MANUSCRIPTS**

<https://www.wjgnet.com/bpg/GerInfo/239>

**ONLINE SUBMISSION**

<https://www.f6publishing.com>



## Percutaneous transforaminal endoscopic decompression combined with percutaneous vertebroplasty in treatment of lumbar vertebral body metastases: A case report

Qiang Ran, Tong Li, Zhi-Ping Kuang, Xiao-Hong Guo

**Specialty type:** Medicine, research and experimental

**Provenance and peer review:** Unsolicited article; Externally peer reviewed.

**Peer-review model:** Single blind

**Peer-review report's scientific quality classification**

Grade A (Excellent): 0  
Grade B (Very good): B  
Grade C (Good): C  
Grade D (Fair): 0  
Grade E (Poor): 0

**P-Reviewer:** Anazawa U, Japan;  
Naem AA, Syria

**Received:** November 22, 2021

**Peer-review started:** November 22, 2021

**First decision:** May 11, 2022

**Revised:** May 19, 2022

**Accepted:** June 21, 2022

**Article in press:** June 21, 2022

**Published online:** August 6, 2022



**Qiang Ran**, Department of Orthopaedics, Chongqing Hospital of Traditional Chinese Medicine, Chongqing 400010, China,

**Qiang Ran, Tong Li**, Hospital of Chengdu University of Traditional Chinese Medicine, Chengdu 610000, Sichuan Province, China

**Zhi-Ping Kuang**, Department of Orthopaedics, Chongqing Hospital of Traditional Chinese Medicine, Chongqing 400000, China

**Xiao-Hong Guo**, Department of Pharmacy, Chongqing Hospital of Traditional Chinese Medicine, Chongqing 400000, China

**Corresponding author:** Xiao-Hong Guo, PhD, Pharmacist, Department of Pharmacy, Chongqing Hospital of Traditional Chinese Medicine, No. 6 Panxi Seventh Branch Road, Jiangbei District, Chongqing 400000, China. [ranqiang129600@163.com](mailto:ranqiang129600@163.com)

### Abstract

#### BACKGROUND

Percutaneous endoscopic lumbar discectomy (PTED) is a procedure that is commonly used to treat lumbar disc herniation and spinal stenosis. Despite its less invasiveness, this surgery is rarely used to treat spinal metastases. Percutaneous vertebroplasty (PVP) has been utilized to treat lumbar vertebral body metastases but it has not proven useful in treating sciatic patients.

#### CASE SUMMARY

A 68-year-old woman presented with low back pain and radicular symptoms. She couldn't straighten her legs because of severe pain. Computed tomography (CT) showed a mass lesion in the lung and bone destruction in the L4 vertebrae. The biopsy of the lung lesion revealed adenocarcinoma and the biopsy for L4 vertebrae revealed metastatic adenocarcinoma. PTED paired with PVP was performed on the patient due to the patient's poor overall physical state and short survival time. Transcatheter arterial embolization of vertebral tumors was performed before surgical resection to reduce excessive blood loss during the operation. The incision was scaled up with the TESSY technology. The pain was obviously relieved following the operation and no serious complications occurred. Postoperative CT showed that the decompression around the nerve root was successful, polymethyl methacrylate filling was satisfactory and the tumor

tissue around the nerve root was obviously removed. During the 1-year follow-up period, the patient was in a stable condition.

### CONCLUSION

PTED in combination with PVP is an effective and safe treatment for Lumbar single-level Spinal Column metastases with radicular symptoms. Because of the small sample size and short follow-up time, the long-term clinical efficacy of this method needs to be further confirmed.

**Key Words:** Minimally invasive surgery; Nerve root; Percutaneous; Spinal metastases; Transforaminal endoscopic decompression; Case report

©The Author(s) 2022. Published by Baishideng Publishing Group Inc. All rights reserved.

**Core Tip:** Spinal metastatic tumor is a common clinical disease. Because of the poor general condition of patients, minimally invasive treatment is widely used. We present a case of metastatic adenocarcinoma in the L4 vertebrae treated with percutaneous endoscopic lumbar discectomy (PTED) combined with percutaneous vertebroplasty (PVP), with transcatheter arterial embolization of vertebral tumors performed before surgical resection. The therapeutic results were satisfactory. PTED combined with PVP is a safe and effective method for treating Lumbar single-level Spinal Column metastases with radicular symptoms.

**Citation:** Ran Q, Li T, Kuang ZP, Guo XH. Percutaneous transforaminal endoscopic decompression combined with percutaneous vertebroplasty in treatment of lumbar vertebral body metastases: A case report. *World J Clin Cases* 2022; 10(22): 7944-7949

**URL:** <https://www.wjgnet.com/2307-8960/full/v10/i22/7944.htm>

**DOI:** <https://dx.doi.org/10.12998/wjcc.v10.i22.7944>

## INTRODUCTION

As the number of cancer cases increases, the incidence of spinal metastases also increases year by year. Patients suffer from severe low back pain and lower extremity radiating pain due to metastases in the vertebral body[1,2]. Some patients with single vertebral metastases can be treated with open surgery in addition to total bed immobilization and symptomatic pain management. Percutaneous vertebroplasty (PVP) has been widely used in patients who suffer from pain without spinal cord compression and radicular symptoms[3-5]. Percutaneous Transforaminal Endoscopic Decompression (PTED) is rarely reported to be used in spinal metastatic disease. In this report, we introduced and described the surgical technique using PTED combined with PVP in lumbar vertebral body metastases[6,7].

## CASE PRESENTATION

### Chief complaints

A 68-year-old woman with low back pain and radicular symptoms was unable to straighten her leg due to severe pain.

### History of present illness

Low back pain and radicular symptoms first appeared 2 wk ago. The Lumbar computed tomography (CT) scan showed a mass lesion in the lung. Lumbar CT and magnetic resonance imaging (MRI) showed metastases in the lumbar vertebral body. The severe radicular symptom could not be relieved by painkillers. Furthermore, this patient could not receive an invasive surgery due to poor general conditions.

### History of past illness

Previous medical history revealed no significant illnesses.

### Personal and family history

Previous medical history revealed no significant illnesses.



### **Physical examination**

Low back tenderness, percussion pain and the straight leg raising test all yielded positive results.

### **Laboratory examinations**

According to cell blood count results, the white blood cell count was increased ( $10.8 \times 10^9/L$ ) and the hemoglobin level was 157 g/L.

### **Imaging examinations**

Lumbar CT and MRI showed bone destruction in the L4 vertebrae. MRI revealed that the tumor had invaded the L4 vertebral body and was compressing the nerve root (Figure 1).

### **Further diagnostic work-up**

Biopsy and histopathological examination of the L4 vertebrae revealed metastatic adenocarcinoma which probably originated from the lung (Figure 2).

---

## **FINAL DIAGNOSIS**

---

The diagnosis of the presented case was lung cancer with lumbar vertebrae metastasis.

---

## **TREATMENT**

---

Given the patient's poor general physical condition, a minimally invasive technique was chosen after a multidisciplinary medical staff discussion. The operation plan was PTED combined with PVP under local anesthesia. Transcatheter arterial embolization of vertebral tumors was performed before surgical resection in order to minimize excessive blood loss during the operation (Figure 3A). PVP and PTED were conducted prone on a radiolucent table under local anesthetic. PVP was conducted on both sides of the vertebral body using standard procedures. Because there was no cement leakage, it was confirmed that the patient's radicular symptoms did not worsen after the treatment. The point of entry was 8 cm from the midline. TESSY technology was used to scale up the incision and no obvious bleeding occurred. Endoscopy could observe pathologic fracture fragments and tumor tissue at the rear of the intervertebral space. The tumor invaded the posterior border of the L4 vertebrae and paravertebral tissue compressing the L4 nerve root. The tissues compressing the nerve root were removed carefully with endoscopic forceps and bleeding was coagulated by radiofrequency electrode (Figure 3B).

---

## **OUTCOME AND FOLLOW-UP**

---

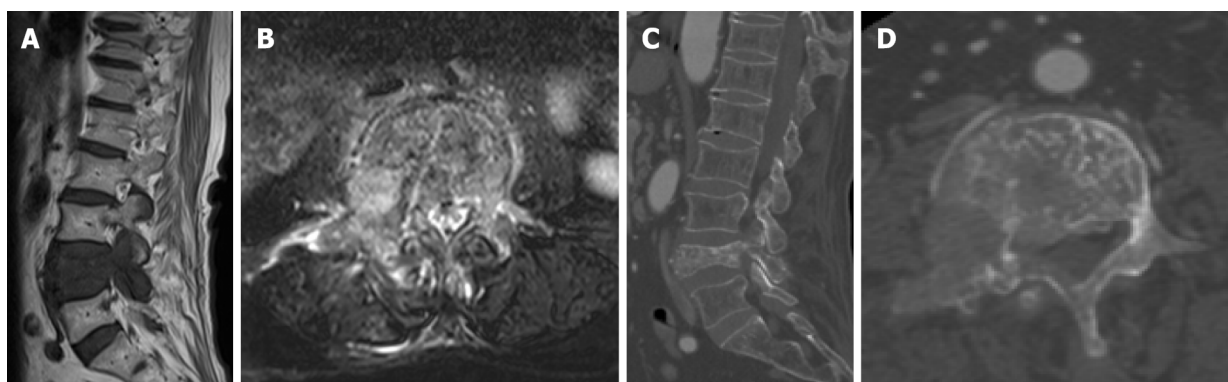
We have completed sufficient decompression of the intervertebral foramen, partial resection of the vertebral body and pedicle of the vertebral arch and exposure of polymethyl methacrylate injected into the vertebral body (Figure 4). The patient's low back pain and radicular symptoms were clearly relieved after the operation. Postoperative CT showed that the decompression around the nerve root was successful. During the 1-year follow-up period, the patient was in a stable condition.

---

## **DISCUSSION**

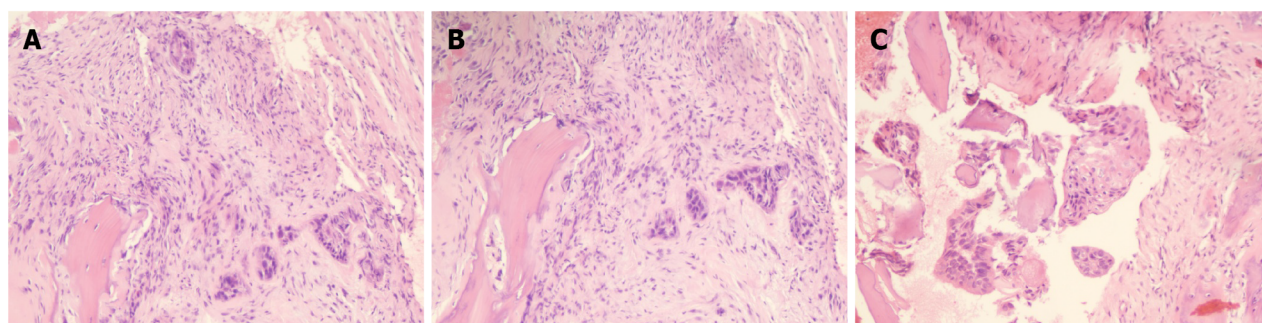
---

The vertebral body is the most common site among bone metastases accounting for 5.00%-10.00% of patients with malignant tumors[8]. Spinal metastases often present as lesions, site pain and limited mobility[9]. Further progression to spinal canal metastases might result in myeloid or radicular symptoms in some patients. The current treatment options include radiotherapy, chemotherapy and surgery with radiotherapy being the first choice for the majority of patients with spinal metastases[8]. Most patients and their families are hesitant to accept traditional surgical treatment due to the short survival time. In recent years, with the development and maturity of minimally invasive techniques, PVP and PTED have been gradually applied in treating vertebral column metastases[10]. However, PVP is ineffective in treating sciatica patients and decompression of the compressed nerve root is required [11]. In order to remove the tumor thoroughly and reconstruct the stability of the column, total spinal resection should be performed under the condition of ensuring the safety of the spinal cord. In this case, these two procedures were operated alternately. The criterion of complete decompression was that the nerve root could move freely with the changes in irrigation pressure.



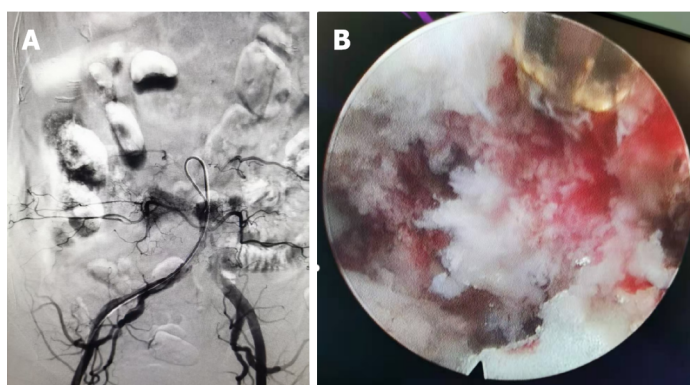
DOI: 10.12998/wjcc.v10.i22.7944 Copyright ©The Author(s) 2022.

**Figure 1 Computed tomography and magnetic resonance imaging.** A: Sagittal position lumbar magnetic resonance imaging (MRI) showed a huge metastatic mass destroying L4 vertebral body and pedicle and compressing the nerve root; B: Cross-sectional lumbar MRI showed vertebral body and pedicle were damaged; C: L4 vertebral body and pedicle pathological fractured; D: L4 vertebral body and pedicle were damaged.



DOI: 10.12998/wjcc.v10.i22.7944 Copyright ©The Author(s) 2022.

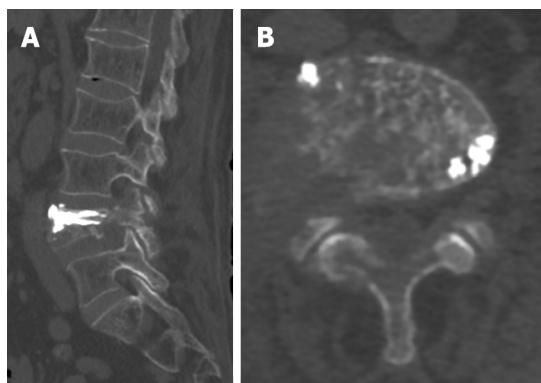
**Figure 2 Histopathological examination.** A: Hematoxylin-eosin stained L4 vertebral body biopsy (200 × magnification) showed metastatic adenocarcinoma; B: Hematoxylin-eosin stained L4 vertebral body biopsy (200 × magnification) showed metastatic adenocarcinoma; C: Hematoxylin-eosin stained L4 vertebral body biopsy (400 × magnification) showed metastatic adenocarcinoma.



DOI: 10.12998/wjcc.v10.i22.7944 Copyright ©The Author(s) 2022.

**Figure 3 Intraoperative imaging.** A: Preoperative angiography showed that L4 vertebral bodies were abundant and selective arterial embolization was performed; B: The image illustrated sufficient decompression of intervertebral foramen, partial resection of vertebral body and pedicle of vertebral arch, and exposure of polymethyl methacrylate injected into vertebral body.

Palliative decompression, intralesional resection or marginal resection of the tumor are ineffective when the vertebral body, appendages or the entire column are involved. Compared with traditional open surgery, PTED has the following advantages: (1) The survival time for patients with metastatic tumors in the column is short and their general physical condition is poor. The combined minimally invasive technique is safe and effective so it is easy to be accepted by patients and their families; (2) The symptoms of nerve root compression can be relieved with less trauma, bleeding and operation time; (3)



DOI: 10.12998/wjcc.v10.i22.7944 Copyright ©The Author(s) 2022.

**Figure 4 Postoperative computed tomography.** A: Lumbar computed tomography showed that the decompression around the nerve root was successful, the percutaneous vertebroplasty filling was satisfactory; B: The tumor tissue around the nerve root was obviously removed.

It has a significant impact on vertebral body stability. The incidence of wound infection and complications (*e.g.*, thrombus, infection caused by post-operative incapacitation) were reduced; and (4) This technique will not cause severe damage to the column's normal bone and soft tissue structure while removing the tumor. The pain caused by internal fixation can be relieved.

Because the tumor invaded the nerve root, causing accumulated necrotic bone tissue and crucial adhesion in the nerve root, partial nerve root decompression occurred. Meanwhile, the nerve might be drawn at the same time, resulting in nerve root injury. Even a tiny amount of blood oozing might easily cause an unclear view in the surgical field due to the invaded tumor tissue. In this case, the nerve root could not be completely separated from the surrounding tissue and easily recognized. Because of the complicated anatomic structure and abundant blood supply, the tumors in the vertebral body are often accompanied by unclear views in the surgical field, difficulties in separating surrounding tissue, a large amount of bleeding and a long operation time. Before surgery, arterial embolization can drastically limit the tumor's blood supply, reduce blood loss during the operation, allow for complete resection of the tumor, and increase the operation's success rate. Recent research and advances in technique have reported that preoperative embolization is a safe and effective method of decreasing intraoperative blood loss[12]. However, the authors consider that this procedure is unsuitable for patients with multiple segmental metastases or tumor's that are spinal canal space-occupying[13].

## CONCLUSION

PTED combined with PVP is a safe and effective method for treating Lumbar single-level Spinal Column metastases with radicular symptoms. Because of the small sample size and short follow-up time, the long-term clinical efficacy of this method needs to be further confirmed.

## FOOTNOTES

**Author contributions:** Ran Q conceived the central idea, analyzed clinical data and wrote the initial draft; All authors participated in clinical diagnosis and revised the manuscript.

**Informed consent statement:** All study participants or their legal guardian provided informed written consent about personal and medical data collection prior to study enrolment.

**Conflict-of-interest statement:** All the authors report no relevant conflicts of interest for this article.

**CARE Checklist (2016) statement:** The authors have read the CARE Checklist (2016), and the manuscript was prepared and revised according to the CARE Checklist (2016).

**Open-Access:** This article is an open-access article that was selected by an in-house editor and fully peer-reviewed by external reviewers. It is distributed in accordance with the Creative Commons Attribution NonCommercial (CC BY-NC 4.0) license, which permits others to distribute, remix, adapt, build upon this work non-commercially, and license their derivative works on different terms, provided the original work is properly cited and the use is non-commercial. See: <https://creativecommons.org/licenses/by-nc/4.0/>

**Country/Territory of origin:** China

**ORCID number:** Qiang Ran 0000-0002-4535-0229; Tong Li 0000-0002-6997-7499; Zhi-Ping Kuang 0000-0001-5006-3526; Xiao-Hong Guo 0000-0001-8232-8330.

**S-Editor:** Fan JR

**L-Editor:** Filipodia

**P-Editor:** Fan JR

## REFERENCES

- 1 **Hariri O**, Takayanagi A, Miulli DE, Siddiqi J, Vriens F. Minimally Invasive Surgical Techniques for Management of Painful Metastatic and Primary Spinal Tumors. *Cureus* 2017; **9**: e1114 [PMID: 28446993 DOI: 10.7759/cureus.1114]
- 2 **Pennington Z**, Ahmed AK, Molina CA, Ehresman J, Laufer I, Sciubba DM. Minimally invasive vs conventional spine surgery for vertebral metastases: a systematic review of the evidence. *Ann Transl Med* 2018; **6**: 103 [PMID: 29707552 DOI: 10.21037/atm.2018.01.28]
- 3 **Chen C**, Li D, Wang Z, Li T, Liu X, Zhong J. Safety and Efficacy Studies of Vertebroplasty, Kyphoplasty, and Mesh-Container-Plasty for the Treatment of Vertebral Compression Fractures: Preliminary Report. *PLoS One* 2016; **11**: e0151492 [PMID: 26963808 DOI: 10.1371/journal.pone.0151492]
- 4 **Tian QH**, Sun XQ, Lu YY, Wang T, Wu CG, Li MH, Cheng YS. Percutaneous Vertebroplasty for Palliative Treatment of Painful Osteoblastic Spinal Metastases: A Single-Center Experience. *J Vasc Interv Radiol* 2016; **27**: 1420-1424 [PMID: 27397620 DOI: 10.1016/j.jvir.2016.04.033]
- 5 **Zhang JJ**, Zhou Y, Hu HY, Sun YJ, Wang YG, Gu YF, Wu CG, Shen Z, Yao Y. Safety and efficacy of multilevel vertebroplasty for painful osteolytic spinal metastases: a single-centre experience. *Eur Radiol* 2017; **27**: 3436-3442 [PMID: 27975147 DOI: 10.1007/s00330-016-4683-x]
- 6 **Wang FA**, He SC, Xiao EH, Wang SX, Sun L, Lv PH, Huang WN. Sequential Transarterial Embolization Followed by Percutaneous Vertebroplasty Is Safe and Effective in Pain Management in Vertebral Metastases. *Pain Physician* 2016; **19**: E559-E567 [PMID: 27228522]
- 7 **Gao Z**, Wu Z, Lin Y, Zhang P. Percutaneous transforaminal endoscopic decompression in the treatment of spinal metastases: A case report. *Medicine (Baltimore)* 2019; **98**: e14819 [PMID: 30882663 DOI: 10.1097/MD.00000000000014819]
- 8 **Miscusi M**, Polli FM, Forcato S, Ricciardi L, Frati A, Cimatti M, De Martino L, Ramieri A, Raco A. Comparison of minimally invasive surgery with standard open surgery for vertebral thoracic metastases causing acute myelopathy in patients with short- or mid-term life expectancy: surgical technique and early clinical results. *J Neurosurg Spine* 2015; **22**: 518-525 [PMID: 25723122 DOI: 10.3171/2014.10.SPINE131201]
- 9 **Verlaan JJ**, Choi D, Versteeg A, Albert T, Arts M, Balabaud L, Bunger C, Buchowski JM, Chung CK, Coppes MH, Crockard HA, Depreitere B, Fehlings MG, Harrop J, Kawahara N, Kim ES, Lee CS, Leung Y, Liu Z, Martin-Benloch A, Massicotte EM, Mazel C, Meyer B, Peul W, Quraishi NA, Tokuhashi Y, Tomita K, Ulbricht C, Wang M, Oner FC. Characteristics of Patients Who Survived < 3 Months or > 2 Years After Surgery for Spinal Metastases: Can We Avoid Inappropriate Patient Selection? *J Clin Oncol* 2016; **34**: 3054-3061 [PMID: 27400936 DOI: 10.1200/JCO.2015.65.1497]
- 10 **Uei H**, Tokuhashi Y, Maseda M, Nakahashi M, Sawada H, Nakayama E, Soma H. Comparison between minimally invasive spine stabilization with and without posterior decompression for the management of spinal metastases: a retrospective cohort study. *J Orthop Surg Res* 2018; **13**: 87 [PMID: 29661205 DOI: 10.1186/s13018-018-0777-2]
- 11 **Mansoorinasab M**, Abdolhoseinpour H. A review and update of vertebral fractures due to metastatic tumors of various sites to the spine: Percutaneous vertebroplasty. *Interv Med Appl Sci* 2018; **10**: 1-6 [PMID: 30363329 DOI: 10.1556/1646.10.2018.03]
- 12 **Ma J**, Tullius T, Van Ha TG. Update on Preoperative Embolization of Bone Metastases. *Semin Intervent Radiol* 2019; **36**: 241-248 [PMID: 31435132 DOI: 10.1055/s-0039-1693120]
- 13 **Uei H**, Tokuhashi Y, Oshima M, Maseda M, Matsumoto K, Soma H, Nakayama E, Tachikawa Y. Clinical Results of Minimally Invasive Spine Stabilization for Spinal Metastases. *Orthopedics* 2017; **40**: e693-e698 [PMID: 28558111 DOI: 10.3928/01477447-20170522-02]



Published by **Baishideng Publishing Group Inc**  
7041 Koll Center Parkway, Suite 160, Pleasanton, CA 94566, USA

**Telephone:** +1-925-3991568

**E-mail:** [bpgoffice@wjgnet.com](mailto:bpgoffice@wjgnet.com)

**Help Desk:** <https://www.f6publishing.com/helpdesk>

<https://www.wjgnet.com>

