

# World Journal of *Clinical Cases*

*World J Clin Cases* 2022 August 16; 10(23): 8057-8431



## Contents

Thrice Monthly Volume 10 Number 23 August 16, 2022

## OPINION REVIEW

- 8057** Invasive intervention timing for infected necrotizing pancreatitis: Late invasive intervention is not late for collection

*Xiao NJ, Cui TT, Liu F, Li W*

- 8063** Clinical utility of left atrial strain in predicting atrial fibrillation recurrence after catheter ablation: An up-to-date review

*Yu ZX, Yang W, Yin WS, Peng KX, Pan YL, Chen WW, Du BB, He YQ, Yang P*

## MINIREVIEWS

- 8076** Gut microbiota and COVID-19: An intriguing pediatric perspective

*Valentino MS, Esposito C, Colosimo S, Caprio AM, Puzone S, Guarino S, Marzuillo P, Miraglia del Giudice E, Di Sessa A*

- 8088** Beta receptor blocker therapy for the elderly in the COVID-19 era

*Santillo E, Migale M*

## ORIGINAL ARTICLE

## Retrospective Cohort Study

- 8097** Nonselective beta-blocker use is associated with increased hepatic encephalopathy-related readmissions in cirrhosis

*Fallahzadeh MA, Asrani SK, Tapper EB, Saracino G, Rahimi RS*

## Retrospective Study

- 8107** Different squatting positions after total knee arthroplasty: A retrospective study

*Li TJ, Sun JY, Du YQ, Shen JM, Zhang BH, Zhou YG*

- 8115** Outcomes of seromuscular bladder augmentation compared with standard bladder augmentation in the treatment of children with neurogenic bladder

*Sun XG, Li YX, Ji LF, Xu JL, Chen WX, Wang RY*

- 8124** Distinctive clinical features of spontaneous pneumoperitoneum in neonates: A retrospective analysis

*Kim SH, Cho YH, Kim HY*

- 8133** Cognitive training for elderly patients with early Alzheimer's disease in the Qinghai-Tibet Plateau: A pilot study

*Wang XH, Luo MQ*

- 8141** Diagnostic value of elevated serum carbohydrate antigen 125 level in sarcoidosis

*Zhang Q, Jing XY, Yang XY, Xu ZJ*

- 8152** Evaluation of progressive early rehabilitation training mode in intensive care unit patients with mechanical ventilation

*Qie XJ, Liu ZH, Guo LM*

- 8161** Comparison of demographic features and laboratory parameters between COVID-19 deceased patients and surviving severe and critically ill cases

*Wang L, Gao Y, Zhang ZJ, Pan CK, Wang Y, Zhu YC, Qi YP, Xie FJ, Du X, Li NN, Chen PF, Yue CS, Wu JH, Wang XT, Tang YJ, Lai QQ, Kang K*

### Clinical Trials Study

- 8170** Role of H<sub>2</sub>receptor blocker famotidine over the clinical recovery of COVID-19 patients: A randomized controlled trial

*Mohiuddin Chowdhury ATM, Kamal A, Abbas MKU, Karim MR, Ali MA, Talukder S, Hamidullah Mehedi H, Hassan H, Shahin AH, Li Y, He S*

### Observational Study

- 8186** Short-term prognostic factors for hepatitis B virus-related acute-on-chronic liver failure

*Ye QX, Huang JF, Xu ZJ, Yan YY, Yan Y, Liu LG*

- 8196** Three-dimensional psychological guidance combined with evidence-based health intervention in patients with liver abscess treated with ultrasound

*Shan YN, Yu Y, Zhao YH, Tang LL, Chen XM*

- 8205** Role of serum  $\beta$ 2-microglobulin, glycosylated hemoglobin, and vascular endothelial growth factor levels in diabetic nephropathy

*Yang B, Zhao XH, Ma GB*

### SYSTEMATIC REVIEWS

- 8212** Gallbladder neuroendocrine carcinoma diagnosis, treatment and prognosis based on the SEER database: A literature review

*Cai XC, Wu SD*

### CASE REPORT

- 8224** Sepsis complicated with secondary hemophagocytic syndrome induced by giant gouty tophi rupture: A case report

*Lai B, Pang ZH*

- 8232** Spontaneous remission of autoimmune pancreatitis: Four case reports

*Zhang BB, Huo JW, Yang ZH, Wang ZC, Jin EH*

- 8242** Epstein-Barr-virus-associated hepatitis with aplastic anemia: A case report

*Zhang WJ, Wu LQ, Wang J, Lin SY, Wang B*

- 8249** Aspiration as the first-choice procedure for airway management in an infant with large epiglottic cysts: A case report

*Zheng JQ, Du L, Zhang WY*

- 8255** Sequential multidisciplinary minimally invasive therapeutic strategy for heart failure caused by four diseases: A case report  
*Zhao CZ, Yan Y, Cui Y, Zhu N, Ding XY*
- 8262** Primary ascending colon cancer accompanying skip metastases in left shoulder skin and left neck lymph node: A case report  
*Zhou JC, Wang JJ, Liu T, Tong Q, Fang YJ, Wu ZQ, Hong Q*
- 8271** Clinical and genetic study of ataxia with vitamin E deficiency: A case report  
*Zhang LW, Liu B, Peng DT*
- 8277** Complete resection of large-cell neuroendocrine and hepatocellular carcinoma of the liver: A case report  
*Noh BG, Seo HI, Park YM, Kim S, Hong SB, Lee SJ*
- 8284** Immunotherapy combined with antiangiogenic agents in patients with advanced malignant pleural mesothelioma: A case report  
*Xuan TT, Li GY, Meng SB, Wang ZM, Qu LL*
- 8291** Bladder malacoplakia: A case report  
*Wang HK, Hang G, Wang YY, Wen Q, Chen B*
- 8298** Delayed inflammatory response evoked in nasal alloplastic implants after COVID-19 vaccination: A case report  
*Seo MG, Choi EK, Chung KJ*
- 8304** Phosphoglyceride crystal deposition disease requiring differential diagnosis from malignant tumors and confirmed by Raman spectroscopy: A case report  
*Ohkura Y, Uruga H, Shiiba M, Ito S, Shimoyama H, Ishihara M, Ueno M, Udagawa H*
- 8312** Vulvovaginal myeloid sarcoma with massive pelvic floor infiltration: A case report and review of literature  
*Wang JX, Zhang H, Ning G, Bao L*
- 8323** Femoral neck stress fracture and medial tibial stress syndrome following high intensity interval training: A case report and review of literature  
*Tan DS, Cheung FM, Ng D, Cheung TLA*
- 8330** Periosteal chondroma of the rib: A case report  
*Gao Y, Wang JG, Liu H, Gao CP*
- 8336** Papillary thyroid carcinoma occurring with undifferentiated pleomorphic sarcoma: A case report  
*Lee YL, Cheng YQ, Zhu CF, Huo HZ*
- 8344** Laparoscopic treatment of bilateral duplex kidney and ectopic ureter: A case report  
*Wang SB, Wan L, Wang Y, Yi ZJ, Xiao C, Cao JZ, Liu XY, Tang RP, Luo Y*
- 8352** Incontinentia pigmenti with intracranial arachnoid cyst: A case report  
*Li WC, Li ML, Ding JW, Wang L, Wang SR, Wang YY, Xiao LF, Sun T*



- 8360** Relapsing polychondritis causing breathlessness: Two case reports  
*Zhai SY, Zhang YH, Guo RY, Hao JW, Wen SX*
- 8367** Endodontic management of a fused left maxillary second molar and two paramolars using cone beam computed tomography: A case report  
*Mei XH, Liu J, Wang W, Zhang QX, Hong T, Bai SZ, Cheng XG, Tian Y, Jiang WK*
- 8375** Infant biliary cirrhosis secondary to a biliary inflammatory myofibroblastic tumor: A case report and review of literature  
*Huang Y, Shu SN, Zhou H, Liu LL, Fang F*
- 8384** Metastatic low-grade endometrial stromal sarcoma with variable morphologies in the ovaries and mesentery: A case report  
*Yu HY, Jin YL*
- 8392** Bronchogenic cysts with infection in the chest wall skin of a 64-year-old asymptomatic patient: A case report  
*Ma B, Fu KW, Xie XD, Cheng Y, Wang SQ*
- 8400** Incidental accumulation of Technetium-99m pertechnetate in subacute cerebral infarction: A case report  
*Han YH, Jeong HJ, Kang HG, Lim ST*
- 8406** Metal stent combined with ileus drainage tube for the treatment of delayed rectal perforation: A case report  
*Cheng SL, Xie L, Wu HW, Zhang XF, Lou LL, Shen HZ*
- 8417** Using ketamine in a patient with a near-occlusion tracheal tumor undergoing tracheal resection and reconstruction: A case report  
*Xu XH, Gao H, Chen XM, Ma HB, Huang YG*

**LETTER TO THE EDITOR**

- 8422** Reflections on the prevalence of human leukocyte antigen-B27 and human leukocyte antigen-B51 co-occurrence in patients with spondylarthritis  
*Gonçalves Júnior J, Sampaio-Barros PD, Shinjo SK*
- 8425** Comment on "Disease exacerbation is common in inflammatory bowel disease patients treated with immune checkpoint inhibitors for malignancy"  
*Argyriou K, Kotsakis A*
- 8428** Intranasal sufentanil combined with intranasal dexmedetomidine: A promising method for non-anesthesiologist sedation during endoscopic ultrasonography  
*Wang Y, Ge ZJ, Han C*

**ABOUT COVER**

Editorial Board Member of *World Journal of Clinical Cases*, Peng Liang, MD, Associate Professor, Day Surgery Center, Department of Anesthesiology, West China Hospital of Sichuan University, Chengdu 610041, Sichuan Province, China. 39485572@qq.com

**AIMS AND SCOPE**

The primary aim of *World Journal of Clinical Cases* (WJCC, *World J Clin Cases*) is to provide scholars and readers from various fields of clinical medicine with a platform to publish high-quality clinical research articles and communicate their research findings online.

WJCC mainly publishes articles reporting research results and findings obtained in the field of clinical medicine and covering a wide range of topics, including case control studies, retrospective cohort studies, retrospective studies, clinical trials studies, observational studies, prospective studies, randomized controlled trials, randomized clinical trials, systematic reviews, meta-analysis, and case reports.

**INDEXING/ABSTRACTING**

The WJCC is now abstracted and indexed in Science Citation Index Expanded (SCIE, also known as SciSearch®), Journal Citation Reports/Science Edition, Current Contents®/Clinical Medicine, PubMed, PubMed Central, Scopus, Reference Citation Analysis, China National Knowledge Infrastructure, China Science and Technology Journal Database, and Superstar Journals Database. The 2022 Edition of Journal Citation Reports® cites the 2021 impact factor (IF) for WJCC as 1.534; IF without journal self cites: 1.491; 5-year IF: 1.599; Journal Citation Indicator: 0.28; Ranking: 135 among 172 journals in medicine, general and internal; and Quartile category: Q4. The WJCC's CiteScore for 2021 is 1.2 and Scopus CiteScore rank 2021: General Medicine is 443/826.

**RESPONSIBLE EDITORS FOR THIS ISSUE**

Production Editor: Hua-Ge Yin; Production Department Director: Xiang Li; Editorial Office Director: Jin-Lei Wang.

**NAME OF JOURNAL**

*World Journal of Clinical Cases*

**ISSN**

ISSN 2307-8960 (online)

**LAUNCH DATE**

April 16, 2013

**FREQUENCY**

Thrice Monthly

**EDITORS-IN-CHIEF**

Bao-Gan Peng, Jerzy Tadeusz Chudek, George Kontogeorgos, Maurizio Serati, Ja Hyeon Ku

**EDITORIAL BOARD MEMBERS**

<https://www.wjnet.com/2307-8960/editorialboard.htm>

**PUBLICATION DATE**

August 16, 2022

**COPYRIGHT**

© 2022 Baishideng Publishing Group Inc

**INSTRUCTIONS TO AUTHORS**

<https://www.wjnet.com/bpg/gerinfo/204>

**GUIDELINES FOR ETHICS DOCUMENTS**

<https://www.wjnet.com/bpg/GerInfo/287>

**GUIDELINES FOR NON-NATIVE SPEAKERS OF ENGLISH**

<https://www.wjnet.com/bpg/gerinfo/240>

**PUBLICATION ETHICS**

<https://www.wjnet.com/bpg/GerInfo/288>

**PUBLICATION MISCONDUCT**

<https://www.wjnet.com/bpg/gerinfo/208>

**ARTICLE PROCESSING CHARGE**

<https://www.wjnet.com/bpg/gerinfo/242>

**STEPS FOR SUBMITTING MANUSCRIPTS**

<https://www.wjnet.com/bpg/GerInfo/239>

**ONLINE SUBMISSION**

<https://www.f6publishing.com>

## Bladder malacoplakia: A case report

Hua-Kang Wang, Gai Hang, Yu-Yang Wang, Quan Wen, Bo Chen

**Specialty type:** Urology and nephrology

**Provenance and peer review:** Unsolicited article; Externally peer reviewed.

**Peer-review model:** Single blind

**Peer-review report's scientific quality classification**

Grade A (Excellent): 0  
Grade B (Very good): B  
Grade C (Good): C  
Grade D (Fair): D  
Grade E (Poor): 0

**P-Reviewer:** Park SB, South Korea; Sharaf MM, Syria; Vagholkar K, India

**Received:** January 27, 2022

**Peer-review started:** January 27, 2022

**First decision:** May 11, 2022

**Revised:** May 17, 2022

**Accepted:** July 6, 2022

**Article in press:** July 6, 2022

**Published online:** August 16, 2022



**Hua-Kang Wang, Yu-Yang Wang,** Graduate School, Inner Mongolia Medical University, Hohhot 010000, Inner Mongolia Autonomous Region, China

**Gai Hang, Quan Wen, Bo Chen,** Department of Urinary Surgery, Inner Mongolia Autonomous Region Tongliao City Hospital, Tongliao 028000, Inner Mongolia Autonomous Region, China

**Corresponding author:** Bo Chen, MD, Chief Doctor, Director, Department of Urinary Surgery, Inner Mongolia Autonomous Region Tongliao City Hospital, No. 668 Horqin Street, Horqin District, Tongliao 028000, Inner Mongolia Autonomous Region, China. [chenmuxin@126.com](mailto:chenmuxin@126.com)

### Abstract

#### BACKGROUND

Bladder malacoplakia is a rare chronic granulomatous disease. The most common site of the malacoplakia is the urinary system. The etiology of bladder malacoplakia is complex, with its clinical misdiagnosis rate is high. Therefore, exposure to more clinical cases is necessary to improve the diagnosis and treatment of this condition.

#### CASE SUMMARY

A 65-year-old woman was admitted to our hospital because of dysuria. She presented with dysuria, frequent urination, urgency, pain, and absence of hematuria and pyuria. After the examination, bladder tumor electrocution was performed under combined intravenous and inhalation anesthesia on September 6, 2021. During the operation, electrotomy and electrocoagulation were performed. The operation was then followed by anti-infection treatment, and the patient recovered well. The postoperative pathology was diagnosed as bladder malacoplakia by light and electron microscopic analyses. On a follow-up after 4 mo, no significant difference between electrotomy and electrocoagulation was found, with both achieving a curative effect.

#### CONCLUSION

Diagnosing bladder malacoplakia depends on histopathological examination. Antibiotic treatment with bladder tumor resection or electrocoagulation provides better therapeutic effect.

**Key Words:** Bladder malacoplakia; Michaelis–Gutman bodies; Transurethral resection; Pathology; Case report

©The Author(s) 2022. Published by Baishideng Publishing Group Inc. All rights reserved.

**Core Tip:** Bladder malacoplakia is a rare chronic granulomatous disease. The most common site of the malacoplakia is the urinary system, and the clinical misdiagnosis rate is high. We reported a case of this rare disease and propose our own perspective on the improvement of diagnosis and treatment of bladder malacoplakia.

**Citation:** Wang HK, Hang G, Wang YY, Wen Q, Chen B. Bladder malacoplakia: A case report. *World J Clin Cases* 2022; 10(23): 8291-8297

**URL:** <https://www.wjgnet.com/2307-8960/full/v10/i23/8291.htm>

**DOI:** <https://dx.doi.org/10.12998/wjcc.v10.i23.8291>

## INTRODUCTION

Bladder malacoplakia[1] is a rare chronic granulomatous lesion. The disease was first reported by Michaelis and Gutmann in 1902, and its most common site was the urinary system, followed by the reproductive tract, gastrointestinal tract, and retroperitoneum[2,3]. The etiology of this disease is complex, and its clinical misdiagnosis rate is high. To improve the diagnosis and treatment of bladder malacoplakia, we herein reported the clinical manifestations, pathological characteristics, and follow-up process of the diagnosis and treatment of one case of bladder malacoplakia in our hospital.

## CASE PRESENTATION

### Chief complaints

A 65-year-old woman presented with dysuria for 1 year and increased symptoms for 2 mo.

### History of present illness

The patient had dysuria for 1 year, the symptoms of which had worsened in the 2 mo prior to admission and were characterized by dysuria, frequency, urgency, and absence of hematuria and pyuria.

### History of past illness

The patient had a history of hypertension for 2 years. Approximately 33 years ago, the patient had undergone hysterectomy for uterine fibroids, with the postoperative recovery noted to be good.

### Personal and family history

The patient had no remarkable personal history and no similar family history.

### Physical examination

Physical examination revealed no tenderness in the bilateral rib angles and ureteric regions, as well as no pain upon percussion of the bilateral kidney areas. In addition, there was no bladder fullness, deep tenderness, or rebound pain.

### Laboratory examinations

Blood routine analysis showed a white blood cell (WBC) count of  $6.25 \times 10^9/L$  and neutrophil percentage of 74.5%. Routine urine analysis showed a bacterial count (BAC) of  $1000/\mu L$ , leucocyte 1+, bacteria, high power field [BACT (HP)] of  $297/\mu L$ , and white blood cells, high power field [WBC (HP)] of 19.35/HP. The urine culture result showed that the sample contained *Escherichia coli*.

### Imaging examinations

The urinary ultrasound report showed bladder wall thickening and a bladder residual urine volume of 50 mL. Urinary computerized tomography urography revealed bladder wall thickening and a visible low-density gas shadow in the bladder. Multiple pale yellow cerebral loop-like bulges were observed in the bladder on cystoscopy. Cystoscopy biopsy also showed lesions mainly composed of tissue cells and infiltration of interstitial inflammatory cells.

## FINAL DIAGNOSIS

According to the patient's history and cystoscopy and relevant literature, the preoperative diagnosis was a bladder tumor (bladder malacoplakia was not excluded). Postoperative pathology confirmed that

the final diagnosis was bladder malacoplakia.

## TREATMENT

The patient was treated with quinolone antibiotics and transurethral resection of the bladder tumor. The patient had not been taking cholinergic drugs or vitamin C. Based on the intraoperative findings (Figure 1), there was no hematuria or any abnormality in the bilateral ureteral orifices. Multiple pale yellow brain loop-like uplifts were found in all bladder walls, with a maximum area of 3.0 cm × 2 cm. With a wide base, the surface mucosa of the tumor remained smooth, and no obvious bleeding, necrosis, or calcification was found. Inflammatory follicular hyperplasia was observed in the bladder triangle; there were no occupying lesions. The tumors in each wall of the bladder were removed and deeply cut into the muscular layer (basal part). Some tumors were simply electrocauterized with bladder tumors, and a pathological examination was performed on the tumor body and basal part.

## OUTCOME AND FOLLOW-UP

The pathological results were as follows (the pathological tissue was the body part and the basilar part of the bladder tumor): Microscopically, diffuse infiltration of tissue cells, mild cell morphology, abundant cytoplasm, eosinophilic granular and concentric circular arrangement of basophilic Michaelis-Gutman (M-G) bodies, as well as infiltration of lymphocytes, plasma cells, eosinophils, and neutrophils were observed (Figure 2).

Immunohistochemistry showed the following results: vimentin (+), CKpan (-), CK5/6 (-), GATA3 (-), P63 (-), CK7 (-), CD68 (+), CD163 (+), lysozyme (+), MAC387 (-), S-100 (-), Ki-67 (+2%), EMA (-), and LCA (-) (Figure 3). Periodic acid-Schiff staining of M-G bodies showed a purple red color; calcium staining showed a black color; and iron staining showed a light blue color. Combined with histological changes and medical history, the lesion was considered to be bladder malacoplakia.

Electron microscopy (Figure 4) revealed phagocytic lysosomes and M-G bodies (indicated by the arrow) in the cytoplasm of macrophages, which were generally rounded. A variability of the phagocytic matrix, microbubbles, and an abundance of bacteria were found in phagocytic lysosomes. Some bacteria were digested and dissolved, and medullary structures, such as microcrystals, were observed. The latter was especially found in larger structures with the same matrix composition as phagolysosomes. In some large crystal deposition structures, central cavitation was observed, which constitutes a typical M-G body. This cavitation occurred both intracellularly and extracellularly.

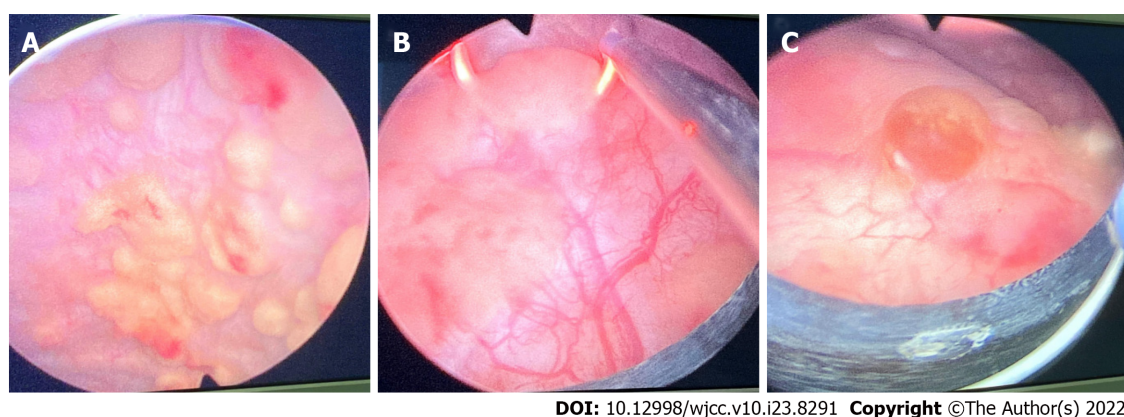
Postoperative anti-infection treatment and an indwelling catheter (7 d) were instituted after recovery. After discharge, the patient continued oral antibiotic treatment and was recommended to undergo routine urine analysis, urine culture, urinary ultrasonography, and cystoscopy every 1-3 mo.

## DISCUSSION

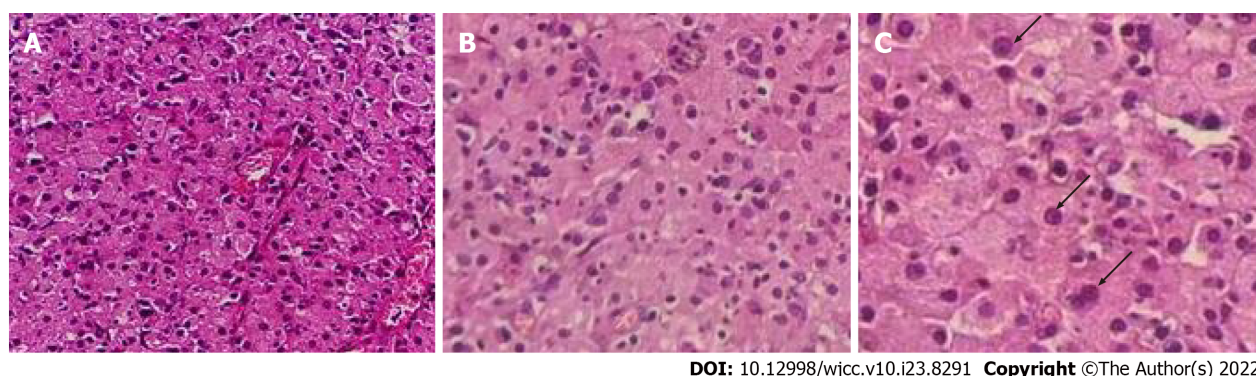
Bladder malacoplakia is an extremely rare disease. There are only 49 reports of 72 cases of bladder malacoplakia in the world from 1986 to 2021. Von Hanseemann officially named this disease bladder malacoplakia in 1903, which initiated understanding and research on this disease. Bladder malacoplakia can occur in both men and women, but it occurs more commonly in the latter, with a male-to-female ratio of about 1:4. Most patients were over 40 years of age, but occasionally children or adolescents were among the reported cases[4]. The incidence of bladder malacoplakia accounts for approximately 40% of malacoplakia cases. In addition to malacoplakia of the bladder, other parts and organs of the genitourinary system may also have malacoplakia. For example, malacoplakia of the kidney accounts for approximately 29% of the incidence of malacoplakia, malacoplakia of the testis accounts for approximately 12%, malacoplakia of the ureter accounts for approximately 11%, malacoplakia of the prostate accounts for approximately 10%, and malacoplakia of the urethra accounts for about 3%[5]. Most patients with bladder malacoplakia suffer from chronic underlying diseases such as diabetes, alcoholic liver disease, post-transplantation, sarcomatosis, urinary tract infection, and hyp immunity or inhibition[6].

The etiology of bladder malacoplakia remains unclear although its pathogenesis has three main hypotheses. First is bacterial infection, especially *Escherichia Coli* infection, which has a long-term and repeated history of chronic urinary tract infection. The local microenvironment of the bladder is suitable for bacterial growth and promotes an inflammatory response in the bladder mucosa[7]. Second, patients having immunosuppressive diseases or long-term chronic diseases, such as HIV infection, tuberculosis, sarcoma, diabetes, and ulcerative colitis[8]. Third, the phagocytosis and digestion functions of macrophages is abnormal, and the macrophages of patients can stretch out pseudopodia to phagocytize bacteria. However, due to the decrease in the microfunction of macrophages, it causes defects in





**Figure 1 Intraoperative findings.** A: Multiple pale yellow brain loop-like uplifts; B: Tumors being electrocuted; C: Proliferation of scattered inflammatory follicles.

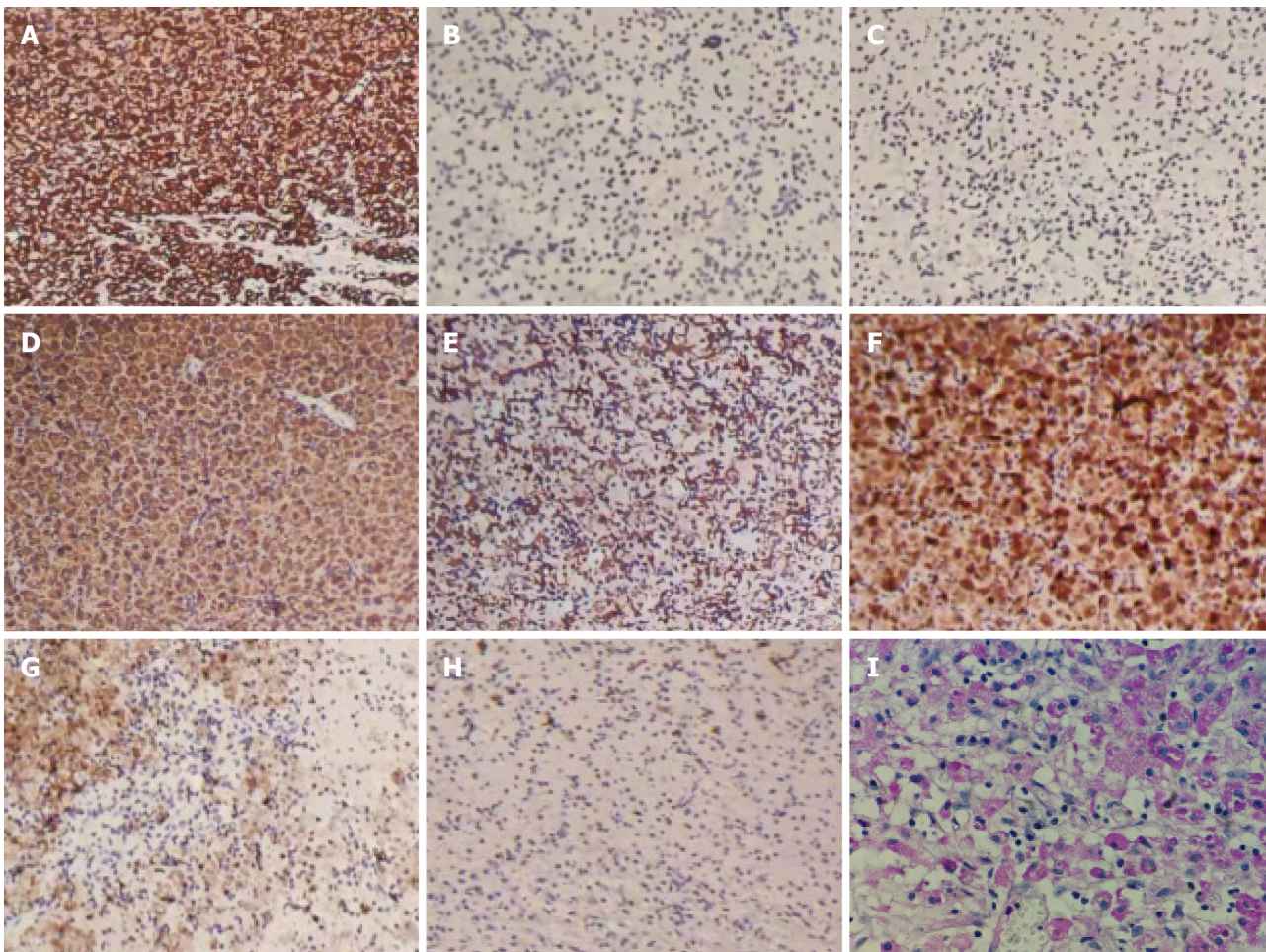


**Figure 2 Microscopic findings.** A: Massive Michaelis-Gutman (M-G) bodies can be seen under microscope (Magnification × 200); B: Alkaline M-G bodies arranged in concentric circles as shown by arrows (Magnification × 400); C: Alkaline M-G bodies arranged in concentric circles as shown by arrows (Magnification × 600).

lysosomes, and thus loses its bactericidal ability[9].

Malacoplakia has nonspecific clinical symptoms, usually for the corresponding organs, as well as leads to long-term, chronic and repeated inflammation. The imaging manifestations of this disease are also nonspecific, and most of the organs develop tumor-like nodules[10]. Currently, its diagnosis relies only on pathological findings. However, due to the small number of biopsy and puncture tissue submissions, typical pathological features are lacking, and its rarity makes it easy to be missed during diagnosis in daily practice. The typical pathological feature of this disease is the formation of the M-G corpuscle. Many macrophages (Von Hansemann cells) were observed under a microscope, accompanied by several lymphocytes and plasma cells. M-G corpuscles are basophilic and can be seen in the interstitium or cytoplasm of macrophages[11]. They are composed of undigested bacterial cells or iron and calcium deposits that are not completely metabolized after bacterial digestion. The organic matter accounts for approximately 95% of the M-G corpuscles, and its diameter is 5–10  $\mu\text{m}$ [12]. A round or irregular ring structure, forming a single body similar to the 'bird eye' is the specific pathological characteristic of the disease and the most reliable pathological basis for clinical diagnosis. Electron microscopy showed that there was a migration phenomenon between intracellular bacteria and M-G bodies, which also proved that M-G bodies were the products of bacterial degeneration and disintegration in lysosomes[13]. However, not every case showed typical pathological changes in the clinic, and typical M-G bodies were not found. This is because bladder malacoplakia showed three stages of pathological changes: (1) Early inflammatory changes, involving chronic inflammatory changes of the bladder mucosa, which was mostly inflammatory cell infiltration; (2) medium-term typical granulomatous changes, involving M-G bodies and macrophages, and occasionally giant cells and lymphocytes; and (3) the healing stage, wherein fibroblasts and collagen cells were gathered around macrophages, and M-G bodies existed simultaneously. In this case, we also observed this phenomenon, although the pathological stages of the patient differed depending on the location. We speculated that bladder malacoplakia may be a type of tissue cell dysfunction disease, and that the three pathological stages of this disease coexist. Therefore, for early chronic inflammatory changes, a regular review is needed to confirm the diagnosis.





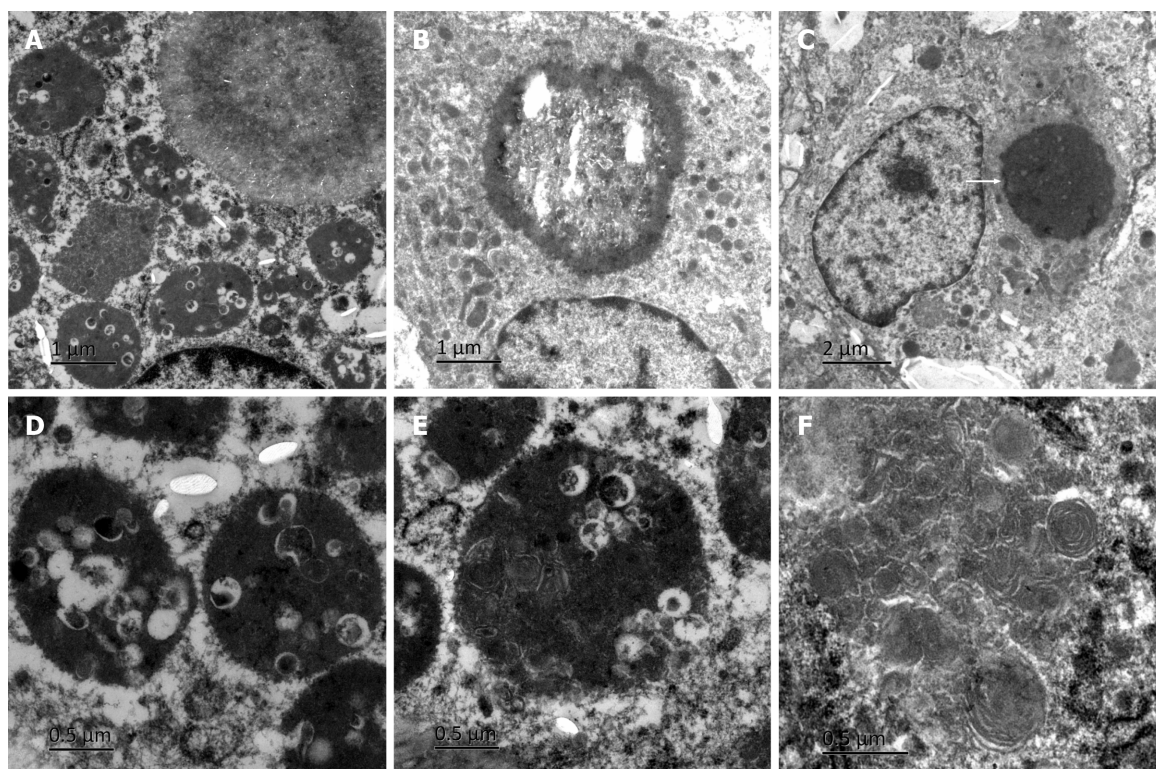
DOI: 10.12998/wjcc.v10.i23.8291 Copyright ©The Author(s) 2022.

**Figure 3 Immunohistochemistry findings.** A: Vimentin (+) (Magnification  $\times 100$ ); B: CKpan (-) (Magnification  $\times 100$ ); C: CK5/6 (-) (Magnification  $\times 100$ ); D: CD68 (+) (Magnification  $\times 100$ ); E: CD163 (+) (Magnification  $\times 100$ ); F: Lysozyme (+) (Magnification  $\times 100$ ); G: MAC387 (-) (Magnification  $\times 100$ ); H: Ki-67 (+2%) (Magnification  $\times 100$ ); I: Michaelis-Gutman body periodic acid-Schiff staining shown in purple red (Magnification  $\times 200$ ).

The diagnosis of the disease is mainly based on foamy eosinophilic tissue cells and basophilic M-G bodies. Differential diagnosis includes other granulomas[14], tuberculosis nodules, and primary and metastatic malignant tumors, although there were no basophilic M-G corpuscles seen in these diseases under the microscope.

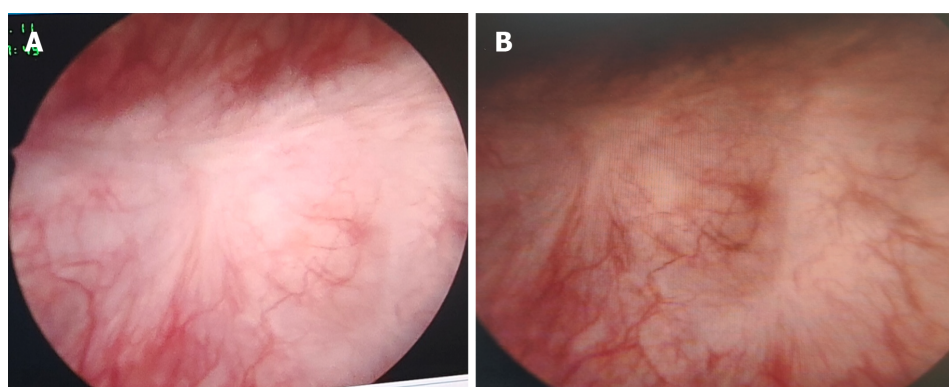
Due to the rarity of this disease, the current treatment employed is empirical in some cases. There is no multicenter randomized controlled evidence-based medical treatment case report, and the treatment mainly focuses on maintaining the sterility of urine. Formal anti-infection treatment of malacoplakia can often control the disease, but as it progresses, surgical treatment remains necessary. The etiology and histopathology of malacoplakia provide a basis for the use of antibiotics in the treatment of this disease. It has been reported that quinolones, sulfamethoxazole, and rifampicin are effective antibiotics for the condition[15,16]. The duration of medication depends on the follow-up results of the disease, and its combination with surgery can shorten the medication time. Recently, cholinergic drugs and vitamin C have been reported to improve the phagocytic function of macrophages and enhance immune efficacy by affecting the state of oxidative stress, as well as by increasing the cGMP/cAMP ratio. The combination of the two drugs and antibiotics has a certain effect on the treatment of malacoplakia[17, 18]. Surgical treatment is necessary when regular drug treatment is ineffective. Continuous postoperative cooperation with anti-infective therapy can improve cure rates. In this case, we simultaneously performed transurethral plasmakinetic resection and plasma coagulation. There was no significant difference between the two methods in the postoperative review (Figure 5), and both achieved curative effects. Accordingly, we speculated that the disease might be a bladder mucosal lesion, which is different from that stated in previous literature. Therefore, we believe that mucosal operation of the disease was sufficient in improving the effectiveness of treatment, as well as in reducing postoperative complications.





DOI: 10.12998/wjcc.v10.i23.8291 Copyright ©The Author(s) 2022.

**Figure 4 Electron microscopy findings.** A: Phagocytic lysosomes in the cytoplasm of macrophages; B: Microbubble; C: A typical Michaelis–Gutman (M-G) body as shown by arrows; D: Large number of bacteria in phagocytic lysosomes; E: Some bacteria were digested and dissolved; F: Myelin figure.



DOI: 10.12998/wjcc.v10.i23.8291 Copyright ©The Author(s) 2022.

**Figure 5 Postoperative review.** A: Scar in the electrotomy area; B: Electrocoagulation scar.

## CONCLUSION

Bladder malacoplakia is a rare chronic granulomatous disease with nonspecific clinical manifestations and a high misdiagnosis rate. Its diagnosis depends on histopathological examination. Long-term oral antibiotics combined with cholinergic drugs or vitamin C can be used as treatments for the condition. If necessary, a better therapeutic effect can be achieved by combining bladder tumor resection or electrocoagulation with medical management.

## FOOTNOTES

**Author contributions:** Wang HK and Chen B contributed to the study conception and writing; Wang HK and Hang G contributed to the collection of pathological and electron microscopic findings; Wang YY and Chen B contributed to the analysis; Wen Q collected data on the surgery; Chen B reviewed and revised the first draft; All authors read and approved the final version of the manuscript.

**Informed consent statement:** Written informed consent has been obtained from patients and their families.

**Conflict-of-interest statement:** All authors have no conflict of interest.

**CARE Checklist (2016) statement:** The authors have read the CARE Checklist (2016), and the manuscript was prepared and revised according to the CARE Checklist (2016).

**Open-Access:** This article is an open-access article that was selected by an in-house editor and fully peer-reviewed by external reviewers. It is distributed in accordance with the Creative Commons Attribution NonCommercial (CC BY-NC 4.0) license, which permits others to distribute, remix, adapt, build upon this work non-commercially, and license their derivative works on different terms, provided the original work is properly cited and the use is non-commercial. See: <https://creativecommons.org/licenses/by-nc/4.0/>

**Country/Territory of origin:** China

**ORCID number:** Hua-Kang Wang 0000-0002-1282-1135; Gai Hang 0000-0002-3721-5916; Yu-Yang Wang 0000-0001-6457-6875; Quan Wen 0000-0002-5396-4917; Bo Chen 0000-0002-1049-0686.

**S-Editor:** Gong ZM

**L-Editor:** Filipodia

**P-Editor:** Gong ZM

## REFERENCES

- 1 Stanton MJ, Maxted W. Malacoplakia: a study of the literature and current concepts of pathogenesis, diagnosis and treatment. *J Urol* 1981; **125**: 139-146 [PMID: 7009885 DOI: 10.1016/s0022-5347(17)54940-x]
- 2 Wang T, Shi Y, Ding YF, Jia ZK, Tian XY, Li SC, Wang J, Yang JJ. Experience in diagnosis and treatment of bladder malacoplakia. *Zhonghua Miniao Waiké Zazhi* 2018; **39**: 389-390 [DOI: 10.3760/cma.j.issn.1000-6702.2018.05.017]
- 3 İnci O, Taştekin E, Gençhellaç H, Arabacı Ö, İşler S, Atakan İH. A Case of Urachal Malacoplakia that Seems Like Urachal Cancer. *Balkan Med J* 2015; **32**: 114-117 [PMID: 25759783 DOI: 10.5152/balkanmedj.2015.15053]
- 4 Stamatiou K, Chelioti E, Tsavari A, Koulia K, Papalexandrou A, Efthymiou E, Tsilivigkou M, Vasilakaki T. Renal failure caused by malakoplakia lesions of the urinary bladder. *Nephrourol Mon* 2014; **6**: e18522 [PMID: 25695020 DOI: 10.5812/numonthly.18522]
- 5 Lee SL, Teo JK, Lim SK, Salkade HP, Mancera K. Coexistence of Malacoplakia and Papillary Urothelial Carcinoma of the Urinary Bladder. *Int J Surg Pathol* 2015; **23**: 575-578 [PMID: 26194600 DOI: 10.1177/1066896915595464]
- 6 van der Voort HJ, ten Velden JA, Wassenaar RP, Silberbusch J. Malacoplakia. Two case reports and a comparison of treatment modalities based on a literature review. *Arch Intern Med* 1996; **156**: 577-583 [PMID: 8604965 DOI: 10.1001/archinte.156.5.577]
- 7 Mukha RP, Kumar S, Ramani MK, Kekre NS. Isolated Malacoplakia of the bladder: a rare case report and review of literature. *Int Urol Nephrol* 2010; **42**: 349-350 [PMID: 19669585 DOI: 10.1007/s11255-009-9624-z]
- 8 Barnard M, Chalvardjian A. Cutaneous malakoplakia in a patient with acquired immunodeficiency syndrome (AIDS). *Am J Dermatopathol* 1998; **20**: 185-188 [PMID: 9557790 DOI: 10.1097/00000372-199804000-00015]
- 9 Botros N, Yan SR, Wanless IR. Malakoplakia of liver: report of two cases. *Pathol Res Pract* 2014; **210**: 459-462 [PMID: 24755510 DOI: 10.1016/j.prp.2014.03.004]
- 10 Matsuda I, Zozumi M, Tsuchida YA, Kimura N, Liu NN, Fujimori Y, Okada M, Hashimoto T, Yamamoto S, Hirota S. Primary extranodal marginal zone lymphoma of mucosa-associated lymphoid tissue type with malakoplakia in the urinary bladder: a case report. *Int J Clin Exp Pathol* 2014; **7**: 5280-5284 [PMID: 25197410]
- 11 Rutland BE, Nimmo J, Goldsworthy M, Simcock JO, Simpson KW, Kuntz CA. Successful treatment of malakoplakia of the bladder in a kitten. *J Feline Med Surg* 2013; **15**: 744-748 [PMID: 23300187 DOI: 10.1177/1098612X12471663]
- 12 Kogulan PK, Smith M, Seidman J, Chang G, Tsokos M, Lucey D. Malakoplakia involving the abdominal wall, urinary bladder, vagina, and vulva: case report and discussion of malakoplakia-associated bacteria. *Int J Gynecol Pathol* 2001; **20**: 403-406 [PMID: 11603228 DOI: 10.1097/00004347-200110000-00016]
- 13 Rosai J. Akman Surgical Pathology: Volume I [M]. 9th edition. Beijing: Peking University Press, 2006: 1321-1322
- 14 Sharma K, Singh V, Gupta S, Sankhwar S. Xanthogranulomatous cystitis with malacoplakia, leading to spontaneous intraperitoneal perforation of the urinary bladder in a 9-year-old girl. *BMJ Case Rep* 2015; **2015** [PMID: 26272961 DOI: 10.1136/bcr-2015-210786]
- 15 Kang YJ, Kim SW, Lee KS, Kim KH. Malacoplakia of the epididymis. *Korean J Urol* 2013; **54**: 274-276 [PMID: 23614068 DOI: 10.4111/kju.2013.54.4.274]
- 16 Liu LY, Liu YJ, Deng YM, Chen H, Zhang S. Clinicopathological analysis of 4 cases of soft spot. *Bingli Zhenduanxue Zazhi* 2010; **20**: 600-603
- 17 Dong H, Dawes S, Philip J, Chaudhri S, Subramanian K. Malakoplakia of the Urogenital Tract. *Urol Case Rep* 2015; **3**: 6-8 [PMID: 26793484 DOI: 10.1016/j.eucr.2014.10.002]
- 18 Abdou NI, NaPombejara C, Sagawa A, Ragland C, Stechschulte DJ, Nilsson U, Gourley W, Watanabe I, Lindsey NJ, Allen MS. Malakoplakia: evidence for monocyte lysosomal abnormality correctable by cholinergic agonist *in vitro* and *in vivo*. *N Engl J Med* 1977; **297**: 1413-1419 [PMID: 200843 DOI: 10.1056/NEJM197712292972601]



Published by **Baishideng Publishing Group Inc**  
7041 Koll Center Parkway, Suite 160, Pleasanton, CA 94566, USA

**Telephone:** +1-925-3991568

**E-mail:** [bpgoffice@wjgnet.com](mailto:bpgoffice@wjgnet.com)

**Help Desk:** <https://www.f6publishing.com/helpdesk>

<https://www.wjgnet.com>

