

World Journal of *Clinical Cases*

World J Clin Cases 2022 August 16; 10(23): 8057-8431



Contents

Thrice Monthly Volume 10 Number 23 August 16, 2022

OPINION REVIEW

- 8057** Invasive intervention timing for infected necrotizing pancreatitis: Late invasive intervention is not late for collection

Xiao NJ, Cui TT, Liu F, Li W

- 8063** Clinical utility of left atrial strain in predicting atrial fibrillation recurrence after catheter ablation: An up-to-date review

Yu ZX, Yang W, Yin WS, Peng KX, Pan YL, Chen WW, Du BB, He YQ, Yang P

MINIREVIEWS

- 8076** Gut microbiota and COVID-19: An intriguing pediatric perspective

Valentino MS, Esposito C, Colosimo S, Caprio AM, Puzone S, Guarino S, Marzuillo P, Miraglia del Giudice E, Di Sessa A

- 8088** Beta receptor blocker therapy for the elderly in the COVID-19 era

Santillo E, Migale M

ORIGINAL ARTICLE

Retrospective Cohort Study

- 8097** Nonselective beta-blocker use is associated with increased hepatic encephalopathy-related readmissions in cirrhosis

Fallahzadeh MA, Asrani SK, Tapper EB, Saracino G, Rahimi RS

Retrospective Study

- 8107** Different squatting positions after total knee arthroplasty: A retrospective study

Li TJ, Sun JY, Du YQ, Shen JM, Zhang BH, Zhou YG

- 8115** Outcomes of seromuscular bladder augmentation compared with standard bladder augmentation in the treatment of children with neurogenic bladder

Sun XG, Li YX, Ji LF, Xu JL, Chen WX, Wang RY

- 8124** Distinctive clinical features of spontaneous pneumoperitoneum in neonates: A retrospective analysis

Kim SH, Cho YH, Kim HY

- 8133** Cognitive training for elderly patients with early Alzheimer's disease in the Qinghai-Tibet Plateau: A pilot study

Wang XH, Luo MQ

- 8141** Diagnostic value of elevated serum carbohydrate antigen 125 level in sarcoidosis

Zhang Q, Jing XY, Yang XY, Xu ZJ

- 8152** Evaluation of progressive early rehabilitation training mode in intensive care unit patients with mechanical ventilation

Qie XJ, Liu ZH, Guo LM

- 8161** Comparison of demographic features and laboratory parameters between COVID-19 deceased patients and surviving severe and critically ill cases

Wang L, Gao Y, Zhang ZJ, Pan CK, Wang Y, Zhu YC, Qi YP, Xie FJ, Du X, Li NN, Chen PF, Yue CS, Wu JH, Wang XT, Tang YJ, Lai QQ, Kang K

Clinical Trials Study

- 8170** Role of H₂receptor blocker famotidine over the clinical recovery of COVID-19 patients: A randomized controlled trial

Mohiuddin Chowdhury ATM, Kamal A, Abbas MKU, Karim MR, Ali MA, Talukder S, Hamidullah Mehedi H, Hassan H, Shahin AH, Li Y, He S

Observational Study

- 8186** Short-term prognostic factors for hepatitis B virus-related acute-on-chronic liver failure

Ye QX, Huang JF, Xu ZJ, Yan YY, Yan Y, Liu LG

- 8196** Three-dimensional psychological guidance combined with evidence-based health intervention in patients with liver abscess treated with ultrasound

Shan YN, Yu Y, Zhao YH, Tang LL, Chen XM

- 8205** Role of serum β 2-microglobulin, glycosylated hemoglobin, and vascular endothelial growth factor levels in diabetic nephropathy

Yang B, Zhao XH, Ma GB

SYSTEMATIC REVIEWS

- 8212** Gallbladder neuroendocrine carcinoma diagnosis, treatment and prognosis based on the SEER database: A literature review

Cai XC, Wu SD

CASE REPORT

- 8224** Sepsis complicated with secondary hemophagocytic syndrome induced by giant gouty tophi rupture: A case report

Lai B, Pang ZH

- 8232** Spontaneous remission of autoimmune pancreatitis: Four case reports

Zhang BB, Huo JW, Yang ZH, Wang ZC, Jin EH

- 8242** Epstein-Barr-virus-associated hepatitis with aplastic anemia: A case report

Zhang WJ, Wu LQ, Wang J, Lin SY, Wang B

- 8249** Aspiration as the first-choice procedure for airway management in an infant with large epiglottic cysts: A case report

Zheng JQ, Du L, Zhang WY

- 8255** Sequential multidisciplinary minimally invasive therapeutic strategy for heart failure caused by four diseases: A case report
Zhao CZ, Yan Y, Cui Y, Zhu N, Ding XY
- 8262** Primary ascending colon cancer accompanying skip metastases in left shoulder skin and left neck lymph node: A case report
Zhou JC, Wang JJ, Liu T, Tong Q, Fang YJ, Wu ZQ, Hong Q
- 8271** Clinical and genetic study of ataxia with vitamin E deficiency: A case report
Zhang LW, Liu B, Peng DT
- 8277** Complete resection of large-cell neuroendocrine and hepatocellular carcinoma of the liver: A case report
Noh BG, Seo HI, Park YM, Kim S, Hong SB, Lee SJ
- 8284** Immunotherapy combined with antiangiogenic agents in patients with advanced malignant pleural mesothelioma: A case report
Xuan TT, Li GY, Meng SB, Wang ZM, Qu LL
- 8291** Bladder malacoplakia: A case report
Wang HK, Hang G, Wang YY, Wen Q, Chen B
- 8298** Delayed inflammatory response evoked in nasal alloplastic implants after COVID-19 vaccination: A case report
Seo MG, Choi EK, Chung KJ
- 8304** Phosphoglyceride crystal deposition disease requiring differential diagnosis from malignant tumors and confirmed by Raman spectroscopy: A case report
Ohkura Y, Uruga H, Shiiba M, Ito S, Shimoyama H, Ishihara M, Ueno M, Udagawa H
- 8312** Vulvovaginal myeloid sarcoma with massive pelvic floor infiltration: A case report and review of literature
Wang JX, Zhang H, Ning G, Bao L
- 8323** Femoral neck stress fracture and medial tibial stress syndrome following high intensity interval training: A case report and review of literature
Tan DS, Cheung FM, Ng D, Cheung TLA
- 8330** Periosteal chondroma of the rib: A case report
Gao Y, Wang JG, Liu H, Gao CP
- 8336** Papillary thyroid carcinoma occurring with undifferentiated pleomorphic sarcoma: A case report
Lee YL, Cheng YQ, Zhu CF, Huo HZ
- 8344** Laparoscopic treatment of bilateral duplex kidney and ectopic ureter: A case report
Wang SB, Wan L, Wang Y, Yi ZJ, Xiao C, Cao JZ, Liu XY, Tang RP, Luo Y
- 8352** Incontinentia pigmenti with intracranial arachnoid cyst: A case report
Li WC, Li ML, Ding JW, Wang L, Wang SR, Wang YY, Xiao LF, Sun T

- 8360** Relapsing polychondritis causing breathlessness: Two case reports
Zhai SY, Zhang YH, Guo RY, Hao JW, Wen SX
- 8367** Endodontic management of a fused left maxillary second molar and two paramolars using cone beam computed tomography: A case report
Mei XH, Liu J, Wang W, Zhang QX, Hong T, Bai SZ, Cheng XG, Tian Y, Jiang WK
- 8375** Infant biliary cirrhosis secondary to a biliary inflammatory myofibroblastic tumor: A case report and review of literature
Huang Y, Shu SN, Zhou H, Liu LL, Fang F
- 8384** Metastatic low-grade endometrial stromal sarcoma with variable morphologies in the ovaries and mesentery: A case report
Yu HY, Jin YL
- 8392** Bronchogenic cysts with infection in the chest wall skin of a 64-year-old asymptomatic patient: A case report
Ma B, Fu KW, Xie XD, Cheng Y, Wang SQ
- 8400** Incidental accumulation of Technetium-99m pertechnetate in subacute cerebral infarction: A case report
Han YH, Jeong HJ, Kang HG, Lim ST
- 8406** Metal stent combined with ileus drainage tube for the treatment of delayed rectal perforation: A case report
Cheng SL, Xie L, Wu HW, Zhang XF, Lou LL, Shen HZ
- 8417** Using ketamine in a patient with a near-occlusion tracheal tumor undergoing tracheal resection and reconstruction: A case report
Xu XH, Gao H, Chen XM, Ma HB, Huang YG

LETTER TO THE EDITOR

- 8422** Reflections on the prevalence of human leukocyte antigen-B27 and human leukocyte antigen-B51 co-occurrence in patients with spondylarthritis
Gonçalves Júnior J, Sampaio-Barros PD, Shinjo SK
- 8425** Comment on "Disease exacerbation is common in inflammatory bowel disease patients treated with immune checkpoint inhibitors for malignancy"
Argyriou K, Kotsakis A
- 8428** Intranasal sufentanil combined with intranasal dexmedetomidine: A promising method for non-anesthesiologist sedation during endoscopic ultrasonography
Wang Y, Ge ZJ, Han C

ABOUT COVER

Editorial Board Member of *World Journal of Clinical Cases*, Peng Liang, MD, Associate Professor, Day Surgery Center, Department of Anesthesiology, West China Hospital of Sichuan University, Chengdu 610041, Sichuan Province, China. 39485572@qq.com

AIMS AND SCOPE

The primary aim of *World Journal of Clinical Cases* (WJCC, *World J Clin Cases*) is to provide scholars and readers from various fields of clinical medicine with a platform to publish high-quality clinical research articles and communicate their research findings online.

WJCC mainly publishes articles reporting research results and findings obtained in the field of clinical medicine and covering a wide range of topics, including case control studies, retrospective cohort studies, retrospective studies, clinical trials studies, observational studies, prospective studies, randomized controlled trials, randomized clinical trials, systematic reviews, meta-analysis, and case reports.

INDEXING/ABSTRACTING

The WJCC is now abstracted and indexed in Science Citation Index Expanded (SCIE, also known as SciSearch®), Journal Citation Reports/Science Edition, Current Contents®/Clinical Medicine, PubMed, PubMed Central, Scopus, Reference Citation Analysis, China National Knowledge Infrastructure, China Science and Technology Journal Database, and Superstar Journals Database. The 2022 Edition of Journal Citation Reports® cites the 2021 impact factor (IF) for WJCC as 1.534; IF without journal self cites: 1.491; 5-year IF: 1.599; Journal Citation Indicator: 0.28; Ranking: 135 among 172 journals in medicine, general and internal; and Quartile category: Q4. The WJCC's CiteScore for 2021 is 1.2 and Scopus CiteScore rank 2021: General Medicine is 443/826.

RESPONSIBLE EDITORS FOR THIS ISSUE

Production Editor: Hua-Ge Yin; Production Department Director: Xiang Li; Editorial Office Director: Jin-Lei Wang.

NAME OF JOURNAL

World Journal of Clinical Cases

ISSN

ISSN 2307-8960 (online)

LAUNCH DATE

April 16, 2013

FREQUENCY

Thrice Monthly

EDITORS-IN-CHIEF

Bao-Gan Peng, Jerzy Tadeusz Chudek, George Kontogeorgos, Maurizio Serati, Ja Hyeon Ku

EDITORIAL BOARD MEMBERS

<https://www.wjgnet.com/2307-8960/editorialboard.htm>

PUBLICATION DATE

August 16, 2022

COPYRIGHT

© 2022 Baishideng Publishing Group Inc

INSTRUCTIONS TO AUTHORS

<https://www.wjgnet.com/bpg/gerinfo/204>

GUIDELINES FOR ETHICS DOCUMENTS

<https://www.wjgnet.com/bpg/GerInfo/287>

GUIDELINES FOR NON-NATIVE SPEAKERS OF ENGLISH

<https://www.wjgnet.com/bpg/gerinfo/240>

PUBLICATION ETHICS

<https://www.wjgnet.com/bpg/GerInfo/288>

PUBLICATION MISCONDUCT

<https://www.wjgnet.com/bpg/gerinfo/208>

ARTICLE PROCESSING CHARGE

<https://www.wjgnet.com/bpg/gerinfo/242>

STEPS FOR SUBMITTING MANUSCRIPTS

<https://www.wjgnet.com/bpg/GerInfo/239>

ONLINE SUBMISSION

<https://www.f6publishing.com>



Delayed inflammatory response evoked in nasal alloplastic implants after COVID-19 vaccination: A case report

Min-Gi Seo, Eun Kyung Choi, Kyu Jin Chung

Specialty type: Surgery

Provenance and peer review:

Unsolicited article; Externally peer reviewed.

Peer-review model: Single blind

Peer-review report's scientific quality classification

Grade A (Excellent): 0

Grade B (Very good): B

Grade C (Good): C

Grade D (Fair): 0

Grade E (Poor): 0

P-Reviewer: Hazafa A, Pakistan; Islamoglu MS, Turkey

Received: February 6, 2022

Peer-review started: February 6, 2022

First decision: May 30, 2022

Revised: June 9, 2022

Accepted: July 16, 2022

Article in press: July 16, 2022

Published online: August 16, 2022



Min-Gi Seo, Kyu Jin Chung, Department of Plastic and Reconstructive Surgery, College of Medicine, Yeungnam University, Daegu 42415, South Korea

Eun Kyung Choi, Department of Anesthesiology and Pain Medicine, College of Medicine, Yeungnam University, Daegu 42415, South Korea

Corresponding author: Kyu Jin Chung, MD, PhD, Associate Professor, Department of Plastic and Reconstructive Surgery, College of Medicine, Yeungnam University, 170, Hyeonchung-ro, Daegu 42415, South Korea. chungkj@ynu.ac.kr

Abstract

BACKGROUND

Delayed inflammatory reactions (DIRs) in alloplast rhinoplasty are a rare complication that may occur several months to years after surgery. The exact causes and mechanisms are unclear, but several triggering factors, including infections, trauma, dental procedures, and vaccination, have been reported.

CASE SUMMARY

A 39-year-old male patient who had undergone augmentation rhinoplasty 8 years ago had DIRs after the administration of the first dose of the mRNA Pfizer coronavirus disease 2019 (COVID-19) vaccine. He suddenly had tender, erythematous swelling on his face 6 d after vaccination. As there was no improvement in the patient's condition after the conservative treatment, surgical removal of an alloplastic nasal implant was performed. Immediately after the surgery, the DIRs and accompanying symptoms ameliorated rapidly. A histological study conducted during surgery was fibrosis and small fragments of the hyaline cartilage.

CONCLUSION

The correlation between DIRs and COVID-19 vaccination has not been reported yet and the exact mechanism is unclear. Because the uncontrolled inflammatory reactions on the nose leave serious sequelae, surgeons should be conscious of the correlation between COVID-19 vaccines and DIRs associated with nasal alloplastic implants. And further histological or microbiological studies should be performed to determine the cause of DIRs.

Key Words: Delayed inflammatory reactions; Alloplast rhinoplasty; Silicone; COVID-19; Vaccination; Case report

©The Author(s) 2022. Published by Baishideng Publishing Group Inc. All rights reserved.

Core Tip: Delayed inflammatory reactions (DIRs) in alloplast rhinoplasty are rare and their correlation with coronavirus disease 2019 (COVID-19) vaccines is unclear. We present herein the first case of DIRs in alloplast rhinoplasty after the first administration of the COVID-19 vaccine. We performed surgical removal of an alloplastic implant because no improvements were observed in the patient's condition after conservative treatment. This intervention accelerated recovery. A delayed fibrotic reaction induced by the COVID-19 vaccine may be a possible cause. Our case suggests surgeons should be aware of the correlation between COVID-19 vaccines and DIRs in alloplast rhinoplasty.

Citation: Seo MG, Choi EK, Chung KJ. Delayed inflammatory response evoked in nasal alloplastic implants after COVID-19 vaccination: A case report. *World J Clin Cases* 2022; 10(23): 8298-8303

URL: <https://www.wjgnet.com/2307-8960/full/v10/i23/8298.htm>

DOI: <https://dx.doi.org/10.12998/wjcc.v10.i23.8298>

INTRODUCTION

Alloplast rhinoplasty is one of the most commonly performed plastic surgery procedures[1]. Clinically, silicone implants account for the majority of alloplastic implants in rhinoplasty. Despite the proven safety of these implants, there are several complications related to these implants such as infections, extrusion, and capsular contractures[2]. Delayed inflammatory reactions (DIRs) in alloplastic implants can also occur several months to many years after alloplast rhinoplasty. Tenderness, swelling, and erythema around the nose and glabella may be noted[3]. DIRs associated with hyaluronic acid (HA) fillers are not rare, the prevalence is up to 4.25%[4]. In addition, studies on the relationship between soft tissue fillers and coronavirus disease 2019 (COVID-19) vaccines have been conducted and global recommendations have also been proposed[5]. Unlike HA fillers, the incidence of DIRs related to alloplastic implants in rhinoplasty is unknown and its exact causes and mechanisms are unclear[3]. And their correlation with COVID-19 vaccines has not been reported yet. Although the incidence of DIRs in alloplast rhinoplasty may be low, the management of DIRs is crucial because DIRs can cause serious esthetic and functional complications[3]. And increased COVID-19 vaccination rates during the COVID-19 pandemic may be a new risk factor for DIRs in alloplast rhinoplasty. In this case report, we present the first case of DIRs in alloplast rhinoplasty after the first administration of the COVID-19 vaccine. The patient who had undergone alloplast rhinoplasty with a silicone implant eight years ago developed DIRs within several days after administration of the first dose of the mRNA Pfizer COVID-19 vaccine. This case and our course of treatment will provide insights into the correlation between the COVID-19 vaccines and DIRs associated with alloplastic implants in rhinoplasty.

CASE PRESENTATION

Chief complaints

In September 2021, a 39-year-old male patient presented with tender, erythematous swelling on his glabella, the nasal dorsum, and both malar areas.

History of present illness

Inflammation began 6 d after the patient had received his first dose of the mRNA Pfizer COVID-19 vaccine.

History of past illness

He had undergone augmentation rhinoplasty with a silicone implant in 2013. After the surgery, he had not experienced any discomfort or complications related to the nasal implant. He had not undergone any dental treatment or suffered any inflammatory skin disease on the face in the six months before the vaccination.

Personal and family history

The patient was physically fit and healthy and did not have a history of any medical comorbidities or allergies. Moreover, he had no significant familial history including a history of inflammatory skin disease.

Physical examination

On the day of the transfer, his body temperature was 38.2 °C. He still had tender, erythematous swelling on his glabella. The redness spread from the nasal dorsum and to both the malar areas (Figure 1). He complained of severe tenderness and discomfort in the center of his face, including his glabella. There were no other visible external lesions or discharge on the face.

Laboratory examinations

The initial erythrocyte sedimentation rate was 18 mm/h (normal range, 0-20 mm/h), the C-reactive protein level was 3.805 mg/dL (normal range, 0-0.5 mg/dL), and the white blood cell (WBC) level was 15550/μL (normal range, 4000-10000/μL). The other laboratory tests included assessments of liver function, kidney function, and electrolytes, which were within the normal range.

Imaging examinations

Owing to the acute symptoms, he immediately visited a nearby emergency room on the day of symptom onset and underwent facial computed tomography (CT). The non-contrast facial CT revealed that the silicone implant was located above the nasal cartilage and infiltrated subcutaneous tissue was confirmed around the silicone implant (Figure 2). There was no evidence of other foreign bodies that could cause inflammation.

FINAL DIAGNOSIS

During surgery, we detected inflammatory tissues and some fluid collection around the silicone implant. No other foreign bodies were detected. Other than a prior administration of COVID-19 vaccination, no other factors could be identified that might evoke this delayed inflammatory response. Bacterial culture of the fluid collection around the silicone implant and biopsy of the capsules was performed during surgery. *Staphylococcus aureus* without any antibiotic resistance was cultured from the fluid collection. In addition, several capsules around the silicone implant were confirmed as fibrosis and small fragments of the hyaline cartilage through biopsy.

TREATMENT

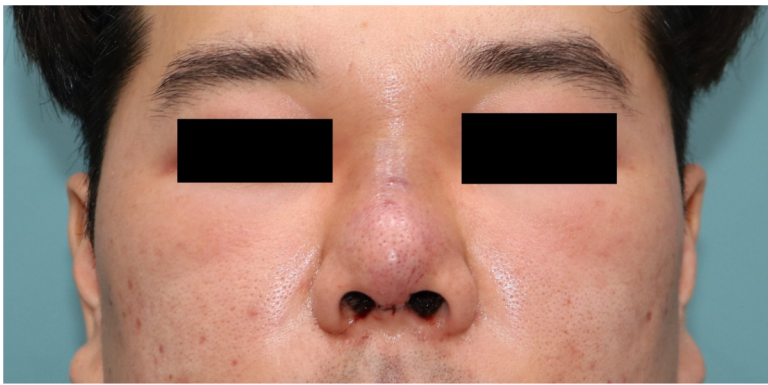
He initially received an intravenous injection of 30 mg of ketorolac tromethamine (Kerola, non-steroidal anti-inflammatory drugs) and 1 g of Cefazolin in the emergency room. As there was no improvement in his symptoms the treatment, the next day, he visited the hospital where he had undergone augmentation rhinoplasty 8 years ago. After sufficient fasting time, he underwent exploration surgery to determine the cause of inflammation and remove the nasal implant under local anesthesia. It was difficult to perform surgery because he had severe pain and anxiety, and thus, the implant removal procedure failed. He was then transferred to the Yeungnam university hospital to undergo revision surgery under general anesthesia. Revision surgery was performed the following day to debride the inflammatory tissue and remove the nasal implant under general anesthesia (Figure 3A). During surgery, bacterial culture of the fluid collection inside the wound was performed. As some capsules were formed around the implant, a biopsy of the capsules was performed (Figure 3B). After confirming that the fluid collection and implant inside the wound were sufficiently removed, wound closure was performed. We prevented hematoma formation by 16G catheters as drainage tubes and packing the merocel inside both nostrils. Intravenous administration of 1.2 g of Amoxicillin and clavulanic acid (Amocla) was performed three times per day.

OUTCOME AND FOLLOW-UP

He experienced an improvement in swelling and erythema within the first day and achieved complete resolution on postoperative day 4 (Figure 4). He reported no recurrence of swelling or erythema on the nose for four months.

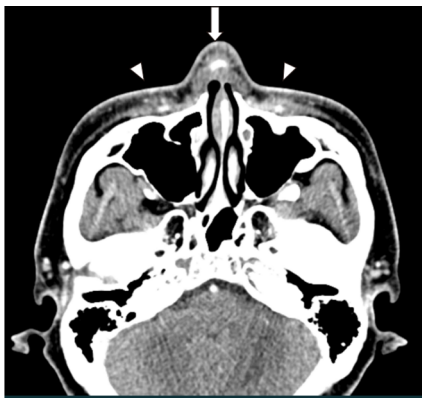DISCUSSION

DIRs associated with alloplast rhinoplasty are rare, and it is difficult to predict when DIRs may occur and what causes DIRs after surgery. It is known that DIRs in HA fillers can be evoked from an immunologic stimulus, with or without the presence of bacterial infection[4]. In particular, immunizations can be potential immunologic stimulations because they can modulate immune surveillance and



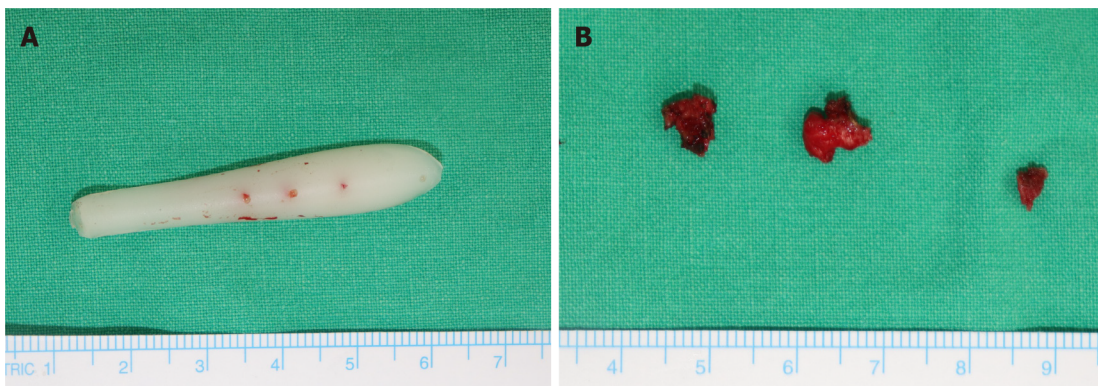
DOI: 10.12998/wjcc.v10.i23.8298 Copyright ©The Author(s) 2022.

Figure 1 Initial gross photograph of the patient at transfer day. After the exploration surgery failed, the patient was transferred to our hospital to undergo revision surgery under general anesthesia.



DOI: 10.12998/wjcc.v10.i23.8298 Copyright ©The Author(s) 2022.

Figure 2 Radiologic findings. Non-contrast facial computed tomography on the day of symptom onset. Infiltrated subcutaneous tissue around silicone implant (arrow) and both malar areas (arrowhead).

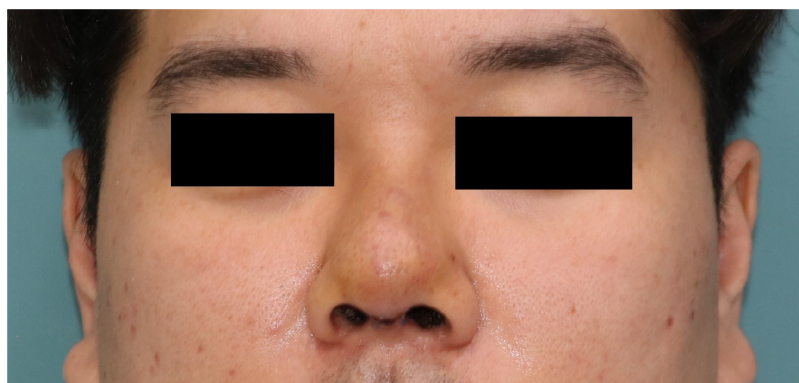


DOI: 10.12998/wjcc.v10.i23.8298 Copyright ©The Author(s) 2022.

Figure 3 Surgical intervention. Through revision surgery, the inflammatory tissues were debridement and the silicone implant was completely removed. A: Completely removed nasal silicone implant; B: Resected several capsules around silicone implant during surgery.

activate immune systems. Moreover, the COVID-19 vaccine has been reported to cause DIRs in HA fillers[6]. The symptoms of DIRs in HA fillers may appear as localized swelling, tenderness, fever, or flu-like illness[7]. As similar reactions and pathophysiological processes were observed in our case, the mRNA Pfizer COVID-19 vaccine also can be considered a triggering factor of DIRs in silicone implants used in rhinoplasty.

Other hypotheses have been proposed to explain the pathophysiology of DIRs in silicone implants used in rhinoplasty. One potential factor is infection and peri-implant biofilm development due to bacteria[3]. In our case, *Staphylococcus aureus* without any antibiotic resistance was cultured from the



DOI: 10.12998/wjcc.v10.i23.8298 Copyright ©The Author(s) 2022.

Figure 4 Postoperative day 4. Skin erythema and swelling decreased with time. The patient was discharged after a complete recovery of symptoms on postoperative day 4.

fluid collection. These results may suggest the cause of DIRs as infection in this case but the possibility is low. The test was performed during the revision surgery, so the results of the microbial culture test suggested a high possibility of contamination during the first surgery. Furthermore, the cultured bacteria were the skin flora. The initial WBC level was 15550/ μ L and the initial differential ratio of neutrophils was 86.9%. These findings can be related to inflammation as well and do not necessarily indicate infection. In addition, the patient had not had any inflammatory skin diseases and had not undergone dental or other aesthetic procedures that could cause infection in the six months prior to presentation.

Late seroma formation may also contribute to the etiology of DIRs[3,6]. During revision surgery, only fluid collection and inflammatory tissue around the implant due to inflammation were identified, and the amount was not large. These small clusters were not sufficient to create the mechanical dynamics required to evoke symptomatic DIRs. In particular, in dermal fillers, some adverse reactions distant from the vaccine injection site are explained by granulomatous or fibrotic reactions caused by vaccination[6]. Similarly, fibrotic reactions around the nasal implant promoted by COVID-19 vaccination may have occurred. In this case, the formation of fibrotic capsules around the nasal implant was confirmed through biopsy. Thus, delayed fibrosis around the nasal implant induced by COVID-19 vaccination may be another factor in DIRs.

As the COVID-19 vaccination rate increases, the incidence of DIRs in alloplast rhinoplasty will increase. However, vaccination is necessary because of the morbidity, mortality, and socioeconomic impact of the COVID-19 pandemic[8]. Surgeons should be conscious of the possibility and perils of DIRs in alloplast rhinoplasty. However, the management of DIRs in alloplast rhinoplasty can be quite challenging due to the mechanisms and causes of DIRs that have not yet been elucidated[7]. Patients with DIRs in nasal alloplastic implants should receive empirical antibiotics and undergo percutaneous drainage if needed[3]. Because DIRs are often transient, self-limited diseases and resolve within days to weeks, further surgical intervention is not always necessary[3,7]. If the conditions and symptoms of the patient do not improve despite conservative treatment, removal of the nasal implant *via* surgery might accelerate the patient's recovery. In our case, the patient experienced an improvement in symptoms within the first day after surgery. With implant removal and total capsulectomy, curettage of the inflammatory tissue and granuloma-like lesions should be performed. The space where the implant resides should be irrigated copiously and a drain should be placed to prevent the formation of hematoma or seroma. A histological study of the capsules and additional bacterial culture tests can be useful data for determining the cause of DIRs.

CONCLUSION

The correlation between COVID-19 vaccines and soft tissue filler reactions has been well studied, and global recommendations have been proposed. In contrast, DIRs in alloplast rhinoplasty are rare, and cases related to COVID-19 vaccines have not yet been reported. Through this case, it was confirmed that the COVID-19 vaccine could be a possible factor in DIRs in nasal alloplastic implants. Surgeons should be conscious of the possibility and perils of DIRs with COVID-19 vaccination. And if DIRs occur, immediate treatment should be instituted. And additional studies should be conducted to establish clear correlations and mechanisms. Patients who undergo alloplast rhinoplasty must be educated about the risk of DIRs before COVID-19 vaccination and consent should be obtained from them.

FOOTNOTES

Author contributions: All authors contributed to the case conception and design; Chung KJ provided the valuable case and performed the operation; data collection and analysis were performed by Seo MG; the first draft of the manuscript was written by Seo MG; all authors commented on previous versions of the manuscript; all authors read and approved the final manuscript.

Supported by the 2016 Yeungnam University Research Grants.

Informed consent statement: A written informed consent was obtained from the patient for publication of this case report.

Conflict-of-interest statement: The authors have nothing to disclose.

CARE Checklist (2016) statement: The authors have read the CARE Checklist (2016), and the manuscript was prepared and revised according to the CARE Checklist (2016).

Open-Access: This article is an open-access article that was selected by an in-house editor and fully peer-reviewed by external reviewers. It is distributed in accordance with the Creative Commons Attribution NonCommercial (CC BY-NC 4.0) license, which permits others to distribute, remix, adapt, build upon this work non-commercially, and license their derivative works on different terms, provided the original work is properly cited and the use is non-commercial. See: <https://creativecommons.org/licenses/by-nc/4.0/>

Country/Territory of origin: South Korea

ORCID number: Min-Gi Seo 0000-0003-3209-2643; Eun Kyung Choi 0000-0001-5758-6741; Kyujin Chung 0000-0001-6335-1818.

S-Editor: Wang DM

L-Editor: A

P-Editor: Wang DM

REFERENCES

- 1 Sharif-Askary B, Carlson AR, Van Noord MG, Marcus JR. Incidence of Postoperative Adverse Events after Rhinoplasty: A Systematic Review. *Plast Reconstr Surg* 2020; **145**: 669-684 [PMID: 32097305 DOI: 10.1097/PRS.0000000000006561]
- 2 Kim IS. Augmentation Rhinoplasty Using Silicone Implants. *Facial Plast Surg Clin North Am* 2018; **26**: 285-293 [PMID: 30005785 DOI: 10.1016/j.fsc.2018.03.003]
- 3 Moon KC, Lee KI, Lee JS, Kim AR, Dhong ES, Kim DW, Han SK. Late-Onset Inflammation in Asian Rhinoplasty Using Alloplastic Implants. *Aesthetic Plast Surg* 2021; **45**: 670-678 [PMID: 32100083 DOI: 10.1007/s00266-020-01648-8]
- 4 Sarigul Guduk S. A case of delayed inflammatory filler reaction following vaccination with successful response to colchicine. *J Cosmet Laser Ther* 2021; **23**: 52-54 [PMID: 34407723 DOI: 10.1080/14764172.2021.1967997]
- 5 Gotkin RH, Gout U, Sattler S, Piansay-Soriano ME, Wanitphakdeedecha R, Ghannam S, Rossi E, Ferrariz TS, Hexsel D, Frank K, Davidovic K, Sarnoff DS, Cotofana S. Global Recommendations on COVID-19 Vaccines and Soft Tissue Filler Reactions: A Survey-Based Investigation in Cooperation With the International Society for Dermatologic and Aesthetic Surgery (ISDS). *J Drugs Dermatol* 2021; **20**: 374-378 [PMID: 33852237 DOI: 10.36849/JDD.2021.6041]
- 6 Niebel D, Novak N, Wilhelmi J, Ziob J, Wilschmann-Theis D, Bieber T, Wenzel J, Braegelmann C. Cutaneous Adverse Reactions to COVID-19 Vaccines: Insights from an Immuno-Dermatological Perspective. *Vaccines (Basel)* 2021; **9** [PMID: 34579181 DOI: 10.3390/vaccines9090944]
- 7 Michon A. Hyaluronic acid soft tissue filler delayed inflammatory reaction following COVID-19 vaccination - A case report. *J Cosmet Dermatol* 2021; **20**: 2684-2690 [PMID: 34174156 DOI: 10.1111/jocd.14312]
- 8 Nicola M, Alsafi Z, Sohrabi C, Kerwan A, Al-Jabir A, Iosifidis C, Agha M, Agha R. The socio-economic implications of the coronavirus pandemic (COVID-19): A review. *Int J Surg* 2020; **78**: 185-193 [PMID: 32305533 DOI: 10.1016/j.ijsu.2020.04.018]



Published by **Baishideng Publishing Group Inc**
7041 Koll Center Parkway, Suite 160, Pleasanton, CA 94566, USA

Telephone: +1-925-3991568

E-mail: bpgoffice@wjgnet.com

Help Desk: <https://www.f6publishing.com/helpdesk>

<https://www.wjgnet.com>

