

World Journal of *Clinical Cases*

World J Clin Cases 2022 August 16; 10(23): 8057-8431



Contents

Thrice Monthly Volume 10 Number 23 August 16, 2022

OPINION REVIEW

- 8057** Invasive intervention timing for infected necrotizing pancreatitis: Late invasive intervention is not late for collection

Xiao NJ, Cui TT, Liu F, Li W

- 8063** Clinical utility of left atrial strain in predicting atrial fibrillation recurrence after catheter ablation: An up-to-date review

Yu ZX, Yang W, Yin WS, Peng KX, Pan YL, Chen WW, Du BB, He YQ, Yang P

MINIREVIEWS

- 8076** Gut microbiota and COVID-19: An intriguing pediatric perspective

Valentino MS, Esposito C, Colosimo S, Caprio AM, Puzone S, Guarino S, Marzuillo P, Miraglia del Giudice E, Di Sessa A

- 8088** Beta receptor blocker therapy for the elderly in the COVID-19 era

Santillo E, Migale M

ORIGINAL ARTICLE

Retrospective Cohort Study

- 8097** Nonselective beta-blocker use is associated with increased hepatic encephalopathy-related readmissions in cirrhosis

Fallahzadeh MA, Asrani SK, Tapper EB, Saracino G, Rahimi RS

Retrospective Study

- 8107** Different squatting positions after total knee arthroplasty: A retrospective study

Li TJ, Sun JY, Du YQ, Shen JM, Zhang BH, Zhou YG

- 8115** Outcomes of seromuscular bladder augmentation compared with standard bladder augmentation in the treatment of children with neurogenic bladder

Sun XG, Li YX, Ji LF, Xu JL, Chen WX, Wang RY

- 8124** Distinctive clinical features of spontaneous pneumoperitoneum in neonates: A retrospective analysis

Kim SH, Cho YH, Kim HY

- 8133** Cognitive training for elderly patients with early Alzheimer's disease in the Qinghai-Tibet Plateau: A pilot study

Wang XH, Luo MQ

- 8141** Diagnostic value of elevated serum carbohydrate antigen 125 level in sarcoidosis

Zhang Q, Jing XY, Yang XY, Xu ZJ

- 8152** Evaluation of progressive early rehabilitation training mode in intensive care unit patients with mechanical ventilation

Qie XJ, Liu ZH, Guo LM

- 8161** Comparison of demographic features and laboratory parameters between COVID-19 deceased patients and surviving severe and critically ill cases

Wang L, Gao Y, Zhang ZJ, Pan CK, Wang Y, Zhu YC, Qi YP, Xie FJ, Du X, Li NN, Chen PF, Yue CS, Wu JH, Wang XT, Tang YJ, Lai QQ, Kang K

Clinical Trials Study

- 8170** Role of H₂receptor blocker famotidine over the clinical recovery of COVID-19 patients: A randomized controlled trial

Mohiuddin Chowdhury ATM, Kamal A, Abbas MKU, Karim MR, Ali MA, Talukder S, Hamidullah Mehedi HM, Hassan H, Shahin AH, Li Y, He S

Observational Study

- 8186** Short-term prognostic factors for hepatitis B virus-related acute-on-chronic liver failure

Ye QX, Huang JF, Xu ZJ, Yan YY, Yan Y, Liu LG

- 8196** Three-dimensional psychological guidance combined with evidence-based health intervention in patients with liver abscess treated with ultrasound

Shan YN, Yu Y, Zhao YH, Tang LL, Chen XM

- 8205** Role of serum β 2-microglobulin, glycosylated hemoglobin, and vascular endothelial growth factor levels in diabetic nephropathy

Yang B, Zhao XH, Ma GB

SYSTEMATIC REVIEWS

- 8212** Gallbladder neuroendocrine carcinoma diagnosis, treatment and prognosis based on the SEER database: A literature review

Cai XC, Wu SD

CASE REPORT

- 8224** Sepsis complicated with secondary hemophagocytic syndrome induced by giant gouty tophi rupture: A case report

Lai B, Pang ZH

- 8232** Spontaneous remission of autoimmune pancreatitis: Four case reports

Zhang BB, Huo JW, Yang ZH, Wang ZC, Jin EH

- 8242** Epstein-Barr-virus-associated hepatitis with aplastic anemia: A case report

Zhang WJ, Wu LQ, Wang J, Lin SY, Wang B

- 8249** Aspiration as the first-choice procedure for airway management in an infant with large epiglottic cysts: A case report

Zheng JQ, Du L, Zhang WY

- 8255** Sequential multidisciplinary minimally invasive therapeutic strategy for heart failure caused by four diseases: A case report
Zhao CZ, Yan Y, Cui Y, Zhu N, Ding XY
- 8262** Primary ascending colon cancer accompanying skip metastases in left shoulder skin and left neck lymph node: A case report
Zhou JC, Wang JJ, Liu T, Tong Q, Fang YJ, Wu ZQ, Hong Q
- 8271** Clinical and genetic study of ataxia with vitamin E deficiency: A case report
Zhang LW, Liu B, Peng DT
- 8277** Complete resection of large-cell neuroendocrine and hepatocellular carcinoma of the liver: A case report
Noh BG, Seo HI, Park YM, Kim S, Hong SB, Lee SJ
- 8284** Immunotherapy combined with antiangiogenic agents in patients with advanced malignant pleural mesothelioma: A case report
Xuan TT, Li GY, Meng SB, Wang ZM, Qu LL
- 8291** Bladder malacoplakia: A case report
Wang HK, Hang G, Wang YY, Wen Q, Chen B
- 8298** Delayed inflammatory response evoked in nasal alloplastic implants after COVID-19 vaccination: A case report
Seo MG, Choi EK, Chung KJ
- 8304** Phosphoglyceride crystal deposition disease requiring differential diagnosis from malignant tumors and confirmed by Raman spectroscopy: A case report
Ohkura Y, Uruga H, Shiiba M, Ito S, Shimoyama H, Ishihara M, Ueno M, Udagawa H
- 8312** Vulvovaginal myeloid sarcoma with massive pelvic floor infiltration: A case report and review of literature
Wang JX, Zhang H, Ning G, Bao L
- 8323** Femoral neck stress fracture and medial tibial stress syndrome following high intensity interval training: A case report and review of literature
Tan DS, Cheung FM, Ng D, Cheung TLA
- 8330** Periosteal chondroma of the rib: A case report
Gao Y, Wang JG, Liu H, Gao CP
- 8336** Papillary thyroid carcinoma occurring with undifferentiated pleomorphic sarcoma: A case report
Lee YL, Cheng YQ, Zhu CF, Huo HZ
- 8344** Laparoscopic treatment of bilateral duplex kidney and ectopic ureter: A case report
Wang SB, Wan L, Wang Y, Yi ZJ, Xiao C, Cao JZ, Liu XY, Tang RP, Luo Y
- 8352** Incontinentia pigmenti with intracranial arachnoid cyst: A case report
Li WC, Li ML, Ding JW, Wang L, Wang SR, Wang YY, Xiao LF, Sun T

- 8360** Relapsing polychondritis causing breathlessness: Two case reports
Zhai SY, Zhang YH, Guo RY, Hao JW, Wen SX
- 8367** Endodontic management of a fused left maxillary second molar and two paramolars using cone beam computed tomography: A case report
Mei XH, Liu J, Wang W, Zhang QX, Hong T, Bai SZ, Cheng XG, Tian Y, Jiang WK
- 8375** Infant biliary cirrhosis secondary to a biliary inflammatory myofibroblastic tumor: A case report and review of literature
Huang Y, Shu SN, Zhou H, Liu LL, Fang F
- 8384** Metastatic low-grade endometrial stromal sarcoma with variable morphologies in the ovaries and mesentery: A case report
Yu HY, Jin YL
- 8392** Bronchogenic cysts with infection in the chest wall skin of a 64-year-old asymptomatic patient: A case report
Ma B, Fu KW, Xie XD, Cheng Y, Wang SQ
- 8400** Incidental accumulation of Technetium-99m pertechnetate in subacute cerebral infarction: A case report
Han YH, Jeong HJ, Kang HG, Lim ST
- 8406** Metal stent combined with ileus drainage tube for the treatment of delayed rectal perforation: A case report
Cheng SL, Xie L, Wu HW, Zhang XF, Lou LL, Shen HZ
- 8417** Using ketamine in a patient with a near-occlusion tracheal tumor undergoing tracheal resection and reconstruction: A case report
Xu XH, Gao H, Chen XM, Ma HB, Huang YG

LETTER TO THE EDITOR

- 8422** Reflections on the prevalence of human leukocyte antigen-B27 and human leukocyte antigen-B51 co-occurrence in patients with spondylarthritis
Gonçalves Júnior J, Sampaio-Barros PD, Shinjo SK
- 8425** Comment on "Disease exacerbation is common in inflammatory bowel disease patients treated with immune checkpoint inhibitors for malignancy"
Argyriou K, Kotsakis A
- 8428** Intranasal sufentanil combined with intranasal dexmedetomidine: A promising method for non-anesthesiologist sedation during endoscopic ultrasonography
Wang Y, Ge ZJ, Han C

ABOUT COVER

Editorial Board Member of *World Journal of Clinical Cases*, Peng Liang, MD, Associate Professor, Day Surgery Center, Department of Anesthesiology, West China Hospital of Sichuan University, Chengdu 610041, Sichuan Province, China. 39485572@qq.com

AIMS AND SCOPE

The primary aim of *World Journal of Clinical Cases* (WJCC, *World J Clin Cases*) is to provide scholars and readers from various fields of clinical medicine with a platform to publish high-quality clinical research articles and communicate their research findings online.

WJCC mainly publishes articles reporting research results and findings obtained in the field of clinical medicine and covering a wide range of topics, including case control studies, retrospective cohort studies, retrospective studies, clinical trials studies, observational studies, prospective studies, randomized controlled trials, randomized clinical trials, systematic reviews, meta-analysis, and case reports.

INDEXING/ABSTRACTING

The WJCC is now abstracted and indexed in Science Citation Index Expanded (SCIE, also known as SciSearch®), Journal Citation Reports/Science Edition, Current Contents®/Clinical Medicine, PubMed, PubMed Central, Scopus, Reference Citation Analysis, China National Knowledge Infrastructure, China Science and Technology Journal Database, and Superstar Journals Database. The 2022 Edition of Journal Citation Reports® cites the 2021 impact factor (IF) for WJCC as 1.534; IF without journal self cites: 1.491; 5-year IF: 1.599; Journal Citation Indicator: 0.28; Ranking: 135 among 172 journals in medicine, general and internal; and Quartile category: Q4. The WJCC's CiteScore for 2021 is 1.2 and Scopus CiteScore rank 2021: General Medicine is 443/826.

RESPONSIBLE EDITORS FOR THIS ISSUE

Production Editor: Hua-Ge Yin; Production Department Director: Xiang Li; Editorial Office Director: Jin-Lei Wang.

NAME OF JOURNAL

World Journal of Clinical Cases

ISSN

ISSN 2307-8960 (online)

LAUNCH DATE

April 16, 2013

FREQUENCY

Thrice Monthly

EDITORS-IN-CHIEF

Bao-Gan Peng, Jerzy Tadeusz Chudek, George Kontogeorgos, Maurizio Serati, Ja Hyeon Ku

EDITORIAL BOARD MEMBERS

<https://www.wjgnet.com/2307-8960/editorialboard.htm>

PUBLICATION DATE

August 16, 2022

COPYRIGHT

© 2022 Baishideng Publishing Group Inc

INSTRUCTIONS TO AUTHORS

<https://www.wjgnet.com/bpg/gerinfo/204>

GUIDELINES FOR ETHICS DOCUMENTS

<https://www.wjgnet.com/bpg/GerInfo/287>

GUIDELINES FOR NON-NATIVE SPEAKERS OF ENGLISH

<https://www.wjgnet.com/bpg/gerinfo/240>

PUBLICATION ETHICS

<https://www.wjgnet.com/bpg/GerInfo/288>

PUBLICATION MISCONDUCT

<https://www.wjgnet.com/bpg/gerinfo/208>

ARTICLE PROCESSING CHARGE

<https://www.wjgnet.com/bpg/gerinfo/242>

STEPS FOR SUBMITTING MANUSCRIPTS

<https://www.wjgnet.com/bpg/GerInfo/239>

ONLINE SUBMISSION

<https://www.f6publishing.com>



Papillary thyroid carcinoma occurring with undifferentiated pleomorphic sarcoma: A case report

Yu-Li Lee, Ya-Qiong Cheng, Chen-Fang Zhu, Hai-Zhong Huo

Specialty type: Pathology

Provenance and peer review:

Unsolicited article; Externally peer reviewed.

Peer-review model: Single blind

Peer-review report's scientific quality classification

Grade A (Excellent): 0

Grade B (Very good): 0

Grade C (Good): C

Grade D (Fair): D

Grade E (Poor): 0

P-Reviewer: Hashimoto K, Japan;
Kanat O, Turkey

Received: March 16, 2022

Peer-review started: March 16, 2022

First decision: May 30, 2022

Revised: June 13, 2022

Accepted: July 8, 2022

Article in press: July 8, 2022

Published online: August 16, 2022



Yu-Li Lee, Ya-Qiong Cheng, Chen-Fang Zhu, Hai-Zhong Huo, Department of General Surgery, Shanghai Ninth People's Hospital, Shanghai Jiao Tong University School of Medicine, Discipline Construction Research Center of China Hospital Development Institute, Shanghai Jiao Tong University, Shanghai 200011, China

Corresponding author: Hai-Zhong Huo, MD, PhD, Doctor, Department of General Surgery, Shanghai Ninth People's Hospital, Shanghai Jiao Tong University School of Medicine, Discipline Construction Research Center of China Hospital Development Institute, Shanghai Jiao Tong University, No. 639 Zhizaoju Road, Huangpu District, Shanghai 200011, China. fireseah@sina.com

Abstract

BACKGROUND

Papillary thyroid cancer (PTC) is the most common malignant tumor of the thyroid. However, the coexistence of PTC and sarcoma in one patient is rare. In this article, we report the case of a patient who presented with both PTC and undifferentiated pleomorphic sarcoma (UPS), which has not been previously reported in the online Medline database (PubMed).

CASE SUMMARY

A 71-year-old man was admitted to our hospital for a mass on the right side of his neck for one month, which rapidly enlarged within 2 wk with distending pain. The patient was diagnosed with a thyroid malignancy by fine-needle aspiration and underwent total thyroidectomy and bilateral central lymph node dissection. Histology and immunohistochemistry revealed features of both PTC and UPS. The thyroid cancer 8 gene detection kit results showed BRAF and telomerase reverse transcriptase mutations. The disease progressed rapidly, and the patient died four months after surgery from extensive lung metastasis.

CONCLUSION

Our report highlights the patient's pathological characteristics and related genetic mutations. Due to the rapid development and poor prognosis of cooccurring PTC and sarcoma, it is important for clinical physicians and pathologists to raise awareness of this type of tumor.

Key Words: Thyroid tumor; Papillary thyroid carcinoma; Undifferentiated pleomorphic sarcoma; BRAF; TERT; Case report

Core Tip: This manuscript reports the case of a patient diagnosed with coexisting papillary thyroid carcinoma and undifferentiated pleomorphic sarcoma. The coexistence of these two pathological types is extremely rare and has not been previously reported in the online Medline database. We retrospectively reviewed the clinical and pathological characteristics of this case and analyzed the related genetic mutations and possible treatments to raise awareness of this rapidly developing tumor.

Citation: Lee YL, Cheng YQ, Zhu CF, Huo HZ. Papillary thyroid carcinoma occurring with undifferentiated pleomorphic sarcoma: A case report. *World J Clin Cases* 2022; 10(23): 8336-8343

URL: <https://www.wjgnet.com/2307-8960/full/v10/i23/8336.htm>

DOI: <https://dx.doi.org/10.12998/wjcc.v10.i23.8336>

INTRODUCTION

Thyroid malignancies include primary thyroid cancer, sarcoma, lymphoma, and secondary malignant cancer. Primary thyroid cancer is the most common thyroid malignancy and is categorized as papillary thyroid cancer (PTC), follicular thyroid cancer (FTC), anaplastic thyroid cancer (ATC), or medullary thyroid cancer (MTC)[1]. While the prognosis of PTC and FTC is good, the prognosis of MTC and ATC is poor. The incidence rate of primary thyroid sarcoma (PTS) is low[2], and this disease category includes angiosarcoma, fibrosarcoma, leiomyosarcoma, hemangioendothelioma and undifferentiated pleomorphic sarcoma (UPS). UPS is a type of sarcoma without defined mesenchymal cell differentiation. It was previously known as malignant fibrous histiocytoma (MFH) and was first named UPS in the 2013 World Health Organization Classification of Soft Tissue Sarcoma[3]. Most malignant thyroid lesions involve only one pathological type; however, some cases have been reported in which two different histological types were present simultaneously. For example, PTC occurring with metastatic uterine leiomyosarcoma[4], epithelial angiosarcoma[5], synovial sarcoma[6], or endobronchial histiocytic sarcoma[7]. In this article, we report the case of a patient with PTC cooccurring with UPS. We also retrospectively reviewed the clinical and pathological characteristics of this case and analyzed the related genetic mutations and possible treatments.

CASE PRESENTATION

Chief complaints

A 71-year-old man was admitted to our hospital for a mass on the right side of his neck for one month.

History of present illness

The mass rapidly enlarged within 2 wk with distending pain from the right shoulder to the neck. Other symptoms included irritability, tremor, and loss of weight. No hoarseness, dyspnea, or other symptoms were present.

History of past illness

The patient had a 10-year history of hyperthyroidism, but he had stopped taking his medications by himself and had not received any further related medical examinations.

Personal and family history

The patient had no family history of thyroid malignancy.

Physical examination

Physical examination revealed a large mass on the right side of his thyroid, which was hard and did not move with swallowing.

Laboratory examinations

The patient's thyroid function, routine blood test, liver function, and renal function results were within the reference range. Acidosis, hyperlactatemia, and hypokalemia were presented, with specific results as: Serum pH, 7.31; PaCO₂, 44.9 mmHg; HCO₃⁻, 22.8 mmol/L; AG, 16.9; lactic acid, 4.8 mmol/L; K⁺, 3.3 mmol/L.

Imaging examinations

Ultrasound showed bilateral thyroid nodules. The right-side nodule was 58 mm × 41 mm × 67 mm and was classified as Thyroid Imaging Reporting and Data System (TI-RADS) 4A. The left-side nodule was 6.4 mm × 8 mm × 8 mm in size and was classified as TI-RADS 4C (Figure 1). Magnetic resonance imaging revealed that the mass was obviously pushing the trachea from right to left (Figure 2). Fine-needle aspiration showed only bilateral thyroid malignancy. Further pathological diagnosis required more thyroid tissue for confirmation.

Genetic testing

Gene mutation analysis was also performed using a thyroid cancer 8 gene detection kit (fluorescent PCR), which detects oncogenic mutations (BRAF, NRAS, HRAS, KRAS, and TERT) and chromosome rearrangements (CCDC6-RET, PAX8/PPAR, and EVT6-NTRK3). The patient had BRAF and TERT mutations.

FINAL DIAGNOSIS

Considering all the information above, the patient was diagnosed with bilateral thyroid malignancy.

TREATMENT

The patient underwent total thyroidectomy with bilateral central lymph node dissection. The pathology of the left nodule showed tumor cells with nuclear membrane irregularities arranged in a follicular pattern (Figure 3), and immunohistochemistry showed positive staining for CK19, MC, Gal-3, and TTF1, which matched the characteristics of PTC. The pathology of the right nodule showed two distinctive components. One component comprised spindle-shaped, round, or ovoid cells with increased mitotic activity, and immunohistochemistry showed diffuse positivity for vimentin and p53 with only sporadic CK19 expression, which supported the diagnosis of UPS (Figure 4). The other component of the right nodule matched the characteristics of PTC pathologically and immunohistochemically (Figure 5). Hence, combining the clinical behavior of the nodules with the pathological results, we concluded that the patient had coexisting PTC and UPS tumors.

OUTCOME AND FOLLOW-UP

Unfortunately, for financial reasons, the patient refused to accept any further treatment. Three months after the surgery, the patient developed severe respiratory symptoms. He came to the hospital again, and serious lung metastasis was discovered (Figure 6). He died one month after the discovery of the metastasis.

DISCUSSION

To the best of our knowledge, this report is the first documented case of coexisting PTC and UPS in one tumor lesion. PTS stems from mesenchymal tissue, and the incidence of this thyroid malignancy is only approximately 0.01% to 1.5% [2]. UPS is a rare type of PTS. The morphological features of UPS are easily distinguished from those of well-differentiated thyroid carcinoma; however, the pathological features of UPS and ATC are similar on H&E staining. On immunohistochemistry, ATC is positive for epithelial markers, such as CK. However, UPS is positive for mesenchymal markers, such as vimentin, but not epithelial markers [8]. In our case, only a few cells were positive for CK; however, diffuse strong positive vimentin expression was detected. Therefore, based on the histological features and immunohistochemical results, we diagnosed the patient with coexisting PTC and UPS.

We searched the PubMed database for patients with PTS occurring with PTC using the following search terms: [(papillary thyroid carcinoma) AND (sarcoma OR angiosarcoma OR fibrosarcoma OR leiomyosarcoma OR hemangioendothelioma OR fibrous histiocytoma OR undifferentiated pleomorphic sarcoma)]. Only three patients with coexisting PTC and PTS were found in PubMed, and the type of sarcoma these patients had was epithelial angiosarcoma [5], synovial sarcoma [6] or endobronchial histiocytic sarcoma [7]. No case similar to ours was found. All patients in the three cases underwent total thyroidectomy. Aggarwal *et al* [7] described the case of a patient with endobronchial histiocytic sarcoma who experienced PTC. The patient underwent 5 cycles of cyclophosphamide, adriamycin, and platinum combination chemotherapy and was well after six months of follow-up. Kefeli *et al* [5] reported the case of a patient with thyroid angiosarcoma arising in follicular-variant PTC but did not report follow-up

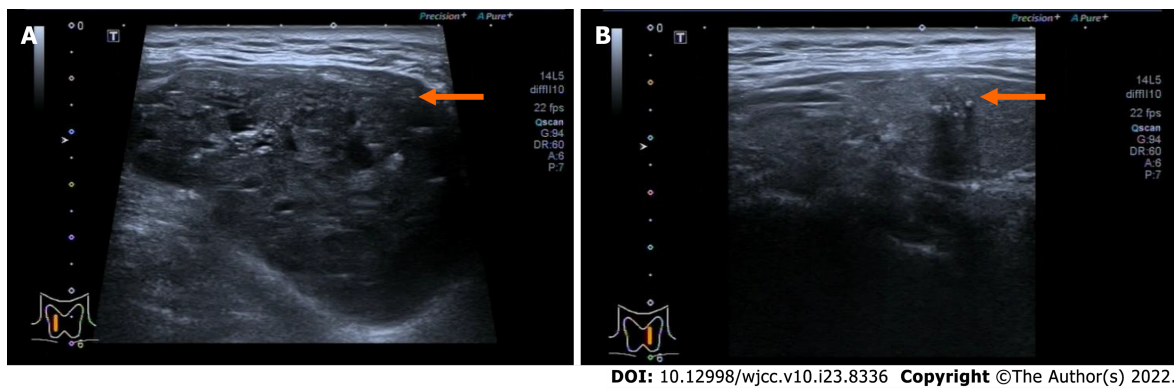


Figure 1 Cervical ultrasound of the patient before surgery. A: The right-side nodule (orange arrow) was 58 mm × 41 mm × 67 mm and was classified as TI-RADS 4A; B: The left-side nodule (orange arrow) was 6.4 mm × 8 mm × 8 mm and was classified as TI-RADS 4C.

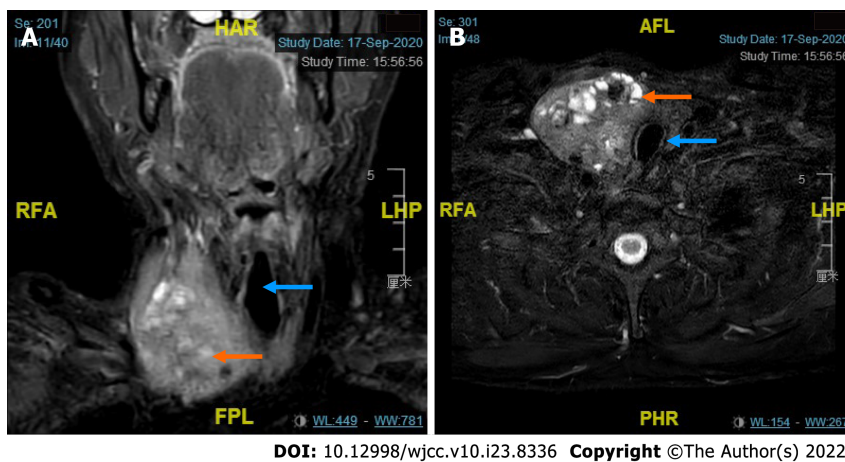
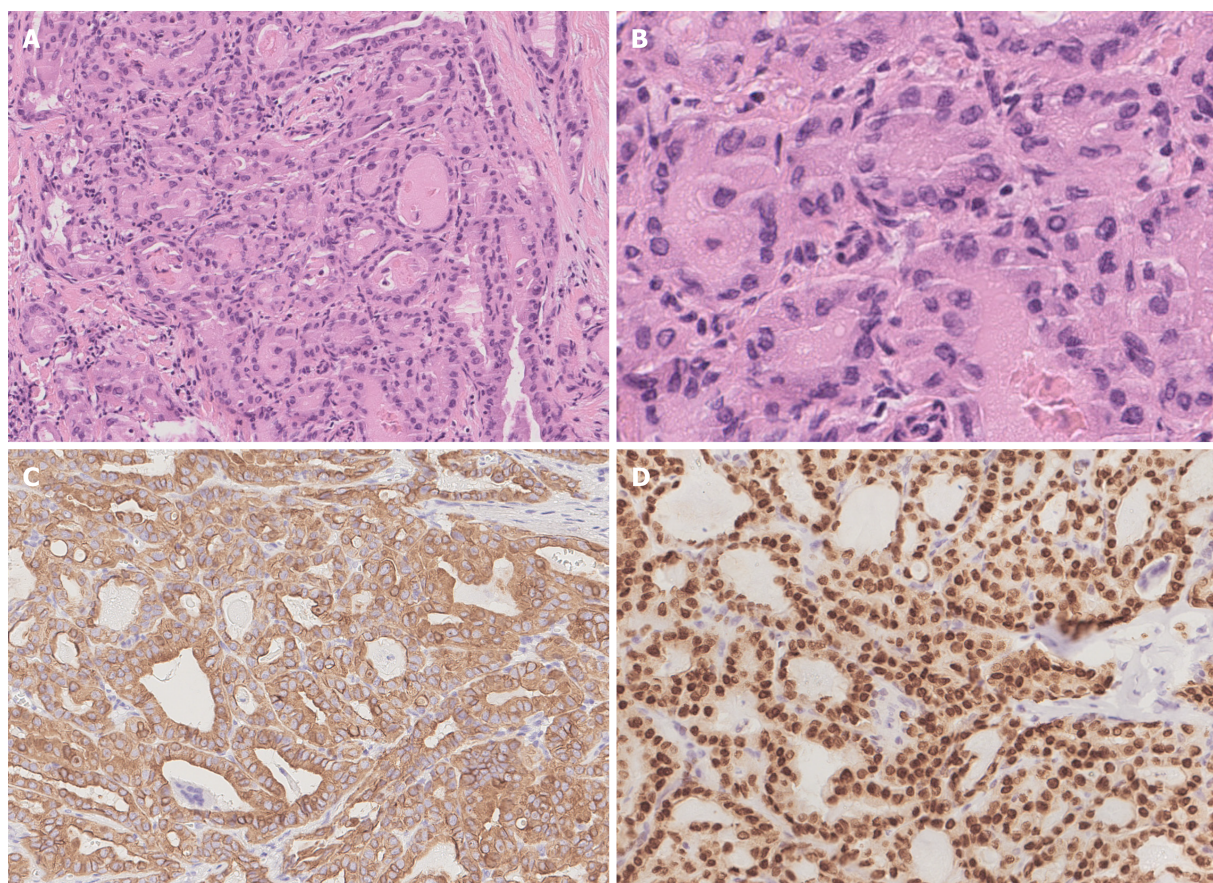


Figure 2 Cervical magnetic resonance imaging of the patient revealing an enlarged thyroid mass. A and B: Coronal and transverse magnetic resonance imaging showing that the enlarged right-sided thyroid nodule (orange arrow) pushed the trachea (blue arrow) to the left.

data. Nicola *et al*[6] reported the case of one patient who had PTC with synovial sarcoma. The patient underwent total thyroidectomy and was free of disease postoperatively. We also found a Chinese case report written by Wang *et al*[9] that described a patient with coexisting PTC and UPS. In this patient, UPS was detected 4 years after thyroidectomy for PTC, and in the UPS tissue, a small papillary lesion was observed, which was defined as tumor-to-tumor metastasis, an uncommon situation in which one tumor metastasizes to a second biologically unrelated primary tumor at the same site[10]. Our patient already presented with both PTC and UPS when it was first discovered, so we could not determine whether tumor-to-tumor metastasis occurred in our case.

The test for 8 gene mutations in this patient included oncogenic mutations (BRAF, NRAS, HRAS, KRAS, and TERT) and chromosome rearrangements (CCDC6-RET, PAX8/PPAR, and EVT6-NTRK3). In our case, the patient had BRAF^{V600E} and TERT^{C228T} gene mutations. The BRAF^{V600E} mutation overstimulates the mitogen-activated protein kinase (MAPK) pathway. The MAPK pathway regulates the expression of several genes associated with proliferation and differentiation[11]. BRAF kinase acts as an intracellular signal transducer in the MAPK pathway. Therefore, the BRAF^{V600E} mutation results in high BRAF^{V600E} kinase activity and can lead to uncontrolled cell proliferation and metastasis[12]. The influence of BRAF on patient outcomes is still inconclusive. Some researchers have pointed out that the BRAF^{V600E} mutation is associated with worse outcomes among PTC patients than other mutations and is also significantly associated with lymph node metastasis, extrathyroidal extension, an advanced disease stage, and a higher recurrence rate[13]. However, some other researchers demonstrated that PTC patients with the BRAF^{V600E} mutation did not have a significantly higher risk for a poor prognosis[14]. These findings suggest that an isolated BRAF mutation is probably not specific for tumor-related mortality. Since thyroid carcinoma patients occasionally have more than one molecular mutation and the behavior of tumors may result from other gene mutations, which are known to lead to aggressive characteristics, a comprehensive discussion of different genes is essential.

Mutations in the telomerase reverse transcriptase promoter (TERT), including TERT^{C228T} or TERT^{C250T}, were first reported in thyroid cancer in 2013 by Liu *et al*[15]. Many studies have been conducted to explore the relationship between a poor prognosis and TERT mutations. TERT is a component of

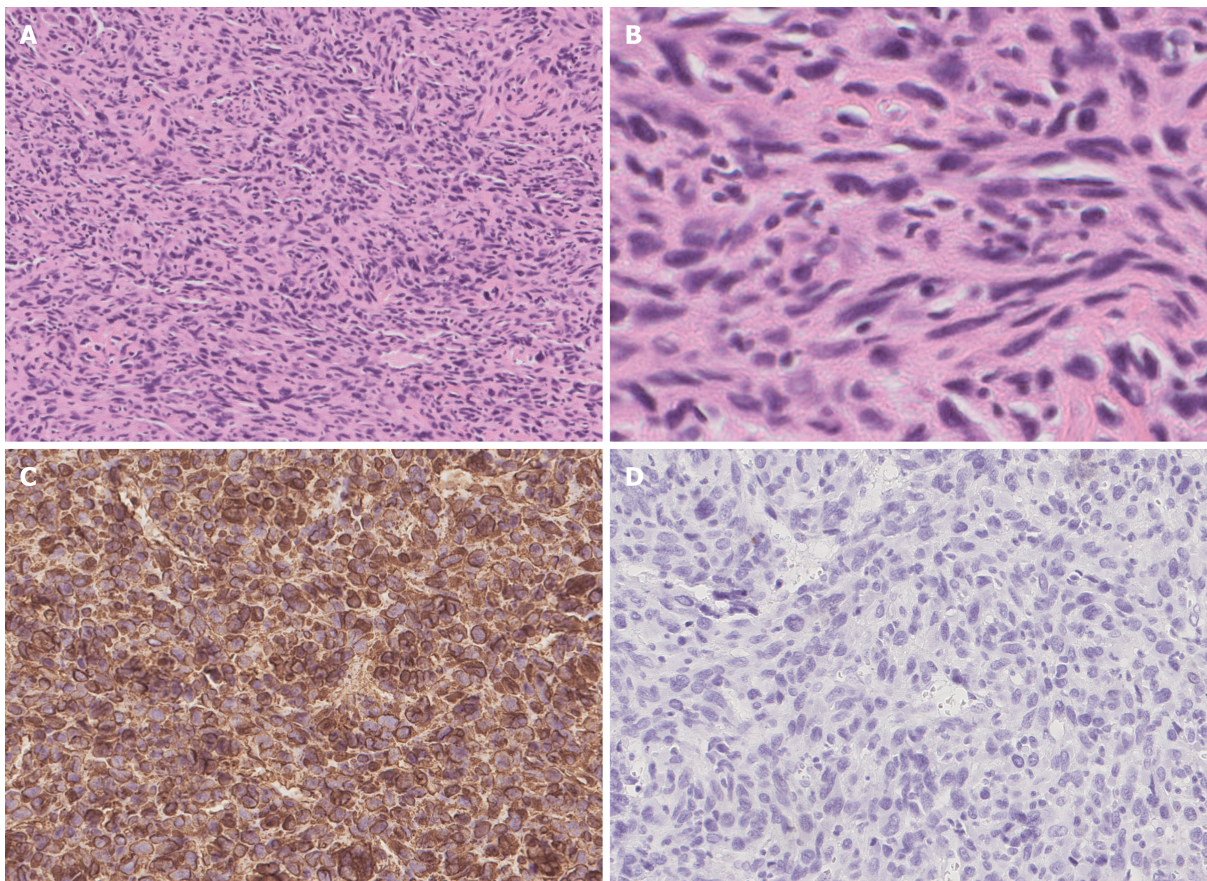


DOI: 10.12998/wjcc.v10.i23.8336 Copyright ©The Author(s) 2022.

Figure 3 Pathological and immunohistochemical characteristics of papillary thyroid cancer. A and B: Tumor cells were arranged in a follicular pattern with enlarged nuclei and irregular nuclear membranes, indicating papillary thyroid cancer (PTC) (A: H&E, × 100; B: H&E, × 400); C: PTC cells were strongly positive for CK19 (IHC, × 200); D: PTC cells were strongly positive for TTF1 (IHC, × 200).

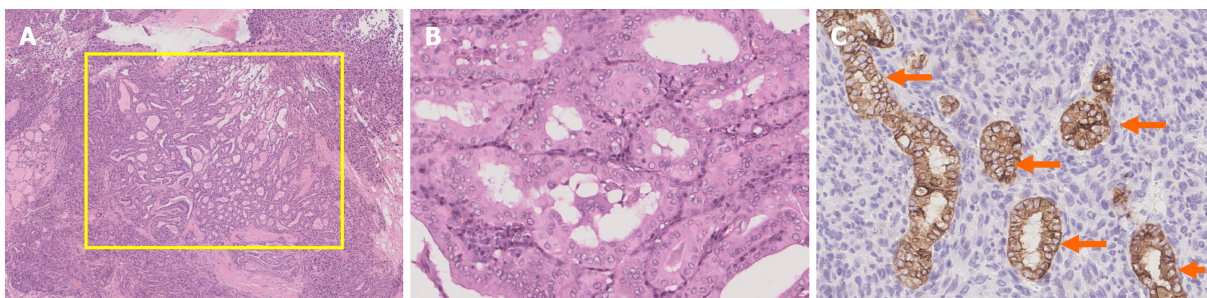
telomerase that adds DNA repeats onto the chromosome. It resynthesizes telomeres to preserve a sufficient telomere length for continued chromosomal replication. Mutation of the TERT promoter prompts TERT transcription, and the unlimited preservation of the telomere length facilitates cancer cell immortality. TERT mutations have been observed in only 10% of well-differentiated PTCs[16] and are associated with factors such as increased age, extrathyroidal invasion, an advanced disease stage at diagnosis, and a dedifferentiated histological type. TERT is also independently associated with PTC dedifferentiation[17]. Several studies have demonstrated the synergistic effects of concomitant mutations of BRAF and TERT. Chen *et al*[14] reported that PTC patients with both BRAF^{V600E} and TERT mutations had an increased risk for a poor prognosis in terms of mortality, disease persistence, and recurrence compared with patients with one gene mutation. In another report, the interaction between BRAF^{V600E} and TERT mutations was studied by transcriptomics[18]. In this study, when the BRAF^{V600E} mutation was present, activation of the MAPK pathway upregulated the expression of the E-twenty-six transcription factor family, which can bind to the mutant TERT promoter and increase TERT transcription[17]. These results explain why cancer-specific mortality is increased in patients with both gene mutations.

No conclusive analysis has been performed of the possible genes associated with UPS. The possible associated mutations described to date are in GNAS, TP53, K-ras, and other genes, such as CSF1R, FGFR3, KDR, APC, PDGFRA, FLT3, ERBB4, KIT, STK11, and RET[19]. Our patient had UPS with BRAF and TERT mutations. Interestingly, studies have shown that high mutant BRAF^{V600E} kinase activity causes genetic instability, and secondary mutation of the phosphoinositide 3-kinase-Akt serine/threonine kinase (PI3K-AKT) pathway occurs, thus leading to further progression of ATC[20]. Since ATC and UPS are both poorly differentiated tumors and have similar histological behaviors, genetic instability caused by BRAF may also lead to the generation of UPS. More research is needed to identify the association between UPS and BRAF and TERT mutations. According to the American Thyroid Association guidelines, treatment for PTC includes surgery, radiotherapy, or chemotherapy. Most PTC patients respond well to surgery and survive long-term. On the other hand, although surgery is the main treatment for UPS, due to the high aggressiveness of the tumor, it is difficult to achieve a satisfactory margin of resection, and there is a high risk of local recurrence[3]. Adjuvant radiotherapy and chemotherapy are typically given after surgery, but no proven benefit has been described[3].



DOI: 10.12998/wjcc.v10.i23.8336 Copyright ©The Author(s) 2022.

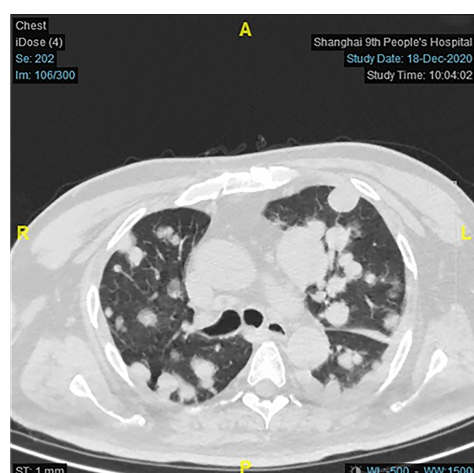
Figure 4 Pathological and immunohistochemical characteristics of undifferentiated pleomorphic sarcoma. A and B: Tumor cells were spindle-shaped, round, and ovoid with irregular nuclei and frequent mitoses (A: H&E, $\times 100$; B: H&E, $\times 400$); C: Tumor cells were strongly positive for vimentin (IHC, $\times 200$); D: Tumor cells were negative for CK19 (IHC, $\times 200$).



DOI: 10.12998/wjcc.v10.i23.8336 Copyright ©The Author(s) 2022.

Figure 5 Pathology result of the right nodule showing both papillary thyroid cancer and undifferentiated pleomorphic sarcoma. A: The papillary component (yellow square) grew within the pleomorphic spindle cell component (H&E, $\times 25$); B: High-power magnification of the yellow-square area in A. In the high-power field, the papillary component showed characteristics of papillary thyroid cancer (PTC) (H&E, $\times 200$); C: CK19 staining showed CK19-positive components (orange arrows), which suggested PTC cells, and the other CK19-negative cells were undifferentiated pleomorphic sarcoma cells (IHC, $\times 200$).

Patients typically die from local recurrence or distant metastasis. Due to the rarity of coexisting PTC and UPS, therapy might be challenging because no treatment recommendations have been made to date. Recently, improvements in molecular diagnostic techniques have helped scientists identify targeted treatments for these patients. These targeted drugs can block the activity of oncogenes by binding to molecules in the signaling pathway associated with cellular differentiation, thus inhibiting tumor progression. Our patient had the BRAF^{V600E} mutation and a TERT mutation, and this pattern of molecular alteration is likely to result in tumor progression. Thus, a more aggressive treatment is needed. When the BRAF^{V600E} mutation is present, the MAPK pathway is overactivated; thus, we hypothesize that tyrosine kinase inhibitors might be effective by suppressing this signaling pathway[1]. A combination of the BRAF inhibitor dabrafenib and the MEK inhibitor trametinib can be considered.



DOI: 10.12998/wjcc.v10.i23.8336 Copyright ©The Author(s) 2022.

Figure 6 Computed tomography of the lung metastasis. Computed tomography three months after surgery showing multiple solid nodules in both lung fields, indicating metastasis, and a larger number of and larger nodules in the left lower lobe. The largest lesion was 25 mm.

This combination is approved by the FDA, and a central radiology review demonstrated an overall response rate of 69% [21]. In one patient, dabrafenib/trametinib therapy was well tolerated, and the patient lived for more than six months [22]. To date, no medications targeting TERT or telomerase have been developed.

CONCLUSION

PTC coexisting with UPS is rare and is first reported in this article. Immunohistochemical tests are crucial for differential diagnosis. Several mutations in important oncogenes, such as BRAF and TERT, may participate in the generation of this tumor. Surgery is the standard treatment for PTC and UPS; however, advanced targeted therapy should be considered for further treatment.

ACKNOWLEDGEMENTS

We express many thanks to the patient for generously authorizing us to share his rare case.

FOOTNOTES

Author contributions: Lee YL collected the data and wrote the paper; Chen YQ was directly responsible for revising the paper; Zhu CF and Huo HZ designed the report and analyzed the data; all authors read and approved the final manuscript.

Informed consent statement: Written informed consent was obtained from the patient and his relatives for publication of this Case report and any accompanying images.

Conflict-of-interest statement: All the authors report no relevant conflicts of interest for this article.

CARE Checklist (2016) statement: The authors have read the CARE Checklist (2016), and the manuscript was prepared and revised according to the CARE Checklist (2016).

Open-Access: This article is an open-access article that was selected by an in-house editor and fully peer-reviewed by external reviewers. It is distributed in accordance with the Creative Commons Attribution NonCommercial (CC BY-NC 4.0) license, which permits others to distribute, remix, adapt, build upon this work non-commercially, and license their derivative works on different terms, provided the original work is properly cited and the use is non-commercial. See: <https://creativecommons.org/licenses/by-nc/4.0/>

Country/Territory of origin: China

ORCID number: Yu-Li Lee 0000-0002-7951-8026; Ya-Qiong Cheng 0000-0002-3324-9262; Chen-Fang Zhu 0000-0003-1588-4905; Hai-Zhong Huo 0000-0002-1573-9655.

S-Editor: Xing YX

L-Editor: A

P-Editor: Xing YX

REFERENCES

- 1 **Cabanillas ME**, McFadden DG, Durante C. Thyroid cancer. *Lancet* 2016; **388**: 2783-2795 [PMID: [27240885](#) DOI: [10.1016/S0140-6736\(16\)30172-6](#)]
- 2 **Surov A**, Gottschling S, Wienke A, Meyer HJ, Spielmann RP, Dralle H. Primary Thyroid Sarcoma: A Systematic Review. *Anticancer Res* 2015; **35**: 5185-5191 [PMID: [26408676](#)]
- 3 **Chen Q**, Huang Q, Yan JX, Li C, Lang JY. Primary undifferentiated pleomorphic sarcoma of the thyroid: A case report and review of the literature. *Medicine (Baltimore)* 2018; **97**: e9927 [PMID: [29443775](#) DOI: [10.1097/MD.00000000000009927](#)]
- 4 **Giannikaki E**, Mantadakis E, Mamalaki E, Delides G, Samonis G. Metastatic uterine leiomyosarcoma coexisting with papillary carcinoma of the thyroid gland. *Int J Gynecol Cancer* 2006; **16**: 442-445 [PMID: [16445675](#) DOI: [10.1111/j.1525-1438.2006.00201.x](#)]
- 5 **Kefeli M**, Mete O. An unusual malignant thyroid nodule: coexistence of epithelioid angiosarcoma and follicular variant papillary thyroid carcinoma. *Endocr Pathol* 2014; **25**: 350-352 [PMID: [23608996](#) DOI: [10.1007/s12022-013-9243-1](#)]
- 6 **Nicola M**, Onorati M, Bertola G, Collini P, Fasci AI, Di Nuovo F. Primary thyroid biphasic synovial sarcoma and synchronous papillary carcinoma: report of a remarkable case. *Pathologica* 2018; **110**: 106-110 [PMID: [30546147](#)]
- 7 **Aggarwal R**, Rao S, Sarangi R. Primary endobronchial histiocytic sarcoma in a case of papillary carcinoma thyroid: a complex clinical scenario. *J Bronchology Interv Pulmonol* 2014; **21**: 353-357 [PMID: [25321458](#) DOI: [10.1097/LBR.0000000000000114](#)]
- 8 **Hsu KF**, Lin YS, Hsieh CB, Yu JC, Duh QY, Sheu LF, Jen YM, Shih ML. Primary malignant fibrous histiocytoma of the thyroid: review of the literature with two new cases. *Thyroid* 2008; **18**: 51-55 [PMID: [18302518](#) DOI: [10.1089/thy.2007.0096](#)]
- 9 **Wang L**, Zhou Q, Zhang Y, Zhao H, Chang H. A case of papillary thyroid carcinoma metastasized to pleomorphic undifferentiated sarcoma and a clinicopathological observation. *J Clin Exp Pathol* 2016; **32**: 696-697
- 10 **Das S**, Chaudhary N, Ang LC, Megyesi JS. Papillary thyroid carcinoma metastasizing to anaplastic meningioma: an unusual case of tumor-to-tumor metastasis. *Brain Tumor Pathol* 2017; **34**: 130-134 [PMID: [28600666](#) DOI: [10.1007/s10014-017-0289-5](#)]
- 11 **Nikiforov YE**, Nikiforova MN. Molecular genetics and diagnosis of thyroid cancer. *Nat Rev Endocrinol* 2011; **7**: 569-580 [PMID: [21878896](#) DOI: [10.1038/nrendo.2011.142](#)]
- 12 **Haroon Al Rasheed MR**, Xu B. Molecular Alterations in Thyroid Carcinoma. *Surg Pathol Clin* 2019; **12**: 921-930 [PMID: [31672298](#) DOI: [10.1016/j.path.2019.08.002](#)]
- 13 **Lee JH**, Lee ES, Kim YS. Clinicopathologic significance of BRAF V600E mutation in papillary carcinomas of the thyroid: a meta-analysis. *Cancer* 2007; **110**: 38-46 [PMID: [17520704](#) DOI: [10.1002/cncr.22754](#)]
- 14 **Chen B**, Shi Y, Xu Y, Zhang J. The predictive value of coexisting BRAFV600E and TERT promoter mutations on poor outcomes and high tumour aggressiveness in papillary thyroid carcinoma: A systematic review and meta-analysis. *Clin Endocrinol (Oxf)* 2021; **94**: 731-742 [PMID: [32816325](#) DOI: [10.1111/cen.14316](#)]
- 15 **Liu X**, Bishop J, Shan Y, Pai S, Liu D, Murugan AK, Sun H, El-Naggar AK, Xing M. Highly prevalent TERT promoter mutations in aggressive thyroid cancers. *Endocr Relat Cancer* 2013; **20**: 603-610 [PMID: [23766237](#) DOI: [10.1530/ERC-13-0210](#)]
- 16 **Kim TH**, Kim YE, Ahn S, Kim JY, Ki CS, Oh YL, Kim K, Yun JW, Park WY, Choe JH, Kim JH, Kim JS, Kim SW, Chung JH. TERT promoter mutations and long-term survival in patients with thyroid cancer. *Endocr Relat Cancer* 2016; **23**: 813-823 [PMID: [27528624](#) DOI: [10.1530/ERC-16-0219](#)]
- 17 **Oishi N**, Kondo T, Ebina A, Sato Y, Akaishi J, Hino R, Yamamoto N, Mochizuki K, Nakazawa T, Yokomichi H, Ito K, Ishikawa Y, Katoh R. Molecular alterations of coexisting thyroid papillary carcinoma and anaplastic carcinoma: identification of TERT mutation as an independent risk factor for transformation. *Mod Pathol* 2017; **30**: 1527-1537 [PMID: [28731042](#) DOI: [10.1038/modpathol.2017.75](#)]
- 18 **Song YS**, Yoo SK, Kim HH, Jung G, Oh AR, Cha JY, Kim SJ, Cho SW, Lee KE, Seo JS, Park YJ. Interaction of BRAF-induced ETS factors with mutant TERT promoter in papillary thyroid cancer. *Endocr Relat Cancer* 2019; **26**: 629-641 [PMID: [30999281](#) DOI: [10.1530/ERC-17-0562](#)]
- 19 **Sawazaki H**, Tsujita Y, Ito Y. Malignant fibrous histiocytoma arising from the renal capsule and gene mutation screening: A case report. *Urol Case Rep* 2019; **27**: 101004 [PMID: [31641593](#) DOI: [10.1016/j.eucr.2019.101004](#)]
- 20 **Abdullah MI**, Junit SM, Ng KL, Jayapalan JJ, Karikalan B, Hashim OH. Papillary Thyroid Cancer: Genetic Alterations and Molecular Biomarker Investigations. *Int J Med Sci* 2019; **16**: 450-460 [PMID: [30911279](#) DOI: [10.7150/ijms.29935](#)]
- 21 **Subbiah V**, Kreitman RJ, Wainberg ZA, Cho JY, Schellens JHM, Soria JC, Wen PY, Zielinski C, Cabanillas ME, Urbanowitz G, Mookerjee B, Wang D, Rangwala F, Keam B. Dabrafenib and Trametinib Treatment in Patients With Locally Advanced or Metastatic BRAF V600-Mutant Anaplastic Thyroid Cancer. *J Clin Oncol* 2018; **36**: 7-13 [PMID: [29072975](#) DOI: [10.1200/JCO.2017.73.6785](#)]
- 22 **Skwiersky S**, Hevroni G, Singh G, Hope L, Haidary T, Salifu MO, McFarlane SI. Concurrent Anaplastic and Papillary Thyroid Carcinomas: A Case Report. *Am J Med Case Rep* 2020; **8**: 202-205 [PMID: [32432164](#) DOI: [10.12691/ajmcr-8-7-11](#)]



Published by **Baishideng Publishing Group Inc**
7041 Koll Center Parkway, Suite 160, Pleasanton, CA 94566, USA

Telephone: +1-925-3991568

E-mail: bpgoffice@wjgnet.com

Help Desk: <https://www.f6publishing.com/helpdesk>

<https://www.wjgnet.com>

