

# World Journal of *Clinical Cases*

*World J Clin Cases* 2022 August 16; 10(23): 8057-8431



## Contents

Thrice Monthly Volume 10 Number 23 August 16, 2022

## OPINION REVIEW

- 8057** Invasive intervention timing for infected necrotizing pancreatitis: Late invasive intervention is not late for collection

*Xiao NJ, Cui TT, Liu F, Li W*

- 8063** Clinical utility of left atrial strain in predicting atrial fibrillation recurrence after catheter ablation: An up-to-date review

*Yu ZX, Yang W, Yin WS, Peng KX, Pan YL, Chen WW, Du BB, He YQ, Yang P*

## MINIREVIEWS

- 8076** Gut microbiota and COVID-19: An intriguing pediatric perspective

*Valentino MS, Esposito C, Colosimo S, Caprio AM, Puzone S, Guarino S, Marzuillo P, Miraglia del Giudice E, Di Sessa A*

- 8088** Beta receptor blocker therapy for the elderly in the COVID-19 era

*Santillo E, Migale M*

## ORIGINAL ARTICLE

## Retrospective Cohort Study

- 8097** Nonselective beta-blocker use is associated with increased hepatic encephalopathy-related readmissions in cirrhosis

*Fallahzadeh MA, Asrani SK, Tapper EB, Saracino G, Rahimi RS*

## Retrospective Study

- 8107** Different squatting positions after total knee arthroplasty: A retrospective study

*Li TJ, Sun JY, Du YQ, Shen JM, Zhang BH, Zhou YG*

- 8115** Outcomes of seromuscular bladder augmentation compared with standard bladder augmentation in the treatment of children with neurogenic bladder

*Sun XG, Li YX, Ji LF, Xu JL, Chen WX, Wang RY*

- 8124** Distinctive clinical features of spontaneous pneumoperitoneum in neonates: A retrospective analysis

*Kim SH, Cho YH, Kim HY*

- 8133** Cognitive training for elderly patients with early Alzheimer's disease in the Qinghai-Tibet Plateau: A pilot study

*Wang XH, Luo MQ*

- 8141** Diagnostic value of elevated serum carbohydrate antigen 125 level in sarcoidosis

*Zhang Q, Jing XY, Yang XY, Xu ZJ*

- 8152** Evaluation of progressive early rehabilitation training mode in intensive care unit patients with mechanical ventilation

*Qie XJ, Liu ZH, Guo LM*

- 8161** Comparison of demographic features and laboratory parameters between COVID-19 deceased patients and surviving severe and critically ill cases

*Wang L, Gao Y, Zhang ZJ, Pan CK, Wang Y, Zhu YC, Qi YP, Xie FJ, Du X, Li NN, Chen PF, Yue CS, Wu JH, Wang XT, Tang YJ, Lai QQ, Kang K*

### Clinical Trials Study

- 8170** Role of H<sub>2</sub>receptor blocker famotidine over the clinical recovery of COVID-19 patients: A randomized controlled trial

*Mohiuddin Chowdhury ATM, Kamal A, Abbas MKU, Karim MR, Ali MA, Talukder S, Hamidullah Mehedi HM, Hassan H, Shahin AH, Li Y, He S*

### Observational Study

- 8186** Short-term prognostic factors for hepatitis B virus-related acute-on-chronic liver failure

*Ye QX, Huang JF, Xu ZJ, Yan YY, Yan Y, Liu LG*

- 8196** Three-dimensional psychological guidance combined with evidence-based health intervention in patients with liver abscess treated with ultrasound

*Shan YN, Yu Y, Zhao YH, Tang LL, Chen XM*

- 8205** Role of serum  $\beta$ 2-microglobulin, glycosylated hemoglobin, and vascular endothelial growth factor levels in diabetic nephropathy

*Yang B, Zhao XH, Ma GB*

### SYSTEMATIC REVIEWS

- 8212** Gallbladder neuroendocrine carcinoma diagnosis, treatment and prognosis based on the SEER database: A literature review

*Cai XC, Wu SD*

### CASE REPORT

- 8224** Sepsis complicated with secondary hemophagocytic syndrome induced by giant gouty tophi rupture: A case report

*Lai B, Pang ZH*

- 8232** Spontaneous remission of autoimmune pancreatitis: Four case reports

*Zhang BB, Huo JW, Yang ZH, Wang ZC, Jin EH*

- 8242** Epstein-Barr-virus-associated hepatitis with aplastic anemia: A case report

*Zhang WJ, Wu LQ, Wang J, Lin SY, Wang B*

- 8249** Aspiration as the first-choice procedure for airway management in an infant with large epiglottic cysts: A case report

*Zheng JQ, Du L, Zhang WY*

- 8255** Sequential multidisciplinary minimally invasive therapeutic strategy for heart failure caused by four diseases: A case report  
*Zhao CZ, Yan Y, Cui Y, Zhu N, Ding XY*
- 8262** Primary ascending colon cancer accompanying skip metastases in left shoulder skin and left neck lymph node: A case report  
*Zhou JC, Wang JJ, Liu T, Tong Q, Fang YJ, Wu ZQ, Hong Q*
- 8271** Clinical and genetic study of ataxia with vitamin E deficiency: A case report  
*Zhang LW, Liu B, Peng DT*
- 8277** Complete resection of large-cell neuroendocrine and hepatocellular carcinoma of the liver: A case report  
*Noh BG, Seo HI, Park YM, Kim S, Hong SB, Lee SJ*
- 8284** Immunotherapy combined with antiangiogenic agents in patients with advanced malignant pleural mesothelioma: A case report  
*Xuan TT, Li GY, Meng SB, Wang ZM, Qu LL*
- 8291** Bladder malacoplakia: A case report  
*Wang HK, Hang G, Wang YY, Wen Q, Chen B*
- 8298** Delayed inflammatory response evoked in nasal alloplastic implants after COVID-19 vaccination: A case report  
*Seo MG, Choi EK, Chung KJ*
- 8304** Phosphoglyceride crystal deposition disease requiring differential diagnosis from malignant tumors and confirmed by Raman spectroscopy: A case report  
*Ohkura Y, Uruga H, Shiiba M, Ito S, Shimoyama H, Ishihara M, Ueno M, Udagawa H*
- 8312** Vulvovaginal myeloid sarcoma with massive pelvic floor infiltration: A case report and review of literature  
*Wang JX, Zhang H, Ning G, Bao L*
- 8323** Femoral neck stress fracture and medial tibial stress syndrome following high intensity interval training: A case report and review of literature  
*Tan DS, Cheung FM, Ng D, Cheung TLA*
- 8330** Periosteal chondroma of the rib: A case report  
*Gao Y, Wang JG, Liu H, Gao CP*
- 8336** Papillary thyroid carcinoma occurring with undifferentiated pleomorphic sarcoma: A case report  
*Lee YL, Cheng YQ, Zhu CF, Huo HZ*
- 8344** Laparoscopic treatment of bilateral duplex kidney and ectopic ureter: A case report  
*Wang SB, Wan L, Wang Y, Yi ZJ, Xiao C, Cao JZ, Liu XY, Tang RP, Luo Y*
- 8352** Incontinentia pigmenti with intracranial arachnoid cyst: A case report  
*Li WC, Li ML, Ding JW, Wang L, Wang SR, Wang YY, Xiao LF, Sun T*

- 8360** Relapsing polychondritis causing breathlessness: Two case reports  
*Zhai SY, Zhang YH, Guo RY, Hao JW, Wen SX*
- 8367** Endodontic management of a fused left maxillary second molar and two paramolars using cone beam computed tomography: A case report  
*Mei XH, Liu J, Wang W, Zhang QX, Hong T, Bai SZ, Cheng XG, Tian Y, Jiang WK*
- 8375** Infant biliary cirrhosis secondary to a biliary inflammatory myofibroblastic tumor: A case report and review of literature  
*Huang Y, Shu SN, Zhou H, Liu LL, Fang F*
- 8384** Metastatic low-grade endometrial stromal sarcoma with variable morphologies in the ovaries and mesentery: A case report  
*Yu HY, Jin YL*
- 8392** Bronchogenic cysts with infection in the chest wall skin of a 64-year-old asymptomatic patient: A case report  
*Ma B, Fu KW, Xie XD, Cheng Y, Wang SQ*
- 8400** Incidental accumulation of Technetium-99m pertechnetate in subacute cerebral infarction: A case report  
*Han YH, Jeong HJ, Kang HG, Lim ST*
- 8406** Metal stent combined with ileus drainage tube for the treatment of delayed rectal perforation: A case report  
*Cheng SL, Xie L, Wu HW, Zhang XF, Lou LL, Shen HZ*
- 8417** Using ketamine in a patient with a near-occlusion tracheal tumor undergoing tracheal resection and reconstruction: A case report  
*Xu XH, Gao H, Chen XM, Ma HB, Huang YG*

**LETTER TO THE EDITOR**

- 8422** Reflections on the prevalence of human leukocyte antigen-B27 and human leukocyte antigen-B51 co-occurrence in patients with spondylarthritis  
*Gonçalves Júnior J, Sampaio-Barros PD, Shinjo SK*
- 8425** Comment on "Disease exacerbation is common in inflammatory bowel disease patients treated with immune checkpoint inhibitors for malignancy"  
*Argyriou K, Kotsakis A*
- 8428** Intranasal sufentanil combined with intranasal dexmedetomidine: A promising method for non-anesthesiologist sedation during endoscopic ultrasonography  
*Wang Y, Ge ZJ, Han C*

**ABOUT COVER**

Editorial Board Member of *World Journal of Clinical Cases*, Peng Liang, MD, Associate Professor, Day Surgery Center, Department of Anesthesiology, West China Hospital of Sichuan University, Chengdu 610041, Sichuan Province, China. 39485572@qq.com

**AIMS AND SCOPE**

The primary aim of *World Journal of Clinical Cases* (WJCC, *World J Clin Cases*) is to provide scholars and readers from various fields of clinical medicine with a platform to publish high-quality clinical research articles and communicate their research findings online.

WJCC mainly publishes articles reporting research results and findings obtained in the field of clinical medicine and covering a wide range of topics, including case control studies, retrospective cohort studies, retrospective studies, clinical trials studies, observational studies, prospective studies, randomized controlled trials, randomized clinical trials, systematic reviews, meta-analysis, and case reports.

**INDEXING/ABSTRACTING**

The WJCC is now abstracted and indexed in Science Citation Index Expanded (SCIE, also known as SciSearch®), Journal Citation Reports/Science Edition, Current Contents®/Clinical Medicine, PubMed, PubMed Central, Scopus, Reference Citation Analysis, China National Knowledge Infrastructure, China Science and Technology Journal Database, and Superstar Journals Database. The 2022 Edition of Journal Citation Reports® cites the 2021 impact factor (IF) for WJCC as 1.534; IF without journal self cites: 1.491; 5-year IF: 1.599; Journal Citation Indicator: 0.28; Ranking: 135 among 172 journals in medicine, general and internal; and Quartile category: Q4. The WJCC's CiteScore for 2021 is 1.2 and Scopus CiteScore rank 2021: General Medicine is 443/826.

**RESPONSIBLE EDITORS FOR THIS ISSUE**

Production Editor: Hua-Ge Yin; Production Department Director: Xiang Li; Editorial Office Director: Jin-Lei Wang.

**NAME OF JOURNAL**

*World Journal of Clinical Cases*

**ISSN**

ISSN 2307-8960 (online)

**LAUNCH DATE**

April 16, 2013

**FREQUENCY**

Thrice Monthly

**EDITORS-IN-CHIEF**

Bao-Gan Peng, Jerzy Tadeusz Chudek, George Kontogeorgos, Maurizio Serati, Ja Hyeon Ku

**EDITORIAL BOARD MEMBERS**

<https://www.wjgnet.com/2307-8960/editorialboard.htm>

**PUBLICATION DATE**

August 16, 2022

**COPYRIGHT**

© 2022 Baishideng Publishing Group Inc

**INSTRUCTIONS TO AUTHORS**

<https://www.wjgnet.com/bpg/gerinfo/204>

**GUIDELINES FOR ETHICS DOCUMENTS**

<https://www.wjgnet.com/bpg/GerInfo/287>

**GUIDELINES FOR NON-NATIVE SPEAKERS OF ENGLISH**

<https://www.wjgnet.com/bpg/gerinfo/240>

**PUBLICATION ETHICS**

<https://www.wjgnet.com/bpg/GerInfo/288>

**PUBLICATION MISCONDUCT**

<https://www.wjgnet.com/bpg/gerinfo/208>

**ARTICLE PROCESSING CHARGE**

<https://www.wjgnet.com/bpg/gerinfo/242>

**STEPS FOR SUBMITTING MANUSCRIPTS**

<https://www.wjgnet.com/bpg/GerInfo/239>

**ONLINE SUBMISSION**

<https://www.f6publishing.com>

# Incontinentia pigmenti with intracranial arachnoid cyst: A case report

Wen-Chao Li, Man-Li Li, Jiang-Wei Ding, Lei Wang, Shu-Ren Wang, Yang-Yang Wang, Li-Fei Xiao, Tao Sun

**Specialty type:** Medicine, research and experimental

**Provenance and peer review:**

Unsolicited article; Externally peer reviewed.

**Peer-review model:** Single blind

**Peer-review report's scientific quality classification**

Grade A (Excellent): 0

Grade B (Very good): B

Grade C (Good): 0

Grade D (Fair): 0

Grade E (Poor): 0

**P-Reviewer:** Surani S, United States

**Received:** March 13, 2022

**Peer-review started:** March 13, 2022

**First decision:** June 16, 2022

**Revised:** June 25, 2022

**Accepted:** July 5, 2022

**Article in press:** July 5, 2022

**Published online:** August 16, 2022



**Wen-Chao Li, Jiang-Wei Ding, Lei Wang, Yang-Yang Wang, Li-Fei Xiao, Tao Sun**, Department of Neurosurgery, General Hospital of Ningxia Medical University, Yinchuan 750000, Ningxia Hui Autonomous Region, China

**Wen-Chao Li, Shu-Ren Wang**, Department of Neurosurgery, The First Affiliated Hospital of Xinxiang Medical University, Xinxiang 453000, Henan Province, China

**Man-Li Li**, Department of Physiology, Sanquan College of Xinxiang Medical University, Xinxiang 453000, Henan Province, China

**Corresponding author:** Tao Sun, Doctor, Chief Doctor, Department of Neurosurgery, General Hospital of Ningxia Medical University, No. 804 Shengli South Street, Xingqing District, Yinchuan 750000, Ningxia Hui Autonomous Region, China. [suntao\\_nxmu@163.com](mailto:suntao_nxmu@163.com)

## Abstract

### BACKGROUND

Incontinentia pigmenti (IP) is a rare X-linked dominant genetic disorder that can be fatal in male infants. It is a disease that affects many systems of the human body. In addition to characteristic skin changes, patients may also have pathological features of the eyes, teeth, and central nervous system. Therefore, the lesions in these systems may be the first symptoms for which patients seek treatment. To date, no cases of IP complicated by intracranial arachnoid cyst (IAC) have been reported. This paper aims to report a case of IP with IAC in order to share the diagnosis and treatment experience of this rare case with other clinicians.

### CASE SUMMARY

An 11-year-old female patient suffered intermittent limb convulsions for five months and was sent to hospital. In the initial stage, the patient was considered to have primary epilepsy. Further investigation of the patient's medical history, physical examination and imaging examination led to the diagnosis of IP combined with intracranial space-occupying lesions, and secondary epilepsy. The patient was treated with craniotomy, and postoperative pathology revealed an IAC. The patient recovered well after craniotomy and had no obvious surgery-related complications. During the follow-up period, the patient did not have recurrent epilepsy symptoms.

### CONCLUSION

IP is a multi-system disease that presents with typical skin lesions at birth, but the

long-term prognosis of this disease depends on the involvement of systems other than the skin, especially nervous system and ocular lesions.

**Key Words:** Incontinentia pigmenti; Intracranial space-occupying lesions; X-linked; Craniotomy; Case report

©The Author(s) 2022. Published by Baishideng Publishing Group Inc. All rights reserved.

**Core Tip:** We report a rare case of incontinentia pigmenti (IP) with an intracranial arachnoid cyst (IAC). The initial diagnosis in this patient was considered to be primary epilepsy. Following admission, her medical history, physical examination and imaging examination led to the diagnosis of IP complicated by intracranial space-occupying lesions and was treated by craniotomy. Postoperative pathology revealed an IAC. During follow-up, the patient recovered well and did not experience recurrence of epilepsy. By recording the diagnosis and treatment history of this patient in detail, and reviewing relevant literature, discussing the characteristics of patients with IP and IAC will help to improve diagnosis and treatment, and improve the overall quality of life of such patients.

**Citation:** Li WC, Li ML, Ding JW, Wang L, Wang SR, Wang YY, Xiao LF, Sun T. Incontinentia pigmenti with intracranial arachnoid cyst: A case report. *World J Clin Cases* 2022; 10(23): 8352-8359

**URL:** <https://www.wjgnet.com/2307-8960/full/v10/i23/8352.htm>

**DOI:** <https://dx.doi.org/10.12998/wjcc.v10.i23.8352>

## INTRODUCTION

Incontinentia pigmenti (IP) or Bloch-Sulzberger syndrome, is a rare X-linked dominant inherited systemic disease affecting primarily the skin but also other neuroectodermal tissues such as teeth, hair, eyes, and the central nervous system. IP is the consequence of a mutation in the *IKBKG* gene (formerly known as NEMO or nuclear factor kappa essential modulator). Because it is an X-linked dominant disorder, it is usually fatal in males and is therefore only seen in female infants. In addition reports suggest that the incidence of IP is 0.7 per 100000 individuals[1,2].

IP with intracranial space-occupying lesions is extremely rare. To date, no cases of IP with an intracranial arachnoid cyst (IAC) have been reported. We here report the first case of IP with an IAC in order to share our experience in managing patients with IP with IAC and help improve diagnosis and treatment and improve the overall quality of life of such patients.

## CASE PRESENTATION

### Chief complaints

An 11-year-old female patient was sent to the emergency department due to intermittent limb convulsions for 5 mo and loss of consciousness with limb twitching for 1 h.

### History of present illness

The patient was sent to the emergency department of the First Affiliated Hospital of Xinxiang Medical University for treatment due to a sudden loss of consciousness with limb twitching for 1 h. The patient presented with sudden epilepsy symptoms without obvious inducement 5 mo ago, and the specific manifestations included turning up of the eyes, twitching of the limbs, no foaming at the mouth, and no incontinence. The above symptoms were relieved without treatment after approximately 30 s. Limb movement was subsequently normal, and there were no residual symptoms such as headache and dizziness. Over the past 5 mo, there were 4 intermittent attacks. The patient was hospitalized for treatment.

### History of past illness

Approximately 10 d after birth, she developed a rash on her body, and with advance of age, her skin color gradually deepened. At present, the child's psychomotor development showed no obvious abnormalities compared with normal children of the same age.

### Personal and family history

The father was healthy, and the mother also had similar skin lesions in childhood, which almost

completely disappeared around the age of 8 years. At present, only a small area of pigmentation remains on the inner side of her left forearm. The mother denied a history of exposure to radioactive substances during pregnancy and a history of taking medication. However, she had a previous miscarriage (details unknown).

### **Physical examination**

Her vital signs were stable. Consciousness, fluent language, memory, calculation, comprehension, judgment, and orientation tests were basically normal. Limb muscle strength was grade 5, and muscle tone was normal; physiological reflex was present, but pathological reflex was not elicited. Ink-splattered and streak-like brown hyperpigmentation was observed all over the trunk and extremities (Figure 1).

### **Laboratory examinations**

The white blood cell count on routine blood testing was slightly increased ( $12.2 \times 10^9/L$ ). The results of other routine laboratory biochemical tests showed no abnormalities.

### **Imaging examinations**

Preoperative magnetic resonance imaging (MRI) revealed a large, circular, homogeneous sac-like signal in the right frontal brain area, approximately  $49.3 \text{ mm} \times 58.5 \text{ mm} \times 54.0 \text{ mm}$ , with clear boundaries, and the adjacent brain sulci were compressed and narrowed, and the right lateral ventricle was deformed due to compression. Diffusion weighted images showed a low signal, and no obvious enhancement on the enhanced scan. A small patchy long T1-weighted imaging and long T2-weighted imaging signal was observed next to the posterior horn of the right lateral ventricle, and T2 fluid-attenuated inversion recovery showed a slightly high signal, and no obvious enhancement was found on the enhanced scan. Radiological diagnosis of the right frontal lobe revealed a cystic mass, which suggested an IAC; small ischemic foci next to the posterior horn of the right lateral ventricle were noted (Figure 2). Considering that the disease can involve multiple organ systems in the body, we performed chest X-ray and abdominal plain computed tomography (CT) scans before surgery, and no lesions were found.

---

## **FINAL DIAGNOSIS**

---

The patient was diagnosed with IP and IAC.

---

## **TREATMENT**

---

A multidisciplinary consultation with a pediatrician and a dermatologist was initially conducted to confirm the patient's diagnosis. After further evaluation of the patient's condition, exclusion of surgical contraindications, and active preoperative preparation, a craniotomy was then performed. During the operation, the skin and subcutaneous tissue were incised along the marked line, the skin flap was turned over, and the bone window size was approximately  $5.0 \times 6.0 \text{ cm}$ . A radial incision of the dura mater revealed an arachnoid cyst with high tension and local arachnoid thickening. The cyst wall was intact and accompanied by hyperplasia of blood vessels. The excised cyst wall was sent to the pathology department for examination. The cyst and subarachnoid space were thoroughly communicated, and the dura mater was sutured and the bone flap was reset after the instruments were checked. The skin was sutured layer by layer. Infusions and epilepsy prevention, and other related treatments were administered after the operation.

---

## **OUTCOME AND FOLLOW-UP**

---

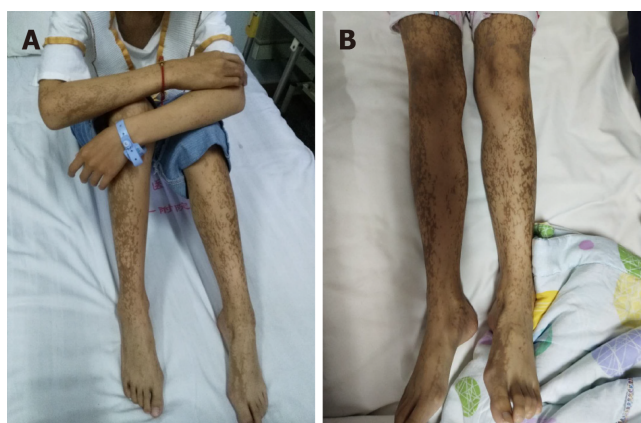Pathological examination of the tissue was performed. The results showed that gray tissue with a diameter of 0.2 cm was observed. Immunohistochemical results revealed an arachnoid cyst (Figure 3). Postoperative head CT was performed (Figure 4). Head MRI was also performed during follow-up and the local bone of the right frontal area showed postoperative changes, and the cystic shadow in the surgical area was significantly smaller than that before surgery at approximately  $23.8 \text{ mm} \times 30.0 \text{ mm} \times 28.5 \text{ mm}$  (Figure 5).

---

## **DISCUSSION**

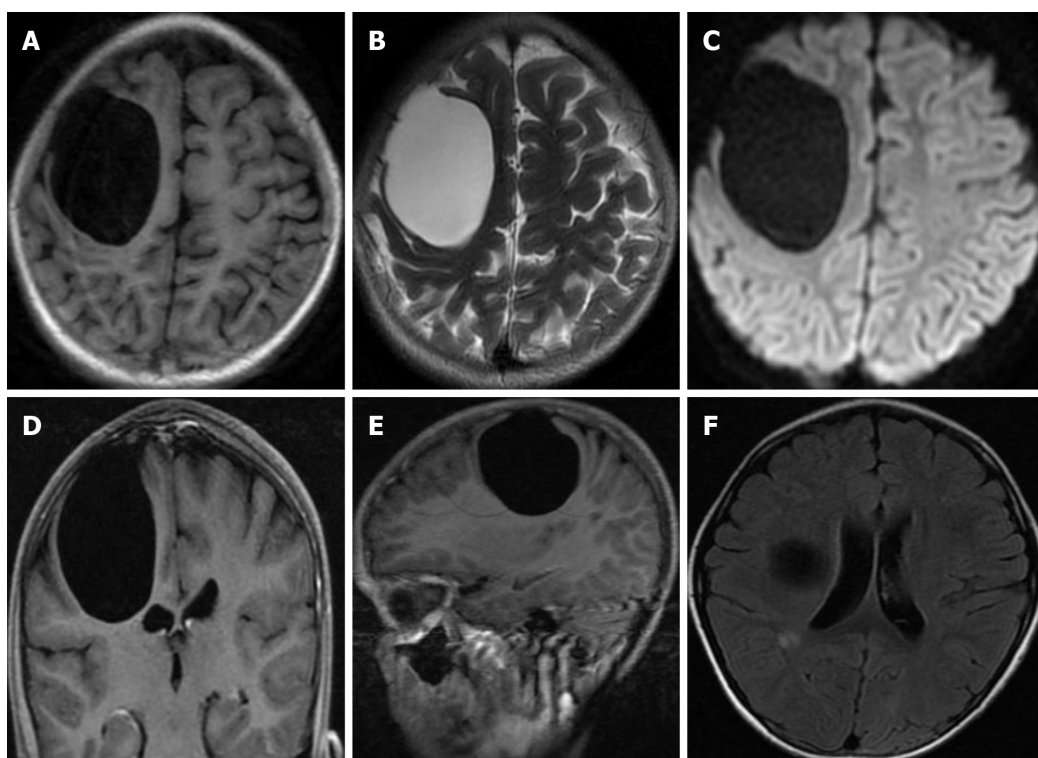
---

Incontinentia pigmenti (IP) is a rare systemic disease involving multiple organ systems. The disease was



DOI: 10.12998/wjcc.v10.i23.8352 Copyright ©The Author(s) 2022.

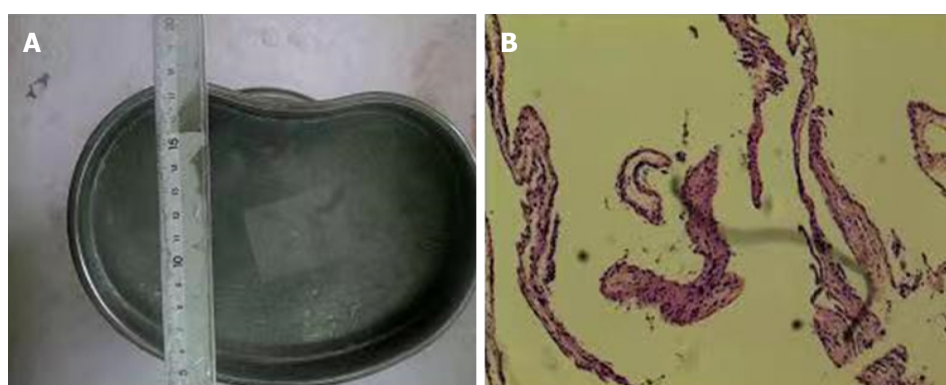
**Figure 1 Presentation at the initial clinic visit.** A: Ink-splattered and streak-like brown hyperpigmentation all over the trunk and extremities; B: Linear lesion of the lower limbs and feet with hyperpigmentation.



DOI: 10.12998/wjcc.v10.i23.8352 Copyright ©The Author(s) 2022.

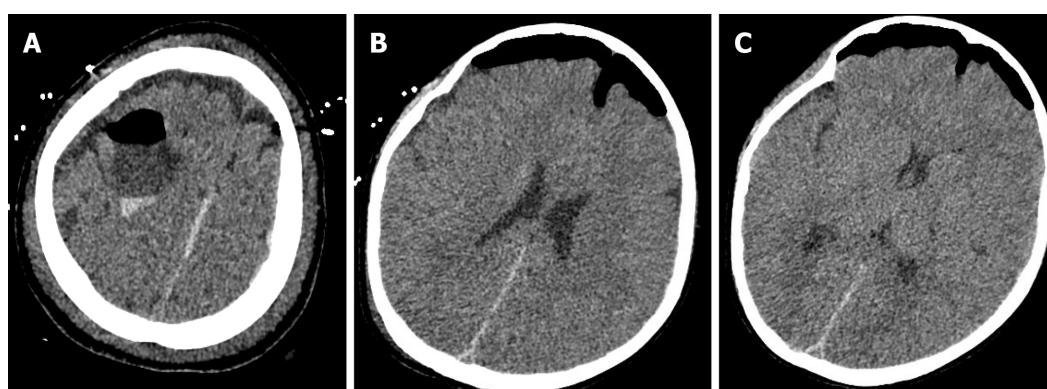
**Figure 2 Preoperative magnetic resonance imaging examination.** A: A large, circular, homogeneous sac-like signal was observed in the right frontal brain area, approximately 49.3 mm × 58.5 mm × 54.0 mm, with clear boundaries, and the adjacent brain sulci were compressed and narrowed. Long T1-weighted imaging (T1WI) magnetic resonance imaging (MRI) signal showed a capsule shadow; B: Long T2-weighted imaging (T2WI) MRI signal showed a capsule shadow; C: Diffusion weighted imaging images showed a low signal; D: The right lateral ventricle was deformed by compression; E: with no obvious enhancement on the enhanced scan; F: There was a small patchy long T1WI and long T2WI signal next to the posterior horn of the right lateral ventricle, T2 fluid-attenuated inversion recovery showed a slightly high signal, and no obvious enhancement was found on the enhanced scan. Radiological diagnosis of the right frontal lobe was a cystic mass, which was considered a possible intracranial arachnoid cyst, and small ischemic foci next to the posterior horn of the right lateral ventricle were noted.

first reported by Bloch in 1926, and was further described by Sulzberger in 1982; thus, it is also called Bloch-Sulzberger syndrome[2,3]. Recent studies have shown that neonatal IP is caused by mutation of the *NEMO* gene located on chromosome Xq28, and the most common mutation type is deletion of *NEMO* Δ 4-10. It is also due to the particularity of the genetic mode of the disease itself that male children inherit homozygous IP, so in most cases of male fetuses, miscarriage or stillbirth may occur during pregnancy. Therefore, in clinical practice, the disease is more common in female children, and the hospital visit rate is higher than that of male children[4-6]. Our female patient had IP complicated with intracranial space-occupying lesions. Her mother had a history of miscarriage in the past, and she



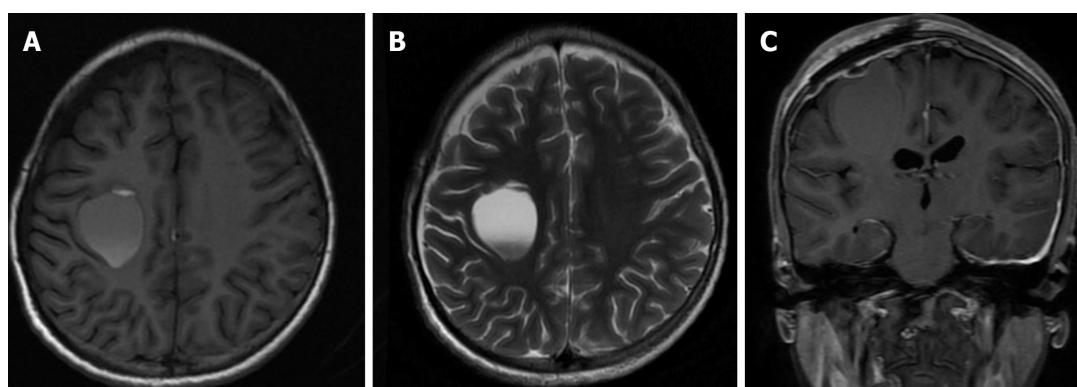
DOI: 10.12998/wjcc.v10.i23.8352 Copyright ©The Author(s) 2022.

**Figure 3** Pathological examination of the tumor tissue. A: Gray tissue with a diameter of 0.2 cm was observed; B: Immunohistochemical results revealed an arachnoid cyst on hematoxylin-eosin staining.



DOI: 10.12998/wjcc.v10.i23.8352 Copyright ©The Author(s) 2022.

**Figure 4** Postoperative head computed tomography. A: The local bone of the right frontal area showed postoperative changes; B: The pressure in the arachnoid cyst was released; C: Right lateral ventricle and the brain tissue that was compressed and deformed before surgery gradually rebounded.



DOI: 10.12998/wjcc.v10.i23.8352 Copyright ©The Author(s) 2022.

**Figure 5** Imaging changes during patient follow-up. A: Magnetic resonance imaging (MRI) examination show the cystic shadow in the surgical area was significantly smaller than that before surgery; B: Long T2-weighted imaging MRI signal showed a capsule shadow and was approximately 23.8 mm × 30.0 mm × 28.5 mm; C: Lateral ventricle and the brain tissue that was compressed before surgery further rebounded.

stated that the possibility of a male fetus was high, but the specific situation could not be verified. The overall situation was consistent with the epidemiology of the disease. We believe that this is the first case of IP with an IAC. This patient was initially misdiagnosed with primary epilepsy. The final diagnosis was IP with IAC based on further investigation of the patient's medical history, physical examination, imaging examination and postoperative pathology.

At present, IP is diagnosed using internationally recognized standards. The main indicators in patients with no previous positive family history are as follows: (1) Typical erythroid blisters in the

neonatal period, and the blisters contain eosinophilia; (2) Pigmentation with a linear distribution on the trunk; and (3) Linear skin atrophy and other signs. Secondary indicators include the following aspects: (1) Baldness; (2) Abnormal teeth; (3) Retinopathy; and (4) Abnormal nails. The main diagnostic criteria for those with a positive family history are as follows: (1) Presence of pigmentation; (2) Skin and hair damage; (3) Abnormal teeth; (4) Baldness; (5) Retinopathy; and (6) Evidence of multiple pregnancy and male abortion. The comprehensive clinical diagnostic criteria are as follows: For those with no positive family history, one major diagnostic indicator and one secondary indicator are required to support the diagnosis. If there is a definite positive family history, the diagnosis can be made with only one clinical criterion[7,8].

The characteristic rash is the main clinical manifestation of IP, which often occurs at birth and in infancy. It can be roughly divided into phase I to IV. The first period is also known as lupus erythematosus blister, in which skin lesions usually occur at birth or within 2 wk after birth, and are characterized by pimples, erythema, blisters, rash along the inside of the limbs and the trunk with a linear lateral distribution. No bacteria are present in the blister fluid, but it does contain a large number of eosinophils. Skin histopathological findings have suggested typical eosinophilic sponge edema. The second period is also known as the verrucous hyperplasia period, in which an excrescence rash is formed combined with different degrees of pigmentation. Histological examination results showed stratum spinosum hypertrophy, often occurring 2-6 wk after birth. The third period is pigmentation, in which skin damage occurs more than 12-26 wk after birth. This period is characterized by pigmentation and a splash-ink swirl pattern. Histological examination revealed dermal melanin cell infiltration. The fourth period is also known as atrophic pigment loss, during which skin macular atrophy, pigmentation and atrophy of skin hair loss occur. The skin lesions in the above stages may overlap but may be alleviated to some extent with age[9,10]. In the present case, typical rashes of stages I, II and III were present, but stage III was the main manifestation at presentation, and no obvious overlap was observed.

Damage and deformity of the central nervous system is one of other major clinical manifestations in children with IP. A considerable number of children seek treatment for neurological diseases with head symptoms. In this case, the patient sought treatment due to frequent epileptic seizures, showing consistency. According to previous reports, the incidence of neurological involvement in neonatal IP children is 18%-32% [11,12]. At present, the pathogenic mechanism of central nervous system damage in children with IP is unclear, and the possibility of vasogenic damage and an inflammatory mechanism is reasonably strong. In addition, the occurrence time and disease type of neurological damage in IP children vary, and the clinical manifestations of neurological damage can be epilepsy, acute disseminated encephalomyelitis and ischemic stroke. Epilepsy can be the first symptom of the disease. The head imaging performed during hospitalization showed that the patient had intracranial space-occupying lesions and ischemic foci. The occurrence of these lesions coincides strikingly with the epidemiology of IP.

The rash in some children only appears in the neonatal period and gradually subsides after 1-2 years, which was consistent with the course of disease development of the mother in this case. In recessive children, epilepsy symptoms such as seizures with unknown causes are often misdiagnosed as primary epilepsy. However, routine treatment of such epilepsy symptoms with sodium valproate has no definite clinical effect. Therefore, it is suggested that the possibility of IP should be considered in children with convulsions without obvious cause, especially female children with a history of specific rash. In addition, systemic damage amongst IP children includes the eyes, teeth, hair, bones, finger (toe) and other areas, mainly manifested as strabismus, unexplained visual loss, cataract, optic nerve atrophy, retinal detachment, absence of teeth, tooth deformity, tooth loss, teeth misalignment, short stature, saggy wrists, saddle head and horseshoe inside turned foot[5,6,10-12].

As mentioned earlier, IP is a multi-system disease that presents with typical skin lesions at birth, but the long-term prognosis of this disease depends on the involvement of systems other than the skin, especially the nervous system and ocular lesions. In this case, intracranial space-occupying lesions were present. Combined with her clinical symptoms, signs, and preoperative imaging examinations, it was suggested that an arachnoid cyst was likely. After clear indications for surgery and exclusion of contraindications to surgery, the patient underwent a craniotomy. Combined with the postoperative pathological results, the diagnosis of IAC was confirmed. An IAC is now considered an external brain parenchymal, non-oncologic space-occupying lesion. Most scholars believe that the formation mechanism of IAC is during the early stage of arachnoid development and dura stratification. Cerebrospinal fluid (CSF) flow is damaged, and CSF constantly impinges on the lumen formed through the rupture site. In addition, there are factors secondary to trauma, including inflammation, infection, intracranial hematoma and other factors[13]. What is the probability of developing an IAC in patients with IP? By reviewing previous literature, we do not have a clear answer at this time and further research is required.

A small IAC can have no obvious clinical symptoms. However, with the gradual increase in size of the cyst, increased compression of adjacent brain tissue, blood vessels and nerves can hinder circulation of the CSF and gradually increase corresponding intracranial pressure, cranial enlargement, epilepsy, cranial nerve compression and other symptoms. Since Howship's report in 1819 and Bright's report in 1931, the diagnosis and treatment of IAC has had a history of more than 70 years, but the treatment of arachnoid cyst, especially the choice of surgical method, is controversial in the medical field. Surgical

treatment of an arachnoid cyst aims to relieve the symptoms of the cyst itself on adjacent brain tissue, nerves and blood vessels, promote the recovery of brain tissue, improve clinical symptoms and reduce the recurrence rate of IAC as far as possible. At present, the main surgical methods include craniotomy for arachnoid cyst, microscopic resection of the capsule wall with communication in the subarachnoid space, a cyst peritoneal shunt, and endoscopic fistula[14-18].

Surgical intervention in the treatment of IAC is not only confined to restoring brain anatomy, but to also provide an effective treatment, recovery and safeguard normal neural physiological function. On this basis, the lumen of the adjacent subarachnoid communication adequately (pool) circulates the CSF, eventually eliminating symptoms and preventing recurrence. Holst *et al*[19] pointed out that a cyst-peritoneal shunt can rapidly reduce the size of the cyst and is beneficial to the recovery of compressed brain tissue, making it an effective surgical method.

Traditional craniotomy for arachnoid cyst excision has been widely used in clinical practice, and it has the advantages of full decompression, accurate curative effect and complete hemostasis. However, complete removal of the cyst is difficult due to the close adhesion between the cyst wall and adjacent brain tissues, blood vessels and nerves. Regeneration of the residual cyst wall and re-closure of the cyst wall can significantly increase the rate of IAC recurrence. However, microscopic resection of the cyst wall and the opening of the arachnoid cistern around the cyst can be performed. On the basis of partial resection of the IAC, the adjacent arachnoid cistern is communicated. Compared with the simple arachnoid cyst-peritoneal shunt, it is more in line with the physiological circulation of CSF. Moreover, because it has the advantage of not relying on the shunt device, it avoids the complications related to the postoperative shunt tube. Compared with traditional craniotomy cyst excision, neurosurgeons can more clearly explore the relationship between the IAC and surrounding tissues during microscopic surgery and the cyst can be excised more safely and effectively. In addition, the entire cyst wall does not need to be removed, thereby reducing the damage caused by separation of the cyst wall.

Finally, we chose this surgical plan based on the clinical symptoms, imaging manifestations and wishes of the child's family members. Intraoperative neuroelectrophysiological monitoring was performed to further avoid related neurological function damage.

## CONCLUSION

In summary, IP is a systemic multi-system disease characterized by skin lesions, and the long-term prognosis of this disease depends on the involvement of other systems aside from the skin, especially nervous system and ocular involvement. In terms of treatment, there is currently no cure for the skin lesions of it. If the lesions in other systems other than the skin system are cured, there is usually no discomfort. Therefore, for patients with IP incontinentia pigmenti, clinicians and doctors generally focus on symptomatic treatment, and give priority to the treatment of critical symptoms. The patient recovered well after surgery and did not develop recurrent epilepsy symptoms.

## FOOTNOTES

**Author contributions:** Li WC and Wang SR were the patient's neurosurgeons, reviewed the literature and contributed to manuscript drafting; Ding JW and Li ML contributed to manuscript drafting; Xiao LF, Wang YY and Wang L analyzed and interpreted the imaging findings; Sun Tao was responsible for revision of the manuscript for important intellectual content; all authors have read and approved the final manuscript.

**Supported by** the National Science Fund Subsidized Project, No. 81971085.

**Informed consent statement:** Informed written consent was obtained from the patient for publication of this report and any accompanying images.

**Conflict-of-interest statement:** All authors declare that they have no conflict of interest.

**CARE Checklist (2016) statement:** The authors have read the CARE Checklist (2016). The manuscript was prepared and revised according to the CARE Checklist (2016).

**Open-Access:** This article is an open-access article that was selected by an in-house editor and fully peer-reviewed by external reviewers. It is distributed in accordance with the Creative Commons Attribution NonCommercial (CC BY-NC 4.0) license, which permits others to distribute, remix, adapt, build upon this work non-commercially, and license their derivative works on different terms, provided the original work is properly cited and the use is non-commercial. See: <https://creativecommons.org/licenses/by-nc/4.0/>

**Country/Territory of origin:** China

**ORCID number:** Wen-Chao Li 0000-0002-9388-9261; Man-Li Li 0000-0002-3019-6142; Jiang-Wei Ding 0000-0002-3231-

9679; Lei Wang 0000-0002-7449-0570; Shu-Ren Wang 0000-0002-1465-7746; Yang-Yang Wang 0000-0001-5810-8928; Li-Fei Xiao 0000-0003-2094-3615; Tao Sun 0000-0001-8062-3432.

**S-Editor:** Wang LL

**L-Editor:** A

**P-Editor:** Wang LL

## REFERENCES

- 1 **Smahi A**, Courtois G, Vabres P, Yamaoka S, Heuertz S, Munnich A, Israël A, Heiss NS, Klauck SM, Kioschis P, Wiemann S, Poustka A, Esposito T, Bardaro T, Gianfrancesco F, Ciccociola A, D'Urso M, Woffendin H, Jakins T, Donnai D, Stewart H, Kenwick SJ, Aradhya S, Yamagata T, Levy M, Lewis RA, Nelson DL. Genomic rearrangement in NEMO impairs NF-kappaB activation and is a cause of incontinentia pigmenti. The International Incontinentia Pigmenti (IP) Consortium. *Nature* 2000; **405**: 466-472 [PMID: 10839543 DOI: 10.1038/35013114]
- 2 **Cai YR**, Liang Y, Zhong X. Late contralateral recurrence of retinal detachment in incontinentia pigmenti: A case report. *World J Clin Cases* 2022; **10**: 4171-4176 [PMID: 35665106 DOI: 10.12998/wjcc.v10.i13.4171]
- 3 **Nirmalasari DA**, Tabri F, Waspodo N, Rimayani S, Adriani A. Incontinentia pigmenti / Bloch-Sulzberger syndrome: a case report. *Acta Dermatovenereol Alp Pannonica Adriat* 2022; **31**: 39-41 [PMID: 35339131]
- 4 **Chambelland A**, Aubert H, Bourrat E, Morice-Picard F, Puzenat E, Lacour JP, Chavierini C; Société française de dermatologie pédiatrique research group. Incontinentia pigmenti in boys: Causes and consequences. *Ann Dermatol Venerol* 2020; **147**: 188-193 [PMID: 31982174 DOI: 10.1016/j.annder.2019.07.007]
- 5 **Sun S**, Li F, Liu Y, Qu H, Wong SW, Zeng L, Yu M, Feng H, Liu H, Han D. A novel inhibitor of nuclear factor kappa-B kinase subunit gamma mutation identified in an incontinentia pigmenti patient with syndromic tooth agenesis. *Arch Oral Biol* 2019; **101**: 100-107 [PMID: 30913450 DOI: 10.1016/j.archoralbio.2019.03.013]
- 6 **Frost M**, Tencerova M, Andreassen CM, Andersen TL, Ejersted C, Svaneby D, Qui W, Kassem M, Zarei A, McAlister WH, Veis DJ, Whyte MP, Frederiksen AL. Absence of an osteopetrosis phenotype in IKBKG (NEMO) mutation-positive women: A case-control study. *Bone* 2019; **121**: 243-254 [PMID: 30659980 DOI: 10.1016/j.bone.2019.01.014]
- 7 **Cammarata-Scalisi F**, Fusco F, Ursini MV. Incontinentia Pigmenti. *Actas Dermosifiliogr (Engl Ed)* 2019; **110**: 273-278 [PMID: 30660327 DOI: 10.1016/j.ad.2018.10.004]
- 8 **Minić S**, Trpinac D, Obradović M. Incontinentia pigmenti diagnostic criteria update. *Clin Genet* 2014; **85**: 536-542 [PMID: 23802866 DOI: 10.1111/cge.12223]
- 9 **Habeshian KA**, Kirkorian AY. Congenital Pigmentary Anomalies in the Newborn. *Neoreviews* 2021; **22**: e660-e672 [PMID: 34599064 DOI: 10.1542/neo.22-10-e660]
- 10 **Ni Y**, Huang X, Ruan L, Xue K, Yu J, Peng J, Zhao P. Intravitreal injection of ranibizumab in severe retinopathy of incontinentia pigmenti. *J AAPOS* 2018; **22**: 325-327.e3 [PMID: 29630932 DOI: 10.1016/j.jaapos.2018.01.008]
- 11 **Greene-Roethke C**. Incontinentia Pigmenti: A Summary Review of This Rare Ectodermal Dysplasia With Neurologic Manifestations, Including Treatment Protocols. *J Pediatr Health Care* 2017; **31**: e45-e52 [PMID: 28870493 DOI: 10.1016/j.pedhc.2017.07.003]
- 12 **Hadj-Rabia S**, Froidevaux D, Bodak N, Hamel-Teillac D, Smahi A, Touil Y, Fraïtag S, de Prost Y, Bodemer C. Clinical study of 40 cases of incontinentia pigmenti. *Arch Dermatol* 2003; **139**: 1163-1170 [PMID: 12975158 DOI: 10.1001/archderm.139.9.1163]
- 13 **White ML**, M Das J. Arachnoid Cysts. 2022 Mar 7. In: StatPearls [Internet]. Treasure Island (FL): StatPearls Publishing, 2022 [PMID: 33085419]
- 14 **Werner C**, Mathkour M, Scullen T, Dallapiazza RF, Dumont AS, Maulucci CM. Recurrent arachnoid cysts secondary to spinal adhesive arachnoiditis successfully treated with a ventriculoperitoneal shunt. *Clin Neurol Neurosurg* 2020; **194**: 105835 [PMID: 32305826 DOI: 10.1016/j.clineuro.2020.105835]
- 15 **Lim JW**, Choi SW, Song SH, Kwon HJ, Koh HS, Youm JY. Is arachnoid cyst a static disease? *Childs Nerv Syst* 2019; **35**: 385-388 [PMID: 30209599 DOI: 10.1007/s00381-018-3962-z]
- 16 **Chen B**, Miao Y, Hu Y, Liao Y, Tu M, Yang X, Qiu Y. Rare Intracranial Arachnoid Cyst Distinguishing From Other Benign Cystic Lesions and its Surgical Strategies. *J Craniofac Surg* 2019; **30**: e400-e402 [PMID: 31299791 DOI: 10.1097/scs.0000000000005315]
- 17 **Kim KH**, Lee JY, Phi JH, Cho BK, Shin MS, Kim SK. Neurocognitive profile in children with arachnoid cysts before and after surgical intervention. *Childs Nerv Syst* 2019; **35**: 517-522 [PMID: 30610479 DOI: 10.1007/s00381-018-4026-0]
- 18 **Hayes MJ**, TerMaath SC, Crook TR, Killeffer JA. A Review on the Effectiveness of Surgical Intervention for Symptomatic Intracranial Arachnoid Cysts in Adults. *World Neurosurg* 2019; **123**: e259-e272 [PMID: 30496927 DOI: 10.1016/j.wneu.2018.11.149]
- 19 **Holst AV**, Danielsen PL, Juhler M. Treatment options for intracranial arachnoid cysts: a retrospective study of 69 patients. *Acta Neurochir Suppl* 2012; **114**: 267-270 [PMID: 22327706 DOI: 10.1007/978-3-7091-0956-4\_52]



Published by **Baishideng Publishing Group Inc**  
7041 Koll Center Parkway, Suite 160, Pleasanton, CA 94566, USA

**Telephone:** +1-925-3991568

**E-mail:** [bpgoffice@wjgnet.com](mailto:bpgoffice@wjgnet.com)

**Help Desk:** <https://www.f6publishing.com/helpdesk>

<https://www.wjgnet.com>

