

World Journal of *Clinical Cases*

World J Clin Cases 2022 August 16; 10(23): 8057-8431



Contents

Thrice Monthly Volume 10 Number 23 August 16, 2022

OPINION REVIEW

- 8057** Invasive intervention timing for infected necrotizing pancreatitis: Late invasive intervention is not late for collection

Xiao NJ, Cui TT, Liu F, Li W

- 8063** Clinical utility of left atrial strain in predicting atrial fibrillation recurrence after catheter ablation: An up-to-date review

Yu ZX, Yang W, Yin WS, Peng KX, Pan YL, Chen WW, Du BB, He YQ, Yang P

MINIREVIEWS

- 8076** Gut microbiota and COVID-19: An intriguing pediatric perspective

Valentino MS, Esposito C, Colosimo S, Caprio AM, Puzone S, Guarino S, Marzuillo P, Miraglia del Giudice E, Di Sessa A

- 8088** Beta receptor blocker therapy for the elderly in the COVID-19 era

Santillo E, Migale M

ORIGINAL ARTICLE

Retrospective Cohort Study

- 8097** Nonselective beta-blocker use is associated with increased hepatic encephalopathy-related readmissions in cirrhosis

Fallahzadeh MA, Asrani SK, Tapper EB, Saracino G, Rahimi RS

Retrospective Study

- 8107** Different squatting positions after total knee arthroplasty: A retrospective study

Li TJ, Sun JY, Du YQ, Shen JM, Zhang BH, Zhou YG

- 8115** Outcomes of seromuscular bladder augmentation compared with standard bladder augmentation in the treatment of children with neurogenic bladder

Sun XG, Li YX, Ji LF, Xu JL, Chen WX, Wang RY

- 8124** Distinctive clinical features of spontaneous pneumoperitoneum in neonates: A retrospective analysis

Kim SH, Cho YH, Kim HY

- 8133** Cognitive training for elderly patients with early Alzheimer's disease in the Qinghai-Tibet Plateau: A pilot study

Wang XH, Luo MQ

- 8141** Diagnostic value of elevated serum carbohydrate antigen 125 level in sarcoidosis

Zhang Q, Jing XY, Yang XY, Xu ZJ

- 8152** Evaluation of progressive early rehabilitation training mode in intensive care unit patients with mechanical ventilation

Qie XJ, Liu ZH, Guo LM

- 8161** Comparison of demographic features and laboratory parameters between COVID-19 deceased patients and surviving severe and critically ill cases

Wang L, Gao Y, Zhang ZJ, Pan CK, Wang Y, Zhu YC, Qi YP, Xie FJ, Du X, Li NN, Chen PF, Yue CS, Wu JH, Wang XT, Tang YJ, Lai QQ, Kang K

Clinical Trials Study

- 8170** Role of H₂receptor blocker famotidine over the clinical recovery of COVID-19 patients: A randomized controlled trial

Mohiuddin Chowdhury ATM, Kamal A, Abbas MKU, Karim MR, Ali MA, Talukder S, Hamidullah Mehedi H, Hassan H, Shahin AH, Li Y, He S

Observational Study

- 8186** Short-term prognostic factors for hepatitis B virus-related acute-on-chronic liver failure

Ye QX, Huang JF, Xu ZJ, Yan YY, Yan Y, Liu LG

- 8196** Three-dimensional psychological guidance combined with evidence-based health intervention in patients with liver abscess treated with ultrasound

Shan YN, Yu Y, Zhao YH, Tang LL, Chen XM

- 8205** Role of serum β 2-microglobulin, glycosylated hemoglobin, and vascular endothelial growth factor levels in diabetic nephropathy

Yang B, Zhao XH, Ma GB

SYSTEMATIC REVIEWS

- 8212** Gallbladder neuroendocrine carcinoma diagnosis, treatment and prognosis based on the SEER database: A literature review

Cai XC, Wu SD

CASE REPORT

- 8224** Sepsis complicated with secondary hemophagocytic syndrome induced by giant gouty tophi rupture: A case report

Lai B, Pang ZH

- 8232** Spontaneous remission of autoimmune pancreatitis: Four case reports

Zhang BB, Huo JW, Yang ZH, Wang ZC, Jin EH

- 8242** Epstein-Barr-virus-associated hepatitis with aplastic anemia: A case report

Zhang WJ, Wu LQ, Wang J, Lin SY, Wang B

- 8249** Aspiration as the first-choice procedure for airway management in an infant with large epiglottic cysts: A case report

Zheng JQ, Du L, Zhang WY

- 8255** Sequential multidisciplinary minimally invasive therapeutic strategy for heart failure caused by four diseases: A case report
Zhao CZ, Yan Y, Cui Y, Zhu N, Ding XY
- 8262** Primary ascending colon cancer accompanying skip metastases in left shoulder skin and left neck lymph node: A case report
Zhou JC, Wang JJ, Liu T, Tong Q, Fang YJ, Wu ZQ, Hong Q
- 8271** Clinical and genetic study of ataxia with vitamin E deficiency: A case report
Zhang LW, Liu B, Peng DT
- 8277** Complete resection of large-cell neuroendocrine and hepatocellular carcinoma of the liver: A case report
Noh BG, Seo HI, Park YM, Kim S, Hong SB, Lee SJ
- 8284** Immunotherapy combined with antiangiogenic agents in patients with advanced malignant pleural mesothelioma: A case report
Xuan TT, Li GY, Meng SB, Wang ZM, Qu LL
- 8291** Bladder malacoplakia: A case report
Wang HK, Hang G, Wang YY, Wen Q, Chen B
- 8298** Delayed inflammatory response evoked in nasal alloplastic implants after COVID-19 vaccination: A case report
Seo MG, Choi EK, Chung KJ
- 8304** Phosphoglyceride crystal deposition disease requiring differential diagnosis from malignant tumors and confirmed by Raman spectroscopy: A case report
Ohkura Y, Uruga H, Shiiba M, Ito S, Shimoyama H, Ishihara M, Ueno M, Udagawa H
- 8312** Vulvovaginal myeloid sarcoma with massive pelvic floor infiltration: A case report and review of literature
Wang JX, Zhang H, Ning G, Bao L
- 8323** Femoral neck stress fracture and medial tibial stress syndrome following high intensity interval training: A case report and review of literature
Tan DS, Cheung FM, Ng D, Cheung TLA
- 8330** Periosteal chondroma of the rib: A case report
Gao Y, Wang JG, Liu H, Gao CP
- 8336** Papillary thyroid carcinoma occurring with undifferentiated pleomorphic sarcoma: A case report
Lee YL, Cheng YQ, Zhu CF, Huo HZ
- 8344** Laparoscopic treatment of bilateral duplex kidney and ectopic ureter: A case report
Wang SB, Wan L, Wang Y, Yi ZJ, Xiao C, Cao JZ, Liu XY, Tang RP, Luo Y
- 8352** Incontinentia pigmenti with intracranial arachnoid cyst: A case report
Li WC, Li ML, Ding JW, Wang L, Wang SR, Wang YY, Xiao LF, Sun T

- 8360** Relapsing polychondritis causing breathlessness: Two case reports
Zhai SY, Zhang YH, Guo RY, Hao JW, Wen SX
- 8367** Endodontic management of a fused left maxillary second molar and two paramolars using cone beam computed tomography: A case report
Mei XH, Liu J, Wang W, Zhang QX, Hong T, Bai SZ, Cheng XG, Tian Y, Jiang WK
- 8375** Infant biliary cirrhosis secondary to a biliary inflammatory myofibroblastic tumor: A case report and review of literature
Huang Y, Shu SN, Zhou H, Liu LL, Fang F
- 8384** Metastatic low-grade endometrial stromal sarcoma with variable morphologies in the ovaries and mesentery: A case report
Yu HY, Jin YL
- 8392** Bronchogenic cysts with infection in the chest wall skin of a 64-year-old asymptomatic patient: A case report
Ma B, Fu KW, Xie XD, Cheng Y, Wang SQ
- 8400** Incidental accumulation of Technetium-99m pertechnetate in subacute cerebral infarction: A case report
Han YH, Jeong HJ, Kang HG, Lim ST
- 8406** Metal stent combined with ileus drainage tube for the treatment of delayed rectal perforation: A case report
Cheng SL, Xie L, Wu HW, Zhang XF, Lou LL, Shen HZ
- 8417** Using ketamine in a patient with a near-occlusion tracheal tumor undergoing tracheal resection and reconstruction: A case report
Xu XH, Gao H, Chen XM, Ma HB, Huang YG

LETTER TO THE EDITOR

- 8422** Reflections on the prevalence of human leukocyte antigen-B27 and human leukocyte antigen-B51 co-occurrence in patients with spondylarthritis
Gonçalves Júnior J, Sampaio-Barros PD, Shinjo SK
- 8425** Comment on "Disease exacerbation is common in inflammatory bowel disease patients treated with immune checkpoint inhibitors for malignancy"
Argyriou K, Kotsakis A
- 8428** Intranasal sufentanil combined with intranasal dexmedetomidine: A promising method for non-anesthesiologist sedation during endoscopic ultrasonography
Wang Y, Ge ZJ, Han C

ABOUT COVER

Editorial Board Member of *World Journal of Clinical Cases*, Peng Liang, MD, Associate Professor, Day Surgery Center, Department of Anesthesiology, West China Hospital of Sichuan University, Chengdu 610041, Sichuan Province, China. 39485572@qq.com

AIMS AND SCOPE

The primary aim of *World Journal of Clinical Cases* (WJCC, *World J Clin Cases*) is to provide scholars and readers from various fields of clinical medicine with a platform to publish high-quality clinical research articles and communicate their research findings online.

WJCC mainly publishes articles reporting research results and findings obtained in the field of clinical medicine and covering a wide range of topics, including case control studies, retrospective cohort studies, retrospective studies, clinical trials studies, observational studies, prospective studies, randomized controlled trials, randomized clinical trials, systematic reviews, meta-analysis, and case reports.

INDEXING/ABSTRACTING

The WJCC is now abstracted and indexed in Science Citation Index Expanded (SCIE, also known as SciSearch®), Journal Citation Reports/Science Edition, Current Contents®/Clinical Medicine, PubMed, PubMed Central, Scopus, Reference Citation Analysis, China National Knowledge Infrastructure, China Science and Technology Journal Database, and Superstar Journals Database. The 2022 Edition of Journal Citation Reports® cites the 2021 impact factor (IF) for WJCC as 1.534; IF without journal self cites: 1.491; 5-year IF: 1.599; Journal Citation Indicator: 0.28; Ranking: 135 among 172 journals in medicine, general and internal; and Quartile category: Q4. The WJCC's CiteScore for 2021 is 1.2 and Scopus CiteScore rank 2021: General Medicine is 443/826.

RESPONSIBLE EDITORS FOR THIS ISSUE

Production Editor: Hua-Ge Yin; Production Department Director: Xiang Li; Editorial Office Director: Jin-Lei Wang.

NAME OF JOURNAL

World Journal of Clinical Cases

ISSN

ISSN 2307-8960 (online)

LAUNCH DATE

April 16, 2013

FREQUENCY

Thrice Monthly

EDITORS-IN-CHIEF

Bao-Gan Peng, Jerzy Tadeusz Chudek, George Kontogeorgos, Maurizio Serati, Ja Hyeon Ku

EDITORIAL BOARD MEMBERS

<https://www.wjgnet.com/2307-8960/editorialboard.htm>

PUBLICATION DATE

August 16, 2022

COPYRIGHT

© 2022 Baishideng Publishing Group Inc

INSTRUCTIONS TO AUTHORS

<https://www.wjgnet.com/bpg/gerinfo/204>

GUIDELINES FOR ETHICS DOCUMENTS

<https://www.wjgnet.com/bpg/GerInfo/287>

GUIDELINES FOR NON-NATIVE SPEAKERS OF ENGLISH

<https://www.wjgnet.com/bpg/gerinfo/240>

PUBLICATION ETHICS

<https://www.wjgnet.com/bpg/GerInfo/288>

PUBLICATION MISCONDUCT

<https://www.wjgnet.com/bpg/gerinfo/208>

ARTICLE PROCESSING CHARGE

<https://www.wjgnet.com/bpg/gerinfo/242>

STEPS FOR SUBMITTING MANUSCRIPTS

<https://www.wjgnet.com/bpg/GerInfo/239>

ONLINE SUBMISSION

<https://www.f6publishing.com>



Incidental accumulation of Technetium-99m pertechnetate in subacute cerebral infarction: A case report

Yeon-Hee Han, Hwan-Jeong Jeong, Hyun Goo Kang, Seok Tae Lim

Specialty type: Medicine, research and experimental

Provenance and peer review: Unsolicited article; Externally peer reviewed.

Peer-review model: Single blind

Peer-review report's scientific quality classification

Grade A (Excellent): 0
Grade B (Very good): B, B
Grade C (Good): 0
Grade D (Fair): 0
Grade E (Poor): 0

P-Reviewer: Luo WL, China; Zhang LH, China

Received: April 5, 2022

Peer-review started: April 5, 2022

First decision: June 16, 2022

Revised: June 17, 2022

Accepted: July 5, 2022

Article in press: July 5, 2022

Published online: August 16, 2022



Yeon-Hee Han, Hwan-Jeong Jeong, Seok Tae Lim, Department of Nuclear Medicine, Research Institute of Clinical Medicine of Jeonbuk National University-Biomedical Research Institute of Jeonbuk National University Hospital, Jeonbuk National University Medical School and Hospital, Jeonju 54907, Jeonbuk, South Korea

Hyun Goo Kang, Department of Neurology, Jeonbuk National University Medical School and Hospital, Jeonju 54907, Jeonbuk, South Korea

Corresponding author: Seok Tae Lim, PhD, Professor, Department of Nuclear Medicine, Research Institute of Clinical Medicine of Jeonbuk National University-Biomedical Research Institute of Jeonbuk National University Hospital, Jeonbuk National University Medical School and Hospital, 20 Geonjiro Deokjin-gu, Jeonju 54907, Jeonbuk, South Korea. stlim@jbnu.ac.kr

Abstract

BACKGROUND

When interpreting nuclear medicine images, unexpected findings are sometimes encountered. Recognizing these findings and determining the mechanism of their occurrence could have a significant impact on early diagnosis of critical diseases and the appropriate management of patients.

CASE SUMMARY

A 59-year-old man was admitted to the emergency room due to left hemiparesis, left hemifacial palsy, and mild dysarthria. After 2 wk of hospitalization, the patient complained of dry eyes and mouth. Thus, salivary scintigraphy was performed to evaluate the functional status of his salivary glands. Incidental accumulation in the right frontoparietal area was found on salivary scintigraphy. Fluid-attenuated inversion recovery phase magnetic resonance (FLAIR phase MR) image showed diffuse high signal intensity in the same area. Anterior and posterior horns of the right lateral ventricle were obliterated and the midline was slightly shifted to the left side due to right frontoparietal swelling. On salivary scintigraphy, Tc-99m pertechnetate was incidentally accumulated in a subacute cerebral infarction lesion. Two years after the diagnosis of acute infarction, the second series of salivary scintigraphy showed no abnormal activity in the brain. FLAIR phase MR image also demonstrated markedly decreased high signal intensity in the previous infarction lesion without evidence of swelling indicating chronic cerebral infarction.

CONCLUSION

This case highlights that Tc-99m pertechnetate could accumulate in a subacute

cerebral infarction lesion. The mechanism of an unexpected uptake of Tc-99m pertechnetate in unusual sites should be evaluated and kept in mind for better interpretation.

Key Words: Cerebral infarction; Tc-99m pertechnetate; Salivary scintigraphy; Case report

©The Author(s) 2022. Published by Baishideng Publishing Group Inc. All rights reserved.

Core Tip: Tc-99m pertechnetate is a truly carrier-free radiotracer transported by sodium iodide symporter. Salivary scintigraphy using Tc-99m pertechnetate is frequently performed for diagnosing salivary gland diseases such as Sjogren's syndrome. Here, we present a rare case of Tc-99m pertechnetate accumulation in the subacute cerebral infarction lesion. The reason for Tc-99m pertechnetate accumulation is thought to be due to ingrowth and proliferation of new capillaries with enhanced permeability in the subacute cerebral infarction lesion. The present case highlights that Tc-99m pertechnetate could accumulate in a subacute cerebral infarction lesion. The mechanisms of an unexpected uptake of Tc-99m pertechnetate in unusual sites should be evaluated and kept in mind for better interpretation.

Citation: Han YH, Jeong HJ, Kang HG, Lim ST. Incidental accumulation of Technetium-99m pertechnetate in subacute cerebral infarction: A case report. *World J Clin Cases* 2022; 10(23): 8400-8405

URL: <https://www.wjgnet.com/2307-8960/full/v10/i23/8400.htm>

DOI: <https://dx.doi.org/10.12998/wjcc.v10.i23.8400>

INTRODUCTION

When interpreting nuclear medicine images, unexpected findings are sometimes encountered. Recognizing these findings and determining the mechanism of their occurrence could have a great impact on early diagnosis of critical disease and appropriate management of patients. Tc-99m pertechnetate is one of the most common and widely used radiotracers in the nuclear medicine department. Although it is mostly used in combination with other pharmaceuticals, free Tc-99m pertechnetate itself is also used to evaluate thyroid and salivary gland function and to detect ectopic gastric mucosa in Meckel's diverticulum. Salivary scintigraphy using Tc-99m pertechnetate provides a series of processes in which saliva is produced and excreted. Therefore, it can evaluate saliva production and excretory functions of major salivary glands such as the parotid and submandibular glands in various salivary gland diseases such as radiation sialoadenitis and Sjogren's syndrome. Here, we present the first case of a subacute cerebral infarction demonstrating an unexpected uptake of Tc-99m pertechnetate on salivary scintigraphy.

CASE PRESENTATION

Chief complaints

A 59-year-old man was admitted to the emergency room because of left hemiparesis, left hemifacial palsy, and mild dysarthria.

History of present illness

After 2 wk of hospitalization, the patient's symptoms of dry eyes and mouth started and worsened as time went by.

History of past illness

The patient had no previous medical history.

Personal and family history

There was no specific family history.

Physical examination

The patient had a body temperature of 36.1 °C, a heart rate of 54 bpm, a respiratory rate of 18 breaths per minute, a blood pressure of 101/61 mmHg, and oxygen saturation in room air of 97%. His mental status was light drowsy. Clinical neurological examination revealed left hemiparesis, left hemifacial palsy, mild dysarthria, and asomatognosia. Our first clinical consideration was an acute cerebral

infarction.

Laboratory examinations

Blood analysis revealed a normal leukocyte count of 7.7×10^9 /L with normal hematocrit and platelet count. Prothrombin time and partial thromboplastin time were normal and d-dimers were increased at 2.38 µg/mL. Serum C-reactive protein was within normal range and erythrocyte sedimentation rate was 10 mm/h. Blood biochemistries and urine analysis results were normal. Electrocardiogram, chest X-ray, and arterial blood gas analysis were also normal. After 2 wk of hospitalization, the patient complained of dry eyes and mouth. Thus further studies were performed. Anti-Ro and anti-La antibodies known to be associated with Sjogren's syndrome, were positive and his Schirmer's test showed a possible shortage of tears.

Imaging examinations

On computed tomography angiography, total obstruction of the right common carotid artery and the M1 portion of the right middle cerebral artery was noted. There was a large acute infarction in the right frontoparietal area on the MR image. Salivary scintigraphy was performed at 2 wk after hospitalization to evaluate functional status of his salivary glands. It demonstrated markedly decreased excretory function of bilateral parotid and submandibular glands, while the uptake ability was relatively preserved. On salivary scintigraphy, an unexpected accumulation of Tc-99m pertechnetate in the right frontoparietal area was also noted (Figure 1). We correlated it with brain magnetic resonance (MR) image. Fluid-attenuated inversion recovery phase MR (FLAIR phase MR) image showed diffuse high signal intensity in the same area (Figure 1). Anterior and posterior horns of the right lateral ventricle were obliterated and the midline was slightly shifted to the left side due to right frontoparietal swelling.

MULTIDISCIPLINARY EXPERT CONSULTATION

Kang HG, MD, PhD, Associate Professor, Department of Neurology, Jeonbuk National University Medical School and Hospital

The patient should undergo immediate transcatheter endovascular thrombectomy of the right common carotid artery with thrombolytic agent as a treatment for acute cerebral infarction.

Han YH, MD, PhD, Fund Professor, Department of Nuclear Medicine, Research Institute of Clinical Medicine of Jeonbuk National University-Biomedical Research Institute of Jeonbuk National University Hospital, Jeonbuk National University Medical School and Hospital

To evaluate his dry eyes and mouth, anti-Ro and anti-La antibodies, Schirmer's test, and salivary scintigraphy using Tc-99m pertechnetate are necessary.

Jeong HJ, Seok Tae Lim, MD, PhD, Professor, Department of Nuclear Medicine, Research Institute of Clinical Medicine of Jeonbuk National University-Biomedical Research Institute of Jeonbuk National University Hospital, Jeonbuk National University Medical School and Hospital

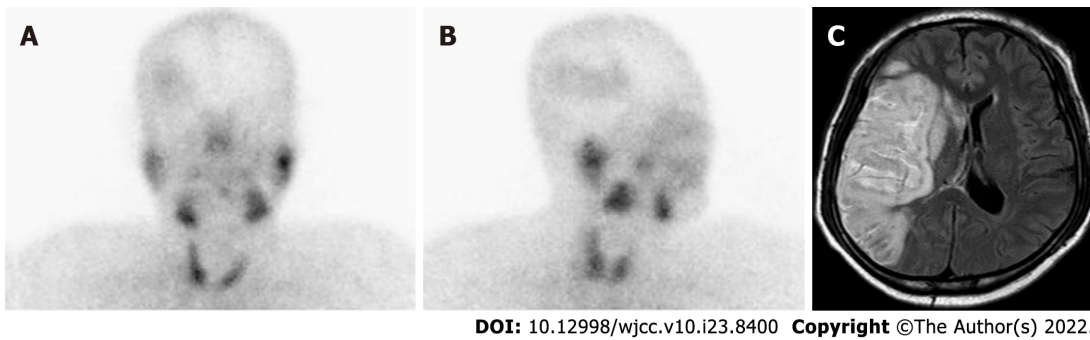
An unexpected accumulation of Tc-99m pertechnetate in the right frontoparietal area was detected. Markedly decreased excretory function of the bilateral parotid and submandibular glands was also noticed suggesting Sjogren's syndrome.

FINAL DIAGNOSIS

The final diagnosis of the presented case was cerebral infarction with unexpected accumulation of Tc-99m pertechnetate in the subacute phase.

TREATMENT

Immediate transcatheter endovascular thrombectomy of the right common carotid artery was performed and a thrombolytic agent was started. The National Institutes of Health stroke scale score was improved from 12 points before thrombectomy to 6 points after thrombectomy and decreased to 3 points after 8 d. After proper management for acute infarction using aspirin, clopidogrel, and mannitol, the patient could walk without assistance of other people. He was independent for most basic activities of daily living, although he might need help with more complex tasks (modified Rankin scale, 3). His eye and mouth dryness also gradually improved after taking pilocarpine, a muscarinic cholinergic agonist. He was discharged after 15 d of hospitalization and regular check-ups were performed in the Departments



DOI: 10.12998/wjcc.v10.i23.8400 Copyright ©The Author(s) 2022.

Figure 1 Salivary scintigraphy and fluid-attenuated inversion recovery phase magnetic resonance image at 2 wk after diagnosis of acute cerebral infarction. A and B: Anterior and right oblique images of salivary scintigraphy show an unexpected accumulation of Tc-99m pertechnetate in the right frontoparietal area; C: Fluid-attenuated inversion recovery phase magnetic resonance image demonstrates diffuse high signal intensity in the same area. Anterior and posterior horns of the right lateral ventricle were obliterated and the midline was slightly shifted to the left side due to right frontoparietal swelling.

of Neurology and Rheumatology.

OUTCOME AND FOLLOW-UP

Two years after the diagnosis of acute infarction, the second series of salivary scintigraphy and brain MR were performed for follow-up evaluation. On salivary scintigraphy, there was no abnormal radioactivity in the brain (Figure 2). FLAIR phase MR image also demonstrated markedly decreased high signal intensity in the previous infarction lesion without evidence of swelling (Figure 2). Informed consent for publication of clinical data was obtained from the patient.

DISCUSSION

Tc-99m pertechnetate is a truly carrier-free radiotracer and transported by the sodium iodide symporter. Therefore, Tc-99m pertechnetate scintigraphy is a powerful imaging modality for assessing sodium iodide symporter activity in various organs[1]. It is widely used to evaluate the function of the thyroid and salivary glands and to detect ectopic gastric mucosa in Meckel's diverticulum[2].

Salivary scintigraphy using Tc-99m pertechnetate provides a series of processes in which saliva is produced and excreted. Therefore, it is used for salivary gland diseases such as radiation sialoadenitis and Sjogren's syndrome to evaluate saliva production and excretory functions of major salivary glands such as the parotid and submandibular glands.

Attempts have been made to localize brain tumors using Tc-99m pertechnetate and Tc-99m labeled phosphate compound from the 1960s to the 1980s[3-4]. However, currently there is no case of using them for such purpose. There are some reports of an unusual uptake of Tc-99m pertechnetate in pediatric Burkitt's lymphoma and in an unilateral breast used predominantly during breastfeeding[5-6]. Uptake mechanisms are thought to be an increased blood pool and a functional overexpression of sodium iodide symporter, respectively.

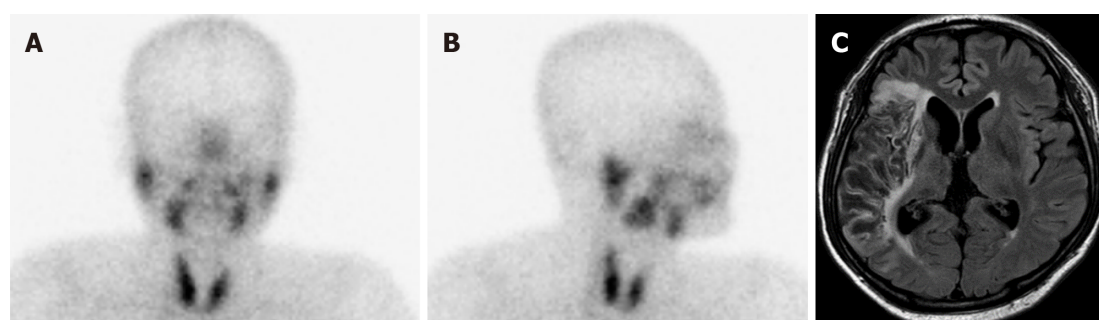
The mechanism of radiotracer localization in a brain lesion can be related to a variety of factors, including increased vascularity, abnormal vascular permeability, edema, and selective cellular metabolism. The underlying mechanism may differ among chemical compounds of the radiotracer and pathologic types of lesions. In our case, the ingrowth and proliferation of new capillaries with enhanced permeability in a subacute cerebral infarction might be the main reason for the accumulation of Tc-99m pertechnetate.

Not many nuclear physicians know that Tc-99m pertechnetate can be taken up by subacute cerebral infarctions. To the best of our knowledge, this is the first report to demonstrate Tc-99m pertechnetate uptake in a subacute cerebral infarction on salivary scintigraphy.

Recognizing these findings and determining the mechanism of their occurrence could make a great impact on early diagnosis of critical disease and appropriate management of patients.

CONCLUSION

This case highlights that Tc-99m pertechnetate could accumulate in a subacute cerebral infarction lesion. The mechanisms of an unexpected uptake of Tc-99m pertechnetate in unusual sites should be evaluated



DOI: 10.12998/wjcc.v10.i23.8400 Copyright ©The Author(s) 2022.

Figure 2 Follow-up salivary scintigraphy and fluid-attenuated inversion recovery phase magnetic resonance image after 2 years. A and B: The second series of salivary scintigraphy shows no abnormal radioactivity in the brain; C: Fluid-attenuated inversion recovery phase magnetic resonance image also demonstrates markedly decreased high signal intensity without evidence of swelling in the previous lesion suggesting chronic infarction.

and kept in mind for better interpretation.

FOOTNOTES

Author contributions: Han YH and Lim ST were nuclear physicians, performed the conceptualization, investigation, and contributed to manuscript drafting; Jeong HJ reviewed the literature and contributed to manuscript editing; Kang HG was a neurophysician and performed the disease consultation and manuscript drafting; Han YH and Lim ST were responsible for the revision of the manuscript for important intellectual content; all authors issued final approval for the version to be submitted.

Informed consent statement: Informed written consent was obtained from the patient for publication of this report and any accompanying images.

Conflict-of-interest statement: All authors declare that they have no conflict of interest.

CARE Checklist (2016) statement: The authors have read the CARE Checklist (2016), and the manuscript was prepared and revised according to the CARE Checklist (2016).

Open-Access: This article is an open-access article that was selected by an in-house editor and fully peer-reviewed by external reviewers. It is distributed in accordance with the Creative Commons Attribution NonCommercial (CC BY-NC 4.0) license, which permits others to distribute, remix, adapt, build upon this work non-commercially, and license their derivative works on different terms, provided the original work is properly cited and the use is non-commercial. See: <https://creativecommons.org/licenses/by-nc/4.0/>

Country/Territory of origin: South Korea

ORCID number: Yeon-Hee Han 0000-0002-7473-2699; Seok Tae Lim 0000-0002-3407-7212.

S-Editor: Wang LL

L-Editor: A

P-Editor: Wang LL

REFERENCES

- 1 **Hingorani M**, Spitzweg C, Vassaux G, Newbold K, Melcher A, Pandha H, Vile R, Harrington K. The biology of the sodium iodide symporter and its potential for targeted gene delivery. *Curr Cancer Drug Targets* 2010; **10**: 242-267 [PMID: 20201784 DOI: 10.2174/156800910791054194]
- 2 **Franken PR**, Guglielmi J, Vanhove C, Koulibaly M, Defrise M, Darcourt J, Pourcher T. Distribution and dynamics of (99m)Tc-pertechnetate uptake in the thyroid and other organs assessed by single-photon emission computed tomography in living mice. *Thyroid* 2010; **20**: 519-526 [PMID: 20384490 DOI: 10.1089/thy.2009.0213]
- 3 **Mori H**, Maeda T, Hisada K, Kobayashi S. Cerebral infarction: a disparity between Tc-99m-pertechnetate and Tc-99m-EHDP images. *Clin Nucl Med* 1980; **5**: 310-312 [PMID: 6771082 DOI: 10.1097/00003072-198007000-00006]
- 4 **McAfee JG**, Fueger CF, Stern HS, Wagner HN Jr, Migita T. Tc99m pertechnetate for brain scanning. *J Nucl Med* 1984; **25**: 385-401 [PMID: 6321702]
- 5 **Cherng SC**, Fan YM, Yu CY, Chu CC, Cheng SN. Incidental accumulation of technetium-99m pertechnetate in pediatric Burkitt's lymphoma with tumor-induced intussusception. *Clin Nucl Med* 2004; **29**: 264-265 [PMID: 15096976 DOI: 10.1097/00003072-200407000-00006]

[10.1097/01.rlu.0000117887.51760.05](https://doi.org/10.1097/01.rlu.0000117887.51760.05)

- 6 **Gayana S**, Bhattacharya A, Kamaleshwaran KK, Mittal BR. Unilateral breast uptake of tc-99m pertechnetate in a patient with cold nodule of the thyroid. *World J Nucl Med* 2012; **11**: 79-80 [PMID: [23372442](https://pubmed.ncbi.nlm.nih.gov/23372442/) DOI: [10.4103/1450-1147.103423](https://doi.org/10.4103/1450-1147.103423)]



Published by **Baishideng Publishing Group Inc**
7041 Koll Center Parkway, Suite 160, Pleasanton, CA 94566, USA

Telephone: +1-925-3991568

E-mail: bpgoffice@wjgnet.com

Help Desk: <https://www.f6publishing.com/helpdesk>

<https://www.wjgnet.com>

