

World Journal of *Clinical Cases*

World J Clin Cases 2022 August 26; 10(24): 8432-8807



Contents

Thrice Monthly Volume 10 Number 24 August 26, 2022

EDITORIAL

- 8432 Evolution of *World Journal of Clinical Cases* over the past 5 years
Muthu S

OPINION REVIEW

- 8436 NF- κ B: A novel therapeutic pathway for gastroesophageal reflux disease?
Zhang ML, Ran LQ, Wu MJ, Jia QC, Qin ZM, Peng YG

MINIREVIEWS

- 8443 Obligate aerobic, gram-positive, weak acid-fast, nonmotile bacilli, *Tsukamurella tyrosinosolvens*: Minireview of a rare opportunistic pathogen
Usuda D, Tanaka R, Suzuki M, Shimozawa S, Takano H, Hotchi Y, Tokunaga S, Osugi I, Katou R, Ito S, Mishima K, Kondo A, Mizuno K, Takami H, Komatsu T, Oba J, Nomura T, Sugita M
- 8450 Diffusion tensor imaging pipeline measures of cerebral white matter integrity: An overview of recent advances and prospects
Safri AA, Nassir CMNCM, Iman IN, Mohd Taib NH, Achuthan A, Mustapha M
- 8463 Graft choices for anterolateral ligament knee reconstruction surgery: Current concepts
Chalidis B, Pitsilos C, Kitridis D, Givissis P
- 8474 Overview of the anterolateral complex of the knee
Garcia-Mansilla I, Zicaro JP, Martinez EF, Astoul J, Yacuzzi C, Costa-Paz M
- 8482 Complication of lengthening and the role of post-operative care, physical and psychological rehabilitation among fibula hemimelia
Salimi M, Sarallah R, Javanshir S, Mirghaderi SP, Salimi A, Khanzadeh S

ORIGINAL ARTICLE

Clinical and Translational Research

- 8490 Pyroptosis-related genes play a significant role in the prognosis of gastric cancer
Guan SH, Wang XY, Shang P, Du QC, Li MZ, Xing X, Yan B

Retrospective Study

- 8506 Effects of propofol combined with lidocaine on hemodynamics, serum adrenocorticotrophic hormone, interleukin-6, and cortisol in children
Shi S, Gan L, Jin CN, Liu RF
- 8514 Correlation analysis of national elite Chinese male table tennis players' shoulder proprioception and muscle strength
Shang XD, Zhang EM, Chen ZL, Zhang L, Qian JH

- 8525** Clinical value of contrast-enhanced ultrasound in early diagnosis of small hepatocellular carcinoma (≤ 2 cm)

Mei Q, Yu M, Chen Q

- 8535** Identification of predictive factors for post-transarterial chemoembolization liver failure in hepatocellular carcinoma patients: A retrospective study

Yuan M, Chen TY, Chen XR, Lu YF, Shi J, Zhang WS, Ye C, Tang BZ, Yang ZG

- 8547** Clinical significance of half-hepatic blood flow occlusion technology in patients with hepatocellular carcinoma with cirrhosis

Liu D, Fang JM, Chen XQ

- 8556** Which octogenarian patients are at higher risk after cholecystectomy for symptomatic gallstone disease? A single center cohort study

D'Acapito F, Solaini L, Di Pietrantonio D, Tauceri F, Mirarchi MT, Antelmi E, Flamini F, Amato A, Framarini M, Ercolani G

Clinical Trials Study

- 8568** Computed tomography combined with gastroscopy for assessment of pancreatic segmental portal hypertension

Wang YL, Zhang HW, Lin F

Observational Study

- 8578** Psychological needs of parents of children with complicated congenital heart disease after admitting to pediatric intensive care unit: A questionnaire study

Zhu JH, Jin CD, Tang XM

Prospective Study

- 8587** Quantitative differentiation of malignant and benign thyroid nodules with multi-parameter diffusion-weighted imaging

Zhu X, Wang J, Wang YC, Zhu ZF, Tang J, Wen XW, Fang Y, Han J

Randomized Controlled Trial

- 8599** Application of unified protocol as a transdiagnostic treatment for emotional disorders during COVID-19: An internet-delivered randomized controlled trial

Yan K, Yusufi MH, Nazari N

- 8615** High-flow nasal cannula oxygen therapy during anesthesia recovery for older orthopedic surgery patients: A prospective randomized controlled trial

Li XN, Zhou CC, Lin ZQ, Jia B, Li XY, Zhao GF, Ye F

SYSTEMATIC REVIEWS

- 8625** Assessment tools for differential diagnosis of neglect: Focusing on egocentric neglect and allocentric neglect

Lee SH, Lim BC, Jeong CY, Kim JH, Jang WH

CASE REPORT

- 8634** Exome analysis for Cronkhite-Canada syndrome: A case report
Li ZD, Rong L, He YJ, Ji YZ, Li X, Song FZ, Li XA
- 8641** Discrepancy between non-invasive prenatal testing result and fetal karyotype caused by rare confined placental mosaicism: A case report
Li Z, Lai GR
- 8648** Paroxysmal speech disorder as the initial symptom in a young adult with anti-N-methyl-D-aspartate receptor encephalitis: A case report
Hu CC, Pan XL, Zhang MX, Chen HF
- 8656** Anesthetics management of a renal angiomyolipoma using pulse pressure variation and non-invasive cardiac output monitoring: A case report
Jeon WJ, Shin WJ, Yoon YJ, Park CW, Shim JH, Cho SY
- 8662** Traumatic giant cell tumor of rib: A case report
Chen YS, Kao HW, Huang HY, Huang TW
- 8667** Analysis of two naval pilots' ejection injuries: Two case reports
Zeng J, Liu XP, Yi JC, Lu X, Liu DD, Jiang YQ, Liu YB, Tian JQ
- 8673** Beware of the DeBakey type I aortic dissection hidden by ischemic stroke: Two case reports
Chen SQ, Luo WL, Liu W, Wang LZ
- 8679** Unilateral lichen planus with Blaschko line distribution: A case report
Dong S, Zhu WJ, Xu M, Zhao XQ, Mou Y
- 8686** Clinical features and progress of ischemic gastritis with high fatalities: Seven case reports
Shionoya K, Sasaki A, Moriya H, Kimura K, Nishino T, Kubota J, Sumida C, Tasaki J, Ichita C, Makazu M, Masuda S, Koizumi K, Kawachi J, Tsukiyama T, Kako M
- 8695** Retinoblastoma in an older child with secondary glaucoma as the first clinical presenting symptom: A case report
Zhang Y, Tang L
- 8703** Recurrent herpes zoster in a rheumatoid arthritis patient treated with tofacitinib: A case report and review of the literature
Lin QX, Meng HJ, Pang YY, Qu Y
- 8709** Intra-abdominal ectopic bronchogenic cyst with a mucinous neoplasm harboring a *GNAS* mutation: A case report
Murakami T, Shimizu H, Yamazaki K, Nojima H, Usui A, Kosugi C, Shuto K, Obi S, Sato T, Yamazaki M, Koda K
- 8718** Effects of intravascular photobiomodulation on motor deficits and brain perfusion images in intractable myasthenia gravis: A case report
Lan CH, Wu YC, Chiang CC, Chang ST

- 8728** Spontaneous acute epidural hematoma secondary to skull and dural metastasis of hepatocellular carcinoma: A case report
Lv GZ, Li GC, Tang WT, Zhou D, Yang Y
- 8735** Malignant melanotic nerve sheath tumors in the spinal canal of psammomatous and non-psammomatous type: Two case reports
Yeom JA, Song YS, Lee IS, Han IH, Choi KU
- 8742** When should endovascular gastrointestinal anastomosis transection Glissonean pedicle not be used in hepatectomy? A case report
Zhao J, Dang YL
- 8749** VARS2 gene mutation leading to overall developmental delay in a child with epilepsy: A case report
Wu XH, Lin SZ, Zhou YQ, Wang WQ, Li JY, Chen QD
- 8755** Junctional bradycardia in a patient with COVID-19: A case report
Aedh AI
- 8761** Application of 3 dimension-printed injection-molded polyether ether ketone lunate prosthesis in the treatment of stage III Kienböck's disease: A case report
Yuan CS, Tang Y, Xie HQ, Liang TT, Li HT, Tang KL
- 8768** High scored thyroid storm after stomach cancer perforation: A case report
Baik SM, Pae Y, Lee JM
- 8775** Cholecystitis-an uncommon complication following thoracic duct embolization for chylothorax: A case report
Dung LV, Hien MM, Tra My TT, Luu DT, Linh LT, Duc NM
- 8782** Endometrial squamous cell carcinoma originating from the cervix: A case report
Shu XY, Dai Z, Zhang S, Yang HX, Bi H
- 8788** Type 2 autoimmune pancreatitis associated with severe ulcerative colitis: Three case reports
Ghali M, Bensted K, Williams DB, Ghaly S
- 8797** Diffuse uterine leiomyomatosis: A case report and review of literature
Ren HM, Wang QZ, Wang JN, Hong GJ, Zhou S, Zhu JY, Li SJ

LETTER TO THE EDITOR

- 8805** Comment on "Posterior reversible encephalopathy syndrome in a patient with metastatic breast cancer: A case report"
Kunić S, Ibrahimagić OČ, Kojić B, Džananović D

ABOUT COVER

Editorial Board Member of *World Journal of Clinical Cases*, Ahmed Mohamed Ahmed Al-Emam, PhD, Associate Professor, Department of Pathology, King Khalid University, Abha 62521, Saudi Arabia. amalemam@kku.edu.sa

AIMS AND SCOPE

The primary aim of *World Journal of Clinical Cases* (WJCC, *World J Clin Cases*) is to provide scholars and readers from various fields of clinical medicine with a platform to publish high-quality clinical research articles and communicate their research findings online.

WJCC mainly publishes articles reporting research results and findings obtained in the field of clinical medicine and covering a wide range of topics, including case control studies, retrospective cohort studies, retrospective studies, clinical trials studies, observational studies, prospective studies, randomized controlled trials, randomized clinical trials, systematic reviews, meta-analysis, and case reports.

INDEXING/ABSTRACTING

The WJCC is now abstracted and indexed in Science Citation Index Expanded (SCIE, also known as SciSearch®), Journal Citation Reports/Science Edition, Current Contents®/Clinical Medicine, PubMed, PubMed Central, Scopus, Reference Citation Analysis, China National Knowledge Infrastructure, China Science and Technology Journal Database, and Superstar Journals Database. The 2022 Edition of Journal Citation Reports® cites the 2021 impact factor (IF) for WJCC as 1.534; IF without journal self cites: 1.491; 5-year IF: 1.599; Journal Citation Indicator: 0.28; Ranking: 135 among 172 journals in medicine, general and internal; and Quartile category: Q4. The WJCC's CiteScore for 2021 is 1.2 and Scopus CiteScore rank 2021: General Medicine is 443/826.

RESPONSIBLE EDITORS FOR THIS ISSUE

Production Editor: *Ying-Yi Yuan*; Production Department Director: *Xu Guo*; Editorial Office Director: *Jin-Lei Wang*.

NAME OF JOURNAL

World Journal of Clinical Cases

ISSN

ISSN 2307-8960 (online)

LAUNCH DATE

April 16, 2013

FREQUENCY

Thrice Monthly

EDITORS-IN-CHIEF

Bao-Gan Peng, Jerzy Tadeusz Chudek, George Kontogeorgos, Maurizio Serati, Ja Hyeon Ku

EDITORIAL BOARD MEMBERS

<https://www.wjgnet.com/2307-8960/editorialboard.htm>

PUBLICATION DATE

August 26, 2022

COPYRIGHT

© 2022 Baishideng Publishing Group Inc

INSTRUCTIONS TO AUTHORS

<https://www.wjgnet.com/bpg/gerinfo/204>

GUIDELINES FOR ETHICS DOCUMENTS

<https://www.wjgnet.com/bpg/GerInfo/287>

GUIDELINES FOR NON-NATIVE SPEAKERS OF ENGLISH

<https://www.wjgnet.com/bpg/gerinfo/240>

PUBLICATION ETHICS

<https://www.wjgnet.com/bpg/GerInfo/288>

PUBLICATION MISCONDUCT

<https://www.wjgnet.com/bpg/gerinfo/208>

ARTICLE PROCESSING CHARGE

<https://www.wjgnet.com/bpg/gerinfo/242>

STEPS FOR SUBMITTING MANUSCRIPTS

<https://www.wjgnet.com/bpg/GerInfo/239>

ONLINE SUBMISSION

<https://www.f6publishing.com>



Graft choices for anterolateral ligament knee reconstruction surgery: Current concepts

Byron Chalidis, Charalampos Pitsilos, Dimitrios Kitridis, Panagiotis Givissis

Specialty type: Medicine, research and experimental

Provenance and peer review: Invited article; Externally peer reviewed.

Peer-review model: Single blind

Peer-review report's scientific quality classification

Grade A (Excellent): 0
Grade B (Very good): B
Grade C (Good): C, C, C, C
Grade D (Fair): 0
Grade E (Poor): 0

P-Reviewer: Cabezuelo AS, Spain; Nambi G, Saudi Arabia; Zhou S, China

Received: March 21, 2022

Peer-review started: March 21, 2022

First decision: June 7, 2022

Revised: June 26, 2022

Accepted: July 18, 2022

Article in press: July 18, 2022

Published online: August 26, 2022



Byron Chalidis, Dimitrios Kitridis, Panagiotis Givissis, 1st Orthopaedic Department, Aristotle University of Thessaloniki, School of Medicine, Thessaloniki 57010, Greece

Charalampos Pitsilos, 2nd Orthopaedic Department, Aristotle University of Thessaloniki, School of Medicine, Thessaloniki 54635, Greece

Corresponding author: Byron Chalidis, MD, PhD, Assistant Professor, 1st Orthopaedic Department, Aristotle University of Thessaloniki, School of Medicine, Exohi, Thessaloniki 57010, Greece. byronchalidis@gmail.com

Abstract

The anterolateral ligament (ALL) is a primary structure of the anterolateral complex of the knee that contributes to internal rotational stability of the joint. Injury of the ALL is commonly associated with rupture of the anterior cruciate ligament. If left untreated, ALL lesions may lead to residual anterolateral rotational instability of the knee after anterior cruciate ligament reconstruction, which is a common cause of anterior cruciate ligament graft failure. The function of the ALL can be restored by lateral extraarticular tenodesis or anterolateral ligament reconstruction (ALLR). In the lateral extraarticular tenodesis procedure, a strip of the iliotibial band is placed in a non-anatomical position to restrain the internal rotation of the tibia, while in ALLR, a free graft is fixed at the insertion points of the native ALL. Gracilis and semitendinosus grafts have mainly been utilized for ALLR, but other autografts have also been suggested. Furthermore, allografts and synthetic grafts have been applied to minimize donor-site morbidity and maximize the size and strength of the graft. Nevertheless, there has been no strong evidence to fully support one method over another thus far. The present review presents a detailed description of the graft choices for ALLR and the current literature available in regard to the effectiveness and outcomes of published surgical techniques.

Key Words: Anterolateral ligament; Reconstruction; Lateral extraarticular tenodesis; Anterior cruciate ligament; Hamstrings; Gracilis; Semitendinosus

©The Author(s) 2022. Published by Baishideng Publishing Group Inc. All rights reserved.

Core Tip: There is no convincing evidence regarding the biomechanical and functional superiority of either lateral extraarticular tenodesis or anterolateral ligament reconstruction procedures during anterior cruciate ligament reconstruction. Although hamstrings remain the most common graft choice for anterolateral ligament reconstruction, other autografts as well as allografts and synthetic grafts have been applied. Further research and comparative studies should be carried out to identify the most effective graft material and technique for the restoration of rotational knee stability in the presence of residual instability after anterior cruciate ligament reconstruction.

Citation: Chalidis B, Pitsilos C, Kitridis D, Givissis P. Graft choices for anterolateral ligament knee reconstruction surgery: Current concepts. *World J Clin Cases* 2022; 10(24): 8463-8473

URL: <https://www.wjgnet.com/2307-8960/full/v10/i24/8463.htm>

DOI: <https://dx.doi.org/10.12998/wjcc.v10.i24.8463>

INTRODUCTION

The anterolateral ligament (ALL) is an independent structure of the anterolateral complex of the knee along with the lateral collateral ligament (LCL), the iliotibial band (ITB) and the anterolateral joint capsule[1,2]. There is no consensus so far on whether ALL bony attachment is located posterior and proximal or anterior and distal to the lateral femoral epicondyle or just on the lateral epicondylar together with the LCL attachment[3-7]. Its course is anterodistal and superficial to the LCL and its distal insertion midway between the anterior border of the fibular head and the Gerdy's tubercle of the tibia [8]. The ALL is a nonisometric structure that tenses during knee flexion and internal tibial rotation and shows the greatest length change at 90° of flexion[9]. As a distinct structure of the anterolateral complex of the knee, the ALL seems to contribute to internal rotational stability of the joint, but its role in resisting rotational as well as anteroposterior instability in an anterior cruciate ligament (ACL) deficient knee is still controversial[10-13].

An ALL lesion is presented as a midsubstance strain and tear or avulsion of its bony insertion on the tibia, which is known as a Segond fracture[14]. The injury is most commonly associated with ACL rupture[5]. Concomitant ACL and ALL deficiency may result in increased knee rotational instability, which may not be restored by isolated anterior cruciate ligament reconstruction (ACLR)[15]. The incidence of positive pivot shift after ACLR could rise to 34% of operated cases, and many studies have demonstrated that additional ALL reconstruction (ALLR) decreases knee laxity and ACL graft failure rate and improves patient-reported outcomes[16-20]. On the other hand, simultaneous ALLR has been associated with overconstrained internal rotation and subsequent knee joint stiffness[21,22]. Furthermore, there is some evidence that ALLR does not decrease the rotational laxity of the knee to a desirable degree and its role in improving the postoperative function is limited[23,24]. Thus, simultaneous ACLR and ALLR have been suggested mainly in cases of grossly unstable pivot-shift and revision ACL surgery[25,26]. Moreover, indications for ALLR may include young patients who participate in pivoting activities as well as knees with chronic ACL deficiency or concomitant meniscal tears requiring surgical repair[27].

LITERATURE SEARCH

We conducted a narrative review using the MEDLINE online database regarding ALLR. The initial search applying the keywords "Anterolateral Ligament Reconstruction" led to 807 results. After abstract and full-text screening, 22 studies describing the results of ALLR in ACLR surgery were enrolled for further assessment (Figure 1). The extracted data were analyzed and organized to present the different reported methods of ALLR during ACLR in respect to graft choice, proximal and distal attachment location, stabilization technique and knee fixation angle (Table 1).

GRAFT TYPES AND TECHNIQUES

So far, many grafts have been applied for the restoration of ALL function, but no consensus exists regarding the ideal graft type and fixation technique. Controversies are based on the anatomic parameters of ALL regarding its bony origin and its length changes during knee motion. They are referred to graft material choice as well as graft insertion site location and fixation angle[6,8,23,28-33]. All the applied procedures aim to restore the knee kinematics in case of ALL deficiency and include either the lateral extraarticular tenodesis (LET) or ALLR techniques. The main principle of the LET

Table 1 Graft choices and fixation methods

Ref.	ACL graft type	ALL graft type	Femoral fixation point	Tibial fixation point	Fixation Technique	Knee flexion/rotation
Lemaire and Combelles [36], 1980	BTB (hole for ITB graft)	ITB	Above the lateral epicondyle, proximal to the LCL insertion	Maintain attachment to Gerdy's tubercle	Two bone tunnels, suture on itself	30° flexion/external rotation
Andrews and Sanders [41], 1983		ITB (two strips)	Lateral femoral epicondyle	Maintain attachment to Gerdy's tubercle	Suture strips together at medial femoral condyle after passing through two parallel lateral-to-medial tunnels	90° flexion/external rotation
Amirault <i>et al</i> [40], 1988		ITB	Above the lateral epicondyle, proximal to the LCL insertion	Maintain attachment to Gerdy's tubercle	Suture fixation to ITB after passing through the lateral intermuscular septum	90° flexion/external rotation
Christel and Djian [37], 2002		ITB	Above the lateral epicondyle, proximal to the LCL insertion	Maintain attachment to Gerdy's tubercle	Interference screw	30° flexion
Mathew <i>et al</i> [38], 2018		ITB	Anterior and proximal to the lateral gastrocnemius tendon	Maintain attachment to Gerdy's tubercle	Richards staple and sutures to itself	60° flexion/neutral rotation
Abusleme <i>et al</i> [39], 2021		ITB	Above the lateral epicondyle, proximal to the LCL insertion	Maintain attachment to Gerdy's tubercle	Suture fixation to ITB after passing through the lateral intermuscular septum	30° flexion/neutral rotation
Colombet [49], 2010	Quadruple (Semitendinosus double-bundle and gracilis double-bundle) or Double (single-bundle each)	Gracilis - semitendinosus (one bundle each)	Proximal to lateral epicondyle	Gerdy's tubercle	Absorbable screws at each fixation point	90° flexion/neutral rotation
Helito <i>et al</i> [29], 2015	Quadruple (semitendinosus triple-bundle and gracilis single-bundle)	Gracilis (single-bundle)	3-4 mm below the halfway point on the Blumensaat's line in the AP direction	5-10 mm below the lateral tibial plateau, between fibular head and Gerdy's tubercle	One 5 mm metal anchors at each fixation point	60-90° of flexion/nm
Smith <i>et al</i> [45], 2015	Semitendinosus graft	Gracilis (double-bundle)	Anterior to lateral femoral epicondyle	Midway between fibular head and the Gerdy's tubercle, 11 mm distal to joint line	4.75 or 5.5 mm bioabsorbable knotless suture anchor at each fixation point	30° of flexion/neutral rotation
Ferreira <i>et al</i> [48], 2016	Semitendinosus triple-bundle	Gracilis (double-bundle)	8 mm posterolaterally from lateral epicondyle	9-13 mm distal to lateral joint line, between fibular head and the Gerdy's tubercle	Interference screw 2 mm larger than tunnel	45-60° flexion/nm
Sonnery-Cottet <i>et al</i> [44], 2016	Semitendinosus SAMBBA	Gracilis (double-bundle)	Proximal and posterior to lateral epicondyle	One superolateral margin of the Gerdy's tubercle and one midway between fibular head and the Gerdy's tubercle	4.75 or 5.5 mm bioabsorbable knotless suture anchor at each fixation point	Full extension/neutral rotation
Delaloye <i>et al</i> [47], 2018	Internal brace	Gracilis (double-bundle)	Proximal and posterior to lateral epicondyle	Bone tunnel: One point just anterior to the fibular head and second posterior to Gerdy's tubercle	4.75 bioabsorbable knotless suture anchor at femoral fixation point	Full extension/neutral rotation
Saithna <i>et al</i> [18], 2018	Quadruple (Semitendinosus triple-bundle and gracilis single-bundle)	Gracilis (single-bundle)	Proximal and posterior to lateral epicondyle	Bone tunnel: One point just anterior to the fibular head and second posterior to Gerdy's tubercle	Ethibond suture around the graft	Full extension/neutral rotation
Goncharov <i>et al</i> [46], 2019	BTB autograft	Gracilis or semitendinosus tendon autograft	Proximal to lateral epicondyle	10 mm distal to joint line, between fibular head and the Gerdy's tubercle	Interference screws	Full extension/nm

Kim <i>et al</i> [50], 2020		Semitendinosus autograft	Proximal and posterior to lateral epicondyle	Midway between fibular head and the Gerdy's tubercle	Interference screw at femur, adjustable length loop button at tibia	30° flexion/neutral rotation
Escudeiro de Oliveira <i>et al</i> [52], 2021	Quintuple, Semitendinosus double-bundle, gracilis double-bundle and peroneous longus single-bundle	Peroneous longus	Proximal and posterior to lateral epicondyle	15 mm distal to joint line, between fibular head and the Gerdy's tubercle	Interference screws	30° flexion/nm
Josipovic <i>et al</i> [53], 2020	Quintuple, Semitendinosus triple-bundle, plantaris longus double-bundle	Plantaris longus	Proximal and posterior to lateral epicondyle	10 mm distal to joint line, between fibular head and the Gerdy's tubercle	Interference screw at tibia	Full extension/nm
Wagih and Elguindy [59], 2016		Polyester tape	Distal and anterior to lateral femoral condyle	Midpoint between the Gerdy's tubercle and the fibular head	Cortical suspension button proximally, tie on a bone bridge of two bone tunnels distally	30° flexion/nm
Lee <i>et al</i> [25], 2019	Tibialis anterior tendon allograft	Gracilis tendon allograft	Proximal and posterior to lateral epicondyle	10 mm distal to joint line, between fibular head and the Gerdy's tubercle	Interference screws	30° flexion/neutral rotation
Chahla <i>et al</i> [57], 2016		Semitendinosus allograft	4.7 mm proximal and posterior to LCL insertion site	9.5 mm distal to joint line, between fibular head and the Gerdy's tubercle	Interference screws	30° flexion/nm
Fernández <i>et al</i> [58], 2020	Achilles tendon allograft	Achilles tendon allograft	Proximal and posterior to lateral epicondyle	15 mm distal to joint line, between fibular head and the Gerdy's tubercle	Staple at distal site	30° flexion/neutral rotation
Benum [42], 1982		Patellar tendon (lateral one-third with proximal bone block)	Femoral origin of LCL	Maintain attachment to tibial tubercle	Staple at femoral side	45° flexion/external rotation

ACL: Anterior cruciate ligament; ALL: Anterolateral ligament; AP: Anteroposterior; BTB: Bone-patellar tendon-bone; LCL: Lateral collateral ligament; ITB: Iliotibial band; nm: Not mentioned; SAMBBA: Single anteromedial bundle biological augmentation.

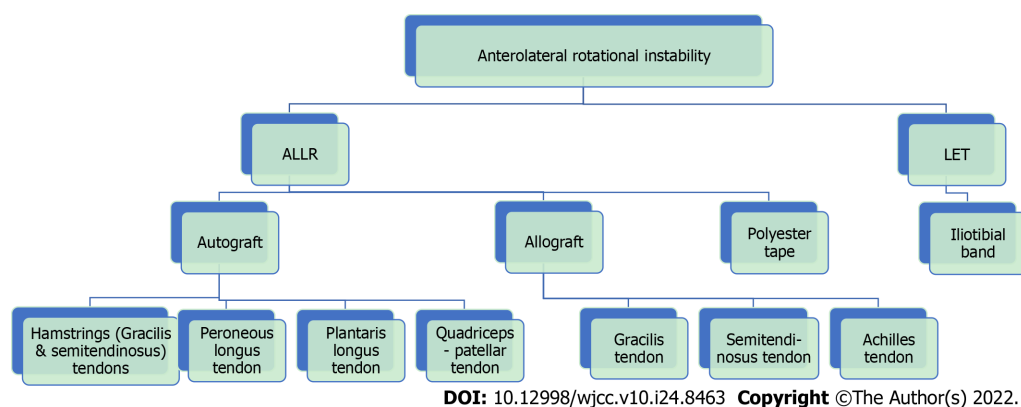


Figure 1 Flow-chart of graft types. ALLR: Anterolateral ligament reconstruction, LET: Lateral extraarticular tenodesis.

procedure is the use of a strip of ITB that is stabilized proximally above the knee joint while its tibial insertion to Gerdy's tubercle remains intact[34]. On the other hand, the ALLR aims to restore the ALL native features by fixing a free tendon graft between the anatomical femoral and tibial insertion points of the ALL[35].

AUTOGRAFTS

Iliotibial band

The ITB is exclusively used for the LET procedure. Lemaire[36] was the first who described the LET technique in cases of chronic ACL injuries. In the original procedure, the ITB was identified and a strip of 1 cm wide and 18 cm long was harvested, leaving the attachment to Gerdy's tubercle intact. The graft was first passed in a distal to proximal direction under the LCL. Then, it was introduced to the distal femur through a bone tunnel above the lateral epicondyle and proximal to the LCL insertion. Consequently, it was passed again under the LCL in a proximal to distal direction and finally fixed to the tibia through a bone tunnel at Gerdy's tubercle and sutured on itself. Fixation was completed in 30° of knee flexion and some tibial external rotation. In cases of combination with ACLR, LET allows for independent ACL graft choice. The authors also proposed a variation of the original technique by fixing the strip of ITB into the femoral tunnel that was created for bone-patellar tendon-bone graft ACLR.

Many modifications of the Lemaire procedure have been described referring to harvesting a shorter strip of tendon[37,38]. In addition, the graft may be stabilized proximally with sutures to the ITB after passing through the lateral intermuscular septum or with either a staple or an interference screw[37-40]. Andrews and Sanders[41] described a technique where two strips of ITB were harvested and passed through two parallel lateral-to-medial femoral tunnels and sutured together.

Moreover, variable knee flexion angles have been recommended during fixation, including 30°, 60° and 90°[38,39,42]. In respect to tibial rotation, older studies suggested that the tibia should be maintained in external rotation, but no specific angle was defined[40,41]. However, that position has been related to excessive restriction of internally rotatory movement and abnormal knee kinematics[34, 43]. This overconstraint along with the non-anatomic nature of the LET procedure may lead to gradual elongation of the graft and subsequent recurrent rotational instability[43]. As a result, most recent studies have advocated a neutral rotation position for ITB graft fixation[38,39].

Gracilis tendon

Gracilis tendon (GT) is a commonly used autograft for ALLR. The free tendon graft is fixed proximally on the lateral femoral epicondyle and distally between the fibular head and Gerdy's tubercle after passing between the ITB and LCL[19]. Most frequently, the graft is introduced proximal and posterior to lateral femoral, but a more anterior position has also been described[44,45]. Femoral fixation can be performed with an interference screw or an anchor[45,46]. The same principles are followed when concomitant ACLR is performed with either hamstrings graft, bone-patellar tendon-bone graft or internal brace[44-47].

The tibial attachment of the graft is placed between the fibular head and Gerdy's tubercle approximately 5 to 13 cm distal to the lateral joint line[29,48]. Fixation is accomplished using an interference screw or an anchor[29,49]. Some authors have described ALLR in an inverted V-shaped fashion. Specifically, the graft is introduced in a tibial bone tunnel extending anterior to the fibular head and posterior to Gerdy's tubercle and then is fixed at the femoral side with an anchor or with sutures around the graft[18,47]. Sonnery-Cottet *et al*[44] completed tibial fixation of the graft with two suture anchors. The first one was placed on the superolateral margin of the Gerdy's tubercle and the other one midway between the fibular head and Gerdy's tubercle.

During combined ALLR and ACLR using hamstring tendon autograft, a single graft is usually used for both procedures. After ACLR, the remaining graft is passed through a bone tunnel to the lateral surface of the distal femur, proximally and posteriorly to the lateral epicondyle[18,48]. Helito *et al*[29] identified the ALLR femoral tunnel location using fluoroscopy, aiming approximately 3-4 mm below the halfway point of the Blumensaat's line in the anteroposterior direction. Furthermore, Ferreira *et al*[48] used a triple semitendinosus tendon (ST) graft for ACLR and a double GT graft for ALLR. Another combination is a four-strand ACL graft formed by a triple ST bundle and a single GT bundle, while the remaining GT is used for ALLR[29]. Colombet[49] also described the use of a quadruple ACL graft composed of two ST and two GT bundles. A double-bundle graft for ALLR was created from the excess tendon tissue of the bundles.

There is no consensus regarding the ideal fixation angle of a GT graft. Several different knee angles have been reported so far including full extension, 30°, 45° to 60°, 60° to 90° and 90°[29,45,47-49]. In contrast, it has been generally accepted that the tibia should be maintained in neutral rotation at the time of graft stabilization[18,44,45].

Semitendinosus tendon

Apart from GT, the ST has been also widely used for ALLR[46]. Kim *et al*[50] harvested the contralateral ST for ALLR, as the ipsilateral ST had been already used for ACLR during the same or previous procedure. The double-bundle graft was first attached on the tibia (midway between the fibular head and Gerdy's tubercle) using an adjustable length loop button, then passed deep to ITB and finally fixed posterior and proximal to the lateral femoral epicondyle with an interference screw, while the knee was positioned in 30° of flexion and neutral rotation. Additionally, Zarins and Rowe[51] proposed simultaneous ACLR and ALLR using only the ipsilateral ST. After proximal release, the ST was passed

through the knee joint for ACLR, then exerted through a lateral femoral bone tunnel and tied to the ITB keeping the knee in 60° of flexion and tibial external rotation.

Peroneus longus

Escudeiro de Oliveira *et al*[52] reconstructed the ALL with an ipsilateral peroneus longus (PL) tendon graft and the ACL with a quintuple graft composed of a double-bundle ST, a double-bundle GT and a single-bundle PL. Specifically, the quintuple graft was initially used for ACLR, and the excess PL material was passed through a femoral tunnel, proximal and posterior to the lateral epicondyle, and was attached distally between the fibular head and Gerdy's tubercle at 15 mm from the joint line. An interference screw was used in each attachment site, and during fixation the knee was kept at mild valgus and 30° of flexion. The authors supported the option of PL graft for ALLR as it could be easily harvested with minimal invasiveness. It was associated with low donor site morbidity and allowed adequate concomitant ACLR in combination with hamstring tendon autograft.

Plantaris longus

Josipovic *et al*[53] presented a technique of ALLR using the ipsilateral plantaris longus tendon. A quintuple graft composed of a three-strand ST and a two-strand GT was used for ACLR and a two-strand plantaris longus graft, which substituted the ALL, sutured to the quintuple graft. After the ACL graft fixation, the plantaris longus tendon was passed through a bone tunnel posterior and proximal to the lateral femoral epicondyle and fixed with an interference screw 10 mm distally from the joint line and midway between the fibular head and Gerdy's tubercle, while the knee was fully extended. Although the authors reported good short-term results, there was a lack of data regarding the effectiveness of the technique.

Quadriceps and patellar tendon grafts

Historically, Marshall *et al*[54] presented the Marshall-MacIntosh procedure using an autograft of quadriceps tendon-prepatellar retinaculum-patellar tendon for concomitant ACL and ALL reconstruction. The distal attachment of the extensor apparatus to the tibial tubercle was preserved, and the graft was passed through a tibial and femoral bone tunnel over the top of the lateral femoral condyle and fixed on Gerdy's tubercle. Dupont *et al*[55] presented a modification of the technique by harvesting a free graft including the bony attachment of the quadriceps tendon-prepatellar retinaculum-patellar tendon on the tibial tubercle. Additionally, Benum[42] reported the use of the lateral one-third of the patellar tendon with a proximal bone block for ALLR. The distal attachment on the tibial tubercle was preserved, and the graft was fixed with staples to the femoral origin of LCL.

ALLOGRAFTS

Some authors have recommended the application of allografts for ALLR, even in primary surgery, emphasizing the advantages of no donor site morbidity and availability of larger and longer grafts[56]. However, the use of allografts has been mainly suggested in revision surgery, where autografts may be not available in sufficient quantity[57]. Lee *et al*[25] used a GT allograft for ALLR in combination with tibialis anterior allograft for ACLR in the setting of revision surgery. Comparing ACLR with and without ALLR, they reported better outcomes after at least 3 years in terms of residual pivot shift, subjective IKDC score and Tegner score, return to the preinjury level of sports activity and possibility of revision surgery when ALLR was additionally performed. Chahla *et al*[57] underwent ALLR using an ST allograft mainly in cases requiring revision ACL surgery. However, they did not present any postoperative outcomes. Fernández *et al*[58] used an Achilles tendon allograft for both ACLR and ALLR in patients with previously failed ACLR and significant bone loss. They performed a two-stage procedure to fill the bone defect with a bone graft and to subsequently reconstruct the ACL and ALL. Still, no postsurgical outcome was reported.

SYNTHETIC GRAFTS (POLYESTER TAPE)

Wagih and Elguindy[59] reported an ALLR technique using polyester tape. The synthetic ligament was attached proximally anterior and distal to the lateral femoral condyle with a cortical suspensory button. Distally, the graft was inserted between the Gerdy's tubercle and the fibular head and stabilized *via* sutures that tied on the medial side of the tibia through two bone tunnels. During fixation, the knee was placed in 30° of flexion. The authors suggested that polyester tape ALLR might be worth further investigation as it was a minimally invasive technique without donor site morbidity. Furthermore, the material could offer adequate strength with minimal possibility of laxity and postoperative failure. However, no details about the postoperative outcome were provided.

BIOMECHANICAL EVALUATION

The combination of ACLR with LET or ALLR can restore residual rotational laxity after isolated ACLR [60]. However, the LET procedure has been related to postoperative overconstraint of the internal rotation of the knee [34]. In a cadaveric study, Smith *et al* [34] reported similar results and equivalent restoration of knee kinematics between ALLR and LET after ACLR. Regarding knee position during graft fixation, Inderhaug *et al* [61] in a controlled ACLR laboratory study found that knee laxity was equally restored when ITB graft tenodesis was performed at 0°, 30° or 60° of knee flexion. On the other hand, ALLR using a GT graft achieved normal kinematics only when fixation was performed in full extension. Conversely, in another cadaveric study, Geeslin *et al* [62] found that both LET and ALLR were effective in reducing internal tibial rotation independently of the knee fixation angle or graft tension.

Additionally, Monaco *et al* [63] noticed that ALLR with GT showed superior biomechanical properties than LET, while the native ALL had lower failure load and stiffness compared to both grafts. Ra *et al* [64] found that LET resulted in similar rotational stability but worse anterior instability compared to ALLR. On the contrary, Spencer *et al* [65] reported that ALLR was less effective in reducing anterolateral rotational laxity than the LET procedure. Deviantri and van der Veen [66] used LET in four patients with residual rotational instability after ACLR and reported a significant improvement of knee kinematics.

In a recent meta-analysis, Yin *et al* [67] reported superior knee kinematics after combined ACLR and ALLR or LET compared to isolated ACLR in ACL deficient knees. Similarly, Littlefield *et al* [19] in a systematic review identified that supplementary ALLR during ACLR improved anterior tibial translation and internal knee rotation and resulted in a lower incidence of graft failure.

CLINICAL EVIDENCE

Current literature suggests that combined ACLR with ALLR or LET can improve clinical outcomes and decrease the possibility of ACL graft failure compared to isolated ACLR [43]. Beckers *et al* [68] observed that both LET and ALLR during ACLR provided superior Lysholm Score and reduced ACL re-rupture rate. Na *et al* [69] in a systematic review found that ALLR or LET along with ACLR were related to superior subjective IKDC, Tegner and Lysholm scores than isolated ACLR. However, the LET was associated with higher postoperative stiffness and complications than ALLR. Sonnery-Cottet *et al* [70] using data from 270 patients noticed that combined ACLR with ALLR led to a lower reoperation rate and better long-term graft survivorship but similar overall complication risk compared to isolated ACLR. The authors reported a 5-fold increase in the risk of ACL graft failure after a mean of 104 mo in cases of isolated ACLR. Similarly, in a systematic review of de Lima *et al* [71] the simultaneous ALLR and ACLR were related to better clinical outcomes than single ACLR, including higher success in return to sport and lower ACL graft rupture rate. The advantages and disadvantages of each technique are summarized in Table 2.

DISCUSSION

Restoration of rotational stability is of paramount importance in the ACL injured knee. Apart from intraarticular ACLR, additional extraarticular procedures may be required to improve knee function and stability and minimize the risk for ACL graft failure. These include the LET and the ALLR with variable modifications of each procedure regarding the graft choice and fixation technique. Semitendinosus and gracilis are the main tendon grafts for ALLR, but other autografts such as peroneus longus, plantaris longus and quadriceps-patellar tendons have also been applied. Allografts and synthetic grafts are usually preferred in revision ACLR procedures where there is limited availability of autograft material for both ACLR and ALLR. Although all the available grafts for LET and ALLR may improve knee rotational stability, few studies with a relatively short follow-up and a small number of patients have been published so far. Therefore, there is inconclusive evidence to favor one method over the others in terms of biomechanical properties and clinical outcomes. Further large-scale studies are required to clarify the benefit of ALLR during primary or revision ACLR procedures. Particularly, future randomized control trials should compare ACLR with or without ALLR in young, active and high-demand patients by using different graft types. The research should focus on the subgroup of patients with large pivot-shift and operated meniscal tears aiming to find a potential correlation between ALLR and failure of ACLR under these conditions.

CONCLUSION

According to the current review and existing literature, there is no convincing evidence regarding the

Table 2 Lateral extraarticular tenodesis and anterolateral ligament reconstruction Techniques: Advantages and disadvantages[39,72,73]

Advantages	Disadvantages
1. Lateral extraarticular tenodesis	
Improvement of rotational knee stability	Non-anatomic procedure
Reduction of ACL graft failure rate	Possible over-constraining
Reproducible, easy-to-learn technique	May add pain to postoperative rehabilitation
Inexpensive procedure, especially when using high-resistance suture	Muscle herniation, if ITB closure is not performed in proper way
No risk of tunnel coalition when fixed with sutures proximally	
2. Anterolateral ligament reconstruction	
Improvement of rotational knee stability	Need ability to identify anatomic landmarks
Reduction of ACL graft failure rate	Use of allograft or synthetic results in increased cost
Preserves iliotibial band	Use of autograft requires additional surgery for graft harvest and possible donor site morbidity
Avoids lateral collateral ligament attachment	
Secure graft fixation allows for early motion and accelerated anterior cruciate ligament rehabilitation	

ACL: Anterior cruciate ligament; ITB: Iliotibial band.

biomechanical and functional superiority of either LET or ALLR procedures during ACLR. Although hamstrings remain the most common graft choice for ALLR, other autografts as well as allografts and synthetic grafts have been applied with satisfactory results and low complication rate. However, a pooled analysis of all published raw data would further improve the quality of the review and related evidence despite the heterogeneity of the studies.

FOOTNOTES

Author contributions: Chalidis B and Kitridis D designed the research; Pitsilos C analyzed the data; Chalidis B and Pitsilos C wrote the paper; Givissis P supervised the paper; All authors read and approved the final manuscript.

Conflict-of-interest statement: There is no conflict of interest associated with any of the senior author or other coauthors contributed their efforts in this manuscript.

Open-Access: This article is an open-access article that was selected by an in-house editor and fully peer-reviewed by external reviewers. It is distributed in accordance with the Creative Commons Attribution NonCommercial (CC BY-NC 4.0) license, which permits others to distribute, remix, adapt, build upon this work non-commercially, and license their derivative works on different terms, provided the original work is properly cited and the use is non-commercial. See: <https://creativecommons.org/licenses/by-nc/4.0/>

Country/Territory of origin: Greece

ORCID number: Byron Chalidis 0000-0003-1305-2734; Charalampos Pitsilos 0000-0002-3091-866X; Dimitrios Kitridis 0000-0002-6063-8650; Panagiotis Givissis 0000-0002-8649-1159.

S-Editor: Wang LL

L-Editor: Filipodia

P-Editor: Wang LL

REFERENCES

- 1 **Caterine S**, Litchfield R, Johnson M, Chronik B, Getgood A. A cadaveric study of the anterolateral ligament: re-introducing the lateral capsular ligament. *Knee Surg Sports Traumatol Arthrosc* 2015; **23**: 3186-3195 [PMID: 24929656 DOI: 10.1007/s00167-014-3117-z]
- 2 **Musahl V**, Herbst E, Burnham JM, Fu FH. The Anterolateral Complex and Anterolateral Ligament of the Knee. *J Am Acad*

- Orthop Surg* 2018; **26**: 261-267 [PMID: 29517517 DOI: 10.5435/jaaos-d-16-00758]
- 3 **Daggett M**, Ockuly AC, Cullen M, Busch K, Lutz C, Imbert P, Sonnery-Cottet B. Femoral Origin of the Anterolateral Ligament: An Anatomic Analysis. *Arthroscopy* 2016; **32**: 835-841 [PMID: 26725451 DOI: 10.1016/j.arthro.2015.10.006]
 - 4 **Kennedy MI**, Claes S, Fuso FA, Williams BT, Goldsmith MT, Turnbull TL, Wijdicks CA, LaPrade RF. The Anterolateral Ligament: An Anatomic, Radiographic, and Biomechanical Analysis. *Am J Sports Med* 2015; **43**: 1606-1615 [PMID: 25888590 DOI: 10.1177/0363546515578253]
 - 5 **Claes S**, Bartholomeeusens S, Bellemans J. High prevalence of anterolateral ligament abnormalities in magnetic resonance images of anterior cruciate ligament-injured knees. *Acta Orthop Belg* 2014; **80**: 45-49 [PMID: 24873084]
 - 6 **Kosy JD**, Soni A, Venkatesh R, Mandalia VI. The anterolateral ligament of the knee: unwrapping the enigma. Anatomical study and comparison to previous reports. *J Orthop Traumatol* 2016; **17**: 303-308 [PMID: 26861760 DOI: 10.1007/s10195-016-0392-0]
 - 7 **Runer A**, Birkmaier S, Pamminger M, Reider S, Herbst E, Künzel KH, Brenner E, Fink C. The anterolateral ligament of the knee: A dissection study. *Knee* 2016; **23**: 8-12 [PMID: 26749203 DOI: 10.1016/j.knee.2015.09.014]
 - 8 **Dodds AL**, Halewood C, Gupte CM, Williams A, Amis AA. The anterolateral ligament: Anatomy, length changes and association with the Segond fracture. *Bone Joint J* 2014; **96-B**: 325-331 [PMID: 24589786 DOI: 10.1302/0301-620x.96b3.33033]
 - 9 **Zens M**, Niemeyer P, Ruhhammer J, Bernstein A, Woias P, Mayr HO, Südkamp NP, Feucht MJ. Length Changes of the Anterolateral Ligament During Passive Knee Motion: A Human Cadaveric Study. *Am J Sports Med* 2015; **43**: 2545-2552 [PMID: 26264771 DOI: 10.1177/0363546515594373]
 - 10 **Parsons EM**, Gee AO, Spiekerman C, Cavanagh PR. The biomechanical function of the anterolateral ligament of the knee. *Am J Sports Med* 2015; **43**: 669-674 [PMID: 25556221 DOI: 10.1177/0363546514562751]
 - 11 **Vundelinckx B**, Herman B, Getgood A, Litchfield R. Surgical Indications and Technique for Anterior Cruciate Ligament Reconstruction Combined with Lateral Extra-articular Tenodesis or Anterolateral Ligament Reconstruction. *Clin Sports Med* 2017; **36**: 135-153 [PMID: 27871655 DOI: 10.1016/j.csm.2016.08.009]
 - 12 **Kittl C**, El-Daou H, Athwal KK, Gupte CM, Weiler A, Williams A, Amis AA. The Role of the Anterolateral Structures and the ACL in Controlling Laxity of the Intact and ACL-Deficient Knee. *Am J Sports Med* 2016; **44**: 345-354 [PMID: 26657572 DOI: 10.1177/0363546515614312]
 - 13 **Huser LE**, Noyes FR, Jurgensmeier D, Levy MS. Anterolateral Ligament and Iliotibial Band Control of Rotational Stability in the Anterior Cruciate Ligament-Intact Knee: Defined by Tibiofemoral Compartment Translations and Rotations. *Arthroscopy* 2017; **33**: 595-604 [PMID: 27964969 DOI: 10.1016/j.arthro.2016.08.034]
 - 14 **Ferretti A**, Monaco E, Fabbri M, Maestri B, De Carli A. Prevalence and Classification of Injuries of Anterolateral Complex in Acute Anterior Cruciate Ligament Tears. *Arthroscopy* 2017; **33**: 147-154 [PMID: 27339397 DOI: 10.1016/j.arthro.2016.05.010]
 - 15 **Tavlo M**, Eljaja S, Jensen JT, Siersma VD, Krogsgaard MR. The role of the anterolateral ligament in ACL insufficient and reconstructed knees on rotatory stability: A biomechanical study on human cadavers. *Scand J Med Sci Sports* 2016; **26**: 960-966 [PMID: 26247376 DOI: 10.1111/sms.12524]
 - 16 **Prodromos CC**, Joyce BT, Shi K, Keller BL. A meta-analysis of stability after anterior cruciate ligament reconstruction as a function of hamstring versus patellar tendon graft and fixation type. *Arthroscopy* 2005; **21**: 1202 [PMID: 16226648 DOI: 10.1016/j.arthro.2005.08.036]
 - 17 **Nitri M**, Rasmussen MT, Williams BT, Moulton SG, Cruz RS, Dornan GJ, Goldsmith MT, LaPrade RF. An In Vitro Robotic Assessment of the Anterolateral Ligament, Part 2: Anterolateral Ligament Reconstruction Combined With Anterior Cruciate Ligament Reconstruction. *Am J Sports Med* 2016; **44**: 593-601 [PMID: 26831632 DOI: 10.1177/0363546515620183]
 - 18 **Saithna A**, Thaunat M, Delaloye JR, Ouanezar H, Fayard JM, Sonnery-Cottet B. Combined ACL and Anterolateral Ligament Reconstruction. *JBJS Essent Surg Tech* 2018; **8**: e2 [PMID: 30233974 DOI: 10.2106/jbjs.St.17.00045]
 - 19 **Littlefield CP**, Belk JW, Houck DA, Kraeutler MJ, LaPrade RF, Chahla J, McCarty EC. The Anterolateral Ligament of the Knee: An Updated Systematic Review of Anatomy, Biomechanics, and Clinical Outcomes. *Arthroscopy* 2021; **37**: 1654-1666 [PMID: 33340678 DOI: 10.1016/j.arthro.2020.12.190]
 - 20 **Rosenstiel N**, Praz C, Ouanezar H, Saithna A, Fournier Y, Hager JP, Thaunat M, Sonnery-Cottet B. Combined Anterior Cruciate and Anterolateral Ligament Reconstruction in the Professional Athlete: Clinical Outcomes From the Scientific Anterior Cruciate Ligament Network International Study Group in a Series of 70 Patients With a Minimum Follow-Up of 2 Years. *Arthroscopy* 2019; **35**: 885-892 [PMID: 30704884 DOI: 10.1016/j.arthro.2018.09.020]
 - 21 **Patel RM**, Brophy RH. Anterolateral Ligament of the Knee: Anatomy, Function, Imaging, and Treatment. *Am J Sports Med* 2018; **46**: 217-223 [PMID: 28320209 DOI: 10.1177/0363546517695802]
 - 22 **Schon JM**, Moatshe G, Brady AW, Serra Cruz R, Chahla J, Dornan GJ, Turnbull TL, Engebretsen L, LaPrade RF. Anatomic Anterolateral Ligament Reconstruction of the Knee Leads to Overconstraint at Any Fixation Angle. *Am J Sports Med* 2016; **44**: 2546-2556 [PMID: 27407088 DOI: 10.1177/0363546516652607]
 - 23 **Drews BH**, Kessler O, Franz W, Dürselen L, Freutel M. Function and strain of the anterolateral ligament part I: biomechanical analysis. *Knee Surg Sports Traumatol Arthrosc* 2017; **25**: 1132-1139 [PMID: 28258329 DOI: 10.1007/s00167-017-4472-3]
 - 24 **Stentz-Olesen K**, Nielsen ET, de Raedt S, Jørgensen PB, Sørensen OG, Kaptein B, Soballe K, Stilling M. Reconstructing the anterolateral ligament does not decrease rotational knee laxity in ACL-reconstructed knees. *Knee Surg Sports Traumatol Arthrosc* 2017; **25**: 1125-1131 [PMID: 28314889 DOI: 10.1007/s00167-017-4500-3]
 - 25 **Lee DW**, Kim JG, Cho SI, Kim DH. Clinical Outcomes of Isolated Revision Anterior Cruciate Ligament Reconstruction or in Combination With Anatomic Anterolateral Ligament Reconstruction. *Am J Sports Med* 2019; **47**: 324-333 [PMID: 30640514 DOI: 10.1177/0363546518815888]
 - 26 **Noyes FR**, Huser LE, Jurgensmeier D, Walsh J, Levy MS. Is an Anterolateral Ligament Reconstruction Required in ACL-Reconstructed Knees With Associated Injury to the Anterolateral Structures? *Am J Sports Med* 2017; **45**: 1018-1027 [PMID: 28056513 DOI: 10.1177/0363546516682233]

- 27 **Sonnery-Cottet B**, Lutz C, Daggett M, Dalmay F, Freychet B, Niglis L, Imbert P. The Involvement of the Anterolateral Ligament in Rotational Control of the Knee. *Am J Sports Med* 2016; **44**: 1209-1214 [PMID: [26865395](#) DOI: [10.1177/0363546515625282](#)]
- 28 **Imbert P**, Lutz C, Daggett M, Niglis L, Freychet B, Dalmay F, Sonnery-Cottet B. Isometric Characteristics of the Anterolateral Ligament of the Knee: A Cadaveric Navigation Study. *Arthroscopy* 2016; **32**: 2017-2024 [PMID: [27157662](#) DOI: [10.1016/j.arthro.2016.02.007](#)]
- 29 **Helito CP**, Bonadio MB, Gobbi RG, da Mota E Albuquerque RF, Pécora JR, Camanho GL, Demange MK. Combined Intra- and Extra-articular Reconstruction of the Anterior Cruciate Ligament: The Reconstruction of the Knee Anterolateral Ligament. *Arthrosc Tech* 2015; **4**: e239-e244 [PMID: [26258037](#) DOI: [10.1016/j.eats.2015.02.006](#)]
- 30 **Wytrykowski K**, Swider P, Reina N, Murgier J, Laffosse JM, Chiron P, Cavaignac E. Cadaveric Study Comparing the Biomechanical Properties of Grafts Used for Knee Anterolateral Ligament Reconstruction. *Arthroscopy* 2016; **32**: 2288-2294 [PMID: [27161509](#) DOI: [10.1016/j.arthro.2016.03.004](#)]
- 31 **Ahn JH**, Patel NA, Lin CC, Lee TQ. The anterolateral ligament of the knee joint: a review of the anatomy, biomechanics, and anterolateral ligament surgery. *Knee Surg Relat Res* 2019; **31**: 12 [PMID: [32660576](#) DOI: [10.1186/s43019-019-0012-4](#)]
- 32 **Inderhaug E**, Stephen JM, Williams A, Amis AA. Biomechanical Comparison of Anterolateral Procedures Combined With Anterior Cruciate Ligament Reconstruction. *Am J Sports Med* 2017; **45**: 347-354 [PMID: [28027653](#) DOI: [10.1177/0363546516681555](#)]
- 33 **Kraeutler MJ**, Welton KL, Chahla J, LaPrade RF, McCarty EC. Current Concepts of the Anterolateral Ligament of the Knee: Anatomy, Biomechanics, and Reconstruction. *Am J Sports Med* 2018; **46**: 1235-1242 [PMID: [28426251](#) DOI: [10.1177/0363546517701920](#)]
- 34 **Slette EL**, Mikula JD, Schon JM, Marchetti DC, Kheir MM, Turnbull TL, LaPrade RF. Biomechanical Results of Lateral Extra-articular Tenodesis Procedures of the Knee: A Systematic Review. *Arthroscopy* 2016; **32**: 2592-2611 [PMID: [27324970](#) DOI: [10.1016/j.arthro.2016.04.028](#)]
- 35 **Sonnery-Cottet B**, Daggett M, Fayard JM, Ferretti A, Helito CP, Lind M, Monaco E, de Pádua VBC, Thaumat M, Wilson A, Zaffagnini S, Zijl J, Claes S. Anterolateral Ligament Expert Group consensus paper on the management of internal rotation and instability of the anterior cruciate ligament - deficient knee. *J Orthop Traumatol* 2017; **18**: 91-106 [PMID: [28220268](#) DOI: [10.1007/s10195-017-0449-8](#)]
- 36 **Lemaire M**, Combelles F. Plastic repair with fascia lata for old tears of the anterior cruciate ligament (author's transl). *Rev Chir Orthop Reparatrice Appar Mot* 1980; **66**: 523-525 [PMID: [6451004](#)]
- 37 **Christel P**, Djian P. [Anterio-lateral extra-articular tenodesis of the knee using a short strip of fascia lata]. *Rev Chir Orthop Reparatrice Appar Mot* 2002; **88**: 508-513 [PMID: [12399717](#)]
- 38 **Mathew M**, Dhollander A, Getgood A. Anterolateral Ligament Reconstruction or Extra-Articular Tenodesis: Why and When? *Clin Sports Med* 2018; **37**: 75-86 [PMID: [29173559](#) DOI: [10.1016/j.csm.2017.07.011](#)]
- 39 **Abusleme S**, Strömback L, Caracciolo G, Zamorano H, Cheyre J, Vergara F, Yañez R. Lateral Extra-articular Tenodesis: A Technique With an Iliotibial Band Strand Without Implants. *Arthrosc Tech* 2021; **10**: e85-e89 [PMID: [33532213](#) DOI: [10.1016/j.eats.2020.09.029](#)]
- 40 **Amirault JD**, Cameron JC, MacIntosh DL, Marks P. Chronic anterior cruciate ligament deficiency. Long-term results of MacIntosh's lateral substitution reconstruction. *J Bone Joint Surg Br* 1988; **70**: 622-624 [PMID: [3403611](#) DOI: [10.1302/0301-620x.70b4.3403611](#)]
- 41 **Andrews JR**, Sanders R. A "mini-reconstruction" technique in treating anterolateral rotatory instability (ALRI). *Clin Orthop Relat Res* 1983; **93**: 93-96 [PMID: [6822011](#)]
- 42 **Benum P**. Anterolateral rotary instability of the knee joint. Results after stabilization by extraarticular transposition of the lateral part of the patellar ligament. A preliminary report. *Acta Orthop Scand* 1982; **53**: 613-617 [PMID: [7102280](#) DOI: [10.3109/17453678208992267](#)]
- 43 **Engelbrechtsen L**, Lew WD, Lewis JL, Hunter RE. The effect of an iliotibial tenodesis on intraarticular graft forces and knee joint motion. *Am J Sports Med* 1990; **18**: 169-176 [PMID: [2343985](#) DOI: [10.1177/036354659001800210](#)]
- 44 **Sonnery-Cottet B**, Barbosa NC, Tuteja S, Daggett M, Kajetanek C, Thaumat M. Minimally Invasive Anterolateral Ligament Reconstruction in the Setting of Anterior Cruciate Ligament Injury. *Arthrosc Tech* 2016; **5**: e211-e215 [PMID: [27274456](#) DOI: [10.1016/j.eats.2015.11.005](#)]
- 45 **Smith JO**, Yaseen SK, Lord B, Wilson AJ. Combined anterolateral ligament and anatomic anterior cruciate ligament reconstruction of the knee. *Knee Surg Sports Traumatol Arthrosc* 2015; **23**: 3151-3156 [PMID: [26387120](#) DOI: [10.1007/s00167-015-3783-5](#)]
- 46 **Goncharov EN**, Koval OA, Dubrov VE, Bezuglov EN, Filimonova AM, Goncharov NG. Clinical experience with combined reconstruction of the anterior cruciate and anterolateral ligaments of the knee in sportsmen. *Int Orthop* 2019; **43**: 2781-2788 [PMID: [31511952](#) DOI: [10.1007/s00264-019-04409-8](#)]
- 47 **Delaloye JR**, Murar J, Vieira TD, Saithna A, Barth J, Ouanezar H, Sonnery-Cottet B. Combined Anterior Cruciate Ligament Repair and Anterolateral Ligament Reconstruction. *Arthrosc Tech* 2019; **8**: e23-e29 [PMID: [30899647](#) DOI: [10.1016/j.eats.2018.08.025](#)]
- 48 **Ferreira Mde C**, Zidan FF, Miduati FB, Fortuna CC, Mizutani BM, Abdalla RJ. Reconstruction of anterior cruciate ligament and anterolateral ligament using interlinked hamstrings - technical note. *Rev Bras Ortop* 2016; **51**: 466-470 [PMID: [27517028](#) DOI: [10.1016/j.rboe.2015.08.021](#)]
- 49 **Colombet PD**. Navigated intra-articular ACL reconstruction with additional extra-articular tenodesis using the same hamstring graft. *Knee Surg Sports Traumatol Arthrosc* 2011; **19**: 384-389 [PMID: [20811736](#) DOI: [10.1007/s00167-010-1223-0](#)]
- 50 **Kim MS**, Koh IJ, In Y. Isometric Anterolateral Ligament Reconstruction Using the Semitendinosus Tendon With Suspensory Tibial Fixation. *Arthrosc Tech* 2020; **9**: e941-e945 [PMID: [32714802](#) DOI: [10.1016/j.eats.2020.03.017](#)]
- 51 **Zarins B**, Rowe CR. Combined anterior cruciate-ligament reconstruction using semitendinosus tendon and iliotibial tract. *J Bone Joint Surg Am* 1986; **68**: 160-177 [PMID: [3944155](#)]

- 52 **Escudeiro de Oliveira D**, Picchi Zaccharias V, Mayumi Horita M, Gabriel Betoni Guglielmetti L, Duarte Junior A, Baches Jorge P. Anterior Cruciate and Anterolateral Ligament Reconstruction Using Hamstring and Peroneus Longus Tendons: Surgical Technique Description. *Arthrosc Tech* 2021; **10**: e397-e402 [PMID: 33680771 DOI: 10.1016/j.eats.2020.10.030]
- 53 **Josipović M**, Vlašić J, Serdar J, Šimunović M, Nizić D, Schauperl Z, Bojanić I, Jelić M. Plantaris tendon: a novel graft for anterolateral ligament reconstruction and additional reinforcement for anterior cruciate ligament autografts in combined reconstructive procedures. *Knee Surg Sports Traumatol Arthrosc* 2020; **28**: 2604-2608 [PMID: 32047996 DOI: 10.1007/s00167-020-05885-x]
- 54 **Marshall JL**, Warren RF, Wickiewicz TL, Reider B. The anterior cruciate ligament: a technique of repair and reconstruction. *Clin Orthop Relat Res* 1979; **97**: 97-106 [PMID: 389520]
- 55 **Dupont JY**, Bellier G, O'Brien WR. Modified Marshall-MacIntosh technique for anterior cruciate ligament substitution with early knee rehabilitation. *Techniques in Orthopaedics* 1988; **2**: 28-35 [DOI: 10.1097/00013611-198801000-00005]
- 56 **McGuire DA**, Wolchok JC. Extra-articular lateral reconstruction technique. *Arthroscopy* 2000; **16**: 553-557 [PMID: 10882455 DOI: 10.1053/jars.2000.7670]
- 57 **Chahla J**, Menge TJ, Mitchell JJ, Dean CS, LaPrade RF. Anterolateral Ligament Reconstruction Technique: An Anatomic-Based Approach. *Arthrosc Tech* 2016; **5**: e453-e457 [PMID: 27656361 DOI: 10.1016/j.eats.2016.01.032]
- 58 **Maestro Fernández A**, Pipa Muñoz I, Rodríguez García N. Two-Stage Anterior Cruciate Ligament Reconstruction Revision Surgery for Severe Bone Defects With Anterolateral Ligament Reconstruction Technique. *Arthrosc Tech* 2020; **9**: e327-e337 [PMID: 32226739 DOI: 10.1016/j.eats.2019.11.001]
- 59 **Wagih AM**, Elguindy AM. Percutaneous Reconstruction of the Anterolateral Ligament of the Knee With a Polyester Tape. *Arthrosc Tech* 2016; **5**: e691-e697 [PMID: 27709023 DOI: 10.1016/j.eats.2016.02.028]
- 60 **Jette C**, Gutierrez D, Sastre S, Llusà M, Combalia A. Biomechanical comparison of anterolateral ligament anatomical reconstruction with a semi-anatomical lateral extra-articular tenodesis. A cadaveric study. *Knee* 2019; **26**: 1003-1009 [PMID: 31427244 DOI: 10.1016/j.knee.2019.07.005]
- 61 **Inderhaug E**, Stephen JM, Williams A, Amis AA. Anterolateral Tenodesis or Anterolateral Ligament Complex Reconstruction: Effect of Flexion Angle at Graft Fixation When Combined With ACL Reconstruction. *Am J Sports Med* 2017; **45**: 3089-3097 [PMID: 28898106 DOI: 10.1177/0363546517724422]
- 62 **Geeslin AG**, Moatshe G, Chahla J, Kruckeberg BM, Muckenhirn KJ, Dornan GJ, Coggins A, Brady AW, Getgood AM, Godin JA, LaPrade RF. Anterolateral Knee Extra-articular Stabilizers: A Robotic Study Comparing Anterolateral Ligament Reconstruction and Modified Lemaire Lateral Extra-articular Tenodesis. *Am J Sports Med* 2018; **46**: 607-616 [PMID: 29268024 DOI: 10.1177/0363546517745268]
- 63 **Monaco E**, Lanzetti RM, Fabbri M, Redler A, De Carli A, Ferretti A. Anterolateral ligament reconstruction with autologous grafting: A biomechanical study. *Clin Biomech (Bristol, Avon)* 2017; **44**: 99-103 [PMID: 28384527 DOI: 10.1016/j.clinbiomech.2017.03.013]
- 64 **Ra HJ**, Kim JH, Lee DH. Comparative clinical outcomes of anterolateral ligament reconstruction versus lateral extra-articular tenodesis in combination with anterior cruciate ligament reconstruction: systematic review and meta-analysis. *Arch Orthop Trauma Surg* 2020; **140**: 923-931 [PMID: 32140829 DOI: 10.1007/s00402-020-03393-8]
- 65 **Spencer L**, Burkhart TA, Tran MN, Rezansoff AJ, Deo S, Catherine S, Getgood AM. Biomechanical analysis of simulated clinical testing and reconstruction of the anterolateral ligament of the knee. *Am J Sports Med* 2015; **43**: 2189-2197 [PMID: 26093007 DOI: 10.1177/0363546515589166]
- 66 **Deviandri R**, van der Veen HC. Isolated lateral extra-articular tenodesis enhance better rotatory knee joint stability post-primary ACL repair: Four cases report and literature review. *Int J Surg Case Rep* 2021; **84**: 106167 [PMID: 34229212 DOI: 10.1016/j.ijscr.2021.106167]
- 67 **Yin J**, Yang K, Zheng D, Xu N. Anatomic reconstruction of the anterior cruciate ligament of the knee with or without reconstruction of the anterolateral ligament: A meta-analysis. *J Orthop Surg (Hong Kong)* 2021; **29**: 2309499020985195 [PMID: 33410381 DOI: 10.1177/2309499020985195]
- 68 **Beckers L**, Vivacqua T, Firth AD, Getgood AMJ. Clinical outcomes of contemporary lateral augmentation techniques in primary ACL reconstruction: a systematic review and meta-analysis. *J Exp Orthop* 2021; **8**: 59 [PMID: 34383156 DOI: 10.1186/s40634-021-00368-5]
- 69 **Na BR**, Kwak WK, Seo HY, Seon JK. Clinical Outcomes of Anterolateral Ligament Reconstruction or Lateral Extra-articular Tenodesis Combined With Primary ACL Reconstruction: A Systematic Review With Meta-analysis. *Orthop J Sports Med* 2021; **9**: 23259671211023099 [PMID: 34541008 DOI: 10.1177/23259671211023099]
- 70 **Sonnery-Cottet B**, Haidar I, Rayes J, Fradin T, Ngbilo C, Vieira TD, Freychet B, Ouanezar H, Saithna A. Long-term Graft Rupture Rates After Combined ACL and Anterolateral Ligament Reconstruction Versus Isolated ACL Reconstruction: A Matched-Pair Analysis From the SANTI Study Group. *Am J Sports Med* 2021; **49**: 2889-2897 [PMID: 34351825 DOI: 10.1177/03635465211028990]
- 71 **Ariel de Lima D**, de Lima LL, de Souza NGR, de Moraes Perez RA, Sobrado MF, Guimarães TM, Helito CP. Clinical outcomes of combined anterior cruciate ligament and anterolateral ligament reconstruction: a systematic review and meta-analysis. *Knee Surg Relat Res* 2021; **33**: 33 [PMID: 34556187 DOI: 10.1186/s43019-021-00115-1]
- 72 **Guenther D**, Irrázaval S, Bell KM, Rahnama-Azar AA, Fu FH, Debski RE, Musahl V. The Role of Extra-Articular Tenodesis in Combined ACL and Anterolateral Capsular Injury. *J Bone Joint Surg Am* 2017; **99**: 1654-1660 [PMID: 28976430 DOI: 10.2106/jbjs.16.01462]
- 73 **Smith PA**, Bley JA. Minimally Invasive Anterolateral Ligament Reconstruction of the Knee. *Arthrosc Tech* 2016; **5**: e1449-e1455 [PMID: 28560142 DOI: 10.1016/j.eats.2016.08.017]



Published by **Baishideng Publishing Group Inc**
7041 Koll Center Parkway, Suite 160, Pleasanton, CA 94566, USA

Telephone: +1-925-3991568

E-mail: bpgoffice@wjgnet.com

Help Desk: <https://www.f6publishing.com/helpdesk>

<https://www.wjgnet.com>

