

World Journal of *Clinical Cases*

World J Clin Cases 2022 August 26; 10(24): 8432-8807



Contents

Thrice Monthly Volume 10 Number 24 August 26, 2022

EDITORIAL

- 8432** Evolution of *World Journal of Clinical Cases* over the past 5 years
Muthu S

OPINION REVIEW

- 8436** NF- κ B: A novel therapeutic pathway for gastroesophageal reflux disease?
Zhang ML, Ran LQ, Wu MJ, Jia QC, Qin ZM, Peng YG

MINIREVIEWS

- 8443** Obligate aerobic, gram-positive, weak acid-fast, nonmotile bacilli, *Tsukamurella tyrosinosolvens*: Minireview of a rare opportunistic pathogen
Usuda D, Tanaka R, Suzuki M, Shimozawa S, Takano H, Hotchi Y, Tokunaga S, Osugi I, Katou R, Ito S, Mishima K, Kondo A, Mizuno K, Takami H, Komatsu T, Oba J, Nomura T, Sugita M
- 8450** Diffusion tensor imaging pipeline measures of cerebral white matter integrity: An overview of recent advances and prospects
Safri AA, Nassir CMNCM, Iman IN, Mohd Taib NH, Achuthan A, Mustapha M
- 8463** Graft choices for anterolateral ligament knee reconstruction surgery: Current concepts
Chalidis B, Pitsilos C, Kitridis D, Givissis P
- 8474** Overview of the anterolateral complex of the knee
Garcia-Mansilla I, Zicaro JP, Martinez EF, Astoul J, Yacuzzi C, Costa-Paz M
- 8482** Complication of lengthening and the role of post-operative care, physical and psychological rehabilitation among fibula hemimelia
Salimi M, Sarallah R, Javanshir S, Mirghaderi SP, Salimi A, Khanzadeh S

ORIGINAL ARTICLE

Clinical and Translational Research

- 8490** Pyroptosis-related genes play a significant role in the prognosis of gastric cancer
Guan SH, Wang XY, Shang P, Du QC, Li MZ, Xing X, Yan B

Retrospective Study

- 8506** Effects of propofol combined with lidocaine on hemodynamics, serum adrenocorticotrophic hormone, interleukin-6, and cortisol in children
Shi S, Gan L, Jin CN, Liu RF
- 8514** Correlation analysis of national elite Chinese male table tennis players' shoulder proprioception and muscle strength
Shang XD, Zhang EM, Chen ZL, Zhang L, Qian JH

- 8525** Clinical value of contrast-enhanced ultrasound in early diagnosis of small hepatocellular carcinoma (≤ 2 cm)

Mei Q, Yu M, Chen Q

- 8535** Identification of predictive factors for post-transarterial chemoembolization liver failure in hepatocellular carcinoma patients: A retrospective study

Yuan M, Chen TY, Chen XR, Lu YF, Shi J, Zhang WS, Ye C, Tang BZ, Yang ZG

- 8547** Clinical significance of half-hepatic blood flow occlusion technology in patients with hepatocellular carcinoma with cirrhosis

Liu D, Fang JM, Chen XQ

- 8556** Which octogenarian patients are at higher risk after cholecystectomy for symptomatic gallstone disease? A single center cohort study

D'Acapito F, Solaini L, Di Pietrantonio D, Tauceri F, Mirarchi MT, Antelmi E, Flamini F, Amato A, Framarini M, Ercolani G

Clinical Trials Study

- 8568** Computed tomography combined with gastroscopy for assessment of pancreatic segmental portal hypertension

Wang YL, Zhang HW, Lin F

Observational Study

- 8578** Psychological needs of parents of children with complicated congenital heart disease after admitting to pediatric intensive care unit: A questionnaire study

Zhu JH, Jin CD, Tang XM

Prospective Study

- 8587** Quantitative differentiation of malignant and benign thyroid nodules with multi-parameter diffusion-weighted imaging

Zhu X, Wang J, Wang YC, Zhu ZF, Tang J, Wen XW, Fang Y, Han J

Randomized Controlled Trial

- 8599** Application of unified protocol as a transdiagnostic treatment for emotional disorders during COVID-19: An internet-delivered randomized controlled trial

Yan K, Yusufi MH, Nazari N

- 8615** High-flow nasal cannula oxygen therapy during anesthesia recovery for older orthopedic surgery patients: A prospective randomized controlled trial

Li XN, Zhou CC, Lin ZQ, Jia B, Li XY, Zhao GF, Ye F

SYSTEMATIC REVIEWS

- 8625** Assessment tools for differential diagnosis of neglect: Focusing on egocentric neglect and allocentric neglect

Lee SH, Lim BC, Jeong CY, Kim JH, Jang WH

CASE REPORT

- 8634** Exome analysis for Cronkhite-Canada syndrome: A case report
Li ZD, Rong L, He YJ, Ji YZ, Li X, Song FZ, Li XA
- 8641** Discrepancy between non-invasive prenatal testing result and fetal karyotype caused by rare confined placental mosaicism: A case report
Li Z, Lai GR
- 8648** Paroxysmal speech disorder as the initial symptom in a young adult with anti-N-methyl-D-aspartate receptor encephalitis: A case report
Hu CC, Pan XL, Zhang MX, Chen HF
- 8656** Anesthetics management of a renal angiomyolipoma using pulse pressure variation and non-invasive cardiac output monitoring: A case report
Jeon WJ, Shin WJ, Yoon YJ, Park CW, Shim JH, Cho SY
- 8662** Traumatic giant cell tumor of rib: A case report
Chen YS, Kao HW, Huang HY, Huang TW
- 8667** Analysis of two naval pilots' ejection injuries: Two case reports
Zeng J, Liu XP, Yi JC, Lu X, Liu DD, Jiang YQ, Liu YB, Tian JQ
- 8673** Beware of the DeBakey type I aortic dissection hidden by ischemic stroke: Two case reports
Chen SQ, Luo WL, Liu W, Wang LZ
- 8679** Unilateral lichen planus with Blaschko line distribution: A case report
Dong S, Zhu WJ, Xu M, Zhao XQ, Mou Y
- 8686** Clinical features and progress of ischemic gastritis with high fatalities: Seven case reports
Shionoya K, Sasaki A, Moriya H, Kimura K, Nishino T, Kubota J, Sumida C, Tasaki J, Ichita C, Makazu M, Masuda S, Koizumi K, Kawachi J, Tsukiyama T, Kako M
- 8695** Retinoblastoma in an older child with secondary glaucoma as the first clinical presenting symptom: A case report
Zhang Y, Tang L
- 8703** Recurrent herpes zoster in a rheumatoid arthritis patient treated with tofacitinib: A case report and review of the literature
Lin QX, Meng HJ, Pang YY, Qu Y
- 8709** Intra-abdominal ectopic bronchogenic cyst with a mucinous neoplasm harboring a *GNAS* mutation: A case report
Murakami T, Shimizu H, Yamazaki K, Nojima H, Usui A, Kosugi C, Shuto K, Obi S, Sato T, Yamazaki M, Koda K
- 8718** Effects of intravascular photobiomodulation on motor deficits and brain perfusion images in intractable myasthenia gravis: A case report
Lan CH, Wu YC, Chiang CC, Chang ST

- 8728** Spontaneous acute epidural hematoma secondary to skull and dural metastasis of hepatocellular carcinoma: A case report
Lv GZ, Li GC, Tang WT, Zhou D, Yang Y
- 8735** Malignant melanotic nerve sheath tumors in the spinal canal of psammomatous and non-psammomatous type: Two case reports
Yeom JA, Song YS, Lee IS, Han IH, Choi KU
- 8742** When should endovascular gastrointestinal anastomosis transection Glissonean pedicle not be used in hepatectomy? A case report
Zhao J, Dang YL
- 8749** VARS2 gene mutation leading to overall developmental delay in a child with epilepsy: A case report
Wu XH, Lin SZ, Zhou YQ, Wang WQ, Li JY, Chen QD
- 8755** Junctional bradycardia in a patient with COVID-19: A case report
Aedh AI
- 8761** Application of 3 dimension-printed injection-molded polyether ether ketone lunate prosthesis in the treatment of stage III Kienböck's disease: A case report
Yuan CS, Tang Y, Xie HQ, Liang TT, Li HT, Tang KL
- 8768** High scored thyroid storm after stomach cancer perforation: A case report
Baik SM, Pae Y, Lee JM
- 8775** Cholecystitis-an uncommon complication following thoracic duct embolization for chylothorax: A case report
Dung LV, Hien MM, Tra My TT, Luu DT, Linh LT, Duc NM
- 8782** Endometrial squamous cell carcinoma originating from the cervix: A case report
Shu XY, Dai Z, Zhang S, Yang HX, Bi H
- 8788** Type 2 autoimmune pancreatitis associated with severe ulcerative colitis: Three case reports
Ghali M, Bensted K, Williams DB, Ghaly S
- 8797** Diffuse uterine leiomyomatosis: A case report and review of literature
Ren HM, Wang QZ, Wang JN, Hong GJ, Zhou S, Zhu JY, Li SJ

LETTER TO THE EDITOR

- 8805** Comment on "Posterior reversible encephalopathy syndrome in a patient with metastatic breast cancer: A case report"
Kunić S, Ibrahimagić OČ, Kojić B, Džananović D

ABOUT COVER

Editorial Board Member of *World Journal of Clinical Cases*, Ahmed Mohamed Ahmed Al-Emam, PhD, Associate Professor, Department of Pathology, King Khalid University, Abha 62521, Saudi Arabia. amalemam@kku.edu.sa

AIMS AND SCOPE

The primary aim of *World Journal of Clinical Cases* (WJCC, *World J Clin Cases*) is to provide scholars and readers from various fields of clinical medicine with a platform to publish high-quality clinical research articles and communicate their research findings online.

WJCC mainly publishes articles reporting research results and findings obtained in the field of clinical medicine and covering a wide range of topics, including case control studies, retrospective cohort studies, retrospective studies, clinical trials studies, observational studies, prospective studies, randomized controlled trials, randomized clinical trials, systematic reviews, meta-analysis, and case reports.

INDEXING/ABSTRACTING

The WJCC is now abstracted and indexed in Science Citation Index Expanded (SCIE, also known as SciSearch®), Journal Citation Reports/Science Edition, Current Contents®/Clinical Medicine, PubMed, PubMed Central, Scopus, Reference Citation Analysis, China National Knowledge Infrastructure, China Science and Technology Journal Database, and Superstar Journals Database. The 2022 Edition of Journal Citation Reports® cites the 2021 impact factor (IF) for WJCC as 1.534; IF without journal self cites: 1.491; 5-year IF: 1.599; Journal Citation Indicator: 0.28; Ranking: 135 among 172 journals in medicine, general and internal; and Quartile category: Q4. The WJCC's CiteScore for 2021 is 1.2 and Scopus CiteScore rank 2021: General Medicine is 443/826.

RESPONSIBLE EDITORS FOR THIS ISSUE

Production Editor: *Ying-Yi Yuan*; Production Department Director: *Xu Guo*; Editorial Office Director: *Jin-Lei Wang*.

NAME OF JOURNAL

World Journal of Clinical Cases

ISSN

ISSN 2307-8960 (online)

LAUNCH DATE

April 16, 2013

FREQUENCY

Thrice Monthly

EDITORS-IN-CHIEF

Bao-Gan Peng, Jerzy Tadeusz Chudek, George Kontogeorgos, Maurizio Serati, Ja Hyeon Ku

EDITORIAL BOARD MEMBERS

<https://www.wjgnet.com/2307-8960/editorialboard.htm>

PUBLICATION DATE

August 26, 2022

COPYRIGHT

© 2022 Baishideng Publishing Group Inc

INSTRUCTIONS TO AUTHORS

<https://www.wjgnet.com/bpg/gerinfo/204>

GUIDELINES FOR ETHICS DOCUMENTS

<https://www.wjgnet.com/bpg/GerInfo/287>

GUIDELINES FOR NON-NATIVE SPEAKERS OF ENGLISH

<https://www.wjgnet.com/bpg/gerinfo/240>

PUBLICATION ETHICS

<https://www.wjgnet.com/bpg/GerInfo/288>

PUBLICATION MISCONDUCT

<https://www.wjgnet.com/bpg/gerinfo/208>

ARTICLE PROCESSING CHARGE

<https://www.wjgnet.com/bpg/gerinfo/242>

STEPS FOR SUBMITTING MANUSCRIPTS

<https://www.wjgnet.com/bpg/GerInfo/239>

ONLINE SUBMISSION

<https://www.f6publishing.com>

Retrospective Study

Clinical significance of half-hepatic blood flow occlusion technology in patients with hepatocellular carcinoma with cirrhosis

Dong Liu, Jian-Ming Fang, Xian-Qi Chen

Specialty type: Gastroenterology and hepatology**Provenance and peer review:** Unsolicited article; Externally peer reviewed.**Peer-review model:** Single blind**Peer-review report's scientific quality classification**Grade A (Excellent): 0
Grade B (Very good): B
Grade C (Good): C
Grade D (Fair): 0
Grade E (Poor): 0**P-Reviewer:** Honda M, Japan;
Mahmud N, United States**Received:** April 19, 2022**Peer-review started:** April 19, 2022**First decision:** May 11, 2022**Revised:** May 23, 2022**Accepted:** July 20, 2022**Article in press:** July 20, 2022**Published online:** August 26, 2022**Dong Liu**, Department of General Surgery, Yongkang First People's Hospital of Zhejiang Province, Yongkang 321300, Zhejiang Province, China**Jian-Ming Fang, Xian-Qi Chen**, Department of Hepatopancreatobiliary Surgery, Jinhua Guangfu Oncology Hospital, Jinhua 321000, Zhejiang Province, China**Corresponding author:** Xian-Qi Chen, BM BCh, Attending Doctor, Department of Hepatopancreatobiliary Surgery, Jinhua Guangfu Oncology Hospital, No. 1296 Huancheng North Road, Jinhua 321000, Zhejiang Province, China. cxqclz1988@163.com

Abstract

BACKGROUND

Most patients with primary hepatocellular carcinoma (HCC) have a history of chronic hepatitis B and usually present with varying degrees of cirrhosis. Owing to the special nature of liver anatomy, the blood vessel wall in the liver parenchyma is thin and prone to bleeding. Heavy bleeding and blood transfusion during hepatectomy are independent risk factors for liver cancer recurrence and death. Various clinical methods have been used to reduce intraoperative bleeding, and the Pringle method is most widely used to prevent blood flow to the liver.

AIM

To investigate the effect of half-hepatic blood flow occlusion after patients with HCC and cirrhosis undergo hepatectomy.

METHODS

This retrospective study included 88 patients with HCC and liver cirrhosis who underwent hepatectomy in our hospital from January 2017 to September 2020. Patients were divided into two groups based on the following treatment methods: the research group ($n = 44$), treated with half-hepatic blood flow occlusion technology and the control group ($n = 44$), treated with total hepatic occlusion. Differences in operation procedure, blood transfusion, liver function, tumor markers, serum inflammatory response, and incidence of surgical complications were compared between the groups.

RESULTS

The operation lasted longer in the research group than in the control group (273.0 ± 24.8 min vs 256.3 ± 28.5 min, $P < 0.05$), and the postoperative anal exhaust time was shorter in the research group than in the control group (50.0 ± 9.7 min vs 55.1

± 10.4 min, $P < 0.05$). There was no statistically significant difference in incision length, surgical bleeding, portal block time, drainage tube indwelling time, and hospital stay between the research and control groups ($P > 0.05$). Before surgery, there were no significant differences in serum alanine transaminase (ALT), aspartate aminotransferase (AST), total bilirubin, and prealbumin levels between the research and control groups ($P > 0.05$). Conversely, 24 and 72 h after the operation the respective serum ALT (378.61 ± 77.49 U/L and 246.13 ± 54.06 U/L) and AST (355.30 ± 69.50 U/L and 223.47 ± 48.64 U/L) levels in the research group were significantly lower ($P < 0.05$) than those in the control group (ALT, 430.58 ± 83.67 U/L and 281.35 ± 59.61 U/L; AST, 416.49 ± 73.03 U/L and 248.62 ± 50.10 U/L). The operation complication rate did not significantly differ between the research group (15.91%) and the control group (22.73%; $P > 0.05$).

CONCLUSION

Half-hepatic blood flow occlusion technology is more beneficial than total hepatic occlusion in reducing liver function injury in hepatectomy for patients with HCC and cirrhosis.

Key Words: Hepatocirrhosis; Hepatocellular carcinoma; Hepatectomy; Hepatic occlusion; Liver function

©The Author(s) 2022. Published by Baishideng Publishing Group Inc. All rights reserved.

Core Tip: There are differences in the selection of different blood-flow blocking techniques during hepatocellular carcinoma (HCC) surgery. We explore surgical effect of half hepatic blood flow occlusion and liver function recovery of patients with hepatocirrhosis HCC in hepatectomy.

Citation: Liu D, Fang JM, Chen XQ. Clinical significance of half-hepatic blood flow occlusion technology in patients with hepatocellular carcinoma with cirrhosis. *World J Clin Cases* 2022; 10(24): 8547-8555

URL: <https://www.wjgnet.com/2307-8960/full/v10/i24/8547.htm>

DOI: <https://dx.doi.org/10.12998/wjcc.v10.i24.8547>

INTRODUCTION

Hepatocellular carcinoma (HCC) accounts for 90% of all primary liver tumors[1]. Most patients with HCC often also have cirrhosis, and the recurrence of microvascular tumor thrombi has been increasing. Currently, radical surgery is the preferred treatment for HCC; however, massive intraoperative bleeding and blood transfusion may increase the incidence of postoperative complications, mortality, and the possibility of recurrence and metastasis of HCC[2,3]. The vascular distribution of the liver is more complex, and the blood supply is rich. Therefore, effective control of bleeding during hepatectomy has been the focus of liver surgery research[4]. In 1988, researchers proposed a method of vascular occlusion during hepatectomy that could be used to control intraoperative blood loss. The classical Pringle total hepatic occlusion and selective semi-hepatic occlusion techniques are mainly used in clinical practice[5]. However, there are differences in the selection of different blood-flow blocking techniques during tumor surgery. This study selected patients with HCC and liver cirrhosis scheduled to undergo hepatectomy in our hospital to explore the postoperative surgical effect of half hepatic blood flow occlusion and liver function recovery in this patient population.

MATERIALS AND METHODS

General data

This retrospective single-blinded study included 88 patients with HCC and liver cirrhosis who underwent hepatectomy from January 2017 to September 2020 in our hospital and were divided into an observation group and a control group (44 patients in each group). The inclusion criteria were based on the diagnostic criteria for patients with HCC in the code for the diagnosis and treatment of primary liver cancer (2011 edition)[6] as follows: confirmed preoperative computed tomography and magnetic resonance imaging examinations or confirmed liver biopsy, age of ≤ 75 years, mild cirrhosis, preoperative Child-Pugh liver function grade A or B[7], and tumor diameter of 2.0–6.0 cm. This study met the relevant requirements of the Medical Ethics Committee, and written informed consent was obtained from the patients. The exclusion criteria were as follows: patients with metastasis to other abdominal organs, with other malignant tumors, history of cerebrovascular or myocardial infarction within the last 6 mo, with history of parasitic diseases such as liver echinococcosis, and with anemia or

malnutrition.

The research group included patients aged 50–75 years, with an average age of 60.6 ± 5.0 years (26 men and 18 women). Forty patients had preoperative Child-Pugh grade A and four patients had grade B. The mean lesion diameter was 5.18 ± 1.00 cm. History of hepatitis B virus infection was noted in 32 cases. The mean serum alpha-fetoprotein (AFP) value was 240.8 ± 75.6 ng/L. Regarding the surgical resection scope, there were ≥ 3 Liver segments in 18 cases and < 3 Liver segments in 26 cases. The control group included patients aged 48–75 years, with an average age of 61.3 ± 5.5 years (22 men and 22 women). Thirty-seven patients had preoperative Child-Pugh grade A and seven patients had grade B. The mean lesion diameter was 5.08 ± 1.30 cm. History of hepatitis B virus infection was noted in 27 cases, and the mean serum AFP value was 228.6 ± 66.3 ng/L. Regarding the surgical resection scope, there were ≥ 3 Liver segments in 14 cases and < 3 liver segments in 30 cases. There was no statistically significant difference in the baseline data between the groups ($P > 0.05$), as shown in Table 1.

Operation methods

All patients underwent a right upper abdominal incision under general anesthesia. The site of the lesion and scope of resection were determined after entering the abdomen. All liver tissues were removed using forceps, and the duct with a larger wound surface was sutured and tied.

The control group was treated with the Pringle total hepatic blood flow occlusion technique, in which partial hepatectomy was performed after the hepatoduodenal ligament and entire hepatic blood flow were blocked with a normal drainage tube through the Venturi hole tightly the hepatoduodenal ligament to completely block the hepatic artery and portal vein. Every operation was controlled for 15 min, depending on the ease of operation and adjustment of the block number of operating time. If the liver tumor could not be removed within the period of closure, the operation had to be repeated for 5–10 min intermittently until the liver tumor was removed and blocked at most twice.

Half-hepatic blood flow occlusion technology was used in the research group. The first hepatic portal was dissected, and the left and right hepatic veins, left and right portal veins, and left and right hepatic ducts were bluntly separated to block the branches of the hepatic artery and portal vein on the affected side to form a local ischemic area. Hepatectomy was performed along the edge of this ischemic area. Vascular forceps were used to externally separate the hilum at the upper margin of the lateral sulcus of the affected side against the Glisson sheath. The fingers of the left hand were guided behind the hepatic portal, and the vascular forceps were threaded out from behind the Glisson sheath and blocked the affected side of the liver into the hepatic blood flow with the blocking band, for < 15 min each time, and blocked again 5 min after opening. After liver resection, the wound was treated, the blood flow pathway was opened, and an abdominal drainage tube was placed.

Observation indicators and detection methods

Operation time, incision length, surgical bleeding, portal block time, postoperative anal exhaust time, drainage tube indwelling time, and hospital stay were compared between the groups. Serum alanine aminotransferase (ALT), aspartate aminotransferase (AST), total bilirubin (TBIL), prealbumin (PA), AFP, carcinoembryonic antigen (CEA), α -L furosylase (AFU), tumor necrosis factor- α (TNF- α), and interleukin-6 (IL-6) levels before and after surgery, C-reactive protein (CRP) levels, and postoperative complications were also compared between the groups.

After surgery, 5 mL fasting venous blood was collected from the patient and centrifuged at 3000 rpm for 5 min; the supernatant was collected to detect serum ALT, AST, TBIL, and PA levels. TBIL levels were determined using the vanadate method. The kit was provided by Beijing Jiuqiang Biotechnology Co., Ltd. The normal reference range was 3.0–20.0 $\mu\text{mol/L}$. AST and ALT were continuously monitored by Ningbo Purui Biotechnology Co., LTD., with the normal reference range being 0–40 U/L. The PA immunotransmission turbidimetry kit was provided by Shanghai Shenfeng Biological Reagent Co., Ltd., with a normal reference range of 200–400 mg/L. The levels of AFP, AFU, and CEA in the serum were detected using a C6000 automatic immunochemiluminescence analyzer provided by Roche. All operations were carried out in strict accordance with the requirements of the kit manufactured by Wuhan Youersheng Bioengineering Co., LTD. The normal reference values of the tumor markers were: AFP < 15 ng/mL, AFU < 40 U/L, CEA < 5.0 ng/mL, and CA19-9 < 27 U/L.

Statistical analysis

SPSS 21.0 was used for data analysis. ALT, AST, TBIL, and other measurement data of the two groups are expressed as mean \pm SD, and the *t*-test was used for inter-group comparisons. For enumeration data, the χ^2 test was used for inter-group comparisons. Statistical significance was set at $P < 0.05$.

RESULTS

Comparison of surgical process indicators between the two groups

The operation group in the research group was longer than that of the control group ($P < 0.05$).

Table 1 Comparison of baseline data between the two groups of patients, *n* (%)

Normal information	Research group (<i>n</i> = 44)	Control group (<i>n</i> = 44)	<i>t</i> / χ^2 value	<i>P</i> value
Age (yr)	60.6 ± 5.0	61.3 ± 5.5	-0.625	0.534
Lesion diameter (cm)	5.18 ± 1.00	5.08 ± 1.30	0.404	0.687
Serum AFP (ng/L)	240.8 ± 75.6	228.6 ± 66.3	0.805	0.423
Sex			0.733	0.392
Male	26 (59.09)	22 (50.00)		
Female	18 (40.91)	22 (50.00)		
Child-Pugh stage			1.252	0.263
A stage	40 (100)	37 (84.09)		
B stage	4 (9.09)	7 (15.91)		
Hepatitis B virus infection			1.286	0.257
Yes	32 (72.73)	27 (61.36)		
No	12 (27.27)	17 (38.64)		
Surgical resection range			0.786	0.375
≥ 3 liver segments	18 (40.91)	14 (31.82)		
< 3 liver segments	26 (59.09)	30 (68.18)		

Postoperative anal exhaust time in the research group was shorter than that in the control group ($P < 0.05$), with no statistically significant difference in incision length, surgical bleeding, portal block time, drainage tube indwelling time, and hospital stay between the operation group and the control group ($P > 0.05$, Table 2).

Comparison of liver function indexes between two groups of patients

Before surgery, there were no significant differences in serum ALT, AST, TBIL, and PA levels between the research and control groups ($P > 0.05$). Meanwhile, 24 h and 72 h after operation, the serum ALT and AST values in the research group were lower than those in the control group ($P < 0.05$, Table 3).

Comparison of tumor marker levels between the two groups

Before surgery, there were no significant differences in serum AFP, CEA, and AFU levels between the research group and the control group ($P > 0.05$). One month after surgery, the serum AFP, CEA, and AFU levels in the two groups were lower than those before surgery ($P < 0.05$), and there was no statistically significant difference between the two groups ($P > 0.05$, Table 4).

Comparison of inflammatory factors between the two groups of patients before and after surgery

Before surgery, there were no significant differences in serum TNF- α , IL-6, and CRP levels between the research and control groups ($P > 0.05$). The levels of TNF- α and IL-6 in the research group were lower than those in the control group ($P < 0.05$, Table 5).

Comparison of operation complication rate between the two groups

The operation complication rate of the research group was 15.91%, whereas that of the control group was 22.73%, and the difference was not statistically significant ($P > 0.05$, Figure 1).

DISCUSSION

Total hepatic blood flow occlusion during surgical resection can completely block blood return to the portal vein system, resulting in gastrointestinal tract hyperemia, impaired mucosal barrier function, and high susceptibility to bacterial and toxin infections. Long-term blocking of portal blood flow can lead to portal vein and superior mesenteric vein thromboses[8-10]. More importantly, the blood entering the liver causes ischemic reperfusion injury of the liver parenchyma and distal organs after the blood flow is restored, and the liver function is seriously impaired. Theoretically, local hemo-occlusion in the affected segment of the patient's liver is better, with minimal damage to liver function and in line with the concepts of anatomic hepatectomy and precise hepatectomy[11-13]. However, the operation process is complicated and requires mastery of color ultrasound-guided puncture technology, which has not been

Table 2 Comparison of surgical process indicators between the two groups (mean \pm SD)

Index	Research group (n = 44)	Control group (n = 44)	t value	P value
Operation time (min)	273.0 \pm 24.8	256.3 \pm 28.5	2.932	0.004
Incision length (cm)	25.98 \pm 1.55	26.14 \pm 1.64	-0.470	0.639
Surgical bleeding (mL)	626.9 \pm 105.1	598.4 \pm 97.0	1.322	0.190
Portal block time (min)	25.3 \pm 4.1	23.5 \pm 4.5	1.961	0.053
Postoperative anal exhaust time (h)	50.0 \pm 9.7	55.1 \pm 10.4	-2.379	0.020
Drainage tube indwelling time (d)	3.84 \pm 0.66	3.62 \pm 0.71	1.505	0.136
Hospital stay (d)	13.6 \pm 1.8	14.0 \pm 2.2	-0.933	0.353

Table 3 Comparison of liver function indexes between the two groups of patients (mean \pm SD)

Index	Research group (n = 44)	Control group (n = 44)	t value	P value
ALT (U/L)				
Preoperative	33.04 \pm 8.56	34.72 \pm 8.11	-0.945	0.347
24 h after operation	378.61 \pm 77.49 ^a	430.58 \pm 83.67 ^a	-3.023	0.003
72 h after operation	246.13 \pm 54.06 ^a	281.35 \pm 59.61 ^a	-2.903	0.005
AST (U/L)				
Preoperative	29.61 \pm 7.21	27.30 \pm 7.85	1.438	0.154
24 h after operation	355.30 \pm 69.50 ^a	416.49 \pm 73.03 ^a	-4.026	0.000
72 h after operation	223.47 \pm 48.64 ^a	248.62 \pm 50.10 ^a	-2.389	0.019
TBIL (μ mol/L)				
Preoperative	15.92 \pm 4.40	15.28 \pm 4.71	0.659	0.512
24 h after operation	32.85 \pm 7.01 ^a	34.06 \pm 8.43 ^a	-0.732	0.466
72 h after operation	20.46 \pm 5.83 ^a	22.90 \pm 6.15 ^a	-1.910	0.059
PA (mg/dL)				
Preoperative	313.86 \pm 46.91	320.74 \pm 51.67	-0.654	0.515
24 h after operation	194.82 \pm 32.65 ^a	188.57 \pm 29.48 ^a	0.942	0.349
72 h after operation	275.12 \pm 41.81 ^a	269.84 \pm 46.10 ^a	0.563	0.575

^aP < 0.05 vs this group before surgery.

ALT: Alanine transaminase; AST: Aspartate aminotransferase; TBIL: Total bilirubin; PA: Prealbumin.

popularized. Although half-hepatic blood flow occlusion technology cannot directly block local liver blood flow from entering the liver, it retains all blood supply to the healthy side of the liver, and intraoperatively greatly reduces healthy-side liver parenchyma ischemia-reperfusion injury, causing minor damage to the liver; after surgery, liver function can be quickly restored, which is obviously advantageous in operations for hepatitis and hepatocirrhosis[14-17].

Our study showed that the operation lasted longer in the research group than in the control group. There was no statistically significant difference in incision length, surgical bleeding, portal block time, drainage tube indwelling time, and hospital stay between the operation and control groups, indicating that control of half-hepatic blood flow during the operation was similar to that during use of the complete hepatic occlusion technique, which could effectively reduce bleeding. The half-hepatic blood flow occlusion technique requires detailed intrathecal dissection of the first hilum of the liver, thus increasing the difficulty of the operation and the operative time. The technique of hepatic blood flow occlusion for hepatectomy can easily lead to liver ischemia and hypoxia, which can cause liver tissue damage and liver function impairment[18]. Meanwhile, 24 and 72 h after the operation, the serum ALT and AST levels in the research group were significantly lower than those in the control group, indicating that the half-hepatic blood flow occlusion technique is superior for postoperative liver function recovery. The reason is that half-hepatic occlusion does not markedly influence the hemodynamics, and

Table 4 Comparison of tumor marker levels between the two groups (mean \pm SD)

Index	Research group (n = 44)	Control group (n = 44)	t value	P value
AFU (U/L)				
Preoperative	66.41 \pm 9.51	68.18 \pm 10.84	-0.814	0.418
1 mo after operation	27.04 \pm 6.44 ^a	29.95 \pm 8.27 ^a	-1.842	0.069
AFP (ng/L)				
Preoperative	240.8 \pm 75.6	228.6 \pm 66.3	0.805	0.423
1 mo after operation	78.55 \pm 18.04 ^a	82.01 \pm 20.63 ^a	-0.837	0.405
CEA (μ g/L)				
Preoperative	18.58 \pm 4.20	20.03 \pm 4.81	-1.506	0.136
1 mo after operation	3.77 \pm 0.89 ^a	4.01 \pm 0.81 ^a	-1.323	0.189

^aP < 0.05 *vs* this group before surgery.

AFU: Alpha-L fasyolase; AFP: Alpha-fetoprotein; CEA: Carcinoembryonic antigen.

Table 5 Comparison of inflammatory factors between the two groups of patients before and after surgery (mean \pm SD)

Index	Research group (n = 44)	Control group (n = 44)	t value	P value
IL-6 (pg/mL)				
Preoperative	54.23 \pm 9.50	56.39 \pm 9.11	-1.089	0.279
24 h after operation	97.41 \pm 17.59	108.26 \pm 18.25	-2.839	0.006
72 h after operation	70.55 \pm 13.02	74.18 \pm 14.40	-1.240	0.218
TNF- α (pg/mL)				
Preoperative	68.33 \pm 13.20	70.53 \pm 12.65	-0.798	0.427
24 h after operation	148.12 \pm 21.04	167.00 \pm 24.28	-3.898	0.000
72 h after operation	98.40 \pm 13.27	102.73 \pm 15.19	-1.424	0.158
CRP (mg/L)				
Preoperative	4.91 \pm 1.53	5.34 \pm 1.58	-1.297	0.198
24 h after operation	18.48 \pm 3.75	20.14 \pm 4.43	-1.897	0.061
72 h after operation	14.20 \pm 3.36	15.38 \pm 4.28	-1.438	0.154

IL-6: interleukin-6; TNF- α : tumor necrosis factor- α ; CRP: C-reactive protein.

the mesenteric blood still flows back to the systemic circulation, avoiding gastrointestinal hyperemia, intestinal bacterium and endotoxin translocation, intestinal ventricular membrane injury, and liver regeneration. After operation, healthy hepatic arteries and portal veins remain open, not affecting the blood supply, thus avoiding ischemia-reperfusion injury and having less impact on liver function, especially in patients with hepatocirrhosis and other liver-related diseases. The rate of surgical complications in the research group was lower than that in the control group. This may be because the single block time of the half-hepatic blood flow occlusion technique is long, and the portal vein and hepatic artery branches at the lesion site are directly ligated or even separated; therefore, there is sufficient time for liver parenchyma dissection, hemostasis of the liver section, and bile leakage of the section to reduce the occurrence of surgical complications. In the past, the clinical diagnosis of patients with liver cancer was mainly based on AFP levels. Although the operation was simple, the detection sensitivity was not high, and it was easy to miss the diagnosis. In this study, 1 mo after surgery, the levels of serum AFP, CEA, and AFU in both groups were lower than those before surgery ($P < 0.05$), and there was no statistically significant difference between the groups. The reason for the analysis was that the patients were relieved of tumor cell growth and other factors after surgery, and the expression levels of AFP, AFU, and CEA decreased significantly.

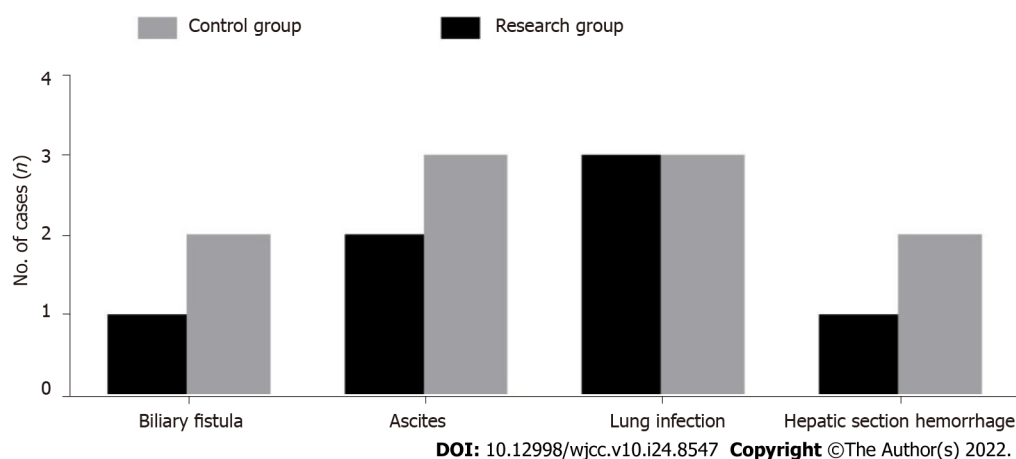


Figure 1 Histogram of complications in the two groups.

Hepatectomy has always been the primary choice for patients with HCC and liver cirrhosis. Intraoperative blood flow occlusion with a half approach to the liver and a complete approach to the liver are both safe and effective, and the choice between the two methods is controversial[19,20]. Therefore, the two methods were compared in this study. Changes in the operation process indicators were compared after the patients with hepatocirrhosis received different treatments. Postoperative liver function recovery and the occurrence of adverse reactions had certain reference values. Although half-hepatic blood flow occlusion is complicated and can prolong the operation time, it causes limited damage to liver function during the operation and is beneficial for the recovery of liver function after surgery, rendering it worthy of widespread clinical application. However, the sample size of this study was relatively small, and it is necessary to increase the sample size and detection indicators in future studies to verify the reliability of the results of this study.

CONCLUSION

In conclusion, half-hepatic blood flow occlusion technology is more beneficial than total hepatic occlusion in reducing liver function injury in patients with HCC and cirrhosis undergoing hepatectomy.

ARTICLE HIGHLIGHTS

Research background

Hepatocellular carcinoma (HCC) accounts for 90% of all primary liver tumors.

Research motivation

Currently, radical surgery is the preferred treatment for HCC.

Research objectives

This study aimed to investigate the effect of half-hepatic blood flow occlusion after patients with HCC and cirrhosis undergo hepatectomy.

Research methods

This retrospective single-blinded study included 88 patients with HCC and liver cirrhosis who underwent hepatectomy from January 2017 to September 2020 in our hospital and were divided into an observation group and a control group.

Research results

About 24 h and 72 h after the operation the respective serum alanine transaminase and aspartate aminotransferase levels in the research group were significantly lower than those in the control group.

Research conclusions

Half-hepatic blood flow occlusion technology is more beneficial than total hepatic occlusion in reducing liver function injury in patients with HCC and cirrhosis undergoing hepatectomy.

Research perspectives

However, the sample size of this study was relatively small, and it is necessary to increase the sample size and detection indicators in future studies.

FOOTNOTES

Author contributions: Liu D and Chen XQ designed the research study; Liu D performed the research; Fang JM contributed new reagents and analytic tools; Liu D analyzed the data and wrote the manuscript; and all authors have read and approve the final manuscript.

Supported by Key Scientific Research Project of Jinhua Science and Technology Bureau in 2020 Fund, No. 2020-3-069.

Institutional review board statement: The study was reviewed and approved by the Yongkang First People's Hospital of Zhejiang Province Institutional Review Board.

Informed consent statement: Patients were not required to give informed consent to the study because the analysis used anonymous clinical data that were obtained after each patient agreed to treatment by written consent.

Conflict-of-interest statement: Dr. Chen XQ reports grants from Scientific Research Project of Jinhua Science and Technology Bureau in 2020, during the conduct of the study. No other conflict of interest to declare.

Data sharing statement: No additional data are available.

Open-Access: This article is an open-access article that was selected by an in-house editor and fully peer-reviewed by external reviewers. It is distributed in accordance with the Creative Commons Attribution NonCommercial (CC BY-NC 4.0) license, which permits others to distribute, remix, adapt, build upon this work non-commercially, and license their derivative works on different terms, provided the original work is properly cited and the use is non-commercial. See: <https://creativecommons.org/licenses/by-nc/4.0/>

Country/Territory of origin: China

ORCID number: Dong Liu 0000-0002-6486-0419; Jian-Ming Fang 0000-0001-8259-3513; Xian-Qi Chen 0000-0002-3902-3256.

S-Editor: Wang JL

L-Editor: A

P-Editor: Wang JL

REFERENCES

- 1 **Hardiman O**, Al-Chalabi A, Chio A, Corr EM, Logroscino G, Robberecht W, Shaw PJ, Simmons Z, van den Berg LH. Amyotrophic lateral sclerosis. *Nat Rev Dis Primers* 2017; **3**: 17071 [PMID: 28980624 DOI: 10.1038/nrdp.2017.71]
- 2 **Kwon ED**, Drake CG, Scher HI, Fizazi K, Bossi A, van den Eertwegh AJ, Krainer M, Houede N, Santos R, Mahammedi H, Ng S, Maio M, Franke FA, Sundar S, Agarwal N, Bergman AM, Ciuleanu TE, Korbenfeld E, Sengeløv L, Hansen S, Logothetis C, Beer TM, McHenry MB, Gagnier P, Liu D, Gerritsen WR; CA184-043 Investigators. Ipilimumab versus placebo after radiotherapy in patients with metastatic castration-resistant prostate cancer that had progressed after docetaxel chemotherapy (CA184-043): a multicentre, randomised, double-blind, phase 3 trial. *Lancet Oncol* 2014; **15**: 700-712 [PMID: 24831977 DOI: 10.1016/S1470-2045]
- 3 **Huang X**, Zeng Y, Xing X, Zeng J, Gao Y, Cai Z, Xu B, Liu X, Huang A, Liu J. Quantitative proteomics analysis of early recurrence/metastasis of huge hepatocellular carcinoma following radical resection. *Proteome Sci* 2014; **12**: 22 [PMID: 24839399 DOI: 10.1186/1477-5956-12-22]
- 4 **Jin S**, Dai CL. Hepatic blood inflow occlusion without hemihepatic artery control in treatment of hepatocellular carcinoma. *World J Gastroenterol* 2010; **16**: 5895-5900 [PMID: 21155013 DOI: 10.3748/wjg.v16.i46.5895]
- 5 **Feng L**, Wang L, Rong W, Wu F, Yu W, An S, Liu F, Tian F, Wu J. [Initial comparison of regional ischemic preconditioning and hemi-hepatic vascular inflow occlusion in resection of hepatocellular carcinoma]. *Zhonghua Zhong Liu Za Zhi* 2015; **37**: 186-189 [PMID: 25975786]
- 6 **Marrero JA**. Hepatocellular carcinoma. *Curr Opin Gastroenterol* 2005; **21**: 308-312 [PMID: 15818151 DOI: 10.1097/01.mog.0000159817.55661.ca]
- 7 **Qin W**, Wang L, Hu B, Leng S, Tian H, Luo H, Yao J, Chen X, Wu C, Chen G, Yang Y. A Novel Score Predicts HBV-Related Hepatocellular Carcinoma Recurrence After Hepatectomy: a Retrospective Multicenter Study. *J Gastrointest Surg* 2019; **23**: 922-932 [PMID: 30446938 DOI: 10.1007/s11605-018-4037-x]
- 8 **Tokumitsu Y**, Sakamoto K, Tokuhisa Y, Matsui H, Matsukuma S, Maeda Y, Sakata K, Wada H, Eguchi H, Ogihara H, Fujita Y, Hamamoto Y, Iizuka N, Ueno T, Nagano H. A new prognostic model for hepatocellular carcinoma recurrence after curative hepatectomy. *Oncol Lett* 2018; **15**: 4411-4422 [PMID: 29556288 DOI: 10.3892/ol.2018.7821]

- 9 **Carr BI.** Introduction: hepatocellular carcinoma. *Semin Oncol* 2012; **39**: 367-368 [PMID: [22846854](#) DOI: [10.1053/j.seminoncol.2012.06.001](#)]
- 10 **Barreiro-Vázquez JD,** Miranda M, Barreiro-Vilanova MI, Diéguez FJ, Barreiro-Lois A. Characterization of the Normal Portal and Hepatic Blood Flow of Adult Holstein-Friesian Cows. *Animals (Basel)* 2019; **9** [PMID: [31234515](#) DOI: [10.3390/ani9060386](#)]
- 11 **Chau GY,** Lui WY, King KL, Wu CW. Evaluation of effect of hemihepatic vascular occlusion and the Pringle maneuver during hepatic resection for patients with hepatocellular carcinoma and impaired liver function. *World J Surg* 2005; **29**: 1374-1383 [PMID: [16240064](#) DOI: [10.1007/s00268-005-7766-4](#)]
- 12 **Han H,** Ji Z, Ding H, Zhang W, Zhang R, Wang W. Assessment of blood flow in the hepatic tumors using non-contrast micro flow imaging: Initial experience. *Clin Hemorheol Microcirc* 2019; **73**: 307-316 [PMID: [31156143](#) DOI: [10.3233/CH-180532](#)]
- 13 **Balci D,** Ozcelik M, Kirimker EO, Cetinkaya A, Ustuner E, Cakici M, Inan B, Alanoglu Z, Bilgic S, Akar AR. Extended left hepatectomy for intrahepatic cholangiocarcinoma: hepatic vein reconstruction with in-situ hypothermic perfusion and extracorporeal membrane oxygenation. *BMC Surg* 2018; **18**: 7 [PMID: [29386002](#) DOI: [10.1186/s12893-018-0342-2](#)]
- 14 **Jo HS,** Kim DS, Jung SW, Yu YD, Choi SB, Kim WB, Han HJ, Song TJ. Clinical significance of post-hepatectomy hepatic failure in patients with liver metastases from colorectal cancer. *Ann Hepatobiliary Pancreat Surg* 2018; **22**: 93-100 [PMID: [29896569](#) DOI: [10.14701/ahbps.2018.22.2.93](#)]
- 15 **Tzartzeva K,** Obi J, Rich NE, Parikh ND, Marrero JA, Yopp A, Waljee AK, Singal AG. Surveillance Imaging and Alpha Fetoprotein for Early Detection of Hepatocellular Carcinoma in Patients With Cirrhosis: A Meta-analysis. *Gastroenterology* 2018; **154**: 1706-1718.e1 [PMID: [29425931](#) DOI: [10.1053/j.gastro.2018.01.064](#)]
- 16 **Fukuda A,** Sakamoto S, Sasaki K, Narumoto S, Kitajima T, Hirata Y, Hishiki T, Kasahara M. Modified triangular hepatic vein reconstruction for preventing hepatic venous outflow obstruction in pediatric living donor liver transplantation using left lateral segment grafts. *Pediatr Transplant* 2018; **22**: e13167 [PMID: [29484815](#) DOI: [10.1111/ptr.13167](#)]
- 17 **Xu HW,** Liu F, Li HY, Wei YG, Li B. Outcomes following laparoscopic versus open major hepatectomy for hepatocellular carcinoma in patients with cirrhosis: a propensity score-matched analysis. *Surg Endosc* 2018; **32**: 712-719 [PMID: [28726140](#) DOI: [10.1007/s00464-017-5727-2](#)]
- 18 **Hallager S,** Ladelund S, Kjaer M, Madsen LG, Belard E, Laursen AL, Gerstoft J, Røge BT, Grønbaek KE, Krarup HB, Christensen PB, Weis N. Hepatocellular carcinoma in patients with chronic hepatitis C and cirrhosis in Denmark: A nationwide cohort study. *J Viral Hepat* 2018; **25**: 47-55 [PMID: [28750141](#) DOI: [10.1111/jvh.12764](#)]
- 19 **D'Ambrosio R,** Aghemo A, Rumi MG, Degasperis E, Sangiovanni A, Maggioni M, Fraquelli M, Perbellini R, Rosenberg W, Bedossa P, Colombo M, Lampertico P. Persistence of hepatocellular carcinoma risk in hepatitis C patients with a response to IFN and cirrhosis regression. *Liver Int* 2018; **38**: 1459-1467 [PMID: [29377616](#) DOI: [10.1111/liv.13707](#)]
- 20 **Hartke J,** Johnson M, Ghabril M. The diagnosis and treatment of hepatocellular carcinoma. *Semin Diagn Pathol* 2017; **34**: 153-159 [PMID: [28108047](#) DOI: [10.1053/j.semdp.2016.12.011](#)]



Published by **Baishideng Publishing Group Inc**
7041 Koll Center Parkway, Suite 160, Pleasanton, CA 94566, USA

Telephone: +1-925-3991568

E-mail: bpgoffice@wjgnet.com

Help Desk: <https://www.f6publishing.com/helpdesk>

<https://www.wjgnet.com>

