

World Journal of *Clinical Cases*

World J Clin Cases 2022 August 26; 10(24): 8432-8807



Contents

Thrice Monthly Volume 10 Number 24 August 26, 2022

EDITORIAL

- 8432** Evolution of *World Journal of Clinical Cases* over the past 5 years
Muthu S

OPINION REVIEW

- 8436** NF- κ B: A novel therapeutic pathway for gastroesophageal reflux disease?
Zhang ML, Ran LQ, Wu MJ, Jia QC, Qin ZM, Peng YG

MINIREVIEWS

- 8443** Obligate aerobic, gram-positive, weak acid-fast, nonmotile bacilli, *Tsukamurella tyrosinosolvens*: Minireview of a rare opportunistic pathogen
Usuda D, Tanaka R, Suzuki M, Shimozawa S, Takano H, Hotchi Y, Tokunaga S, Osugi I, Katou R, Ito S, Mishima K, Kondo A, Mizuno K, Takami H, Komatsu T, Oba J, Nomura T, Sugita M
- 8450** Diffusion tensor imaging pipeline measures of cerebral white matter integrity: An overview of recent advances and prospects
Safri AA, Nassir CMNCM, Iman IN, Mohd Taib NH, Achuthan A, Mustapha M
- 8463** Graft choices for anterolateral ligament knee reconstruction surgery: Current concepts
Chalidis B, Pitsilos C, Kitridis D, Givissis P
- 8474** Overview of the anterolateral complex of the knee
Garcia-Mansilla I, Zicaro JP, Martinez EF, Astoul J, Yacuzzi C, Costa-Paz M
- 8482** Complication of lengthening and the role of post-operative care, physical and psychological rehabilitation among fibula hemimelia
Salimi M, Sarallah R, Javanshir S, Mirghaderi SP, Salimi A, Khanzadeh S

ORIGINAL ARTICLE

Clinical and Translational Research

- 8490** Pyroptosis-related genes play a significant role in the prognosis of gastric cancer
Guan SH, Wang XY, Shang P, Du QC, Li MZ, Xing X, Yan B

Retrospective Study

- 8506** Effects of propofol combined with lidocaine on hemodynamics, serum adrenocorticotrophic hormone, interleukin-6, and cortisol in children
Shi S, Gan L, Jin CN, Liu RF
- 8514** Correlation analysis of national elite Chinese male table tennis players' shoulder proprioception and muscle strength
Shang XD, Zhang EM, Chen ZL, Zhang L, Qian JH

- 8525** Clinical value of contrast-enhanced ultrasound in early diagnosis of small hepatocellular carcinoma (≤ 2 cm)

Mei Q, Yu M, Chen Q

- 8535** Identification of predictive factors for post-transarterial chemoembolization liver failure in hepatocellular carcinoma patients: A retrospective study

Yuan M, Chen TY, Chen XR, Lu YF, Shi J, Zhang WS, Ye C, Tang BZ, Yang ZG

- 8547** Clinical significance of half-hepatic blood flow occlusion technology in patients with hepatocellular carcinoma with cirrhosis

Liu D, Fang JM, Chen XQ

- 8556** Which octogenarian patients are at higher risk after cholecystectomy for symptomatic gallstone disease? A single center cohort study

D'Acapito F, Solaini L, Di Pietrantonio D, Tauceri F, Mirarchi MT, Antelmi E, Flamini F, Amato A, Framarini M, Ercolani G

Clinical Trials Study

- 8568** Computed tomography combined with gastroscopy for assessment of pancreatic segmental portal hypertension

Wang YL, Zhang HW, Lin F

Observational Study

- 8578** Psychological needs of parents of children with complicated congenital heart disease after admitting to pediatric intensive care unit: A questionnaire study

Zhu JH, Jin CD, Tang XM

Prospective Study

- 8587** Quantitative differentiation of malignant and benign thyroid nodules with multi-parameter diffusion-weighted imaging

Zhu X, Wang J, Wang YC, Zhu ZF, Tang J, Wen XW, Fang Y, Han J

Randomized Controlled Trial

- 8599** Application of unified protocol as a transdiagnostic treatment for emotional disorders during COVID-19: An internet-delivered randomized controlled trial

Yan K, Yusufi MH, Nazari N

- 8615** High-flow nasal cannula oxygen therapy during anesthesia recovery for older orthopedic surgery patients: A prospective randomized controlled trial

Li XN, Zhou CC, Lin ZQ, Jia B, Li XY, Zhao GF, Ye F

SYSTEMATIC REVIEWS

- 8625** Assessment tools for differential diagnosis of neglect: Focusing on egocentric neglect and allocentric neglect

Lee SH, Lim BC, Jeong CY, Kim JH, Jang WH

CASE REPORT

- 8634** Exome analysis for Cronkhite-Canada syndrome: A case report
Li ZD, Rong L, He YJ, Ji YZ, Li X, Song FZ, Li XA
- 8641** Discrepancy between non-invasive prenatal testing result and fetal karyotype caused by rare confined placental mosaicism: A case report
Li Z, Lai GR
- 8648** Paroxysmal speech disorder as the initial symptom in a young adult with anti-N-methyl-D-aspartate receptor encephalitis: A case report
Hu CC, Pan XL, Zhang MX, Chen HF
- 8656** Anesthetics management of a renal angiomyolipoma using pulse pressure variation and non-invasive cardiac output monitoring: A case report
Jeon WJ, Shin WJ, Yoon YJ, Park CW, Shim JH, Cho SY
- 8662** Traumatic giant cell tumor of rib: A case report
Chen YS, Kao HW, Huang HY, Huang TW
- 8667** Analysis of two naval pilots' ejection injuries: Two case reports
Zeng J, Liu XP, Yi JC, Lu X, Liu DD, Jiang YQ, Liu YB, Tian JQ
- 8673** Beware of the DeBakey type I aortic dissection hidden by ischemic stroke: Two case reports
Chen SQ, Luo WL, Liu W, Wang LZ
- 8679** Unilateral lichen planus with Blaschko line distribution: A case report
Dong S, Zhu WJ, Xu M, Zhao XQ, Mou Y
- 8686** Clinical features and progress of ischemic gastritis with high fatalities: Seven case reports
Shionoya K, Sasaki A, Moriya H, Kimura K, Nishino T, Kubota J, Sumida C, Tasaki J, Ichita C, Makazu M, Masuda S, Koizumi K, Kawachi J, Tsukiyama T, Kako M
- 8695** Retinoblastoma in an older child with secondary glaucoma as the first clinical presenting symptom: A case report
Zhang Y, Tang L
- 8703** Recurrent herpes zoster in a rheumatoid arthritis patient treated with tofacitinib: A case report and review of the literature
Lin QX, Meng HJ, Pang YY, Qu Y
- 8709** Intra-abdominal ectopic bronchogenic cyst with a mucinous neoplasm harboring a *GNAS* mutation: A case report
Murakami T, Shimizu H, Yamazaki K, Nojima H, Usui A, Kosugi C, Shuto K, Obi S, Sato T, Yamazaki M, Koda K
- 8718** Effects of intravascular photobiomodulation on motor deficits and brain perfusion images in intractable myasthenia gravis: A case report
Lan CH, Wu YC, Chiang CC, Chang ST

- 8728** Spontaneous acute epidural hematoma secondary to skull and dural metastasis of hepatocellular carcinoma: A case report
Lv GZ, Li GC, Tang WT, Zhou D, Yang Y
- 8735** Malignant melanotic nerve sheath tumors in the spinal canal of psammomatous and non-psammomatous type: Two case reports
Yeom JA, Song YS, Lee IS, Han IH, Choi KU
- 8742** When should endovascular gastrointestinal anastomosis transection Glissonean pedicle not be used in hepatectomy? A case report
Zhao J, Dang YL
- 8749** VARS2 gene mutation leading to overall developmental delay in a child with epilepsy: A case report
Wu XH, Lin SZ, Zhou YQ, Wang WQ, Li JY, Chen QD
- 8755** Junctional bradycardia in a patient with COVID-19: A case report
Aedh AI
- 8761** Application of 3 dimension-printed injection-molded polyether ether ketone lunate prosthesis in the treatment of stage III Kienböck's disease: A case report
Yuan CS, Tang Y, Xie HQ, Liang TT, Li HT, Tang KL
- 8768** High scored thyroid storm after stomach cancer perforation: A case report
Baik SM, Pae Y, Lee JM
- 8775** Cholecystitis-an uncommon complication following thoracic duct embolization for chylothorax: A case report
Dung LV, Hien MM, Tra My TT, Luu DT, Linh LT, Duc NM
- 8782** Endometrial squamous cell carcinoma originating from the cervix: A case report
Shu XY, Dai Z, Zhang S, Yang HX, Bi H
- 8788** Type 2 autoimmune pancreatitis associated with severe ulcerative colitis: Three case reports
Ghali M, Bensted K, Williams DB, Ghaly S
- 8797** Diffuse uterine leiomyomatosis: A case report and review of literature
Ren HM, Wang QZ, Wang JN, Hong GJ, Zhou S, Zhu JY, Li SJ

LETTER TO THE EDITOR

- 8805** Comment on "Posterior reversible encephalopathy syndrome in a patient with metastatic breast cancer: A case report"
Kunić S, Ibrahimagić OČ, Kojić B, Džananović D

ABOUT COVER

Editorial Board Member of *World Journal of Clinical Cases*, Ahmed Mohamed Ahmed Al-Emam, PhD, Associate Professor, Department of Pathology, King Khalid University, Abha 62521, Saudi Arabia. amalemam@kku.edu.sa

AIMS AND SCOPE

The primary aim of *World Journal of Clinical Cases* (WJCC, *World J Clin Cases*) is to provide scholars and readers from various fields of clinical medicine with a platform to publish high-quality clinical research articles and communicate their research findings online.

WJCC mainly publishes articles reporting research results and findings obtained in the field of clinical medicine and covering a wide range of topics, including case control studies, retrospective cohort studies, retrospective studies, clinical trials studies, observational studies, prospective studies, randomized controlled trials, randomized clinical trials, systematic reviews, meta-analysis, and case reports.

INDEXING/ABSTRACTING

The WJCC is now abstracted and indexed in Science Citation Index Expanded (SCIE, also known as SciSearch®), Journal Citation Reports/Science Edition, Current Contents®/Clinical Medicine, PubMed, PubMed Central, Scopus, Reference Citation Analysis, China National Knowledge Infrastructure, China Science and Technology Journal Database, and Superstar Journals Database. The 2022 Edition of Journal Citation Reports® cites the 2021 impact factor (IF) for WJCC as 1.534; IF without journal self cites: 1.491; 5-year IF: 1.599; Journal Citation Indicator: 0.28; Ranking: 135 among 172 journals in medicine, general and internal; and Quartile category: Q4. The WJCC's CiteScore for 2021 is 1.2 and Scopus CiteScore rank 2021: General Medicine is 443/826.

RESPONSIBLE EDITORS FOR THIS ISSUE

Production Editor: *Ying-Yi Yuan*; Production Department Director: *Xu Guo*; Editorial Office Director: *Jin-Lei Wang*.

NAME OF JOURNAL

World Journal of Clinical Cases

ISSN

ISSN 2307-8960 (online)

LAUNCH DATE

April 16, 2013

FREQUENCY

Thrice Monthly

EDITORS-IN-CHIEF

Bao-Gan Peng, Jerzy Tadeusz Chudek, George Kontogeorgos, Maurizio Serati, Ja Hyeon Ku

EDITORIAL BOARD MEMBERS

<https://www.wjgnet.com/2307-8960/editorialboard.htm>

PUBLICATION DATE

August 26, 2022

COPYRIGHT

© 2022 Baishideng Publishing Group Inc

INSTRUCTIONS TO AUTHORS

<https://www.wjgnet.com/bpg/gerinfo/204>

GUIDELINES FOR ETHICS DOCUMENTS

<https://www.wjgnet.com/bpg/GerInfo/287>

GUIDELINES FOR NON-NATIVE SPEAKERS OF ENGLISH

<https://www.wjgnet.com/bpg/gerinfo/240>

PUBLICATION ETHICS

<https://www.wjgnet.com/bpg/GerInfo/288>

PUBLICATION MISCONDUCT

<https://www.wjgnet.com/bpg/gerinfo/208>

ARTICLE PROCESSING CHARGE

<https://www.wjgnet.com/bpg/gerinfo/242>

STEPS FOR SUBMITTING MANUSCRIPTS

<https://www.wjgnet.com/bpg/GerInfo/239>

ONLINE SUBMISSION

<https://www.f6publishing.com>



Unilateral lichen planus with Blaschko line distribution: A case report

Shuai Dong, Wen-Jing Zhu, Meng Xu, Xue-Qi Zhao, Yan Mou

Specialty type: Dermatology

Provenance and peer review:

Unsolicited article; Externally peer reviewed.

Peer-review model: Single blind

Peer-review report's scientific quality classification

Grade A (Excellent): 0

Grade B (Very good): B

Grade C (Good): C

Grade D (Fair): D

Grade E (Poor): 0

P-Reviewer: Park HK, South Korea; Vyshka G, Albania; Zhang Y, China

Received: February 14, 2022

Peer-review started: February 14, 2022

First decision: March 24, 2022

Revised: April 3, 2022

Accepted: July 25, 2022

Article in press: July 25, 2022

Published online: August 26, 2022



Shuai Dong, Wen-Jing Zhu, Meng Xu, Xue-Qi Zhao, Yan Mou, Department of Dermatology, The Second Hospital of Jilin University, Changchun 130041, Jilin Province, China

Corresponding author: Yan Mou, MD, PhD, Associate Professor, Senior Consultant Dermatologist, Department of Dermatology, The Second Hospital of Jilin University, No. 218 Ziqiang Street, Changchun 130041, Jilin Province, China. muyan_20031017@jlu.edu.cn

Abstract

BACKGROUND

Lichen planus (LP) with distribution of lesions along Blaschko's lines is a rare entity, accounting for 0.24%-0.62% of all patients. Unilateral distribution of lesions in arm, leg, trunk, and waist is even less common. Approximately 10% of patients with LP manifest nail lesions.

CASE SUMMARY

A 20-year-old woman presented to our department with polygonal, purpuric, flat-topped papules over the right arm, right leg, and right side of trunk and waist for the last 5 mo. The patient initially developed nail deformation in the left middle finger with no obvious cause, followed by development of blue-purple and red maculopapular rash with pruritus. During the disease course, the skin lesions aggravated and spread to several segments due to scratching. The lesions showed unilateral distribution along the Blaschko's lines. The diagnosis of LP along Blaschko's lines was established based on dermoscopy and skin biopsy. Her cutaneous lesions considerably improved after 4-wk treatment with intramuscular glucocorticoid, oral acitretin, topical glucocorticoid, and retinoids.

CONCLUSION

Cases of LP involving multiple segments of the body along the Blaschko's lines with nail damage are rare.

Key Words: Lichen planus; Blaschko's lines; Lichen planus involving nails; Case report

©The Author(s) 2022. Published by Baishideng Publishing Group Inc. All rights reserved.

Core Tip: Lichen planus (LP) with lesion distribution along the Blaschko's lines can be differentiated from other skin lesions with linear distribution by dermoscopy and pathological biopsy. The isotopic response can occur in patients with LP, which may be an important cause for rapid spread of lesions and involvement of multiple segments. Therefore, early diagnosis and treatment are of great significance. Treatment strategy should be individualized based on the lesion characteristics and patient acceptance. Our patient showed considerable improvement of cutaneous lesions after 4-wk treatment with intramuscular glucocorticoid, oral acitretin, topical glucocorticoid and retinoids.

Citation: Dong S, Zhu WJ, Xu M, Zhao XQ, Mou Y. Unilateral lichen planus with Blaschko line distribution: A case report. *World J Clin Cases* 2022; 10(24): 8679-8685

URL: <https://www.wjgnet.com/2307-8960/full/v10/i24/8679.htm>

DOI: <https://dx.doi.org/10.12998/wjcc.v10.i24.8679>

INTRODUCTION

Although cases of lichen planus (LP) are not uncommon, LP with lesion distribution along the Blaschko's lines is a rare entity, accounting for only 0.24%-0.62% of all patients with LP[1]. Cases with unilateral involvement of upper and lower limbs, chest, back, and waist are even rarer. Approximately 10% of patients with LP have nail lesions[2]. We report a rare case of LP with unilateral distribution of cutaneous lesions along the Blaschko's lines along with nail lesions. Our experience with this case may provide insights into this rare disease and facilitate timely diagnosis and treatment of this disease.

CASE PRESENTATION

Chief complaints

On September 24, 2021, a 20-year-old woman presented to our department with polygonal, purpuric, flat-topped papules over her right arm, right leg, and right side of trunk and waist since the last 5 mo.

History of present illness

In January 2021, the patient noted asymptomatic deformation of her left middle finger nail with no obvious cause along with splitting of the distal nail plate. In April 2021, due to exposure to cherry blossom, she developed red miliary size papules on the inner aspect of right upper arm with severe itching, and was diagnosed with allergic dermatitis at a local hospital. Her symptoms improved after treatment with loratadine and topical compound dexamethasone acetate cream. In May 2021, she had symptoms of hyperhidrosis followed by development of a red polygonal flat papule (size: 5 mm) with pruritus in her right lower limb. Her symptoms were not relieved after topical application of desonide cream. One week later, a similar lesion appeared on the right side of waist. In June, her symptoms were alleviated, and she had black discoloration of some lesions. In July, the patient had recurrence of pruritus on the same site with no obvious triggering factor. After scratching, the eruption on the right upper extremity and right lower extremity spread to distal sites along the longitudinal axis, which brought the patient to our department.

History of past illness

Her past history was unremarkable.

Personal and family history

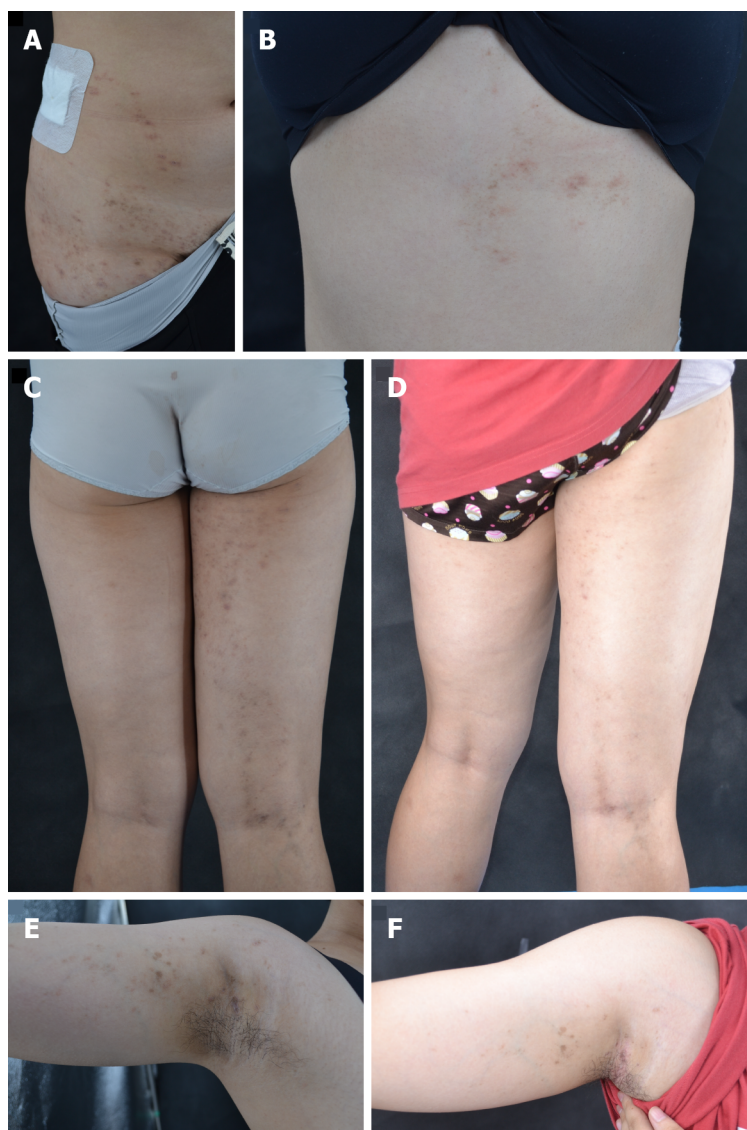There was no family history of similar disease.

Physical examination

Systemic examination revealed no obvious abnormalities. Cutaneous examination showed violaceous, erythematous macules and maculopapules sized 1-5 mm on the right upper and lower limbs and on the right side of chest, back and waist. Some of the lesions had coalesced into flaky plaques with no obvious scale formation. The lesions were distributed unilaterally without crossing the midline, along the Blaschko's lines (Figure 1A-C and E). There was no abnormality in oral mucosa. Splitting in the distal plate of the left middle finger was present and nail pit was also seen (Figure 2).

Laboratory examinations

Due to the financial constraints of the patient, relevant laboratory examinations were not conducted.



DOI: 10.12998/wjcc.v10.i24.8679 Copyright ©The Author(s) 2022.

Figure 1 Clinical photographs. A: Violaceous, brownish, polygonal papules on the right abdomen along the Blaschko's lines; B: Violaceous, brownish papules and plaques distributed along the Blaschko's lines on the right back and extended to the upper extremity. C: Before treatment, violaceous and red maculae with a size of 1-5 mm were seen on the right lower limb, and maculae papules were partially coalesced into patchy maculae linearly distributed; E: Before treatment, violaceous and red maculae were seen on the right upper limb; D and F: After treatment, the old lesions disappear or only pigmentation patches remain.

Imaging examinations

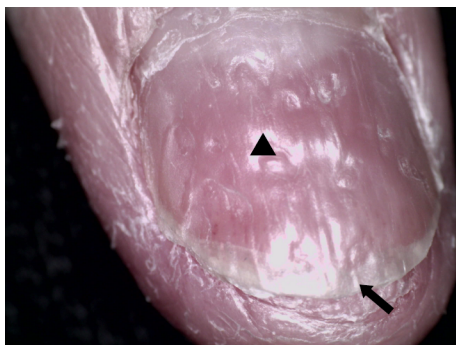
Dermoscopy examination showed linear and punctate blood vessels in the lesions. The vascular structure was radially arranged, and white reticular stripes were seen (Figure 3A). Histopathological examination showed reticular hyperkeratosis of the stratum corneum, wedge-shaped thickening of the granular layer, irregular thickening of spinous layer, basal cell vacuolization and liquefaction, compact bandlike lymphocytic infiltration in superficial dermis, and sporadic infiltration of chromatophilic cells. These were typical features of LP (Figure 4).

FINAL DIAGNOSIS

LP along the lines of Blaschko's.

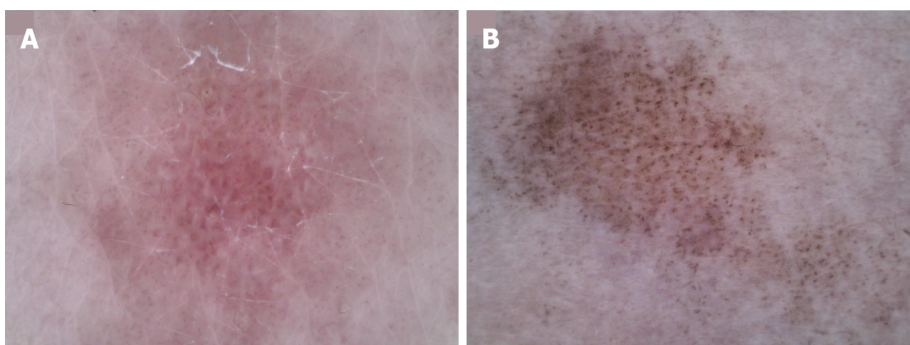
TREATMENT

The patient was prescribed compound betamethasone (glucocorticoid) 5 mg by intramuscular injection; capsule acitretin 10 mg (oral) once daily; topical fluticasone propionate (glucocorticoid) cream, twice



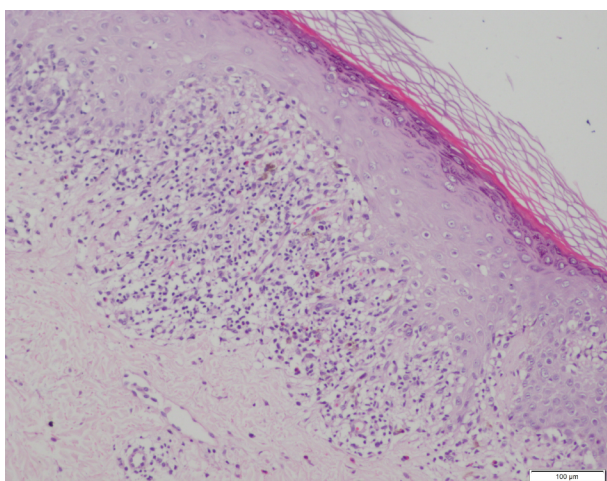
DOI: 10.12998/wjcc.v10.i24.8679 Copyright ©The Author(s) 2022.

Figure 2 Nail damage. Arrow: Distal deck splitting; Triangle: nail pits.



DOI: 10.12998/wjcc.v10.i24.8679 Copyright ©The Author(s) 2022.

Figure 3 Dermoscopic photographs (50×). A: Before treatment, linear and punctured vessels were seen under dermoscopy. The vascular structure was arranged radially with obvious white stripes; B: After treatment, the vascular structure disappeared, leaving blue-gray spots and faint white reticular stripes.



DOI: 10.12998/wjcc.v10.i24.8679 Copyright ©The Author(s) 2022.

Figure 4 Skin histopathology (hematoxylin-eosin staining, 100×). Histopathological examination showed reticular hyperkeratosis of the stratum corneum, wedge-shaped thickening of granular layer, irregular thickening of spinous layer, basal cell vacuolization and liquefaction, compact bandlike lymphocytic infiltration in superficial dermis, sporadic infiltration of chromatophilic cells, which shows typical features of lichen planus.

daily; and topical adapalene gel, once daily. The patient's symptoms showed considerable improvement after 4-wk treatment with the above regime.

OUTCOME AND FOLLOW-UP

Follow-up examination after 4 wk revealed no new cutaneous lesion, while the old cutaneous lesions were resolved or had become pigmented patches with no pruritus (Figure 1D and F). Dermoscopy revealed disappearance of the vascular structure with residual blue-gray spots and faint white reticular stripes (Figure 3B). There was no significant improvement in nail deformation. At 16 wk, the cutaneous lesions had disappeared, but there was still no significant improvement in nail damage.

DISCUSSION

The concept of Blaschko's lines was first proposed by Alfred Blaschko in 1901. It does not follow the distribution of blood vessels, lymph nodes, or nerves, but rather reflects the direction of spread of cell cloning and differentiation during embryonic development[3]. It is believed that LP along the Blaschko's lines is found in 0.24%-0.62% of all LP patients[1], and nail LP affects approximately 10% of all patients with cutaneous LP[2]. In the published literature, cases of LP with unilateral distribution of lesions along the Blaschko's lines mostly showed involvement of the trunk and limbs[1,4-6]. Our patient had extensive lesions involving the right upper and lower limb and right side of chest, back and waist.

The development of Koebner phenomenon in LP is well documented. It refers to the appearance of new skin lesions on areas of cutaneous injury or trauma in otherwise healthy skin[7,8]. In the present case, the cutaneous lesions may have resulted from allergic dermatitis or due to the spread of lesion caused by scratching. Patients with LP should be advised to avoid trauma and seek medical treatment as early as possible to avert further aggravation of symptoms.

The diagnosis of LP relies on the typical morphology of lesions at the affected site with histopathological correlation[9,10]. The histological features of LP with lesion distribution along Blaschko's lines is identical to those of generalized LP[11]. Laboratory investigations can help rule out other systemic diseases or infectious diseases. Unfortunately, our patient did not undergo laboratory investigations due to financial constraints. The differential diagnoses in the present case included inflammatory linear verrucous epidermal nevus (ILVEN), lichen striatus, and linear porokeratosis[3]. ILVEN typically occurs in children aged < 5 years and generally involves the legs with intense pruritus. Lichen striatus predominantly occurs in children below the age of 15 years. It typically manifests as asymptomatic linear papules arranged in the form of band with slight scaling and hypopigmentation over proximal parts of limbs with spontaneous resolution in 3-6 mo[12]. Linear porokeratosis typically occurs in infants[13], and it can be type I lichen striatus or an isotopic response triggered by trauma. Differential diagnosis can be done based on the history, characteristics of cutaneous lesions, and findings of dermoscopy and histopathological examination. In addition, our case was consistent with type I nail LP, *i.e.*, typical cutaneous lesion with nail damage[14]. After the diagnosis of LP, the diagnosis of nail LP is straightforward.

The majority of cases of cutaneous LP show spontaneous resolution within 1 or 2 years[15]. However, in a study, LP patients rated their disease on the Dermatology Life Quality Index as equivalent to that of psoriasis. The resulting decrease in the quality of life places increased emphasis on the need for effective, lasting treatments for LP[16]. The first-line treatment for cutaneous LP includes topical steroids, intralesional injection of triamcinolone acetonide, systemic corticosteroid therapy (oral or intramuscular injection), oral acitretin or isotretinoin[10,17]. Intramuscular corticosteroids show similar efficacy and improved safety in comparison to oral steroids, since the former allows for stable release of corticosteroids over a relatively long time. Intramuscular corticosteroids are considered the most reliable treatment for refractory LP with an overall success rate of 79%. Besides, topical retinoids also have a good therapeutic effect[18]. Similar cases reported previously were predominantly treated with topical steroids or oral prednisone[1,4-6]. Considering the advantages of intramuscular injection and the patient's condition (extensive cutaneous lesions and failure of topical injection), we opted for the following treatment regime and achieved good outcome: compound betamethasone (glucocorticoid) 5 mg (intramuscular injection); oral acitretin 10 mg once daily; topical fluticasone propionate cream, twice daily; and topical adapalene gel, once daily.

Compared with the treatment of cutaneous LP, treatment of nail LP is challenging due to limited treatment options and the tendency for frequent relapse[19]. Systemic application of glucocorticoids is more effective than topical agents alone, thus systemic administration should be used as early as possible for the treatment of nail LP[2,20]. The nail condition of our patient showed no significant improvement after treatment. A previous case report described considerable improvement in nail lesions after treatment with topical methoxypsoralen and UV A for 4 mo[21]. We could not implement this treatment because of the study schedule of the patient. The patient is currently being followed up.

In summary, there is a paucity of reports on LP with lesion distribution along the Blaschko's lines. The condition is liable to be misdiagnosed as other skin lesions with linear distribution. Few previous reports have described pre- and post-treatment clinical images and dermoscopic photographs. In this report, we present the detailed pre- and post-treatment images, which may facilitate the recognition of this condition.

CONCLUSION

LP with unilateral distribution of lesions along the Blaschko's lines is a rare entity that needs to be differentiated from other cutaneous lesions with linear distribution. Isomorphism can occur in patients with LP, which may be an important cause for rapid spread of lesions and involvement of multiple segments. Therefore, early diagnosis and treatment are important. Our patient showed considerable improvement in skin lesions with intramuscular glucocorticoid, oral acitretin, topical glucocorticoid, and tretinoin for 4 wk, with no significant side effects. However, no improvement was observed in nail lesion. Long-term follow up is required to assess the treatment efficacy.

ACKNOWLEDGEMENTS

We thank the patient and their family members for their support.

FOOTNOTES

Author contributions: Dong S collected the data, performed the literature search and contributed to the manuscript drafting; Zhu WJ, Xu M, Zhao XQ did the follow up and contributed to the manuscript drafting; Mou Y was involved in treatment of the patient, and revised and reviewed the manuscript; all authors issued final approval for the version to be submitted.

Supported by National Natural Science Foundation of China, No. 81803160.

Informed consent statement: Informed consent was obtained from the patient for publication of this report and any accompanying images.

Conflict-of-interest statement: The authors declare that they have no conflict of interest.

CARE Checklist (2016) statement: The authors have read the CARE Checklist (2016), and the manuscript was prepared and revised according to the CARE Checklist (2016).

Open-Access: This article is an open-access article that was selected by an in-house editor and fully peer-reviewed by external reviewers. It is distributed in accordance with the Creative Commons Attribution NonCommercial (CC BY-NC 4.0) license, which permits others to distribute, remix, adapt, build upon this work non-commercially, and license their derivative works on different terms, provided the original work is properly cited and the use is non-commercial. See: <https://creativecommons.org/licenses/by-nc/4.0/>

Country/Territory of origin: China

ORCID number: Shuai Dong 0000-0002-7728-4537; Wen-Jing Zhu 0000-0003-1253-0503; Meng Xu 0000-0001-7131-4320; Xue-Qi Zhao 0000-0003-2174-5936; Yan Mou 0000-0002-9152-6301.

S-Editor: Chang KL

L-Editor: Kerr C

P-Editor: Chang KL

REFERENCES

- 1 Criscito MC, Brinster NK, Skopicki DL, Seidenberg R, Cohen JM. Blaschkoid lichen planus: Throwing a "curve" in the nomenclature of linear lichen planus. *JAAD Case Rep* 2020; **6**: 237-239 [PMID: 32140526 DOI: 10.1016/j.jdc.2020.01.001]
- 2 Solimani F, Forchhammer S, Schloegl A, Ghoreschi K, Meier K. Lichen planus - a clinical guide. *J Dtsch Dermatol Ges* 2021; **19**: 864-882 [PMID: 34096678 DOI: 10.1111/ddg.14565]
- 3 Yayla D, Külcü Çakmak S, Oğuz ID, Gönül M, Ozhamam E, Colak A, Gül U. Two cases of unilateral lichen planus following the lines of blaschko. *Ann Dermatol* 2014; **26**: 636-638 [PMID: 25324660 DOI: 10.5021/ad.2014.26.5.636]
- 4 Kapoor P, Kumar S, Batrani M. Unilateral Linear Lichen Planus Hypertrophicus Along Blaschko's Lines. *Indian Dermatol Online J* 2021; **12**: 185-187 [PMID: 33768052 DOI: 10.4103/idoj.IDOJ_254_20]
- 5 Chuamanochan M, Onoufriadis A, Farnood S, Hsu CK, Simpson MA, Mahanupab P, Tovanabutra N, Chiewchanvit S, McGrath JA. Blaschko-linear lichen planus: Clinicopathological and genetic analysis. *J Dermatol* 2020; **47**: e384-e385 [PMID: 32789885 DOI: 10.1111/1346-8138.15546]
- 6 Dayal S, Sahu P, Verma P, Amrani A, Khare R. Unilateral Blaschkoian Lichen Planus: A Series of Cases with Review of literature. *J Clin Diagn Res* 2017; **11**: WR01-WR04 [PMID: 28658889 DOI: 10.7860/JCDR/2017/24692.9916]
- 7 Conforti C, Vezzoni R, Moret A, Retrosi C, Corneli P, Magaton-Rizzi G, Zalaudek I, di Meo N. Dermatoscopic features of

- Koebner phenomenon in lichen planus on light and dark skin. *Acta Dermatovenereol Alp Pannonica Adriat* 2019; **28**: 93-94 [PMID: [31233175](#) DOI: [10.15570/actaapa.2019.23](#)]
- 8 **Sagi L**, Trau H. The Koebner phenomenon. *Clin Dermatol* 2011; **29**: 231-236 [PMID: [21396563](#) DOI: [10.1016/j.clindermatol.2010.09.014](#)]
 - 9 **Tziotzios C**, Lee JYW, Brier T, Saito R, Hsu CK, Bhargava K, Stefanato CM, Fenton DA, McGrath JA. Lichen planus and lichenoid dermatoses: Clinical overview and molecular basis. *J Am Acad Dermatol* 2018; **79**: 789-804 [PMID: [30318136](#) DOI: [10.1016/j.jaad.2018.02.010](#)]
 - 10 **Ioannides D**, Vakirlis E, Kemeny L, Marinovic B, Massone C, Murphy R, Nast A, Ronnevig J, Ruzicka T, Cooper SM, Trüeb RM, Pujol Vallverdú RM, Wolf R, Neumann M. European S1 guidelines on the management of lichen planus: a cooperation of the European Dermatology Forum with the European Academy of Dermatology and Venereology. *J Eur Acad Dermatol Venereol* 2020; **34**: 1403-1414 [PMID: [32678513](#) DOI: [10.1111/jdv.16464](#)]
 - 11 **Kabbash C**, Laude TA, Weinberg JM, Silverberg NB. Lichen planus in the lines of Blaschko. *Pediatr Dermatol* 2002; **19**: 541-545 [PMID: [12437560](#) DOI: [10.1046/j.1525-1470.2002.00229.x](#)]
 - 12 **Kumavat S**. Unilateral Blaschkoid Lichen Planus. *Indian Dermatol Online J* 2019; **10**: 606-607 [PMID: [31544091](#) DOI: [10.4103/idoj.IDOJ_514_18](#)]
 - 13 **Blue E**, Abbott J, Bowen A, Cipriano SD. Linear porokeratosis with bone abnormalities treated with compounded topical 2% cholesterol/2% lovastatin ointment. *Pediatr Dermatol* 2021; **38**: 242-245 [PMID: [33170511](#) DOI: [10.1111/pde.14447](#)]
 - 14 **Yokozeki H**, Niiyama S, Nishioka K. Twenty-nail dystrophy (trachyonychia) caused by lichen planus in a patient with gold allergy. *Br J Dermatol* 2005; **152**: 1087-1089 [PMID: [15888190](#) DOI: [10.1111/j.1365-2133.2005.06581.x](#)]
 - 15 **Beck PB**, Goksel M, Kraleti S. Eruptive Lichen Planus Associated With Chronic Hepatitis C Infection Presenting as a Diffuse, Pruritic Rash. *Cureus* 2020; **12**: e9732 [PMID: [32944450](#) DOI: [10.7759/cureus.9732](#)]
 - 16 **Hunt KM**, Klager S, Kwak YJ, Sami N. Successful systemic treatment outcomes of lichen planus: A single-center retrospective review. *Dermatol Ther* 2021; **34**: e14903 [PMID: [33605044](#) DOI: [10.1111/dth.14903](#)]
 - 17 **Böer-Auer A**, Lütgerath C. [Lichen planus: fundamentals, clinical variants, histological features, and differential diagnosis]. *Hautarzt* 2020; **71**: 1007-1021 [PMID: [33201324](#) DOI: [10.1007/s00105-020-04717-w](#)]
 - 18 **Husein-ElAhmed H**, Gieler U, Steinhoff M. Lichen planus: a comprehensive evidence-based analysis of medical treatment. *J Eur Acad Dermatol Venereol* 2019; **33**: 1847-1862 [PMID: [31265737](#) DOI: [10.1111/jdv.15771](#)]
 - 19 **Gupta MK**, Lipner SR. Review of Nail Lichen Planus: Epidemiology, Pathogenesis, Diagnosis, and Treatment. *Dermatol Clin* 2021; **39**: 221-230 [PMID: [33745635](#) DOI: [10.1016/j.det.2020.12.002](#)]
 - 20 **Wechsurok P**, Bunyaratavej S, Kiratiwongwan R, Suphatsathienkul P, Wongdama S, Leeyaphan C. Clinical features and treatment outcomes of nail lichen planus: A retrospective study. *JAAD Case Rep* 2021; **17**: 43-48 [PMID: [34703863](#) DOI: [10.1016/j.jder.2021.09.015](#)]
 - 21 **Pita da Veiga G**, Pérez-Feal P, Moreiras-Arias N, Peteiro-García C, Suárez-Peñaranda JM, Vázquez-Veiga H, Rodríguez-Granados MT. Treatment of nail lichen planus with localized bath-PUVA. *Photodermatol Photoimmunol Photomed* 2020; **36**: 241-243 [PMID: [31769540](#) DOI: [10.1111/php.12528](#)]



Published by **Baishideng Publishing Group Inc**
7041 Koll Center Parkway, Suite 160, Pleasanton, CA 94566, USA

Telephone: +1-925-3991568

E-mail: bpgoffice@wjgnet.com

Help Desk: <https://www.f6publishing.com/helpdesk>

<https://www.wjgnet.com>

