

# World Journal of *Clinical Cases*

*World J Clin Cases* 2022 August 26; 10(24): 8432-8807



## Contents

Thrice Monthly Volume 10 Number 24 August 26, 2022

### EDITORIAL

- 8432** Evolution of *World Journal of Clinical Cases* over the past 5 years  
*Muthu S*

### OPINION REVIEW

- 8436** NF- $\kappa$ B: A novel therapeutic pathway for gastroesophageal reflux disease?  
*Zhang ML, Ran LQ, Wu MJ, Jia QC, Qin ZM, Peng YG*

### MINIREVIEWS

- 8443** Obligate aerobic, gram-positive, weak acid-fast, nonmotile bacilli, *Tsukamurella tyrosinosolvens*: Minireview of a rare opportunistic pathogen  
*Usuda D, Tanaka R, Suzuki M, Shimozawa S, Takano H, Hotchi Y, Tokunaga S, Osugi I, Katou R, Ito S, Mishima K, Kondo A, Mizuno K, Takami H, Komatsu T, Oba J, Nomura T, Sugita M*
- 8450** Diffusion tensor imaging pipeline measures of cerebral white matter integrity: An overview of recent advances and prospects  
*Safri AA, Nassir CMNCM, Iman IN, Mohd Taib NH, Achuthan A, Mustapha M*
- 8463** Graft choices for anterolateral ligament knee reconstruction surgery: Current concepts  
*Chalidis B, Pitsilos C, Kitridis D, Givissis P*
- 8474** Overview of the anterolateral complex of the knee  
*Garcia-Mansilla I, Zicaro JP, Martinez EF, Astoul J, Yacuzzi C, Costa-Paz M*
- 8482** Complication of lengthening and the role of post-operative care, physical and psychological rehabilitation among fibula hemimelia  
*Salimi M, Sarallah R, Javanshir S, Mirghaderi SP, Salimi A, Khanzadeh S*

### ORIGINAL ARTICLE

#### Clinical and Translational Research

- 8490** Pyroptosis-related genes play a significant role in the prognosis of gastric cancer  
*Guan SH, Wang XY, Shang P, Du QC, Li MZ, Xing X, Yan B*

#### Retrospective Study

- 8506** Effects of propofol combined with lidocaine on hemodynamics, serum adrenocorticotrophic hormone, interleukin-6, and cortisol in children  
*Shi S, Gan L, Jin CN, Liu RF*
- 8514** Correlation analysis of national elite Chinese male table tennis players' shoulder proprioception and muscle strength  
*Shang XD, Zhang EM, Chen ZL, Zhang L, Qian JH*

- 8525** Clinical value of contrast-enhanced ultrasound in early diagnosis of small hepatocellular carcinoma ( $\leq 2$  cm)

*Mei Q, Yu M, Chen Q*

- 8535** Identification of predictive factors for post-transarterial chemoembolization liver failure in hepatocellular carcinoma patients: A retrospective study

*Yuan M, Chen TY, Chen XR, Lu YF, Shi J, Zhang WS, Ye C, Tang BZ, Yang ZG*

- 8547** Clinical significance of half-hepatic blood flow occlusion technology in patients with hepatocellular carcinoma with cirrhosis

*Liu D, Fang JM, Chen XQ*

- 8556** Which octogenarian patients are at higher risk after cholecystectomy for symptomatic gallstone disease? A single center cohort study

*D'Acapito F, Solaini L, Di Pietrantonio D, Tauceri F, Mirarchi MT, Antelmi E, Flamini F, Amato A, Framarini M, Ercolani G*

### Clinical Trials Study

- 8568** Computed tomography combined with gastroscopy for assessment of pancreatic segmental portal hypertension

*Wang YL, Zhang HW, Lin F*

### Observational Study

- 8578** Psychological needs of parents of children with complicated congenital heart disease after admitting to pediatric intensive care unit: A questionnaire study

*Zhu JH, Jin CD, Tang XM*

### Prospective Study

- 8587** Quantitative differentiation of malignant and benign thyroid nodules with multi-parameter diffusion-weighted imaging

*Zhu X, Wang J, Wang YC, Zhu ZF, Tang J, Wen XW, Fang Y, Han J*

### Randomized Controlled Trial

- 8599** Application of unified protocol as a transdiagnostic treatment for emotional disorders during COVID-19: An internet-delivered randomized controlled trial

*Yan K, Yusufi MH, Nazari N*

- 8615** High-flow nasal cannula oxygen therapy during anesthesia recovery for older orthopedic surgery patients: A prospective randomized controlled trial

*Li XN, Zhou CC, Lin ZQ, Jia B, Li XY, Zhao GF, Ye F*

### SYSTEMATIC REVIEWS

- 8625** Assessment tools for differential diagnosis of neglect: Focusing on egocentric neglect and allocentric neglect

*Lee SH, Lim BC, Jeong CY, Kim JH, Jang WH*

## CASE REPORT

- 8634** Exome analysis for Cronkhite-Canada syndrome: A case report  
*Li ZD, Rong L, He YJ, Ji YZ, Li X, Song FZ, Li XA*
- 8641** Discrepancy between non-invasive prenatal testing result and fetal karyotype caused by rare confined placental mosaicism: A case report  
*Li Z, Lai GR*
- 8648** Paroxysmal speech disorder as the initial symptom in a young adult with anti-N-methyl-D-aspartate receptor encephalitis: A case report  
*Hu CC, Pan XL, Zhang MX, Chen HF*
- 8656** Anesthetics management of a renal angiomyolipoma using pulse pressure variation and non-invasive cardiac output monitoring: A case report  
*Jeon WJ, Shin WJ, Yoon YJ, Park CW, Shim JH, Cho SY*
- 8662** Traumatic giant cell tumor of rib: A case report  
*Chen YS, Kao HW, Huang HY, Huang TW*
- 8667** Analysis of two naval pilots' ejection injuries: Two case reports  
*Zeng J, Liu XP, Yi JC, Lu X, Liu DD, Jiang YQ, Liu YB, Tian JQ*
- 8673** Beware of the DeBakey type I aortic dissection hidden by ischemic stroke: Two case reports  
*Chen SQ, Luo WL, Liu W, Wang LZ*
- 8679** Unilateral lichen planus with Blaschko line distribution: A case report  
*Dong S, Zhu WJ, Xu M, Zhao XQ, Mou Y*
- 8686** Clinical features and progress of ischemic gastritis with high fatalities: Seven case reports  
*Shionoya K, Sasaki A, Moriya H, Kimura K, Nishino T, Kubota J, Sumida C, Tasaki J, Ichita C, Makazu M, Masuda S, Koizumi K, Kawachi J, Tsukiyama T, Kako M*
- 8695** Retinoblastoma in an older child with secondary glaucoma as the first clinical presenting symptom: A case report  
*Zhang Y, Tang L*
- 8703** Recurrent herpes zoster in a rheumatoid arthritis patient treated with tofacitinib: A case report and review of the literature  
*Lin QX, Meng HJ, Pang YY, Qu Y*
- 8709** Intra-abdominal ectopic bronchogenic cyst with a mucinous neoplasm harboring a *GNAS* mutation: A case report  
*Murakami T, Shimizu H, Yamazaki K, Nojima H, Usui A, Kosugi C, Shuto K, Obi S, Sato T, Yamazaki M, Koda K*
- 8718** Effects of intravascular photobiomodulation on motor deficits and brain perfusion images in intractable myasthenia gravis: A case report  
*Lan CH, Wu YC, Chiang CC, Chang ST*

- 8728** Spontaneous acute epidural hematoma secondary to skull and dural metastasis of hepatocellular carcinoma: A case report  
*Lv GZ, Li GC, Tang WT, Zhou D, Yang Y*
- 8735** Malignant melanotic nerve sheath tumors in the spinal canal of psammomatous and non-psammomatous type: Two case reports  
*Yeom JA, Song YS, Lee IS, Han IH, Choi KU*
- 8742** When should endovascular gastrointestinal anastomosis transection Glissonean pedicle not be used in hepatectomy? A case report  
*Zhao J, Dang YL*
- 8749** VARS2 gene mutation leading to overall developmental delay in a child with epilepsy: A case report  
*Wu XH, Lin SZ, Zhou YQ, Wang WQ, Li JY, Chen QD*
- 8755** Junctional bradycardia in a patient with COVID-19: A case report  
*Aedh AI*
- 8761** Application of 3 dimension-printed injection-molded polyether ether ketone lunate prosthesis in the treatment of stage III Kienböck's disease: A case report  
*Yuan CS, Tang Y, Xie HQ, Liang TT, Li HT, Tang KL*
- 8768** High scored thyroid storm after stomach cancer perforation: A case report  
*Baik SM, Pae Y, Lee JM*
- 8775** Cholecystitis-an uncommon complication following thoracic duct embolization for chylothorax: A case report  
*Dung LV, Hien MM, Tra My TT, Luu DT, Linh LT, Duc NM*
- 8782** Endometrial squamous cell carcinoma originating from the cervix: A case report  
*Shu XY, Dai Z, Zhang S, Yang HX, Bi H*
- 8788** Type 2 autoimmune pancreatitis associated with severe ulcerative colitis: Three case reports  
*Ghali M, Bensted K, Williams DB, Ghaly S*
- 8797** Diffuse uterine leiomyomatosis: A case report and review of literature  
*Ren HM, Wang QZ, Wang JN, Hong GJ, Zhou S, Zhu JY, Li SJ*

**LETTER TO THE EDITOR**

- 8805** Comment on "Posterior reversible encephalopathy syndrome in a patient with metastatic breast cancer: A case report"  
*Kunić S, Ibrahimagić OČ, Kojić B, Džananović D*

**ABOUT COVER**

Editorial Board Member of *World Journal of Clinical Cases*, Ahmed Mohamed Ahmed Al-Emam, PhD, Associate Professor, Department of Pathology, King Khalid University, Abha 62521, Saudi Arabia. amalemam@kku.edu.sa

**AIMS AND SCOPE**

The primary aim of *World Journal of Clinical Cases* (WJCC, *World J Clin Cases*) is to provide scholars and readers from various fields of clinical medicine with a platform to publish high-quality clinical research articles and communicate their research findings online.

WJCC mainly publishes articles reporting research results and findings obtained in the field of clinical medicine and covering a wide range of topics, including case control studies, retrospective cohort studies, retrospective studies, clinical trials studies, observational studies, prospective studies, randomized controlled trials, randomized clinical trials, systematic reviews, meta-analysis, and case reports.

**INDEXING/ABSTRACTING**

The WJCC is now abstracted and indexed in Science Citation Index Expanded (SCIE, also known as SciSearch®), Journal Citation Reports/Science Edition, Current Contents®/Clinical Medicine, PubMed, PubMed Central, Scopus, Reference Citation Analysis, China National Knowledge Infrastructure, China Science and Technology Journal Database, and Superstar Journals Database. The 2022 Edition of Journal Citation Reports® cites the 2021 impact factor (IF) for WJCC as 1.534; IF without journal self cites: 1.491; 5-year IF: 1.599; Journal Citation Indicator: 0.28; Ranking: 135 among 172 journals in medicine, general and internal; and Quartile category: Q4. The WJCC's CiteScore for 2021 is 1.2 and Scopus CiteScore rank 2021: General Medicine is 443/826.

**RESPONSIBLE EDITORS FOR THIS ISSUE**

Production Editor: *Ying-Yi Yuan*; Production Department Director: *Xu Guo*; Editorial Office Director: *Jin-Lei Wang*.

**NAME OF JOURNAL**

*World Journal of Clinical Cases*

**ISSN**

ISSN 2307-8960 (online)

**LAUNCH DATE**

April 16, 2013

**FREQUENCY**

Thrice Monthly

**EDITORS-IN-CHIEF**

Bao-Gan Peng, Jerzy Tadeusz Chudek, George Kontogeorgos, Maurizio Serati, Ja Hyeon Ku

**EDITORIAL BOARD MEMBERS**

<https://www.wjgnet.com/2307-8960/editorialboard.htm>

**PUBLICATION DATE**

August 26, 2022

**COPYRIGHT**

© 2022 Baishideng Publishing Group Inc

**INSTRUCTIONS TO AUTHORS**

<https://www.wjgnet.com/bpg/gerinfo/204>

**GUIDELINES FOR ETHICS DOCUMENTS**

<https://www.wjgnet.com/bpg/GerInfo/287>

**GUIDELINES FOR NON-NATIVE SPEAKERS OF ENGLISH**

<https://www.wjgnet.com/bpg/gerinfo/240>

**PUBLICATION ETHICS**

<https://www.wjgnet.com/bpg/GerInfo/288>

**PUBLICATION MISCONDUCT**

<https://www.wjgnet.com/bpg/gerinfo/208>

**ARTICLE PROCESSING CHARGE**

<https://www.wjgnet.com/bpg/gerinfo/242>

**STEPS FOR SUBMITTING MANUSCRIPTS**

<https://www.wjgnet.com/bpg/GerInfo/239>

**ONLINE SUBMISSION**

<https://www.f6publishing.com>



# Application of 3 dimension-printed injection-molded polyether ether ketone lunate prosthesis in the treatment of stage III Kienböck's disease: A case report

Cheng-Song Yuan, Yao Tang, Hai-Qiong Xie, Tao-Tao Liang, Hong-Tao Li, Kang-Lai Tang

**Specialty type:** Orthopedics

**Provenance and peer review:**

Unsolicited article; Externally peer reviewed.

**Peer-review model:** Single blind

**Peer-review report's scientific quality classification**

Grade A (Excellent): 0  
Grade B (Very good): B  
Grade C (Good): C  
Grade D (Fair): 0  
Grade E (Poor): 0

**P-Reviewer:** Eccher A, Italy; Wang Y, China

**Received:** April 5, 2022

**Peer-review started:** April 5, 2022

**First decision:** June 16, 2022

**Revised:** July 5, 2022

**Accepted:** July 18, 2022

**Article in press:** July 18, 2022

**Published online:** August 26, 2022



**Cheng-Song Yuan, Yao Tang, Hai-Qiong Xie, Tao-Tao Liang, Hong-Tao Li, Kang-Lai Tang**, Sports Medicine Center, The First Affiliated Hospital of Army Medical University, Chongqing 400038, China

**Corresponding author:** Kang-Lai Tang, MD, PhD, Doctor, Sports Medicine Center, The First Affiliated Hospital of Army Medical University, No. 30 Gaotanyan Street, Chongqing 400038, China. [tangkanlai@hotmail.com](mailto:tangkanglai@hotmail.com)

## Abstract

### BACKGROUND

Polyether ether ketone (PEEK) is a high-performance medical polymer, and there are some clinical cases of PEEK prosthesis implantation. However, application of 3D-printed injection-molded PEEK lunate prosthesis for treatment of stage III Kienböck's disease has not been reported. This study's purpose was to analyze the clinical efficacy of 3D-printed injection-molded PEEK lunate prosthesis in the treatment of stage III Kienböck's disease and thus provide a good therapeutic choice for Kienböck's disease.

### CASE SUMMARY

We report a patient with stage III Kienböck's disease. With the healthy lunate bone as reference, 3D lunate reconstruction was performed using a mirroring technique. A PEEK lunate prosthesis was prepared by 3D printing and injection molding, and then it was inserted into the original anatomical position after removing the necrotic lunate bone. Wrist pain and function, anatomical suitability of the lunate prosthesis, and complications were evaluated and analyzed postoperatively. At the last visit (one year after surgery), the range of motion, grasp force, visual analog scale score and Cooney score of the affected wrist were significantly improved, and postoperative X-ray examination indicated that the lunate prosthesis had good anatomical suitability for adjacent bony structures.

### CONCLUSION

The 3D-printed injection-molded PEEK lunate prosthesis demonstrated definite efficacy in treating stage III Kienböck's disease.

**Key Words:** 3D printing; Polyetheretherketone; Kienböck disease; Lunate fixation; Lunate collapse; Clinical outcomes; Case report

**Core Tip:** Polyether ether ketone (PEEK) has been widely used in the preparation of human bone tissue scaffolds and joint prostheses. This study evaluates the clinical efficacy of 3D-printed injection-molded PEEK lunate prosthesis designed by our team in the treatment of stage III Kienböck's disease. Compared with other replacement methods, this technique can better reconstruct the anatomical structure of the wrist, alleviate pain, and restore the activity function and grip strength of the patient. Imaging examination confirmed that the lunar bone cement prosthesis has good anatomical adaptability. 3D-printed injection-molded PEEK lunate prosthesis is a safe and effective artificial replacement technique.

**Citation:** Yuan CS, Tang Y, Xie HQ, Liang TT, Li HT, Tang KL. Application of 3 dimension-printed injection-molded polyether ether ketone lunate prosthesis in the treatment of stage III Kienböck's disease: A case report. *World J Clin Cases* 2022; 10(24): 8761-8767

**URL:** <https://www.wjgnet.com/2307-8960/full/v10/i24/8761.htm>

**DOI:** <https://dx.doi.org/10.12998/wjcc.v10.i24.8761>

## INTRODUCTION

Kienböck's disease is one of the main causes for wrist pain and movement limitation[1]. Stage III Kienböck's disease is clinically characterized by lunate rupture, necrosis, atrophy and flattening[2], and its treatment aims to conserve normal structure, restore movement function, and relieve wrist symptoms. There are no uniform surgical procedures for Kienböck's disease, and revascularization, biomechanical therapy, lunate resection and substitute implantation are all commonly used in clinical practice, but they have varying efficacy[3].

Polyether ether ketone (PEEK) is a special thermoplastic polymer, which has the advantages of high strength, high stiffness, corrosion resistance, and hydrolysis resistance. Compared with traditional metal materials, the elastic modulus of PEEK is closer to that of human cortical bone, and it has good plasticity. In the 1990s, as a substitute for metal implants, PEEK was increasingly used in the field of orthopedics. PEEK has good biocompatibility and biological inertia. It has no sensitization. Genotoxicity test results show that PEEK does not cause any chromosome aberration. It can maintain stable physical and chemical properties under the stimulation of various chemical and physical conditions. It is an ideal material for prosthesis fabrication[4-6], thus, it is more suitable for preparing human bone tissue scaffolds and joint prostheses. A hotspot issue in the recent years has been how to fabricate the implants with a precise anatomical structure by combining 3D printing technology, and some clinical cases of PEEK prosthesis implantation have been reported[7]. However, none of these has involved the application of 3D-printed injection-molded PEEK lunate prosthesis in the treatment of stage III Kienböck's disease.

Based on the anatomical and biomechanical characteristics of the wrist and combining the physical and chemical properties of PEEK materials, we prepared a PEEK lunate prosthesis by 3D printing and injection molding to substitute the necrotic lunate bone. This is the first case report of a 3D-printed injection-molded PEEK lunate prosthesis in the treatment of stage III Kienböck's disease, and aimed to present a new therapy and the clinical outcome of the disease.

## CASE PRESENTATION

### Chief complaints

A 42-yr-old female patient was admitted to hospital for left wrist pain with movement limitation for 5 mo.

### History of present illness

Before surgery, her symptoms lasted 5 mo. The pain was persistent, became aggravated during loading, and was relieved after rest. The pain was associated with limited mobility of the wrist joint.

### History of past illness

The patient had no previous medical history.



**Personal and family history**

There is no history of genetic diseases and infectious diseases in the family.

**Physical examination**

The left wrist was slightly swollen, with obvious tenderness at the palmarar lunate, limited range of motion of wrist joint, decreased grip strength (Table 1), and normal peripheral blood flow and skin sensation.

**Laboratory examinations**

The patient's preoperative laboratory examination was unremarkable.

**Imaging examinations**

X-ray, computed tomography (CT), and magnetic resonance imaging were performed, and the imaging findings suggested lunate necrosis of the left wrist joint (Figure 1).

---

**FINAL DIAGNOSIS**

---

The patient was diagnosed with stage III Kienböck's disease according to the Lichtman staging.

---

**TREATMENT**

---

**Preparation of lunate prosthesis**

The precise 3D raw data of healthy lunate bone were acquired from the patient by CT examination, and then a 3D lunate model was constructed with reverse engineering methodology. Thereafter, a cutting plane of a 3D lunate model was created according to the individualized anatomical characteristics of lunate bone, and used to cut the 3D lunate model and obtain a 3D model of lunate prosthesis using a mirroring technique. Based on the 3D model of lunate prosthesis, a PEEK lunate prosthesis mold was prepared for injection molding by 3D printing. The mold, a high-strength prosthetic structure and a PEEK lunate prosthesis with a high surface smoothness (after good finishing with specific technology), a complete overall shape and dense material texture were fabricated by injection molding (Figure 2).

**Surgical procedures**

A longitudinal incision was made on the dorsal wrist, and the skin, subcutaneous tissue and dorsal extensor retinaculum were dissected layer by layer to expose the articular capsule of the lunate bone, and the perilunate ligaments were cut off to expose and completely remove the necrotic lunate bone (Figure 3A). Subsequently, the 3D-printed PEEK lunate prosthesis was inserted into the original anatomical position of the lunate bone (Figure 3B and C). After dorsal extension and palmar flexion reached a normal level through the repeated radioulnar deviation of the wrist and no prosthesis extrusion was observed, the lunate prosthesis was found with good matching by C-arm X-ray examination. The dorsal articular capsule and dorsal extensor retinaculum of the wrist were sutured layer by layer. After surgery, the wrist was fixed in the functional position using plaster slab for 4 wk.

---

**OUTCOME AND FOLLOW-UP**

---

One year after surgery at the last visit, the range of motion and grasp force of the affected wrist were nearly normal, but VAS score and Cooney score were both improved in both resting and loading states (Tables 1 and 2). The carpal height ratio and radial scaphoid angle were nearly normal, the imaging examination confirmed that the PEEK lunate prosthesis had good anatomical suitability and no rupture, extrusion and detachment to other carpal bones (Figure 4).

---

**DISCUSSION**

---

There are many therapies for Kienböck's disease that have an uniform goal of conserving normal structure, restoring movement function, and relieving the clinical wrist symptoms[8]. Four surgical procedures are usually applied: Revascularization, biomechanical therapy, lunate resection, and substitute implantation[3]. Lunate resection often induces downward shift and disordered arrangement of the carpal bone, as well as causing wrist pain and dysfunction. Therefore, choosing a suitable substitute is important for reconstructing radiocarpal joint and restoring wrist function[9], thus lunate

**Table 1 Comparison of wrist range of motion and grasp force**

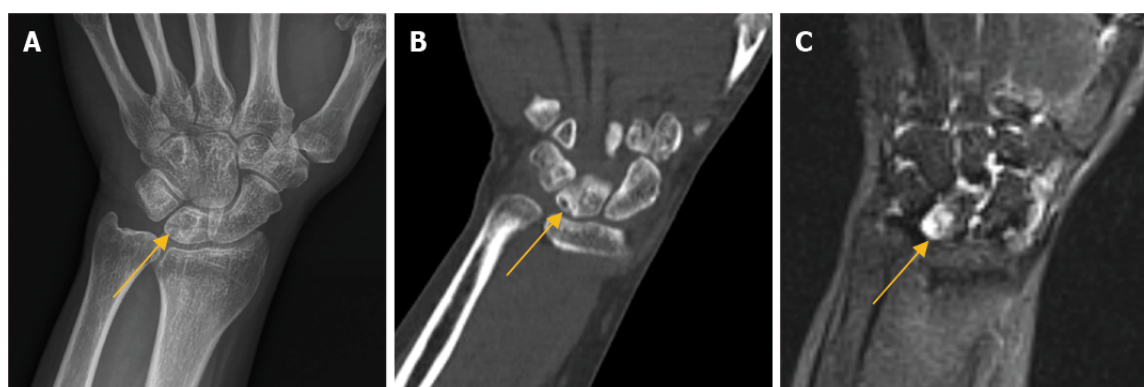
	Affected wrist		Healthy wrist
	Before operation	At last visit	
Dorsal extension (°)	0-25/32	0-50/55	0-50/59
Palmar flexion (°)	0-20/28	0-45/52	0-45/53
Ulnar deviation (°)	0-10/15	0-25/33	0-25/34
Radical deviation (°)	0-5/9	0-15/17	0-10/18
GF (kg)	15-20	30/38	35/40

Comparison between before operation and at the last visit or between the affected wrist and the healthy wrist.

**Table 2 Comparison of wrist VAS score and Cooney score**

	VAS score		Cooney score
	Resting state	Loading state	
Before operation	6	7	50
At last visit	0	1	85

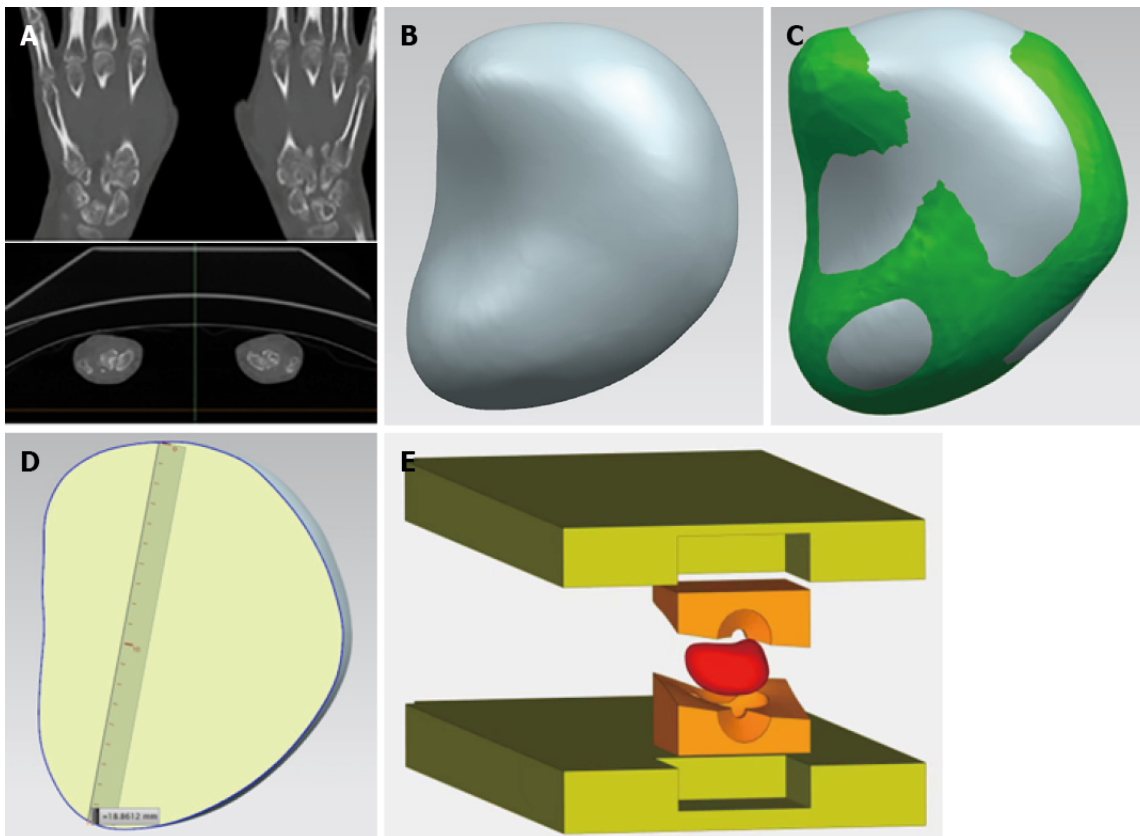
Comparison between before operation and at the last visit. VAS: Visual analog scale.



DOI: 10.12998/wjcc.v10.i24.8761 Copyright ©The Author(s) 2022.

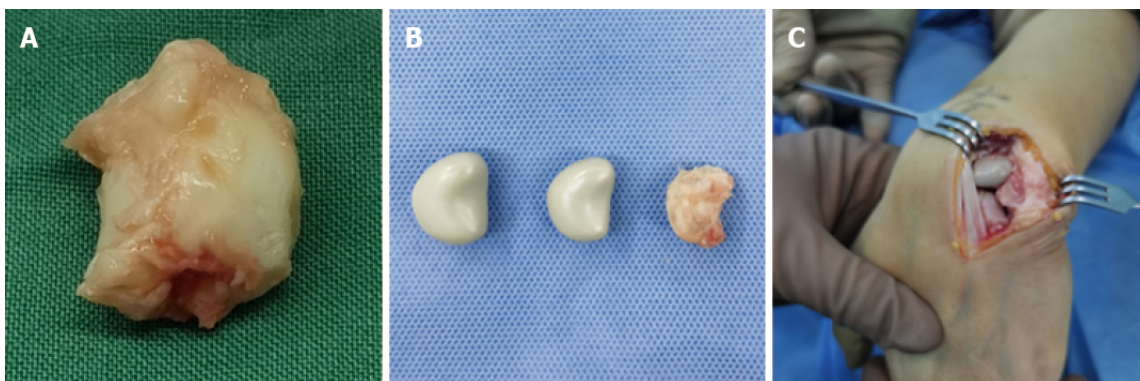
**Figure 1 Preoperative imaging findings.** A-C: Preoperative radiographs (A), computed tomography (B) and magnetic resonance imaging (C), the arrow shows the necrotic lunate bone.

resection + substitute implantation is a good therapy for Kienböck's disease. Many substitutes are available to be implanted after lunate resection, for example, tendon mass, capital bone shift, metal ball, pisiform bone shift, titanium alloy prosthesis, silicone prosthesis, and bone cement implant[10]. Tendon mass and arcuated transparent cartilage are soft in the texture, and have poor long-term efficacy as wrist instability will easily happen after their implantation[11]. Mariconda *et al*[12] reported that tendon flap could be used for sufficient interposition in the cavity. After surgery, however, the low-strength tendon is incapable to transmit the stress, and wrist synovitis and radial-scaphoid joint changes easily occur. The substitute implantation of capital and pisiform bone shift has complicated surgery and can damage the structure and partial function of the wrist. The hard metal ball causes abrasion against the adjacent carpal bones; the titanium alloy prosthesis is expensive and requires premature customization, and it is difficult to adjust the size of such prosthesis and achieve the simulation[13]; and the bone cement prosthesis presents an unavoidable friction against the adjacent bones, which may lead to the abrasion and injury of the articular facet. Viljakka *et al*[14] reported that the silicone prosthesis had high hardness but poor tissue compatibility; thus, prosthesis extrusion and silicone synovitis can happen after implantation, followed by prosthesis damage and abrasion, further aggravating injury of adjacent joints. Therefore, the silicone prosthesis cannot meet the long-term functional demand of patients. The above-mentioned surgical procedures all have some limitations and vary in their clinical efficacy.



DOI: 10.12998/wjcc.v10.i24.8761 Copyright ©The Author(s) 2022.

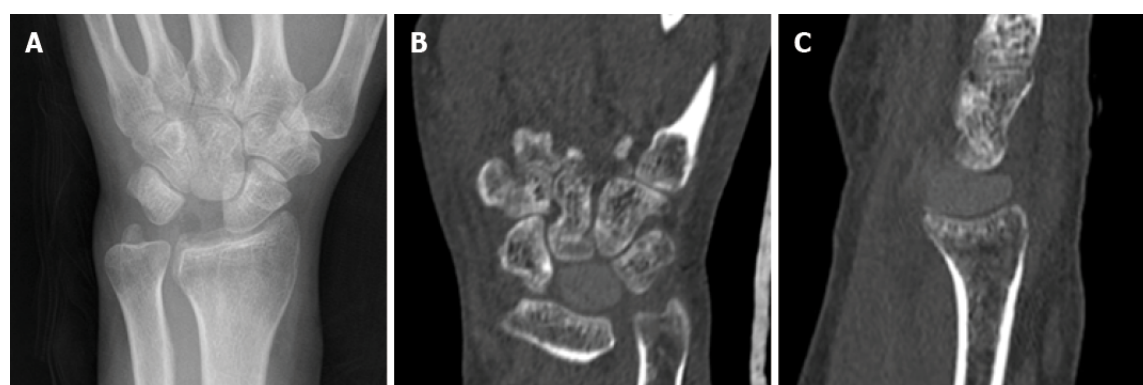
**Figure 2 The process of 3D-printed injection-molded polyether ether ketone lunate prosthesis.** A: The original data of healthy lunate bone were obtained by computed tomography; B-D: 3D model of lunate prosthesis using mirroring technique; E: Prosthesis structure was prepared by injection molding.



DOI: 10.12998/wjcc.v10.i24.8761 Copyright ©The Author(s) 2022.

**Figure 3 Intraoperative photographs.** A: Necrotic lunate bone resected; B: Necrotic lunate bone and custom-made lunate bone prosthesis of different sizes; C: Prosthesis in the original anatomic position of lunate bone.

Söhling *et al*[15] reported that implants made of biomaterials have become an integral part of modern medicine. Therefore, the ideal implant is reactive, but does not cause foreign body reaction. Elucidating the early immune response in the foreign body reaction is implant-material specific. Tanca *et al*[16] also reported application of 2D-fluorescence difference gel electrophoresis (2D-DIGE) to formalin-fixed diseased tissue samples from hospital repositories, and showed that 2D-DIGE can support biomarker discovery and validation studies on large sample cohorts. The associated patient information can considerably boost studies with limited sample availability or those involving long-distance exchange of samples. Kyriakides *et al*[17] reported the foreign body reaction to synthetic polymer biomaterials and the role of adaptive immunity, and suggested the existence of crosstalk between innate and adaptive immune cells that depends on the nature of the implants.



DOI: 10.12998/wjcc.v10.i24.8761 Copyright ©The Author(s) 2022.

**Figure 4 Postoperative imaging findings.** Postoperative radiographs (A) and computed tomography (1 yr) (B).

PEEK is a high-performance polymer that has been used for the manufacturing of dental implants. PEEK is a material with high biocompatibility, good mechanical properties, high temperature resistance, chemical stability, polishability, good wear resistance, low plaque affinity and high bond strength with veneering composites and luting cements. Compared to rigid framework materials such as zirconium oxide and metal alloys, PEEK has a low modulus of elasticity of 4 GPa and is as elastic as bone, providing a cushioning effect and reduction of stresses transferred[4,5]. So, it is more suitable for fabricating human bone tissue scaffolds and artificial joints. With such advantages as a short processing cycle, less material consumption and complex shaping, 3D printing technology better meets the clinical demand of individualized prosthesis customization. In addition, the prostheses may be fabricated with varying rigidity and elasticity by temperature control during 3D printing[4]; thus, a prosthesis can be designed which has a shape and size normally coincident to the original lunate bone and complies with the physiological characteristics of wrist. As a result, 3D-printed PEEK lunate prosthesis is a good choice. As the lunate bone has an irregular shape, the preoperative prosthesis design is important and focuses on the width, height and concave of lunate bone to keep the original size as much as possible. A prosthesis that is too big bears excessive pressure and thus become ruptured and extruded, while one that is too small size cannot stabilize the joint.

PEEK has outstanding tribological properties, excellent sliding and fretting wear resistance, especially high wear resistance and low friction coefficient at 250°C. It is easy for extrusion and injection molding, with excellent processing performance and high molding efficiency. As a medical implant, its elastic modulus is similar to that of bone, with good biocompatibility and transparent rays. The material is resistant to simulated *in vivo* degradation, including damage caused by lipid exposure. Although PEEK has these excellent characteristics[4], it still has some problems as a bone implant. One of them is that there is still a gap between PEEK and human bone in terms of modulus and mechanical strength. In terms of mechanical strength, PEEK still cannot meet the needs of human bones. Another problem with PEEK as a medical implant is that it is biologically inert[5]. Its low reactivity and integration with surrounding tissues will affect the successful transplantation of PEEK *in vivo*. In the next step of the treatment of lunar osteonecrosis, we plan to modify PEEK to better increase its mechanical strength and better match its elastic modulus.

## CONCLUSION

In summary, the 3D-printed injection-molded PEEK lunate prosthesis demonstrates definite efficacy in treating stage III Kienböck's disease, and it is an effective therapy worthy of being popularized. Although such prosthesis has good clinical efficacy, the subsequent large-sized long-term clinical case observation is needed.

## FOOTNOTES

**Author contributions:** Yuan CS and Tang KL contributed equally to this work; Yuan CS, Tang Y, Xie HQ, Liang TT and Tang KL designed the research study; Operative procedures were carried out by Tang KL; Yuan CS and Tang Y completed manuscript writing; Date collection and results evaluation were completed by Xie HQ and Liang; all authors have read and approve the final manuscript.

**Supported by** Chongqing Science and Health Combined Medical Discipline, No. 2020MSXM012.



**Informed consent statement:** All study participants provided informed written consent prior to study enrollment.

**Conflict-of-interest statement:** All authors report no relevant conflict of interest for this article.

**CARE Checklist (2016) statement:** The authors have read the CARE Checklist (2016), and the manuscript was prepared and revised according to the CARE Checklist (2016).

**Open-Access:** This article is an open-access article that was selected by an in-house editor and fully peer-reviewed by external reviewers. It is distributed in accordance with the Creative Commons Attribution NonCommercial (CC BY-NC 4.0) license, which permits others to distribute, remix, adapt, build upon this work non-commercially, and license their derivative works on different terms, provided the original work is properly cited and the use is non-commercial. See: <https://creativecommons.org/licenses/by-nc/4.0/>

**Country/Territory of origin:** China

**ORCID number:** Kang-Lai Tang 0000-0002-0370-106X.

**S-Editor:** Wu YXJ

**L-Editor:** A

**P-Editor:** Wu YXJ

## REFERENCES

- 1 **Chou J**, Bacle G, Ek ETH, Tham SKY. Fixation of the Fractured Lunate in Kienböck Disease. *J Hand Surg Am* 2019; **44**: 67.e1-67.e8 [PMID: 29934081 DOI: 10.1016/j.jhsa.2018.05.008]
- 2 **Matsumoto T**, Kakinoki R, Ikeguchi R, Ohta S, Akagi M, Matsuda S. Vascularized Bone Graft to the Lunate Combined With Temporary Scaphocapitate Fixation for Treatment of Stage III Kienböck Disease: A Report of the Results, a Minimum of 2 Years After Surgery. *J Hand Surg Am* 2018; **43**: 773.e1-773.e7 [PMID: 29454599 DOI: 10.1016/j.jhsa.2018.01.008]
- 3 **Li S**, Sun C, Zhou X, Shi J, Han T, Yan H. Treatment of Intraosseous Ganglion Cyst of the Lunate: A Systematic Review. *Ann Plast Surg* 2019; **82**: 577-581 [PMID: 30059388 DOI: 10.1097/SAP.0000000000001584]
- 4 **Zhang J**, Tian W, Chen J, Yu J, Zhang J. The application of polyetheretherketone (PEEK) implants in cranioplasty. *Brain Res Bull* 2019; **153**: 143-149 [PMID: 31425730 DOI: 10.1016/j.brainresbull.2019.08.010]
- 5 **Souza JCM**, Pinho SS, Braz MP, Silva FS, Henriques B. Carbon fiber-reinforced PEEK in implant dentistry: A scoping review on the finite element method. *Comput Methods Biomech Biomed Engin* 2021; **24**: 1355-1367 [PMID: 33616450 DOI: 10.1080/10255842.2021.1888939]
- 6 **Papathanasiou I**, Kamposiora P, Papavasiliou G, Ferrari M. The use of PEEK in digital prosthodontics: A narrative review. *BMC Oral Health* 2020; **20**: 217 [PMID: 32741366 DOI: 10.1186/s12903-020-01202-7]
- 7 **Wang L**, Huang L, Li X, Zhong D, Li D, Cao T, Yang S, Yan X, Zhao J, He J, Cao Y, Wang L. Three-Dimensional Printing PEEK Implant: A Novel Choice for the Reconstruction of Chest Wall Defect. *Ann Thorac Surg* 2019; **107**: 921-928 [PMID: 30403979 DOI: 10.1016/j.athoracsur.2018.09.044]
- 8 **Park JH**, Jang WY, Kwak DH, Park JW. Lunate morphology as a risk factor of idiopathic ulnar impaction syndrome. *Bone Joint J* 2017; **99-B**: 1508-1514 [PMID: 29092991 DOI: 10.1302/0301-620X.99B11.BJJ-2016-1238.R2]
- 9 **Havulinna J**, Jokiharja J, Paavilainen P, Leppänen OV. Keyhole Revascularization for Treatment of Coronal Plane Fracture of the Lunate in Kienböck Disease. *J Hand Surg Am* 2016; **41**: e441-e445 [PMID: 27663052 DOI: 10.1016/j.jhsa.2016.08.010]
- 10 **Fontaine C**. Kienböck's disease. *Chir Main* 2015; **34**: 4-17 [PMID: 25600763 DOI: 10.1016/j.main.2014.10.149]
- 11 **Kennedy C**, Abrams R. In Brief: The Lichtman Classification for Kienböck Disease. *Clin Orthop Relat Res* 2019; **477**: 1516-1520 [PMID: 30507834 DOI: 10.1097/CORR.0000000000000595]
- 12 **Mariconda M**, Soscia E, Sirignano C, Smeraglia F, Soldati A, Balato G. Long-term clinical results and MRI changes after tendon ball arthroplasty for advanced Kienböck's disease. *J Hand Surg Eur Vol* 2013; **38**: 508-514 [PMID: 23303835 DOI: 10.1177/1753193412471183]
- 13 **Dewan AK**, Chhabra AB, Khanna AJ, Anderson MW, Brunton LM. Magnetic resonance imaging of the hand and wrist: techniques and spectrum of disease: AAOS exhibit selection. *J Bone Joint Surg Am* 2013; **95**: e68 [PMID: 23677369 DOI: 10.2106/JBJS.L.00334]
- 14 **Viljakka T**, Tallroth K, Vastamäki M. Long-term outcome (22-36 years) of silicone lunate arthroplasty for Kienböck's disease. *J Hand Surg Eur Vol* 2014; **39**: 405-415 [PMID: 23695152 DOI: 10.1177/1753193413489460]
- 15 **Söhling N**, Ondreka M, Konradowitz K, Reichel T, Marzi I, Henrich D. Early Immune Response in Foreign Body Reaction Is Implant/Material Specific. *Materials (Basel)* 2022; **15** [PMID: 35329646 DOI: 10.3390/ma15062195]
- 16 **Tanca A**, Pisanu S, Bioss G, Pagnozzi D, Antuofermo E, Burrai GP, Canzonieri V, Cossu-Rocca P, De Re V, Eccher A, Fanciulli G, Rocca S, Uzzau S, Addis MF. Application of 2D-DIGE to formalin-fixed diseased tissue samples from hospital repositories: results from four case studies. *Proteomics Clin Appl* 2013; **7**: 252-263 [PMID: 23090899 DOI: 10.1002/prca.201200054]
- 17 **Kyriakides TR**, Kim HJ, Zheng C, Harkins L, Tao W, Deschenes E. Foreign body response to synthetic polymer biomaterials and the role of adaptive immunity. *Biomed Mater* 2022; **17** [PMID: 35168213 DOI: 10.1088/1748-605X/ac5574]



Published by **Baishideng Publishing Group Inc**  
7041 Koll Center Parkway, Suite 160, Pleasanton, CA 94566, USA

**Telephone:** +1-925-3991568

**E-mail:** [bpgoffice@wjgnet.com](mailto:bpgoffice@wjgnet.com)

**Help Desk:** <https://www.f6publishing.com/helpdesk>

<https://www.wjgnet.com>

