

World Journal of *Clinical Cases*

World J Clin Cases 2022 September 6; 10(25): 8808-9179



Contents

Thrice Monthly Volume 10 Number 25 September 6, 2022

MINIREVIEWS

- 8808 Ear, nose, and throat manifestations of COVID-19 and its vaccines
Al-Ani RM
- 8816 Potential influences of religiosity and religious coping strategies on people with diabetes
Onyishi CN, Eseadi C, Ilechukwu LC, Okoro KN, Okolie CN, Egbule E, Asogwa E

ORIGINAL ARTICLE

Case Control Study

- 8827 Effectiveness of six-step complex decongestive therapy for treating upper limb lymphedema after breast cancer surgery
Zhang HZ, Zhong QL, Zhang HT, Luo QH, Tang HL, Zhang LJ

Retrospective Study

- 8837 Hospital admissions from alcohol-related acute pancreatitis during the COVID-19 pandemic: A single-centre study
Mak WK, Di Mauro D, Pearce E, Karran L, Myintmo A, Duckworth J, Orabi A, Lane R, Holloway S, Manzelli A, Mossadegh S
- 8844 Indocyanine green plasma clearance rate and 99mTc-galactosyl human serum albumin single-photon emission computed tomography evaluated preoperative remnant liver
Iwaki K, Kaihara S, Kita R, Kitamura K, Hashida H, Uryuhara K
- 8854 Arthroscopy with subscapularis upper one-third tenodesis for treatment of recurrent anterior shoulder instability independent of glenoid bone loss
An BJ, Wang FL, Wang YT, Zhao Z, Wang MX, Xing GY
- 8863 Evaluation of the prognostic nutritional index for the prognosis of Chinese patients with high/extremely high-risk prostate cancer after radical prostatectomy
Yang F, Pan M, Nie J, Xiao F, Zhang Y

Observational Study

- 8872 Chlorine poisoning caused by improper mixing of household disinfectants during the COVID-19 pandemic: Case series
Lin GD, Wu JY, Peng XB, Lu XX, Liu ZY, Pan ZG, Qiu ZW, Dong JG
- 8880 Mental health of the Slovak population during COVID-19 pandemic: A cross-sectional survey
Kralova M, Brazinova A, Sivcova V, Izakova L

Prospective Study

- 8893** Arthroscopic anatomical reconstruction of lateral collateral ligaments with ligament advanced reinforcement system artificial ligament for chronic ankle instability
Wang Y, Zhu JX

SYSTEMATIC REVIEWS

- 8906** How to select the quantitative magnetic resonance technique for subjects with fatty liver: A systematic review
Li YW, Jiao Y, Chen N, Gao Q, Chen YK, Zhang YF, Wen QP, Zhang ZM
- 8922** Lymphocytic choriomeningitis virus: An under-recognized congenital teratogen
Ferenc T, Vujica M, Mrzljak A, Vilbic-Cavlek T

CASE REPORT

- 8932** Alagille syndrome associated with total anomalous pulmonary venous connection and severe xanthomas: A case report
Zeng HS, Zhang ZH, Hu Y, Zheng GL, Wang J, Zhang JW, Guo YX
- 8939** Colo-colonic intussusception with post-polypectomy electrocoagulation syndrome: A case report
Moon JY, Lee MR, Yim SK, Ha GW
- 8945** Portal vein gas combined with pneumatosis intestinalis and emphysematous cystitis: A case report and literature review
Hu SF, Liu HB, Hao YY
- 8954** Quadricuspid aortic valve and right ventricular type of myocardial bridging in an asymptomatic middle-aged woman: A case report
Sopek Merkaš I, Lakušić N, Paar MH
- 8962** Treatment of gastric carcinoma with lymphoid stroma by immunotherapy: A case report
Cui YJ, Ren YY, Zhang HZ
- 8968** Gallstone associated celiac trunk thromboembolisms complicated with splenic infarction: A case report
Wu CY, Su CC, Huang HH, Wang YT, Wang CC
- 8974** Extracorporeal membrane oxygenation for lung cancer-related life-threatening hypoxia: A case report
Yoo SS, Lee SY, Choi SH
- 8980** Multi-disciplinary treatment of maxillofacial skeletal deformities by orthognathic surgery combined with periodontal phenotype modification: A case report
Liu JY, Li GF, Tang Y, Yan FH, Tan BC
- 8990** X-linked recessive Kallmann syndrome: A case report
Zhang P, Fu JY
- 8998** Delayed complications of intradural cement leakage after percutaneous vertebroplasty: A case report
Ma QH, Liu GP, Sun Q, Li JG

- 9004** Coexistent Kaposi sarcoma and post-transplant lymphoproliferative disorder in the same lymph nodes after pediatric liver transplantation: A case report
Zhang SH, Chen GY, Zhu ZJ, Wei L, Liu Y, Liu JY
- 9012** Misdiagnosis of pancreatic metastasis from renal cell carcinoma: A case report
Liang XK, Li LJ, He YM, Xu ZF
- 9020** Discoid medial meniscus of both knees: A case report
Zheng ZR, Ma H, Yang F, Yuan L, Wang GD, Zhao XW, Ma LF
- 9028** Simultaneous laparoscopic and arthroscopic excision of a huge juxta-articular ganglionic cyst compressing the sciatic nerve: A case report
Choi WK, Oh JS, Yoon SJ
- 9036** One-stage revision arthroplasty in a patient with ochronotic arthropathy accompanied by joint infection: A case report
Wang XC, Zhang XM, Cai WL, Li Z, Ma C, Liu YH, He QL, Yan TS, Cao XW
- 9044** Bladder paraganglioma after kidney transplantation: A case report
Wang L, Zhang YN, Chen GY
- 9050** Total spinal anesthesia caused by lidocaine during unilateral percutaneous vertebroplasty performed under local anesthesia: A case report
Wang YF, Bian ZY, Li XX, Hu YX, Jiang L
- 9057** Ruptured splenic artery aneurysms in pregnancy and usefulness of endovascular treatment in selective patients: A case report and review of literature
Lee SH, Yang S, Park I, Im YC, Kim GY
- 9064** Gastrointestinal metastasis secondary to invasive lobular carcinoma of the breast: A case report
Li LX, Zhang D, Ma F
- 9071** Post-bulbar duodenal ulcer with anterior perforation with kissing ulcer and duodenocaval fistula: A case report and review of literature
Alzerwi N
- 9078** Modified orthodontic treatment of substitution of canines by first premolars: A case report
Li FF, Li M, Li M, Yang X
- 9087** Renal cell carcinoma presented with a rare case of icteric Stauffer syndrome: A case report
Popov DR, Antonov KA, Atanasova EG, Pentchev CP, Milatchkov LM, Petkova MD, Neykov KG, Nikolov RK
- 9096** Successful resection of a huge retroperitoneal venous hemangioma: A case report
Qin Y, Qiao P, Guan X, Zeng S, Hu XP, Wang B
- 9104** Malignant transformation of biliary adenofibroma combined with benign lymphadenopathy mimicking advanced liver carcinoma: A case report
Wang SC, Chen YY, Cheng F, Wang HY, Wu FS, Teng LS

- 9112** Congenital hepatic cyst: Eleven case reports
Du CX, Lu CG, Li W, Tang WB
- 9121** Endovascular treatment of a ruptured pseudoaneurysm of the internal carotid artery in a patient with nasopharyngeal cancer: A case report
Park JS, Jang HG
- 9127** Varicella-zoster virus meningitis after spinal anesthesia: A case report
Lee YW, Yoo B, Lim YH
- 9132** Chondrosarcoma of the toe: A case report and literature review
Zhou LB, Zhang HC, Dong ZG, Wang CC
- 9142** Tamsulosin-induced life-threatening hypotension in a patient with spinal cord injury: A case report
Lee JY, Lee HS, Park SB, Lee KH
- 9148** CCNO mutation as a cause of primary ciliary dyskinesia: A case report
Zhang YY, Lou Y, Yan H, Tang H
- 9156** Repeated bacteremia and hepatic cyst infection lasting 3 years following pancreatoduodenectomy: A case report
Zhang K, Zhang HL, Guo JQ, Tu CY, Lv XL, Zhu JD
- 9162** Idiopathic cholesterol crystal embolism with atheroembolic renal disease and blue toes syndrome: A case report
Cheng DJ, Li L, Zheng XY, Tang SF
- 9168** Systemic lupus erythematosus with visceral varicella: A case report
Zhao J, Tian M

LETTER TO THE EDITOR

- 9176** Imaging of fibroadenoma: Be careful with imaging follow-up
Ece B, Aydın S

ABOUT COVER

Editorial Board Member of *World Journal of Clinical Cases*, Mohsen Khosravi, MD, Assistant Professor, Department of Psychiatry and Clinical Psychology, Zahedan University of Medical Sciences, Zahedan 9819713955, Iran. m.khosravi@zaums.ac.ir

AIMS AND SCOPE

The primary aim of *World Journal of Clinical Cases* (WJCC, *World J Clin Cases*) is to provide scholars and readers from various fields of clinical medicine with a platform to publish high-quality clinical research articles and communicate their research findings online.

WJCC mainly publishes articles reporting research results and findings obtained in the field of clinical medicine and covering a wide range of topics, including case control studies, retrospective cohort studies, retrospective studies, clinical trials studies, observational studies, prospective studies, randomized controlled trials, randomized clinical trials, systematic reviews, meta-analysis, and case reports.

INDEXING/ABSTRACTING

The WJCC is now abstracted and indexed in Science Citation Index Expanded (SCIE, also known as SciSearch®), Journal Citation Reports/Science Edition, Current Contents®/Clinical Medicine, PubMed, PubMed Central, Scopus, Reference Citation Analysis, China National Knowledge Infrastructure, China Science and Technology Journal Database, and Superstar Journals Database. The 2022 Edition of Journal Citation Reports® cites the 2021 impact factor (IF) for WJCC as 1.534; IF without journal self cites: 1.491; 5-year IF: 1.599; Journal Citation Indicator: 0.28; Ranking: 135 among 172 journals in medicine, general and internal; and Quartile category: Q4. The WJCC's CiteScore for 2021 is 1.2 and Scopus CiteScore rank 2021: General Medicine is 443/826.

RESPONSIBLE EDITORS FOR THIS ISSUE

Production Editor: *Xu Guo*; Production Department Director: *Xiang Li*; Editorial Office Director: *Jin-Lei Wang*.

NAME OF JOURNAL

World Journal of Clinical Cases

ISSN

ISSN 2307-8960 (online)

LAUNCH DATE

April 16, 2013

FREQUENCY

Thrice Monthly

EDITORS-IN-CHIEF

Bao-Gan Peng, Jerzy Tadeusz Chudek, George Kontogeorgos, Maurizio Serati, Ja Hyeon Ku

EDITORIAL BOARD MEMBERS

<https://www.wjgnet.com/2307-8960/editorialboard.htm>

PUBLICATION DATE

September 6, 2022

COPYRIGHT

© 2022 Baishideng Publishing Group Inc

INSTRUCTIONS TO AUTHORS

<https://www.wjgnet.com/bpg/gerinfo/204>

GUIDELINES FOR ETHICS DOCUMENTS

<https://www.wjgnet.com/bpg/GerInfo/287>

GUIDELINES FOR NON-NATIVE SPEAKERS OF ENGLISH

<https://www.wjgnet.com/bpg/gerinfo/240>

PUBLICATION ETHICS

<https://www.wjgnet.com/bpg/GerInfo/288>

PUBLICATION MISCONDUCT

<https://www.wjgnet.com/bpg/gerinfo/208>

ARTICLE PROCESSING CHARGE

<https://www.wjgnet.com/bpg/gerinfo/242>

STEPS FOR SUBMITTING MANUSCRIPTS

<https://www.wjgnet.com/bpg/GerInfo/239>

ONLINE SUBMISSION

<https://www.f6publishing.com>



Systemic lupus erythematosus with visceral varicella: A case report

Jing Zhao, Mei Tian

Specialty type: Rheumatology

Provenance and peer review:

Unsolicited article; Externally peer reviewed.

Peer-review model: Single blind

Peer-review report's scientific quality classification

Grade A (Excellent): A, A

Grade B (Very good): 0

Grade C (Good): C

Grade D (Fair): D

Grade E (Poor): 0

P-Reviewer: Ozden F, Turkey;
Sharaf MM, Syria; Tajiri K, Japan

Received: April 29, 2022

Peer-review started: April 29, 2022

First decision: May 30, 2022

Revised: June 6, 2022

Accepted: July 29, 2022

Article in press: July 29, 2022

Published online: September 6, 2022



Jing Zhao, Mei Tian, Department of Rheumatology, Affiliated Hospital of Zunyi Medical University, Zunyi 563003, Guizhou Province, China

Corresponding author: Mei Tian, PhD, Chief Doctor, Doctor, Department of Rheumatology, Affiliated Hospital of Zunyi Medical University, No. 149 Dalian Road, Huichuan District, Zunyi 563003, Guizhou Province, China. 348820517@qq.com

Abstract

BACKGROUND

As an autoimmune disease, systemic lupus erythematosis (SLE) can affect multiple systems of the body and is mainly treated by steroids and immunosuppressive agents. SLE results in a long-term immunocompromised state with the potential of infection complications (e.g., bacterial, fungal and viral infections). Abdominal pain or acute abdomen are frequently the only manifestations of SLE at disease onset or during the early stage of the disease course. Thus, multidisciplinary collaboration is required to identify these patients because timely diagnosis and treatment are crucial for improving their prognosis.

CASE SUMMARY

Herein, we reported a case of an SLE patient with visceral varicella that was identified after the onset of abdominal pain. The 16-year-old female patient with SLE was admitted to our hospital due to initial attacks of abdominal pain and intermittent fever. The patient's condition rapidly became aggravated within a short time after admission, with large areas of vesicular rash, severe pneumonia, respiratory failure, shock, and haematologic system and hepatic function impairment. Based on multidisciplinary collaboration, the patient was diagnosed with visceral disseminated varicella and was administered life support, antiviral (acyclovir), immunomodulatory (intravenous injection of human immunoglobulin), anti-infection (vancomycin) and anti-inflammatory (steroid) therapies. After treatment, her clinical symptoms and laboratory indicators gradually improved, and the patient was discharged.

CONCLUSION

SLE patients long treated with steroids and immunosuppressive agents are susceptible to various infections. Considering that visceral varicella with abdominal pain as the initial presentation is characterized by rapid progression and often coexists with serious complications, prompt diagnosis and early antiviral therapy are critical to prevent severe life-threatening complications.

Key Words: Systemic lupus erythematosus; Visceral varicella; Severe pneumonia;

Tacrolimus; Mycophenolate mofetil; Case report

©The Author(s) 2022. Published by Baishideng Publishing Group Inc. All rights reserved.

Core Tip: The long-term use of steroids and immunosuppressive agents for the treatment of systemic lupus erythematosus may decrease immunity, which is a high-risk factor for varicella-zoster virus (VZV) infection and severe varicella. Patients with varicella who suddenly develop abdominal pain should be informed about visceral disseminated VZV infection, which principally manifests as severe abdominal pain, with potential stomach, intestine and spleen involvement. Furthermore, abdominal pain may appear several days before skin rashes, and such infections may be misdiagnosed for other acute abdomen, lupus mesenteric vasculitis or thromboembolic diseases. Thus, prompt and accurate diagnosis and the early initiation of antiviral therapy are particularly important for avoiding severe life-threatening complications.

Citation: Zhao J, Tian M. Systemic lupus erythematosus with visceral varicella: A case report. *World J Clin Cases* 2022; 10(25): 9168-9175

URL: <https://www.wjgnet.com/2307-8960/full/v10/i25/9168.htm>

DOI: <https://dx.doi.org/10.12998/wjcc.v10.i25.9168>

INTRODUCTION

Systemic lupus erythematosus (SLE) is an autoimmune disease that involves multiple systems of the body. Intestinal and mesenteric vasculitis frequently occurs in SLE patients with digestive system involvement. Studies have demonstrated that some cases may be complicated by acute abdomen, such as pancreatitis, intestinal necrosis or intestinal infarction. Varicella-zoster virus (VZV), a human alpha herpes virus of the Varicellovirus genus, causes varicella and herpes zoster. Autoimmune diseases, immune disorders and/or use of immune modulators are high-risk factors for VZV infection and induction of severe varicella. In some patients, varicella initially manifests as severe abdominal pain with potential stomach, intestine and spleen involvement. In some varicella patients, severe abdominal pain is the first presentation, and the stomach, intestines, and spleen may be involved. When these patients have SLE, it is difficult to differentiate varicella from intestinal wall and mesenteric vasculitis, which makes diagnosis and treatment difficult.

CASE PRESENTATION

Chief complaints

A 16-year-old female patient diagnosed with SLE 5 years prior was admitted to our hospital due to a 2-d history of intermittent abdominal pain accompanied by fever without obvious inducement.

History of present illness

Five years previously, the patient presented with fever, cough and expectoration after catching a cold, which was accompanied by skin petechiae and ecchymoses in the distal extremities. After receiving an infusion at the local hospital (details unknown), the patient's condition improved; therefore, the episode was considered unremarkable. Three months later, the patient experienced a relapse of the above symptoms that was associated with hair loss, photoallergy and joint pain. Laboratory test results were as follows: Urine protein, 2 +; 24-h urinary protein quantity, 2.412 g; anti-double-stranded DNA (anti-dsDNA) antibody, +++; anti-nucleosome antibody, ++; anti-histone antibody, ++; anti-nuclear antibody (ANA) (1:100), positive; ANA (1:320), positive; ANA (1:1000), weakly positive; complement C3, 0.45 g/L (reference range: 0.79-1.52 g/L); liver and kidney function, normal; and routine blood test, normal. Combined with mild mesangial proliferative glomerulonephritis indicated by renal biopsy pathology, the patient was diagnosed with "SLE and lupus nephritis". After treatment with mycophenolate mofetil (0.5 g bid), prednisone tablets (10 mg qd), hydroxychloroquine (200 mg bid) and enalapril maleate and folic acid tablets (10 mg qd), the patient's clinical symptoms were relieved, and she was discharged. The results for several routine urine tests thereafter were as follows: Urine protein, 3 +; and 24-h urinary protein quantity, 1-3 g. After the steroid was tapered and terminated, tacrolimus (1 mg bid) was added to the original treatment plan. In the past 4 years, the patient experienced no relapse of the above symptoms; however, her urine protein failed to normalize. Two months prior, the patient experienced persistent pain with paroxysmal exacerbations in both hands and feet. Each onset lasted approximately 2-3 d and was relieved spontaneously. Physical examination showed vasculitis-like changes in the skin

on both hands. Laboratory test results were as follows: Anti-neutrophil cytoplasmic antibody, perinuclear anti-neutrophil cytoplasmic antibody (pANCA) +; creatinine (Cr), 105 $\mu\text{mol/L}$ (reference range: 30–90 $\mu\text{mol/L}$); urine protein, 3 +; urinary occult blood, 1 +; erythrocyte sedimentation rate (ESR), 49 mm/h (reference range: < 38 mm/h); C-reactive protein (CRP), 29.9 mg/L (reference range: 0.068–8.2 mg/L); complement C3, 0.66 g/L; and haemoglobin (Hb), 86 g/L (reference range: 115–150 g/L). Chest computed tomography (CT) indicated bilateral interstitial pneumonia. Renal biopsy-proven active class IV lupus nephritis and cutaneous vasculitis were considered. Considering the presentation of abnormal renal function, tacrolimus was discontinued. The patient and family members refused cyclophosphamide. Then, targeted therapy with belimumab was given on the basis of steroids and mycophenolate mofetil. Her extremity pain was alleviated after treatment, and she was discharged. Treatment with prednisone tablets (50 mg qd), mycophenolate mofetil (0.5 g bid) and intravenous injection of belimumab (360 mg 1/mo) was continued at home. Two days prior, the patient was admitted to our hospital due to a 2-d history of intermittent abdominal pain accompanied by fever without obvious inducement. The primary symptom was whole-abdominal pain, especially in the upper abdomen, presenting as colic, occasionally involving the waist, back and buttocks and lasting from tens of minutes to several hours. Self-administration of acid-reducing agents had no effect, and her body temperature ranged from 35.9 °C to 38.5 °C. There was no oedema, oral ulcer, photoallergy, cough, expectoration or diarrhoea, and her urine and stool were normal.

Physical examination

The patient had whole-abdomen tenderness, particularly in the upper abdomen, without rebound pain or muscle tension. Two days after admission, a small amount of tufted herpes appeared in the labia majora and minora and pharynx, and the patient developed fever with a maximum body temperature of 39 °C (axillary temperature), which was accompanied by ocular hyperaemia, light bloody tears, and oral, nasal and vaginal bleeding. Four days after admission, numerous vesicular herpes and small pustules appeared on her entire body, some of which fused into flakes, and the patient exhibited tachypnoea in the decubitus position with a high pillow and uncontrolled blood pressure and oxygen saturation under oxygen inhalation. A large number of wet rales were heard in both lungs, and low-pitched breath sounds were heard in the lower lobes of both lungs.

Laboratory examinations

Laboratory test results are provided in Tables 1 and 2.

Imaging examinations

Whole-abdomen CT + contrast-enhanced scanning and CT angiography of the kidney were normal. Gastroscopy indicated chronic gastritis. Chest CT indicated bilateral pneumonia, bilateral pleural effusion and pericardial effusion (Figure 1A).

FINAL DIAGNOSIS

The final diagnosis was severe pneumonia complicated with parapneumonic effusion, septic shock, multi-organ failure, disseminated varicella infection, SLE, and lupus nephritis.

TREATMENT

The patient was administered antiviral (acyclovir), immunomodulatory (intravenous injection of human immunoglobulin), anti-infection (meropenem and vancomycin) and anti-inflammatory (methylprednisolone, 40 mg qd) therapies, intermittent transfusion of platelets for the prevention and treatment of bleeding, and symptomatic and supportive treatments, including life support, closed thoracic drainage, liver protection, and fluid replacement.

OUTCOME AND FOLLOW-UP

After treatment for 12 d in the ICU, the patient's condition gradually improved. The patient was removed from the ventilator and transferred to the general ward. Laboratory tests showed improvements in relevant indicators (Tables 1 and 2); the herpes subsided, with residual skin pigmentation. Subsequently, the physician communicated with the patient's family members regarding her condition, and tacrolimus (1 mg bid) was prescribed for treating SLE. At regular follow-ups after discharge, there was no recurrence of varicella or abdominal pain; her urine protein was at 1 +, with a 24-h urinary protein quantity of 0.44 g.

Table 1 Results of laboratory tests performed during hospitalization

Item	Before treatment	During treatment	After treatment	Reference range
WBC ($\times 10^9/L$)	20.61	10.64	6.42	3.5-9.5
NEUT ($\times 10^9/L$)	14.84	9.23	3.02	1.8-6.3
ALC ($\times 10^9/L$)	4.74	0.82	1.93	1.1-3.2
RBC ($\times 10^{12}/L$)	3.3	2.54	3.15	3.8-5.1
Hb (g/L)	103	80	97	115-150
PLT ($\times 10^9/L$)	245	27	306	100-300
IgG (g/L)	3.68	/	6.03	7.51-15.60
C3 (g/L)	0.47	/	0.44	0.79-1.52
C4 (g/L)	0.075	/	0.072	0.16-0.38
ALT (U/L)	47	656	12	7-40
AST (U/L)	65	836	34	13-35
Alb (g/L)	31.5	20.9	37.4	40-55
Cr ($\mu\text{mol/L}$)	75	67	58	30-90
Urinary occult blood	++	+++	+	-
Urine protein	+++	+++	+++	-
24-h urinary protein quantity (g/24-h)	2.8	/	0.44	-
ANA	1:320	1:320	-	-
D-D ($\mu\text{g/mL}$)	0.64	25.5	3.03	< 0.5
Anti-RNP	+	+	/	-
Anti-dsDNA	-	-	/	-
Anti-Sm	-	-	/	-
Anti-RO-52	+	+	/	-
ESR (mm/h)	2	56	2	< 38
CRP (g/L)	2.7	84.2	3.7	0.68-8.20
Blood/urine amylase	-	/	/	-
ANCA	-	/	/	-
VZV-DNA	+	/	/	-
Blood culture	Gram-positive bacterium	Staphylococcus aureus	-	-

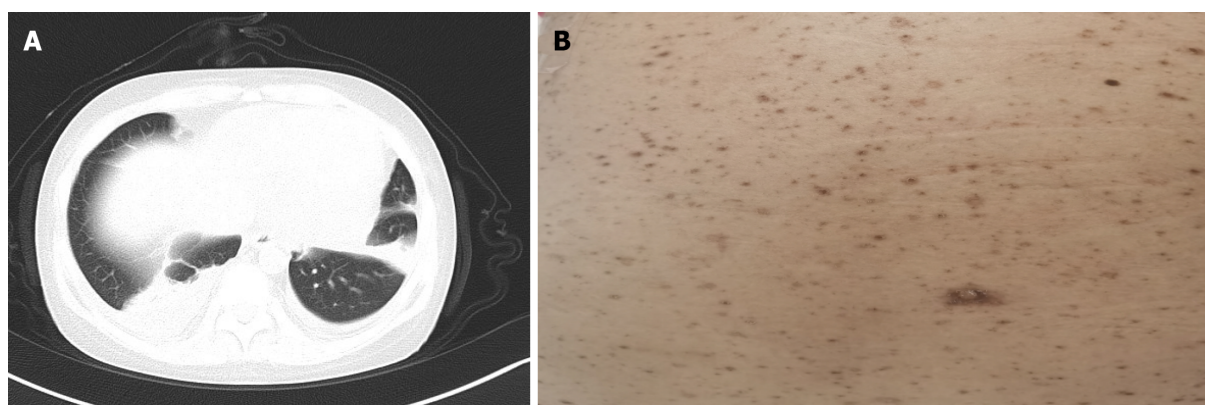
"/": Not checked; "-": Negative. WBC: White blood cell; NEUT: Neutrophil; RBC: Red blood cell; Hb: Haemoglobin; PLT: Platelet; IgG: Immunoglobulin G; C3/4: Complement 3/4; ALT: Alanine transaminase; AST: Aspartate aminotransferase; Alb: Albumin; Cr: Creatinine; ANA: Anti-nuclear antibody; D-D: D-dimer; Anti-RNP: Anti-Ribonuclear protein antibody; Anti-dsDNA: Anti-Double-stranded DNA antibody; ESR: Erythrocyte sedimentation rate; CRP: C-reactive protein; ANCA: Anti-Neutrophil cytoplasmic antibody; VZV: Varicella-zoster virus.

DISCUSSION

SLE is an autoimmune disease that involves multiple systems, and digestive system involvement usually manifests as intestinal wall and mesenteric vasculitis, mainly involving the small arteries or venules of the jejunum and ileum. In general, gastrointestinal symptoms such as nausea, vomiting, anorexia, and abdominal pain are nonspecific[1]. Endoscopy is able to reveal intestinal oedema, congestion or ischaemia with or without obstruction, with vascular inflammation and necrosis as pathological changes[2]. Although serological and inflammatory markers are considered to be nonspecific, contrast-enhanced abdominal CT is of great value for the diagnosis of SLE-related mesenteric vasculitis[3]. In clinical practice, some cases of SLE are complicated by severe acute abdomen (*e.g.*, pancreatitis, peritonitis, and intestinal infarction), as reported in several studies[4-6].

Table 2 Routine biochemistry test results before and after pleural effusion treatment

Item	Before treatment	After treatment	Reference range
Appearance	Red and turbid	Yellowish and transparent	Yellowish and clear
Rivalta's test	+	-	-
Total cell count ($\times 10^6/L$)	6480	440	-
Nucleated cell count ($\times 10^6/L$)	810	110	< 300
Proportion of neutrophils (%)	10	-	-
Proportion of lymphocytes (%)	54	-	-
Proportion of mesothelial cells (%)	32	-	-
Proportion of macrophages (%)	4	-	-
Alb (g/L)	20.3	29.8	< 25
Glucose (mmol/L)	5.04	7.68	3.6-5.5
Lactate dehydrogenase (U/L)	173	213	0-200
Adenosine dehydrogenase (U/L)	4.68	10.63	0-45



DOI: 10.12998/wjcc.v10.i25.9168 Copyright ©The Author(s) 2022.

Figure 1 Imaging examinations. A: Chest computed tomography indicated bilateral pneumonia, bilateral pleural effusion and pericardial effusion; B: Residual pigmentation of the skin following numerous herpetic lesions.

In addition to the above diseases, long-term use of steroids and immunosuppressive agents for the treatment of SLE may decrease immunity, which is a high-risk factor for VZV infection and subsequent progression to severe varicella. The initial manifestation in the patient in this case study was abdominal pain; therefore, SLE complicated with gastrointestinal vasculitis or acute abdomen was first considered. After these conditions were ruled out by relevant examinations and after typical skin rashes appeared, varicella was ascertained with the assistance of the Department of Dermatology and the Department of Infection. Her abdominal pain resolved after the administration of antiviral therapy for 2 d. Patients with varicella should be informed about the sudden development of abdominal pain and the possibility of visceral disseminated VZV infection, which principally presents as severe abdominal pain, with potential stomach, intestine and spleen involvement[7]. Moreover, abdominal pain may appear several days before skin rashes, resulting in misdiagnosis as other acute abdomen, lupus mesenteric vasculitis or thromboembolic diseases. Visceral disseminated varicella-induced abdominal pain is attributed to the proliferation of VZV in the abdominal cavity and mesenteric ganglia, but the specific mechanism remains unclear[8-11]. Furthermore, VZV infection may be accompanied by vasculitis, presenting as abdominal pain, vomiting, diarrhoea and intestinal obstruction when infection occurs in the abdominal blood vessels[12,13].

VZV infection occurs mostly in children but rarely in adults. Nonetheless, adult patients who experience VZV infection often present severe symptoms and complications. Varicella pneumonia is the most common complication of VZV infection in adults, but there are also clinical reports on acute liver failure and thrombocytopenia involving the blood system[14,15]. For the patient in this case study, no relevant antibodies were present in the body because of the lack of regular vaccination during childhood. Overall, long-term application of steroids and immunosuppressive agents for SLE treatment

may have led to decreased immunity, and there was a recent history of contact with varicella patients, all of which resulted in varicella. In addition to numerous herpes lesions on the body and pharyngeal isthmus, the patient presented secondary acute liver injury, thrombocytopenia, severe pneumonia, and uncontrolled respiratory and circulatory functions; therefore, her condition was extremely critical. Due to emotional stress among family members, photographs were not taken when the patient was critically ill; residual skin pigmentation after numerous herpes lesions was photographically recorded at discharge (Figure 1B).

Currently, there is a lack of definite recommendations for the treatment of SLE with severe varicella, but varicella infection following organ or stem cell transplantation has already been reported. With corresponding therapeutic experience as the reference, the following aspects should be taken into account for treating severe varicella in critically ill patients with rapidly progressive disease: (1) Given that maintaining respiratory and circulatory stability is the premise for successful rescue, life support must be a priority; (2) early addition of antiviral drugs contributes to reducing tissue injury and diminishing or even preventing the destruction of affected ganglion cells[16]. In general, antiviral therapy should be continued until all rashes have dried and organ symptoms have resolved; (3) in the presence of severe complications, intravenous injection of human immunoglobulin can be used to control virus invasion and suppress toxemia-related antibodies, exerting a synergistic effect with antiviral drugs in the clinical treatment of varicella[17]; (4) glucocorticoids repress synthesis of interferon in the reticuloendothelial system, thus lowering the number of WBCs involved in phagocytosis and facilitating proliferation and spread of the virus in the body. Hence, glucocorticoid therapy is not recommended for mild VZV infection but for patients with severe pneumonia complications. Administration of methylprednisolone sodium succinate can reduce inflammatory reactions, suppress release of inflammatory mediators and cytokines and diminish exudation, thus achieving favourable curative effects[18]; (5) complications should be actively prevented and treated; and (6) the varicella-zoster vaccine should be considered for patients with autoimmune inflammatory rheumatism [19].

Yamada *et al*[20] reported a patient with VZV infection after living-donor liver transplantation. The patient was given methylprednisolone, tacrolimus and mycophenolate mofetil after transplantation, but 12 mo later, fever and back pain with systemic vesicular rashes appeared, followed by severe pneumonia, serious liver injury and disseminated intravascular coagulation. VZV-DNA PCR indicated VZV infection; the patient was administered antiviral (intravenous injection of acyclovir), anti-infective, immunomodulatory (intravenous injection of human immunoglobulin), anti-inflammatory (steroid), respiratory and circulatory support and symptomatic support therapies. When the clinical symptoms were relieved, immunosuppressive therapy with methylprednisolone and tacrolimus was reinitiated. However, the VZV-DNA level remained quite high, even after all rashes and organ symptoms had completely subsided. Hence, prophylactic oral acyclovir was provided and discontinued until monitoring indicated a marked decline in VZV-DNA. The 6-mo follow-up showed no recurrence[20].

According to Doki *et al*[21], 20 of 2411 patients show visceral VZV infection within 103-800 d after allogeneic stem cell transplantation in our hospital, with 17 receiving immunosuppressive therapy when varicella appeared and 80% complaining of abdominal pain. After treatment with acyclovir, 18 patients survived, though 2 died. From this, it can be seen that although the incidence rate of visceral VZV infection is not high, it is a serious disease. Furthermore, potential visceral VZV infection and early treatment should be taken into account when abdominal pain appears in patients administered immunosuppressive agents[21].

The timing of reinitiating immunosuppressive agents for controlling SLE remains obscure, and no definite therapeutic evidence has been reported. Previous literature on VZV infection after renal transplantation has suggested that if immunosuppressive agents cannot be discontinued, such agents should be replaced with cyclosporine, azathioprine and prednisone[22]; mycophenolate mofetil may increase the incidence rate of severe varicella[23]. If high-dose steroids such as mycophenolate mofetil and cyclophosphamide are required because of disease conditions, herpes zoster virus reactivation should be strongly suspected. Specifically, elevated VZV-IgM and VZV-DNA without clinical symptoms indicates subclinical reactivation, and the appearance of herpes zoster or varicella suggests clinical reactivation. In addition, VZV-IgG levels persist during infection[24,25] and are thus of no value for determining the presence or absence of varicella infection. In this case, the patient's family members refused to undergo VZV-DNA assessment during the recovery period; however, after communication, the patient was given tacrolimus (1 mg bid) to treat SLE. Regular follow-up showed no varicella. Furthermore, it was unexpected that the urine protein level was only 1 + and that the 24-h urinary protein quantity declined to 0.44 g. Whether these findings are relevant to varicella development is uncertain.

CONCLUSION

In conclusion, the incidence rate of SLE accompanied by visceral varicella with abdominal pain as the initial presentation is low, but its onset can lead to rapid disease progression with the potential of severe

complications. Therefore, prompt diagnosis and early antiviral therapy are vital to prevent severe life-threatening complications.

FOOTNOTES

Author contributions: Zhao J wrote the manuscript; Zhao J and Tian M have given final approval to the version to be submitted.

Informed consent statement: Informed written consent was obtained from the patients for the publication of this report and any accompanying images.

Conflict-of-interest statement: The authors declare that they have no conflict of interest.

CARE Checklist (2016) statement: The authors have read the CARE Checklist (2016), and the manuscript was prepared and revised according to the CARE Checklist (2016).

Open-Access: This article is an open-access article that was selected by an in-house editor and fully peer-reviewed by external reviewers. It is distributed in accordance with the Creative Commons Attribution NonCommercial (CC BY-NC 4.0) license, which permits others to distribute, remix, adapt, build upon this work non-commercially, and license their derivative works on different terms, provided the original work is properly cited and the use is non-commercial. See: <https://creativecommons.org/licenses/by-nc/4.0/>

Country/Territory of origin: China

ORCID number: Jing Zhao 0000-0001-7140-4377; Mei Tian 0000-0002-1633-2988.

S-Editor: Chen YL

L-Editor: A

P-Editor: Chen YL

REFERENCES

- Lee CK, Ahn MS, Lee EY, Shin JH, Cho YS, Ha HK, Yoo B, Moon HB. Acute abdominal pain in systemic lupus erythematosus: focus on lupus enteritis (gastrointestinal vasculitis). *Ann Rheum Dis* 2002; **61**: 547-550 [PMID: 12006332 DOI: 10.1136/ard.61.6.547]
- Janssens P, Arnaud L, Galicier L, Mathian A, Hie M, Sene D, Haroche J, Veyssier-Belot C, Huynh-Charlier I, Grenier PA, Piette JC, Amoura Z. Lupus enteritis: from clinical findings to therapeutic management. *Orphanet J Rare Dis* 2013; **8**: 67 [PMID: 23642042 DOI: 10.1186/1750-1172-8-67]
- Brewer BN, Kamen DL. Gastrointestinal and Hepatic Disease in Systemic Lupus Erythematosus. *Rheum Dis Clin North Am* 2018; **44**: 165-175 [PMID: 29149925 DOI: 10.1016/j.rdc.2017.09.011]
- El Qadiry R, Bourrahout A, Aitsab I, Sbihi M, Mouaffak Y, Moussair FZ, Younous S. Systemic Lupus Erythematosus-Related Pancreatitis in Children: Severe and Lethal Form. *Case Rep Pediatr* 2018; **2018**: 4612754 [PMID: 30693130 DOI: 10.1155/2018/4612754]
- Kheyri Z, Laripour A, Ala M. Peritonitis as the first presentation of systemic lupus erythematosus: a case report. *J Med Case Rep* 2021; **15**: 611 [PMID: 34953487 DOI: 10.1186/s13256-021-03216-3]
- White S, Merrie A. Recurrent bowel infarction in a patient with systemic lupus erythematosus. *N Z Med J* 2003; **116**: U483 [PMID: 12835811]
- Furuto Y, Kawamura M, Namikawa A, Takahashi H, Shibuya Y. Successful management of visceral disseminated varicella zoster virus infection during treatment of membranous nephropathy: a case report. *BMC Infect Dis* 2019; **19**: 625 [PMID: 31307420 DOI: 10.1186/s12879-019-4193-y]
- Chen JJ, Gershon AA, Li Z, Cowles RA, Gershon MD. Varicella zoster virus (VZV) infects and establishes latency in enteric neurons. *J Neurovirol* 2011; **17**: 578-589 [PMID: 22190254 DOI: 10.1007/s13365-011-0070-1]
- Serris A, Michot JM, Fourn E, Le Bras P, Dollat M, Hirsch G, Pallier C, Carbonnel F, Tertan G, Lambotte O. [Disseminated varicella-zoster virus infection with hemorrhagic gastritis during the course of chronic lymphocytic leukemia: case report and literature review]. *Rev Med Interne* 2014; **35**: 337-340 [PMID: 23773904 DOI: 10.1016/j.revmed.2013.05.004]
- Chang AE, Young NA, Reddick RL, Orenstein JM, Hosea SW, Katz P, Brennan MF. Small bowel obstruction as a complication of disseminated varicella-zoster infection. *Surgery* 1978; **83**: 371-374 [PMID: 635773]
- Au WY, Ma SY, Cheng VC, Ooi CG, Lie AK. Disseminated zoster, hyponatraemia, severe abdominal pain and leukaemia relapse: recognition of a new clinical quartet after bone marrow transplantation. *Br J Dermatol* 2003; **149**: 862-865 [PMID: 14616382 DOI: 10.1046/j.1365-2133.2003.05656.x]
- Abendroth A, Slobodman B. Varicella-Zoster Virus and Giant Cell Arteritis. *J Infect Dis* 2021; **223**: 4-6 [PMID: 32901280 DOI: 10.1093/infdis/jiaa567]
- Gilden D, White T, Boyer PJ, Galetta KM, Hedley-Whyte ET, Frank M, Holmes D, Nagel MA. Varicella Zoster Virus

- Infection in Granulomatous Arteritis of the Aorta. *J Infect Dis* 2016; **213**: 1866-1871 [PMID: [27037084](#) DOI: [10.1093/infdis/jiw101](#)]
- 14 **Muraoka H**, Tokeshi S, Abe H, Miyahara Y, Uchimura Y, Noguchi S, Sata M, Tanikawa K. Two cases of adult varicella accompanied by hepatic dysfunction. *Kansenshogaku Zasshi* 1998; **72**: 418-423 [PMID: [9621571](#) DOI: [10.11150/kansenshogakuzasshi1970.72.418](#)]
 - 15 **Shibusawa M**, Motomura S, Hidai H, Tsutsumi H, Fujita A. Varicella infection complicated by marked thrombocytopenia. *Jpn J Infect Dis* 2014; **67**: 292-294 [PMID: [25056076](#) DOI: [10.7883/yoken.67.292](#)]
 - 16 **Sauerbrei A**. Diagnosis, antiviral therapy, and prophylaxis of varicella-zoster virus infections. *Eur J Clin Microbiol Infect Dis* 2016; **35**: 723-734 [PMID: [26873382](#) DOI: [10.1007/s10096-016-2605-0](#)]
 - 17 **Lu YC**, Fan HC, Wang CC, Cheng SN. Concomitant use of acyclovir and intravenous immunoglobulin rescues an immunocompromised child with disseminated varicella caused multiple organ failure. *J Pediatr Hematol Oncol* 2011; **33**: e350-e351 [PMID: [21127434](#) DOI: [10.1097/MPH.0b013e3181ec0efb](#)]
 - 18 **Anwar SK**, Masoodi I, Alfaifi A, Hussain S, Sirwal IA. Combining corticosteroids and acyclovir in the management of varicella pneumonia: a prospective study. *Antivir Ther* 2014; **19**: 221-224 [PMID: [24535428](#) DOI: [10.3851/IMP2751](#)]
 - 19 **Rondaan C**, de Haan A, Horst G, Hempel JC, van Leer C, Bos NA, van Assen S, Bijl M, Westra J. Altered cellular and humoral immunity to varicella-zoster virus in patients with autoimmune diseases. *Arthritis Rheumatol* 2014; **66**: 3122-3128 [PMID: [25223407](#) DOI: [10.1002/art.38804](#)]
 - 20 **Yamada N**, Sanada Y, Okada N, Wakiya T, Ihara Y, Urahashi T, Mizuta K. Successful rescue of disseminated varicella infection with multiple organ failure in a pediatric living donor liver transplant recipient: a case report and literature review. *Virology* 2015; **12**: 91 [PMID: [26081644](#) DOI: [10.1186/s12985-015-0311-7](#)]
 - 21 **Doki N**, Miyawaki S, Tanaka M, Kudo D, Wake A, Oshima K, Fujita H, Uehara T, Hyo R, Mori T, Takahashi S, Okamoto S, Sakamaki H; Kanto Study Group for Cell Therapy. Visceral varicella zoster virus infection after allogeneic stem cell transplantation. *Transpl Infect Dis* 2013; **15**: 314-318 [PMID: [23551634](#) DOI: [10.1111/tid.12073](#)]
 - 22 **Kaul A**, Sharma RK, Bhadhuria D, Gupta A, Prasad N. Chickenpox infection after renal transplantation. *Clin Kidney J* 2012; **5**: 203-206 [PMID: [26069765](#) DOI: [10.1093/ckj/sfs036](#)]
 - 23 **Habuka M**, Wada Y, Kurosawa Y, Yamamoto S, Tani Y, Ohashi R, Ajioka Y, Nakano M, Narita I. Fatal visceral disseminated varicella zoster infection during initial remission induction therapy in a patient with lupus nephritis and rheumatoid arthritis-possible association with mycophenolate mofetil and high-dose glucocorticoid therapy: a case report. *BMC Res Notes* 2018; **11**: 165 [PMID: [29506558](#) DOI: [10.1186/s13104-018-3271-3](#)]
 - 24 **Rondaan C**, van Leer CC, van Assen S, Bootsma H, de Leeuw K, Arends S, Bos NA, Westra J. Longitudinal analysis of varicella-zoster virus-specific antibodies in systemic lupus erythematosus: No association with subclinical viral reactivations or lupus disease activity. *Lupus* 2018; **27**: 1271-1278 [PMID: [29667858](#) DOI: [10.1177/0961203318770535](#)]
 - 25 **Craddock-Watson JE**, Ridehalgh MK, Bourne MS. Specific immunoglobulin responses after varicella and herpes zoster. *J Hyg (Lond)* 1979; **82**: 319-336 [PMID: [219110](#) DOI: [10.1017/s0022172400025730](#)]



Published by **Baishideng Publishing Group Inc**
7041 Koll Center Parkway, Suite 160, Pleasanton, CA 94566, USA

Telephone: +1-925-3991568

E-mail: bpgoffice@wjgnet.com

Help Desk: <https://www.f6publishing.com/helpdesk>

<https://www.wjgnet.com>

