

World Journal of *Clinical Cases*

World J Clin Cases 2022 September 26; 10(27): 9550-9969



Contents

Thrice Monthly Volume 10 Number 27 September 26, 2022

OPINION REVIEW

- 9550 Psychiatric disorders and pain: The recurrence of a comorbidity
Vyshka G

REVIEW

- 9556 Cardiovascular disease and COVID-19, a deadly combination: A review about direct and indirect impact of a pandemic
Vidal-Perez R, Brandão M, Pazdernik M, Kresoja KP, Carpenito M, Maeda S, Casado-Arroyo R, Muscoli S, Pöss J, Fontes-Carvalho R, Vazquez-Rodriguez JM
- 9573 Molecular factors, diagnosis and management of gastrointestinal tract neuroendocrine tumors: An update
Pavlidis ET, Pavlidis TE

MINIREVIEWS

- 9588 Human-induced pluripotent stem cell-atrial-specific cardiomyocytes and atrial fibrillation
Leowattana W, Leowattana T, Leowattana P
- 9602 COVID-19 and the cardiovascular system-current knowledge and future perspectives
Chatzis DG, Magounaki K, Pantazopoulos I, Bhaskar SMM

ORIGINAL ARTICLE

Case Control Study

- 9611 PDCA nursing in improving quality management efficacy in endoscopic submucosal dissection
He YH, Wang F

Retrospective Study

- 9619 Impact of COVID-19 pandemic on the ocular surface
Marta A, Marques JH, Almeida D, José D, Sousa P, Barbosa I
- 9628 Anatomy and clinical application of suprascapular nerve to accessory nerve transfer
Wang JW, Zhang WB, Li F, Fang X, Yi ZQ, Xu XL, Peng X, Zhang WG
- 9641 Therapeutic effect of two methods on avulsion fracture of tibial insertion of anterior cruciate ligament
Niu HM, Wang QC, Sun RZ
- 9650 Efficacy of transcatheter arterial chemoembolization using pirarubicin-loaded microspheres combined with lobaplatin for primary liver cancer
Zhang C, Dai YH, Lian SF, Liu L, Zhao T, Wen JY

- 9657** Prognostic significance of sex determining region Y-box 2, E-cadherin, and vimentin in esophageal squamous cell carcinoma

Li C, Ma YQ

- 9670** Clinical characteristics and prognosis of orbital solitary fibrous tumor in patients from a Chinese tertiary eye hospital

Ren MY, Li J, Wu YX, Li RM, Zhang C, Liu LM, Wang JJ, Gao Y

Observational Study

- 9680** Altered heart rate variability and pulse-wave velocity after spinal cord injury

Tsou HK, Shih KC, Lin YC, Li YM, Chen HY

- 9693** Intra and extra pelvic multidisciplinary surgical approach of retroperitoneal sarcoma: Case series report

Song H, Ahn JH, Jung Y, Woo JY, Cha J, Chung YG, Lee KH

META-ANALYSIS

- 9703** Meta-analysis of gemcitabine plus nab-paclitaxel combined with targeted agents in the treatment of metastatic pancreatic cancer

Li ZH, Ma YJ, Jia ZH, Weng YY, Zhang P, Zhu SJ, Wang F

- 9714** Clinical efficacy analysis of mesenchymal stem cell therapy in patients with COVID-19: A systematic review

Cao JX, You J, Wu LH, Luo K, Wang ZX

CASE REPORT

- 9727** Treatment of gastric cancer with dermatomyositis as the initial symptom: Two case reports and review of literature

Sun XF, Gao XD, Shen KT

- 9734** Gallbladder hemorrhage—An uncommon surgical emergency: A case report

Valenti MR, Cavallaro A, Di Vita M, Zanghi A, Longo Trischitta G, Cappellani A

- 9743** Successful treatment of stage IIIB intrahepatic cholangiocarcinoma using neoadjuvant therapy with the PD-1 inhibitor camrelizumab: A case report

Zhu SG, Li HB, Dai TX, Li H, Wang GY

- 9750** Myocarditis as an extraintestinal manifestation of ulcerative colitis: A case report and review of the literature

Wang YY, Shi W, Wang J, Li Y, Tian Z, Jiao Y

- 9760** Endovascular treatment of traumatic renal artery pseudoaneurysm with a Stanford type A intramural haematoma: A case report

Kim Y, Lee JY, Lee JS, Ye JB, Kim SH, Sul YH, Yoon SY, Choi JH, Choi H

- 9768** Histiocytoid giant cellulitis-like Sweet syndrome at the site of sternal aspiration: A case report and review of literature

Zhao DW, Ni J, Sun XL

- 9776** Rare giant corneal keloid presenting 26 years after trauma: A case report
Li S, Lei J, Wang YH, Xu XL, Yang K, Jie Y
- 9783** Efficacy evaluation of True Lift®, a nonsurgical facial ligament retightening injection technique: Two case reports
Huang P, Li CW, Yan YQ
- 9790** Synchronous primary duodenal papillary adenocarcinoma and gallbladder carcinoma: A case report and review of literature
Chen J, Zhu MY, Huang YH, Zhou ZC, Shen YY, Zhou Q, Fei MJ, Kong FC
- 9798** Solitary fibrous tumor of the renal pelvis: A case report
Liu M, Zheng C, Wang J, Wang JX, He L
- 9805** Gastric metastasis presenting as submucosa tumors from renal cell carcinoma: A case report
Chen WG, Shan GD, Zhu HT, Chen LH, Xu GQ
- 9814** Laparoscopic correction of hydronephrosis caused by left paraduodenal hernia in a child with cryptorchism: A case report
Wang X, Wu Y, Guan Y
- 9821** Diagnosed corrected transposition of great arteries after cesarean section: A case report
Ichii N, Kakinuma T, Fujikawa A, Takeda M, Ohta T, Kagimoto M, Kaneko A, Izumi R, Kakinuma K, Saito K, Maeyama A, Yanagida K, Takeshima N, Ohwada M
- 9828** Misdiagnosis of an elevated lesion in the esophagus: A case report
Ma XB, Ma HY, Jia XF, Wen FF, Liu CX
- 9834** Diagnostic features and therapeutic strategies for malignant paraganglioma in a patient: A case report
Gan L, Shen XD, Ren Y, Cui HX, Zhuang ZX
- 9845** Infant with reverse-transcription polymerase chain reaction confirmed COVID-19 and normal chest computed tomography: A case report
Ji GH, Li B, Wu ZC, Wang W, Xiong H
- 9851** Pulmonary hypertension secondary to seronegative rheumatoid arthritis overlapping antisynthetase syndrome: A case report
Huang CY, Lu MJ, Tian JH, Liu DS, Wu CY
- 9859** Monitored anesthesia care for craniotomy in a patient with Eisenmenger syndrome: A case report
Ri HS, Jeon Y
- 9865** Emergency treatment and anesthesia management of internal carotid artery injury during neurosurgery: Four case reports
Wang J, Peng YM

- 9873** Resolution of herpes zoster-induced small bowel pseudo-obstruction by epidural nerve block: A case report
Lin YC, Cui XG, Wu LZ, Zhou DQ, Zhou Q
- 9879** Accidental venous port placement *via* the persistent left superior vena cava: Two case reports
Zhou RN, Ma XB, Wang L, Kang HF
- 9886** Application of digital positioning guide plates for the surgical extraction of multiple impacted supernumerary teeth: A case report and review of literature
Wang Z, Zhao SY, He WS, Yu F, Shi SJ, Xia XL, Luo XX, Xiao YH
- 9897** Iatrogenic aortic dissection during right transradial intervention in a patient with aberrant right subclavian artery: A case report
Ha K, Jang AY, Shin YH, Lee J, Seo J, Lee SI, Kang WC, Suh SY
- 9904** Pneumomediastinum and subcutaneous emphysema secondary to dental extraction: Two case reports
Ye LY, Wang LF, Gao JX
- 9911** Hemorrhagic shock due to submucosal esophageal hematoma along with mallory-weiss syndrome: A case report
Oba J, Usuda D, Tsuge S, Sakurai R, Kawai K, Matsubara S, Tanaka R, Suzuki M, Takano H, Shimoizawa S, Hotchi Y, Usami K, Tokunaga S, Osugi I, Katou R, Ito S, Mishima K, Kondo A, Mizuno K, Takami H, Komatsu T, Nomura T, Sugita M
- 9921** Concurrent severe hepatotoxicity and agranulocytosis induced by *Polygonum multiflorum*: A case report
Shao YL, Ma CM, Wu JM, Guo FC, Zhang SC
- 9929** Transient ischemic attack after mRNA-based COVID-19 vaccination during pregnancy: A case report
Chang CH, Kao SP, Ding DC
- 9936** Drug-induced lung injury caused by acetaminophen in a Japanese woman: A case report
Fujii M, Kenzaka T
- 9945** Familial mitochondrial encephalomyopathy, lactic acidosis, and stroke-like episode syndrome: Three case reports
Yang X, Fu LJ
- 9954** Renal pseudoaneurysm after rigid ureteroscopic lithotripsy: A case report
Li YH, Lin YS, Hsu CY, Ou YC, Tung MC

LETTER TO THE EDITOR

- 9961** Role of traditional Chinese medicine in the initiative practice for health
Li Y, Li SY, Zhong Y
- 9964** Impact of the COVID-19 pandemic on healthcare workers' families
Helou M, El Osta N, Husni R

- 9967** Transition beyond the acute phase of the COVID-19 pandemic: Need to address the long-term health impacts of COVID-19

Tsioutis C, Tofarides A, Spernovasilis N

ABOUT COVER

Editorial Board Member of *World Journal of Clinical Cases*, Yusuf Tutar, PhD, Chairman, Director, Full Professor, Department of Basic Pharmaceutical Sciences, Division of Biochemistry, University of Health Sciences, Istanbul 34668, Turkey. ytutar@outlook.com

AIMS AND SCOPE

The primary aim of *World Journal of Clinical Cases* (WJCC, *World J Clin Cases*) is to provide scholars and readers from various fields of clinical medicine with a platform to publish high-quality clinical research articles and communicate their research findings online.

WJCC mainly publishes articles reporting research results and findings obtained in the field of clinical medicine and covering a wide range of topics, including case control studies, retrospective cohort studies, retrospective studies, clinical trials studies, observational studies, prospective studies, randomized controlled trials, randomized clinical trials, systematic reviews, meta-analysis, and case reports.

INDEXING/ABSTRACTING

The WJCC is now abstracted and indexed in Science Citation Index Expanded (SCIE, also known as SciSearch®), Journal Citation Reports/Science Edition, Current Contents®/Clinical Medicine, PubMed, PubMed Central, Scopus, Reference Citation Analysis, China National Knowledge Infrastructure, China Science and Technology Journal Database, and Superstar Journals Database. The 2022 Edition of Journal Citation Reports® cites the 2021 impact factor (IF) for WJCC as 1.534; IF without journal self cites: 1.491; 5-year IF: 1.599; Journal Citation Indicator: 0.28; Ranking: 135 among 172 journals in medicine, general and internal; and Quartile category: Q4. The WJCC's CiteScore for 2021 is 1.2 and Scopus CiteScore rank 2021: General Medicine is 443/826.

RESPONSIBLE EDITORS FOR THIS ISSUE

Production Editor: *Ying-Yi Yuan*; Production Department Director: *Xiang Li*; Editorial Office Director: *Jin-Lei Wang*.

NAME OF JOURNAL

World Journal of Clinical Cases

ISSN

ISSN 2307-8960 (online)

LAUNCH DATE

April 16, 2013

FREQUENCY

Thrice Monthly

EDITORS-IN-CHIEF

Bao-Gan Peng, Jerzy Tadeusz Chudek, George Kontogeorgos, Maurizio Serati, Ja Hyeon Ku

EDITORIAL BOARD MEMBERS

<https://www.wjgnet.com/2307-8960/editorialboard.htm>

PUBLICATION DATE

September 26, 2022

COPYRIGHT

© 2022 Baishideng Publishing Group Inc

INSTRUCTIONS TO AUTHORS

<https://www.wjgnet.com/bpg/gerinfo/204>

GUIDELINES FOR ETHICS DOCUMENTS

<https://www.wjgnet.com/bpg/GerInfo/287>

GUIDELINES FOR NON-NATIVE SPEAKERS OF ENGLISH

<https://www.wjgnet.com/bpg/gerinfo/240>

PUBLICATION ETHICS

<https://www.wjgnet.com/bpg/GerInfo/288>

PUBLICATION MISCONDUCT

<https://www.wjgnet.com/bpg/gerinfo/208>

ARTICLE PROCESSING CHARGE

<https://www.wjgnet.com/bpg/gerinfo/242>

STEPS FOR SUBMITTING MANUSCRIPTS

<https://www.wjgnet.com/bpg/GerInfo/239>

ONLINE SUBMISSION

<https://www.f6publishing.com>



Retrospective Study

Anatomy and clinical application of suprascapular nerve to accessory nerve transfer

Jian-Wei Wang, Wen-Bo Zhang, Fan Li, Xuan Fang, Zhi-Qiang Yi, Xiang-Liang Xu, Xin Peng, Wei-Guang Zhang

Specialty type: Anatomy and morphology

Provenance and peer review:

Unsolicited article; Externally peer reviewed.

Peer-review model: Single blind

Peer-review report's scientific quality classification

Grade A (Excellent): 0

Grade B (Very good): 0

Grade C (Good): C

Grade D (Fair): D

Grade E (Poor): 0

P-Reviewer: Ishigaki T, Japan; Liu J, United States

Received: April 6, 2022

Peer-review started: April 6, 2022

First decision: June 16, 2022

Revised: June 30, 2022

Accepted: August 21, 2022

Article in press: August 21, 2022

Published online: September 26, 2022



Jian-Wei Wang, Xuan Fang, Wei-Guang Zhang, Department of Anatomy, Histology and Embryology, School of Basic Medical Sciences, Peking University Health Science Center, Beijing 100191, China

Wen-Bo Zhang, Xiang-Liang Xu, Xin Peng, Department of Oral and Maxillofacial Surgery, National Center of Stomatology and National Clinical Research Center for Oral Diseases and National Engineering Research Center of Oral Biomaterials and Digital Medical Devices, Peking University School and Hospital of Stomatology, Beijing 100081, China

Fan Li, Department of Stomatology, Beijing Haidian Hospital, Beijing 100081, China

Zhi-Qiang Yi, Department of Neurosurgery, Peking University First Hospital, Beijing 100034, China

Corresponding author: Xiang-Liang Xu, PhD, Doctor, Department of Oral and Maxillofacial Surgery, National Center of Stomatology and National Clinical Research Center for Oral Diseases and National Engineering Research Center of Oral Biomaterials and Digital Medical Devices, Peking University School and Hospital of Stomatology, No. 22 Zhongguancun Nandajie, Haidian District, Beijing 100081, China. kqxxl@126.com

Abstract

BACKGROUND

Loss of motor function in the trapezius muscle is one complication of radical neck dissection after cutting the accessory nerve (AN) during surgery. Nerve repair is an effective method to restore trapezius muscle function, and includes neurolysis, direct suture, and nerve grafting. The suprascapular nerve (SCN) and AN are next to each other in position. The function of the AN and SCN in shoulder elevation and abduction movement is synergistic. SCN might be considered by surgeons for AN reanimation.

AIM

To obtain anatomical and clinical data for partial suprascapular nerve-to-AN transfer.

METHODS

Ten sides of cadavers perfused with formalin were obtained from the Department of Human Anatomy, Histology and Embryology, Peking University Health

Science Center. The SCN ($n = 10$) and AN ($n = 10$) were carefully dissected in the posterior triangle of the neck, and the trapezius muscle was dissected to fully display the accessory nerve. The length of the SCN from the origin of the brachial plexus (a point) to the scapular notch (b point) and the distance of the SCN from the origin point (a point) to the point (c point) where the AN entered the border of the trapezius muscle were measured. The length and branches of the AN in the trapezius muscle were measured. A female patient aged 55 years underwent surgery for partial SCN to AN transfer at Department of Oral and Maxillofacial Surgery, Peking University School and Hospital of Stomatology. The patient suffered from recurrent upper gingival cancer. Radical neck dissection was performed on the right side, and the right AN was removed at the intersection between the nerve and the posterior border of the SCM muscle. One-third of the diameter of the SCN was cut off, and combined epineurial and perineurial sutures were applied between the distal end of the cut-off fascicles of the SCN and the proximal end of the AN without tension. Both subjective and objective evaluations were performed before, three months after, and nine months after surgery. For the subjective evaluation, the questionnaire included the Neck Dissection Impairment Index (NDII) and the Constant Shoulder Scale. Electromyography was used for the objective examination. Data were analyzed using *t* tests with SPSS 19.0 software to determine the relationship between the length of the SCN and the linear distance. A *P* value of < 0.05 was considered as statistically significant.

RESULTS

The whole length of the AN in the trapezius muscle was 16.89 cm. The average numbers of branches distributed in the descending, horizontal and ascending portions were 3.8, 2.6 and 2.2, respectively. The diameter of the AN was 1.94 mm at the anterior border of the trapezius. The length of the suprascapular nerve from the origin of the brachial plexus to the scapular notch was longer than the distance of the suprascapular nerve from the origin point to the point where the accessory nerve entered the upper edge of the trapezius muscle. The amplitude of trapezius muscle electromyography indicated that both the horizontal and ascending portions of the trapezius muscle on the right side had better function than the left side nine months after surgery. The results showed that the right-sided supraspinatus and infraspinatus muscles did not lose more function than the left side.

CONCLUSION

Based on anatomical data and clinical application, partial suprascapular nerve-to-AN transfer could be achieved and may improve innervation of the affected trapezius muscle after radical neck dissection.

Key Words: Suprascapular nerve; Accessory nerve; Nerve transfer; Trapezius; Supraspinatus; Infraspinatus

©The Author(s) 2022. Published by Baishideng Publishing Group Inc. All rights reserved.

Core Tip: We performed the dissection and measurement of ten sides of cadavers to obtain the data of the suprascapular nerve and accessory nerve. In the posterior cervical triangle, we found that the suprascapular nerve could obtain enough nerve length, from its origin to the suprascapular notch, to perform suprascapular nerve-accessory nerve partial nerve transplantation and achieve tension-free suture, suggesting the feasibility of transplantation of the suprascapular nerve as a donor. Nerve transfer from the partial suprascapular nerve to the accessory nerve was performed on one patient, and electromyography examinations were performed three months and nine months after surgery. Our research showed that suprascapular nerve transfer may improve trapezius muscle function and reduce loss of function in the supraspinatus and infraspinatus muscles after suprascapular nerve transfer.

Citation: Wang JW, Zhang WB, Li F, Fang X, Yi ZQ, Xu XL, Peng X, Zhang WG. Anatomy and clinical application of suprascapular nerve to accessory nerve transfer. *World J Clin Cases* 2022; 10(27): 9628-9640

URL: <https://www.wjgnet.com/2307-8960/full/v10/i27/9628.htm>

DOI: <https://dx.doi.org/10.12998/wjcc.v10.i27.9628>

INTRODUCTION

Iatrogenic injury is one of the major causes of human nerve injury. Approximately 94% of accessory nerve (AN) injuries are iatrogenic[1,2]. Injury to the AN can cause weakness or paralysis in the sternocl-

oidomastoid (SCM) and trapezius muscles[3]. Loss of motor function in the trapezius muscle leads to a painful and disabling condition[2], and this syndrome is frequently observed after radical neck dissection. Pain and dysfunction associated with a loss of innervation by the AN have been reported[4, 5].

Anatomic information and the precise position of the AN are very important for the protection of the AN during surgery. AN is generally accepted as being a motor nerve. It mainly innervates the sternocleidomastoid and trapezius muscles. AN is classically described as having a spinal root and a cranial root. The spinal root originates from the spinal nucleus of cervical vertebrae C1 to C5. The cranial root originates from the dorsolateral surface of the medulla oblongata. The spinal and cranial roots merge into a total stem and exit the skull. Then, it passes through the posterior cervical triangle, lateral to the vagus nerve, ahead of the internal jugular vein (IJV), while sending out muscle branches to the SCM and the trapezius muscle. In the posterior cervical triangle region, its position is relatively superficial and vulnerable to injury[6,7]. Previous studies have shown that the AN passes through the SCM in three ways[8]. In addition to AN, one study showed that the branches of the cervical plexus that join the main AN or separate branches innervated the trapezius muscle[9], which are conducive to the protection of the AN or other branch nerves and the function of the trapezius muscle during surgery.

Current surgical treatment for trapezius paralysis mainly includes two strategies. First, fascial muscle transplantation mainly includes static and dynamic transplantation. A static procedure involves fixing the scapula to the spinous process by fascia transplantation, but it could lead to weakened fascia due to prolonged stretching. The dynamic approach is used to restore the function of the scapula through muscle transfer[2]. Another surgical strategy is nerve repair[10,11], which includes neurolysis, direct suture, and nerve grafting. A key point in nerve transplantation for the treatment of trapezius paralysis is finding the appropriate donor nerves. It has been reported that trapezius muscle function can be restored by directly transplanting a nerve in the upper trunk of the brachial plexus and suturing the distal end of the AN[12]. According to Tubbs's anatomical study, the suprascapular nerve (SCN) could be used as a donor nerve for nerve repair[13]. SCN mainly originates from the C5, C6, and occasionally C4 nerve roots. It contains motor and sensory nerve fibers. It walks in the posterior triangle of the neck, passes through the scapular notch and walks on the back of the scapula. Its main function is motor innervation of the supraspinatus and infraspinatus muscles. In addition, it also sends out sensory branches to the acromioclavicular and glenohumeral joints and the coracoacromial ligament[14]. The accessory nerve and suprascapular nerve are adjacent to each other and have similar functions. To further explore the feasibility of transplanting the suprascapular nerve as a donor nerve to the accessory nerve to restore trapezius muscle function, we conducted exploratory studies of both human anatomy and clinical application.

MATERIALS AND METHODS

Cadavers for research

Ten sides of cadavers perfused with formalin through the femoral artery were obtained from the Department of Human Anatomy, Histology and Embryology, Peking University Health Science Center. This study was approved by the Peking University Institutional Review Board (IRB00001052-21011-Exempt). The age range of cadavers was 60-80 years. All cadavers had no visible scars, deformities, or obvious trauma to the face, neck, or shoulders.

Cadaveric dissection

Cadavers were dissected, and the SCN ($n = 10$) and AN ($n = 10$) at the lateral cervical region were exposed. The SCN and AN were carefully dissected in the posterior triangle of the neck as follows. First, the SCM was exposed after removing the superficial tissue. Second, the SCN from C5 of the brachial plexus could be found beneath and close to the lower belly of the omohyoid muscle, and AN emerges in the posterior triangle at the anterior margin of the trapezius (Figure 1). Third, the SCM was elevated, beneath which we found the accessory nerve at the anterior edge of the trapezius muscle and the suprascapular nerve from the beginning to the scapular notch segment (Figures 2 and 3). Fourth, the trapezius muscle was dissected to fully display the accessory nerve (Figure 4).

Measurements

The length and branches of the AN in the trapezius muscle, the length of the SCN from the origin of the brachial plexus (a point, Figure 2) to the scapular notch (b point, Figure 2), and the distance of the SCN from the origin point (a point, Figure 2) to the point (c point, Figure 3) where the AN entered the border of the trapezius muscle were measured.

The length and branches of the AN in the trapezius muscle were measured. The trapezius muscle was divided into three portions: The descending portion, horizontal portion, and ascending portion. The division was based on two horizontal lines: one was through the vertex of the angle between the acromion and the spine of the scapula at the lateral dorsal edge of the scapula, and the other was through the uppermost edge of the plane of the deltoid tubercle at the medial edge of the scapula

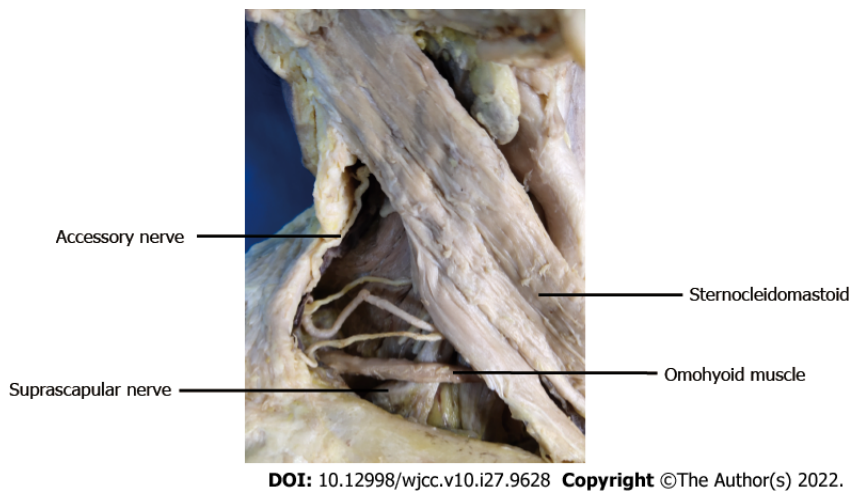


Figure 1 The suprascapular nerve beneath the lower belly of the omohyoid muscle.

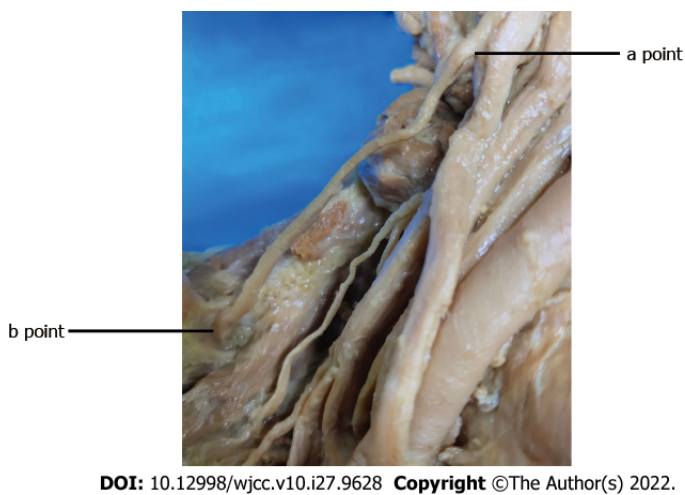


Figure 2 Suprascapular nerve from the origin of the brachial plexus (a point) to the scapular notch (b point).

(Figure 4). We measured the number of branches of the accessory nerve in three portions. A branch whose diameter was less than 0.5 mm was considered as the end branch and was no longer dissected.

Data analysis

Data were analyzed using *t* tests with SPSS 19.0 software to determine the relationship between the length of the SCN and the linear distance. A *P* value of < 0.05 was considered as statistically significant.

Clinical application

A female patient aged 55 years underwent surgery for partial SCN to AN transfer at Department of Oral and Maxillofacial Surgery, Peking University School, and Hospital of Stomatology. All procedures were approved by the Biomedical Ethics Committee of Peking University School and Hospital of Stomatology (PKUSSIRB-2013040). The patient suffered from recurrent upper gingival cancer, which demonstrated lymphatic metastasis in the right cervical region. Radical neck dissection in cervical regions I, II, III, IV, and V was performed on the right side, and the SCM muscle was removed. On the left side, selective neck dissection in cervical regions I, II, and III was performed without AN injury. The right AN was removed at the intersection between the nerve and the posterior border of the SCM muscle. The SCN was dissected along the branch of the brachial plexus. Groups of fascicles of the SCN were identified. One-third of the diameter of the SCN was cut off, and combined epineurial and perineurial sutures were applied between the distal end of the cut-off fascicles of the SCN and the proximal end of the AN without tension (Figures 5 and 6). Nylon suture (8-0) was used for nerve transfer.

Both subjective and objective evaluations were performed before, three months after, and nine months after surgery. For the subjective evaluation, the questionnaire included the Neck Dissection Impairment Index (NDII) and the Constant Shoulder Scale[15,16]. Thirty-five points on the Constant Shoulder Scale were recorded in this section. For the objective evaluation, two methods were used. One

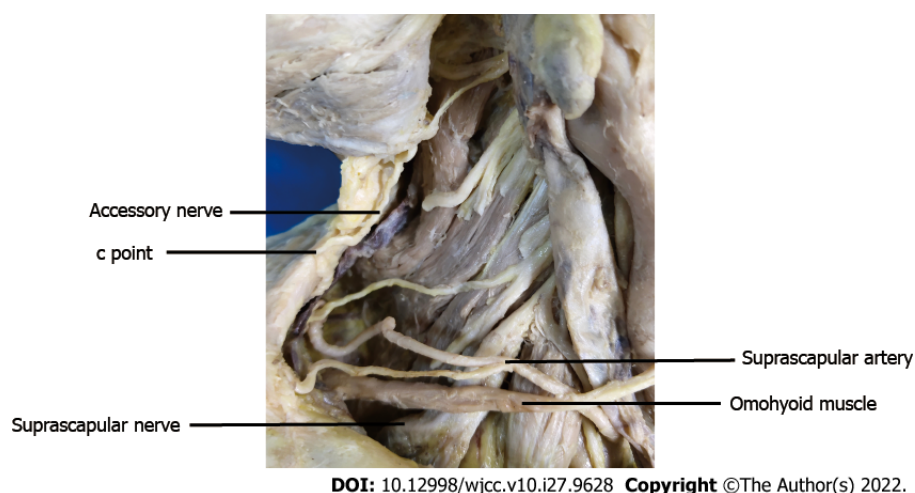


Figure 3 Relationship between the suprascapular nerve and the accessory nerve. c point was referring to the position where accessory nerve entered into the border of the trapezius muscle.

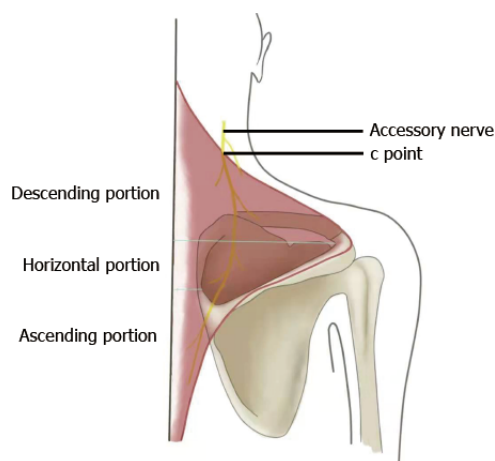


Figure 4 Schematic diagram of distribution of accessory nerve in trapezius muscle.

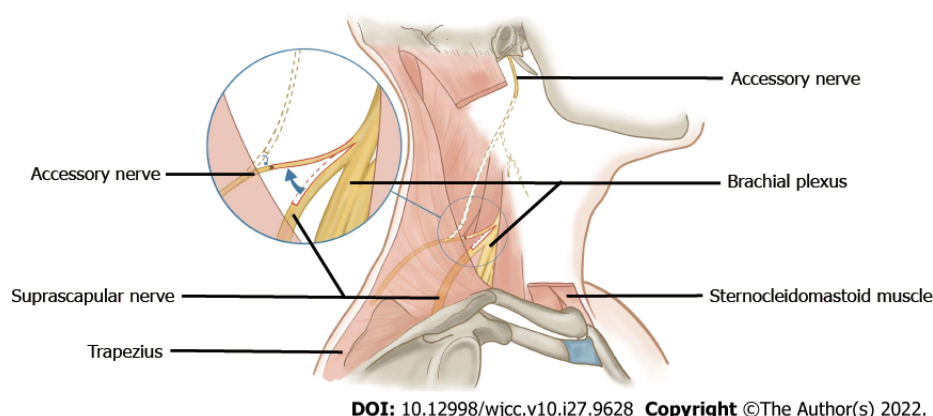
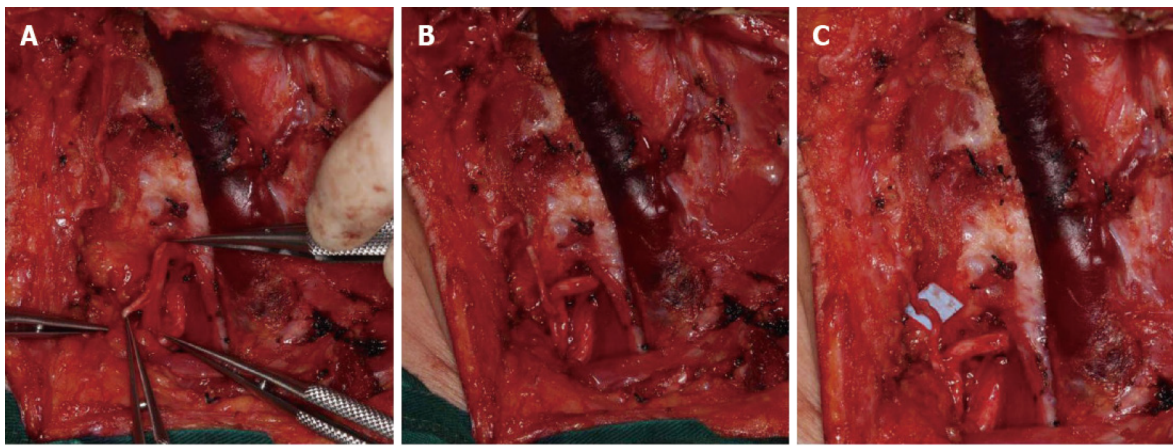


Figure 5 Schematic diagram of anastomosis between the proximal stump of the accessory nerve and the suprascapular nerve.

was to examine the movement of the shoulder and upper arm and record the 65 points of objective evaluation using the Constant Shoulder Scale before, three months after, and nine months after surgery. Another was to carry out electromyography of the trapezius, supraspinatus, and infraspinatus muscles before, three months after, and nine months after surgery. Electromyography (Dentec Keypoint, Natus Medical Incorporated, Denmark) was used for the examination. The descending, horizontal, and



DOI: 10.12998/wjcc.v10.i27.9628 Copyright ©The Author(s) 2022.

Figure 6 Transfer procedure between the suprascapular nerve and the proximal stump of accessory nerve. A: One third of the diameter of the suprascapular nerve (SCN) was dissected; B: The nerve was cut off and put next to the proximal stump of accessory nerve (AN); C: The two stumps of AN and SCN were sutured with nylon suture (8-0).

ascending parts of the trapezius muscle were detected in this study according to the method used by Krause *et al*[17]. The middle was placed at the line from the level of the second thoracic vertebra to the suprascapular angle, 3 cm from the longitudinal axis of the spine. The ascending portion was placed at the horizontal line of the inferior corner of the shoulder, 3 cm from the longitudinal axis of the spine. During examination of the trapezius muscle, electromyography was performed when the patient shrugged shoulders and closed shoulder blades with maximum strength and abducted the upper arm to 90° for two seconds. For supraspinatus and infraspinatus electromyography, external rotation of the upper arm around the humerus bone with maximum strength and abduction of the upper arm to 90° for two seconds were performed. Surface electrodes were placed on the supraspinatus and infraspinatus just above and below the scapular spine and at the middle of the supraspinous and infraspinous fossa of the scapula, respectively[18,19]. The ratio, R, of the amplitude of electromyography before and after surgery was calculated as follows:

$R = (\text{amplitude of EMG before surgery} - \text{amplitude of EMG after surgery}) / \text{amplitude of EMG before surgery}$.

The range of R was 0–1. The lower the value, or the closer it was to 0, the smaller the degree of loss of muscle function.

RESULTS

The anatomic data of SCN and AN

The length of the SCN from the origin of the brachial plexus (a point, Figure 3) to the scapular notch (b point, Figure 3) was approximately 5.64 ± 0.78 cm ($n = 10$). The linear distance from the SCN origin point (a point, Figure 3) to the point (c point, Figure 2) where the AN entered the border of the trapezius muscle was approximately 4.30 ± 0.79 cm ($n = 10$). The length of the SCN from the origin of the brachial plexus to the scapular notch (a-b) was longer than the linear distance (a-c) between two points ($P < 0.01$) (Table 1).

The whole length of the AN in the trapezius muscle was 16.89 cm, with a length range of 12.70–20.50 cm. The average number of branches distributed in the descending portion was 2.6 with a number range of 0–5; the average number of branches distributed in the horizontal portion was 2.6 with a number range of 1–4; and the average number of branches distributed in the ascending portion was 2.2 with a number range of 1–4. There were still 1.2 branches with a number range of 0–3 distributed in the descending portion before the AN entered into the trapezius muscle. Therefore, there were 3.8 branches distributed in the descending portion of the trapezius muscle.

The clinical outcomes of nerve transfer surgery

The NDII of the patient was 37.5 points three months and 47.5 points nine months after surgery. The results of the CMS are shown in Table 2 and suggested that shoulder function recovered better at nine months after surgery than at three months. The amplitudes of electromyography of the trapezius, supraspinatus and infraspinatus muscles are shown in Tables 3 and 4. Even though muscle function did not recover completely three months and nine months after surgery, more function was regained within nine months than in three months. Excluding the descending portion, both the horizontal and ascending portions of the right-sided trapezius muscle had larger amplitudes than the left side nine months after

Table 1 The measurements of a-b and a-c

	(mean \pm SD, cm)	P (95%CI)
a-b	5.64 \pm 0.78	< 0.01
a-c	4.30 \pm 0.79	

SD: Standard deviation; CI: Confidence interval.

Table 2 Results of Constant's Shoulder Scale

	Subjective evaluation		Objective evaluation	
	Left	Right	Left	Right
Before surgery	27	27	63	63
Three months after surgery	22	21	25	23
Nine months after surgery	26	23	48	46

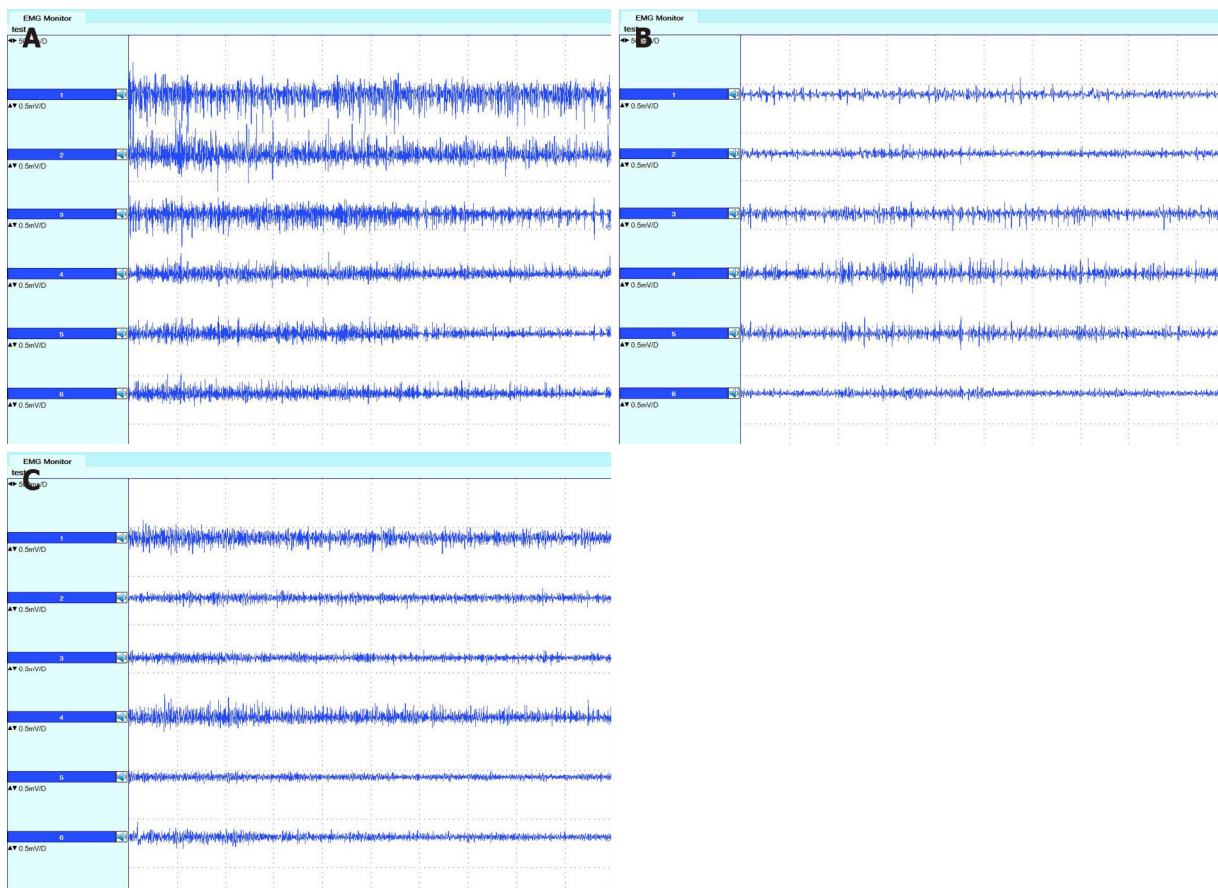
Table 3 Amplitude of electromyographic and the ratio R of the trapezius

	Left side			Right side		
	Descending portion	Horizontal portion	Ascending portion	Descending portion	Horizontal portion	Ascending portion
Before surgery	288.25	260.67	187.33	278.00	186.00	182.67
Three months after surgery	130.00	135.25	132.50	125.25	141.25	124.50
R _{3m}	0.55	0.48	0.29	0.55	0.24	0.32
Nine months after surgery	182.35	138.16	129.36	139.15	179.38	140.57
R _{9m}	0.37	0.47	0.31	0.50	0.04	0.23

Table 4 Amplitude of electromyographic and the ratio R of the supraspinatus and infraspinatus

	Left side		Right side	
	Supraspinatus	Infraspinatus	Supraspinatus	Infraspinatus
Before surgery	423.75	267.33	183.00	181.33
Three months after surgery	189.50	245.75	181.25	170.00
R _{3m}	0.55	0.08	0.01	0.06
Nine months after surgery	170.28	253.46	172.33	175.30
R _{9m}	0.60	0.05	0.06	0.03

surgery, which demonstrates the effect of SCN transfer in this patient. The amplitude of right-sided supraspinatus and infraspinatus electromyography revealed that the right side did not lose more function than the left side three months and nine months after surgery, which indicates less loss of function in the supraspinatus and infraspinatus muscles after SCN transfer. Electromyographs of the trapezius, supraspinatus, and infraspinatus muscles are shown in Figures 7 and 8. The results are similar to the amplitude of the muscles demonstrated in Tables 3 and 4. The patient's clinical manifestation of upper limb movement is shown in Figure 9, which indicates similar recovery behavior between the right and left sides.



DOI: 10.12998/wjcc.v10.i27.9628 Copyright ©The Author(s) 2022.

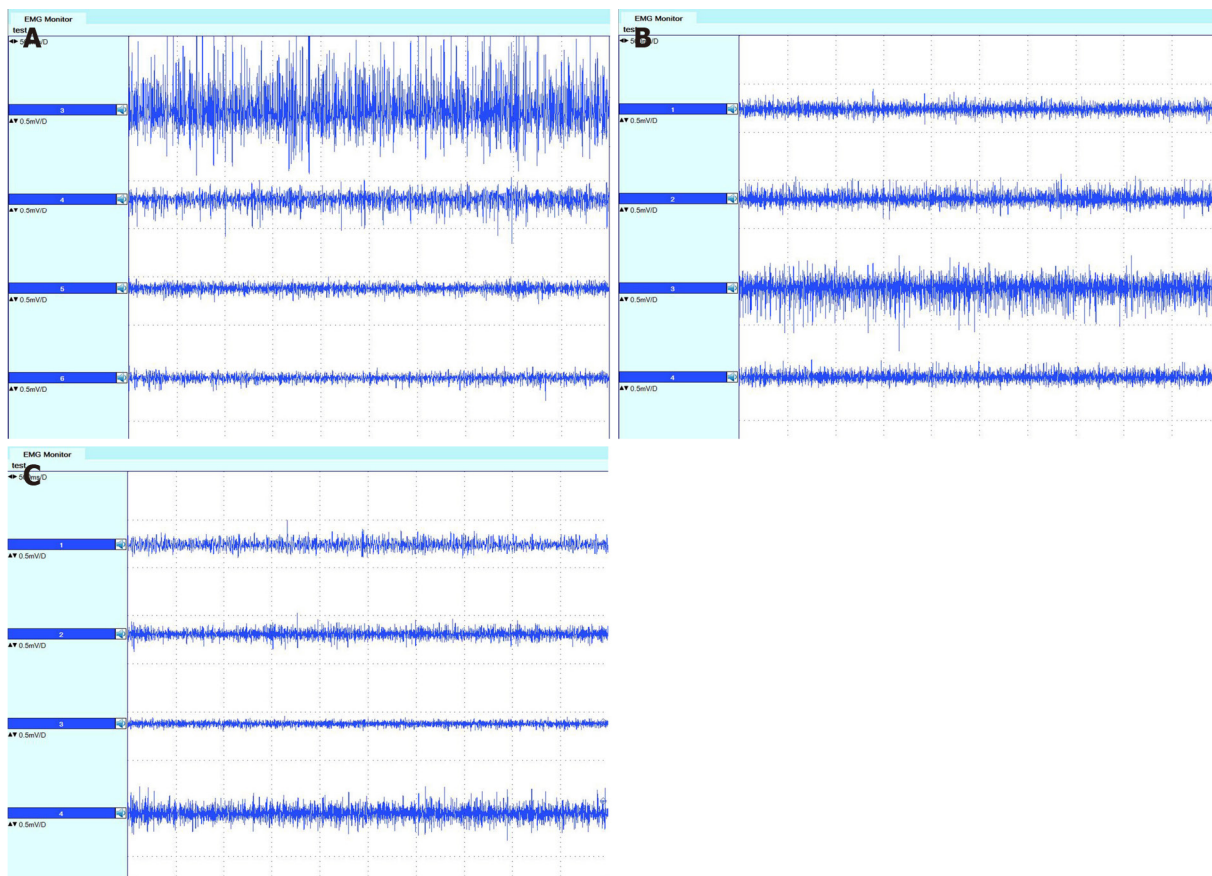
Figure 7 Electromyographs of the trapezius muscle. A: Before surgery; B: Three months after surgery; C: Nine months after surgery. Electromyographs from top to bottom show the results of the descending portion on the left side, the descending portion on the right side, the horizontal portion on the left side, the horizontal portion on the right side, the ascending portion on the left side, and the horizontal portion on the right side, respectively.

DISCUSSION

The spinal AN would usually be sacrificed during radical neck dissection. Therefore, trapezius muscle paralysis often results in destabilization and dropping of the shoulder girdle[20]. Several patients experience severe upper extremity impairment with deficits in functional movement and continuous shoulder pain[21].

Understanding the anatomical information of the accessory nerve is very important in protecting the accessory nerve during neck dissection. Some studies have disclosed the anatomy of the accessory nerve in detail. Shiozaki *et al*[8] found that the AN passed through the SCM in three ways. Another study showed that the branches of the cervical plexus that join the main AN or separate branches innervated the trapezius muscle[9]. There have also been some studies revealing the relationship between AN and the IJV[7,22]. The results of these studies[7-9,22] were conducive to the protection of the AN or other branch nerves and the function of the trapezius muscle during surgery.

There are several approaches to repair the injured AN, including nerve transfer from the upper trunk [12], which is much thicker than the SCN. Taking a fascicle from the upper trunk might cause more side effects than the SCN. Considering the number of myelinated axons, with 6004 for the SCN and 1500-3000 for the AN, partially splitting the SCN could be used to transfer to the distal stump of the AN[23, 24]. The SCN could be an attractive substitute donor for some nerve graft procedures. Lanisnik *et al*[25] found that the AN could give off the branches before entering the SCM muscle and joining the cervical plexus at the posterior part of the SCM muscle in some cases. The function of the AN and SCN in shoulder elevation and abduction movement is synergistic. This synergistic function implied that SCN could be an alternative donor nerve to restore AN function. Tubbs *et al*[13] reported a cadaveric study related to the SCN connection with the facial nerve. They measured the length and diameter of the SCN in 10 human cadavers. They believed that using the SCN might be considered by surgeons for facial nerve reanimation. In addition, parts of the SCN and AN are located in the same region of the neck[26]. They are next to each other in position, which is conducive to nerve transplantation to achieve no tension suture. We found that the length of the a-b segment of SCN was significantly greater than the distance length of the a-c segment. This result indicated that a sufficient suprascapular nerve length could be achieved to realize a tension-free suture during the SCN-AN partial nerve transplantation



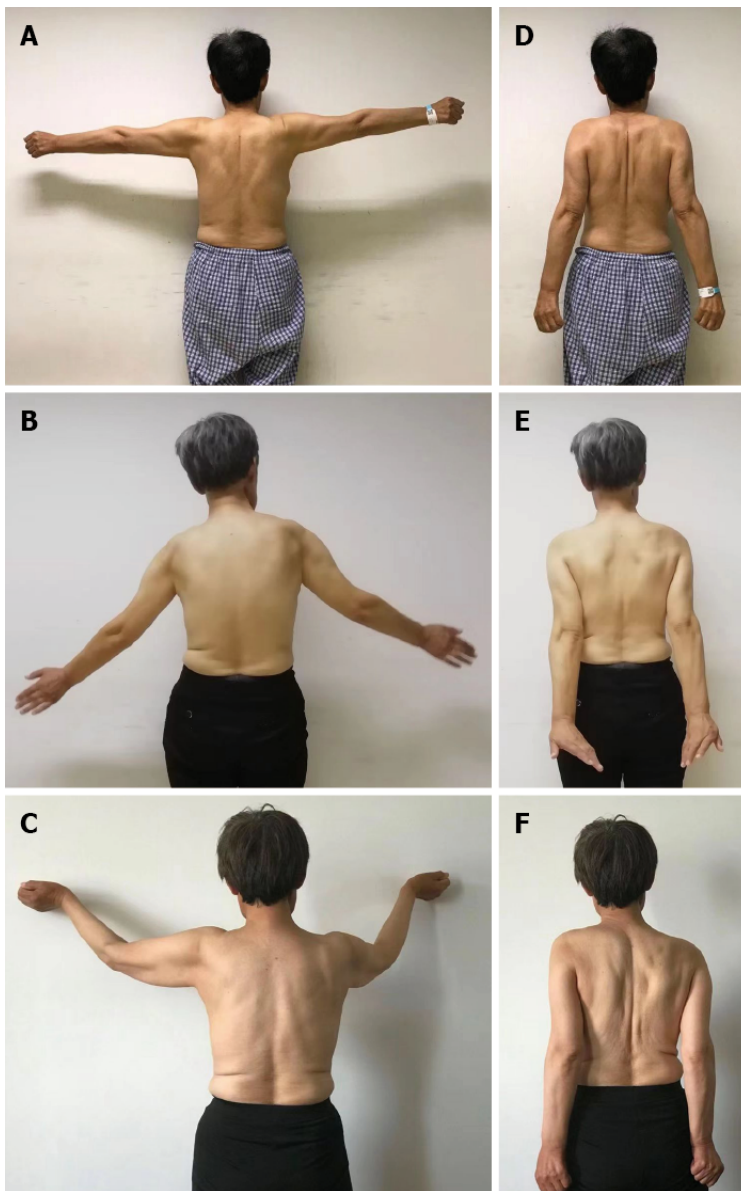
DOI: 10.12998/wjcc.v10.i27.9628 Copyright ©The Author(s) 2022.

Figure 8 Electromyographs of the supraspinatus and infraspinatus muscles. A: Before surgery; B: Three months after surgery; C: Nine months after surgery. Electromyographs from top to bottom show the results of the supraspinatus on the left side, supraspinatus on the right side, infraspinatus on the left side, and infraspinatus on the right side, respectively.

procedure. The a-b segment of SCN was chosen because the other part of the SCN was covered by the supraspinatus and infraspinatus muscles, which would increase the difficulty of surgical exposure. In the present study, the SCN was split longitudinally, and partial nerve transfer was performed in one patient. The results of clinical outcomes showed that supraspinatus and infraspinatus muscle function were not affected much three and nine months after surgery.

AN to SCN transfer has been proven to be a valid strategy to repair nerve injury[27-30]. The AN could be used as a donor nerve in brachial plexus injury, especially injury to the SCN[31]. One advantage of transfer between these two nerves is the greater proximity to the muscle to be reinnervated[30]. Although transfer from the AN to the SCN does not completely recover the strength of the shoulder, it still improves pain control and shoulder stability[32]. Bertelli and Ghizoni described a unique approach to identify and harvest the AN for nerve transfer in brachial plexus injuries[33]. These studies indicated that the spinal AN had a similar histological compatibility with the SCN[27-33]. Therefore, the SCN could be a suitable donor to recover AN function when iatrogenic injury or resection occurs during surgery.

Although the results showed that the descending portion of the right trapezius muscle did not recover better than the left side, the electromyography results indicated that the horizontal and ascending portions on the right side had larger amplitudes than those on the left side nine months after surgery. The possible reason for this result is that SCN transfer improved trapezius muscle innervation. Meanwhile, partial nerve transfer maintained the original function of the supraspinatus and infraspinatus muscles in the patient. Therefore, shoulder function was enhanced. The trapezius muscle is the main dominant nerve of the AN. There are also C2-C4 nerve branches into the AN trunk or directly into the trapezius muscle. However, the location of the branches from the cervical nerve is often not constant. Some branches may contain sensory nerves, and even play a role in the innervation of the trapezius muscle[9]. Therefore, partial SCN transfer was not the only factor that improved the amplitude of the trapezius muscle. The feature of this SCN transfer is “partial”, which does not completely sacrifice the SCN and maintains the function of the nerve. In addition, neck dissection can expose the SCN well, which is one benefit of this technique. However, the evidence for clinical promotion was insufficient in our study due to the limited number of clinical cases performed.



DOI: 10.12998/wjcc.v10.i27.9628 Copyright ©The Author(s) 2022.

Figure 9 The patient's clinical manifestation of upper limb movement. A and D: Before surgery; B and E: Three months after surgery; C and F: Nine months after surgery. The panels A-C showed the movement of abduction of the upper arms, and the panels D-F showed the movement of external rotation of the upper arms.

CONCLUSION

Based on anatomical data and clinical application, partial suprascapular nerve-to-accessory nerve transfer could be achieved and may improve shoulder function after radical neck dissection. Further basic research and clinical evidence are necessary to elaborate on the findings presented in this study.

ARTICLE HIGHLIGHTS

Research background

Injury to the accessory nerve (AN) can cause weakness or paralysis in the sternocleidomastoid (SCM) and trapezius muscles. Loss of motor function in the trapezius muscle leads to a painful and disabling condition. This syndrome is frequently observed after radical neck dissection. Current surgical treatment for trapezius paralysis mainly includes two strategies. The first is fascial muscle transplantation, which mainly includes static and dynamic transplantation. Another surgical strategy is nerve repair, which includes neurolysis, direct suture, and nerve grafting.

Research motivation

A key point in nerve transplantation for the treatment of trapezius paralysis is finding the appropriate donor nerves. It has been reported that trapezius muscle function can be restored by directly transplanting a nerve in the upper trunk of the brachial plexus and suturing the distal end of the AN. According to Tubbs's anatomical study, the suprascapular nerve (SCN) could be used as a donor nerve for nerve repair.

Research objectives

To further explore the feasibility of transplanting the suprascapular nerve as a donor nerve to the accessory nerve to restore trapezius muscle function, we conducted exploratory studies of both human anatomy and clinical application.

Research methods

Based on the dissection of ten sides of cadavers, the length of the SCN ($n = 10$) from the origin of the brachial plexus (a point) to the scapular notch (b point) and the distance of the SCN from the origin point (a point) to the point (c point) where the AN entered the border of the trapezius muscle were measured. The length and branches of the AN ($n = 10$) in the trapezius muscle were measured. A female patient aged 55 years underwent surgery for partial SCN to AN transfer. One-third of the diameter of the SCN was cut off, and combined epineurial and perineurial sutures were applied between the distal end of the cut-off fascicles of the SCN and the proximal end of the AN without tension. Both subjective and objective evaluations were performed before, three months after, and nine months after surgery.

Research results

The whole length of the AN in the trapezius muscle was 16.89 cm. The average numbers of branches distributed in the descending, horizontal and ascending portions were 3.8, 2.6 and 2.2, respectively. The diameter of the AN was 1.94 mm at the anterior border of the trapezius. The length of the suprascapular nerve from the origin of the brachial plexus to the scapular notch was longer than the distance of the suprascapular nerve from the origin point to the point where the accessory nerve entered the upper edge of the trapezius muscle. The amplitude of trapezius muscle electromyography indicated that both the horizontal and ascending portions of the trapezius muscle on the right side had better function than the left side nine months after surgery. The results showed that the right-sided supraspinatus and infraspinatus muscles did not lose more function than the left side.

Research conclusions

Based on anatomical data and clinical application, partial suprascapular nerve-to-AN transfer could be achieved and may improve innervation of the affected trapezius muscle after radical neck dissection.

Research perspectives

The suprascapular nerve could be used as a donor nerve for nerve repair according to the anatomical measurements and clinical findings in our study.

FOOTNOTES

Author contributions: Xu XL and Wang JW were the main performers of the research and completed the manuscript writing; Xu XL were also responsible for the overall project coordination; Zhang WB, Li F and Peng X participated in the investigation and surgery; Fang X participated in the image design; and Yi ZQ and Zhang WG participated in the method research.

Supported by Beijing Municipal Science and Technology Commission, No. Z201100005520055; and Education Research Project of Peking University School and Hospital of Stomatology, No. 2013-ZD-03.

Institutional review board statement: This study was approved by the Peking University Institutional Review Board (No. IRB00001052-21011-Exempt). Clinical practice was approved by the Biomedical Ethics Committee of Peking University School and Hospital of Stomatology (No. PKUSSIRB-2013040).

Informed consent statement: Informed written consent was obtained from the patient.

Conflict-of-interest statement: All authors report no relevant conflict of interest for this article.

Data sharing statement: The data is available from the corresponding author at kqxxl@126.com.

Open-Access: This article is an open-access article that was selected by an in-house editor and fully peer-reviewed by external reviewers. It is distributed in accordance with the Creative Commons Attribution NonCommercial (CC BY-NC 4.0) license, which permits others to distribute, remix, adapt, build upon this work non-commercially, and license

their derivative works on different terms, provided the original work is properly cited and the use is non-commercial. See: <https://creativecommons.org/licenses/by-nc/4.0/>

Country/Territory of origin: China

ORCID number: Jian-Wei Wang 0000-0002-8609-2000; Wen-Bo Zhang 0000-0002-2909-3525; Fan Li 0000-0002-0881-8945; Xuan Fang 0000-0002-7705-6139; Zhi-Qiang Yi 0000-0003-3837-5847; Xiang-Liang Xu 0000-0002-1201-2768; Xin Peng 0000-0001-8535-1771; Wei-Guang Zhang 0000-0001-5055-4907.

S-Editor: Wu YXJ

L-Editor: A

P-Editor: Wu YXJ

REFERENCES

- 1 **Kim DH**, Cho YJ, Tiel RL, Kline DG. Surgical outcomes of 111 spinal accessory nerve injuries. *Neurosurgery* 2003; **53**: 1106-1112; discussion 1102 [PMID: 14580277 DOI: 10.1227/01.neu.0000089058.82201.3d]
- 2 **Wiater JM**, Bigliani LU. Spinal accessory nerve injury. *Clin Orthop Relat Res* 1999; **5**: 5-16 [PMID: 10613148 DOI: 10.1097/00003086-199911000-00003]
- 3 **Lloyd S**. Accessory nerve: anatomy and surgical identification. *J Laryngol Otol* 2007; **121**: 1118-1125 [PMID: 17892604 DOI: 10.1017/S0022215107000461]
- 4 **Nahum AM**, Mullally W, Marmor L. A syndrome resulting from radical neck dissection. *Arch Otolaryngol* 1961; **74**: 424-428 [PMID: 14477989 DOI: 10.1001/archotol.1961.00740030433011]
- 5 **Leipzig B**, Suen JY, English JL, Barnes J, Hooper M. Functional evaluation of the spinal accessory nerve after neck dissection. *Am J Surg* 1983; **146**: 526-530 [PMID: 6625099 DOI: 10.1016/0002-9610(83)90246-5]
- 6 **Overland J**, Hodge JC, Breik O, Krishnan S. Surgical anatomy of the spinal accessory nerve: review of the literature and case report of a rare anatomical variant. *J Laryngol Otol* 2016; **130**: 969-972 [PMID: 27268496 DOI: 10.1017/S0022215116008148]
- 7 **Anehosur V**, Kulkarni K, Kumar N. Variations in the Anatomy of Spinal Accessory Nerve and its Landmarks for Identification in Neck Dissection: A Clinical Study. *J Maxillofac Oral Surg* 2021; **20**: 426-431 [PMID: 34408369 DOI: 10.1007/s12663-021-01542-z]
- 8 **Shiozaki K**, Abe S, Agematsu H, Mitarashi S, Sakiyama K, Hashimoto M, Ide Y. Anatomical study of accessory nerve innervation relating to functional neck dissection. *J Oral Maxillofac Surg* 2007; **65**: 22-29 [PMID: 17174759 DOI: 10.1016/j.joms.2005.11.091]
- 9 **Pu YM**, Tang EY, Yang XD. Trapezius muscle innervation from the spinal accessory nerve and branches of the cervical plexus. *Int J Oral Maxillofac Surg* 2008; **37**: 567-572 [PMID: 18346876 DOI: 10.1016/j.ijom.2008.02.002]
- 10 **Anderson R**, Flowers RS. Free grafts of the spinal accessory nerve during radical neck dissection. *Am J Surg* 1969; **118**: 796-799 [PMID: 5347096 DOI: 10.1016/0002-9610(69)90232-3]
- 11 **Vastamäki M**, Solonen KA. Accessory nerve injury. *Acta Orthop Scand* 1984; **55**: 296-299 [PMID: 6741478 DOI: 10.3109/17453678408992360]
- 12 **Cambon-Binder A**, Preure L, Dubert-Khalifa H, Marcheix PS, Belkheyar Z. Spinal accessory nerve repair using a direct nerve transfer from the upper trunk: results with 2 years follow-up. *J Hand Surg Eur Vol* 2018; **43**: 589-595 [PMID: 29433411 DOI: 10.1177/1753193418755618]
- 13 **Tubbs RS**, Louis RG Jr, Wartmann CT, Loukas M, Shojja MM, Ardan MR, Oakes WJ. Suprascapular nerve as a donor for extracranial facial nerve reanimation procedures: a cadaveric feasibility study. *J Neurosurg* 2008; **108**: 145-148 [PMID: 18173324 DOI: 10.3171/JNS/2008/108/01/0145]
- 14 **Michael C**, MHS Bhargavi Maheshwer, Nikhil N Verma. Suprascapular Neuropathy. *Operative Techniques in Sports Medicine* 2021; **29**: 1-6 [DOI: 10.1016/j.otsm.2021.150803]
- 15 **Taylor RJ**, Chepeha JC, Teknos TN, Bradford CR, Sharma PK, Terrell JE, Hogikyan ND, Wolf GT, Chepeha DB. Development and validation of the neck dissection impairment index: a quality of life measure. *Arch Otolaryngol Head Neck Surg* 2002; **128**: 44-49 [PMID: 11784253 DOI: 10.1001/archotol.128.1.44]
- 16 **Constant CR**, Murley AH. A clinical method of functional assessment of the shoulder. *Clin Orthop Relat Res* 1987; **160**: 164 [PMID: 3791738 DOI: 10.1097/00003086-198701000-00023]
- 17 **Krause HR**, Bremerich A, Herrmann M. The innervation of the trapezius muscle in connection with radical neck-dissection. An anatomical study. *J Craniomaxillofac Surg* 1991; **19**: 87-89 [PMID: 2037698 DOI: 10.1016/s1010-5182(05)80613-4]
- 18 **Tsuruike M**, Ellenbecker TS. Serratus anterior and lower trapezius muscle activities during multi-joint isotonic scapular exercises and isometric contractions. *J Athl Train* 2015; **50**: 199-210 [PMID: 25689561 DOI: 10.4085/1062-6050-49.3.80]
- 19 **de Witte PB**, Werner S, ter Braak LM, Veeger HE, Nelissen RG, de Groot JH. The Supraspinatus and the Deltoid - not just two arm elevators. *Hum Mov Sci* 2014; **33**: 273-283 [PMID: 24289984 DOI: 10.1016/j.humov.2013.08.010]
- 20 **Weisberger EC**. The efferent supply of the trapezius muscle: a neuroanatomic basis for the preservation of shoulder function during neck dissection. *Laryngoscope* 1987; **97**: 435-445 [PMID: 3561129 DOI: 10.1288/00005537-198704000-00006]
- 21 **Brown H**, Burns S, Kaiser CW. The spinal accessory nerve plexus, the trapezius muscle, and shoulder stabilization after radical neck cancer surgery. *Ann Surg* 1988; **208**: 654-661 [PMID: 3056289 DOI: 10.1097/0000658-198811000-00019]
- 22 **Mills S**, Aristotelous C, Touil LL, James RCW. Rare anatomical variant of the spinal accessory nerve: case report and

- comprehensive review. *Int J Oral Maxillofac Surg* 2022; **51**: 467-472 [PMID: [34419286](#) DOI: [10.1016/j.ijom.2021.08.003](#)]
- 23 **Merrell GA**, Barrie KA, Katz DL, Wolfe SW. Results of nerve transfer techniques for restoration of shoulder and elbow function in the context of a meta-analysis of the English literature. *J Hand Surg Am* 2001; **26**: 303-314 [PMID: [11279578](#) DOI: [10.1053/jhsu.2001.21518](#)]
 - 24 **Pruksakorn D**, Sananpanich K, Khunamornpong S, Phudhichareonrat S, Chalidapong P. Posterior approach technique for accessory-suprascapular nerve transfer: a cadaveric study of the anatomical landmarks and number of myelinated axons. *Clin Anat* 2007; **20**: 140-143 [PMID: [16944529](#) DOI: [10.1002/ca.20376](#)]
 - 25 **Lanitsnik B**, Zargi M, Rodi Z. Identification of three anatomical patterns of the spinal accessory nerve in the neck by neurophysiological mapping. *Radiol Oncol* 2014; **48**: 387-392 [PMID: [25435852](#) DOI: [10.2478/raon-2013-0069](#)]
 - 26 **Harold Ellis**, Vishy Mahadevan. The posterior triangle of the neck. *Surgery* 2014; **32** suppl 2: e17-e27 [DOI: [10.1016/j.mpsur.2013.04.021](#)]
 - 27 **Bertelli JA**, Ghizoni MF. Reconstruction of C5 and C6 brachial plexus avulsion injury by multiple nerve transfers: spinal accessory to suprascapular, ulnar fascicles to biceps branch, and triceps long or lateral head branch to axillary nerve. *J Hand Surg Am* 2004; **29**: 131-139 [PMID: [14751116](#) DOI: [10.1016/j.jhsa.2003.10.013](#)]
 - 28 **Waikakul S**, Wongtragul S, Vanadurongwan V. Restoration of elbow flexion in brachial plexus avulsion injury: comparing spinal accessory nerve transfer with intercostal nerve transfer. *J Hand Surg Am* 1999; **24**: 571-577 [PMID: [10357538](#) DOI: [10.1053/jhsu.1999.0571](#)]
 - 29 **Lu J**, Xu J, Xu W, Xu L, Fang Y, Chen L, Gu Y. Combined nerve transfers for repair of the upper brachial plexus injuries through a posterior approach. *Microsurgery* 2012; **32**: 111-117 [PMID: [22002897](#) DOI: [10.1002/micr.20962](#)]
 - 30 **Souza FH**, Bernardino SN, Filho HC, Gobbato PL, Martins RS, Martins HA, Silva-Néto RP. Comparison between the anterior and posterior approach for transfer of the spinal accessory nerve to the suprascapular nerve in late traumatic brachial plexus injuries. *Acta Neurochir (Wien)* 2014; **156**: 2345-2349 [PMID: [25326278](#) DOI: [10.1007/s00701-014-2222-6](#)]
 - 31 **Rezzadeh K**, Donnelly M, Vieira D, Daar D, Shah A, Hacquebord J. The extent of brachial plexus injury: an important factor in spinal accessory nerve to suprascapular nerve transfer outcomes. *Br J Neurosurg* 2020; **34**: 591-594 [PMID: [31307250](#) DOI: [10.1080/02688697.2019.1639620](#)]
 - 32 **Abdouni YA**, Checoli GF, Salles HC, da Costa AC, Chakkour I, Fucs PMMB. Assessment of the results of accessory to suprascapular nerve transfer. *Acta Ortop Bras* 2018; **26**: 332-334 [PMID: [30464716](#) DOI: [10.1590/1413-785220182605193532](#)]
 - 33 **Bertelli JA**, Ghizoni MF. Improved technique for harvesting the accessory nerve for transfer in brachial plexus injuries. *Neurosurgery* 2006; **58**: ONS-366 [PMID: [16582662](#) DOI: [10.1227/01.NEU.0000205286.70890.27](#)]



Published by **Baishideng Publishing Group Inc**
7041 Koll Center Parkway, Suite 160, Pleasanton, CA 94566, USA

Telephone: +1-925-3991568

E-mail: bpgoffice@wjgnet.com

Help Desk: <https://www.f6publishing.com/helpdesk>

<https://www.wjgnet.com>

