

World Journal of *Clinical Cases*

World J Clin Cases 2022 October 6; 10(28): 9970-10390



Contents

Thrice Monthly Volume 10 Number 28 October 6, 2022

REVIEW

- 9970** COVID-19 and the heart
Xanthopoulos A, Bourazana A, Giamouzis G, Skoularigki E, Dimos A, Zagouras A, Papamichalis M, Leventis I, Magouliotis DE, Triposkiadis F, Skoularigis J
- 9985** Role of short chain fatty acids in gut health and possible therapeutic approaches in inflammatory bowel diseases
Caetano MAF, Castelucci P

MINIREVIEWS

- 10004** Review of the pharmacological effects of astragaloside IV and its autophagic mechanism in association with inflammation
Yang Y, Hong M, Lian WW, Chen Z

ORIGINAL ARTICLE

Clinical and Translational Research

- 10017** Effects of targeted-edited oncogenic insulin-like growth factor-1 receptor with specific-sgRNA on biological behaviors of HepG2 cells
Yao M, Cai Y, Wu ZJ, Zhou P, Sai WL, Wang DF, Wang L, Yao DF

Retrospective Study

- 10031** Analysis of the successful clinical treatment of 140 patients with parathyroid adenoma: A retrospective study
Peng ZX, Qin Y, Bai J, Yin JS, Wei BJ
- 10042** Efficacy of digital breast tomosynthesis combined with magnetic resonance imaging in the diagnosis of early breast cancer
Ren Y, Zhang J, Zhang JD, Xu JZ
- 10053** Prevention and management of adverse events following COVID-19 vaccination using traditional Korean medicine: An online survey of public health doctors
Kang B, Chu H, Youn BY, Leem J
- 10066** Clinical outcomes of targeted therapies in elderly patients aged ≥ 80 years with metastatic colorectal cancer
Jang HR, Lee HY, Song SY, Lim KH
- 10077** Endovascular treatment vs drug therapy alone in patients with mild ischemic stroke and large infarct cores
Kou WH, Wang XQ, Yang JS, Qiao N, Nie XH, Yu AM, Song AX, Xue Q

Clinical Trials Study

- 10085** One hundred and ninety-two weeks treatment of entecavir maleate for Chinese chronic hepatitis B predominantly genotyped B or C

Xu JH, Wang S, Zhang DZ, Yu YY, Si CW, Zeng Z, Xu ZN, Li J, Mao Q, Tang H, Sheng JF, Chen XY, Ning Q, Shi GF, Xie Q, Zhang XQ, Dai J

Observational Study

- 10097** Dementia-related contact experience, attitudes, and the level of knowledge in medical vocational college students

Liu DM, Yan L, Wang L, Lin HH, Jiang XY

SYSTEMATIC REVIEWS

- 10109** Link between COVID-19 vaccines and myocardial infarction

Zafar U, Zafar H, Ahmed MS, Khattak M

CASE REPORT

- 10120** Successful treatment of disseminated nocardiosis diagnosed by metagenomic next-generation sequencing: A case report and review of literature

Li T, Chen YX, Lin JJ, Lin WX, Zhang WZ, Dong HM, Cai SX, Meng Y

- 10130** Multiple primary malignancies - hepatocellular carcinoma combined with splenic lymphoma: A case report

Wu FZ, Chen XX, Chen WY, Wu QH, Mao JT, Zhao ZW

- 10136** Metastatic multifocal melanoma of multiple organ systems: A case report

Maksimaityte V, Reivytyte R, Milaknyte G, Mickys U, Razanskiene G, Stundys D, Kazenaite E, Valantinas J, Stundiene I

- 10146** Cavernous hemangioma of the ileum in a young man: A case report and review of literature

Yao L, Li LW, Yu B, Meng XD, Liu SQ, Xie LH, Wei RF, Liang J, Ruan HQ, Zou J, Huang JA

- 10155** Successful management of a breastfeeding mother with severe eczema of the nipple beginning from puberty: A case report

Li R, Zhang LX, Tian C, Ma LK, Li Y

- 10162** Short benign ileocolonic anastomotic strictures - management with bi-flanged metal stents: Six case reports and review of literature

Kasapidis P, Mavrogenis G, Mandrekas D, Bazerbachi F

- 10172** Simultaneous bilateral floating knee: A case report

Wu CM, Liao HE, Lan SJ

- 10180** Chemotherapy, transarterial chemoembolization, and nephrectomy combined treated one giant renal cell carcinoma (T3aN1M1) associated with Xp11.2/TFE3: A case report

Wang P, Zhang X, Shao SH, Wu F, Du FZ, Zhang JF, Zuo ZW, Jiang R

- 10186** Tislelizumab-related enteritis successfully treated with adalimumab: A case report

Chen N, Qian MJ, Zhang RH, Gao QQ, He CC, Yao YK, Zhou JY, Zhou H

- 10193** Treatment of refractory/relapsed extranodal NK/T cell lymphoma with decitabine plus anti-PD-1: A case report
Li LJ, Zhang JY
- 10201** Clinical analysis of pipeline dredging agent poisoning: A case report
Li YQ, Yu GC, Shi LK, Zhao LW, Wen ZX, Kan BT, Jian XD
- 10208** Follicular lymphoma with cardiac involvement in a 90-year-old patient: A case report
Sun YX, Wang J, Zhu JH, Yuan W, Wu L
- 10214** Twin reversed arterial perfusion sequence-a rare and dangerous complication form of monochorionic twins: A case report
Anh ND, Thu Ha NT, Sim NT, Toan NK, Thuong PTH, Duc NM
- 10220** Potential otogenic complications caused by cholesteatoma of the contralateral ear in patients with otogenic abscess secondary to middle ear cholesteatoma of one ear: A case report
Zhang L, Niu X, Zhang K, He T, Sun Y
- 10227** Myeloid sarcoma with ulnar nerve entrapment: A case report
Li DP, Liu CZ, Jeremy M, Li X, Wang JC, Nath Varma S, Gai TT, Tian WQ, Zou Q, Wei YM, Wang HY, Long CJ, Zhou Y
- 10236** Alpha-fetoprotein-producing hepatoid adenocarcinoma of the lung responsive to sorafenib after multiline treatment: A case report
Xu SZ, Zhang XC, Jiang Q, Chen M, He MY, Shen P
- 10244** Acute mesenteric ischemia due to percutaneous coronary intervention: A case report
Ding P, Zhou Y, Long KL, Zhang S, Gao PY
- 10252** Persistent diarrhea with petechial rash - unusual pattern of light chain amyloidosis deposition on skin and gastrointestinal biopsies: A case report
Bilton SE, Shah N, Dougherty D, Simpson S, Holliday A, Sahebjam F, Grider DJ
- 10260** Solitary splenic tuberculosis: A case report
Guo HW, Liu XQ, Cheng YL
- 10266** Coronary artery aneurysms caused by Kawasaki disease in an adult: A case report and literature review
He Y, Ji H, Xie JC, Zhou L
- 10273** Double filtration plasmapheresis for pregnancy with hyperlipidemia in glycogen storage disease type Ia: A case report
Wang J, Zhao Y, Chang P, Liu B, Yao R
- 10279** Treatment of primary tracheal schwannoma with endoscopic resection: A case report
Shen YS, Tian XD, Pan Y, Li H
- 10286** Concrecence of maxillary second molar and impacted third molar: A case report
Su J, Shao LM, Wang LC, He LJ, Pu YL, Li YB, Zhang WY

- 10293** Rare leptin in non-alcoholic fatty liver cirrhosis: A case report
Nong YB, Huang HN, Huang JJ, Du YQ, Song WX, Mao DW, Zhong YX, Zhu RH, Xiao XY, Zhong RX
- 10301** One-stage resection of four genotypes of bilateral multiple primary lung adenocarcinoma: A case report
Zhang DY, Liu J, Zhang Y, Ye JY, Hu S, Zhang WX, Yu DL, Wei YP
- 10310** Ectopic pregnancy and failed oocyte retrieval during *in vitro* fertilization stimulation: Two case reports
Zhou WJ, Xu BF, Niu ZH
- 10317** Malignant peritoneal mesothelioma with massive ascites as the first symptom: A case report
Huang X, Hong Y, Xie SY, Liao HL, Huang HM, Liu JH, Long WJ
- 10326** Subperiosteal orbital hematoma concomitant with abscess in a patient with sinusitis: A case report
Hu XH, Zhang C, Dong YK, Cong TC
- 10332** Postpartum posterior reversible encephalopathy syndrome secondary to preeclampsia and cerebrospinal fluid leakage: A case report and literature review
Wang Y, Zhang Q
- 10339** Sudden extramedullary and extranodal Philadelphia-positive anaplastic large-cell lymphoma transformation during imatinib treatment for CML: A case report
Wu Q, Kang Y, Xu J, Ye WC, Li ZJ, He WF, Song Y, Wang QM, Tang AP, Zhou T
- 10346** Relationship of familial cytochrome P450 4V2 gene mutation with liver cirrhosis: A case report and review of the literature
Jiang JL, Qian JF, Xiao DH, Liu X, Zhu F, Wang J, Xing ZX, Xu DL, Xue Y, He YH
- 10358** COVID-19-associated disseminated mucormycosis: An autopsy case report
Kyuno D, Kubo T, Tsujiwaki M, Sugita S, Hosaka M, Ito H, Harada K, Takasawa A, Kubota Y, Takasawa K, Ono Y, Magara K, Narimatsu E, Hasegawa T, Osanai M
- 10366** Thalidomide combined with endoscopy in the treatment of Cronkhite-Canada syndrome: A case report
Rong JM, Shi ML, Niu JK, Luo J, Miao YL
- 10375** Thoracolumbar surgery for degenerative spine diseases complicated with tethered cord syndrome: A case report
Wang YT, Mu GZ, Sun HL

LETTER TO THE EDITOR

- 10384** Are pregnancy-associated hypertensive disorders so sweet?
Thomopoulos C, Ilias I
- 10387** Tumor invasion front in oral squamous cell carcinoma
Cuevas-González JC, Cuevas-González MV, Espinosa-Cristobal LF, Donohue Cornejo A

ABOUT COVER

Editorial Board Member of *World Journal of Clinical Cases*, Kaleem Ullah, FCPS, MBBS, Assistant Professor, Solid Organ Transplantation and Hepatobiliary Surgery, Pir Abdul Qadir Shah Jeelani Institute of Medical Sciences, Gambat 66070, Sindh, Pakistan. drkaleempk@gmail.com

AIMS AND SCOPE

The primary aim of *World Journal of Clinical Cases* (WJCC, *World J Clin Cases*) is to provide scholars and readers from various fields of clinical medicine with a platform to publish high-quality clinical research articles and communicate their research findings online.

WJCC mainly publishes articles reporting research results and findings obtained in the field of clinical medicine and covering a wide range of topics, including case control studies, retrospective cohort studies, retrospective studies, clinical trials studies, observational studies, prospective studies, randomized controlled trials, randomized clinical trials, systematic reviews, meta-analysis, and case reports.

INDEXING/ABSTRACTING

The WJCC is now abstracted and indexed in Science Citation Index Expanded (SCIE, also known as SciSearch®), Journal Citation Reports/Science Edition, Current Contents®/Clinical Medicine, PubMed, PubMed Central, Scopus, Reference Citation Analysis, China National Knowledge Infrastructure, China Science and Technology Journal Database, and Superstar Journals Database. The 2022 Edition of Journal Citation Reports® cites the 2021 impact factor (IF) for WJCC as 1.534; IF without journal self cites: 1.491; 5-year IF: 1.599; Journal Citation Indicator: 0.28; Ranking: 135 among 172 journals in medicine, general and internal; and Quartile category: Q4. The WJCC's CiteScore for 2021 is 1.2 and Scopus CiteScore rank 2021: General Medicine is 443/826.

RESPONSIBLE EDITORS FOR THIS ISSUE

Production Editor: *Xu Guo*; Production Department Director: *Xiang Li*; Editorial Office Director: *Jin-Lei Wang*.

NAME OF JOURNAL

World Journal of Clinical Cases

ISSN

ISSN 2307-8960 (online)

LAUNCH DATE

April 16, 2013

FREQUENCY

Thrice Monthly

EDITORS-IN-CHIEF

Bao-Gan Peng, Jerzy Tadeusz Chudek, George Kontogeorgos, Maurizio Serati, Ja Hyeon Ku

EDITORIAL BOARD MEMBERS

<https://www.wjnet.com/2307-8960/editorialboard.htm>

PUBLICATION DATE

October 6, 2022

COPYRIGHT

© 2022 Baishideng Publishing Group Inc

INSTRUCTIONS TO AUTHORS

<https://www.wjnet.com/bpg/gerinfo/204>

GUIDELINES FOR ETHICS DOCUMENTS

<https://www.wjnet.com/bpg/GerInfo/287>

GUIDELINES FOR NON-NATIVE SPEAKERS OF ENGLISH

<https://www.wjnet.com/bpg/gerinfo/240>

PUBLICATION ETHICS

<https://www.wjnet.com/bpg/GerInfo/288>

PUBLICATION MISCONDUCT

<https://www.wjnet.com/bpg/gerinfo/208>

ARTICLE PROCESSING CHARGE

<https://www.wjnet.com/bpg/gerinfo/242>

STEPS FOR SUBMITTING MANUSCRIPTS

<https://www.wjnet.com/bpg/GerInfo/239>

ONLINE SUBMISSION

<https://www.f6publishing.com>



Successful treatment of disseminated nocardiosis diagnosed by metagenomic next-generation sequencing: A case report and review of literature

Ting Li, Yi-Xin Chen, Jia-Jia Lin, Wei-Xian Lin, Wei-Zhen Zhang, Hang-Ming Dong, Shao-Xi Cai, Ying Meng

Specialty type: Medicine, research and experimental

Provenance and peer review:

Unsolicited article; Externally peer reviewed.

Peer-review model: Single blind

Peer-review report's scientific quality classification

Grade A (Excellent): 0
Grade B (Very good): B
Grade C (Good): C, C, C
Grade D (Fair): D
Grade E (Poor): 0

P-Reviewer: Roganovic J, Croatia;
Watanabe T, Japan; Enomoto H, Japan

Received: January 25, 2022

Peer-review started: January 25, 2022

First decision: March 23, 2022

Revised: March 25, 2022

Accepted: August 21, 2022

Article in press: August 21, 2022

Published online: October 6, 2022



Ting Li, Yi-Xin Chen, Jia-Jia Lin, Wei-Xian Lin, Wei-Zhen Zhang, Hang-Ming Dong, Shao-Xi Cai, Ying Meng, Department of Respiratory and Critical Care Medicine, Nanfang Hospital, Southern Medical University, Guangzhou 510515, Guangdong Province, China

Corresponding author: Ying Meng, Doctor, Chief Doctor, Department of Respiratory and Critical Care Medicine, Nanfang Hospital, Southern Medical University, No. 1838 North Guangzhou Avenue, Baiyun District, Guangzhou 510515, Guangdong Province, China. nfyymengy@163.com

Abstract

BACKGROUND

Nocardia paucivorans is an infrequently found bacterium with the potential to cause severe infection, with a predilection for the central nervous system, both in immunocompromised and immunocompetent individuals. Rapid etiological diagnosis of nocardiosis can facilitate timely and rational antimicrobial treatment. Metagenomic next-generation sequencing (mNGS) can improve the rate and reduce the turnaround time for the detection of *Nocardia*.

CASE SUMMARY

A 49-year-old man was admitted to hospital with cough and hemoptysis. Imaging revealed pulmonary consolidation as well as multiple brain lesions. *Nocardia asiatica* and *Nocardia beijingensis* were rapidly detected by mNGS of bronchoalveolar lavage fluid (BALF) while bacterial culture of BALF and pathological biopsy of lung tissue were negative. In early stages, he was treated with trimethoprim-sulfamethoxazole (TMP-SMZ) and linezolid by individual dose adjustment based on serum concentrations and the adverse effects of thrombocytopenia and leukopenia. The treatment was then replaced by TMP-SMZ and ceftriaxone or minocycline. He was treated with 8 mo of parenteral and/or oral antibiotics, and obvious clinical improvement was achieved with resolution of pulmonary and brain lesions on repeat imaging.

CONCLUSION

mNGS provided fast and precise pathogen detection of *Nocardia*. In disseminated nocardiosis, linezolid is an important alternative that can give a better outcome with the monitoring of linezolid serum concentrations and platelet count.

Key Words: Disseminated nocardiosis; Metagenomic next-generation sequencing; Linezolid; Thrombocytopenia; Case report

©The Author(s) 2022. Published by Baishideng Publishing Group Inc. All rights reserved.

Core Tip: Early detection of *Nocardia paucivorans* can optimize antibiotic management, shorten hospital stays and improve survival rates. We report rapid detection of *N. paucivorans* by metagenomic next-generation sequencing (mNGS) of BALF. The patient was treated with trimethoprim-sulfamethoxazole (TMP-SMZ) and linezolid by individual dose adjustment based on serum concentration and thrombocytopenia and leukopenia, then replaced by TMP-SMZ and ceftriaxone or minocycline. This case suggests that mNGS is a convenient and efficient technique for detecting *Nocardia*, especially suitable for rare, novel and atypical etiologies of complicated infectious diseases. Linezolid may be an important alternative in disseminated nocardiosis.

Citation: Li T, Chen YX, Lin JJ, Lin WX, Zhang WZ, Dong HM, Cai SX, Meng Y. Successful treatment of disseminated nocardiosis diagnosed by metagenomic next-generation sequencing: A case report and review of literature. *World J Clin Cases* 2022; 10(28): 10120-10129

URL: <https://www.wjgnet.com/2307-8960/full/v10/i28/10120.htm>

DOI: <https://dx.doi.org/10.12998/wjcc.v10.i28.10120>

INTRODUCTION

Nocardia paucivorans is a Gram-positive aerobic bacterium of the order Actinomycetales and has become an increasingly important opportunistic pathogen, mostly in immunocompromised individuals[1]. It causes a wide spectrum of illness, including pneumonia, cutaneous or subcutaneous infections, brain or other solid organ abscesses, thus resulting in high mortality[2]. Early detection of *N. paucivorans* can optimize antibiotic management, shorten hospital stays, improve survival rates and reduce medical costs. Delaying diagnosis may impede targeted therapies and lead to poor prognosis. However, the definitive diagnosis of nocardiosis still depends on the isolation and identification of organisms from the infected site, which may take days to weeks and the positive rates by these methods are very low. As these methods cannot meet the current demand for rapid and accurate diagnosis, metagenome next-generation sequencing (mNGS) has become available in clinical practice[3]. mNGS also known as shotgun deep-sequencing, is a high-throughput sequencing approach with more rapid and accurate diagnostic advantages than traditional methods, especially in culture-negative samples[4,5]. mNGS can simultaneously detect and identify pathogens by extracting only a small amount of DNA or RNA from samples. mNGS can theoretically detect all pathogens in clinical samples, especially for rare, novel, and atypical etiologies of complex infectious diseases[6]. Here, we describe a case of disseminated nocardiosis in a 49-year-old man diagnosed by mNGS of bronchoalveolar lavage fluid (BALF) rather than bacterial culture of BALF and pathological biopsy of lung tissue. He was successfully treated with parenteral or oral antibiotics for 8 mo, with evident clinical improvement and resolution of pulmonary and brain lesions on repeat imaging.

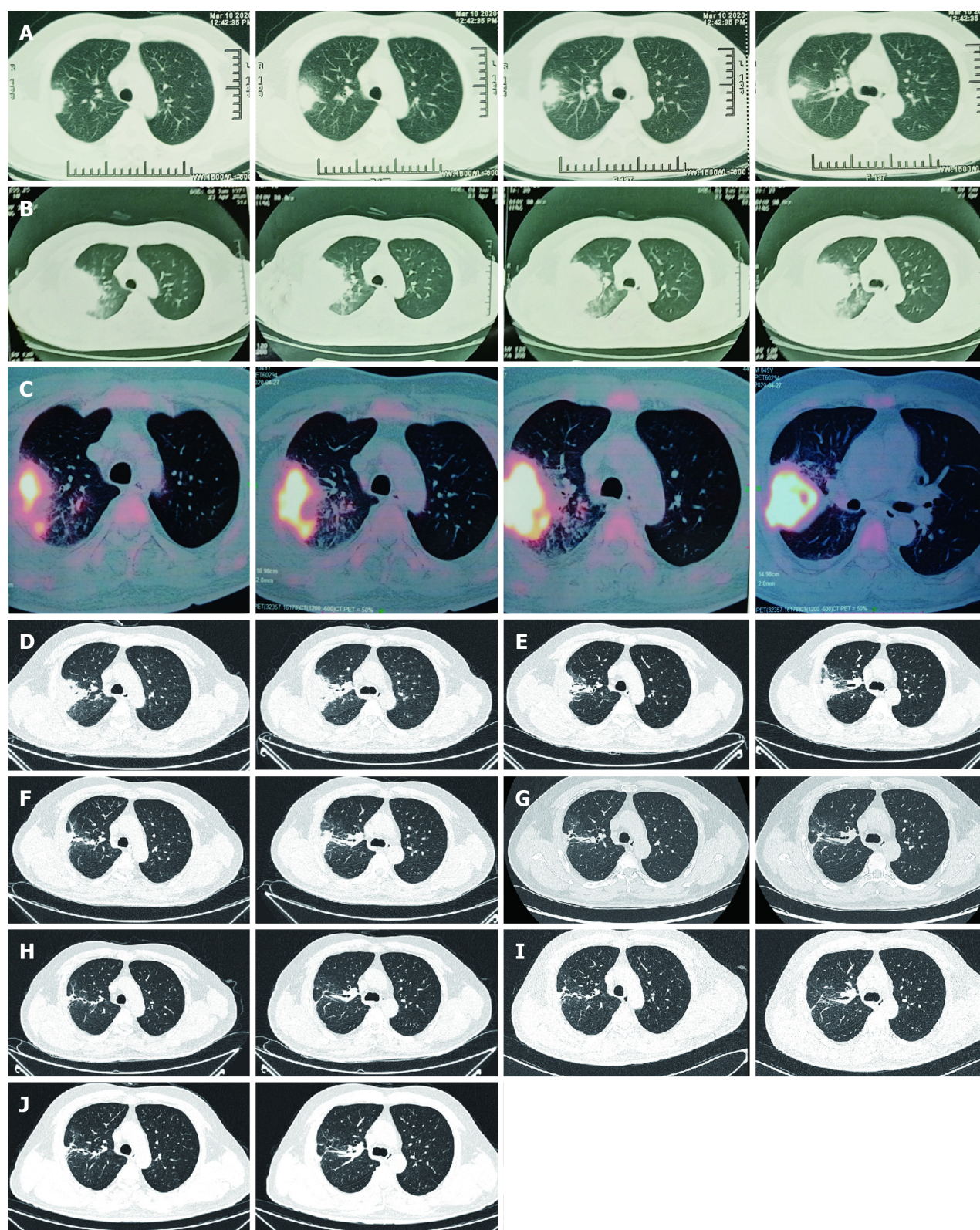
CASE PRESENTATION

Chief complaints

A 49-year-old Chinese man had symptoms of cough and hemoptysis for 2 mo.

History of present illness

A 49-year-old Chinese man presented to the hospital with 2 mo of cough and hemoptysis, but without fever or chest pain. Daily blood loss was estimated to be 20-30mL. During a visit to a different hospital on March 10, 2020, chest computed tomography (CT) demonstrated a mass and atelectasis in the right upper lobe (Figure 1A). BALF was obtained by bronchoscopy; however, the bacterial culture of BALF was negative. The patient was diagnosed with pulmonary infection and treated with oral cefixime capsules (0.2g every 12h) and azithromycin (500 mg/d) for 1 wk. However, there was no improvement and the patient was in a poor general status. He had dyspnea when walking hastily or going up stairs and had chest pain. Chest CT on April 23, 2020 showed aggravation of the original lesion, especially in the right upper lobe (Figure 1B). He was admitted to our respiratory department for further evaluation



DOI: 10.12998/wjcc.v10.i28.10120 Copyright ©The Author(s) 2022.

Figure 1 Computed tomography of right lung. A: The first scan demonstrated a mass and atelectasis in the right upper lobe on March 20, 2020; B: Chest Computed Tomography (CT) showed aggravation of the original lesion on April 23, 2020; C: Positron emission tomography-CT showed that the mass lesions in the posterior segment of the right upper lobe had significantly increased glucose metabolism inhomogeneously on April 27, 2020; D: Primary lesion of the right upper lobe reduced on May 23, 2020; E-J: Repeated pulmonary CT showed primary lesion size of the right upper lobe continued to decrease on different times, involving June 22, 2020 (E), July 29, 2020 (F), September 8, 2020 (G), November 20, 2020 (H), January 7, 2021 (I) and March 25, 2021 (J). CT: Computed tomography.

on April 25, 2020.

History of past illness

The patient had no previous medical history, and no history of drug allergy.

Personal and family history

The patient worked as a welder and lived with his wife and children. He had no history of cigarette smoking or alcohol abuse. There was no family history to note.

Physical examination

On admission, the patient was afebrile and vital signs were normal. Breath sounds were decreased in the right lung, and neurological examination was unremarkable.

Laboratory examinations

The oxygenation index in blood gas analysis was 265 mmHg (Table 1). Leukocytosis was $14.36 \times 10^9/L$, C-reactive protein was 117.50 mg/L, and procalcitonin was 0.126 ng/mL, and liver and kidney functions were normal. GeneXpert MTB/RIF, quantitative immunoglobulins, 1-3- β -D-glucan, galactomannan (GM), cryptococcal and deep sputum bacteriological culture antigen were all negative.

Imaging examinations

Positron emission tomography (PET)-CT was ordered on the suspicion of lung cancer. PET-CT showed that most of the mass lesions in the posterior segment of the right upper lobe had significantly increased glucose metabolism inhomogeneously with peripheral exudative changes, which were suspicious for infection on April 27, 2020 (Figure 1C).

Further diagnostic work-up

The patient was inhaled oxygen 4 L/min and treated empirically with simultaneous cefoperazone-tazobactam and teicoplanin for 7 d, but he continued to experience cough and hemoptysis with elevated C-reactive protein (109.92 mg/L) and procalcitonin (0.189 ng/mL). Meropenem and teicoplanin were then administered. In addition, bronchoscopy was performed to obtain specimens including BALF and lung tissue. Transbronchial biopsy of soft tissue of the right upper lung showed chronic inflammation with acute activity and fibrous tissue hyperplasia with focal necrosis. GeneXpert MTB/RIF, GM (1-3)- β -D-Glucan, fungi and acid-fast bacillus stains, and BALF culture for bacteria were negative. However, mNGS analysis of BALF detected *N. asiatica* and *N. beijingensis*. The patient developed a new symptom of headache at the same time. Cranial enhanced magnetic resonance imaging (MRI) was ordered on the suspicion of intracranial *Nocardia* infection and it showed multiple lesions in the left occipital lobe, right cerebellar hemisphere and left frontal lobe on May 13, 2020 (Figure 2A). Cerebrospinal fluid (CSF) obtained by lumbar puncture identified no white or red blood cells, glucose 3.42 mmol/L and protein 0.54 g/L. The bacterial culture, cryptococcal antigen, virus DNA and exfoliative cell examination of CSF were all negative, as was NGS analysis of CSF (Figure 3).

FINAL DIAGNOSIS

Disseminated nocardiosis affecting the CNS and lungs.

TREATMENT

The patient was immediately treated with oral TMP-SMZ 0.96 g every 8 h and intravenous linezolid 600 mg every 12 h from May 9, 2020. After 2 wk of combined antibiotic therapy, his condition improved and pulmonary CT showed an obvious reduction in consolidation in both lung fields on May 23, 2020 (Figure 1D). The oxygenation index in blood gas analysis was 388 mmHg (Table 1). Platelet count showed thrombocytopenia ($171 \times 10^9/L$ $10^9/L$ vs normal $233 \times 10^9/L$). After 3 wk, because of the higher dose of linezolid in the plasma (9.36 mg/L) and reduction of hemamebas ($3.34 \times 10^9/L$) and platelets ($122 \times 10^9/L$), we adjusted the dose of intravenous linezolid (600 mg/d) and oral TMP-SMZ (0.96 g every 12 h) on May 31, 2020 (Table 2). The patient's blood count recovered gradually, and at the same time his clinical conditions continued to improve. After 5 wk and improvement of his brain lesions on repeat MRI (Figure 2B), as the dose of linezolid in plasma was still high (6.38 mg/L), the treatment was replaced by ceftriaxone (2 g/d) on June 16, 2020 (Table 2). After 1 wk of treatment with ceftriaxone (2 g/d) and TMP-SMZ (0.96 g every 12 h), we shifted the antibiotic therapy to oral minocycline (100 mg every 12 h) and TMP-SMZ (0.96 g every 12 h) for 6.5 mo (Table 2). He completed nearly 8 mo of antibiotic therapy, with resolution of his pulmonary and brain lesions (Figure 1E-J), and complete cure was achieved (Figure 2C and D).

Table 1 Efficacy before and after treatment

	April 25, 2020	May 23, 2020	June 16, 2020
Cough	2	1	0
Hemoptysis	20-30 mL	0	0
Dyspnea index	2	1	0
Supplemental O ₂ in L/min	4 L/min	2 L/min	0
Oxygenation index	265 mmHg	388 mmHg	412 mmHg

Cough index: 0: NO cough; 1: Occasionally have a cough; 2: Frequent cough, mild impact on daily life; 3: Frequent cough, serious impact on daily life. Hemoptysis volume: Small amount: < 100 mL/24 h; Moderate amount: 100-500 mL/24 h; Massive amount: > 500 mL/24 h or > 100 mL at one time. Dyspnea index: 0: Asymptomatic while climbing stairs; 1: Symptomatic while climbing stairs; 2: Symptomatic after walking 100 m on flat ground; 3: Symptomatic with the least effort (*e.g.*, talking, getting dressed); 4: Symptomatic in bed, at rest. Oxygenation index: partial blood oxygen divided by oxygen concentration.

Table 2 Therapeutic strategy and the laboratory examinations

	April 9, 2020	May 30, 2020	May 31, 2020	June 16, 2020	June 23, 2020
Treatment	TMP-SMZ 0.96 g q8 h + linezolid 0.6 g q12 h		TMP-SMZ 0.96 g q12 h + linezolid 0.6 g qd	TMP-SMZ 0.96 g q12 h + ceftriaxone 2 g/d	TMP-SMZ 0.96 g q12 h and minocycline 100 mg q12 h
WBC (10 ⁹ /L)	4.03		3.34	4.07	3.91
PLT (10 ⁹ /L)	379		130	219	185
The dose of linezolid (mg/L)	No		9.36	6.38	No

TMP-SMZ: Trimethoprim-sulfamethoxazole; WBC: White Blood Cell; PLT: Platelet.

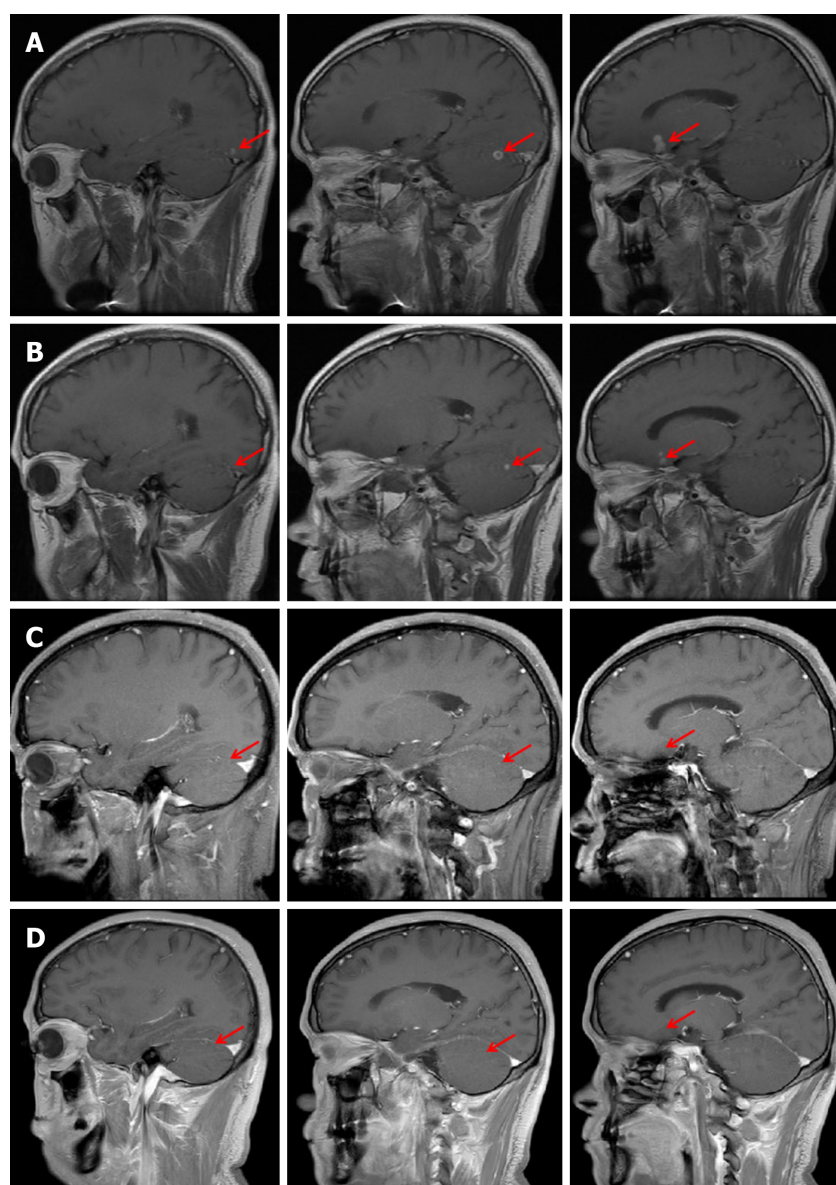
OUTCOME AND FOLLOW-UP

He completed nearly 8 mo of antibiotic therapy, with resolution of his pulmonary and brain lesions (Figure 1E-J), and complete cure was achieved (Figure 2C and D).

DISCUSSION

Disseminated nocardiosis may affect many organs, especially the lungs, CNS, skin and even the pericardium. Among disseminated infections, 44% of patients had CNS involvement, highlighting the neurotrophic features of *Nocardia* spp. CNS manifestations of *Nocardia* infection can include isolated or multifocal brain abscesses and meningitis[7-9]. Consistent with the previous reports, our patient presented with disseminated disease spreading from a primary pulmonary infection to the central nervous system. He had a neurological symptom of headache and MRI revealed multiple lesions in the left frontal lobe, occipital lobe and right cerebellar hemisphere. Although bacterial culture and NGS analysis of CSF were both negative, his headache disappeared and MRI showed that the craniocerebral lesions were significantly reduced or even disappeared after antibiotic therapy, which confirmed that he had cerebral nocardiosis.

A definitive diagnosis of nocardiosis requires the isolation and identification of the organism from a clinical specimen. The traditional detection methods in specimens for microbial culture, histopathology, or smear microscopy, have low yield and are time-consuming; therefore, NGS has emerged[3]. NGS can detect unknown pathogens and a variety of mixed infectious pathogens by one-stop precision sequencing, therefore simplifying the detection process, improving pathogen detection sensitivity, and shortening detection time[4,5]. In this case, *N. asiatica* and *N. beijingensis* were rapidly detected by the mNGS of BALF, while the bacterial culture of BALF and the pathological biopsy of lung tissue were negative, contributing to prompt and accurate antibiotic treatment, and obvious clinical improvement was observed with resolution of pulmonary and brain lesions on repeat imaging. As reported, NGS can enable in-depth identification and classification of pathogens and their abilities to resist current treatment methods. In addition, the analysis of drug genes and virulence factors has an incomparable advantage over traditional detection methods[10,11]. However, as mNGS usually detects more than one pathogen in one test, clinicians need to comprehensively evaluate the clinical status and sequencing

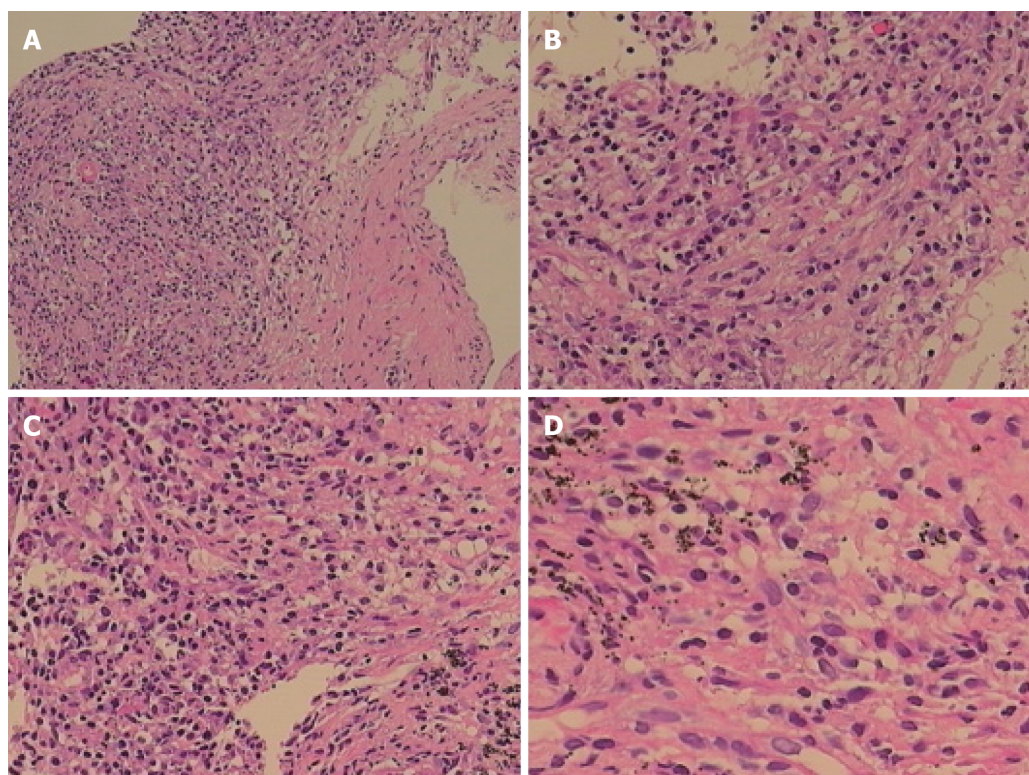


DOI: 10.12998/wjcc.v10.i28.10120 Copyright ©The Author(s) 2022.

Figure 2 Brain magnetic resonance imaging findings. A: Cranial magnetic resonance imaging (MRI) showed multiple lesions in the left occipital lobe, right cerebellar hemisphere and left frontal lobe on May 13, 2020; B: Cranial MRI showed a decrease of the original lesion on June 15, 2020; C: Primary lesions of the brain maintained shrinkage on July 31, 2020; D: Primary lesions of the brain almost completely disappeared on September 10, 2020. MRI: Magnetic resonance imaging.

results of the patients to distinguish pathogens, symbiotic flora and pollutants. Although this method could detect the common resistant genes, it was unable to provide direct formation about antibiotic sensitivity. Furthermore, the high cost and low accessibility of NGS still limit its application in clinical practice. In the future, optimization of sample acquisition, sample preparation and bioinformatics analysis will be essential to the application of mNGS in clinical diagnosis. We hope that in the near future, this technology will benefit more patients.

Treatment of CNS nocardiosis is largely based upon expert opinion. Popular treatment strategies include empirical combination intravenous therapy with agents such as imipenem, TMP-SMZ, linezolid and amikacin for several weeks followed by antibiogram-guided oral therapy^[12,13]. Consistent with these strategies, our patient initiated treatment with parenteral and oral antibiotics for 6 wk and had definite clinical improvement, followed by switching to oral minocycline and TMP-SMZ for 6.5 mo. He completed nearly 8 mo of antibiotic therapy, with resolution of his brain and pulmonary lesions and achieved complete cure. Furthermore, this successful case confirmed that in some cases of disseminated nocardiosis, linezolid may be an important alternative that can give a better outcome. However, it should be emphasized that the risk of adverse effects might be increased if linezolid was combined with other antibiotics. Postmarketing studies have reported higher rates of linezolid-associated thrombocytopenia, ranging from 15% to 50%^[14,15]. The higher dose of linezolid in the plasma and prolonged duration of therapy have been suggested as more important risk factors^[16-19]. Consistent with these



DOI: 10.12998/wjcc.v10.i28.10120 Copyright ©The Author(s) 2022.

Figure 3 Chronic inflammation with acute activity and fibrous hyperplasia, with focal necrosis in the right upper lobe. A: A large number of chronic inflammatory cells with a small amount of neutrophil infiltration in hyperplastic fibrous connective tissue (Original magnification: 100 ×; scale bar: 100 μm); B: There are collagen hyperplasia and no obvious alveolar epithelial cells in some areas (Original magnification: 200 ×; scale bar: 100 μm); C and D: In addition, there are phagocytic cells that engulf carbonic acid in some areas, inflammatory cell infiltration and capillary endothelial cells in the interstitium (C: 200 ×; scale bar: 100 μm; D: 400 ×; scale bar: 100 μm).

findings, our study identified longer duration of therapy as a risk factor. The first thrombocytopenic platelet count occurred after 14 d of linezolid therapy. The severity of thrombocytopenia increased with the duration of treatment. Similarly, in this case, thrombocytopenia was closely related to the higher dose of linezolid in the plasma. The combined treatment of linezolid and TMP-SMZ may aggravate the myelosuppressive effects of reversible neutropenia and thrombocytopenia. Selection of appropriate antibiotics given at the optimal time is hence crucial for effective therapy. Although NGS can detect the presence of drug resistant genes in pathogens, it may not be consistent with clinical drug susceptibility results. Furthermore, there are still many drug resistant genes that have not yet been discovered and false negative results may exist.

A PubMed/MEDLINE search of literature found a total of 17 cases within a decade except for the references already cited in the article (Table 3)[20-36]. For patients with underlying conditions (87.5% in immunocompromised individuals), affected organs (lung involvement is most common, followed by the brain), and positive results (mostly from culture and histopathology, but not the NGS), TMP-SMZ is the most commonly used and effective drug.

CONCLUSION

This case illustrates that *Nocardia* may cause severe disseminated infection in immunocompetent patients, which often involves the CNS and lungs. mNGS can establish a more rapid and accurate diagnosis than traditional methods. It is a convenient and efficient technique for the detection of *Nocardia*, and is especially suitable for rare, novel and atypical etiologies of complicated infectious diseases. This successfully treated case confirmed that, in some patients with disseminated nocardiosis, TMP-SMZ is still the first choice of treatment, but linezolid may be an important alternative that can give a better outcome with the monitoring of linezolid serum concentrations and platelet count. Notable risk factors for linezolid-induced thrombocytopenia included high daily weight-based dose and prolonged duration of therapy (some patients experience thrombocytopenia within 14 d of treatment). Clinicians should monitor patients for linezolid-induced thrombocytopenia throughout therapy.

Table 3 Cases of pulmonary nocardiosis reported in recent 10 yr

Ref.	Predisposing or underlying condition	Affected organ (s)	Positive specimen (s)	Anti-biotic therapy	Outcome
Komiya <i>et al</i> [20], 2013	Hypersensitivity pneumonitis	Lung	sputum	Meropenem, TMP-SMZ	Improved
Yasar <i>et al</i> [21], 2014	No	Lung	Lung tissue	TMP-SMZ	Improved
Cooper <i>et al</i> [22], 2014	Smoking and alcohol consumption	Lung +Brain	Tissue of lung and brain	Vancomycin, Ceftriaxone, Amphotericin B, TMP-SMZ	Dead
Yagi <i>et al</i> [23], 2014	Mycobacterium avium	Lung	Sputum	TMP-SMZ	Improved
Ibrahim <i>et al</i> [24], 2016	Hematopoietic stem cell transplant	Lung +Brain	Lung tissue	TMP-SMZ	Improved
Mendonca <i>et al</i> [25], 2016	Multiple Myeloma	Lung	BALF	TMP-SMZ, Meropenem, Tigecycline	Improved
Jayaschandran <i>et al</i> [26], 2016	Idiopathic CD4 T-lymphocytopenia	Lung	BALF	Meropenem, TMP-SMZ	Improved
Khadka <i>et al</i> [27], 2017	Renal transplant, Pulmonary tuberculosis	Lung+Brain+ Celiac lymph nodes	BALF	TMP-SMZ	Improved
Kobayashi <i>et al</i> [28], 2018	Olfactory neuroblastoma, Ectopic adrenocorticotrophic hormone	Lung	BALF	TMP-SMZ	Improved
Khaliq <i>et al</i> [29], 2019	Cladophialophora bantiana Cerebral Phaeohyphomycosis	Lung	Lung tissue	TMP-SMZ, Meropenem, Voriconazole, Liposomal amphotericin	Died
Miyaoka <i>et al</i> [30], 2019	Smoking	Lung	BALF	Meropenem, TMP-SMZ	Improved
Kato <i>et al</i> [31], 2019	Radiation pneumonitis treated with prednisolone [PSL (50 mg/d)]	Lung	The PCR of 16S rRNA gene of the BALF	TMP-SMZ, Doripenem	Improved
Deterding <i>et al</i> [32], 2020	heart transplant recipient requiring dialysis	lung	BALF	Amikacin, Imipenem	Improved
Campoli <i>et al</i> [33], 2020	Liver transplant, Cutaneous infection by <i>Alternaria alternata</i>	Lung	BALF	TMP-SMZ, Linezolid, Ceftriaxone	Improved
Meena <i>et al</i> [34], 2020	Pulmonary tuberculosis and COPD	Lung	BALF	TMP-SMZ	Improved
Wu <i>et al</i> [35], 2021	Pulmonary alveolar proteinosis	Lung	Lung tissue	TMP-SMZ	Improved
Atemnkeng <i>et al</i> [36], 2021	COVID-19 Pneumonia	Lung +Brain	BALF	Meropenem, TMP-SMZ, Linezolid	Improved

TMP-SMZ: Trimethoprim-sulfamethoxazole; BALF: Bronchoalveolar lavage fluid; PCR: Polymerase Chain Reaction; COPD: Chronic obstructive pulmonary disease.

FOOTNOTES

Author contributions: Meng Y provided this case; Li T and Chen TX wrote the manuscript; Lin JJ, Lin WX and Zhang WZ contributed significantly to manuscript preparation; Dong HM and Cai SX helped perform the analysis and contributed to constructive discussions; all authors have read and approved the final version.

Supported by the Project of Nanfang Hospital President Foundation of Southern Medical University, No. 2019C006.

Informed consent statement: Informed written consent was obtained from the patient for publication of this report and any accompanying images.

Conflict-of-interest statement: All authors declare that there is no conflict of interest. The patient agreed with the case report.

CARE Checklist (2016) statement: All authors have read the CARE Checklist (2016), and the manuscript was prepared and revised according to the CARE Checklist (2016).

Open-Access: This article is an open-access article that was selected by an in-house editor and fully peer-reviewed by external reviewers. It is distributed in accordance with the Creative Commons Attribution NonCommercial (CC BY-NC 4.0) license, which permits others to distribute, remix, adapt, build upon this work non-commercially, and license

their derivative works on different terms, provided the original work is properly cited and the use is non-commercial. See: <https://creativecommons.org/licenses/by-nc/4.0/>

Country/Territory of origin: China

ORCID number: Ting Li 0000-0002-7030-9738; Yi-Xin Chen 0000-0003-4315-0511; Jia-Jia Lin 0000-0002-7860-7596; Wei-Xian Lin 0000-0002-8515-4564; Wei-Zhen Zhang 0000-0003-3201-2850; Hang-Ming Dong 0000-0002-4476-9829; Shao-Xi Cai 0000-0003-2816-8262.

S-Editor: Wang LL

L-Editor: A

P-Editor: Wang LL

REFERENCES

- 1 **Wilson JW.** Nocardiosis: updates and clinical overview. *Mayo Clin Proc* 2012; **87**: 403-407 [PMID: 22469352 DOI: 10.1016/j.mayocp.2011.11.016]
- 2 **Rouzaud C,** Rodriguez NV, Catherinot E, Méchai F, Bergeron E, Farfour E, Scemla A, Poirée S, Delavaud C, Mathieu D, Durupt S, Larosa F, Lengelé JP, Christophe JL, Suarez F, Lortholary O, Lebeaux D. Clinical Assessment of a Nocardia spp polymerase chain reaction PCR-Based Assay for Diagnosis of Nocardiosis. *J Clin microbiol* 2018; **56**: e00002-18
- 3 **Bragg L,** Tyson GW. Metagenomics using next-generation sequencing. *Methods Mol Biol* 2014; **1096**: 183-201 [PMID: 24515370 DOI: 10.1007/978-1-62703-712-9_15]
- 4 **Wang K,** Li P, Lin Y, Chen H, Yang L, Li J, Zhang T, Chen Q, Li Z, Du X, Zhou Y, Wang H, Song H. Metagenomic Diagnosis for a Culture-Negative Sample From a Patient With Severe Pneumonia by Nanopore and Next-Generation Sequencing. *Front Cell Infect Microbiol* 2020; **10**: 182 [PMID: 32432051 DOI: 10.3389/fcimb.2020.00182]
- 5 **Huang J,** Jiang E, Yang D, Wei J, Zhao M, Feng J, Cao J. Metagenomic Next-Generation Sequencing versus Traditional Pathogen Detection in the Diagnosis of Peripheral Pulmonary Infectious Lesions. *Infect Drug Resist* 2020; **13**: 567-576 [PMID: 32110067 DOI: 10.2147/IDR.S235182]
- 6 **Goldberg B,** Sichtig H, Geyer C, Ledebner N, Weinstock GM. Making the Leap from Research Laboratory to Clinic: Challenges and Opportunities for Next-Generation Sequencing in Infectious Disease Diagnostics. *mBio* 2015; **6**: e01888-e01815 [PMID: 26646014 DOI: 10.1128/mBio.01888-15]
- 7 **Lederman ER,** Crum NF. A case series and focused review of nocardiosis: clinical and microbiologic aspects. *Medicine (Baltimore)* 2004; **83**: 300-313 [PMID: 15342974 DOI: 10.1097/01.md.0000141100.30871.39]
- 8 **Mohanty A,** Meena S, Kumar SP, Gupta PK, Kaistha N, Gupta P, Jha MK, Rekha S. Incidental Finding of Nocardia: A Case Series from a Tertiary Care Centre in Uttarakhand. *Case Rep Infect Dis* 2020; **2020**: 6874625 [PMID: 32328325 DOI: 10.1155/2020/6874625]
- 9 **Anagnostou T,** Arvanitis M, Kourkoumpetis TK, Desalermos A, Carneiro HA, Mylonakis E. Nocardiosis of the central nervous system: experience from a general hospital and review of 84 cases from the literature. *Medicine (Baltimore)* 2014; **93**: 19-32 [PMID: 24378740 DOI: 10.1097/MD.0000000000000012]
- 10 **Didelot X,** Bowden R, Wilson DJ, Peto TEA, Crook DW. Transforming clinical microbiology with bacterial genome sequencing. *Nat Rev Genet* 2012; **13**: 601-612 [PMID: 22868263 DOI: 10.1038/nrg3226]
- 11 **Lerner PI.** Nocardiosis. *Clin Infect Dis* 1996; **22**: 891-903; quiz 904 [PMID: 8783685 DOI: 10.1093/clinids/22.6.891]
- 12 **Shen Q,** Zhou H, Li H, Zhou J. Linezolid combined with trimethoprim-sulfamethoxazole therapy for the treatment of disseminated nocardiosis. *J Med Microbiol* 2011; **60**: 1043-1045 [PMID: 21393455 DOI: 10.1099/jmm.0.018549-0]
- 13 **Wang T,** Jia Y, Chu B, Liu H, Dong X, Zhang Y. Nocardiosis in Kidney Disease Patients under Immunosuppressive Therapy: Case Report and Literature Review. *Int J Med Sci* 2019; **16**: 838-844 [PMID: 31337957 DOI: 10.7150/ijms.32440]
- 14 **Hirano R,** Sakamoto Y, Tachibana N, Ohnishi M. Retrospective analysis of the risk factors for linezolid-induced thrombocytopenia in adult Japanese patients. *Int J Clin Pharm* 2014; **36**: 795-799 [PMID: 24913359 DOI: 10.1007/s11096-014-9961-6]
- 15 **Natsumoto B,** Yokota K, Omata F, Furukawa K. Risk factors for linezolid-associated thrombocytopenia in adult patients. *Infection* 2014; **42**: 1007-1012 [PMID: 25119433 DOI: 10.1007/s15010-014-0674-5]
- 16 **Hanai Y,** Matsuo K, Ogawa M, Higashi A, Kimura I, Hirayama S, Kosugi T, Nishizawa K, Yoshio T. A retrospective study of the risk factors for linezolid-induced thrombocytopenia and anemia. *J Infect Chemother* 2016; **22**: 536-542 [PMID: 27321773 DOI: 10.1016/j.jiac.2016.05.003]
- 17 **Ikuta S,** Tanimura K, Yasui C, Aihara T, Yoshie H, Iida H, Beppu N, Kurimoto A, Yanagi H, Mitsunobu M, Yamanaka N. Chronic liver disease increases the risk of linezolid-related thrombocytopenia in methicillin-resistant Staphylococcus aureus-infected patients after digestive surgery. *J Infect Chemother* 2011; **17**: 388-391 [PMID: 21161560 DOI: 10.1007/s10156-010-0188-8]
- 18 **Nukui Y,** Hatakeyama S, Okamoto K, Yamamoto T, Hisaka A, Suzuki H, Yata N, Yotsuyanagi H, Moriya K. High plasma linezolid concentration and impaired renal function affect development of linezolid-induced thrombocytopenia. *J Antimicrob Chemother* 2013; **68**: 2128-2133 [PMID: 23625638 DOI: 10.1093/jac/dkt133]
- 19 **Matsumoto K,** Shigemitsu A, Takeshita A, Watanabe E, Yokoyama Y, Ikawa K, Morikawa N, Takeda Y. Analysis of thrombocytopenic effects and population pharmacokinetics of linezolid: a dosage strategy according to the trough concentration target and renal function in adult patients. *Int J Antimicrob Agents* 2014; **44**: 242-247 [PMID: 25108880 DOI: 10.1016/j.ijantimicag.2014.05.010]

- 20 **Komiya K**, Ishii H, Tsubone T, Okabe E, Matsumoto B, Kadota J. Bird fancier's lung complicated by pulmonary nocardiosis. *J Bras Pneumol* 2013; **39**: 102-107 [PMID: [23503493](#) DOI: [10.1590/s1806-37132013000100015](#)]
- 21 **Yaşar Z**, Acat M, Onaran H, Özgül MA, Fener N, Talay F, Cetinkaya E. An unusual case of pulmonary nocardiosis in immunocompetent patient. *Case Rep Pulmonol* 2014; **2014**: 963482 [PMID: [25506020](#) DOI: [10.1155/2014/963482](#)]
- 22 **Cooper CJ**, Said S, Popp M, Alkhateeb H, Rodriguez C, Porres Aguilar M, Alozie O. A complicated case of an immunocompetent patient with disseminated nocardiosis. *Infect Dis Rep* 2014; **6**: 5327 [PMID: [24757510](#) DOI: [10.4081/idr.2014.5327](#)]
- 23 **Yagi K**, Ishii M, Namkoong H, Asami T, Fujiwara H, Nishimura T, Saito F, Kimizuka Y, Asakura T, Suzuki S, Kamo T, Tasaka S, Gono T, Kamei K, Betsuyaku T, Hasegawa N. Pulmonary nocardiosis caused by *Nocardia cyriacigeorgica* in patients with *Mycobacterium avium* complex lung disease: two case reports. *BMC Infect Dis* 2014; **14**: 684 [PMID: [25491030](#) DOI: [10.1186/s12879-014-0684-z](#)]
- 24 **Ibrahim U**, Saqib A, Mohammad F, Terjanian T. An Unusual Presentation of Nocardiosis in an Allogeneic Transplant Recipient. *Cureus* 2016; **8**: e834 [PMID: [27904816](#) DOI: [10.7759/cureus.834](#)]
- 25 **Mendonca NP**, Kadayakkara DK, Forde IC, Rudkovskaia A, Saul ZK, Lobo DJ. Pulmonary Nocardiosis in a Multiple Myeloma Patient Treated with Proteasome Inhibitors. *Am J Case Rep* 2016; **17**: 76-78 [PMID: [26861506](#) DOI: [10.12659/ajcr.896280](#)]
- 26 **Jayaschandran V**, Gjorgova-Gjeorgievski S, Siddique H. Pulmonary nocardiosis in a patient with idiopathic CD4 T-lymphocytopenia. *Respirol Case Rep* 2018; **6**: e00283 [PMID: [29321927](#) DOI: [10.1002/rccr.2.283](#)]
- 27 **Khadka P**, Basnet RB, Khadka P, Shah DS, Pokhrel BM, Rijal BP, Sherchand JB. Disseminated Nocardiosis in renal transplant recipient under therapy for pulmonary tuberculosis: a case report. *BMC Res Notes* 2017; **10**: 83 [PMID: [28159010](#) DOI: [10.1186/s13104-017-2408-0](#)]
- 28 **Kobayashi K**, Asakura T, Ishii M, Ueda S, Irie H, Ozawa H, Saitoh K, Kurihara I, Itoh H, Betsuyaku T. Pulmonary nocardiosis mimicking small cell lung cancer in ectopic ACTH syndrome associated with transformation of olfactory neuroblastoma: a case report. *BMC Pulm Med* 2018; **18**: 142 [PMID: [30134888](#) DOI: [10.1186/s12890-018-0710-9](#)]
- 29 **Khaliq MF**, Ihle RE, Schirtzinger CP. *Cladophialophora bantiana* Cerebral Phaeohyphomycosis Complicated by Pulmonary Nocardiosis: A Tale of Two Infections. *Case Rep Infect Dis* 2019; **2019**: 4352040 [PMID: [31143481](#) DOI: [10.1155/2019/4352040](#)]
- 30 **Miyaoka C**, Nakamoto K, Shirai T, Miyamoto M, Sasaki Y, Ohta K. Pulmonary nocardiosis caused by *Nocardia exalbida* mimicking lung cancer. *Respirol Case Rep* 2019; **7**: e00458 [PMID: [31304018](#) DOI: [10.1002/rccr.2.458](#)]
- 31 **Kato K**, Noguchi S, Naito K, Ikushima I, Hanaka T, Yamasaki K, Kawanami T, Yatera K. Pulmonary Nocardiosis Caused by *Nocardia exalbida* in a Patient with Lung Cancer and Radiation Pneumonitis: A Case Report and Literature Review. *Intern Med* 2019; **58**: 1605-1611 [PMID: [30713323](#) DOI: [10.2169/internalmedicine.2177-18](#)]
- 32 **Deterding L**, Körner T, Borte G, Wirtz H, Seyfarth HJ. Nocardiosis mimicking lung cancer in a heart transplant patient with end-stage renal disease. *Respir Med Case Rep* 2020; **30**: 101101 [PMID: [32528841](#) DOI: [10.1016/j.rmcr.2020.101101](#)]
- 33 **Campoli C**, Ferraro S, Salfi N, Coladonato S, Morelli MC, Giannella M, Ambretti S, Viale PL, Cricca M. Diffuse primary cutaneous infection by *Alternaria alternata* in a liver transplant recipient with pulmonary nocardiosis: Importance of prompt identification for clinical resolution. *Med Mycol Case Rep* 2020; **28**: 42-45 [PMID: [32420014](#) DOI: [10.1016/j.mmcr.2020.04.007](#)]
- 34 **Meena DS**, Kumar D, Bohra GK, Garg MK, Yadav P, Sharma A, Abhishek KS, Garg P, Pamnani J. Pulmonary Nocardiosis with Aspergillosis in a patient with COPD: A rare co-infection. *IDCases* 2020; **20**: e00766 [PMID: [32368494](#) DOI: [10.1016/j.idcr.2020.e00766](#)]
- 35 **Wu XK**, Lin Q. Pulmonary alveolar proteinosis complicated with nocardiosis: A case report and review of the literature. *World J Clin Cases* 2021; **9**: 2874-2883 [PMID: [33969072](#) DOI: [10.12998/wjcc.v9.i12.2874](#)]
- 36 **Atemnkeng F**, Ducey J, Khalil A, Elemam A, Diaz K. Diagnosing Disseminated Nocardiosis in a Patient With COVID-19 Pneumonia. *J Med Cases* 2021; **12**: 319-324 [PMID: [34429798](#) DOI: [10.14740/jmc3716](#)]



Published by **Baishideng Publishing Group Inc**
7041 Koll Center Parkway, Suite 160, Pleasanton, CA 94566, USA

Telephone: +1-925-3991568

E-mail: bpgoffice@wjgnet.com

Help Desk: <https://www.f6publishing.com/helpdesk>

<https://www.wjgnet.com>

