

# World Journal of *Clinical Cases*

*World J Clin Cases* 2022 October 16; 10(29): 10391-10822



## Contents

Thrice Monthly Volume 10 Number 29 October 16, 2022

## STANDARD AND CONSENSUS

- 10391** Baishideng's Reference Citation Analysis database announces the first Article Influence Index of multidisciplinary scholars

Wang JL, Ma YJ, Ma L, Ma N, Guo DM, Ma LS

## REVIEW

- 10399** Cholecystectomy for asymptomatic gallstones: Markov decision tree analysis

Lee BJH, Yap QV, Low JK, Chan YH, Shelat VG

- 10413** Liver transplantation for hepatocellular carcinoma: Historical evolution of transplantation criteria

Ince V, Sahin TT, Akbulut S, Yilmaz S

## MINIREVIEWS

- 10428** Prostate only radiotherapy using external beam radiotherapy: A clinician's perspective

Lee JW, Chung MJ

## ORIGINAL ARTICLE

## Retrospective Study

- 10435** Age-adjusted NT-proBNP could help in the early identification and follow-up of children at risk for severe multisystem inflammatory syndrome associated with COVID-19 (MIS-C)

Rodriguez-Gonzalez M, Castellano-Martinez A

- 10451** Clinicopathological characteristics and prognosis of gastric signet ring cell carcinoma

Tian HK, Zhang Z, Ning ZK, Liu J, Liu ZT, Huang HY, Zong Z, Li H

- 10467** Development and validation of a prognostic nomogram for decompensated liver cirrhosis

Zhang W, Zhang Y, Liu Q, Nie Y, Zhu X

## Observational Study

- 10478** Effect of medical care linkage-continuous management mode in patients with posterior circulation cerebral infarction undergoing endovascular interventional therapy

Zhu FX, Ye Q

- 10487** Effect of the COVID-19 pandemic on patients with presumed diagnosis of acute appendicitis

Akbulut S, Tuncer A, Ogut Z, Sahin TT, Koc C, Guldogan E, Karabulut E, Tanriverdi ES, Ozer A

**EVIDENCE-BASED MEDICINE**

- 10501** Delineation of a SMARCA4-specific competing endogenous RNA network and its function in hepatocellular carcinoma

*Zhang L, Sun T, Wu XY, Fei FM, Gao ZZ*

**SYSTEMATIC REVIEWS**

- 10516** Comparison of laboratory parameters, clinical symptoms and clinical outcomes of COVID-19 and influenza in pediatric patients: A systematic review and meta-analysis

*Yu B, Chen HH, Hu XF, Mai RZ, He HY*

**CASE REPORT**

- 10529** Surgical treatment of bipolar segmental clavicle fracture: A case report  
*Liang L, Chen XL, Chen Y, Zhang NN*
- 10535** Multiple disciplinary team management of rare primary splenic malignancy: Two case reports  
*Luo H, Wang T, Xiao L, Wang C, Yi H*
- 10543** Klippel-Trenaunay-Weber syndrome with ischemic stroke: A case report  
*Lee G, Choi T*
- 10550** Vedolizumab in the treatment of immune checkpoint inhibitor-induced colitis: Two case reports  
*Zhang Z, Zheng CQ*
- 10559** Novel way of patent foramen ovale detection and percutaneous closure by intracardiac echocardiography: A case report  
*Han KN, Yang SW, Zhou YJ*
- 10565** Treatment failure in a patient infected with *Listeria* sepsis combined with latent meningitis: A case report  
*Wu GX, Zhou JY, Hong WJ, Huang J, Yan SQ*
- 10575** Three-in-one incidence of hepatocellular carcinoma, cholangiocellular carcinoma, and neuroendocrine carcinoma: A case report  
*Wu Y, Xie CB, He YH, Ke D, Huang Q, Zhao KF, Shi RS*
- 10583** Intestinal microbiome changes in an infant with right atrial isomerism and recurrent necrotizing enterocolitis: A case report and review of literature  
*Kaplina A, Zaikova E, Ivanov A, Volkova Y, Alkhova T, Nikiforov V, Latypov A, Khavkina M, Fedoseeva T, Pervunina T, Skorobogatova Y, Volkova S, Ulyantsev V, Kalinina O, Sitkin S, Petrova N*
- 10600** *Serratia fonticola* and its role as a single pathogen causing emphysematous pyelonephritis in a non-diabetic patient: A case report  
*Villasuso-Alcocer V, Flores-Tapia JP, Perez-Garfias F, Rochel-Perez A, Mendez-Dominguez N*
- 10606** Cardiac myxoma shedding leads to lower extremity arterial embolism: A case report  
*Meng XH, Xie LS, Xie XP, Liu YC, Huang CP, Wang LJ, Zhang GH, Xu D, Cai XC, Fang X*

- 10614** Extracorporeal membrane oxygenation in curing a young man after modified Fontan operation: A case report  
*Guo HB, Tan JB, Cui YC, Xiong HF, Li CS, Liu YF, Sun Y, Pu L, Xiang P, Zhang M, Hao JJ, Yin NN, Hou XT, Liu JY*
- 10622** Wandering small intestinal stromal tumor: A case report  
*Su JZ, Fan SF, Song X, Cao LJ, Su DY*
- 10629** Acute mesenteric ischemia secondary to oral contraceptive-induced portomesenteric and splenic vein thrombosis: A case report  
*Zhao JW, Cui XH, Zhao WY, Wang L, Xing L, Jiang XY, Gong X, Yu L*
- 10638** Perioperative anesthesia management in pediatric liver transplant recipient with atrial septal defect: A case report  
*Liu L, Chen P, Fang LL, Yu LN*
- 10647** Multiple tophi deposits in the spine: A case report  
*Chen HJ, Chen DY, Zhou SZ, Chi KD, Wu JZ, Huang FL*
- 10655** Myeloproliferative neoplasms complicated with  $\beta$ -thalassemia: Two case report  
*Xu NW, Li LJ*
- 10663** Synchronous renal pelvis carcinoma associated with small lymphocytic lymphoma: A case report  
*Yang HJ, Huang X*
- 10670** *Leclercia adecarboxylata* infective endocarditis in a man with mitral stenosis: A case report and review of the literature  
*Tan R, Yu JQ, Wang J, Zheng RQ*
- 10681** Progressive ataxia of cerebrotendinous xanthomatosis with a rare c.255+1G>T splice site mutation: A case report  
*Chang YY, Yu CQ, Zhu L*
- 10689** Intravesical explosion during transurethral resection of bladder tumor: A case report  
*Xu CB, Jia DS, Pan ZS*
- 10695** Submucosal esophageal abscess evolving into intramural submucosal dissection: A case report  
*Jiao Y, Sikong YH, Zhang AJ, Zuo XL, Gao PY, Ren QG, Li RY*
- 10701** Immune checkpoint inhibitor-associated arthritis in advanced pulmonary adenocarcinoma: A case report  
*Yang Y, Huang XJ*
- 10708** Chondroid syringoma of the lower back simulating lipoma: A case report  
*Huang QF, Shao Y, Yu B, Hu XP*
- 10713** Tension-reduced closure of large abdominal wall defect caused by shotgun wound: A case report  
*Li Y, Xing JH, Yang Z, Xu YJ, Yin XY, Chi Y, Xu YC, Han YD, Chen YB, Han Y*

- 10721** Myocardial bridging phenomenon is not invariable: A case report  
*Li HH, Liu MW, Zhang YF, Song BC, Zhu ZC, Zhao FH*
- 10728** Recurrent atypical leiomyoma in bladder trigone, confused with uterine fibroids: A case report  
*Song J, Song H, Kim YW*
- 10735** Eczema herpeticum *vs* dermatitis herpetiformis as a clue of dedicator of cytokinesis 8 deficiency diagnosis: A case report  
*Alshengeti A*
- 10742** Cutaneous allergic reaction to subcutaneous vitamin K<sub>1</sub>: A case report and review of literature  
*Zhang M, Chen J, Wang CX, Lin NX, Li X*
- 10755** Perithyroidal hemorrhage caused by hydrodissection during radiofrequency ablation for benign thyroid nodules: Two case reports  
*Zheng BW, Wu T, Yao ZC, Ma YP, Ren J*
- 10763** Malignant giant cell tumors of the tendon sheath of the right hip: A case report  
*Huang WP, Gao G, Yang Q, Chen Z, Qiu YK, Gao JB, Kang L*
- 10772** Atypical Takotsubo cardiomyopathy presenting as acute coronary syndrome: A case report  
*Wang ZH, Fan JR, Zhang GY, Li XL, Li L*
- 10779** Secondary light chain amyloidosis with Waldenström's macroglobulinemia and internodal marginal zone lymphoma: A case report  
*Zhao ZY, Tang N, Fu XJ, Lin LE*
- 10787** Bilateral occurrence of sperm granulomas in the left spermatic cord and on the right epididymis: A case report  
*Ly DY, Xie HJ, Cui F, Zhou HY, Shuang WB*
- 10794** Glucocorticoids combined with tofacitinib in the treatment of Castleman's disease: A case report  
*Liu XR, Tian M*
- 10803** Giant bilateral scrotal lipoma with abnormal somatic fat distribution: A case report  
*Chen Y, Li XN, Yi XL, Tang Y*
- 10811** Elevated procalcitonin levels in the absence of infection in procalcitonin-secreting hepatocellular carcinoma: A case report  
*Zeng JT, Wang Y, Wang Y, Luo ZH, Qing Z, Zhang Y, Zhang YL, Zhang JF, Li DW, Luo XZ*

**LETTER TO THE EDITOR**

- 10817** "Helicobacter pylori treatment guideline: An Indian perspective": Letter to the editor  
*Swarnakar R, Yadav SL*
- 10820** Effect of gender on the reliability of COVID-19 rapid antigen test among elderly  
*Nori W, Akram W*

**ABOUT COVER**

Editorial Board Member of *World Journal of Clinical Cases*, Natalia Stepanova, DSc, MD, PhD, Academic Research, Chief Doctor, Full Professor, Department of Nephrology and Dialysis, State Institution "Institute of Nephrology of the National Academy of Medical Sciences of Ukraine", Kyiv 04050, Ukraine. nmstep88@gmail.com

**AIMS AND SCOPE**

The primary aim of *World Journal of Clinical Cases* (WJCC, *World J Clin Cases*) is to provide scholars and readers from various fields of clinical medicine with a platform to publish high-quality clinical research articles and communicate their research findings online.

WJCC mainly publishes articles reporting research results and findings obtained in the field of clinical medicine and covering a wide range of topics, including case control studies, retrospective cohort studies, retrospective studies, clinical trials studies, observational studies, prospective studies, randomized controlled trials, randomized clinical trials, systematic reviews, meta-analysis, and case reports.

**INDEXING/ABSTRACTING**

The WJCC is now abstracted and indexed in Science Citation Index Expanded (SCIE, also known as SciSearch®), Journal Citation Reports/Science Edition, Current Contents®/Clinical Medicine, PubMed, PubMed Central, Scopus, Reference Citation Analysis, China National Knowledge Infrastructure, China Science and Technology Journal Database, and Superstar Journals Database. The 2022 Edition of Journal Citation Reports® cites the 2021 impact factor (IF) for WJCC as 1.534; IF without journal self cites: 1.491; 5-year IF: 1.599; Journal Citation Indicator: 0.28; Ranking: 135 among 172 journals in medicine, general and internal; and Quartile category: Q4. The WJCC's CiteScore for 2021 is 1.2 and Scopus CiteScore rank 2021: General Medicine is 443/826.

**RESPONSIBLE EDITORS FOR THIS ISSUE**

Production Editor: Hua-Ge Yin; Production Department Director: Xiang Li; Editorial Office Director: Jin-Lei Wang.

**NAME OF JOURNAL**

*World Journal of Clinical Cases*

**ISSN**

ISSN 2307-8960 (online)

**LAUNCH DATE**

April 16, 2013

**FREQUENCY**

Thrice Monthly

**EDITORS-IN-CHIEF**

Bao-Gan Peng, Jerzy Tadeusz Chudek, George Kontogeorgos, Maurizio Serati, Ja Hyeon Ku

**EDITORIAL BOARD MEMBERS**

<https://www.wjgnet.com/2307-8960/editorialboard.htm>

**PUBLICATION DATE**

October 16, 2022

**COPYRIGHT**

© 2022 Baishideng Publishing Group Inc

**INSTRUCTIONS TO AUTHORS**

<https://www.wjgnet.com/bpg/gerinfo/204>

**GUIDELINES FOR ETHICS DOCUMENTS**

<https://www.wjgnet.com/bpg/GerInfo/287>

**GUIDELINES FOR NON-NATIVE SPEAKERS OF ENGLISH**

<https://www.wjgnet.com/bpg/gerinfo/240>

**PUBLICATION ETHICS**

<https://www.wjgnet.com/bpg/GerInfo/288>

**PUBLICATION MISCONDUCT**

<https://www.wjgnet.com/bpg/gerinfo/208>

**ARTICLE PROCESSING CHARGE**

<https://www.wjgnet.com/bpg/gerinfo/242>

**STEPS FOR SUBMITTING MANUSCRIPTS**

<https://www.wjgnet.com/bpg/GerInfo/239>

**ONLINE SUBMISSION**

<https://www.f6publishing.com>





## Immune checkpoint inhibitor-associated arthritis in advanced pulmonary adenocarcinoma: A case report

Yan Yang, Xiao-Jie Huang

**Specialty type:** Oncology

**Provenance and peer review:**

Unsolicited article; Externally peer reviewed.

**Peer-review model:** Single blind

**Peer-review report's scientific quality classification**

Grade A (Excellent): A

Grade B (Very good): B

Grade C (Good): 0

Grade D (Fair): 0

Grade E (Poor): 0

**P-Reviewer:** Dauey K,  
Kazakhstan; Tovoli F, Italy

**Received:** May 10, 2022

**Peer-review started:** May 10, 2022

**First decision:** June 27, 2022

**Revised:** July 16, 2022

**Accepted:** September 1, 2022

**Article in press:** September 1, 2022

**Published online:** October 16, 2022



**Yan Yang, Xiao-Jie Huang**, Department of Respiratory Medicine, The Second Affiliated Hospital, Zhejiang University School of Medicine, Hangzhou 310000, Zhejiang Province, China

**Corresponding author:** Yan Yang, MM, Associate Chief Physician, Department of Respiratory Medicine, The Second Affiliated Hospital, Zhejiang University School of Medicine, No. 88 Jiefang Road, Hangzhou 310000, Zhejiang Province, China. [163987@zju.edu.cn](mailto:163987@zju.edu.cn)

### Abstract

#### BACKGROUND

With the wide application of immune checkpoint inhibitors (ICIs) in cancer treatment, immune-related adverse events occur frequently, involving almost all organs and systems. The incidence of ICI-associated arthritis (IA) is unknown. In most cases, IA is not serious and non-lethal. Higher checkpoint inhibitor arthritis disease activity may be associated with cancer progression. Here, we report a severe case of IA with high arthritis disease activity in advanced pulmonary adenocarcinoma, causing permanent withdrawal of pembrolizumab, but the patient remained in complete remission (CR) 20 mo after the development of IA.

#### CASE SUMMARY

An 81-year-old smoking man was admitted to our hospital because of left chest pain for 9 mo. He was finally diagnosed with advanced pulmonary adenocarcinoma, with programmed cell death 1 ligand 1 expression of 70%. The patient responded to pembrolizumab treatment and achieved CR, but IA occurred after the 5<sup>th</sup> cycle of pembrolizumab administration. Although non-steroidal anti-inflammatory drugs and disease-modifying anti-rheumatic drugs were prescribed, arthralgia and joint swelling occurred. The symptoms of arthritis were further aggravated when immunotherapy was given again after short-term withdrawal. Clinical Disease Activity Index (CDAI) score, a traditional measure of arthritis activity, was 43. Intravenous methylprednisolone was prescribed at 20 mg/d and then tapered over the subsequent 4 wk. The symptoms of arthritis steadily improved and completely resolved 4 mo after withdrawal of pembrolizumab. A recent follow-up in June 2022 revealed satisfactory clinical recovery of arthritis and the patient remained in CR.

#### CONCLUSION

This case report highlights that early recognition of IA and appropriate treatment are critical to improving the outcome of both ICI-arthritis and lung cancer.

**Key Words:** Immune checkpoint inhibitors; Immune checkpoint inhibitor-associated arthritis; Pembrolizumab; Clinical Disease Activity Index; Case report

©The Author(s) 2022. Published by Baishideng Publishing Group Inc. All rights reserved.

**Core Tip:** We report a severe case of immune checkpoint inhibitor-associated arthritis (IA) in advanced pulmonary adenocarcinoma. A recent study suggested that higher checkpoint inhibitor arthritis disease activity may be associated with cancer progression. In our case, Clinical Disease Activity Index (CDAI) score increased to as high as 43, but cancer disease remained in complete remission 20 mo after the development of IA. Whether CDAI can be a predictor of disease progression needs to be confirmed in future studies.

**Citation:** Yang Y, Huang XJ. Immune checkpoint inhibitor-associated arthritis in advanced pulmonary adenocarcinoma: A case report. *World J Clin Cases* 2022; 10(29): 10701-10707

**URL:** <https://www.wjgnet.com/2307-8960/full/v10/i29/10701.htm>

**DOI:** <https://dx.doi.org/10.12998/wjcc.v10.i29.10701>

## INTRODUCTION

Immune checkpoint inhibitors (ICIs) have resulted in a marked change in the therapeutic modality of non-small cell lung cancer (NSCLC). However, due to the widespread application of ICIs, immune-related adverse events (irAEs) involving all organs and systems may occur due to immunological enhancement. ICI-associated arthritis (IA) is rarely reported as case reports or in randomized controlled clinical studies. The reason for this may be that the symptoms such as joint pain are usually not serious and are non-fatal. Therefore, it does not attract enough attention from patients and clinicians, and the diagnosis is easily missed. In addition, some patients have osteoarthritis, which is easily confused with immune-related arthritis symptoms by patients themselves. With the wide application of immunotherapy in the field of cancer, we have reason to believe that many more cases of IA will be reported. In most cases, IA is mild or moderate and non-fatal. However, it can affect the life quality of patients, reduce their confidence in disease treatment, interrupt the treatment plan, and finally affect the treatment effect or survival. Prompt recognition and appropriate treatment are critical to improving the outcome of IA, which can be realized if physicians are familiar with the clinical manifestations and therapeutic measures. However, in clinical practice, sometimes the diagnosis of IA is difficult or delayed.

Herein, we report a case of IA in a patient with advanced lung adenocarcinoma treated with pembrolizumab. The patient achieved complete remission (CR), but had to permanently discontinue pembrolizumab after 10 treatment cycles due to severe IA. A recent study found that Clinical Disease Activity Index (CDAI) may be a predictor of disease progression[1]. Our patient had a high CDAI score of 43, but remained in CR 20 mo after the development of IA. Thus, whether the CDAI can be used a predictor of disease progression requires confirmation in future studies.

## CASE PRESENTATION

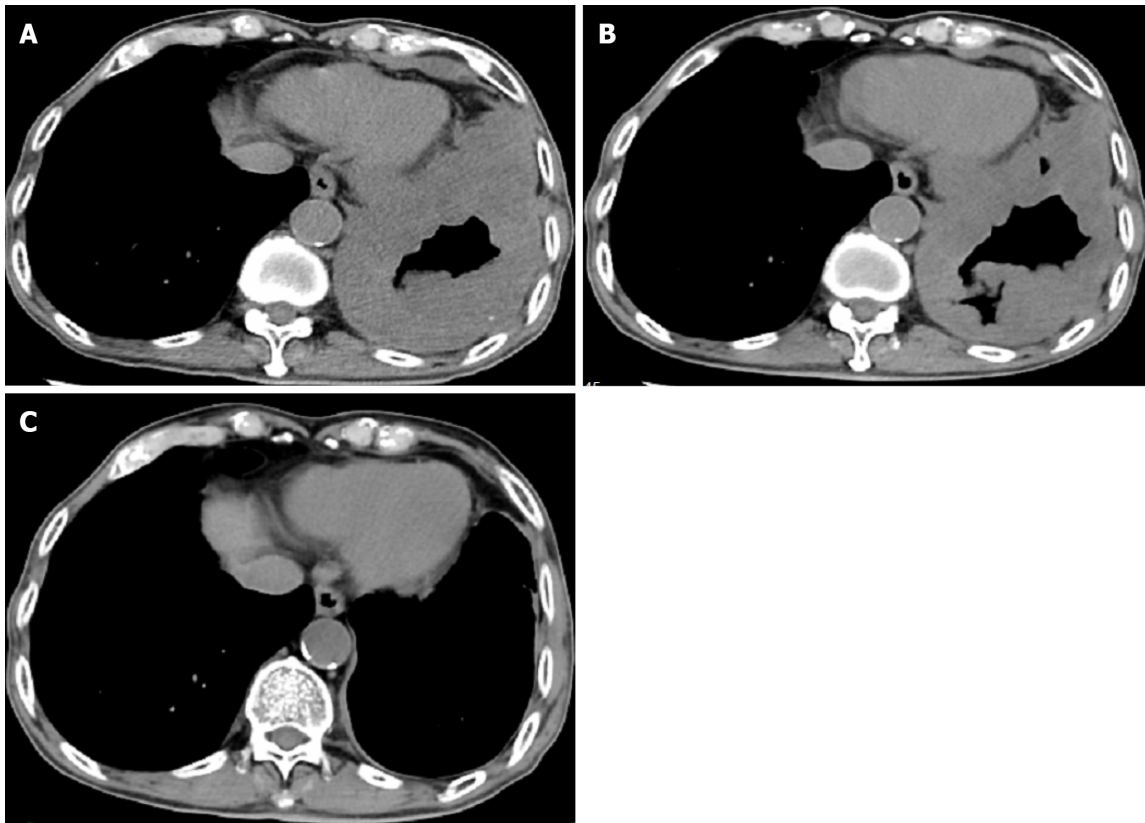
### Chief complaints

An 81-year-old smoking man complained of bilateral wrist, knee and ankle pain (grade 1) with mild edema (grade 1) after the 5<sup>th</sup> cycle of pembrolizumab administration for lung cancer.

### History of present illness

The patient was admitted to the Second Affiliated Hospital, Zhejiang University School of Medicine on May 31, 2020 due to left chest pain for 9 mo. Diffuse thickening of the left pleura and interlobar pleura was found on a chest computed tomography (CT) scan (Figure 1A). CT-guided lung puncture was performed and pathology revealed adenocarcinoma of the lung, with programmed cell death 1 ligand 1 (PD-L1) expression of 70%. He was finally diagnosed with NSCLC (stage IV, adenocarcinoma) at our hospital. Lung cancer related genes including *EGFR*, *ALK*, and *ROS1* were negative. The patient was treated with first-line pembrolizumab monotherapy at a standard dosage of 2 mg/kg every 3 wk. From June 2020 to August 2020, the patient received three cycles of pembrolizumab. His left chest pain was relieved and chest CT scanning revealed stable disease (Figure 1B). The patient complained of mild





DOI: 10.12998/wjcc.v10.i29.10701 Copyright ©The Author(s) 2022.

**Figure 1** Chest computed tomography images. A: Chest computed tomography (CT) before therapy; B: Chest CT after three cycles of pembrolizumab; C: Chest CT after five cycles of pembrolizumab.

weakness, which was grade 1 according to the Common Terminology Criteria for Adverse Events (CTCAE v4.0). Another two cycles of pembrolizumab were administered. Left chest pain disappeared and he achieved CR ([Figure 1C](#)).

#### **History of past illness**

The patient had a history of lumbar 2 vertebral compression fractures and recovered well after surgical treatment.

#### **Personal and family history**

The patient had smoked for more than 50 years, 20 cigarettes/d, and stopped smoking following the diagnosis of lung cancer. He had a history of penicillin anaphylaxis. The patient had no previous rheumatoid arthritis or rheumatic immune system diseases.

#### **Physical examination**

Bilateral wrists, knees, and ankles showed slightly depressed edema with pain. Functional limitation was reported and symptoms did not abate after mobilization.

#### **Laboratory examinations**

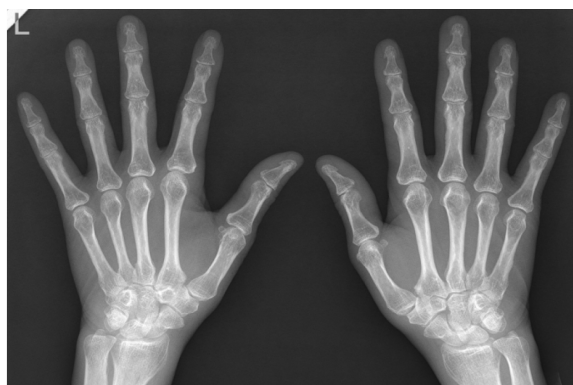Anti-cyclic citrullinated peptide antibody, rheumatoid factor, antinuclear antibody, anti-neutrophil cytoplasmic antibodies, and hepatic and renal function analysis were performed and were found to be normal. C-reactive protein level was 18.5 mg/L, and the erythrocyte sedimentation rate was 44 mm/h. The CDAI score was 43.

#### **Imaging examinations**

X-ray of the hands was normal ([Figure 2](#)).

### **FINAL DIAGNOSIS**

IA and advanced lung adenocarcinoma.



DOI: 10.12998/wjcc.v10.i29.10701 Copyright ©The Author(s) 2022.

Figure 2 X-ray of the patient's hands.

## TREATMENT

Non-steroidal anti-inflammatory drugs (NSAIDs) were administered and treatment with pembrolizumab was continued. However, the manifestations of arthritis persisted, defined as arthralgia (grade 1) and swollen joints (grade 2). After consultation with a rheumatic immunologist, diuretics and disease modifying anti-rheumatic drugs (DMARDs) were prescribed. Pembrolizumab was discontinued temporarily. When IA returned to grade 1, pembrolizumab therapy was continued. After the 10<sup>th</sup> cycle of pembrolizumab administration, pain in the fingers, wrists, and ankles increased (grade 3). The life quality of the patient was seriously affected due to joint swelling and pain. In addition, the patient felt anxious and fearful of lung cancer progression. Intravenous methylprednisolone at 20 mg/d was prescribed and then tapered over the subsequent 4 wk.

## OUTCOME AND FOLLOW-UP

The symptoms of arthritis steadily improved after steroid treatment and completely resolved 4 mo after withdrawal of immunotherapy. A recent follow-up in June 2022 revealed satisfactory clinical recovery of arthritis and lung cancer was still in CR as shown by CT scanning.

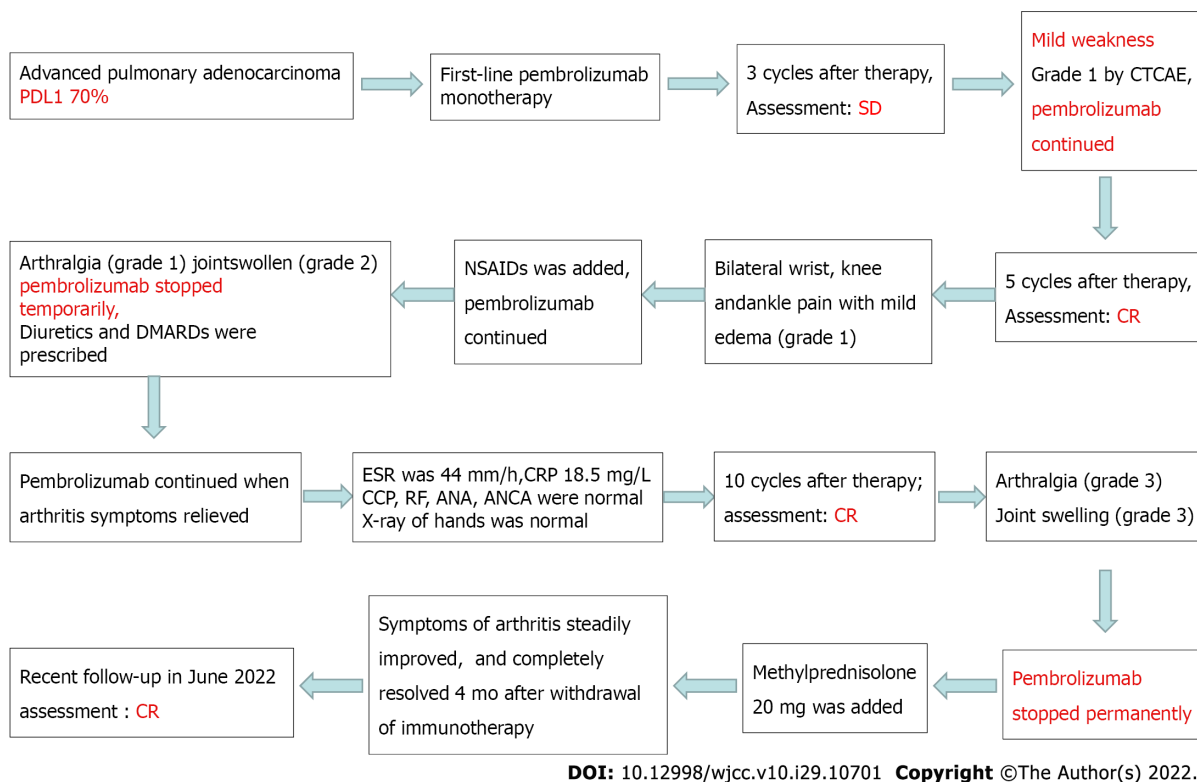
## DISCUSSION

ICIs have been confirmed to be an effective treatment modality and are widely used for the treatment of NSCLC. With increasing use of ICIs, a large spectrum of immune side effects, described as irAEs, have emerged. Dermatologic, gastrointestinal, pulmonary, cardiac, endocrine, skin, and rheumatologic systems, and almost all organs of the body can be affected[2,3]. Unlike irAEs in other systems, rheumatic irAEs are mainly reported in case reports, and are usually ignored in the clinic both by patients and physicians[4]. Arthralgia/arthritis and myalgia/myositis are the most frequently reported rheumatic irAEs[5]. A single-center prospective cohort study reported the incidence of IA to be 3.8%[6].

The most frequent clinical manifestations of IA are similar to those of rheumatoid arthritis[7,8]. As in our case, IA is characterized by small-joint involvement of the metacarpophalangeal joint, proximal interphalangeal joint, the wrist, knee, and feet[4]. Rheumatoid factor and anti-citrullinated peptide antibody levels are usually normal[9]. Another relatively rare phenotype closely resembles that of spinal arthritis, which is characterized by large joint involvement, such as inflammatory back pain, adhesion point inflammation, and phalangitis[10-12]. Unlike spinal arthritis, human leukocyte antigen-B27 was negative in most of these patients[13].

The time to arthritis occurrence after administration of ICIs varies, ranging from 2 mo to 24 mo, and symptoms may persist for more than 1 year[14-18], regardless of whether the ICI is discontinued[1]. The persistence of IA demonstrated in our study lasted 9 mo (4 mo after pembrolizumab discontinuation), which was consistent with other reported cases[19,20].

The treatment principles recommended by the National Comprehensive Cancer Network, European Society for Medical Oncology, and Chinese Society of Clinical Oncology guidelines are basically the same. Therapeutic drugs mainly include NSAIDs, glucocorticoids, and DMARDs. For patients with irAEs above the G2 level, most require systemic corticosteroids in addition to DMARDs. A large single-institution retrospective study found that 37% of patients with musculoskeletal irAEs needed either higher prednisone doses or low-dose maintenance therapy. Several patients even received steroids for



**Figure 3 Flow diagram of the treatment process.** PD-L1: Programmed cell death 1 ligand 1; NSAID: Non-steroidal anti-inflammatory drugs; CTCAE: Common Terminology Criteria for Adverse Events; CR: Complete remission.

more than 1 year[21]. If symptoms do not improve after initial treatment, consultation with rheumatology experts is necessary for disease control. Some patients even require more than one type of immunosuppressive therapy.

IA patients rarely require hospitalization and most cases are defined as having grade 1 or 2 disease. However, some patients reported significant impairment both in function and emotion, even when characterized as low grade[1,21]. Thus, in addition to the CTCAE grade, the CDAI, a traditional measure of arthritis activity, is recommended to assess IA[1]. It is interesting that increased CDAI may be related to cancer progression[1]. However, in our case, the CDAI increased during the treatment of IA, but the patient remained in CR (Figure 3). Whether the CDAI can be used as a predictor of disease progression requires confirmation in future studies.

## CONCLUSION

Immunotherapy has opened a new chapter in the treatment of advanced NSCLC. However, with the wide application of ICIs, more and more irAEs have been reported. Rheumatic arthritis/myalgia has rarely been reported in previous clinical trials. However, the actual incidence in the real world may be much higher than the data shown in current clinical studies. During the course of immunotherapy, clinicians should pay attention to symptoms of arthritis, distinguish IA from traditional rheumatic diseases, and provide appropriate treatment. In addition to the CTCAE grade, the CDAI is recommended to assess IA. A recent study found that the CDAI may be a predictor of cancer disease progression, which needs to be confirmed in future studies. Early recognition of IA and appropriate treatment are critical to improving the outcome of both IA and lung cancer.

## ACKNOWLEDGEMENTS

We thank the patient for providing consent for the publication of this case report.

## FOOTNOTES

**Author contributions:** Yang Y designed the study, interpreted the data, and drafted the paper; Huang XJ participated in clinical treatment and revised the manuscript; both authors approved the final version to be published.

**Informed consent statement:** Informed written consent was obtained from the patient for the publication of this report and any accompanying images.

**Conflict-of-interest statement:** The authors declare that they have no conflict of interest to disclose.

**CARE Checklist (2016) statement:** The authors have read the CARE Checklist (2016), and the manuscript was prepared and revised according to the CARE Checklist (2016).

**Open-Access:** This article is an open-access article that was selected by an in-house editor and fully peer-reviewed by external reviewers. It is distributed in accordance with the Creative Commons Attribution NonCommercial (CC BY-NC 4.0) license, which permits others to distribute, remix, adapt, build upon this work non-commercially, and license their derivative works on different terms, provided the original work is properly cited and the use is non-commercial. See: <https://creativecommons.org/licenses/by-nc/4.0/>

**Country/Territory of origin:** China

**ORCID number:** Yang Yan 000000027448711X; Xiao-Jie Huang 0000000334417480.

**S-Editor:** Chen YL

**L-Editor:** Wang TQ

**P-Editor:** Chen YL

## REFERENCES

- 1 **Chan KK**, Tirpack A, Vitone G, Benson C, Nguyen J, Ghosh N, Jannat-Khah D, Bykerk V, Bass AR. Higher Checkpoint Inhibitor Arthritis Disease Activity may be Associated With Cancer Progression: Results From an Observational Registry. *ACR Open Rheumatol* 2020; **2**: 595-604 [PMID: 33010198 DOI: 10.1002/acr2.11181]
- 2 **Suarez-Almazor ME**, Kim ST, Abdel-Wahab N, Diab A. Review: Immune-Related Adverse Events With Use of Checkpoint Inhibitors for Immunotherapy of Cancer. *Arthritis Rheumatol* 2017; **69**: 687-699 [PMID: 28085999 DOI: 10.1002/art.40043]
- 3 **Khoja L**, Day D, Wei-Wu Chen T, Siu LL, Hansen AR. Tumour- and class-specific patterns of immune-related adverse events of immune checkpoint inhibitors: a systematic review. *Ann Oncol* 2017; **28**: 2377-2385 [PMID: 28945858 DOI: 10.1093/annonc/mdx286]
- 4 **Xiao Y**, Zeng L, Shen Q, Zhou Z, Mao Z, Wang Q, Zhang X, Li Y, Yao W. Diagnosis and Treatment of Rheumatic Adverse Events Related to Immune Checkpoint Inhibitors. *J Immunol Res* 2020; **2020**: 2640273 [PMID: 32832568 DOI: 10.1155/2020/2640273]
- 5 **Cappelli LC**, Gutierrez AK, Bingham CO 3rd, Shah AA. Rheumatic and Musculoskeletal Immune-Related Adverse Events Due to Immune Checkpoint Inhibitors: A Systematic Review of the Literature. *Arthritis Care Res (Hoboken)* 2017; **69**: 1751-1763 [PMID: 27998041 DOI: 10.1002/acr.23177]
- 6 **Kostine M**, Rouxel L, Barnette T, Veillon R, Martin F, Dutriaux C, Dousset L, Pham-Ledard A, Prey S, Beylot-Barry M, Daste A, Gross-Goupil M, Lallier J, Ravaud A, Forcade E, Bannwarth B, Truchetet ME, Richez C, Mehse N, Schaevebeke T; FHU ACRONIM. Rheumatic disorders associated with immune checkpoint inhibitors in patients with cancer-clinical aspects and relationship with tumour response: a single-centre prospective cohort study. *Ann Rheum Dis* 2018; **77**: 393-398 [PMID: 29146737 DOI: 10.1136/annrheumdis-2017-212257]
- 7 **Richter MD**, Crowson C, Kottschade LA, Finnes HD, Markovic SN, Thanarajasingam U. Rheumatic Syndromes Associated With Immune Checkpoint Inhibitors: A Single-Center Cohort of Sixty-One Patients. *Arthritis Rheumatol* 2019; **71**: 468-475 [PMID: 30281202 DOI: 10.1002/art.40745]
- 8 **Arnaud L**, Lebrun-Vignes B, Salem JE. Checkpoint inhibitor-associated immune arthritis. *Ann Rheum Dis* 2019; **78**: e68 [PMID: 29724725 DOI: 10.1136/annrheumdis-2018-213470]
- 9 **Haikal A**, Borba E, Khaja T, Doolittle G, Schmidt P. Nivolumab-induced new-onset seronegative rheumatoid arthritis in a patient with advanced metastatic melanoma: A case report and literature review. *Avicenna J Med* 2018; **8**: 34-36 [PMID: 29404271 DOI: 10.4103/ajm.AJM\_127\_17]
- 10 **Puzanov I**, Diab A, Abdallah K, Bingham CO 3rd, Brogdon C, Dadu R, Hamad L, Kim S, Lacouture ME, LeBoeuf NR, Lenihan D, Onofrei C, Shannon V, Sharma R, Silk AW, Skondra D, Suarez-Almazor ME, Wang Y, Wiley K, Kaufman HL, Ernstoff MS; Society for Immunotherapy of Cancer Toxicity Management Working Group. Managing toxicities associated with immune checkpoint inhibitors: consensus recommendations from the Society for Immunotherapy of Cancer (SITC) Toxicity Management Working Group. *J Immunother Cancer* 2017; **5**: 95 [PMID: 29162153 DOI: 10.1186/s40425-017-0300-z]
- 11 **Tocut M**, Brenner R, Zandman-Goddard G. Autoimmune phenomena and disease in cancer patients treated with immune checkpoint inhibitors. *Autoimmun Rev* 2018; **17**: 610-616 [PMID: 29631064 DOI: 10.1016/j.autrev.2018.01.010]
- 12 **Ohnuma K**, Hatano R, Dang NH, Morimoto C. Rheumatic diseases associated with immune checkpoint inhibitors in cancer immunotherapy. *Mod Rheumatol* 2019; **29**: 721-732 [PMID: 30285531 DOI: 10.1080/14397595.2018.1532559]

- 13 **Lee KA**, Kim HR, Yoon SY. Rheumatic complications in cancer patients treated with immune checkpoint inhibitors. *Korean J Intern Med* 2019; **34**: 1197-1209 [PMID: [31014065](#) DOI: [10.3904/kjim.2019.060](#)]
- 14 **Smith MH**, Bass AR. Arthritis After Cancer Immunotherapy: Symptom Duration and Treatment Response. *Arthritis Care Res (Hoboken)* 2019; **71**: 362-366 [PMID: [29125905](#) DOI: [10.1002/acr.23467](#)]
- 15 **Mooradian MJ**, Nasrallah M, Gainor JF, Reynolds KL, Cohen JV, Lawrence DP, Miloslavsky EM, Kohler MJ, Sullivan RJ, Schoenfeld SR. Musculoskeletal rheumatic complications of immune checkpoint inhibitor therapy: A single center experience. *Semin Arthritis Rheum* 2019; **48**: 1127-1132 [PMID: [30409415](#) DOI: [10.1016/j.semarthrit.2018.10.012](#)]
- 16 **Lidar M**, Giat E, Garelick D, Horowitz Y, Amital H, Steinberg-Silman Y, Schachter J, Shapira-Frommer R, Markel G. Rheumatic manifestations among cancer patients treated with immune checkpoint inhibitors. *Autoimmun Rev* 2018; **17**: 284-289 [PMID: [29341936](#) DOI: [10.1016/j.autrev.2018.01.003](#)]
- 17 **Cappelli LC**, Gutierrez AK, Baer AN, Albayda J, Manno RL, Haque U, Lipson EJ, Bleich KB, Shah AA, Naidoo J, Brahmer JR, Le D, Bingham CO 3rd. Inflammatory arthritis and sicca syndrome induced by nivolumab and ipilimumab. *Ann Rheum Dis* 2017; **76**: 43-50 [PMID: [27307501](#) DOI: [10.1136/annrheumdis-2016-209595](#)]
- 18 **Calabrese C**, Kirchner E, Kontzias A, Velcheti V, Calabrese LH. Correction: Rheumatic immune-related adverse events of checkpoint therapy for cancer: case series of a new nosological entity. *RMD Open* 2017; **3**: e000412corr1 [PMID: [29299345](#) DOI: [10.1136/rmdopen-2016-000412corr1](#)]
- 19 **Smolen JS**, Breedveld FC, Schiff MH, Kalden JR, Emery P, Eberl G, van Riel PL, Tugwell P. A simplified disease activity index for rheumatoid arthritis for use in clinical practice. *Rheumatology (Oxford)* 2003; **42**: 244-257 [PMID: [12595618](#) DOI: [10.1093/rheumatology/keg072](#)]
- 20 **Braaten TJ**, Brahmer JR, Forde PM, Le D, Lipson EJ, Naidoo J, Schollenberger M, Zheng L, Bingham CO, Shah AA, Cappelli LC. Immune checkpoint inhibitor-induced inflammatory arthritis persists after immunotherapy cessation. *Ann Rheum Dis* 2020; **79**: 332-338 [PMID: [31540935](#) DOI: [10.1136/annrheumdis-2019-216109](#)]
- 21 **Cappelli LC**, Grieb SM, Shah AA, Bingham CO 3rd, Orbai AM. Immune checkpoint inhibitor-induced inflammatory arthritis: a qualitative study identifying unmet patient needs and care gaps. *BMC Rheumatol* 2020; **4**: 32 [PMID: [32766511](#) DOI: [10.1186/s41927-020-00133-8](#)]



Published by **Baishideng Publishing Group Inc**  
7041 Koll Center Parkway, Suite 160, Pleasanton, CA 94566, USA

**Telephone:** +1-925-3991568

**E-mail:** [bpgoffice@wjgnet.com](mailto:bpgoffice@wjgnet.com)

**Help Desk:** <https://www.f6publishing.com/helpdesk>

<https://www.wjgnet.com>

