

World Journal of *Clinical Cases*

World J Clin Cases 2022 October 16; 10(29): 10391-10822



Contents

Thrice Monthly Volume 10 Number 29 October 16, 2022

STANDARD AND CONSENSUS

- 10391** Baishideng's *Reference Citation Analysis* database announces the first *Article Influence Index* of multidisciplinary scholars
Wang JL, Ma YJ, Ma L, Ma N, Guo DM, Ma LS

REVIEW

- 10399** Cholecystectomy for asymptomatic gallstones: Markov decision tree analysis
Lee BJH, Yap QV, Low JK, Chan YH, Shelat VG
- 10413** Liver transplantation for hepatocellular carcinoma: Historical evolution of transplantation criteria
Ince V, Sahin TT, Akbulut S, Yilmaz S

MINIREVIEWS

- 10428** Prostate only radiotherapy using external beam radiotherapy: A clinician's perspective
Lee JW, Chung MJ

ORIGINAL ARTICLE

Retrospective Study

- 10435** Age-adjusted NT-proBNP could help in the early identification and follow-up of children at risk for severe multisystem inflammatory syndrome associated with COVID-19 (MIS-C)
Rodriguez-Gonzalez M, Castellano-Martinez A
- 10451** Clinicopathological characteristics and prognosis of gastric signet ring cell carcinoma
Tian HK, Zhang Z, Ning ZK, Liu J, Liu ZT, Huang HY, Zong Z, Li H
- 10467** Development and validation of a prognostic nomogram for decompensated liver cirrhosis
Zhang W, Zhang Y, Liu Q, Nie Y, Zhu X

Observational Study

- 10478** Effect of medical care linkage-continuous management mode in patients with posterior circulation cerebral infarction undergoing endovascular interventional therapy
Zhu FX, Ye Q
- 10487** Effect of the COVID-19 pandemic on patients with presumed diagnosis of acute appendicitis
Akbulut S, Tuncer A, Ogut Z, Sahin TT, Koc C, Guldogan E, Karabulut E, Tanriverdi ES, Ozer A

EVIDENCE-BASED MEDICINE

- 10501** Delineation of a SMARCA4-specific competing endogenous RNA network and its function in hepatocellular carcinoma

Zhang L, Sun T, Wu XY, Fei FM, Gao ZZ

SYSTEMATIC REVIEWS

- 10516** Comparison of laboratory parameters, clinical symptoms and clinical outcomes of COVID-19 and influenza in pediatric patients: A systematic review and meta-analysis

Yu B, Chen HH, Hu XF, Mai RZ, He HY

CASE REPORT

- 10529** Surgical treatment of bipolar segmental clavicle fracture: A case report

Liang L, Chen XL, Chen Y, Zhang NN

- 10535** Multiple disciplinary team management of rare primary splenic malignancy: Two case reports

Luo H, Wang T, Xiao L, Wang C, Yi H

- 10543** Klippel-Trenaunay-Weber syndrome with ischemic stroke: A case report

Lee G, Choi T

- 10550** Vedolizumab in the treatment of immune checkpoint inhibitor-induced colitis: Two case reports

Zhang Z, Zheng CQ

- 10559** Novel way of patent foramen ovale detection and percutaneous closure by intracardiac echocardiography: A case report

Han KN, Yang SW, Zhou YJ

- 10565** Treatment failure in a patient infected with *Listeria* sepsis combined with latent meningitis: A case report

Wu GX, Zhou JY, Hong WJ, Huang J, Yan SQ

- 10575** Three-in-one incidence of hepatocellular carcinoma, cholangiocellular carcinoma, and neuroendocrine carcinoma: A case report

Wu Y, Xie CB, He YH, Ke D, Huang Q, Zhao KF, Shi RS

- 10583** Intestinal microbiome changes in an infant with right atrial isomerism and recurrent necrotizing enterocolitis: A case report and review of literature

Kaplina A, Zaikova E, Ivanov A, Volkova Y, Alkhova T, Nikiforov V, Latypov A, Khavkina M, Fedoseeva T, Pervunina T, Skorobogatova Y, Volkova S, Ulyantsev V, Kalinina O, Sitkin S, Petrova N

- 10600** *Serratia fonticola* and its role as a single pathogen causing emphysematous pyelonephritis in a non-diabetic patient: A case report

Villasuso-Alcocer V, Flores-Tapia JP, Perez-Garfias F, Rochel-Perez A, Mendez-Dominguez N

- 10606** Cardiac myxoma shedding leads to lower extremity arterial embolism: A case report

Meng XH, Xie LS, Xie XP, Liu YC, Huang CP, Wang LJ, Zhang GH, Xu D, Cai XC, Fang X

- 10614** Extracorporeal membrane oxygenation in curing a young man after modified Fontan operation: A case report
Guo HB, Tan JB, Cui YC, Xiong HF, Li CS, Liu YF, Sun Y, Pu L, Xiang P, Zhang M, Hao JJ, Yin NN, Hou XT, Liu JY
- 10622** Wandering small intestinal stromal tumor: A case report
Su JZ, Fan SF, Song X, Cao LJ, Su DY
- 10629** Acute mesenteric ischemia secondary to oral contraceptive-induced portomesenteric and splenic vein thrombosis: A case report
Zhao JW, Cui XH, Zhao WY, Wang L, Xing L, Jiang XY, Gong X, Yu L
- 10638** Perioperative anesthesia management in pediatric liver transplant recipient with atrial septal defect: A case report
Liu L, Chen P, Fang LL, Yu LN
- 10647** Multiple tophi deposits in the spine: A case report
Chen HJ, Chen DY, Zhou SZ, Chi KD, Wu JZ, Huang FL
- 10655** Myeloproliferative neoplasms complicated with β -thalassemia: Two case report
Xu NW, Li LJ
- 10663** Synchronous renal pelvis carcinoma associated with small lymphocytic lymphoma: A case report
Yang HJ, Huang X
- 10670** *Leclercia adecarboxylata* infective endocarditis in a man with mitral stenosis: A case report and review of the literature
Tan R, Yu JQ, Wang J, Zheng RQ
- 10681** Progressive ataxia of cerebrotendinous xanthomatosis with a rare c.255+1G>T splice site mutation: A case report
Chang YY, Yu CQ, Zhu L
- 10689** Intravesical explosion during transurethral resection of bladder tumor: A case report
Xu CB, Jia DS, Pan ZS
- 10695** Submucosal esophageal abscess evolving into intramural submucosal dissection: A case report
Jiao Y, Sikong YH, Zhang AJ, Zuo XL, Gao PY, Ren QG, Li RY
- 10701** Immune checkpoint inhibitor-associated arthritis in advanced pulmonary adenocarcinoma: A case report
Yang Y, Huang XJ
- 10708** Chondroid syringoma of the lower back simulating lipoma: A case report
Huang QF, Shao Y, Yu B, Hu XP
- 10713** Tension-reduced closure of large abdominal wall defect caused by shotgun wound: A case report
Li Y, Xing JH, Yang Z, Xu YJ, Yin XY, Chi Y, Xu YC, Han YD, Chen YB, Han Y

- 10721** Myocardial bridging phenomenon is not invariable: A case report
Li HH, Liu MW, Zhang YF, Song BC, Zhu ZC, Zhao FH
- 10728** Recurrent atypical leiomyoma in bladder trigone, confused with uterine fibroids: A case report
Song J, Song H, Kim YW
- 10735** Eczema herpeticum *vs* dermatitis herpetiformis as a clue of dedicator of cytokinesis 8 deficiency diagnosis: A case report
Alshengeti A
- 10742** Cutaneous allergic reaction to subcutaneous vitamin K₁: A case report and review of literature
Zhang M, Chen J, Wang CX, Lin NX, Li X
- 10755** Perithyroidal hemorrhage caused by hydrodissection during radiofrequency ablation for benign thyroid nodules: Two case reports
Zheng BW, Wu T, Yao ZC, Ma YP, Ren J
- 10763** Malignant giant cell tumors of the tendon sheath of the right hip: A case report
Huang WP, Gao G, Yang Q, Chen Z, Qiu YK, Gao JB, Kang L
- 10772** Atypical Takotsubo cardiomyopathy presenting as acute coronary syndrome: A case report
Wang ZH, Fan JR, Zhang GY, Li XL, Li L
- 10779** Secondary light chain amyloidosis with Waldenström's macroglobulinemia and internodal marginal zone lymphoma: A case report
Zhao ZY, Tang N, Fu XJ, Lin LE
- 10787** Bilateral occurrence of sperm granulomas in the left spermatic cord and on the right epididymis: A case report
Ly DY, Xie HJ, Cui F, Zhou HY, Shuang WB
- 10794** Glucocorticoids combined with tofacitinib in the treatment of Castleman's disease: A case report
Liu XR, Tian M
- 10803** Giant bilateral scrotal lipoma with abnormal somatic fat distribution: A case report
Chen Y, Li XN, Yi XL, Tang Y
- 10811** Elevated procalcitonin levels in the absence of infection in procalcitonin-secreting hepatocellular carcinoma: A case report
Zeng JT, Wang Y, Wang Y, Luo ZH, Qing Z, Zhang Y, Zhang YL, Zhang JF, Li DW, Luo XZ

LETTER TO THE EDITOR

- 10817** "Helicobacter pylori treatment guideline: An Indian perspective": Letter to the editor
Swarnakar R, Yadav SL
- 10820** Effect of gender on the reliability of COVID-19 rapid antigen test among elderly
Nori W, Akram W

ABOUT COVER

Editorial Board Member of *World Journal of Clinical Cases*, Natalia Stepanova, DSc, MD, PhD, Academic Research, Chief Doctor, Full Professor, Department of Nephrology and Dialysis, State Institution "Institute of Nephrology of the National Academy of Medical Sciences of Ukraine", Kyiv 04050, Ukraine. nmstep88@gmail.com

AIMS AND SCOPE

The primary aim of *World Journal of Clinical Cases* (WJCC, *World J Clin Cases*) is to provide scholars and readers from various fields of clinical medicine with a platform to publish high-quality clinical research articles and communicate their research findings online.

WJCC mainly publishes articles reporting research results and findings obtained in the field of clinical medicine and covering a wide range of topics, including case control studies, retrospective cohort studies, retrospective studies, clinical trials studies, observational studies, prospective studies, randomized controlled trials, randomized clinical trials, systematic reviews, meta-analysis, and case reports.

INDEXING/ABSTRACTING

The WJCC is now abstracted and indexed in Science Citation Index Expanded (SCIE, also known as SciSearch®), Journal Citation Reports/Science Edition, Current Contents®/Clinical Medicine, PubMed, PubMed Central, Scopus, Reference Citation Analysis, China National Knowledge Infrastructure, China Science and Technology Journal Database, and Superstar Journals Database. The 2022 Edition of Journal Citation Reports® cites the 2021 impact factor (IF) for WJCC as 1.534; IF without journal self cites: 1.491; 5-year IF: 1.599; Journal Citation Indicator: 0.28; Ranking: 135 among 172 journals in medicine, general and internal; and Quartile category: Q4. The WJCC's CiteScore for 2021 is 1.2 and Scopus CiteScore rank 2021: General Medicine is 443/826.

RESPONSIBLE EDITORS FOR THIS ISSUE

Production Editor: Hua-Ge Yin; Production Department Director: Xiang Li; Editorial Office Director: Jin-Lei Wang.

NAME OF JOURNAL

World Journal of Clinical Cases

ISSN

ISSN 2307-8960 (online)

LAUNCH DATE

April 16, 2013

FREQUENCY

Thrice Monthly

EDITORS-IN-CHIEF

Bao-Gan Peng, Jerzy Tadeusz Chudek, George Kontogeorgos, Maurizio Serati, Ja Hyeon Ku

EDITORIAL BOARD MEMBERS

<https://www.wjgnet.com/2307-8960/editorialboard.htm>

PUBLICATION DATE

October 16, 2022

COPYRIGHT

© 2022 Baishideng Publishing Group Inc

INSTRUCTIONS TO AUTHORS

<https://www.wjgnet.com/bpg/gerinfo/204>

GUIDELINES FOR ETHICS DOCUMENTS

<https://www.wjgnet.com/bpg/GerInfo/287>

GUIDELINES FOR NON-NATIVE SPEAKERS OF ENGLISH

<https://www.wjgnet.com/bpg/gerinfo/240>

PUBLICATION ETHICS

<https://www.wjgnet.com/bpg/GerInfo/288>

PUBLICATION MISCONDUCT

<https://www.wjgnet.com/bpg/gerinfo/208>

ARTICLE PROCESSING CHARGE

<https://www.wjgnet.com/bpg/gerinfo/242>

STEPS FOR SUBMITTING MANUSCRIPTS

<https://www.wjgnet.com/bpg/GerInfo/239>

ONLINE SUBMISSION

<https://www.f6publishing.com>



Recurrent atypical leiomyoma in bladder trigone, confused with uterine fibroids: A case report

Jeonghwa Song, Heekyoung Song, Yong-Wook Kim

Specialty type: Urology and nephrology

Provenance and peer review:

Unsolicited article; Externally peer reviewed.

Peer-review model: Single blind

Peer-review report's scientific quality classification

Grade A (Excellent): A
Grade B (Very good): B, B
Grade C (Good): C, C
Grade D (Fair): 0
Grade E (Poor): 0

P-Reviewer: Gadelkareem RA, Egypt; Kolat D, Poland; Tan B, China; Yadav P, India

Received: May 31, 2022

Peer-review started: May 31, 2022

First decision: August 4, 2022

Revised: August 18, 2022

Accepted: September 7, 2022

Article in press: September 7, 2022

Published online: October 16, 2022



Jeonghwa Song, Heekyoung Song, Yong-Wook Kim, Department of Obstetrics and Gynecology, College of Medicine, The Catholic University of Korea, Incheon St. Mary's Hospital, Incheon 21431, South Korea

Corresponding author: Yong-Wook Kim, MD, PhD, Professor, Department of Obstetrics and Gynecology, College of Medicine, The Catholic University of Korea, Incheon St. Mary's Hospital, 56 Dongsu-ro, Bupyeong-gu, Incheon 21431, South Korea. ywk@catholic.ac.kr

Abstract

BACKGROUND

Tumors originating from the posterior bladder wall can be challenging to diagnose because they may mimic a mass from the uterine cervix. Atypical leiomyoma of the bladder trigone is extremely rare, with few reported cases, and requires caution during surgery to avoid damage to the adjacent ureter. Diagnostic surgery and confirmational pathology are essential to assess whether the tumor is malignant and relieve clinical symptoms. Herein, we describe a case of recurrent leiomyoma with focal atypia in the bladder trigone.

CASE SUMMARY

A 29-year-old woman with a uterine fibroid incidentally found at a regular checkup was referred to our hospital. Based on magnetic resonance imaging, either urinary bladder leiomyoma or protrusion of pedunculated uterine cervical fibroid into the bladder was suspected. This leiomyoma in the trigone of the bladder was completely excised by laparotomy, and the patient was discharged without complication. Follow-up outpatient ultrasonography identified tumor recurrence after four years. As focal atypia was identified previously, laparotomy was performed to confirm the pathology. A round solid mass was resected from the posterior bladder wall without injuring either ureteric orifice. This tumor was pathologically diagnosed as a leiomyoma without atypia. Three-year follow-up ultrasonography has revealed no recurrence.

CONCLUSION

Atypical leiomyoma in bladder trigone is rare and could be easily mistaken for fibroid in the uterine cervix. To confirm histopathology, surgical excision is mandatory and regular follow-up is necessary to detect recurrence.

Key Words: Case report; Cervix uteri; Leiomyoma; Recurrence; Trigone; Urinary bladder

Core Tip: Diagnosis of a tumor originating from the bladder trigone is challenging because it may mimic a mass from the uterine cervix. Magnetic resonance imaging is considered superior to computed tomography or ultrasonography for assessing bladder leiomyoma. Leiomyoma in bladder trigone requires caution during surgery because it can cause damage to the adjacent ureter. Surgical removal is mandatory for histopathological confirmation since it can be atypical fibroids or sarcomas. Regular follow-up is essential to detect recurrence.

Citation: Song J, Song H, Kim YW. Recurrent atypical leiomyoma in bladder trigone, confused with uterine fibroids: A case report. *World J Clin Cases* 2022; 10(29): 10728-10734

URL: <https://www.wjgnet.com/2307-8960/full/v10/i29/10728.htm>

DOI: <https://dx.doi.org/10.12998/wjcc.v10.i29.10728>

INTRODUCTION

Mesenchymal tumors represent 5% of all urinary bladder tumors[1]. Leiomyomas of the urinary bladder are very rare neoplasms, with an incidence of 0.43% of all bladder tumors[2]. Leiomyomas can be submucosal, intramural, or extravesical. Submucosal (*i.e.*, endovesical) leiomyomas are the most common, corresponding to 63%-86% of all cases, while intramural and extravesical leiomyomas represent 3%-7% and 11%-30% of cases, respectively[3,4]. Women make up 76% of the total patient population for leiomyomas[4]. Patients present most commonly with obstructive urinary symptoms (49%), irritative symptoms (38%), hematuria (11%), or flank pain (13%), but nearly 19% of patients are asymptomatic[4].

Imaging studies such as ultrasonography or magnetic resonance imaging (MRI) are effective methods to predict histopathology. In ultrasonography, atypical leiomyoma demonstrated irregular cauliflower shape and homogenous enhancement[5]. In the MRI view, atypical myoma is similar to bladder malignancy rather than bladder leiomyoma, showing an isointense signal on T1- and T2-weighted images and an uneven surface with a cauliflower-like appearance[5]. However, there is no definitive imaging finding that could diagnose atypical bladder leiomyoma.

We report the case of a 29-year-old woman with surgically resected recurrent atypical bladder leiomyoma and recurred bladder leiomyoma. In this case, we reviewed the diagnosis, treatment, and precautions for the treatment of atypical bladder leiomyoma with the relevant literature.

CASE PRESENTATION

Chief complaints

The patient was incidentally diagnosed with a uterine fibroid at a clinic. Following diagnosis, the patient was referred to our center, a tertiary care hospital, for treatment.

History of present illness

A 29-year-old woman was diagnosed with a uterine fibroid on ultrasonography at a regular checkup and was referred to our hospital for surgical treatment. She denied any specific symptoms.

History of past illness

The patient's clinical history was insignificant, and she had no other diseases.

Personal and family history

The patient's personal and family history was insignificant, and she had no other diseases.

Physical examination

Laboratory findings were non-specific except for micro-hematuria (red blood cell: 5-9/high power field (HPF) in urine sediment examination), and no abnormalities were found on physical examination.

Laboratory examinations

The laboratory findings were as follows: Hemoglobin (14.3 g/dL), white blood cell count (8810/mm³), platelet count (311000/mm³), sodium (139 mmol/L), potassium (3.8 mmol/L), fasting blood glucose (97

mg/dL), creatinine (0.6 mg/dL), aspartate aminotransferase (28 U/L), and alanine aminotransferase (37 U/L).

Imaging examinations

Ultrasonography revealed a 6 cm × 4.6 cm solid mass between the uterine wall and bladder. We considered the tumor a uterine fibroid, and a pelvis MRI was performed to determine the exact anatomical location. Based on MRI findings, the mass was suspected leiomyoma (6 cm × 4.6 cm) between the cervix and urinary bladder. The mass protruded into the urinary bladder with relatively increased signal intensity on T2-weighted image suggesting high cellularity and ruling in either bladder leiomyoma or pedunculated cervical fibroid (Figure 1A).

FINAL DIAGNOSIS

The final diagnosis of the initial case was bladder leiomyoma with focal atypia (mitotic count: 1/10 HPF). In the recurrent case, bladder leiomyoma without atypia was diagnosed.

TREATMENT

Magnetic resonance imaging was performed before surgery, but considering the incidence, we focused on pedunculated uterine fibroid rather than bladder leiomyoma. Therefore, instead of cystoscopy, laparotomy was performed. No mass was found in the pelvic cavity when the abdominal wall was incised. Therefore, we made an incision on the bladder and found a submucosal tumor. The tumor was resected by visually complete excision. Both ureteral orifices were deviated due to mass effect. To avoid damage to the ureteral orifices, we performed bilateral Double J-stent placement before tumor resection. It was a well-demarcated single tumor (Figure 2A), and histopathological examination revealed a focally atypical leiomyoma with mitotic count of 1/10 HPF (Figure 2B). Necrotic features were absent. The patient was discharged without any complications. The bilateral Double-J catheters were removed two weeks after surgery.

At both six months and one year after surgery, no recurrence was found on ultrasonography. However, tumor recurrence was detected by ultrasonography without specific symptoms when the patient visited our hospital for a third checkup, four years after surgery. Cystoscopy revealed a protruding mass in the posterior bladder wall (Figure 3A). For further evaluation, a preoperative MRI revealed a 3.8 cm × 3 cm-sized homogeneous mass on the posterior wall of the bladder (Figure 1B). Transvesical laparotomy was performed considering recurrence of the previous pathology, atypical leiomyoma. A round solid mass was found in the bladder trigone during surgery (Figures 3B and 4A), and it was resected without injuring either ureteric orifice. This well-encapsulated tumor was found to be leiomyoma without atypia on permanent pathology (Figure 4B).

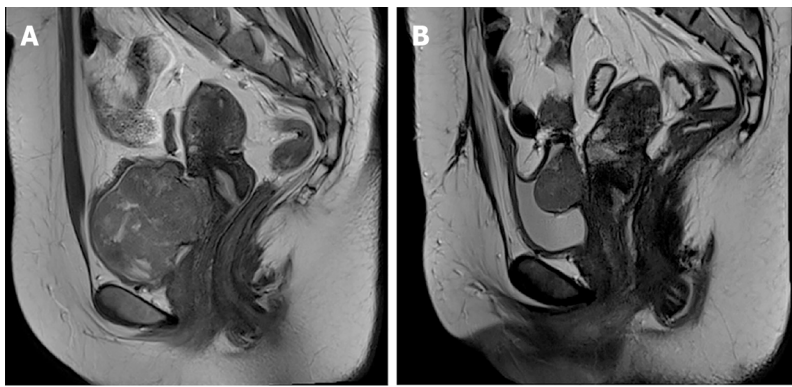
OUTCOME AND FOLLOW-UP

There were no complications after surgery, and there has been no recurrence for more than three years, as observed on follow-up ultrasonography.

DISCUSSION

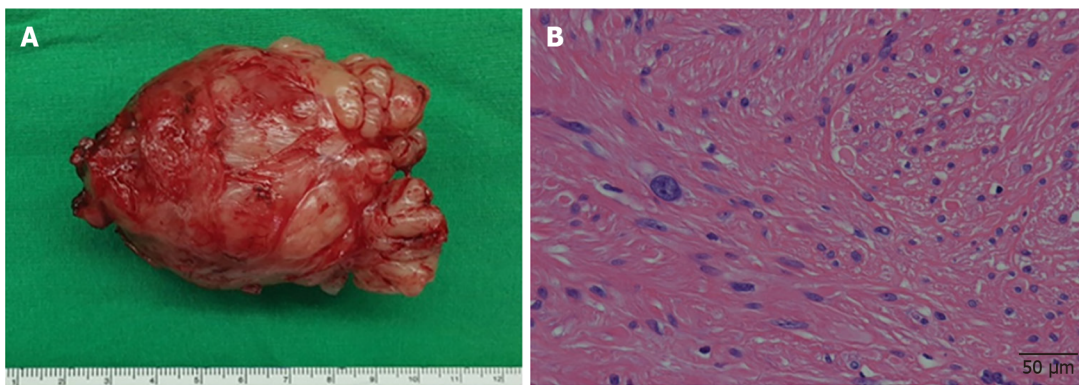
Leiomyoma is a benign disease that can develop from fibroblasts found in any part of the body, including the genitourinary tract. However, bladder leiomyoma is a rare condition, accounting for only 0.43% of all bladder tumors[2,6]. Leiomyoma can be endovesical, intramural, and extravesical. Endovesical origin is also known as submucosal origin, which is the most frequent site and more symptomatic than other origins. Leiomyoma affects individuals with a wide age range (22-78 years)[7] and is more predominant in women, especially in recently published case series[8,9].

Our case was asymptomatic except for microhematuria. However, since various symptoms, such as urinary retention, hematuria, and dyspareunia, are possible[4,7-12], a thorough history is necessary. In a review by Goluboff *et al*[4], 49% of the 37 patients presented with obstructive symptoms, 38% showed irritative symptoms, 11% had hematuria, and 19% were asymptomatic. In a case report by Xin *et al*[10], a 44-year-old female with dyspareunia was diagnosed with bladder leiomyoma coexisting with uterine leiomyoma on histological examination. Saidi *et al*[11] reported leiomyoma of the urinary bladder presenting with hematuria, and Ameli *et al*[12] reported atypical leiomyoma of the bladder presenting as flank pain.



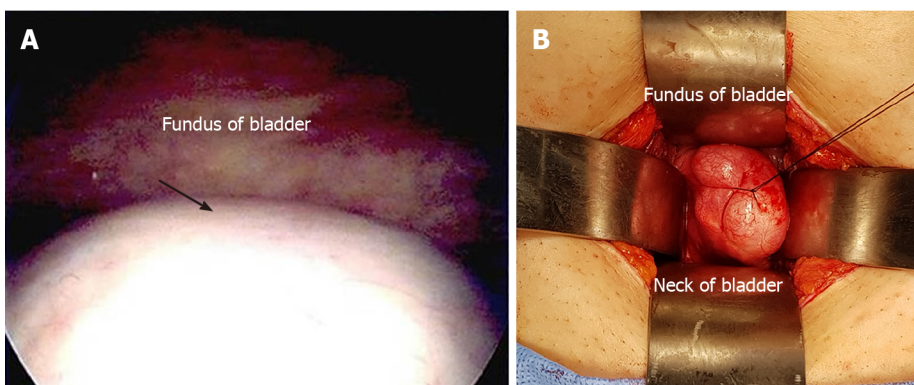
DOI: 10.12998/wjcc.v10.i29.10728 Copyright ©The Author(s) 2022.

Figure 1 Magnetic resonance imaging findings. A: Initial Magnetic resonance imaging (MRI) finding. Sagittal T2-weighted MR image shows a 6 cm × 4.6 cm mass between the uterine cervix and urinary bladder; B: MRI finding after recurrence. Sagittal T2-weighted MR image shows a 3.8 cm × 3 cm sized homogeneous mass arising from posterior wall of the bladder.



DOI: 10.12998/wjcc.v10.i29.10728 Copyright ©The Author(s) 2022.

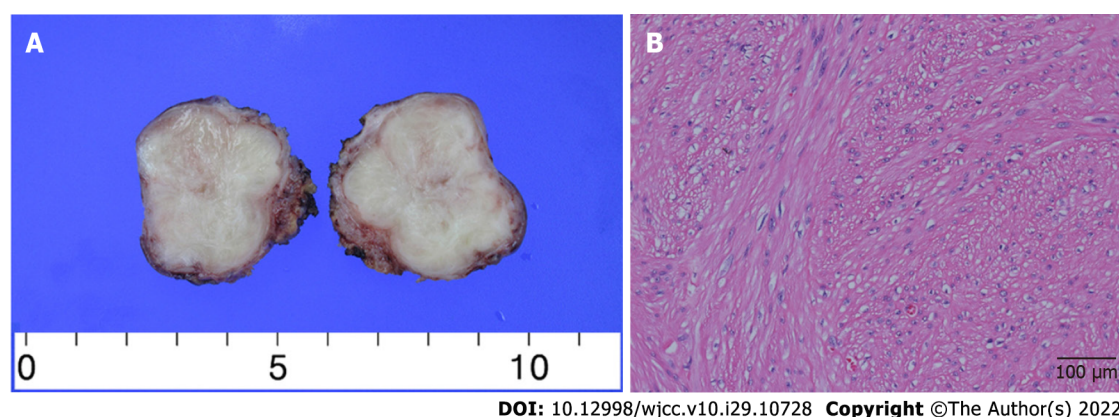
Figure 2 Initial pathological findings. A: Gross image; B: Leiomyoma with bizarre nuclei and moderate cytologic atypia cells (hematoxylin-eosin stain, scale bar = 50 μm).



DOI: 10.12998/wjcc.v10.i29.10728 Copyright ©The Author(s) 2022.

Figure 3 Cystoscopic and intraoperative findings after recurrence. A: Cystoscopic image (arrow: Protruding mass); B: Intraoperative finding (protruding mass in the bladder).

Magnetic resonance imaging is considered to be superior to computed tomography (CT) or ultrasonography for assessing bladder leiomyoma[1,8,13]. Leiomyoma shows intermediate signal intensity on T1-weighted MR images and low signal intensity on T2-weighted MR images[1,14]. In our case, atypical bladder leiomyoma showed hypercellularity on MRI. However, imaging findings could not accurately diagnose atypical bladder leiomyoma. Therefore, pathological confirmation was the best option to diagnose atypical bladder leiomyoma.



DOI: 10.12998/wjcc.v10.i29.10728 Copyright ©The Author(s) 2022.

Figure 4 Pathological findings after recurrence. A: Gross image; B: Leiomyoma without atypia (hematoxylin-eosin stain, scale bar = 100 μm).

Cystoscopy is a high-value diagnostic tool that can show the leiomyoma's morphology and anatomical location[12]. Moreover, cystoscopy can be used to confirm the histopathology of bladder mass. However, cystoscopy, an invasive procedure, is usually performed when abnormalities in the urethra or bladder are detected on imaging tests[15,16]. One of the limitations of cystoscopy is that if the mass size is too large it is difficult to determine the overall contour considering this case. Cystoscopy could be contraindicated in the presence of acute urinary tract infection or urethral stricture[16].

Before the first surgery, since bladder leiomyomas are very rare, we thought that uterine fibroids were more likely and did not perform preoperative cystoscopy. At the time of recurrence, cystoscopy was performed, but a biopsy was not performed because it was assumed that the recurrent mass would be the same atypical bladder leiomyoma as before. Unlike our expectations, the final diagnosis was leiomyoma without atypia. Although we did not perform cystoscopy and biopsy, the procedures would have been helpful in determining preoperative diagnosis. If fibroids protruding from the cervix to the bladder are found on imaging tests, though rare, there is a possibility of bladder fibroids, so a cystoscopy is recommended.

There are several surgical approaches to resect bladder myoma. According to anatomical position, abdominal, transvaginal, transurethral, or laparoscopic resection may be possible. In malignancy, a huge or recurrent mass in an unfavorable location should be excised through an abdominal or laparoscopic approach for complete resection. Murota *et al*[17] presented a laparoscopic partial cystectomy case using both retroperitoneoscopic and transurethral procedures to treat a leiomyoma sized 2 cm on the right wall of the bladder. Once the mass was palpable through the vagina, it could be removed *via* a transvaginal approach[18]. If a small tumor is located within the endovesical wall of the bladder, it can be managed with transurethral resection. Zachariou *et al*[19] reported transurethral resection of a bladder trigone leiomyoma.

As with our case report, if protruding subserosal leiomyoma of the uterine cervix is suspected in imaging studies, a differential diagnosis for the tumor-originated bladder is required. Such masses could either be sarcoma or other malignant masses. Therefore, surgeons should be mindful of several possibilities to decide on better treatment options. In a case reported by Asano *et al*[20], a 32-year-old woman with hematuria and suspicious bladder myoma underwent resection for treatment. However, alveolar soft part sarcoma was reported later on final pathology[20].

Recurrent cases are very rare in atypical or benign bladder leiomyoma. Khater *et al*[13], who reviewed 36 reports for bladder leiomyoma, reported no recurrent cases. Conversely, 2 recurrent bladder leiomyomas in all 9 cases were reported, and no recurrent disease was noted after the complete recurrent lesion of bladder leiomyoma[14]. To avoid recurrent disease, complete resection was effective and important method[13]. In large-sized bladder leiomyoma, partial cystectomy was considered to obtain complete resection with a clear surgical margin[21]. In the first surgery of this case, the tumor was completely removed visually. However, given the recurrence of leiomyoma, it appears that the tumor has not been removed with a sufficiently wide and deep margin because there were ureteral orifices right next to the tumor and the cervix behind it.

There are only a few case reports of recurrence after leiomyoma resection, as in our case[14,21]. Although rare, recurrence is possible in some cases, and regular outpatient follow-up is necessary after surgical treatment.

CONCLUSION

Leiomyoma in bladder trigone is rare and could be easily mistaken for fibroid in the uterine cervix. Magnetic resonance imaging is an effective method of assessing the anatomical position of a leiomyoma.

Surgical excision is mandatory to confirm pathology since it can be atypical fibroids or sarcomas, and regular follow-up is necessary to detect recurrence.

FOOTNOTES

Author contributions: Song J and Song H contributed equally to this work as first authors; Song J and Song H reviewed all medical records, examined relevant literature, summarized the case findings, and contributed to manuscript drafting; Kim YW reviewed the literature and interpreted the imaging findings, and were responsible for the revision of the manuscript for important intellectual content in the manuscript; all authors issued final approval for the version to be submitted.

Informed consent statement: Informed written consent was obtained from the patient for publication of this report and any accompanying images.

Conflict-of-interest statement: The authors declare that they have no conflict of interest to disclose.

CARE Checklist (2016) statement: The authors have read the CARE Checklist (2016), and the manuscript was prepared and revised according to the CARE Checklist (2016).

Open-Access: This article is an open-access article that was selected by an in-house editor and fully peer-reviewed by external reviewers. It is distributed in accordance with the Creative Commons Attribution NonCommercial (CC BY-NC 4.0) license, which permits others to distribute, remix, adapt, build upon this work non-commercially, and license their derivative works on different terms, provided the original work is properly cited and the use is non-commercial. See: <https://creativecommons.org/licenses/by-nc/4.0/>

Country/Territory of origin: South Korea

ORCID number: Jeonghwa Song 0000-0003-4620-9320; Heekyoung Song 0000-0002-9786-3528; Yong-Wook Kim 0000-0002-9301-2697.

S-Editor: Zhang H

L-Editor: A

P-Editor: Zhang H

REFERENCES

- 1 **Wong-You-Cheong JJ**, Woodward PJ, Manning MA, Sesterhenn IA. From the Archives of the AFIP: neoplasms of the urinary bladder: radiologic-pathologic correlation. *Radiographics* 2006; **26**: 553-580 [PMID: 16549617 DOI: 10.1148/rg.262055172]
- 2 **Blasco Casares FJ**, Sacristán Sanfelipe J, Ibarz Servio L, Batalla Cadira JL, Ruiz Marcellán FJ. [Characteristics of bladder leiomyoma in our setting]. *Arch Esp Urol* 1995; **48**: 987-990 [PMID: 8588732]
- 3 **Knoll LD**, Segura JW, Scheithauer BW. Leiomyoma of the bladder. *J Urol* 1986; **136**: 906-908 [PMID: 3761457 DOI: 10.1016/s0022-5347(17)45124-x]
- 4 **Goluboff ET**, O'Toole K, Sawczuk IS. Leiomyoma of bladder: report of case and review of literature. *Urology* 1994; **43**: 238-241 [PMID: 8116123 DOI: 10.1016/0090-4295(94)90053-1]
- 5 **Wu S**. Imaging findings of atypical leiomyoma of the urinary bladder simulating bladder cancer: a case report and literature review. *Med Ultrason* 2013; **15**: 161-163 [PMID: 23702508 DOI: 10.11152/mu.2013.2066.152.sw1]
- 6 **Cornella JL**, Larson TR, Lee RA, Magrina JF, Kammerer-Doak D. Leiomyoma of the female urethra and bladder: report of twenty-three patients and review of the literature. *Am J Obstet Gynecol* 1997; **176**: 1278-1285 [PMID: 9215185 DOI: 10.1016/s0002-9378(97)70346-6]
- 7 **Martin SA**, Sears DL, Sebo TJ, Lohse CM, Cheville JC. Smooth muscle neoplasms of the urinary bladder: a clinicopathologic comparison of leiomyoma and leiomyosarcoma. *Am J Surg Pathol* 2002; **26**: 292-300 [PMID: 11859200 DOI: 10.1097/00000478-200203000-00002]
- 8 **Matsushima M**, Asakura H, Sakamoto H, Horinaga M, Nakahira Y, Yanaihara H. Leiomyoma of the bladder presenting as acute urinary retention in a female patient: urodynamic analysis of lower urinary tract symptom; a case report. *BMC Urol* 2010; **10**: 13 [PMID: 20684762 DOI: 10.1186/1471-2490-10-13]
- 9 **Rey Valzacchi GM**, Pavan LI, Bourguignon GA, Cortez JP, Ubertazzi EP, Saadi JM. Transvesical laparoscopy for bladder leiomyoma excision: a novel surgical technique. *Int Urogynecol J* 2021; **32**: 2543-2544 [PMID: 33064155 DOI: 10.1007/s00192-020-04557-1]
- 10 **Xin J**, Lai HP, Lin SK, Zhang QQ, Shao CX, Jin L, Lei WH. Bladder leiomyoma presenting as dyspareunia: Case report and literature review. *Medicine (Baltimore)* 2016; **95**: e3971 [PMID: 27428187 DOI: 10.1097/MD.0000000000003971]
- 11 **Saidi R**, Lefi M, Touffahi M, Farhane S, Saad H. [Leiomyoma of the urinary bladder]. *Prog Urol* 2002; **12**: 493-496 [PMID: 12189765]
- 12 **Ameli M**, Rahmandoust M. Elderly patient with atypical leiomyoma of the bladder presenting as flank pain: A case report. *Arch Ital Urol Androl* 2017; **89**: 327-328 [PMID: 29473387 DOI: 10.4081/aiua.2017.4.327]

- 13 **Khater N**, Sakr G. Bladder leiomyoma: Presentation, evaluation and treatment. *Arab J Urol* 2013; **11**: 54-61 [PMID: [26579246](#) DOI: [10.1016/j.aju.2012.11.007](#)]
- 14 **Park JW**, Jeong BC, Seo SI, Jeon SS, Kwon GY, Lee HM. Leiomyoma of the urinary bladder: a series of nine cases and review of the literature. *Urology* 2010; **76**: 1425-1429 [PMID: [20947147](#) DOI: [10.1016/j.urology.2010.02.046](#)]
- 15 **McCarthy TC**. Cystoscopy and biopsy of the feline lower urinary tract. *Vet Clin North Am Small Anim Pract* 1996; **26**: 463-482 [PMID: [9157647](#) DOI: [10.1016/s0195-5616\(96\)50078-1](#)]
- 16 **Messer JS**, Chew DJ, McLoughlin MA. Cystoscopy: techniques and clinical applications. *Clin Tech Small Anim Pract* 2005; **20**: 52-64 [PMID: [15822531](#) DOI: [10.1053/j.ctsap.2004.12.008](#)]
- 17 **Murota T**, Komai Y, Danno S, Fujita I, Kawakita M, Matsuda T. Endoscopic partial cystectomy for bladder leiomyoma using retroperitoneoscopic and transurethral procedures. *Int J Urol* 2002; **9**: 190-192 [PMID: [12010334](#) DOI: [10.1046/j.1442-2042.2002.00447.x](#)]
- 18 **Yin FF**, Wang N, Wang YL, Bi XN, Xu XH, Wang YK. Transvaginal Resection of a Bladder Leiomyoma Misdiagnosed with a Vaginal Mass: A Case Report and Literature Review. *Case Rep Obstet Gynecol* 2015; **2015**: 981843 [PMID: [26693368](#) DOI: [10.1155/2015/981843](#)]
- 19 **Zachariou A**, Filiponi M, Dimitriadis F, Kaltsas A, Sofikitis N. Transurethral resection of a bladder trigone leiomyoma: a rare case report. *BMC Urol* 2020; **20**: 152 [PMID: [33028269](#) DOI: [10.1186/s12894-020-00722-2](#)]
- 20 **Asano A**, Nishikimi T, Morikami H, Ohashi T, Yamauchi Y, Ishida R, Yamada H, Kobayashi H, Tsuduki T. [A primary bladder alveolar soft part sarcoma: a case report]. *Nihon Hinyokika Gakkai Zasshi* 2021; **112**: 45-48 [PMID: [35046236](#) DOI: [10.5980/jpnjurol.112.45](#)]
- 21 **Bangash M**, Faruqi N, Muhammad AU, Uddin Z. Leiomyoma Urinary Bladder, Mimicking Urothelial Cancer. *J Ayub Med Coll Abbottabad* 2021; **33**: 685-689 [PMID: [35124930](#)]



Published by **Baishideng Publishing Group Inc**
7041 Koll Center Parkway, Suite 160, Pleasanton, CA 94566, USA

Telephone: +1-925-3991568

E-mail: bpgoffice@wjgnet.com

Help Desk: <https://www.f6publishing.com/helpdesk>

<https://www.wjgnet.com>

