

World Journal of *Clinical Cases*

World J Clin Cases 2022 October 16; 10(29): 10391-10822



Contents

Thrice Monthly Volume 10 Number 29 October 16, 2022

STANDARD AND CONSENSUS

- 10391** Baishideng's *Reference Citation Analysis* database announces the first *Article Influence Index* of multidisciplinary scholars

Wang JL, Ma YJ, Ma L, Ma N, Guo DM, Ma LS

REVIEW

- 10399** Cholecystectomy for asymptomatic gallstones: Markov decision tree analysis

Lee BJH, Yap QV, Low JK, Chan YH, Shelat VG

- 10413** Liver transplantation for hepatocellular carcinoma: Historical evolution of transplantation criteria

Ince V, Sahin TT, Akbulut S, Yilmaz S

MINIREVIEWS

- 10428** Prostate only radiotherapy using external beam radiotherapy: A clinician's perspective

Lee JW, Chung MJ

ORIGINAL ARTICLE

Retrospective Study

- 10435** Age-adjusted NT-proBNP could help in the early identification and follow-up of children at risk for severe multisystem inflammatory syndrome associated with COVID-19 (MIS-C)

Rodriguez-Gonzalez M, Castellano-Martinez A

- 10451** Clinicopathological characteristics and prognosis of gastric signet ring cell carcinoma

Tian HK, Zhang Z, Ning ZK, Liu J, Liu ZT, Huang HY, Zong Z, Li H

- 10467** Development and validation of a prognostic nomogram for decompensated liver cirrhosis

Zhang W, Zhang Y, Liu Q, Nie Y, Zhu X

Observational Study

- 10478** Effect of medical care linkage-continuous management mode in patients with posterior circulation cerebral infarction undergoing endovascular interventional therapy

Zhu FX, Ye Q

- 10487** Effect of the COVID-19 pandemic on patients with presumed diagnosis of acute appendicitis

Akbulut S, Tuncer A, Ogut Z, Sahin TT, Koc C, Guldogan E, Karabulut E, Tanriverdi ES, Ozer A

EVIDENCE-BASED MEDICINE

- 10501** Delineation of a SMARCA4-specific competing endogenous RNA network and its function in hepatocellular carcinoma

Zhang L, Sun T, Wu XY, Fei FM, Gao ZZ

SYSTEMATIC REVIEWS

- 10516** Comparison of laboratory parameters, clinical symptoms and clinical outcomes of COVID-19 and influenza in pediatric patients: A systematic review and meta-analysis

Yu B, Chen HH, Hu XF, Mai RZ, He HY

CASE REPORT

- 10529** Surgical treatment of bipolar segmental clavicle fracture: A case report

Liang L, Chen XL, Chen Y, Zhang NN

- 10535** Multiple disciplinary team management of rare primary splenic malignancy: Two case reports

Luo H, Wang T, Xiao L, Wang C, Yi H

- 10543** Klippel-Trenaunay-Weber syndrome with ischemic stroke: A case report

Lee G, Choi T

- 10550** Vedolizumab in the treatment of immune checkpoint inhibitor-induced colitis: Two case reports

Zhang Z, Zheng CQ

- 10559** Novel way of patent foramen ovale detection and percutaneous closure by intracardiac echocardiography: A case report

Han KN, Yang SW, Zhou YJ

- 10565** Treatment failure in a patient infected with *Listeria* sepsis combined with latent meningitis: A case report

Wu GX, Zhou JY, Hong WJ, Huang J, Yan SQ

- 10575** Three-in-one incidence of hepatocellular carcinoma, cholangiocellular carcinoma, and neuroendocrine carcinoma: A case report

Wu Y, Xie CB, He YH, Ke D, Huang Q, Zhao KF, Shi RS

- 10583** Intestinal microbiome changes in an infant with right atrial isomerism and recurrent necrotizing enterocolitis: A case report and review of literature

Kaplina A, Zaikova E, Ivanov A, Volkova Y, Alkhova T, Nikiforov V, Latypov A, Khavkina M, Fedoseeva T, Pervunina T, Skorobogatova Y, Volkova S, Ulyantsev V, Kalinina O, Sitkin S, Petrova N

- 10600** *Serratia fonticola* and its role as a single pathogen causing emphysematous pyelonephritis in a non-diabetic patient: A case report

Villasuso-Alcocer V, Flores-Tapia JP, Perez-Garfias F, Rochel-Perez A, Mendez-Dominguez N

- 10606** Cardiac myxoma shedding leads to lower extremity arterial embolism: A case report

Meng XH, Xie LS, Xie XP, Liu YC, Huang CP, Wang LJ, Zhang GH, Xu D, Cai XC, Fang X

- 10614** Extracorporeal membrane oxygenation in curing a young man after modified Fontan operation: A case report
Guo HB, Tan JB, Cui YC, Xiong HF, Li CS, Liu YF, Sun Y, Pu L, Xiang P, Zhang M, Hao JJ, Yin NN, Hou XT, Liu JY
- 10622** Wandering small intestinal stromal tumor: A case report
Su JZ, Fan SF, Song X, Cao LJ, Su DY
- 10629** Acute mesenteric ischemia secondary to oral contraceptive-induced portomesenteric and splenic vein thrombosis: A case report
Zhao JW, Cui XH, Zhao WY, Wang L, Xing L, Jiang XY, Gong X, Yu L
- 10638** Perioperative anesthesia management in pediatric liver transplant recipient with atrial septal defect: A case report
Liu L, Chen P, Fang LL, Yu LN
- 10647** Multiple tophi deposits in the spine: A case report
Chen HJ, Chen DY, Zhou SZ, Chi KD, Wu JZ, Huang FL
- 10655** Myeloproliferative neoplasms complicated with β -thalassemia: Two case report
Xu NW, Li LJ
- 10663** Synchronous renal pelvis carcinoma associated with small lymphocytic lymphoma: A case report
Yang HJ, Huang X
- 10670** *Leclercia adecarboxylata* infective endocarditis in a man with mitral stenosis: A case report and review of the literature
Tan R, Yu JQ, Wang J, Zheng RQ
- 10681** Progressive ataxia of cerebrotendinous xanthomatosis with a rare c.255+1G>T splice site mutation: A case report
Chang YY, Yu CQ, Zhu L
- 10689** Intravesical explosion during transurethral resection of bladder tumor: A case report
Xu CB, Jia DS, Pan ZS
- 10695** Submucosal esophageal abscess evolving into intramural submucosal dissection: A case report
Jiao Y, Sikong YH, Zhang AJ, Zuo XL, Gao PY, Ren QG, Li RY
- 10701** Immune checkpoint inhibitor-associated arthritis in advanced pulmonary adenocarcinoma: A case report
Yang Y, Huang XJ
- 10708** Chondroid syringoma of the lower back simulating lipoma: A case report
Huang QF, Shao Y, Yu B, Hu XP
- 10713** Tension-reduced closure of large abdominal wall defect caused by shotgun wound: A case report
Li Y, Xing JH, Yang Z, Xu YJ, Yin XY, Chi Y, Xu YC, Han YD, Chen YB, Han Y

- 10721** Myocardial bridging phenomenon is not invariable: A case report
Li HH, Liu MW, Zhang YF, Song BC, Zhu ZC, Zhao FH
- 10728** Recurrent atypical leiomyoma in bladder trigone, confused with uterine fibroids: A case report
Song J, Song H, Kim YW
- 10735** Eczema herpeticum *vs* dermatitis herpetiformis as a clue of dedicator of cytokinesis 8 deficiency diagnosis: A case report
Alshengeti A
- 10742** Cutaneous allergic reaction to subcutaneous vitamin K₁: A case report and review of literature
Zhang M, Chen J, Wang CX, Lin NX, Li X
- 10755** Perithyroidal hemorrhage caused by hydrodissection during radiofrequency ablation for benign thyroid nodules: Two case reports
Zheng BW, Wu T, Yao ZC, Ma YP, Ren J
- 10763** Malignant giant cell tumors of the tendon sheath of the right hip: A case report
Huang WP, Gao G, Yang Q, Chen Z, Qiu YK, Gao JB, Kang L
- 10772** Atypical Takotsubo cardiomyopathy presenting as acute coronary syndrome: A case report
Wang ZH, Fan JR, Zhang GY, Li XL, Li L
- 10779** Secondary light chain amyloidosis with Waldenström's macroglobulinemia and internodal marginal zone lymphoma: A case report
Zhao ZY, Tang N, Fu XJ, Lin LE
- 10787** Bilateral occurrence of sperm granulomas in the left spermatic cord and on the right epididymis: A case report
Ly DY, Xie HJ, Cui F, Zhou HY, Shuang WB
- 10794** Glucocorticoids combined with tofacitinib in the treatment of Castleman's disease: A case report
Liu XR, Tian M
- 10803** Giant bilateral scrotal lipoma with abnormal somatic fat distribution: A case report
Chen Y, Li XN, Yi XL, Tang Y
- 10811** Elevated procalcitonin levels in the absence of infection in procalcitonin-secreting hepatocellular carcinoma: A case report
Zeng JT, Wang Y, Wang Y, Luo ZH, Qing Z, Zhang Y, Zhang YL, Zhang JF, Li DW, Luo XZ

LETTER TO THE EDITOR

- 10817** "Helicobacter pylori treatment guideline: An Indian perspective": Letter to the editor
Swarnakar R, Yadav SL
- 10820** Effect of gender on the reliability of COVID-19 rapid antigen test among elderly
Nori W, Akram W

ABOUT COVER

Editorial Board Member of *World Journal of Clinical Cases*, Natalia Stepanova, DSc, MD, PhD, Academic Research, Chief Doctor, Full Professor, Department of Nephrology and Dialysis, State Institution "Institute of Nephrology of the National Academy of Medical Sciences of Ukraine", Kyiv 04050, Ukraine. nmstep88@gmail.com

AIMS AND SCOPE

The primary aim of *World Journal of Clinical Cases* (WJCC, *World J Clin Cases*) is to provide scholars and readers from various fields of clinical medicine with a platform to publish high-quality clinical research articles and communicate their research findings online.

WJCC mainly publishes articles reporting research results and findings obtained in the field of clinical medicine and covering a wide range of topics, including case control studies, retrospective cohort studies, retrospective studies, clinical trials studies, observational studies, prospective studies, randomized controlled trials, randomized clinical trials, systematic reviews, meta-analysis, and case reports.

INDEXING/ABSTRACTING

The WJCC is now abstracted and indexed in Science Citation Index Expanded (SCIE, also known as SciSearch®), Journal Citation Reports/Science Edition, Current Contents®/Clinical Medicine, PubMed, PubMed Central, Scopus, Reference Citation Analysis, China National Knowledge Infrastructure, China Science and Technology Journal Database, and Superstar Journals Database. The 2022 Edition of Journal Citation Reports® cites the 2021 impact factor (IF) for WJCC as 1.534; IF without journal self cites: 1.491; 5-year IF: 1.599; Journal Citation Indicator: 0.28; Ranking: 135 among 172 journals in medicine, general and internal; and Quartile category: Q4. The WJCC's CiteScore for 2021 is 1.2 and Scopus CiteScore rank 2021: General Medicine is 443/826.

RESPONSIBLE EDITORS FOR THIS ISSUE

Production Editor: Hua-Ge Yin; Production Department Director: Xiang Li; Editorial Office Director: Jin-Lei Wang.

NAME OF JOURNAL

World Journal of Clinical Cases

ISSN

ISSN 2307-8960 (online)

LAUNCH DATE

April 16, 2013

FREQUENCY

Thrice Monthly

EDITORS-IN-CHIEF

Bao-Gan Peng, Jerzy Tadeusz Chudek, George Kontogeorgos, Maurizio Serati, Ja Hyeon Ku

EDITORIAL BOARD MEMBERS

<https://www.wjgnet.com/2307-8960/editorialboard.htm>

PUBLICATION DATE

October 16, 2022

COPYRIGHT

© 2022 Baishideng Publishing Group Inc

INSTRUCTIONS TO AUTHORS

<https://www.wjgnet.com/bpg/gerinfo/204>

GUIDELINES FOR ETHICS DOCUMENTS

<https://www.wjgnet.com/bpg/GerInfo/287>

GUIDELINES FOR NON-NATIVE SPEAKERS OF ENGLISH

<https://www.wjgnet.com/bpg/gerinfo/240>

PUBLICATION ETHICS

<https://www.wjgnet.com/bpg/GerInfo/288>

PUBLICATION MISCONDUCT

<https://www.wjgnet.com/bpg/gerinfo/208>

ARTICLE PROCESSING CHARGE

<https://www.wjgnet.com/bpg/gerinfo/242>

STEPS FOR SUBMITTING MANUSCRIPTS

<https://www.wjgnet.com/bpg/GerInfo/239>

ONLINE SUBMISSION

<https://www.f6publishing.com>



Eczema herpeticum vs dermatitis herpetiformis as a clue of dedicator of cytokinesis 8 deficiency diagnosis: A case report

Amer Alshengeti

Specialty type: Immunology

Provenance and peer review:

Unsolicited article; Externally peer reviewed.

Peer-review model: Single blind

Peer-review report's scientific quality classification

Grade A (Excellent): 0

Grade B (Very good): B, B

Grade C (Good): 0

Grade D (Fair): 0

Grade E (Poor): 0

P-Reviewer: Bredt LC, Brazil; Su YY, Taiwan

Received: May 27, 2022

Peer-review started: May 27, 2022

First decision: July 12, 2022

Revised: August 10, 2022

Accepted: September 8, 2022

Article in press: September 8, 2022

Published online: October 16, 2022



Amer Alshengeti, Department of Pediatrics, College of Medicine, Taibah University; Department of Infection prevention and control, Prince Mohammad Bin Abdulaziz Hospital, National Guard Health Affairs, Al-Madinah 41491, Saudi Arabia

Corresponding author: Amer Alshengeti, MD, Assistant Professor, Department of Pediatrics, College of Medicine, Taibah University, Al-Qiblatain District, P.O. BOX 4495, Al-Madinah 41491, Saudi Arabia. aalshengeti@dal.ca

Abstract

BACKGROUND

Dedicator of cytokinesis 8 (DOCK 8) deficiency, also known as autosomal recessive hyper immunoglobulin E (IgE) syndrome, is a combined immunodeficiency disease that was first recognized in 2009. It is caused by genetic alterations (mutations or deletions) in the DOCK 8 gene and is characterized by multiple allergies, elevated IgE levels, and susceptibility to viral and bacterial infections. Early diagnosis is critical to optimize the success of stem cell transplantation.

CASE SUMMARY

This study reports the case of a pediatric patient with DOCK 8 deficiency who had negative genetic testing using multiplex primary immunodeficiency (PID) panel and whole-exome sequencing (WES) with a next-generation sequencing method. He presented with chronic diarrhea and was managed as celiac disease based on previous negative workup for immunodeficiency and duodenal biopsy. He developed a generalized vesicular rash which was thought to be dermatitis herpetiformis associated with celiac disease. However, it turned out to be Eczema herpeticum based on positive herpes simplex virus from blood and lesions. The diagnosis was re-evaluated after the child was found to have multiple viral, bacterial, and parasitic co-infections (herpes simplex virus, cytomegalovirus, Epstein-Barr virus, *Salmonella*, and *cryptosporidiosis*). Re-evaluation with target gene testing with copy number variation (CNV) analysis and Multiplex Ligation Probe Amplification (MLPA) showed a large homozygous deletion in the DOCK 8 gene, confirming the diagnosis of DOCK 8 deficiency.

CONCLUSION

Targeted gene testing with CNV analysis might detect deletions that can be missed by WES for diagnosing patients with PID.

Key Words: Immunoglobulin E; Whole-exome sequencing; Infections; Dedicator of

cytokines 8; Case report

©The Author(s) 2022. Published by Baishideng Publishing Group Inc. All rights reserved.

Core Tip: Diagnosis of primary immunodeficiency syndromes is challenging, especially those involving the innate immune system. Whole-exome sequencing (WES) is a promising method for diagnosis but has limitations. This article reports a case of delayed diagnosis of Dedicator of cytokines 8 deficiency based on negative WES results and highlights the importance of specific gene testing, when the clinical features are suggestive of specific disease, rather than depending on WES alone.

Citation: Alshengeti A. Eczema herpeticum vs dermatitis herpetiformis as a clue of dedicator of cytokines 8 deficiency diagnosis: A case report. *World J Clin Cases* 2022; 10(29): 10735-10741

URL: <https://www.wjgnet.com/2307-8960/full/v10/i29/10735.htm>

DOI: <https://dx.doi.org/10.12998/wjcc.v10.i29.10735>

INTRODUCTION

The dedicator of cytokines 8 (DOCK 8) gene, which is located on chromosome 9q24, was first discovered in 2009 by Zhang *et al*[1] after an extensive workup of 11 patients with recurrent sinopulmonary infections, viral skin infections, elevated immunoglobulin E (IgE), and multiple allergies. DOCK 8 deficiency, along with other genetic defects, causes rare autosomal recessive hyper-IgE syndromes, while signal transducer and activator of transcription 3 (STAT3) defect causes the most common classical autosomal dominant hyper IgE[1,2]. This report describes a case of DOCK 8 deficiency, the diagnosis of which was challenging.

CASE PRESENTATION

Chief complaints

An 8-year-old Yemeni boy was referred to our hospital for chronic diarrhea workup and management.

History of present illness

Upon admission to our hospital, he had diarrhea with 9-12 episodes of loose bowel motion per day with mucus but no blood. There was no history of vomiting, fever, cough or shortness of breath.

History of past illness

He had a history of recurrent skin abscesses, eczema, and multiple food allergies since the age of nine months. He was admitted at the ages of 18 mo and 3 years with community-acquired pneumonia. He had a history of recurrent chronic diarrhea that occurred 3-5 times per year and lasted 3-6 wk with increased baseline bowel habits (2-3 times/day). Two months before admission to our hospital, he developed severe diarrhea that led to hypovolemic shock and was admitted to the pediatric intensive care unit at the referring hospital. He stayed in the hospital for 45 days and lost approximately 7 kg of body weight (decreased from 21 kg to 14 kg).

The patient was born through a normal vaginal delivery with no major events or hospital admission in the first year of life. He had a history of poor weight gain since the age of three years. His developmental milestones were normal for his age. He had been vaccinated for up to 2 years of age.

The patient was evaluated at the age of 7 years for primary immunodeficiency, and the workup showed elevated IgE at a level of 2200 IU/mL (reference 25-550 IU/mL) with normal lymphocytes on flow cytometry. The primary immunodeficiency (PID) genetic testing panel, including the DOCK 8 gene, was negative for any pathogenic mutation. This panel uses a syndrome-based technique *via* simultaneous next-generation sequencing of the targeted genes (Saudi Mendeliome Group, Riyadh, Saudi Arabia, 2015)[3]. In addition, whole-exome sequencing (WES) was sent from the referring hospital before transfer and later turned negative for any pathogenic mutation (details regarding the WES methodology are outlined in [Supplementary material 1](#).

Personal and family history

The parents were first-degree relatives with another 10 and 3-year-old male and 5-year-old female healthy offspring.

Physical examination

On examination, he appeared ill and cachectic, with a loss of subcutaneous fat. His vital signs were normal without fever. His weight was 13.2 kg (below the 3rd percentile), height was 107 cm (below the 3rd percentile), and body mass index was 11.5 kg/m². Systemic examination revealed dry eczematous skin with ulcerated lesions behind the left ear.

Laboratory examinations

Initial and follow up laboratory investigation showed leukocytosis ($15\text{--}32 \times 10^9/\text{L}$; normal range: $4\text{--}11 \times 10^9/\text{L}$), eosinophilia ($0.9\text{--}3 \times 10^9/\text{L}$; normal range: $0.1\text{--}0.35 \times 10^9/\text{L}$), and mildly elevated liver enzymes. The workup for chronic diarrhea showed a positive stool culture for *Salmonella spp.*, for which he received ciprofloxacin for 10 days. The patient was started on total parenteral nutrition and was scheduled for upper and lower GI endoscopy to rule out celiac disease and other pathologies.

Upper GI endoscopy with duodenal biopsy showed increased intraepithelial T-lymphocytes, consistent with a clinical history of celiac disease. In addition, there were increased kappa light chain-restricted plasma cells present in the lamina propria. The patient was diagnosed with celiac disease with celiac crisis based on his clinical presentation and duodenal biopsy findings. A gluten-free diet, along with other nutritional supplements, was initiated.

Imaging examinations

Abdominal ultrasound and chest radiography showed unremarkable findings.

MULTIDISCIPLINARY EXPERT CONSULTATION

The infectious disease team was consulted, as diarrhea persisted despite a gluten-free diet for three weeks, to rule out other infectious causes.

FURTHER DIAGNOSTIC WORKUP

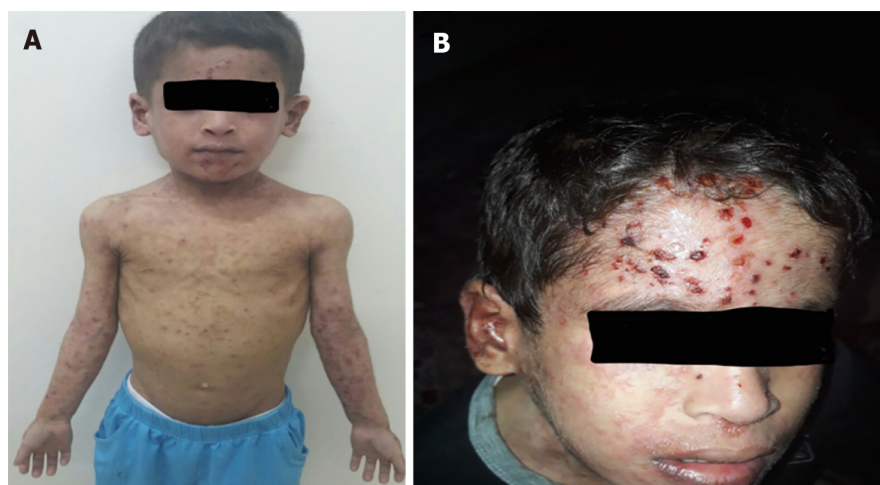Stool testing for other pathogens revealed a positive *Cryptosporidium* antigen. The patient was administered paromomycin and azithromycin for 14 days. His diarrhea improved after 10 days of treatment; the stool frequency decreased to one to three times per day, with more formed stools. However, the repeat antigen test was positive. It was not clear whether the improvement in diarrhea was secondary to a gluten-free diet or antimicrobials for *Cryptosporidium*.

During the sixth week of admission, the patient developed a vesicular skin rash involving the face, upper limbs, and trunk (Figure 1A and B). The rash was itchy without fever. Based on the diagnosis of celiac disease, dermatitis herpetiformis was suspected. Therefore, dapsone treatment was initiated without improvement. At this time, a herpes simplex virus (HSV) swab from the lesion and serum for polymerase chain reaction (PCR) was sent, which turned positive for both. Viral work-up showed positive cytomegalovirus (CMV) and Epstein-Barr virus (EBV) viremia with low viral load. The skin rash resolved after treatment with intravenous acyclovir for 14 days (Figure 2). However, the patient continued to have recurrent HSV skin infections in subsequent months, which improved with valacyclovir prophylaxis. Repeated immune workup showed elevated IgE levels of 5500 IU/mL (reference 25–550 IU/mL), low T-lymphocytes (CD4+, CD8+, and NK), and high B-lymphocytes.

Based on these findings, the diagnosis of DOCK 8 deficiency was reconsidered despite negative previous genetic testing in the primary immunodeficiency panel and WES. Therefore, targeted gene sequencing for the DOCK 8 gene was performed using next-generation sequencing (NGS). NGS did not reveal any point mutations. However, due to the classic phenotype, a copy number variation (CNV) analysis of NGS data was performed which showed a large homozygous deletion in the DOCK 8 gene, including exons 23 to 48 (note that the DOCK 8 gene has 48 exons). This deletion was confirmed by Multiplex Ligation Probe Amplification (MLPA) (SALSA® MLPA® Probemix, MRC Holland, Amsterdam, The Netherlands). The CNV analysis data and the full result report are shown in [Supplementary material 2](#) and [3](#), respectively.

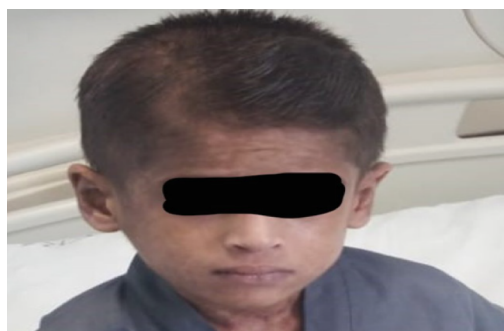FINAL DIAGNOSIS

Based on this finding, the patient was diagnosed with DOCK 8 deficiency.



DOI: 10.12998/wjcc.v10.i29.10735 Copyright ©The Author(s) 2022.

Figure 1 Skin rash that appeared during the sixth week of admission. A: Disseminated vesicular rash that was thought to be dermatitis herpetiformis associated with celiac disease and found to be eczema herpeticum with positive polymerase chain reaction result for herpes simplex virus from the lesions and blood; and B: Closer image of the lesions involving the face.



DOI: 10.12998/wjcc.v10.i29.10735 Copyright ©The Author(s) 2022.

Figure 2 Improvement in skin rash after treatment with intravenous acyclovir for 14 days.

TREATMENT

The patient's condition improved after the initiation of regular intravenous immunoglobulin (IVIG) therapy. The patient was referred to a bone marrow transplantation (BMT) center. He underwent hematopoietic stem cell transplantation (HSCT) from a partially mismatched sibling donor at the age of 10 years.

OUTCOME AND FOLLOW-UP

Unfortunately, the transplantation was complicated by engraftment failure, and the patient died from multiorgan failure after 6 wk.

DISCUSSION

This case report describes an unusual presentation of PID with viral, bacterial, and parasitic co-infections in a child. This led to a high index of suspicion and a final diagnosis of DOCK 8 deficiency secondary to a large deletion in the DOCK 8 gene. The diagnosis was delayed because of the negative results of the PID panel for point mutations, as well as negative WES. The diagnosis was made using target gene testing and CNV analysis.

The clinical and laboratory findings of the patient reported here are consistent with most cases reported in the literature[1,4]. Eczema, food allergies, recurrent and persistent viral infections, eosinophilia, elevated IgE, and low T lymphocyte levels are characteristics of DOCK 8 deficiency[1,4]. A

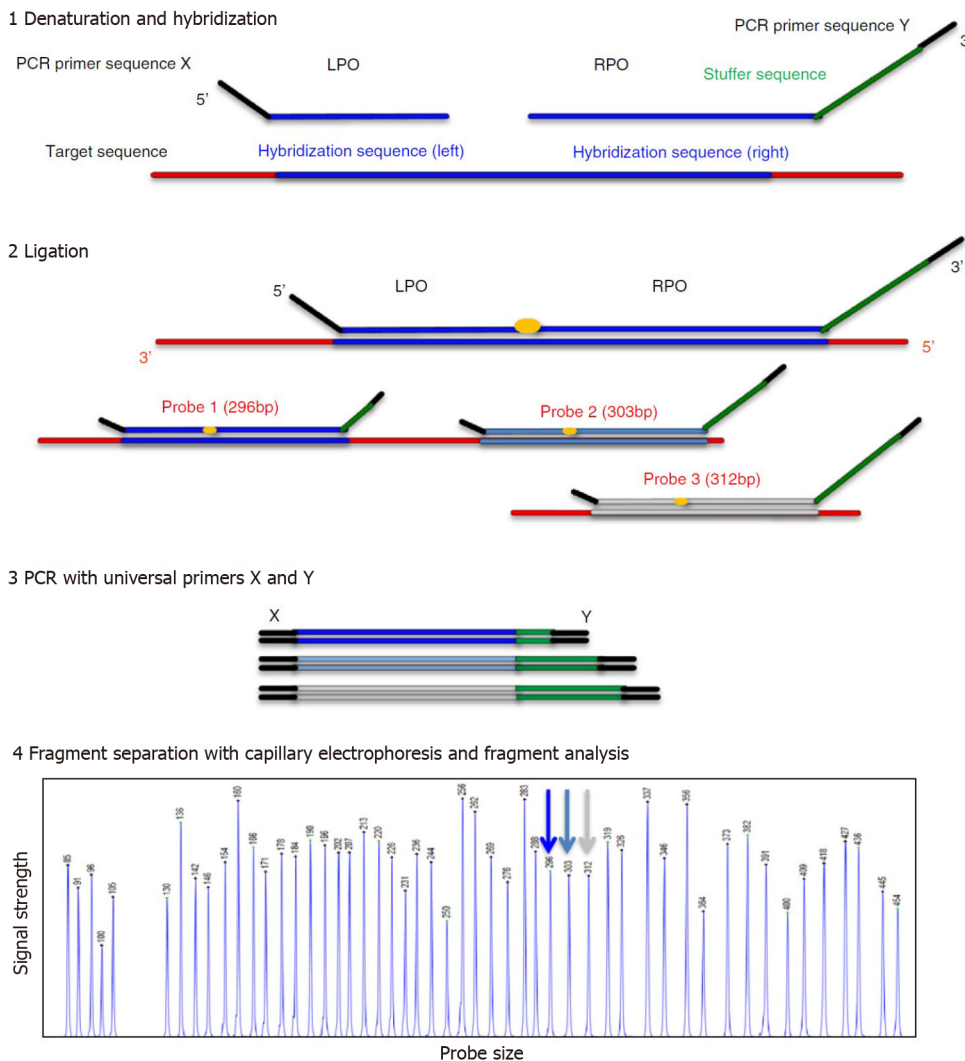


Figure 3 An overview of multiplex ligation-dependent probe amplification technology for copy number detection. An outline of the MLPA technique: (1) Multiplex ligation-dependent probe amplification (MLPA) probes consist of 2 hemiprobes: a 50 oligonucleotide called the left probe oligonucleotide (LPO) and the 30 oligonucleotide called the right probe oligonucleotide (RPO), which target adjacent sequences (blue) and a polymerase chain reaction (PCR) primer sequence (black). The RPO has a nonhybridizing stuffer sequence (green), which gives the probe a specific length. To begin the reaction, the MLPA probe mix is added to denatured DNA for approximately 16 hours of hybridization; (2) After successful hybridization to their target sequences in the sample DNA, the bound probe oligonucleotides are enzymatically ligated, creating a template for the subsequent PCR reaction; (3) In the PCR reaction, all MLPA probes are amplified by the same PCR primer pair (X and Y), allowing semiquantitative amplification of the probes; (4) Because of the different lengths of the stuffer sequences, the amplification products of different MLPA probes can be separated, identified, and quantified by capillary electrophoresis. This allows the use of up to 50 probes in a single MLPA reaction. Relative amounts of probe amplification products, as compared with a reference DNA sample, reflect the relative copy number of the target sequences. PCR: Polymerase chain reaction; RPO: Right probe oligonucleotide; LPO: Left probe oligonucleotide. Citation: Hömig-Hölzel C, Savola S. Multiplex ligation-dependent probe amplification (MLPA) in tumor diagnostics and prognostics. *Diagn Mol Pathol* 2012; 21: 189-206. Copyright ©The Authors 2012. Published by Wolters Kluwer Health, Inc.

unique feature of the patient reported here is multiple coinfections with different viruses (HSV, CMV, and EBV) and severe *cryptosporidiosis* at the same time. Although these infections have been reported among DOCK 8 patients separately, to our knowledge, coinfection has not been reported[4,5]. This coinfection was a clue to the diagnosis in this case.

The genetic deletion in our patient was detected by CNV analysis of the target gene NGS data and confirmed by MLPA after negative results for point mutation obtained from NGS. NGS is a new DNA sequencing method that can be used for whole-genome sequencing (WGS), WES, and targeted genes sequencing[6]. One of the known limitations of NGS in WES and targeted gene sequencing is the inability to detect deletions and duplications in the tested genes, as this requires a different analysis pipeline[6]. This limitation can be overcome by WGS, but it is expensive and time-consuming[6]. However, a new method for CNV analysis of NGS data using software is a promising technique for detecting this type of deletion[6]. Both point mutations and deletions have been reported in patients with DOCK 8 deficiency[7]. Therefore, testing for both deletion and point mutation should be performed when the phenotype is consistent with the genetic defect to overcome the false-negative result when only point mutation is tested, while the cause is a large deletion, as in our patient.

The CNV analysis of our patient's NGS data was confirmed by MLPA. MLPA is a molecular technique that was developed by MRC Holland (Amsterdam, The Netherlands) in 2002, and can detect copy number variations (duplication or deletion), point mutations, and quantify the messenger RNA[8]. Figure 3 illustrates the MLPA method[9].

Early diagnosis and HSCT play critical roles in the treatment of patients with DOCK 8 deficiency. Evidence regarding BMT in patients with DOCK 8 deficiency is growing. A large retrospective multicenter study involving 81 patients with DOCK 8 deficiency showed that patients who underwent HSCT before age of 8 had better 2-year overall survival than those who were older than 8 (96% vs 78%) [10].

CONCLUSION

This case report shows the limitations of genetic testing and the essential rules of clinical findings to guide laboratory testing. Our study suggests that DOCK 8 deficiency should be considered in any child presenting with the typical symptoms, and both mutations and deletions should be tested to avoid delays in diagnosis and optimize outcomes with early HSCT.

ACKNOWLEDGEMENTS

The author would like to thank Dr. Abdulhadi Habeb, Dr. Yousef El-Hag, The Department of Pediatrics, and Mr. Abdurhaman Aboud, Laboratory Medicine Department, Prince Mohammad Bin Abdulaziz Hospital, The Ministry of National Guard Health Affairs, Al-Madinah, Saudi Arabia, for their support in genetic testing. Author would like to thank Suvi Savola, MRC, Holand and the Publisher Wolters Kluwer Health, Inc. for the permission to reuse figure 3.

FOOTNOTES

Author contributions: Alshengeti A has prepared and finalized the whole manuscript.

Informed consent statement: This case report was approved by the Research Ethics Board of King Abdullah International Medical Research Center (KAIMRC), National Guard Health Affairs (NGHA), Ministry of National Guard, Jeddah, Saudi Arabia. Written informed consent was obtained from the patient's father.

Conflict-of-interest statement: The author declares no conflict of interest.

CARE Checklist (2016) statement: The authors have read the CARE Checklist (2016), and the manuscript was prepared and revised according to the CARE Checklist (2016).

Open-Access: This article is an open-access article that was selected by an in-house editor and fully peer-reviewed by external reviewers. It is distributed in accordance with the Creative Commons Attribution NonCommercial (CC BY-NC 4.0) license, which permits others to distribute, remix, adapt, build upon this work non-commercially, and license their derivative works on different terms, provided the original work is properly cited and the use is non-commercial. See: <https://creativecommons.org/licenses/by-nc/4.0/>

Country/Territory of origin: Saudi Arabia

ORCID number: Amer Alshengeti 0000-0001-6861-6934.

S-Editor: Ma YJ

L-Editor: A

P-Editor: Ma YJ

REFERENCES

- 1 **Zhang Q**, Davis JC, Lamborn IT, Freeman AF, Jing H, Favreau AJ, Matthews HF, Davis J, Turner ML, Uzel G, Holland SM, Su HC. Combined immunodeficiency associated with DOCK8 mutations. *N Engl J Med* 2009; **361**: 2046-2055 [PMID: 19776401 DOI: 10.1056/NEJMoa0905506]
- 2 **Alsum Z**, Hawwari A, Alsmadi O, Al-Hissi S, Borrero E, Abu-Staiteh A, Khalak HG, Wakil S, Eldali AM, Arnaout R, Al-Ghonaïm A, Al-Muhsen S, Al-Dhekri H, Al-Saud B, Al-Mousa H. Clinical, immunological and molecular characterization of DOCK8 and DOCK8-like deficient patients: single center experience of twenty-five patients. *J Clin Immunol* 2013; **33**:

- 55-67 [PMID: 22968740 DOI: 10.1007/s10875-012-9769-x]
- 3 **Saudi Mendeliome Group.** Comprehensive gene panels provide advantages over clinical exome sequencing for Mendelian diseases. *Genome Biol* 2015; **16**: 134 [PMID: 26112015 DOI: 10.1186/s13059-015-0693-2]
- 4 **Aydin SE,** Kilic SS, Aytekin C, Kumar A, Porras O, Kainulainen L, Kostyuchenko L, Genel F, Kütükcüler N, Karaca N, Gonzalez-Granado L, Abbott J, Al-Zahrani D, Rezaei N, Baz Z, Thiel J, Ehl S, Marodi L, Orange JS, Sawalle-Belohradsky J, Keles S, Holland SM, Sanal Ö, Ayvaz DC, Tezcan I, Al-Mousa H, Alsum Z, Hawwari A, Metin A, Matthes-Martin S, Hönig M, Schulz A, Picard C, Barlogis V, Gennery A, Ifversen M, van Montfrans J, Kuijpers T, Bredius R, Dückers G, Al-Herz W, Pai SY, Geha R, Notheis G, Schwarze CP, Tavit B, Azik F, Bienemann K, Grimbacher B, Heinz V, Gaspar HB, Aydin R, Hagl B, Gathmann B, Belohradsky BH, Ochs HD, Chatila T, Renner ED, Su H, Freeman AF, Engelhardt K, Albert MH; inborn errors working party of EBMT. DOCK8 deficiency: clinical and immunological phenotype and treatment options - a review of 136 patients. *J Clin Immunol* 2015; **35**: 189-198 [PMID: 25627830 DOI: 10.1007/s10875-014-0126-0]
- 5 **Su HC.** Dedicator of cytokinesis 8 (DOCK8) deficiency. *Curr Opin Allergy Clin Immunol* 2010; **10**: 515-520 [PMID: 20864884 DOI: 10.1097/ACI.0b013e32833fd718]
- 6 **Ellingford JM,** Campbell C, Barton S, Bhaskar S, Gupta S, Taylor RL, Sergouniotis PI, Horn B, Lamb JA, Michaelides M, Webster AR, Newman WG, Panda B, Ramsden SC, Black GC. Validation of copy number variation analysis for next-generation sequencing diagnostics. *Eur J Hum Genet* 2017; **25**: 719-724 [PMID: 28378820 DOI: 10.1038/ejhg.2017.42]
- 7 **Engelhardt KR,** McGhee S, Winkler S, Sassi A, Woellner C, Lopez-Herrera G, Chen A, Kim HS, Lloret MG, Schulze I, Ehl S, Thiel J, Pfeifer D, Veelken H, Niehues T, Siepermann K, Weinspach S, Reisli I, Keles S, Genel F, Kutukculer N, Camcioğlu Y, Somer A, Karakoc-Aydiner E, Barlan I, Gennery A, Metin A, Degerliyurt A, Pietrogrande MC, Yeganeh M, Baz Z, Al-Tamemi S, Klein C, Puck JM, Holland SM, McCabe ER, Grimbacher B, Chatila TA. Large deletions and point mutations involving the dedicator of cytokinesis 8 (DOCK8) in the autosomal-recessive form of hyper-IgE syndrome. *J Allergy Clin Immunol* 2009; **124**: 1289-302.e4 [PMID: 20004785 DOI: 10.1016/j.jaci.2009.10.038]
- 8 **Principle of MLPA.** Accessed August 14 2022. Available from: <https://www.mrcholland.com/technology/mlpa>
- 9 **Hörmig-Hölzel C,** Savola S. Multiplex ligation-dependent probe amplification (MLPA) in tumor diagnostics and prognostics. *Diagn Mol Pathol* 2012; **21**: 189-206 [PMID: 23111197 DOI: 10.1097/PDM.0b013e3182595516]
- 10 **Aydin SE,** Freeman AF, Al-Herz W, Al-Mousa HA, Arnaout RK, Aydin RC, Barlogis V, Belohradsky BH, Bonfim C, Bredius RG, Chu JI, Ciocarlie OC, Doğu F, Gaspar HB, Geha RS, Gennery AR, Hauck F, Hawwari A, Hickstein DD, Hoenig M, Ikinciogullari A, Klein C, Kumar A, Ifversen MRS, Matthes S, Metin A, Neven B, Pai SY, Parikh SH, Picard C, Renner ED, Sanal Ö, Schulz AS, Schuster F, Shah NN, Shereck EB, Slatter MA, Su HC, van Montfrans J, Woessmann W, Ziegler JB, Albert MH; Inborn Errors Working Party of the European Group for Blood and Marrow Transplantation and the European Society for Primary Immunodeficiencies. Hematopoietic Stem Cell Transplantation as Treatment for Patients with DOCK8 Deficiency. *J Allergy Clin Immunol Pract* 2019; **7**: 848-855 [PMID: 30391550 DOI: 10.1016/j.jaip.2018.10.035]



Published by **Baishideng Publishing Group Inc**
7041 Koll Center Parkway, Suite 160, Pleasanton, CA 94566, USA

Telephone: +1-925-3991568

E-mail: bpgoffice@wjgnet.com

Help Desk: <https://www.f6publishing.com/helpdesk>

<https://www.wjgnet.com>

