

World Journal of *Clinical Cases*

World J Clin Cases 2022 October 16; 10(29): 10391-10822



STANDARD AND CONSENSUS

- 10391** Baishideng's Reference Citation Analysis database announces the first Article Influence Index of multidisciplinary scholars

Wang JL, Ma YJ, Ma L, Ma N, Guo DM, Ma LS

REVIEW

- 10399** Cholecystectomy for asymptomatic gallstones: Markov decision tree analysis
Lee BJH, Yap QV, Low JK, Chan YH, Shelat VG
- 10413** Liver transplantation for hepatocellular carcinoma: Historical evolution of transplantation criteria
Ince V, Sahin TT, Akbulut S, Yilmaz S

MINIREVIEWS

- 10428** Prostate only radiotherapy using external beam radiotherapy: A clinician's perspective

Lee JW, Chung MJ

ORIGINAL ARTICLE

Retrospective Study

- 10435** Age-adjusted NT-proBNP could help in the early identification and follow-up of children at risk for severe multisystem inflammatory syndrome associated with COVID-19 (MIS-C)

Rodriguez-Gonzalez M, Castellano-Martinez A

- 10451** Clinicopathological characteristics and prognosis of gastric signet ring cell carcinoma

Tian HK, Zhang Z, Ning ZK, Liu J, Liu ZT, Huang HY, Zong Z, Li H

- 10467** Development and validation of a prognostic nomogram for decompensated liver cirrhosis

Zhang W, Zhang Y, Liu Q, Nie Y, Zhu X

Observational Study

- 10478** Effect of medical care linkage-continuous management mode in patients with posterior circulation cerebral infarction undergoing endovascular interventional therapy

Zhu FX, Ye Q

- 10487** Effect of the COVID-19 pandemic on patients with presumed diagnosis of acute appendicitis

Akbulut S, Tuncer A, Ogut Z, Sahin TT, Koc C, Guldogan E, Karabulut E, Tanriverdi ES, Ozer A

EVIDENCE-BASED MEDICINE

- 10501** Delineation of a SMARCA4-specific competing endogenous RNA network and its function in hepatocellular carcinoma

Zhang L, Sun T, Wu XY, Fei FM, Gao ZZ

SYSTEMATIC REVIEWS

- 10516** Comparison of laboratory parameters, clinical symptoms and clinical outcomes of COVID-19 and influenza in pediatric patients: A systematic review and meta-analysis

Yu B, Chen HH, Hu XF, Mai RZ, He HY

CASE REPORT

- 10529** Surgical treatment of bipolar segmental clavicle fracture: A case report

Liang L, Chen XL, Chen Y, Zhang NN

- 10535** Multiple disciplinary team management of rare primary splenic malignancy: Two case reports

Luo H, Wang T, Xiao L, Wang C, Yi H

- 10543** Klippel-Trenaunay-Weber syndrome with ischemic stroke: A case report

Lee G, Choi T

- 10550** Vedolizumab in the treatment of immune checkpoint inhibitor-induced colitis: Two case reports

Zhang Z, Zheng CQ

- 10559** Novel way of patent foramen ovale detection and percutaneous closure by intracardiac echocardiography: A case report

Han KN, Yang SW, Zhou YJ

- 10565** Treatment failure in a patient infected with *Listeria* sepsis combined with latent meningitis: A case report

Wu GX, Zhou JY, Hong WJ, Huang J, Yan SQ

- 10575** Three-in-one incidence of hepatocellular carcinoma, cholangiocellular carcinoma, and neuroendocrine carcinoma: A case report

Wu Y, Xie CB, He YH, Ke D, Huang Q, Zhao KF, Shi RS

- 10583** Intestinal microbiome changes in an infant with right atrial isomerism and recurrent necrotizing enterocolitis: A case report and review of literature

Kaplina A, Zaikova E, Ivanov A, Volkova Y, Alkhova T, Nikiforov V, Latypov A, Khavkina M, Fedoseeva T, Pervunina T, Skorobogatova Y, Volkova S, Ulyantsev V, Kalinina O, Sitkin S, Petrova N

- 10600** *Serratia fonticola* and its role as a single pathogen causing emphysematous pyelonephritis in a non-diabetic patient: A case report

Villasuso-Alcocer V, Flores-Tapia JP, Perez-Garfias F, Rochel-Perez A, Mendez-Dominguez N

- 10606** Cardiac myxoma shedding leads to lower extremity arterial embolism: A case report

Meng XH, Xie LS, Xie XP, Liu YC, Huang CP, Wang LJ, Zhang GH, Xu D, Cai XC, Fang X

- 10614** Extracorporeal membrane oxygenation in curing a young man after modified Fontan operation: A case report
Guo HB, Tan JB, Cui YC, Xiong HF, Li CS, Liu YF, Sun Y, Pu L, Xiang P, Zhang M, Hao JJ, Yin NN, Hou XT, Liu JY
- 10622** Wandering small intestinal stromal tumor: A case report
Su JZ, Fan SF, Song X, Cao LJ, Su DY
- 10629** Acute mesenteric ischemia secondary to oral contraceptive-induced portomesenteric and splenic vein thrombosis: A case report
Zhao JW, Cui XH, Zhao WY, Wang L, Xing L, Jiang XY, Gong X, Yu L
- 10638** Perioperative anesthesia management in pediatric liver transplant recipient with atrial septal defect: A case report
Liu L, Chen P, Fang LL, Yu LN
- 10647** Multiple tophi deposits in the spine: A case report
Chen HJ, Chen DY, Zhou SZ, Chi KD, Wu JZ, Huang FL
- 10655** Myeloproliferative neoplasms complicated with β -thalassemia: Two case report
Xu NW, Li LJ
- 10663** Synchronous renal pelvis carcinoma associated with small lymphocytic lymphoma: A case report
Yang HJ, Huang X
- 10670** *Leclercia adecarboxylata* infective endocarditis in a man with mitral stenosis: A case report and review of the literature
Tan R, Yu JQ, Wang J, Zheng RQ
- 10681** Progressive ataxia of cerebrotendinous xanthomatosis with a rare c.255+1G>T splice site mutation: A case report
Chang YY, Yu CQ, Zhu L
- 10689** Intravesical explosion during transurethral resection of bladder tumor: A case report
Xu CB, Jia DS, Pan ZS
- 10695** Submucosal esophageal abscess evolving into intramural submucosal dissection: A case report
Jiao Y, Sikong YH, Zhang AJ, Zuo XL, Gao PY, Ren QG, Li RY
- 10701** Immune checkpoint inhibitor-associated arthritis in advanced pulmonary adenocarcinoma: A case report
Yang Y, Huang XJ
- 10708** Chondroid syringoma of the lower back simulating lipoma: A case report
Huang QF, Shao Y, Yu B, Hu XP
- 10713** Tension-reduced closure of large abdominal wall defect caused by shotgun wound: A case report
Li Y, Xing JH, Yang Z, Xu YJ, Yin XY, Chi Y, Xu YC, Han YD, Chen YB, Han Y

- 10721** Myocardial bridging phenomenon is not invariable: A case report
Li HH, Liu MW, Zhang YF, Song BC, Zhu ZC, Zhao FH
- 10728** Recurrent atypical leiomyoma in bladder trigone, confused with uterine fibroids: A case report
Song J, Song H, Kim YW
- 10735** Eczema herpeticum *vs* dermatitis herpetiformis as a clue of dedicator of cytokinesis 8 deficiency diagnosis: A case report
Alshengeti A
- 10742** Cutaneous allergic reaction to subcutaneous vitamin K₁: A case report and review of literature
Zhang M, Chen J, Wang CX, Lin NX, Li X
- 10755** Perithyroidal hemorrhage caused by hydrodissection during radiofrequency ablation for benign thyroid nodules: Two case reports
Zheng BW, Wu T, Yao ZC, Ma YP, Ren J
- 10763** Malignant giant cell tumors of the tendon sheath of the right hip: A case report
Huang WP, Gao G, Yang Q, Chen Z, Qiu YK, Gao JB, Kang L
- 10772** Atypical Takotsubo cardiomyopathy presenting as acute coronary syndrome: A case report
Wang ZH, Fan JR, Zhang GY, Li XL, Li L
- 10779** Secondary light chain amyloidosis with Waldenström's macroglobulinemia and internodal marginal zone lymphoma: A case report
Zhao ZY, Tang N, Fu XJ, Lin LE
- 10787** Bilateral occurrence of sperm granulomas in the left spermatic cord and on the right epididymis: A case report
Ly DY, Xie HJ, Cui F, Zhou HY, Shuang WB
- 10794** Glucocorticoids combined with tofacitinib in the treatment of Castleman's disease: A case report
Liu XR, Tian M
- 10803** Giant bilateral scrotal lipoma with abnormal somatic fat distribution: A case report
Chen Y, Li XN, Yi XL, Tang Y
- 10811** Elevated procalcitonin levels in the absence of infection in procalcitonin-secreting hepatocellular carcinoma: A case report
Zeng JT, Wang Y, Wang Y, Luo ZH, Qing Z, Zhang Y, Zhang YL, Zhang JF, Li DW, Luo XZ

LETTER TO THE EDITOR

- 10817** "Helicobacter pylori treatment guideline: An Indian perspective": Letter to the editor
Swarnakar R, Yadav SL
- 10820** Effect of gender on the reliability of COVID-19 rapid antigen test among elderly
Nori W, Akram W

ABOUT COVER

Editorial Board Member of *World Journal of Clinical Cases*, Natalia Stepanova, DSc, MD, PhD, Academic Research, Chief Doctor, Full Professor, Department of Nephrology and Dialysis, State Institution "Institute of Nephrology of the National Academy of Medical Sciences of Ukraine", Kyiv 04050, Ukraine. nmstep88@gmail.com

AIMS AND SCOPE

The primary aim of *World Journal of Clinical Cases* (WJCC, *World J Clin Cases*) is to provide scholars and readers from various fields of clinical medicine with a platform to publish high-quality clinical research articles and communicate their research findings online.

WJCC mainly publishes articles reporting research results and findings obtained in the field of clinical medicine and covering a wide range of topics, including case control studies, retrospective cohort studies, retrospective studies, clinical trials studies, observational studies, prospective studies, randomized controlled trials, randomized clinical trials, systematic reviews, meta-analysis, and case reports.

INDEXING/ABSTRACTING

The WJCC is now abstracted and indexed in Science Citation Index Expanded (SCIE, also known as SciSearch®), Journal Citation Reports/Science Edition, Current Contents®/Clinical Medicine, PubMed, PubMed Central, Scopus, Reference Citation Analysis, China National Knowledge Infrastructure, China Science and Technology Journal Database, and Superstar Journals Database. The 2022 Edition of Journal Citation Reports® cites the 2021 impact factor (IF) for WJCC as 1.534; IF without journal self cites: 1.491; 5-year IF: 1.599; Journal Citation Indicator: 0.28; Ranking: 135 among 172 journals in medicine, general and internal; and Quartile category: Q4. The WJCC's CiteScore for 2021 is 1.2 and Scopus CiteScore rank 2021: General Medicine is 443/826.

RESPONSIBLE EDITORS FOR THIS ISSUE

Production Editor: Hua-Ge Yin; Production Department Director: Xiang Li; Editorial Office Director: Jin-Lei Wang.

NAME OF JOURNAL

World Journal of Clinical Cases

ISSN

ISSN 2307-8960 (online)

LAUNCH DATE

April 16, 2013

FREQUENCY

Thrice Monthly

EDITORS-IN-CHIEF

Bao-Gan Peng, Jerzy Tadeusz Chudek, George Kontogeorgos, Maurizio Serati, Ja Hyeon Ku

EDITORIAL BOARD MEMBERS

<https://www.wjgnet.com/2307-8960/editorialboard.htm>

PUBLICATION DATE

October 16, 2022

COPYRIGHT

© 2022 Baishideng Publishing Group Inc

INSTRUCTIONS TO AUTHORS

<https://www.wjgnet.com/bpg/gerinfo/204>

GUIDELINES FOR ETHICS DOCUMENTS

<https://www.wjgnet.com/bpg/GerInfo/287>

GUIDELINES FOR NON-NATIVE SPEAKERS OF ENGLISH

<https://www.wjgnet.com/bpg/gerinfo/240>

PUBLICATION ETHICS

<https://www.wjgnet.com/bpg/GerInfo/288>

PUBLICATION MISCONDUCT

<https://www.wjgnet.com/bpg/gerinfo/208>

ARTICLE PROCESSING CHARGE

<https://www.wjgnet.com/bpg/gerinfo/242>

STEPS FOR SUBMITTING MANUSCRIPTS

<https://www.wjgnet.com/bpg/GerInfo/239>

ONLINE SUBMISSION

<https://www.f6publishing.com>



Giant bilateral scrotal lipoma with abnormal somatic fat distribution: A case report

Yu Chen, Xiu-Ning Li, Xian-Lin Yi, Yong Tang

Specialty type: Urology and nephrology

Provenance and peer review: Unsolicited article; Externally peer reviewed.

Peer-review model: Single blind

Peer-review report's scientific quality classification

Grade A (Excellent): 0
Grade B (Very good): B
Grade C (Good): C
Grade D (Fair): 0
Grade E (Poor): 0

P-Reviewer: Carannante F, Italy; Wang P, China

Received: July 14, 2022

Peer-review started: July 14, 2022

First decision: August 1, 2022

Revised: August 11, 2022

Accepted: September 1, 2022

Article in press: September 1, 2022

Published online: October 16, 2022



Yu Chen, Xiu-Ning Li, Xian-Lin Yi, Yong Tang, Department of Urology, Wuming Hospital of Guangxi Medical University, Nanning 530199, Guangxi Zhuang Autonomous Region, China

Corresponding author: Yong Tang, MD, Chief Doctor, Department of Urology, Wuming hospital of Guangxi Medical University, No. 26 Yongning Road, Wuming District, Nanning City, Guangxi Zhuang Autonomous Region, China. yong_tang_md@hotmail.com

Abstract

BACKGROUND

Scrotal lipoma is exceedingly rare, so its origin is still unknown. Injury is suggested as a potential factor, but the cause remains unclear. It is difficult to determine the origin of these tumours. Previous studies have suggested that these tumours may be congenital or that they originate from small fatty particles around the cord. Other studies have suggested that these tumours originate from testicles or the tunica.

CASE SUMMARY

A 66-years elderly male with giant scrotal mass. B-ultrasound, computed tomography and magnetic resonance imaging examinations are typical lipoma-like changes, which were confirmed by postoperative pathological analysis. Abnormal somatic fat distribution was confirmed by images. no recurrence after follow-up for 2 years. Previously published English-language literature was reviewed, and a history of inguinal or pelvic surgery was reported in 6 studies (total 21 cases). To our knowledge, this is the heaviest bilateral scrotal lipoma in the English-language literature, and it has the longest postoperative follow-up time. More importantly, the origin of these tumours is reviewed and discussed.

CONCLUSION

Giant bilateral scrotal lipoma in elderly may as part of the symptoms of abnormal somatic fat distribution.

Key Words: Lipoma; Crotum; Bilateral; Extratesticular tumour; Fat distribution; Case report

©The Author(s) 2022. Published by Baishideng Publishing Group Inc. All rights reserved.

Core Tip: A case of giant bilateral scrotal lipoma was reported, and the literature was reviewed. A 66-year-old male with a giant scrotal mass was evaluated. Surgical treatment was performed, and scrotal lipoma were confirmed by postoperative pathological analysis. This is the heaviest bilateral scrotal lipoma in the English-language literature, and it has the longest postoperative follow-up time. More importantly, the origin of these tumours is reviewed and discussed.

Citation: Chen Y, Li XN, Yi XL, Tang Y. Giant bilateral scrotal lipoma with abnormal somatic fat distribution: A case report. *World J Clin Cases* 2022; 10(29): 10803-10810

URL: <https://www.wjgnet.com/2307-8960/full/v10/i29/10803.htm>

DOI: <https://dx.doi.org/10.12998/wjcc.v10.i29.10803>

INTRODUCTION

In 1780, Pelletan described a fatty tumour of the cord[1]. In 1883, Roswell Park reported a case of intrascrotal lipoma and concurrently reviewed three reported cases[1,2]. Cecil[1] reported a case of intrascrotal lipoma in 1927.

Scrotal lipoma is exceedingly rare, so its origin is still unknown[2,3]. Injury is suggested as a potential factor, but the cause remains unclear. It is difficult to determine the origin of these tumours. Previous studies have suggested that these tumours may be congenital[4] or that they originate from small fatty particles around the cord. Other studies have suggested that these tumours originate from testicles or the tunica[2].

These tumours are very large. A 75-cm lipoma from the scrotum to the knee was reported by Kocher [1]. Regarding weight, Brossard reported a tumour that weighed 9 pounds, and Bonney reported a 20-pound fibrolipoma in 1930[2]. However, no pure lipoma was observed[1]. A study published in 1930 reported a giant scrotal lipoma weighing 480-1100 g[2,5]. Seidu *et al*[5] reported a large unilateral scrotal mass that weighed 1100 g in 2020.

Herein, a large bilateral scrotal lipoma with abnormal accumulation of body surface fat was reported. To our knowledge, this is the heaviest bilateral scrotal lipoma in the English-language literature, and it has the longest postoperative follow-up time. More importantly, the origin of these tumours is reviewed and discussed.

CASE PRESENTATION

Chief complaints

Progressive enlargement of bilateral scrotum for more than one year.

History of present illness

At first, the bilateral scrotal tumours were small (approximately the size of peanuts); then, they became larger. The patients reported slight itching, but no pain or other discomfort. Both sides of his scrotum were obviously enlarged, approximately 13 cm in diameter, and the skin of the scrotum was tight, with no redness or varicose veins.

History of past illness

The patient had undergone electroresection of the prostate and bladder lithotripsy for benign prostatic hyperplasia three years ago in our clinic.

Physical examination

It was failure to touch spermatic cord and testes with negative light transmission test (Figure 1A).

Laboratory examinations

Serum beta-human chorionic gonadotropin, alpha-fetoprotein and lactate dehydrogenase levels were normal. Abnormally decreased platelets were shown from the first operation (Table 1). A bone marrow test was performed, and immune thrombocytopenia was diagnosed.

Imaging examinations

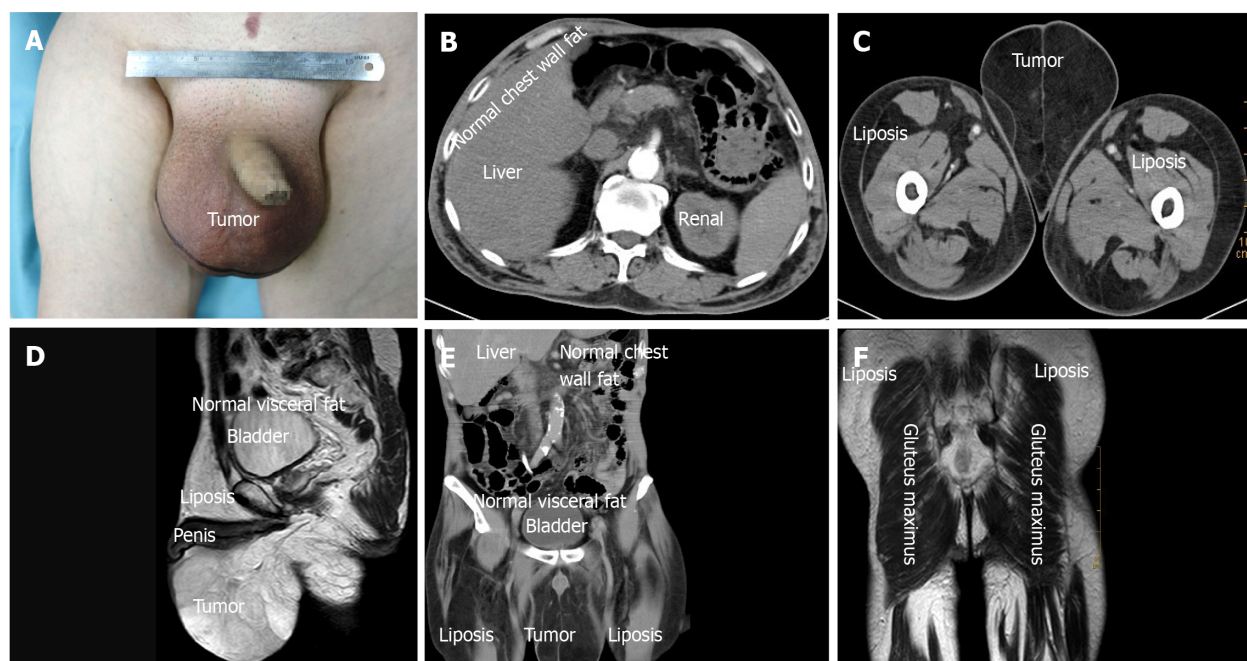
Scrotal ultrasonography showed a slightly higher echogenic mass. The computed tomography (CT) scan showed diffuse fat accumulation in the scrotum, and its density was not uniform. The CT value range was approximately -66 to -94 Hu. The testicles on both sides were normal in size and compressed by the

Table 1 Laboratory test results before first and second surgery¹

Test	First operation (3 yr ago)	Current operation	Normal reference range
CRP	< 5	< 5	0-10 mg/L
hs-CRP	2.74	3.56	0-3 mg/L
Hemoglobin	136	130	131-172 g/L
Red blood cell count	3.95	3.62	$4-5.5 \times 10^9/L$
White blood cell count	3.38	2.7	$4-10 \times 10^9/L$
Platelets	93	58	$100-300 \times 10^9/L$
Cholinesterase	3223	2587	5320-12920
Glutamyltransferase	233	256	8-73
LDH	360	366	120-250 g/L
Myoglobin	29.3	22.4	25-58
Glutamate dehydrogenase	41	25	0-5
Triglyceride	N/A	1.38	0.48-1.7
Apolipoprotein-A1	N/A	1.97	1-1.6
Thyroid stimulating hormone	13.52	8.39	0.27-4.2
Ferritin	N/A	942	30-400 $\mu g/L$

¹N/A, not applicable.

CRP: C-reactive protein; hs-CRP: High-sensitivity C-reactive protein; LDH: Lactate dehydrogenase.



DOI: 10.12998/wjcc.v10.i29.10803 Copyright ©The Author(s) 2022.

Figure 1 Bilateral scrotal lipoma imaging examination findings. A: Preoperative scrotal lipoma image; B-D: The computer tomography images showed liposis of the lower abdomen, perineum and thigh but no liposis in the chest wall or pelvic cavity; E and F: Magnetic resonance imaging image showing the same findings.

scrotal wall (Figure 1B-D). A magnetic resonance imaging (MRI) scan showed bilateral patchy abnormal signals on both scrotum, high signals on T1 weighted imaging and T2 weighted imaging (T2WI) scans, a low signal on a T2WI lipid-suppressing sequence, no obvious diffusion-restricted signal changes on diffusion weighted imaging and apparent diffusion coefficient, and no obvious abnormal enhancement on an enhanced scan (Figure 1E and F).

FINAL DIAGNOSIS

Giant bilateral scrotal lipoma with abnormal somatic fat distribution.

TREATMENT

Surgical treatment was performed. The tumour squeezed the bilateral testis, epididymis and spermatic cord tightly against the inner wall of the scrotum, and the boundary between the tumour and the testis was obvious. The capsules of both tumours were intact, lobulated, light yellow, and soft (Figure 2A-D). The cut surface was off-white and slightly tough. The total weight of bilateral scrotal tumours reached 995 g (Figure 2E). Bilateral scrotal lipomas were confirmed by postoperative pathology (Figure 2F). follow-up only postoperative, no radiotherapy and chemotherapy.

OUTCOME AND FOLLOW-UP

The patient was followed up for two years and no recurrence was found.

DISCUSSION

Scrotal lipoma is very rare, and only approximately 20 cases have been reported[3,6]. In most cases, the aetiology and origination are still unknown. Some patients are young[7], and the cause is suggested to be congenital[4]. However, some patients were older than 60 years, as shown in Table 2. An elderly patient with abnormal fat somatic distribution was reported herein, and its origin was discussed in this study.

Florante *et al*[8] used the term "extratesticular" to describe scrotal tumours that do not directly affect the testes themselves. While 95% of testicular tumours are malignant, most paratesticular tumours, including scrotal lipoma, are benign[9].

Large scrotal lipomas often present with scrotal enlargement and discomfort[10-12]. A large right scrotal mass that weighed 1100 g was reported[5]. Yamamichi *et al*[13] reported a case of scrotal lipoma with a maximum diameter of 14 cm combined with liposarcoma (weight 250 g). The lesion described in the current report is the heaviest bilateral scrotal lipoma in the English-language literature[10-12], which was 995 g in weight (Figure 1D).

Scrotal lipomas can be divided into three types[14]: (1) Originating from the posterior spermatic cord and spreading into the scrotum; (2) Originating from the inside or outside of the spermatic cord, and (3) originating from fat lobules of the scrotal dartos tunica. The latter lipomas are called primary scrotal lipomas, and they usually occur in young individuals[4].

However, abnormal somatic fat distribution may be an important influencing factor in the current case. The CT and MRI results of this patient showed liposis of the lower abdomen, perineum and thigh but no liposis in the chest wall or pelvic cavity (Figure 1B-F). Excess fat around the penis was shown on MRI (Figure 1D). A fat test was performed, and only apolipoprotein-A1 was slightly increased (Table 1). Multiple metabolic enzyme abnormalities were also shown, which lasted for three years in this case (Table 1). These results showed that bilateral scrotal lipoma in elderly individuals may be a symptom of abnormal somatic fat distribution caused by metabolic diseases. Because the scrotal tissue is loose and extensible, which is more suitable for fat accumulation, bilateral scrotal lipoma developed. Recently, a giant bilateral scrotal lipoma along with multiple lipomas was also reported[3]. Indirect evidence can also be provided by many patients with obesity[15].

The aetiology of scrotal lipoma is still unclear. In addition to congenital factors[4], local pluripotent cells develop into adipocyte lines[15]. Moreover, injury may be a factor when the lesion originates from the spermatic cord or inguinal canal in elderly individuals[2]. We reviewed the English-language literature, and a history of inguinal or pelvic surgery was reported in 6 patients, including the current patient (21 patients total, Table 2). However, a small mass similar to a peanut was observed before this patient's first operation three years ago. There was one case of contralateral inguinal surgery in the literature[8]. However, these results suggest that inguinal or pelvic surgery is an accelerating factor, if not an initiating factor.

Blood diseases may also play a role in the tumorigenesis of scrotal lipoma. This current case was diagnosed as primary thrombocytopenia due to decreased platelets for more than 3 years. Szmigielski *et al*[16] reported a case of a large scrotal lipoma that arose after venous thrombosis and pulmonary embolism. The scrotal mass in the 67-year-old patient was approximately 9 cm × 11 cm after taking oral anticoagulants for 3 mo.

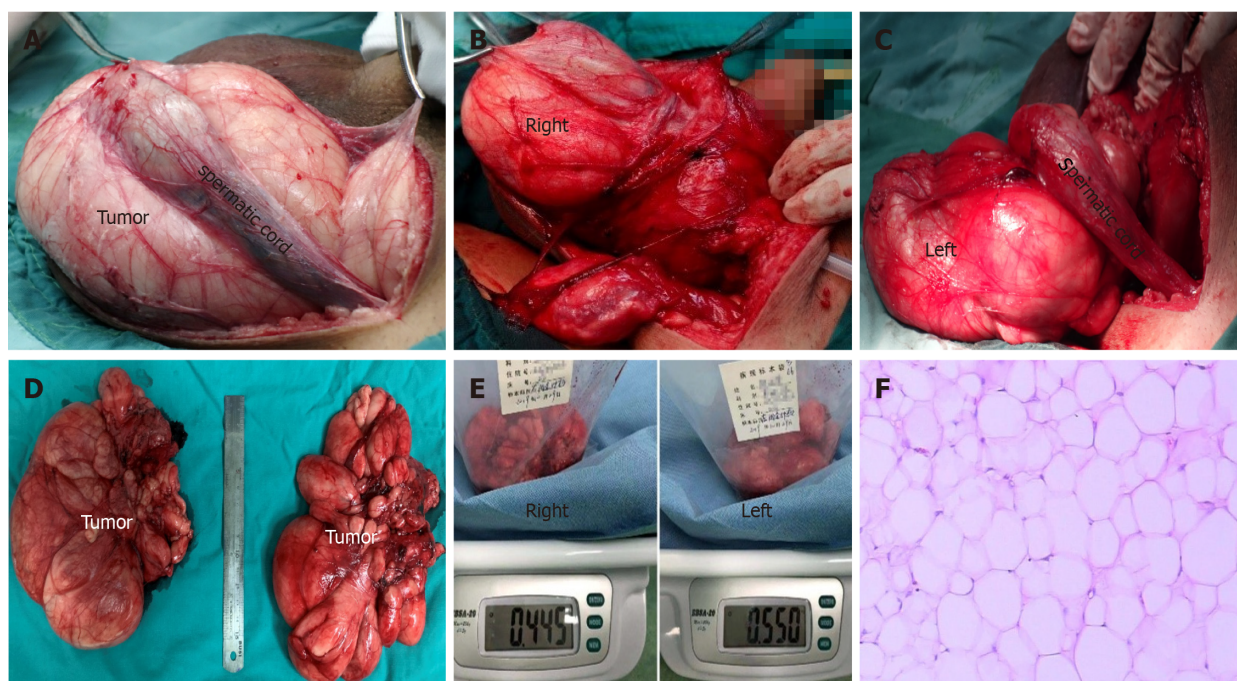
Ultrasonography and MRI play an important role in the evaluation of scrotal lipoma[11]. Ultrasound is the first choice for an investigation tool. MRI is the most sensitive method to distinguish a benign

Table 2 Literature review

Ref.	Age (yr)	Place (side)	Size (cm)	Weight (g)	Symptom	Presumably origination	Midical history (yr)	Operation history	Follow-up (mo)	Outcome/prognosis
Cecil[1]	44	Left	10.5 × 9 × 7.5	N/A	Hard lumb	Spermatic cord	8 yr	Fractured rib	N/A	N/A
Livermor[2]	75	Left	16.5 × 8.89	225	Weight and pressure	Spermatic cord	1 yr	Prostate surgery	N/A	N/A
Mccullough[20]	49	Left	Two 2.0 × 1.5 × 1.5	N/A	Pressure	Spermatic cord	5 yr	Inguinal surgery	N/A	N/A
Florante <i>et al</i> [8]	20	Right	5 × 3.5 × 2	N/A	Symptomless mass	Perineum	N/A	Contralateral inguinal surgery	N/A	No recurrence
Florante <i>et al</i> [8]	76	Right	3 × 2	N/A	Symptomless mass	Perineum	2 mo	Prostate surgery	N/A	N/A
Fujimura and Kurokawa[4]	19	Right	6.5 × 6 × 5	41	Symptomless mass	Scrotum (tunica dartos)	2 yr	N/A	N/A	No recurrence
Kryvenko <i>et al</i> [19]	37	Left	26 × 14 (scrotum)	N/A	N/a	Scrotal wall	18 mo	N/A	N/A	N/A
Kryvenko <i>et al</i> [19]	N/A	N/A	N/A	N/A	Inguinal and scrotal swelling	Inguinal canal	N/A	N/A	N/A	N/A
Szmigielski <i>et al</i> [16]	67	Both	17 × 16 × 11	N/A	Symptomless mass	Scrotal wall	2 yr	Pulmonary embolism	N/A	N/A
Edelstein[15]	48	N/A	7 × 6	N/A	Scrotal swelling	Spermatic cord	8 yr	Inguinal surgery	N/A	N/A
Kim <i>et al</i> [21]	1 mo	Midline	3 × 1.5	N/A	N/A	Scrotal wall	Congenital	N/A	N/A	N/A
Sakorafas and Polychronopoulos [22]	67	N/A	N/A	N/A	Mild discomfort	Scrotal wall	6 yr	N/A	N/A	No recurrence
Kaplanoglu <i>et al</i> [12]	64	Left	10 × 9 × 5	550	Painless swelling	Intrascrotal lipoma	10 yr	N/A	6	No recurrence
Fabiani <i>et al</i> [9]	22	Left	3 × 2	N/A	Painful nodule	Intrascrotal lipoma	3 mo	N/A	N/A	N/A
Creta <i>et al</i> [11]	54	Midline	8 × 10 × 12	600	Swelling	Scrotal wall	N/A	N/A	N/A	N/A
Srivastava <i>et al</i> [7]	29	Left	15 × 10	N/A	Increasing lump	Scrotum (tunica dartos)	N/A	N/A	N/A	No recurrence
Yamamichi <i>et al</i> [13]	58	Left	14 × 6	250	Swelling and discomfort	Scrotal wall	46 yr	N/A	6	No recurrence
Vignot <i>et al</i> [23]	47	Left	17 × 11 × 6	460	Large left scrotal mass	Scrotal wall	10 yr	N/A	N/A	No recurrence
Zheng <i>et al</i> [3]	47	Both	Right 9.9 × 4.5, left 10.8 × 5.6	N/A	Progressively enlarging lumps	Scrotal wall	8 mo	N/A	5	No recurrence
Seidu <i>et al</i> [5]	28	Right	21 × 7 × 9	1100	Inguinoscrotal swelling	Inguinal canal	3 yr	N/A	N/A	N/A
Current case	66	Both	13 × 11 × 10	995	Swelling	Inguinal canal	3 yr	Thrombocytopenia; cystolithotomy	24	No recurrence

N/A: Not applicable.

lesion from a malignant lesion. High T1 signal strength is a characteristic of fat-containing tumours. Nevertheless, it is difficult to distinguish low-grade liposarcoma from benign lipoma based on MRI findings alone[17]. Complete removal of a tumour by surgery and pathological examination can confirm lipoma[11]. Lipoma is homogenous, and its CT values are between -50 and -150 Hounsfield units; this



DOI: 10.12998/wjcc.v10.i29.10803 Copyright ©The Author(s) 2022.

Figure 2 Bilateral scrotal lipoma specimen and pathology. A: Incision of the scrotum: the testis and spermatic cord were squeezed, the boundary between the tumour and the tumour was clear, and slight adherence was evident; B: Right scrotal lipoma; C: Left scrotal lipoma; D and E: Bilateral scrotal lipoma postoperative specimen and weighing (approximately 995 g); F: Hematoxylin-eosin staining (40 ×).

information can help in the identification of liposarcoma[16].

If lipomas are excluded, more than 50% of spermatic cord tumours are malignant[18]. If the tumour grows rapidly beyond 10 cm, liposarcoma should be considered in the differential diagnosis[19]. To our knowledge, this is the longest reported postoperative follow-up time. Yamamichi *et al*[13] reported a case and follow-up for six months[13]. Kaplanoglu *et al*[12] reported a case of intrascrotal lipoma (weight 550 g) with a diameter of 10 cm[12]. No tumour recurrence was observed after six months of follow-up. The main limitation of this study is that it is a case report, and there are no genomic data.

CONCLUSION

To our knowledge, this is the heaviest bilateral scrotal lipoma and the longest postoperative follow-up time in English-language literature. Bilateral scrotal lipoma in elderly maybe as part of the symptoms of abnormal somatic fat distribution, which caused by metabolic diseases. Inguinal or pelvic surgery is an accelerating factor, if not an initiating factor. Blood system diseases may also play a role in the tumorigenesis.

FOOTNOTES

Author contributions: Chen Y, Li XN, Yi XL are joint first authors; Chen Y, Li XN, Tang Y contributed to study design and patient surgery; Chen Y, Li XN, Yi XL, Tang Y contributed to acquisition, analysis and interpretation of data, drafting of the manuscript; all authors have read and approved the final manuscript, written consent to publication was obtained.

Supported by the "139" Plan for Cultivating High-level and Key Talents in Guangxi Medicine, No. G201903036; Key Research and Development Plan Projects of Scientific Research and Technology Development Plan in Wuming District of Nanning, No. 20180120; and National Natural Science Fund of China, No 31860289.

Informed consent statement: A written informed consent was obtained from the patient for publication of this case report.

Conflict-of-interest statement: The authors have nothing to disclose.

CARE Checklist (2016) statement: The authors have read the CARE Checklist (2016), and the manuscript was

prepared and revised according to the CARE Checklist (2016).

Open-Access: This article is an open-access article that was selected by an in-house editor and fully peer-reviewed by external reviewers. It is distributed in accordance with the Creative Commons Attribution NonCommercial (CC BY-NC 4.0) license, which permits others to distribute, remix, adapt, build upon this work non-commercially, and license their derivative works on different terms, provided the original work is properly cited and the use is non-commercial. See: <https://creativecommons.org/licenses/by-nc/4.0/>

Country/Territory of origin: China

ORCID number: Yu Chen 0000-0001-6920-4982; Xiu-Ning Li 0000-0003-0376-6100; Xian-Lin Yi 0000-0002-3615-3784; Yong Tang 0000-0001-9214-4412.

S-Editor: Wang DM

L-Editor: A

P-Editor: Wang DM

REFERENCES

- 1 Cecil AB. Intrascrotal lipomata. *J Urol* 1927; **17**: 557-568 [DOI: [10.1016/S0022-5347\(17\)73375-7](https://doi.org/10.1016/S0022-5347(17)73375-7)]
- 2 LIVERMORE GR. Lipoma of the scrotum; case report. *J Urol* 1948; **60**: 153-155 [PMID: [18873056](https://pubmed.ncbi.nlm.nih.gov/18873056/) DOI: [10.1016/s0022-5347\(17\)69215-2](https://doi.org/10.1016/s0022-5347(17)69215-2)]
- 3 Zheng W, Shi M, Li T, Xu H, Chen Z, Wang X, Bai S, Le W, Yang L, Wei Q. Giant bilateral primary scrotal lipoma along with lipomas in multiple sites of the body: a case report and literature review. *Transl Androl Urol* 2021; **10**: 983-990 [PMID: [33718099](https://pubmed.ncbi.nlm.nih.gov/33718099/) DOI: [10.21037/tau-20-1073](https://doi.org/10.21037/tau-20-1073)]
- 4 Fujimura N, Kurokawa K. Primary lipoma of the scrotum. *Eur Urol* 1979; **5**: 182-183 [PMID: [446491](https://pubmed.ncbi.nlm.nih.gov/446491/) DOI: [10.1159/000473101](https://doi.org/10.1159/000473101)]
- 5 Seidu AS, Yorke J, Akpaloo J, Danso P, Sukenibe SS, Fiifi-Yankson PK, Aday-Aboagye K, Amoah G, Yamoah FA, Afful-Yorke D, Agyeman-Gyebi SNP, Brenu SG, Adjei E. Giant primary scrotal lipoma in a low-resource setting: challenges with diagnosis and review of literature. *J Surg Case Rep* 2021; **2021**: rjab398 [PMID: [34567516](https://pubmed.ncbi.nlm.nih.gov/34567516/) DOI: [10.1093/jscr/rjab398](https://doi.org/10.1093/jscr/rjab398)]
- 6 Galosi AB, Scarpelli M, Mazzucchelli R, Lopez-Beltran A, Giustini L, Cheng L, Montironi R. Adult primary paratesticular mesenchymal tumors with emphasis on a case presentation and discussion of spermatic cord leiomyosarcoma. *Diagn Pathol* 2014; **9**: 90 [PMID: [24885500](https://pubmed.ncbi.nlm.nih.gov/24885500/) DOI: [10.1186/1746-1596-9-90](https://doi.org/10.1186/1746-1596-9-90)]
- 7 Srivastava KN, Agarwal A, Siddharth Vikram SS, Gupta M. Huge scrotal lipoma posing a diagnostic dilemma: A case report and review of literature. *Urol Case Rep* 2017; **15**: 39-41 [PMID: [28983457](https://pubmed.ncbi.nlm.nih.gov/28983457/) DOI: [10.1016/j.eucr.2017.08.008](https://doi.org/10.1016/j.eucr.2017.08.008)]
- 8 Florante J, Leyson J, Doroshov LW, Robbins MA. Extratesticular lipoma: report of 2 cases and a new classification. *J Urol* 1976; **116**: 324-326 [PMID: [957499](https://pubmed.ncbi.nlm.nih.gov/957499/) DOI: [10.1016/s0022-5347\(17\)58801-1](https://doi.org/10.1016/s0022-5347(17)58801-1)]
- 9 Fabiani A, Principi E, Filosa A, Pieramici T, Fioretti F, Maurelli V, Servi L, Mammana G. An unusual case of primary intrascrotal lipoma. *Arch Ital Urol Androl* 2016; **88**: 345-346 [PMID: [28073211](https://pubmed.ncbi.nlm.nih.gov/28073211/) DOI: [10.4081/aiua.2016.4.345](https://doi.org/10.4081/aiua.2016.4.345)]
- 10 Masciovecchio S, Saldutto P, Del Rosso A, Galatioto GP, Vicentini C. [An unusual case of massive funicular lipoma]. *Urologia* 2014; **81**: 184-186 [PMID: [24474534](https://pubmed.ncbi.nlm.nih.gov/24474534/) DOI: [10.5301/urologia.5000035](https://doi.org/10.5301/urologia.5000035)]
- 11 Creta M, De Stefano G, Buonopane R, Barba C, Di Meo S, Imperatore V, Imbimbo C, Mirone V. Giant primary scrotal lipoma: A case report. *Arch Ital Urol Androl* 2017; **89**: 243-244 [PMID: [28969412](https://pubmed.ncbi.nlm.nih.gov/28969412/) DOI: [10.4081/aiua.2017.3.243](https://doi.org/10.4081/aiua.2017.3.243)]
- 12 Kaplanoglu V, Kaplanoglu H, Parlak IS, Tatar IG. Giant intrascrotal lipoma. *BMJ Case Rep* 2013; **2013** [PMID: [23946530](https://pubmed.ncbi.nlm.nih.gov/23946530/) DOI: [10.1136/bcr-2013-200500](https://doi.org/10.1136/bcr-2013-200500)]
- 13 Yamamichi G, Nakata W, Yamamoto A, Tsujimura G, Tsujimoto Y, Nin M, Tsujihata M. Liposarcoma of the spermatic cord associated with scrotum lipoma: A case report and review of the literature. *Urol Case Rep* 2018; **17**: 114-116 [PMID: [29541595](https://pubmed.ncbi.nlm.nih.gov/29541595/) DOI: [10.1016/j.eucr.2018.01.022](https://doi.org/10.1016/j.eucr.2018.01.022)]
- 14 Mostofi FK, Price EB. Tumors of the male genital system. *Ar For Instit of Pathol* 1973 [DOI: [10.1136/jcp.27.10.849-a](https://doi.org/10.1136/jcp.27.10.849-a)]
- 15 Edelstein RA. Giant spermatic cord lipoma. *ScientificWorldJournal* 2009; **9**: 1194-1196 [PMID: [19882088](https://pubmed.ncbi.nlm.nih.gov/19882088/) DOI: [10.1100/tsw.2009.140](https://doi.org/10.1100/tsw.2009.140)]
- 16 Szmigielski W, Khairat M, Haider A, Ejeckam GC. Huge scrotal lipoma masquerading as haematoma. *Clin Radiol* 2000; **55**: 479-480 [PMID: [10873696](https://pubmed.ncbi.nlm.nih.gov/10873696/) DOI: [10.1053/crad.2000.0090](https://doi.org/10.1053/crad.2000.0090)]
- 17 Muglia V, Tucci S Jr, Elias J Jr, Trad CS, Bilbey J, Cooperberg PL. Magnetic resonance imaging of scrotal diseases: when it makes the difference. *Urology* 2002; **59**: 419-423 [PMID: [11880084](https://pubmed.ncbi.nlm.nih.gov/11880084/) DOI: [10.1016/s0090-4295\(01\)01579-5](https://doi.org/10.1016/s0090-4295(01)01579-5)]
- 18 Patel NG, Rajagopalan A, Shrotri NS. Scrotal liposarcoma - a rare extratesticular tumour. *JRSM Short Rep* 2011; **2**: 93 [PMID: [22279603](https://pubmed.ncbi.nlm.nih.gov/22279603/) DOI: [10.1258/shorts.2011.011064](https://doi.org/10.1258/shorts.2011.011064)]
- 19 Kryvenko ON, Rosenberg AE, Jorda M, Epstein JI. Dedifferentiated liposarcoma of the spermatic cord: a series of 42 cases. *Am J Surg Pathol* 2015; **39**: 1219-1225 [PMID: [25828386](https://pubmed.ncbi.nlm.nih.gov/25828386/) DOI: [10.1097/PAS.0000000000000426](https://doi.org/10.1097/PAS.0000000000000426)]
- 20 McCULLOUGH CP. Unusual scrotal lipoma associated with sigmoid diverticulum. *Calif Med* 1953; **79**: 449-450 [PMID: [13106733](https://pubmed.ncbi.nlm.nih.gov/13106733/)]
- 21 Kim SO, Im CM, Joo JS, Oh KJ, Jung SI, Park K, Choi C, Kang TW, Kwon D, Ryu SB. Scrotal primary lipoma with unusual clinical appearance in newborn. *Urology* 2009; **73**: 1024-1025 [PMID: [19193418](https://pubmed.ncbi.nlm.nih.gov/19193418/) DOI: [10.1016/j.urology.2008.11.018](https://doi.org/10.1016/j.urology.2008.11.018)]
- 22 Sakorafas GH, Polychronopoulos D. Giant scrotal lipoma. *Eur J Cancer Care (Engl)* 2010; **19**: e5 [PMID: [19912293](https://pubmed.ncbi.nlm.nih.gov/19912293/) DOI: [10.1111/j.1365-2354.2008.00986.x](https://doi.org/10.1111/j.1365-2354.2008.00986.x)]

- 23 **Vignot L**, Saad E, Peyromaure M, Barry Delongchamps N. Giant Primary Scrotal Lipoma: A Rare Entity with Diagnostic Pitfalls. *Case Rep Urol* 2020; 2020: 8815845 [PMID: [33489406](#) DOI: [10.1155/2020/8815845](#)]



Published by **Baishideng Publishing Group Inc**
7041 Koll Center Parkway, Suite 160, Pleasanton, CA 94566, USA

Telephone: +1-925-3991568

E-mail: bpgoffice@wjgnet.com

Help Desk: <https://www.f6publishing.com/helpdesk>

<https://www.wjgnet.com>

