

World Journal of *Clinical Cases*

World J Clin Cases 2022 January 21; 10(3): 753-1139



Contents

Thrice Monthly Volume 10 Number 3 January 21, 2022

OPINION REVIEW

- 753 Lung injury after cardiopulmonary bypass: Alternative treatment prospects
Zheng XM, Yang Z, Yang GL, Huang Y, Peng JR, Wu MJ

REVIEW

- 762 Acute myocardial injury in patients with COVID-19: Possible mechanisms and clinical implications
Rusu I, Turlacu M, Micheu MM

MINIREVIEWS

- 777 Anemia in cirrhosis: An underestimated entity
Manrai M, Dawra S, Kapoor R, Srivastava S, Singh A

ORIGINAL ARTICLE

Retrospective Cohort Study

- 790 High tumor mutation burden indicates a poor prognosis in patients with intrahepatic cholangiocarcinoma
Song JP, Liu XZ, Chen Q, Liu YF

Retrospective Study

- 802 Does delaying ureteral stent placement lead to higher rates of preoperative acute pyelonephritis during pregnancy?
He MM, Lin XT, Lei M, Xu XL, He ZH
- 811 Management of retroperitoneal sarcoma involving the iliac artery: Single-center surgical experience
Li WX, Tong HX, Lv CT, Yang H, Zhao G, Lu WQ, Zhang Y
- 820 COVID-19 pandemic changed the management and outcomes of acute appendicitis in northern Beijing: A single-center study
Zhang P, Zhang Q, Zhao HW
- 830 Laparoscopic approach for managing intussusception in children: Analysis of 65 cases
Li SM, Wu XY, Luo CF, Yu LJ
- 840 Clinical features and risk factors of severely and critically ill patients with COVID-19
Chu X, Zhang GF, Zheng YK, Zhong YG, Wen L, Zeng P, Fu CY, Tong XL, Long YF, Li J, Liu YL, Chang ZG, Xi H
- 856 Evaluating tumor-infiltrating lymphocytes in hepatocellular carcinoma using hematoxylin and eosin-stained tumor sections
Du M, Cai YM, Yin YL, Xiao L, Ji Y

Clinical Trials Study

- 870 Role of carbon nanotracers in lymph node dissection of advanced gastric cancer and the selection of preoperative labeling time
Zhao K, Shan BQ, Gao YP, Xu JY

Observational Study

- 882 Craving variations in patients with substance use disorder and gambling during COVID-19 lockdown: The Italian experience
Alessi MC, Martinotti G, De Berardis D, Sociali A, Di Natale C, Sepede G, Cheffo DPR, Monti L, Casella P, Pettorruso M, Sensi S, Di Giannantonio M
- 891 Mesh safety in pelvic surgery: Our experience and outcome of biological mesh used in laparoscopic ventral mesh rectopexy
Tsiaousidou A, MacDonald L, Shalli K
- 899 Dynamic monitoring of carcinoembryonic antigen, CA19-9 and inflammation-based indices in patients with advanced colorectal cancer undergoing chemotherapy
Manojlovic N, Savic G, Nikolic B, Rancic N
- 919 Prevalence of depression and anxiety and associated factors among geriatric orthopedic trauma inpatients: A cross-sectional study
Chen JL, Luo R, Liu M

Randomized Controlled Trial

- 929 Efficacy of acupuncture at ghost points combined with fluoxetine in treating depression: A randomized study
Wang Y, Huang YW, Ablikim D, Lu Q, Zhang AJ, Dong YQ, Zeng FC, Xu JH, Wang W, Hu ZH

SYSTEMATIC REVIEWS

- 939 Atrial fibrillation burden and the risk of stroke: A systematic review and dose-response meta-analysis
Yang SY, Huang M, Wang AL, Ge G, Ma M, Zhi H, Wang LN

META-ANALYSIS

- 954 Effectiveness of Maitland and Mulligan mobilization methods for adults with knee osteoarthritis: A systematic review and meta-analysis
Li LL, Hu XJ, Di YH, Jiao W
- 966 Patients with inflammatory bowel disease and post-inflammatory polyps have an increased risk of colorectal neoplasia: A meta-analysis
Shi JL, Lv YH, Huang J, Huang X, Liu Y

CASE REPORT

- 985 Intravascular fasciitis involving the external jugular vein and subclavian vein: A case report
Meng XH, Liu YC, Xie LS, Huang CP, Xie XP, Fang X

- 992** Occurrence of human leukocyte antigen B51-related ankylosing spondylitis in a family: Two case reports
Lim MJ, Noh E, Lee RW, Jung KH, Park W
- 1000** Multicentric recurrence of intraductal papillary neoplasm of bile duct after spontaneous detachment of primary tumor: A case report
Fukuya H, Kuwano A, Nagasawa S, Morita Y, Tanaka K, Yada M, Masumoto A, Motomura K
- 1008** Case of primary extracranial meningioma of the maxillary sinus presenting as buccal swelling associated with headache: A case report
Sigdel K, Ding ZF, Xie HX
- 1016** Pulmonary amyloidosis and multiple myeloma mimicking lymphoma in a patient with Sjogren's syndrome: A case report
Kim J, Kim YS, Lee HJ, Park SG
- 1024** Concomitant Othello syndrome and impulse control disorders in a patient with Parkinson's disease: A case report
Xu T, Li ZS, Fang W, Cao LX, Zhao GH
- 1032** Multiple endocrine neoplasia type 1 combined with thyroid neoplasm: A case report and review of literatures
Xu JL, Dong S, Sun LL, Zhu JX, Liu J
- 1041** Full recovery from chronic headache and hypopituitarism caused by lymphocytic hypophysitis: A case report
Yang MG, Cai HQ, Wang SS, Liu L, Wang CM
- 1050** Novel method of primary endoscopic realignment for high-grade posterior urethral injuries: A case report
Ho CJ, Yang MH
- 1056** Congenital muscular dystrophy caused by *beta1,3-N-acetylgalactosaminyltransferase 2* gene mutation: Two case reports
Wu WJ, Sun SZ, Li BG
- 1067** Novel α -galactosidase A gene mutation in a Chinese Fabry disease family: A case report
Fu AY, Jin QZ, Sun YX
- 1077** Cervical spondylotic myelopathy with syringomyelia presenting as hip Charcot neuroarthropathy: A case report and review of literature
Lu Y, Xiang JY, Shi CY, Li JB, Gu HC, Liu C, Ye GY
- 1086** Bullectomy used to treat a patient with pulmonary vesicles related to COVID-19: A case report
Tang HX, Zhang L, Wei YH, Li CS, Hu B, Zhao JP, Mokadam NA, Zhu H, Lin J, Tian SF, Zhou XF
- 1093** Epibulbar osseous choristoma: Two case reports
Wang YC, Wang ZZ, You DB, Wang W
- 1099** Gastric submucosal lesion caused by an embedded fish bone: A case report
Li J, Wang QQ, Xue S, Zhang YY, Xu QY, Zhang XH, Feng L

- 1106** Metastasis to the thyroid gland from primary breast cancer presenting as diffuse goiter: A case report and review of literature
Wen W, Jiang H, Wen HY, Peng YL
- 1116** New method to remove tibial intramedullary nail through original suprapatellar incision: A case report
He M, Li J
- 1122** Recurrence of sigmoid colon cancer-derived anal metastasis: A case report and review of literature
Meng LK, Zhu D, Zhang Y, Fang Y, Liu WZ, Zhang XQ, Zhu Y
- 1131** *Mycoplasma hominis* meningitis after operative neurosurgery: A case report and review of literature
Yang NL, Cai X, Que Q, Zhao H, Zhang KL, Lv S

ABOUT COVER

Editorial Board Member of *World Journal of Clinical Cases*, M Anwar Iqbal, PhD, Professor, Department of Pathology and Laboratory Medicine, University of Rochester Medical Center, Rochester, NY 14642, United States. anwar_iqbal@urmc.rochester.edu

AIMS AND SCOPE

The primary aim of *World Journal of Clinical Cases* (WJCC, *World J Clin Cases*) is to provide scholars and readers from various fields of clinical medicine with a platform to publish high-quality clinical research articles and communicate their research findings online.

WJCC mainly publishes articles reporting research results and findings obtained in the field of clinical medicine and covering a wide range of topics, including case control studies, retrospective cohort studies, retrospective studies, clinical trials studies, observational studies, prospective studies, randomized controlled trials, randomized clinical trials, systematic reviews, meta-analysis, and case reports.

INDEXING/ABSTRACTING

The WJCC is now indexed in Science Citation Index Expanded (also known as SciSearch®), Journal Citation Reports/Science Edition, Scopus, PubMed, and PubMed Central. The 2021 Edition of Journal Citation Reports® cites the 2020 impact factor (IF) for WJCC as 1.337; IF without journal self cites: 1.301; 5-year IF: 1.742; Journal Citation Indicator: 0.33; Ranking: 119 among 169 journals in medicine, general and internal; and Quartile category: Q3. The WJCC's CiteScore for 2020 is 0.8 and Scopus CiteScore rank 2020: General Medicine is 493/793.

RESPONSIBLE EDITORS FOR THIS ISSUE

Production Editor: *Ying-Yi Yuan*, Production Department Director: *Xiang Li*, Editorial Office Director: *Jin-Lei Wang*.

NAME OF JOURNAL

World Journal of Clinical Cases

ISSN

ISSN 2307-8960 (online)

LAUNCH DATE

April 16, 2013

FREQUENCY

Thrice Monthly

EDITORS-IN-CHIEF

Bao-Gan Peng, Jerzy Tadeusz Chudek, George Kontogeorgos, Maurizio Serati, Ja Hyeon Ku

EDITORIAL BOARD MEMBERS

<https://www.wjgnet.com/2307-8960/editorialboard.htm>

PUBLICATION DATE

January 21, 2022

COPYRIGHT

© 2022 Baishideng Publishing Group Inc

INSTRUCTIONS TO AUTHORS

<https://www.wjgnet.com/bpg/gerinfo/204>

GUIDELINES FOR ETHICS DOCUMENTS

<https://www.wjgnet.com/bpg/GerInfo/287>

GUIDELINES FOR NON-NATIVE SPEAKERS OF ENGLISH

<https://www.wjgnet.com/bpg/gerinfo/240>

PUBLICATION ETHICS

<https://www.wjgnet.com/bpg/GerInfo/288>

PUBLICATION MISCONDUCT

<https://www.wjgnet.com/bpg/gerinfo/208>

ARTICLE PROCESSING CHARGE

<https://www.wjgnet.com/bpg/gerinfo/242>

STEPS FOR SUBMITTING MANUSCRIPTS

<https://www.wjgnet.com/bpg/GerInfo/239>

ONLINE SUBMISSION

<https://www.f6publishing.com>

Cervical spondylotic myelopathy with syringomyelia presenting as hip Charcot neuroarthropathy: A case report and review of literature

Yu Lu, Jun-Yi Xiang, Cheng-Yu Shi, Ju-Bao Li, Hai-Chao Gu, Chang Liu, Guo-Yu Ye

ORCID number: Yu Lu 0000-0002-3741-5643; Jun-Yi Xiang 0000-0002-1342-5708; Cheng-Yu Shi 0000-0002-6940-6258; Ju-Bao Li 0000-0003-2295-1184; Hai-Chao Gu 0000-0001-5788-081X; Chang Liu 0000-0002-1729-563X; Guo-Yu Ye 0000-0003-1553-7233.

Author contributions: Lu Y and Ye GY were the patient's orthopedist, reviewed the literature and contributed to manuscript drafting; Shi CY reviewed the literature and contributed to manuscript drafting; Xiang JY, Li JB, and Gu HC analyzed and interpreted the imaging findings; Liu C performed the psychiatric analyses and interpretation and contributed to manuscript drafting; Lu Y and Ye GY were responsible for the revision of the manuscript for important intellectual content; all authors issued final approval for the version to be submitted.

Informed consent statement:

Informed written consent was obtained from the patient for publication of this report and any accompanying images.

Conflict-of-interest statement: The authors declare that they have no conflict of interest.

CARE Checklist (2016) statement:

The authors have read the CARE Checklist (2016), and the

Yu Lu, Jun-Yi Xiang, Ju-Bao Li, Hai-Chao Gu, Guo-Yu Ye, Department of Orthopedics, Yunnan Provincial Hospital of Traditional Chinese Medicine, Kunming 650000, Yunnan Province, China

Cheng-Yu Shi, Department of Management and Economics, Kunming University of Science and Technology, Kunming 650000, Yunnan Province, China

Chang Liu, Department of Sleep Center, The First People's Hospital of Yunnan Province, Kunming 650000, Yunnan Province, China

Corresponding author: Guo-Yu Ye, MM, Attending Doctor, Department of Orthopedics, Yunnan Provincial Hospital of Traditional Chinese Medicine, No. 120 Guanghua Street, Kunming 650000, Yunnan Province, China. yeguoyumed@163.com

Abstract

BACKGROUND

Charcot neuroarthropathy (CN) is a systemic disease characterized by progressive bone loss and destruction, which is usually closely related to diabetes, HIV, *etc.* However, CN caused by syringomyelia accounts for only 5% of CN cases; the shoulder and elbow are most often involved, and the hip joint is rarely affected. As a rare factor, cervical spondylotic myelopathy (CSM) can be associated with syringomyelia, which is scarcely reported in the literature. Here, we present the first case report to date of CN of the hip caused by syringomyelia secondary to CSM.

CASE SUMMARY

We describe a 76-year-old male patient who was diagnosed with CSM due to neck pain and weakness of limbs 16 years ago. Four years ago, he noticed recurrent swelling of the right hip with pain and was diagnosed with degenerative arthritis. Recently, however, his symptoms gradually worsened, and because of progressive pain, destabilization and weakness of the right hip, he was admitted to our hospital. Through systematic physical, radiographic and laboratory examinations, we finally reached a diagnosis: CN of the right hip associated with syringomyelia secondary to CSM. After comprehensive evaluation of the patient's condition, we performed right total hip arthroplasty. During the follow-up, the patient felt well clinically and could walk independently with a knee brace.

CONCLUSION

We suggest a possible etiological association between CSM and syringomyelia,

manuscript was prepared and revised according to the CARE Checklist (2016).

Country/Territory of origin: China

Specialty type: Orthopedics

Provenance and peer review:

Unsolicited article; Externally peer reviewed.

Peer-review model: Single blind

Peer-review report's scientific quality classification

Grade A (Excellent): 0

Grade B (Very good): B, B

Grade C (Good): 0

Grade D (Fair): 0

Grade E (Poor): 0

Open-Access: This article is an open-access article that was selected by an in-house editor and fully peer-reviewed by external reviewers. It is distributed in accordance with the Creative Commons Attribution NonCommercial (CC BY-NC 4.0) license, which permits others to distribute, remix, adapt, build upon this work non-commercially, and license their derivative works on different terms, provided the original work is properly cited and the use is non-commercial. See: <http://creativecommons.org/licenses/by-nc/4.0/>

Received: June 29, 2021

Peer-review started: June 29, 2021

First decision: September 1, 2021

Revised: September 8, 2021

Accepted: December 22, 2021

Article in press: December 22, 2021

Published online: January 21, 2022

P-Reviewer: Oommen AT

S-Editor: Yan JP

L-Editor: A

P-Editor: Yan JP



which may reflect a potential pathogenesis of CN. We encourage clinicians to actively carry out a detailed medical history and comprehensive physical and imaging examinations in patients with joint lesions, especially chronic shoulder neck pain, to rule out the possibility of this association, which plays a crucial role in the early diagnosis of CN. Arthroplasty may no longer be an absolute contraindication to surgical treatment of CN. Reasonable selection of the surgical strategy can markedly improve the clinical symptoms and quality of life of patients.

Key Words: Cervical spondylotic myelopathy; Syringomyelia; Hip; Charcot neuroarthropathy; Case report

©The Author(s) 2022. Published by Baishideng Publishing Group Inc. All rights reserved.

Core Tip: We report an unprecedented case of Charcot neuroarthropathy (CN) of the right hip associated with syringomyelia secondary to cervical spondylotic myelopathy (CSM). After comprehensive evaluation of the patient's condition, we performed right total hip arthroplasty. During the follow-up, the patient felt well clinically and could walk independently with a knee brace. We suggest a potential etiological association between CN and CSM complicated by syringomyelia, which reminds clinicians to actively carry out comprehensive physical and imaging examinations in patients with joint lesions, especially chronic shoulder neck pain, to rule out the possibility of this association. Detailed medical history acquisition and comprehensive examination play a crucial role in the early diagnosis of CN. Arthroplasty may no longer be an absolute contraindication to surgical treatment of CN. Reasonable selection of the surgical strategy can markedly improve the clinical symptoms and quality of life of patients.

Citation: Lu Y, Xiang JY, Shi CY, Li JB, Gu HC, Liu C, Ye GY. Cervical spondylotic myelopathy with syringomyelia presenting as hip Charcot neuroarthropathy: A case report and review of literature. *World J Clin Cases* 2022; 10(3): 1077-1085

URL: <https://www.wjgnet.com/2307-8960/full/v10/i3/1077.htm>

DOI: <https://dx.doi.org/10.12998/wjcc.v10.i3.1077>

INTRODUCTION

Charcot neuroarthropathy (CN), or Charcot joint, is a systemic disease characterized by progressive bone loss and destruction of the joints and/or spine usually accompanied by dysfunctions of sensitive and autonomic nerves and is reported to be closely associated with diabetes mellitus, HIV, chronic alcoholism, end-stage renal disease, gigantism, intra-articular steroid injections, peripheral neuropathy, meningocele, multiple sclerosis, myelodysplasia, leprosy, amyloidosis, and congenital pain insensitivity[1-3]. However, CN caused by syringomyelia accounts for approximately 5% of CN cases[4]. A retrospective study showed that syringomyelia-associated CN most often involves the shoulder (17 of 33, 50.0%) and elbow (17 of 33, 50.0%), while the hip joint is rarely involved (1 of 33, 2.94%)[5]. To date, a few cases of CN associated with syringomyelia have been reported, but a case report of CN of the hip caused by syringomyelia secondary to cervical spondylotic myelopathy (CSM) has never been published. Therefore, the purpose of this report is to discuss this rare pathological association and to provide new insights into the surgical treatment of CN.

CASE PRESENTATION

Chief complaints

A 76-year-old male patient presented to the Department of Orthopedics of our hospital complaining of worsening progressive right hip pain, a limp when walking and weakness of the right hip. He was admitted to our hospital.

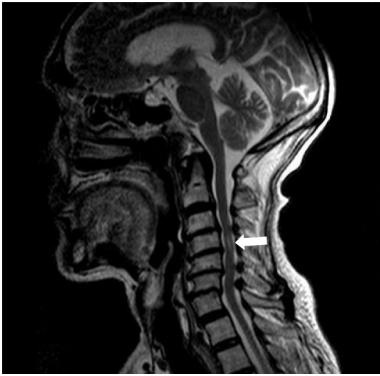


Figure 1 Magnetic resonance imaging of the cervical spine. Cervical syringomyelia at C4 (white arrow); cervical disc herniation and spinal stenosis from the C3 to C7 Levels.

History of present illness

The patient's symptoms started four years ago with recurrent swelling of the right hip with mild pain, which had worsened in the last 48 h.

History of past illness

The patient initially presented with neck pain and weakness in all four limbs 16 years ago and was diagnosed with cervical spondylosis, which was treated conservatively.

Personal and family history

The patient had an unremarkable personal and family history.

Physical examination

The patient reported mild pain with flexion and extension of the cervical spine and activity limitation. Apparent swelling was observed in the left hip, and more than 110 mL of clear yellowish joint fluid was extracted. The active range of motion of the right hip was recorded as follows: flexion 90°, abduction 30°, internal rotation 20°, and external rotation 35°, with pain in all directions. The visual analog score was 6/10 points, and the Harris hip score (HHS) was 56 points. Neurologically, the sensation of pain and temperature in the upper and lower extremities was decreased, and proprioception and position sensation were normal. A pathologic reflex was not elicited. Both upper limbs and the right lower limb exhibited weakness with a muscle strength of 4/5, the muscle strength of the left lower limb was normal at 5/5, the right abductor had a muscle strength score of 5/5, and the modified Japanese Orthopedic Association score for CSM was 9/17 points. The bone mineral density (BMD) of the hip was 0.45 g/cm², and the T score was -2.9. Laboratory results were nonspecific.

Laboratory examinations

Blood biochemistry and urine analyses were normal. Electrocardiogram, chest X-ray and arterial blood gases were also normal. The BMD of the hip was 0.45 g/cm², and the T score was -2.9.

Imaging examinations

Magnetic resonance imaging (MRI) of the cervical spine showed cervical syringomyelia at C4, cervical disc herniation and spinal canal stenosis from the C3 to the C7 levels (Figure 1). Cervical computed tomography (CT) revealed destruction of the vertebral body at C4 and C5–7 vertebral body assimilation (Figure 2). Three-dimensional CT reconstruction, CT scans, and X-rays of the right hip joint showed joint space loss, articular surface collapse, and destructive changes in the acetabulum and femoral head (Figure 3A-C). T2W1 MRI of the right hip showed articular cartilage loss, degeneration of the joint, disordered soft tissue, and apparent joint fluid (Figure 3D).

FINAL DIAGNOSIS

The final diagnosis was CN of the hip associated with syringomyelia and CSM.

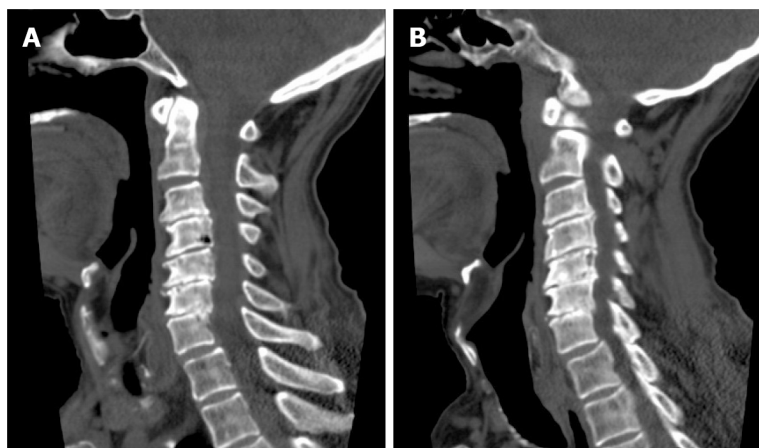


Figure 2 Computed tomography of the cervical spine. A: C4 vertebral body destruction; B: C5-7 vertebral body assimilation.

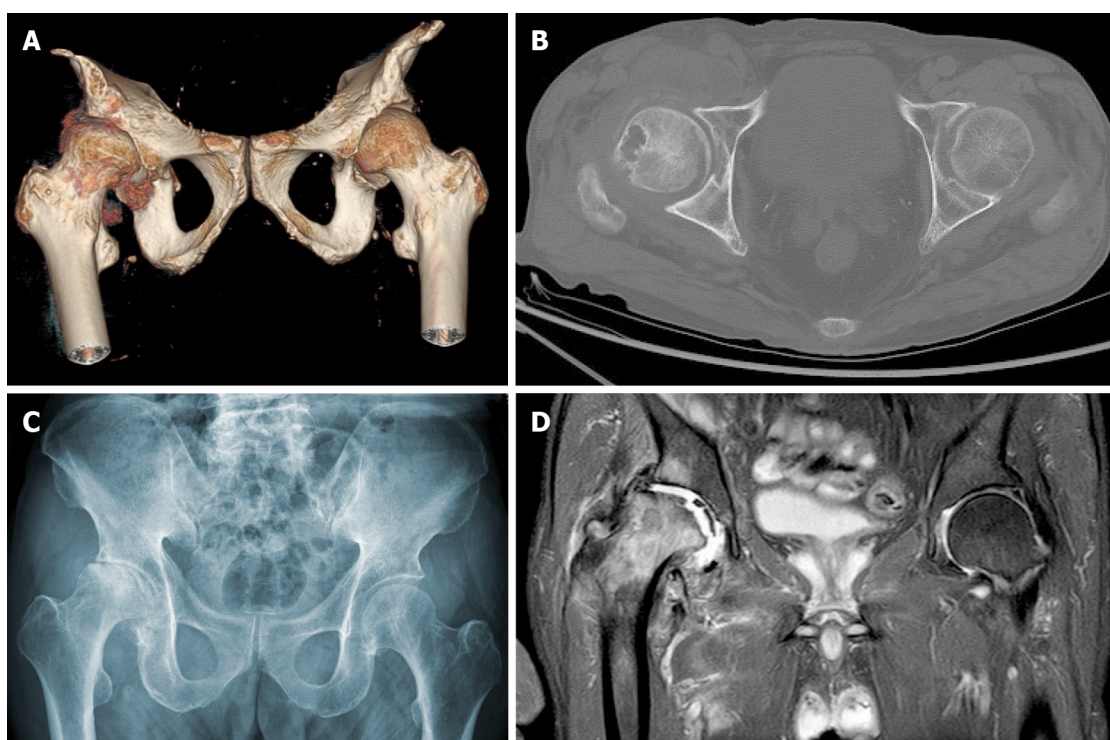


Figure 3 Right hip joint. A: Computed tomography (CT) three-dimensional reconstruction; B: CT; C: X-ray. Joint space loss, articular surface collapse, and destructive acetabulum and femoral head changes; D: Right hip magnetic resonance imaging, T2W1. Articular cartilage loss, joint degeneration, soft tissue disorder, and obvious joint fluid were observed.

TREATMENT

We performed total hip arthroplasty (THA) on the right hip (Figure 4) with a cement-type Lubinus anti-dislocation acetabular cup, D = 50 mm (Walde mar Link, Germany). We conducted pathological examinations on specimens of the right femoral head and synovial tissue collected intraoperatively. Tissue degeneration, calcification, small vascular proliferation and a multicore giant cell response were observed in some regions of femoral head tissue sections, and capillary hyperplasia with acute and chronic inflammatory cell infiltration, local tissue denaturation, and calcification were observed in synovial tissue sections (Figure 5). The pathologist considered that the pathological changes were consistent with CN.

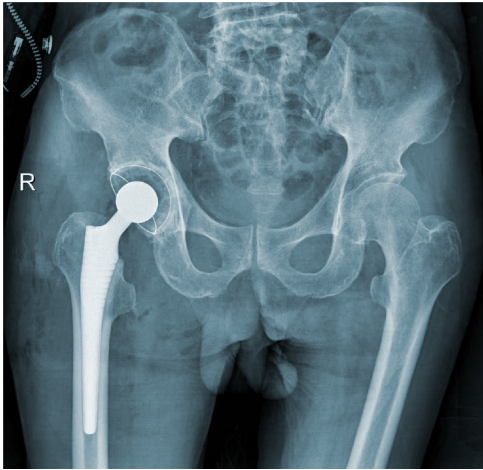


Figure 4 Right hip X-ray film after total hip arthroplasty.

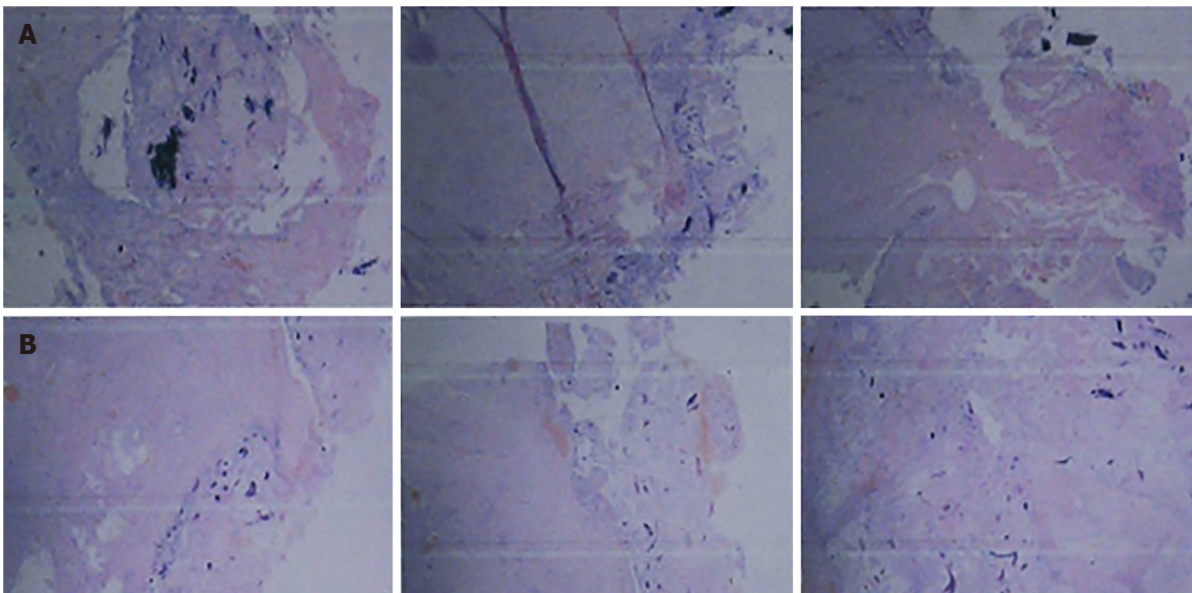


Figure 5 Pathological results. A: Right femoral head tissue sections during surgery. Tissue degeneration, calcification, small vascular proliferation and a multicore giant cell response in some regions; B: Synovial tissue sections of the right hip joint during the operation. Capillary hyperplasia was accompanied by infiltration of acute chronic inflammatory cells, local region tissue denaturation and calcification.

OUTCOME AND FOLLOW-UP

At the 6-mo follow-up, the patient felt clinically well, with no pain, joint fluid collection, or hip dislocation, and could walk independently with a knee brace. The right lower limb had a muscle strength score of 4/5, and the HHS score was 84 points. The 6-mo follow-up X-rays revealed that the acetabular inclination and anteversion were well maintained, without clinical manifestations of implant loosening compared with postoperative observations (Figure 6).

DISCUSSION

CN is considered a multifactorial disease that may lead to progressive bone resorption and destruction of the joints and further develop into joint instability, deformity, and structural collapse with or without pain[6,7]. The possible pathogenesis includes the following: (1) Inflammatory cascading reactions caused by excessive expression of proinflammatory cytokines lead to an increase in osteoclastogenesis; (2) Abnormal neurovascular reflexes at joints promote osteoclast activation, leading to osteopenia;

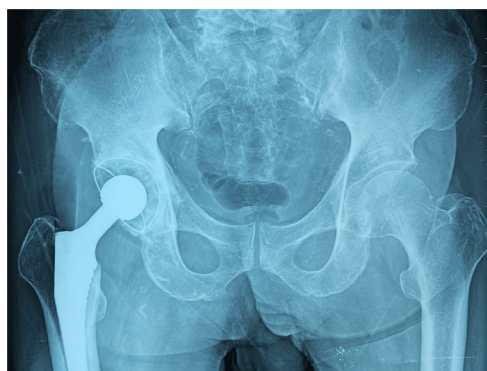

Figure 6 Follow-up right hip X-ray film 6 mo after total hip arthroplasty. X-rays revealed that the acetabular inclination and anteversion were well maintained and showed signs of periprosthetic bone growth without clinical manifestations of implant loosening compared with postoperative observations.

and (3) Painful sensory neuropathy and local temperature increases lead to the accumulation of microtrauma, resulting in joint dislocation and collapse[8,9]. Diabetes is considered the most common cause of CN and usually affects the foot and ankle joints[10]. However, syringomyelia-associated CN accounts for only approximately 5% of CN cases and easily causes upper limb CN[4,11], which most frequently involves the shoulder and elbow joints[3,12]. Only a few studies have reported that CN of the hip and knee joint is a rare complication of lumbar syringomyelia caused by epidural anesthesia[13,14].

Syringomyelia is a chronic progressive condition in which cystic tubular cavitation of the spinal cord is commonly caused by disorders of normal cerebrospinal fluid (CSF) flow dynamics. The possible mechanisms of syringomyelia include: (1) CSF transfer from the fourth ventricle to the central canal[15,16]; and (2) CSF filtration through medullary channels through perivascular and interstitial metastasis[17]. While the etiology of syringomyelia is not completely understood, Chiari 1 malformation is generally considered the most significant etiology. Other possible causes include Chiari 2 malformation, myelomeningocele, tethered cord syndrome, hydrocephalus, infection, inflammatory conditions, trauma, extramedullary tumors, arachnoid cysts and spinal canal stenosis[18,19]. As a rare factor, CSM associated with syringomyelia is scarcely reported in the literature[20]. Four potential pathologic mechanisms have been considered for cervical syringomyelia secondary to CSM: Ischemia causing degeneration, microtrauma caused by persistent oppression, hydrodynamic changes in CSF, and the dynamic pincer effect[21]. In addition, enhanced blood flow signals in compressed segments of the cervical spinal cord suggest that dyskinesia of CSF movement may play a role in the process of lesion development[22,23]. The typical clinical manifestation of syringomyelia is weakening or loss of pain and temperature sensation, but proprioception and position sensation are maintained, which is known as "free anesthesia", with muscular atrophy and undernourishment at the level of lesions. With loss of the normal protective reflex, joints may suffer from unrecognized trauma or repeated injury, eventually leading to the occurrence of CN.

In this case, the patient had no significant previous medical history except for CSM diagnosed 16 years prior. According to the MRI results, we found that the patient had CSM and cervical syringomyelia at C4, without other special lesions. Therefore, we suspected that cervical syringomyelia at C4 was associated with long-term CSM, although this is an extremely rare pathological association. Meanwhile, a typical X-ray showed severe hip deterioration, bone loss, and destruction. Interestingly, we carried out systemic physical, laboratory and imaging examinations on the patient, which confirmed that the patient's blood glucose and laboratory results were normal, indicating no other systemic diseases. Therefore, we excluded the differential diagnoses of congenital pain insensitivity, infection and inflammatory joint disease. Finally, after discussion with neurologists and radiologists, the patient was diagnosed with CN of the right hip caused by cervical syringomyelia secondary to CSM.

Early CN is difficult to distinguish from other diseases due to a lack of characteristic clinical manifestations, typical X-ray findings, laboratory tests, and severe underlying neurological disease that can facilitate clinical diagnosis. The management goal for CN patients is early diagnosis and intervention to maintain joint and limb function and active treatment of primary underlying diseases. The surgical strategy for CN of the hip remains controversial.

In the past, THA was considered a contraindication in the absence of complete remission of the primary disease[24,25]. However, a recent study suggested that the clinical prognosis of patients undergoing primary THA for CN was significantly improved, including pain relief, mobility recovery, and joint stability enhancement. Notably, a higher risk of early complications, such as recurrent dislocation, femoral body loosening and periprosthetic fracture, is evident due to the loss of protective sensations and reflexes, osteopenia, and ligament and muscle weakness[26,27]. According to the study of Parvizi *et al*[28], in the largest series of TKA (non-THA) treatment for CN, the survival rate without mechanical failure within 8 years was 82.5%, the aseptic loosening rate was 5.3%, and the instability rate was 2.6%.

Therefore, adopting reasonable precautions to provide a fixed prosthesis and increase the stability of the hip joint is particularly important to avoid early complications, including: (1) The use of a larger diameter femoral head to reduce the risk of postoperative dislocation; (2) The use of a highly cross-linked polyethylene lining to reduce wear; (3) The use of 3D CT template software to produce femoral stems with appropriate anteversion and femoral offset; (4) The use of a CT navigation system to reproduce the preoperative plan as much as possible; (5) Judicious use of dual mobility constructs; and (6) Revision of the acetabular component and the use of multiple acetabular screws to enhance the firmness of the component[26,29,30]. In addition, we should adhere to conservative treatments during the perioperative period, such as weight-bearing, immobilization, passive stretching, physical therapy and nonsteroidal anti-inflammatory drugs[5].

In our case, the patient refused to undergo cervical decompression surgery. To relieve the pain in the hip joint and restore the motor function of the limbs, we performed right THA. In the preoperative evaluation, the patient suffered from osteoporosis and bone fragmentation and loss around the hip. We suspect that the mass and strength of bone around the hip joint cannot provide sufficient stability at the bone-implant interface if a biotype acetabular cup is adopted. Moreover, the cement-type prosthesis possesses a short curing time, and strong fixation is achieved immediately after curing. Two to three days postoperatively, the patient can begin to bear partial weight with support, which reduces perioperative complications. During the operation, to reduce the risk of dislocation, we used the Hardinge approach to preserve the external rotator muscle group, which can reduce hip joint stability impairment with close suturing of the joint tendon. The cement-type Lubinus anti-dislocation acetabular cup and a biological fully coated biconical femoral stem were used to improve stability and promote bone ingrowth. After surgery, the patient's symptoms improved, without complications such as recurrent dislocation, loosening of the femoral prosthesis, and fracture around the prosthesis.

CONCLUSION

We suggest a possible etiological association between CSM and syringomyelia, which may reflect a potential pathogenesis of CN. A differential diagnosis should be established for patients with joint swelling, pain and limited mobility, especially patients with chronic shoulder and neck pain. Imaging examinations should be actively performed to rule out the possibility of syringomyelia secondary to CSM. Therefore, the key to successful treatment of patients with CN is comprehensive medical history acquisition, examination and early diagnosis. In addition, arthroplasty may no longer be an absolute contraindication to surgical treatment of CN. Reasonable selection of the surgical strategy can markedly improve the clinical symptoms and quality of life of patients.

ACKNOWLEDGEMENTS

We thank the staff at the Department of Radiology and the Department of Pathology in Yunnan Provincial Hospital of Traditional Chinese Medicine.

REFERENCES

- 1 Johnson JT. Neuropathic fractures and joint injuries. Pathogenesis and rationale of prevention and treatment. *J Bone Joint Surg Am* 1967; 49: 1-30 [PMID: 4163089 DOI: 10.1097/00006123-196704000000010]

- 10.2106/00004623-196749010-00001]
- 2 **Wukich DK**, Sung W. Charcot arthropathy of the foot and ankle: modern concepts and management review. *J Diabetes Complications* 2009; **23**: 409-426 [PMID: [18930414](#) DOI: [10.1016/j.jdiacomp.2008.09.004](#)]
- 3 **Alpert SW**, Koval KJ, Zuckerman JD. Neuropathic Arthropathy: Review of Current Knowledge. *J Am Acad Orthop Surg* 1996; **4**: 100-108 [PMID: [10795044](#) DOI: [10.5435/00124635-199603000-00005](#)]
- 4 **Sahoo SK**, Salunke P. Charcot arthropathy of the elbow joint as a presenting feature of Chiari malformation with syringomyelia. *Br J Neurosurg* 2014; **28**: 811-812 [PMID: [25076017](#) DOI: [10.3109/02688697.2014.944482](#)]
- 5 **Wang X**, Li Y, Gao J, Wang T, Li Z. Charcot arthropathy of the shoulder joint as a presenting feature of basilar impression with syringomyelia: A case report and literature review. *Medicine (Baltimore)* 2018; **97**: e11391 [PMID: [29995782](#) DOI: [10.1097/MD.00000000000011391](#)]
- 6 **Anders LF**. Charcot neuroarthropathy of the foot. In: Bowker J, Pfeifer M, editors. The diabetic foot. 6th edition. St. Louis: Mosby, 2001: 439-466
- 7 **Chantelau E**, Richter A, Ghassem-Zadeh N, Poll LW. "Silent" bone stress injuries in the feet of diabetic patients with polyneuropathy: a report on 12 cases. *Arch Orthop Trauma Surg* 2007; **127**: 171-177 [PMID: [17216478](#) DOI: [10.1007/s00402-006-0271-x](#)]
- 8 **Chisholm KA**, Gilchrist JM. The Charcot joint: a modern neurologic perspective. *J Clin Neuromuscul Dis* 2011; **13**: 1-13 [PMID: [22361621](#) DOI: [10.1097/CND.0b013e3181c6f55b](#)]
- 9 **Rajbhandari SM**, Jenkins RC, Davies C, Tesfaye S. Charcot neuroarthropathy in diabetes mellitus. *Diabetologia* 2002; **45**: 1085-1096 [PMID: [12189438](#) DOI: [10.1007/s00125-002-0885-7](#)]
- 10 **Deng X**, Wu L, Yang C, Xu Y. Neuropathic arthropathy caused by syringomyelia. *J Neurosurg Spine* 2013; **18**: 303-309 [PMID: [23289508](#) DOI: [10.3171/2012.11.SPINE12860](#)]
- 11 **Williams B**. Orthopaedic features in the presentation of syringomyelia. *J Bone Joint Surg Br* 1979; **61-B**: 314-323 [PMID: [158024](#) DOI: [10.1302/0301-620X.61B3.158024](#)]
- 12 **Kenan S**, Lewis MM, Main WK, Hermann G, Abdelwahab IF. Neuropathic arthropathy of the shoulder mimicking soft tissue sarcoma. *Orthopedics* 1993; **16**: 1133-1136 [PMID: [8255808](#) DOI: [10.3928/0147-7447-19931001-09](#)]
- 13 **Paliwal VK**, Singh P, Rahi SK, Agarwal V, Gupta RK. Charcot knee secondary to lumbar spinal cord syringomyelia: complication of spinal anesthesia. *J Clin Rheumatol* 2012; **18**: 207-208 [PMID: [22647866](#) DOI: [10.1097/RHU.0b013e3182598915](#)]
- 14 **Memarpour R**, Tashtoush B, Issac L, Gonzalez-Ibarra F. Syringomyelia with Chiari I malformation presenting as hip charcot arthropathy: a case report and literature review. *Case Rep Neurol Med* 2015; **2015**: 487931 [PMID: [25692057](#) DOI: [10.1155/2015/487931](#)]
- 15 **Gardner WJ**. Hydrodynamic mechanism of syringomyelia: its relationship to myelocoele. *J Neurol Neurosurg Psychiatry* 1965; **28**: 247-259 [PMID: [14345682](#) DOI: [10.1136/jnnp.28.3.247](#)]
- 16 **Williams B**, Terry AF, Jones F, McSweeney T. Syringomyelia as a sequel to traumatic paraplegia. *Paraplegia* 1981; **19**: 67-80 [PMID: [7220069](#) DOI: [10.1038/sc.1981.18](#)]
- 17 **Ball MJ**, Dayan AD. Pathogenesis of syringomyelia. *Lancet* 1972; **2**: 799-801 [PMID: [4116236](#) DOI: [10.1016/s0140-6736\(72\)92152-6](#)]
- 18 **Vandertop WP**. Syringomyelia. *Neuropediatrics* 2014; **45**: 3-9 [PMID: [24272770](#) DOI: [10.1055/s-0033-1361921](#)]
- 19 **Jones BV**. Cord Cystic Cavities: Syringomyelia and Prominent Central Canal. *Semin Ultrasound CT MR* 2017; **38**: 98-104 [PMID: [28347422](#) DOI: [10.1053/j.sult.2016.07.008](#)]
- 20 **Bhagavathula Venkata SS**, Arimappamagan A, Lafazan S, Pruthi N. Syringomyelia secondary to cervical spondylosis: Case report and review of literature. *J Neurosci Rural Pract* 2014; **5**: S78-S82 [PMID: [25540552](#) DOI: [10.4103/0976-3147.145215](#)]
- 21 **Chang HS**, Nejo T, Yoshida S, Oya S, Matsui T. Increased flow signal in compressed segments of the spinal cord in patients with cervical spondylotic myelopathy. *Spine (Phila Pa 1976)* 2014; **39**: 2136-2142 [PMID: [25271503](#) DOI: [10.1097/BRS.0000000000000607](#)]
- 22 **Baron EM**, Young WF. Cervical spondylotic myelopathy: a brief review of its pathophysiology, clinical course, and diagnosis. *Neurosurgery* 2007; **60**: S35-S41 [PMID: [17204884](#) DOI: [10.1227/01.NEU.0000215383.64386.82](#)]
- 23 **Fehlings MG**, Skaf G. A review of the pathophysiology of cervical spondylotic myelopathy with insights for potential novel mechanisms drawn from traumatic spinal cord injury. *Spine (Phila Pa 1976)* 1998; **23**: 2730-2737 [PMID: [9879098](#) DOI: [10.1097/00007632-199812150-00012](#)]
- 24 **Jostel A**, Jude EB. Medical treatment of Charcot neuroosteoarthropathy. *Clin Podiatr Med Surg* 2008; **25**: 63-69, vi [PMID: [18165112](#) DOI: [10.1016/j.cpm.2007.09.001](#)]
- 25 **Fullerton BD**, Browngohl LA. Total knee arthroplasty in a patient with bilateral Charcot knees. *Arch Phys Med Rehabil* 1997; **78**: 780-782 [PMID: [9228885](#) DOI: [10.1016/s0003-9993\(97\)90090-3](#)]
- 26 **Chalmers BP**, Tibbo ME, Trousdale RT, Lewallen DG, Berry DJ, Abdel MP. Primary Total Hip Arthroplasty for Charcot Arthropathy is Associated With High Complications but Improved Clinical Outcomes. *J Arthroplasty* 2018; **33**: 2912-2918 [PMID: [29706256](#) DOI: [10.1016/j.arth.2018.04.002](#)]
- 27 **Snoddy MC**, Lee DH, Kuhn JE. Charcot shoulder and elbow: a review of the literature and update on treatment. *J Shoulder Elbow Surg* 2017; **26**: 544-552 [PMID: [28111181](#) DOI: [10.1016/j.jse.2016.10.015](#)]
- 28 **Parvizi J**, Marrs J, Morrey BF. Total knee arthroplasty for neuropathic (Charcot) joints. *Clin Orthop Relat Res* 2003; **415**: 145-150 [PMID: [14646753](#) DOI: [10.1097/01.blo.0000081937.75404.ed](#)]

- 29 **Inoue D**, Kabata T, Maeda T, Kajino Y, Fujita K, Hasegawa K, Yamamoto T, Tsuchiya H. Value of computed tomography-based three-dimensional surgical preoperative planning software in total hip arthroplasty with developmental dysplasia of the hip. *J Orthop Sci* 2015; **20**: 340-346 [PMID: 25623254 DOI: 10.1007/s00776-014-0683-3]
- 30 **Kajino Y**, Kabata T, Maeda T, Iwai S, Kuroda K, Tsuchiya H. Does degree of the pelvic deformity affect the accuracy of computed tomography-based hip navigation? *J Arthroplasty* 2012; **27**: 1651-1657 [PMID: 22552221 DOI: 10.1016/j.arth.2012.03.009]



Published by **Baishideng Publishing Group Inc**
7041 Koll Center Parkway, Suite 160, Pleasanton, CA 94566, USA

Telephone: +1-925-3991568

E-mail: bpgoffice@wjgnet.com

Help Desk: <https://www.f6publishing.com/helpdesk>

<https://www.wjgnet.com>

