

World Journal of *Clinical Cases*

World J Clin Cases 2022 November 6; 10(31): 11214-11664



Contents

Thrice Monthly Volume 10 Number 31 November 6, 2022

REVIEW

- 11214** Diabetes and skin cancers: Risk factors, molecular mechanisms and impact on prognosis
Dobrică EC, Banciu ML, Kipkorir V, Khazeei Tabari MA, Cox MJ, Simhachalam Kutikuppala LV, Găman MA
- 11226** Endocrine disruptor chemicals as obesogen and diabetogen: Clinical and mechanistic evidence
Kurşunoğlu NE, Sarer Yurekli BP
- 11240** Intestinal microbiota in the treatment of metabolically associated fatty liver disease
Wang JS, Liu JC

MINIREVIEWS

- 11252** Lactation mastitis: Promising alternative indicators for early diagnosis
Huang Q, Zheng XM, Zhang ML, Ning P, Wu MJ
- 11260** Clinical challenges of glycemic control in the intensive care unit: A narrative review
Sreedharan R, Martini A, Das G, Aftab N, Khanna S, Ruetzler K
- 11273** Concise review on short bowel syndrome: Etiology, pathophysiology, and management
Lakkasani S, Seth D, Khokhar I, Touza M, Dacosta TJ
- 11283** Role of nickel-regulated small RNA in modulation of *Helicobacter pylori* virulence factors
Freire de Melo F, Marques HS, Fellipe Bueno Lemos F, Silva Luz M, Rocha Pinheiro SL, de Carvalho LS, Souza CL, Oliveira MV
- 11292** Surgical intervention for acute pancreatitis in the COVID-19 era
Su YJ, Chen TH

ORIGINAL ARTICLE

Clinical and Translational Research

- 11299** Screening of traditional Chinese medicine monomers as ribonucleotide reductase M2 inhibitors for tumor treatment
Qin YY, Feng S, Zhang XD, Peng B

Case Control Study

- 11313** Covered transjugular intrahepatic portosystemic stent-shunt *vs* large volume paracentesis in patients with cirrhosis: A real-world propensity score-matched study
Dhaliwal A, Merhzad H, Karkhanis S, Tripathi D

Retrospective Cohort Study

- 11325** Endoscopic submucosal tunnel dissection for early esophageal squamous cell carcinoma in patients with cirrhosis: A propensity score analysis
Zhu LL, Liu LX, Wu JC, Gan T, Yang JL

Retrospective Study

- 11338** Nomogram for predicting overall survival in Chinese triple-negative breast cancer patients after surgery
Lin WX, Xie YN, Chen YK, Cai JH, Zou J, Zheng JH, Liu YY, Li ZY, Chen YX
- 11349** Early patellar tendon rupture after total knee arthroplasty: A direct repair method
Li TJ, Sun JY, Du YQ, Shen JM, Zhang BH, Zhou YG
- 11358** Coxsackievirus A6 was the most common enterovirus serotype causing hand, foot, and mouth disease in Shiyang City, central China
Li JF, Zhang CJ, Li YW, Li C, Zhang SC, Wang SS, Jiang Y, Luo XB, Liao XJ, Wu SX, Lin L
- 11371** Dynamic changes of estimated glomerular filtration rate are conversely related to triglyceride in non-overweight patients
Liu SQ, Zhang XJ, Xue Y, Huang R, Wang J, Wu C, He YS, Pan YR, Liu LG
- 11381** C-reactive protein as a non-linear predictor of prolonged length of intensive care unit stay after gastrointestinal cancer surgery
Yan YM, Gao J, Jin PL, Lu JJ, Yu ZH, Hu Y

Clinical Trials Study

- 11391** Dan Bai Xiao Formula combined with glucocorticoids and cyclophosphamide for pediatric lupus nephritis: A pilot prospective study
Cao TT, Chen L, Zhen XF, Zhao GJ, Zhang HF, Hu Y

Observational Study

- 11403** Relationship between lipids and sleep apnea: Mendelian randomization analysis
Zhang LP, Zhang XX
- 11411** Efficacy and safety profile of two-dose SARS-CoV-2 vaccines in cancer patients: An observational study in China
Cai SW, Chen JY, Wan R, Pan DJ, Yang WL, Zhou RG

Prospective Study

- 11419** Pressure changes in tapered and cylindrical shaped cuff after extension of head and neck: A randomized controlled trial
Seol G, Jin J, Oh J, Byun SH, Jeon Y

Randomized Controlled Trial

- 11427** Effect of intradermal needle therapy at combined acupoints on patients' gastrointestinal function following surgery for gastrointestinal tumors
Guo M, Wang M, Chen LL, Wei FJ, Li JE, Lu QX, Zhang L, Yang HX

SYSTEMATIC REVIEWS

- 11442** Video-assisted bystander cardiopulmonary resuscitation improves the quality of chest compressions during simulated cardiac arrests: A systemic review and meta-analysis

Pan DF, Li ZJ, Ji XZ, Yang LT, Liang PF

META-ANALYSIS

- 11454** Efficacy of the femoral neck system in femoral neck fracture treatment in adults: A systematic review and meta-analysis

Wu ZF, Luo ZH, Hu LC, Luo YW

- 11466** Prevalence of polymyxin-induced nephrotoxicity and its predictors in critically ill adult patients: A meta-analysis

Wang JL, Xiang BX, Song XL, Que RM, Zuo XC, Xie YL

CASE REPORT

- 11486** Novel compound heterozygous variants in the LHX3 gene caused combined pituitary hormone deficiency: A case report

Lin SZ, Ma QJ, Pang QM, Chen QD, Wang WQ, Li JY, Zhang SL

- 11493** Fatal bleeding due to an aorto-esophageal fistula: A case report and literature review

Ćeranić D, Nikolić S, Lučev J, Slanić A, Bujas T, Ocepek A, Skok P

- 11500** Tolvaptan ameliorated kidney function for one elderly autosomal dominant polycystic kidney disease patient: A case report

Zhou L, Tian Y, Ma L, Li WG

- 11508** Extensive right coronary artery thrombosis in a patient with COVID-19: A case report

Dall'Orto CC, Lopes RPF, Cancela MT, de Sales Padilha C, Pinto Filho GV, da Silva MR

- 11517** Yokoyama procedure for a woman with heavy eye syndrome who underwent multiple recession-resection operations: A case report

Yao Z, Jiang WL, Yang X

- 11523** Rectal cancer combined with abdominal tuberculosis: A case report

Liu PG, Chen XF, Feng PF

- 11529** Malignant obstruction in the ileocecal region treated by self-expandable stent placement under the fluoroscopic guidance: A case report

Wu Y, Li X, Xiong F, Bao WD, Dai YZ, Yue LJ, Liu Y

- 11536** Granulocytic sarcoma with long spinal cord compression: A case report

Shao YD, Wang XH, Sun L, Cui XG

- 11542** Aortic dissection with epileptic seizure: A case report

Zheng B, Huang XQ, Chen Z, Wang J, Gu GF, Luo XJ

- 11549** Multiple bilateral and symmetric C1-2 ganglioneuromas: A case report
Wang S, Ma JX, Zheng L, Sun ST, Xiang LB, Chen Y
- 11555** Acute myocardial infarction due to Kounis syndrome: A case report
Xu GZ, Wang G
- 11561** Surgical excision of a large retroperitoneal lymphangioma: A case report
Park JH, Lee D, Maeng YH, Chang WB
- 11567** Mass-like extragonadal endometriosis associated malignant transformation in the pelvis: A rare case report
Chen P, Deng Y, Wang QQ, Xu HW
- 11574** Gastric ulcer treated using an elastic traction ring combined with clip: A case report
Pang F, Song YJ, Sikong YH, Zhang AJ, Zuo XL, Li RY
- 11579** Novel liver vein deprivation technique that promotes increased residual liver volume (with video): A case report
Wu G, Jiang JP, Cheng DH, Yang C, Liao DX, Liao YB, Lau WY, Zhang Y
- 11585** Linear porokeratosis of the foot with dermoscopic manifestations: A case report
Yang J, Du YQ, Fang XY, Li B, Xi ZQ, Feng WL
- 11590** Primary hepatic angiosarcoma: A case report
Wang J, Sun LT
- 11597** Hemorrhagic shock due to ruptured lower limb vascular malformation in a neurofibromatosis type 1 patient: A case report
Shen LP, Jin G, Zhu RT, Jiang HT
- 11607** Gastric linitis plastica with autoimmune pancreatitis diagnosed by an endoscopic ultrasonography-guided fine-needle biopsy: A case report
Sato R, Matsumoto K, Kanzaki H, Matsumi A, Miyamoto K, Morimoto K, Terasawa H, Fujii Y, Yamazaki T, Uchida D, Tsutsumi K, Horiguchi S, Kato H
- 11617** Favorable response of primary pulmonary lymphoepithelioma-like carcinoma to sintilimab combined with chemotherapy: A case report
Zeng SY, Yuan J, Lv M
- 11625** Benign paroxysmal positional vertigo with congenital nystagmus: A case report
Li GF, Wang YT, Lu XG, Liu M, Liu CB, Wang CH
- 11630** Secondary craniofacial necrotizing fasciitis from a distant septic emboli: A case report
Lee DW, Kwak SH, Choi HJ
- 11638** Pancreatic paraganglioma with multiple lymph node metastases found by spectral computed tomography: A case report and review of the literature
Li T, Yi RQ, Xie G, Wang DN, Ren YT, Li K

- 11646** Apnea caused by retrobulbar anesthesia: A case report
Wang YL, Lan GR, Zou X, Wang EQ, Dai RP, Chen YX
- 11652** Unexplained septic shock after colonoscopy with polyethylene glycol preparation in a young adult: A case report
Song JJ, Wu CJ, Dong YY, Ma C, Gu Q
- 11658** Metachronous isolated penile metastasis from sigmoid colon adenocarcinoma: A case report
Yin GL, Zhu JB, Fu CL, Ding RL, Zhang JM, Lin Q

ABOUT COVER

Editorial Board Member of *World Journal of Clinical Cases*, Muhammad Hamdan Gul, MD, Assistant Professor, Department of Internal Medicine, University of Kentucky, Chicago, IL 60657, United States.
hamdan3802@hotmail.com

AIMS AND SCOPE

The primary aim of *World Journal of Clinical Cases* (WJCC, *World J Clin Cases*) is to provide scholars and readers from various fields of clinical medicine with a platform to publish high-quality clinical research articles and communicate their research findings online.

WJCC mainly publishes articles reporting research results and findings obtained in the field of clinical medicine and covering a wide range of topics, including case control studies, retrospective cohort studies, retrospective studies, clinical trials studies, observational studies, prospective studies, randomized controlled trials, randomized clinical trials, systematic reviews, meta-analysis, and case reports.

INDEXING/ABSTRACTING

The WJCC is now abstracted and indexed in Science Citation Index Expanded (SCIE, also known as SciSearch®), Journal Citation Reports/Science Edition, Current Contents®/Clinical Medicine, PubMed, PubMed Central, Scopus, Reference Citation Analysis, China National Knowledge Infrastructure, China Science and Technology Journal Database, and Superstar Journals Database. The 2022 Edition of Journal Citation Reports® cites the 2021 impact factor (IF) for WJCC as 1.534; IF without journal self cites: 1.491; 5-year IF: 1.599; Journal Citation Indicator: 0.28; Ranking: 135 among 172 journals in medicine, general and internal; and Quartile category: Q4. The WJCC's CiteScore for 2021 is 1.2 and Scopus CiteScore rank 2021: General Medicine is 443/826.

RESPONSIBLE EDITORS FOR THIS ISSUE

Production Editor: *Xu Guo*; Production Department Director: *Xiang Li*; Editorial Office Director: *Jin-Lei Wang*.

NAME OF JOURNAL

World Journal of Clinical Cases

ISSN

ISSN 2307-8960 (online)

LAUNCH DATE

April 16, 2013

FREQUENCY

Thrice Monthly

EDITORS-IN-CHIEF

Bao-Gan Peng, Jerzy Tadeusz Chudek, George Kontogeorgos, Maurizio Serati, Ja Hyeon Ku

EDITORIAL BOARD MEMBERS

<https://www.wjnet.com/2307-8960/editorialboard.htm>

PUBLICATION DATE

November 6, 2022

COPYRIGHT

© 2022 Baishideng Publishing Group Inc

INSTRUCTIONS TO AUTHORS

<https://www.wjnet.com/bpg/gerinfo/204>

GUIDELINES FOR ETHICS DOCUMENTS

<https://www.wjnet.com/bpg/GerInfo/287>

GUIDELINES FOR NON-NATIVE SPEAKERS OF ENGLISH

<https://www.wjnet.com/bpg/gerinfo/240>

PUBLICATION ETHICS

<https://www.wjnet.com/bpg/GerInfo/288>

PUBLICATION MISCONDUCT

<https://www.wjnet.com/bpg/gerinfo/208>

ARTICLE PROCESSING CHARGE

<https://www.wjnet.com/bpg/gerinfo/242>

STEPS FOR SUBMITTING MANUSCRIPTS

<https://www.wjnet.com/bpg/GerInfo/239>

ONLINE SUBMISSION

<https://www.f6publishing.com>



Retrospective Study

Coxsackievirus A6 was the most common enterovirus serotype causing hand, foot, and mouth disease in Shiyan City, central China

Jing-Feng Li, Chuan-Jie Zhang, Ya-Wei Li, Chao Li, Shi-Chao Zhang, Sha-Sha Wang, Yong Jiang, Xin-Bing Luo, Xing-Juan Liao, Shou-Xin Wu, Ling Lin

Specialty type: Medicine, research and experimental

Provenance and peer review:

Unsolicited article; Externally peer reviewed.

Peer-review model: Single blind

Peer-review report's scientific quality classification

Grade A (Excellent): 0
Grade B (Very good): B, B, B
Grade C (Good): C, C
Grade D (Fair): 0
Grade E (Poor): 0

P-Reviewer: Chisthi MM, India; Hoveidaei AH, Iran; Enomoto H, Japan

Received: July 19, 2022

Peer-review started: July 19, 2022

First decision: August 22, 2022

Revised: September 4, 2022

Accepted: September 20, 2022

Article in press: September 20, 2022

Published online: November 6, 2022



Jing-Feng Li, Chao Li, Shi-Chao Zhang, Sha-Sha Wang, Yong Jiang, Xin-Bing Luo, Xing-Juan Liao, Department of Pediatrics, Taihe Hospital, Affiliated Hospital of Hubei University of Medicine, Shiyan 442000, Hubei Province, China

Chuan-Jie Zhang, Department of Children Health Care, Wuhan Children's Hospital (Wuhan Maternal and Child Healthcare Hospital), Tongji Medical College, Huazhong University of Science and Technology, Wuhan 430061, Hubei Province, China

Ya-Wei Li, Department of Health Services, Taihe Hospital, Affiliated Hospital of Hubei University of Medicine, Shiyan 442000, Hubei Province, China

Shou-Xin Wu, Ling Lin, Department of Pharmaceuticals, Shanghai Biotechan Pharmaceuticals Co. Ltd., Shanghai 200000, China

Shou-Xin Wu, Ling Lin, Zhangjiang Center for Translational Medicine, Shanghai Zhangjiang Institute of Medical Innovation, Shanghai 442000, China

Corresponding author: Jing-Feng Li, MD, Chief Physician, Department of Pediatrics, Taihe Hospital, Affiliated Hospital of Hubei University of Medicine, No. 32 Renmin South Road, Shiyan 442000, Hubei Province, China. zihe1206@126.com

Abstract

BACKGROUND

Hand, foot, and mouth disease (HFMD) has become one of the most common infectious diseases in China. Before 2016, the primary causal serotypes were enterovirus A71 (EV-A71) and coxsackievirus A16 (CV-A16). Following the introduction of EV-A71 vaccines in China since 2016, the situation could change. CV-A6 has recently replaced EV-A71 and CV-A16 in some areas of China. However, the epidemiological characteristics of central China remain unknown.

AIM

To investigate the clinical symptoms and pathogen spectrum of HFMD in Shiyan City, central China, in recent years.

METHODS

The epidemiological, clinical, and laboratory data from HFMD cases reported to the Shiyan Center for Disease Control and Prevention between January 2016 and

December 2020 were analyzed. 196 throat swab specimens were collected from hospitalized HFMD patients between January 2018 and December 2020. To detect and genotype enteroviruses, real-time reverse transcription-polymerase chain reaction and sequencing of the 5'-untranslated region were used. In Shiyang, 168 laboratory-confirmed HFMD cases were studied using a logistic regression model to determine the effect of predominant enterovirus serotypes. Based on the logistic regression model, the least absolute shrinkage and selection operator model was used to analyze the correlation between CV-A6 infection and various clinical characteristics in HFMD patients in Shiyang.

RESULTS

From 2016 to 2020, 35840 HFMD cases were reported in Shiyang. The number of cases decreased by 48.4% from 2016 to 2017. Approximately 1.58-fold increases were found in 2018 and 2019 when compared to the previous year, respectively. In 2020, a decrease of about 85.5% was reported when compared to 2019. The most common serotypes shifted from EV-A71 and CV-A16 (about 60%-80% in 2016 and 2018) to others (more than 80.0% in 2017, 2019, and 2020). EV-A71 lost its dominance in 2017 in Shiyang. Among 196 confirmed HFMD cases, 85.7% tested positive for enterovirus, with CV-A6 being the most common serotype (121/168, 72.0%). The positive rates for CV-A16 and CV-A10 were 4.8% and 3.0%, respectively. There was no EV-A71 discovered. Infection with CV-A6 was linked to fever, myocardial damage, increased creatine kinase MB isoenzyme, and lactate dehydrogenase levels.

CONCLUSION

CV-A6 was the most common enterovirus serotype in Shiyang City, replacing EV-A71 and CV-A16 as the HFMD pathogen. Developing vaccines against CV-A6 or multiple pathogens, as well as rising CV-A6 surveillance, will help prevent HFMD in central China.

Key Words: Hand, foot, and mouth disease; Coxsackievirus A6; Enterovirus; Prevalence serotype; Fever; Myocardial damage

©The Author(s) 2022. Published by Baishideng Publishing Group Inc. All rights reserved.

Core Tip: Hand, foot, and mouth disease (HFMD) has become China's most common infectious disease since 2008. Enterovirus A71 (EV-A71) and coxsackievirus A16 (CV-A16) were the primary causal serotypes. However, the dominant serotypes shifted recently to other enteroviruses. Nevertheless, there has been no report on the prevalence of the pathogen spectrum in Hubei, central China, since 2017. Our findings revealed that CV-A6 was the most common HFMD pathogen in Shiyang City, displacing EV-A71 and CV-A16. Fever and myocardial damage were more common in HFMD caused by CV-A6.

Citation: Li JF, Zhang CJ, Li YW, Li C, Zhang SC, Wang SS, Jiang Y, Luo XB, Liao XJ, Wu SX, Lin L. Coxsackievirus A6 was the most common enterovirus serotype causing hand, foot, and mouth disease in Shiyang City, central China. *World J Clin Cases* 2022; 10(31): 11358-11370

URL: <https://www.wjgnet.com/2307-8960/full/v10/i31/11358.htm>

DOI: <https://dx.doi.org/10.12998/wjcc.v10.i31.11358>

INTRODUCTION

Hand, foot, and mouth disease (HFMD) is one of the most widespread infectious diseases in the world. It disproportionately affects children under the age of five[1]. The Chinese Ministry of Health has designated HFMD as a category III notifiable infectious disease since 2008. The Chinese Center for Disease Control and Prevention (China CDC) has documented more than 20 million cases of HFMD from 2008 to 2018. The clinical presentation of HFMD is characterized by low-grade fever, a maculopapular or papulovesicular rash on the palms and soles of the feet, and severe oral ulcerations[2]. The illness is self-limiting, and the majority of children recover in a week without sequelae; however, a small proportion of children who experience neurologic or cardiopulmonary complications could be lethal[2].

As ever reported, the pathogens that caused HFMD are enterovirus-A (EV-A) and enterovirus-B (EV-B) species of the *Enterovirus* genus of the family *Picornaviridae*[3]. There are at least 23 serotypes, including nine coxsackievirus-A (CV-A) serotypes, enterovirus-A71 (EV-A71), six CV-B serotypes, six enteric cytopathogenic human orphan (ECHO) virus serotypes, and EV-B84[3]. The most common serotypes are CV-A16 and EV-A71, particularly in Asia-Pacific[4,5]. Furthermore, EV-A71 is also

responsible for the most severe and fatal cases[6,7].

However, since the first inactivated EV-A71 whole virus vaccine was launched in China in December 2015, the prevalence of EV-A71 has decreased dramatically[8,9]. A CV-A6-associated HFMD outbreak was reported in Finland in 2008[10]. Since then, CV-A6 has emerged as one of the pathogens responsible for the prevalence of HFMD in America, Europe, Africa, and Asia[11-14]. Between 2009 and 2017, several Chinese provinces reported sporadic HFMD cases caused by CV-A6[15-18]. Furthermore, the CV-A6 epidemic is becoming more widespread[14]. However, etiological data on HFMD in China after 2017 is scarce. There was even no report from Central China after 2017. Nonetheless, monitoring the circulating pathogens following the cumulative coverage of the EV-A71 vaccine is critical because it will help determine how to best implement a preventative strategy.

In this study, we focused on changes in the pathogen spectrum in Shiyan City, Hubei Province, between 2016 and 2020. We also analyzed the relationship between the primary pathogens and the clinical features of HFMD.

MATERIALS AND METHODS

Data collection

We obtained the surveillance data of HFMD in Shiyan city from 2016 to 2020 from Shiyan CDC. Since 2008, all clinically diagnosed and laboratory-confirmed HFMD cases have been reported to the local CDC within 24 h. The diagnostic criteria were based on the People's Republic of China Hygiene Industry Standard for Hand, Foot, and Mouth Disease Diagnosis (WS 588-2018)[19].

Patients and specimen collection

From 2018 to 2020, 196 hospitalized HFMD patients were enrolled in this study. The demographics of the patients, clinical data from their hospitalization, and throat swab specimens were all collected. The study was approved by the Institutional Review Board of the Taihe Hospital, Affiliated Hospital of Hubei University of Medicine (2017KS035). Participants' legal guardians signed informed consent forms.

Viral RNA extraction and real-time RT-PCR

Viral RNAs were extracted from the throat swab specimens using the Tianlong automatic nucleic acid extractor (NP968, Tianlong Science and Technology, Xi'an, China) and its corollary automatic nucleic acid extraction kit according to the manufacturer's instructions. In brief, 200 μ L specimens were used. The extracted RNAs were eluted in 100 μ L elution buffer and stored at -70 °C until used.

Real-time reverse transcription-polymerase chain reaction (RT-PCR) was performed to identify the enteroviruses in clinical samples using EV-A71 specific, CV-A16 specific, and pan-enterovirus real-time RT-PCR Kits (Tianlong Science and Technology).

5'-untranslated region amplification and sequencing for enterovirus serotypes identification

Enterovirus-positive samples were amplified for 5'-untranslated region (5'-UTR) and sequenced to identify the serotypes. The amplification was performed by RT-PCR using the 5'-UTR primers of the enteroviruses as described previously[20]. The primer sequences were as follows: EV-F: AYCYTTGTRCGCTGTTT; and EV-R: CCCAAAGTGTCGGTCCGC. The products of RT-PCR were sequenced using the EV-R primer by Biotecan (Shanghai, China). To identify the serotypes, the detected sequences were compared to reference strains in GenBank from the National Center for Biotechnology Information.

Statistical analyses

Categorical variables were summarized as frequencies and proportions using descriptive statistics. Chi-square and Fisher's exact tests were used to examine the relationships between categorical variables. Continuous variables were expressed as mean \pm SD. For normally distributed data, the means of continuous variables were compared using independent group *t*-tests, and for non-normally distributed data, the Mann-Whitney test. To determine the relationship between viral pathogens and HFMD characteristics, a logistic regression model was used. The least absolute shrinkage and selection operator (LASSO) method, which is suitable for analyzing high-dimensional data, was used to select the most significant pathogen-related characteristics[21]. In the forward stepwise logistic regression model, features with non-zero coefficients (automatically removing unnecessary/uninfluential covariates in the LASSO regression model were set[22]. All the statistical analyses were performed using R software version 4.1.2 (R Foundation for Statistical Computing, Vienna, Austria) and GraphPad Prism 7 (GraphPad Software, La Jolla, California, United States).

RESULTS

Shiyang City experienced a fluctuant decrease in the annual number of HFMD cases from 2016 to 2020

From 2016 to 2020, the Shiyang CDC surveillance system received 35840 HFMD cases, with 1690 (4.7%) laboratory-confirmed cases, 4 (0.01%) severe cases, and 2 (0.06%) fatal cases. In 2017 and 2020, the temporal distribution showed two low ebbs. The yearly number of HFMD decreased by 48.4% in 2017 ($n = 5405$) compared to 2016 ($n = 10473$), following 1.6-fold increases in 2018 ($n = 8513$) and 2019 ($n = 9997$). In 2020 ($n = 1452$), the incidence of HFMD fell by 85.5% compared to 2019 (Table 1 and Figure 1A). When compared to 2016 (308.63/100000), the annual incidence rate of HFMD decreased by 48.8% in 2017 (158.05/100000), then increased by 1.6-fold and 1.2-fold in 2018 (247.78/100000) and 2019 (292.48/100000) respectively. In 2020, the incidence of HFMD reduced by 85.4% (42.73/100000) compared to 2019 (Table 1 and Figure 1B), which could be attributed to the COVID-19 epidemic and China's isolation policy.

EV-A71 lost its dominance since the year 2017 in Shiyang

Since 2017, the proportion of EV-A71-associated HFMD cases among 1690 laboratory-confirmed HFMD cases in Shiyang has decreased significantly. In 2016, 45.5% of EV-A71-positive cases (167/367) were confirmed; however, this proportion dropped to 2.5% (9/363) in 2017 and nearly zero between 2018 and 2020 (Table 1 and Figure 1C). According to these findings, EV-A71 was the dominant pathogen of HFMD in Shiyang in 2016, but it lost the advantage between 2017 and 2020. The China Food and Drug Administration approved the EV-A71 whole virus vaccine in December 2015[8]. In Shiyang city, there were 8234 inoculated people in 2016, 28064 in 2017, 45948 in 2018, 45109 in 2019, and 50337 in 2020, with the number steadily increasing year after year (Figure 1C). These findings suggest that EV-A71 vaccine inoculation may be linked to the recent decrease in EV-A71 prevalence.

The CV-A16 was another common pathogen in China[5]. Its prevalence in Shiyang fluctuates between 2016 and 2020. In 2016, 34.1% of cases (125/367) tested positive for CV-A16. However, the ratio in 2017 was 11.8% (43/363), 61.0% (316/518) in 2018, 15.1% (56/370) in 2019, and 2.8% (2/72) in 2020 (Table 1 and Figure 1C). These findings indicate that CV-A16 was also a dominant HFMD pathogen in Shiyang in 2016, but that its dominance waned sharply in 2018.

In contrast to EV-A71 and CV-A16, the prevalence of other enteroviruses tends to rise in Shiyang from 2016 to 2020. Other enteroviruses ratios were 20.4% (75/367) in 2016, 85.7% (311/363) in 2017, 39.0% (202/518) in 2018, 84.6% (313/370) in 2019, and 97.2% (70/72) in 2020. 971 laboratory-confirmed cases were linked to other enteroviruses between 2016 and 2020, accounting for 57.5% of all cases (Table 1 and Figure 1C). These results suggest that other enteroviruses will gradually replace EV-A71 and CV-A16 as the most common HFMD pathogens in Shiyang. The specific prevailing serotype, however, remained unknown.

CV-A6 was the pathogen that had recently emerged in Shiyang

From 2018 to 2020, we collected 196 throat swab samples from hospitalized HFMD patients to investigate the newly prevalent enterovirus serotype (s) in Shiyang. Using EV-A71 specific, CV-A16 specific, and pan-enterovirus real-time RT-PCR Kits, 168 enterovirus-positive specimens were identified (Figure 2A). According to the 5'-UTR sequences of 168 enterovirus-positive samples, 121 (72.0%) were CV-A6 positive, 8 (4.8%) were CV-A16 positive, and 5 (3.0%) were CV-A10. Other enteroviruses were found in 34 of the samples (20.2%) (Figure 2B). From these results, CV-A6 was the newly prevalent serotype contributing to HFMD in Shiyang between 2018 and 2020.

Clinical characteristics of CV-A6-associated HFMD in Shiyang from 2018 to 2020

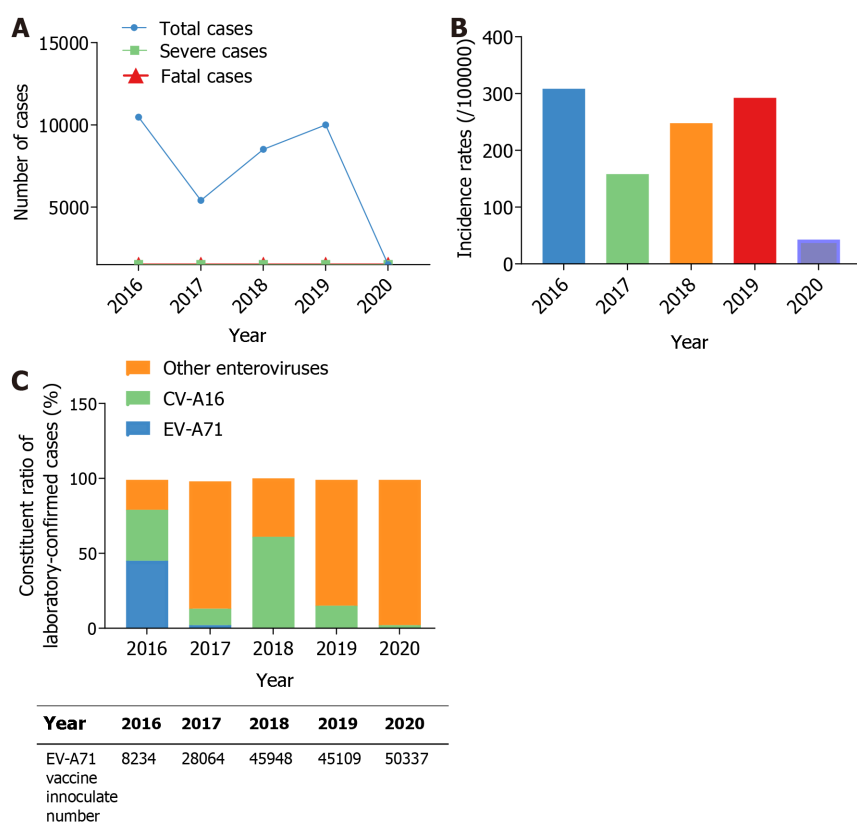
As shown in Table 2 and Figure 3A, the male-to-female ratio among the 168 enterovirus-positive cases was 1.67:1. 91 cases (54.2%) were under one year old, and no case was older than six years old. All patients had oral mucosal or skin rashes on the hand, foot, crissum, or hip. However, no significant differences in gender, age, or rashes were found between CV-A6 and other enteroviruses (CV-A16, CV-A10, and others). Fever was present in 95.9% of CV-A6-positive HFMD patients and 83.0% of CV-A6-negative HFMD patients. Fever levels differed significantly between HFMD with CV-A6 infection and HFMD without CV-A6 infection, according to univariate and multivariate logistic regression analyses (Table 2 and Figure 3B). A subsequent study using the LASSO regression model discovered that CV-A6 infection was more likely to result in fever ($P = 0.023 < 0.05$, Table 3).

There were no severe or fatal cases among the 168 enterovirus-positive cases. However, some patients had respiratory inflammation (such as bronchopneumonia, bronchitis, other upper respiratory tract diseases, or abnormal chest X-ray), and vomited. Nonetheless, there were no significant differences in these clinical manifestations between CV-A6 and other enteroviruses (CV-A16, CV-A10, and others) (Table 2). Myocardial damage, on the other hand, was significantly more common in CV-A6 infected patients than in other enterovirus infections (presenting as polyhedrosis, flustered, electrocardiographic abnormality, increased CK, CK-MB, and LDH). Myocardial damage was present in approximately 25.6% (31/121) of CV-A6-positive HFMD cases, whereas it was present in 8.5% (4/47) of CV-A6-negative HFMD patients (Table 2, Figure 3C). Furthermore, the LASSO regression model revealed that

Table 1 Incidence, severe illness, mortality, and etiological results of hand, foot, and mouth disease cases in 2016-2020 of Shiyan, central China, *n* (%)

Characteristics	Year				
	2016	2017	2018	2019	2020
Total cases	10473	5405	8513	9997	1452
Incidence rates (/100000)	308.63	158.05	247.78	292.48	42.73
Laboratory-detected cases	660	530	700	530	146
Laboratory-confirmed cases	367	363	518	370	72
Severe cases	1	0	2	1	0
Fatal cases	2	0	0	0	0
Etiological results					
EV-A71	167 (45.5)	9 (2.5)	0 (0.0)	1 (0.3)	0 (0.0)
CV-A16	125 (34.1)	43 (11.8)	316 (61.0)	56 (15.1)	2 (2.8)
Other enteroviruses	75 (20.4)	311 (85.7)	202 (39.0)	313 (84.6)	70 (97.2)

HFMD: Hand, foot, and mouth disease; EV-A71: Enterovirus A71; CV-A16: Coxsackievirus A16.



DOI: 10.12998/wjcc.v10.i31.11358 Copyright ©The Author(s) 2022.

Figure 1 Yearly distribution of hand, foot, and mouth disease cases from 2016 to 2020, in Shiyan, central China. A: Yearly distribution of hand, foot, and mouth disease (HFMD) cases, severe cases, and fatal cases; B: Yearly incidence rates of HFMD; C: Yearly distribution of laboratory-confirmed HFMD cases and enterovirus A71 vaccine inoculation numbers. CV-A16: Coxsackievirus A16; EV-A71: Enterovirus A71.

myocardial damage ($P = 0.037 < 0.05$) was significantly associated with CV-A6 infection. Additionally, elevated CK-MB ($P = 0.015 < 0.05$) and LDH ($P = 0.001$), two myocardial damage markers, were strongly linked with CV-A6 infection (Table 3), implying that myocardial damage is more frequent in HFMD caused by CV-A6.

Table 2 Logistic regression analysis on the effect of predominant enterovirus serotypes in 168 laboratory-confirmed hand, foot, and mouth disease cases in Shiyang, central China, *n* (%)

	HFMD pathogens				Univariate analysis	Multivariate analysis	
	CV-A6 (<i>n</i> = 121)	CV-A16 (<i>n</i> = 8)	CV-A10 (<i>n</i> = 5)	Other enteroviruses (<i>n</i> = 34)	<i>P</i> value	Coefficient (SD)	<i>P</i> value
Gender					1	-0.224 (0.451)	0.619
Male (<i>n</i> = 105)	76 (62.8)	5 (62.5)	4 (80.0)	20 (58.8)			
Female (<i>n</i> = 63)	45 (37.2)	3 (37.5)	1 (20.0)	14 (41.2)			
Age (yr)					0.794		
≤ 1 (<i>n</i> = 91)	65 (53.7)	4 (50.0)	3 (60.0)	19 (55.9)			
≤ 2 (<i>n</i> = 49)	37 (30.6)	2 (25.0)	2 (40.0)	8 (23.5)		0.131 (0.497)	0.792
≤ 3 (<i>n</i> = 18)	13 (10.7)	0 (0.0)	0 (0.0)	5 (14.7)		0.236 (0.717)	0.742
≤ 6 (<i>n</i> = 10)	6 (5.0)	2 (25.0)	0 (0.0)	2 (5.9)		-0.371 (0.785)	0.637
Fever					0.013 ^a	2.124 (0.747)	0.004 ^b
Yes	116 (95.9)	5 (62.5)	5 (100.0)	29 (85.3)			
No	5 (4.1)	3 (37.5)	0 (0.0)	5 (14.7)			
Clinical manifestations							
Skin or oral mucosal rashes	121 (100.0)	8 (100.0)	5 (100.0)	34 (100.0)			
Respiratory system syndromes ¹	24 (19.8)	3 (37.5)	1 (20.0)	3 (8.8)	0.603	0.811 (0.589)	0.168
Myocardial damage	31 (25.6)	1 (12.5)	1 (20.0)	2 (5.9)	0.025 ^a	1.040 (0.678)	0.125
Vomit	0 (0.0)	0 (0.0)	1 (20.0)	0 (0.0)	0.623	-15.923 (882.744)	0.986
Laboratory findings, <i>n</i> (%), mean ± SD)							
WBC increased	69 (56.6, 14.07 ± 3.42)	4 (50.0, 19.82 ± 10.74)	5 (100.0, 20.68 ± 7.67)	15 (44.1, 13.88 ± 4.38)	0.042 ^a	-0.058 (0.050)	0.247
CRP increased	79 (64.8, 24.64 ± 26.90)	5 (62.5, 25.28 ± 26.64)	5 (100.0, 47.68 ± 29.52)	15 (44.1, 25.97 ± 43.35)	0.431	-0.007 (0.006)	0.271
CK-MB increased	56 (45.9, 33.77 ± 13.78)	2 (25.0, 30.00 ± 4.24)	4 (80.0, 28.00 ± 6.48)	17 (50.0, 30.94 ± 7.04)	0.262	0.045 (0.027)	0.097
LDH increased	98 (80.3, 313.08 ± 59.37)	6 (75.0, 298.17 ± 38.97)	5 (100.0, 275.00 ± 24.81)	27 (79.4, 334.52 ± 59.64)	0.487	-0.009 (0.004)	0.043 ^a
ALT increased	20 (16.4)	1 (12.5)	1 (20.0)	3 (8.8)	0.333	-0.575 (1.328)	0.665
AST increased	29 (23.8)	1 (12.5)	1 (20.0)	3 (8.8)	0.086	1.778 (1.196)	0.137
Radiographic evaluation							
Abnormal chest X-ray ²	48 (39.3)	4 (50.0)	1 (20.0)	8 (23.5)	0.267	0.275 (0.449)	0.540
Abnormal electrocardiogram ³	24 (19.7)	1 (12.5)	1 (20.0)	5 (14.7)	0.389	0.236 (0.566)	0.677

¹Respiratory system syndromes were defined as the presence of at least one of the followings: Bronchopneumonia, bronchitis, or other upper respiratory tract diseases.

²Abnormal chest X-ray: unilateral or bilateral enhanced lung texture.

³abnormal electrocardiogram: sinus arrhythmia, or sinus tachycardia.

^a*P* < 0.05.

^b*P* < 0.01. HFMD: Hand, foot, and mouth disease; CV-A6: Coxsackievirus A6; CV-A16: Coxsackievirus A16; CV-A10: Coxsackievirus A10; SD: Standard deviation; WBC: White blood cell; CRP: C-reactive protein; CK-MB: Creatine kinase MB isoenzyme; LDH: Lactate dehydrogenase; ALT: Alanine transaminase; AST: Aspartate aminotransferase.

DISCUSSION

In 1957, HFMD was initially reported in New Zealand and Canada[23,24]. Then it spread all over the world, including the United States, Bulgaria, Hungary, and a slew of Asia countries[25-33]. For a long time, little attention was paid to this disease due to its mild clinical manifestations and self-limiting nature. Nonetheless, over the last two decades, an increasing number of outbreaks with atypical manifestations and expanding pathogen spectrums have been reported worldwide, attracting public attention[3,34,35]. Because of the widespread prevalence of HFMD in China, the Chinese Ministry of Health has also designated it as a category III notifiable infectious disease since 2008. The main pathogens in the pathogen spectrums were CV-A16 and EV-A71[36]. The disease caused by CV-A16 was typically mild, with classical rashes. EV-A71, on the other hand, can cause severe neurological manifestations such as polio-like paralysis, fatal encephalitis, and cardiopulmonary complications in addition to rashes[37]. As a result, developing effective pathogen-specific vaccines is a wise decision.

Since 2016, three inactivated, whole EV-A71 vaccines have been launched in China[38]. And the EV-A71 vaccines were proved to be effective in a recent epidemiologic survey in Guangxi Province (Southern China). The incidence and severity of EV-A71 cases have both decreased significantly following vaccination with EV-A71 vaccines from 2017 to 2019[9]. A report from Nanchang (Southeastern China) found no EV-A71 after a 2-year implementation of the EV-A71 vaccination[39]. Our findings also showed the efficacy of EV-A71 vaccines. It was discovered that, as the number of inoculated people in Shiyan (Central China) increased year after year, the incidence of HFMD decreased sharply in 2017 (Table 1 and Figure 1A-B). Furthermore, EV-A71 prevalence in Shiyan decreased sharply in 2017 and will almost completely disappear between 2018 and 2020 (Table 1 and Figure 1C), indicating that EV-A71 vaccine inoculation may be beneficial. However, the HFMD incidence increased again in Shiyan in 2018 and 2019, indicating that, while EV-A71 was under control, other pathogens may be contributing to the increased HFMD cases. In fact, the EV-A71 vaccine provided no cross-protection against other serotypes. Then, which pathogen(s) were responsible for the rise in HFMD cases in Shiyan between 2018 and 2020?

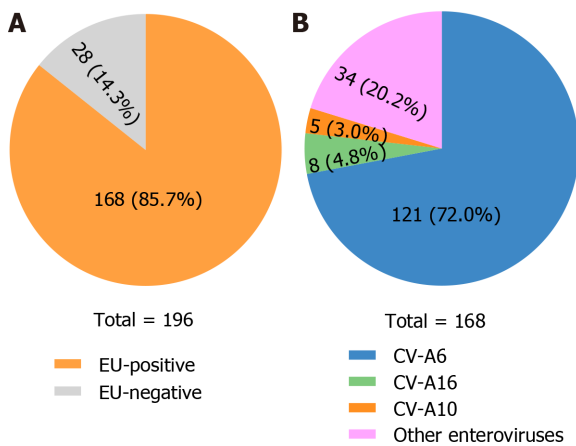
In reality, a shift in HFMD etiology has been reported in recent years. CV-A6, CV-A10, and CV-A12 have emerged as important HFMD pathogens, except for CV-A16 and EV-A71[40-42]. HFMD caused by CV-A6 has been reported in countries around the world, including Finland, the United States, Japan, Spain, *etc*[10,11,43,44]. CV-A6 was also a significant pathogen contributing to HFMD in China. Between 2010 and 2012, CV-A6 surpassed CV-A16 as the second most common serotype in southern China (Guangdong Province)[45,46]. In 2013, CV-A6 replaced EV-A71 and CV-A16 as the primary pathogen of HFMD in northern (Beijing, Tianjin), northeastern (Jilin), eastern (Taizhou), and middle China (Chongqing)[47-51]. In 2015, CV-A6 outbreaks were reported in northern (Beijing) and middle (Chongqing) China[52,53]. During 2018-2019, CV-A6 was found to be the most common cause of HFMD in eastern (Shanghai), northern (Beijing, 2018, and 2020), southeastern (Nanchang, 2019), and southern (Kunming, 2018) China[39,54-56]. In our study, CV-A6 surpassed EV-A71 and CV-A16 as the leading cause of HFMD in central China (Shiyan) between 2018 and 2020 (Table 2 and Figure 2), demonstrating that CV-A6 has become the most common serotype recently in China. Intriguingly, CV-A6 nonetheless overtook CV-A16 and EV-A71 as the primary causal agent in some regions in 2013 despite the absence of EV-A71 vaccines. The reason remained unknown.

It has been reported that CV-A6 can cause severe HFMD in children and atypical HFMD in adults[57-59]. Clinical manifestations involved vesiculobullous exanthema, palm and sole desquamation, and onychomadesis[14,60]. A study of 8 confirmed HFMD children found severe clinical features such as 100% fever (higher than 39 °C), 87.5% herpangina, 100% meningitis, and 25% myocardial damage caused by CV-A6[57]. In our collected samples, we found that more than half of the cases occurred in boys and children under the age of one year. No patient was older than the age of six (Table 2). As a result, the prevention of infant HFMD should be prioritized. Because we collected samples from the pediatric department, no adult patients were found. In addition, we showed that CV-A6 was more likely to cause fever (95.9% *vs* 83%) and myocardial damage (25.6% *vs* 8.5%) (Table 3 and Figure 3), which was consistent with the previous study[57]. However, no onychomadesis was observed in our study. It might be due to different CV-A6 genotypes. The limitation is that genotypes of prevailing CV-A6 in Shiyan and other regions were not identified. Further study can be done to determine the association between different CV-A6 genotypes and clinical features.

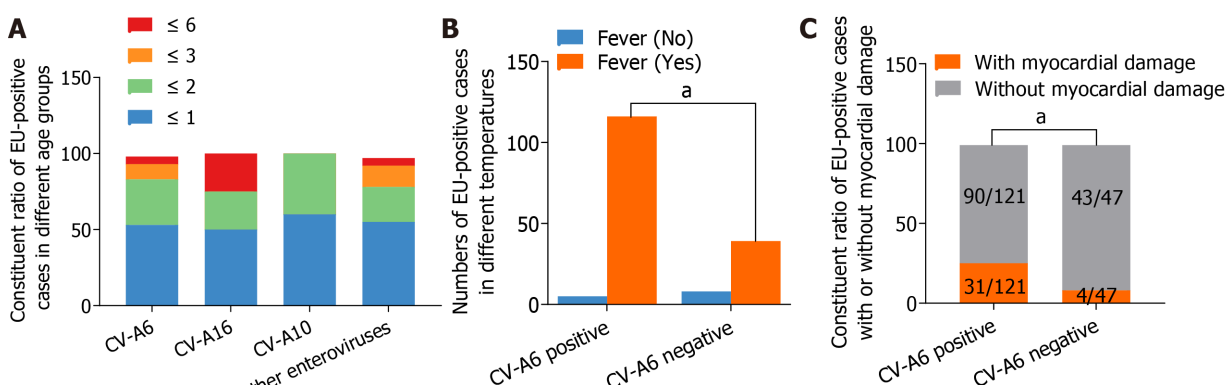
The median R0 (interquartile range) of the major HFMD serotypes was calculated in a recent study. Among EV-A71, CV-A16, and CV-A6, CV-A6 had the highest R0 (5.94, and 25.80 after adjusting for seroprevalences), implying that CV-A6 may be the major challenge in the prevention and control of HFMD in China[61]. As a result, developing vaccines against CV-A6 or multiple pathogens will help prevent HFMD. Recently, an inactivated CV-A6 vaccine candidate based on Vero cells was shown to be effective in mouse models[62]. However, more clinical trials were required to provide evidence of its efficacy. A recent study[63] used cryo-electron microscopy to identify the virion structure of CV-A6, laying the groundwork for the development of novel vaccines and drugs. In addition, multiple enterovirus serotypes, including CV-A6, should be included in long-term HFMD surveillance.

Table 3 The least absolute shrinkage and selection operator regression analysis of the correlation between coxsackievirus A6 infection and various characteristics in hand, foot, and mouth disease patients in Shiyan, China

Characteristic	CV-A6 infection	
	Coefficient (SE)	P value
Temperature	-8.880e-01 (3.899e-01)	0.023 ^a
Myocardial damage	1.224e+00 (5.894e-01)	0.037 ^a
CK-MB increased	7.187e-02 (2.978e-02)	0.015 ^a
LDH increased	-1.355e-02 (4.137e-03)	0.001 ^b

^a $P < 0.05$.^b $P < 0.01$. CV-A6: Coxsackievirus A6; SE: Standard error; CK-MB: Creatine kinase MB isoenzyme; LDH: Lactate dehydrogenase.

DOI: 10.12998/wjcc.v10.i31.11358 Copyright ©The Author(s) 2022.

Figure 2 Enterovirus serotypes of 196 hospitalized hand, foot, and mouth disease patients enrolled in this study from 2018 to 2020 in Shiyan, central China. A: Enterovirus A71 specific, coxsackievirus A16 specific, and pan-enterovirus real-time reverse transcription-polymerase chain reaction Kits were used to identify enterovirus-positive specimens; B: The 5'-untranslated region sequences identified enterovirus serotypes of 168 enterovirus-positive samples. EU-positive: Enterovirus-positive; CV: Coxsackievirus.

DOI: 10.12998/wjcc.v10.i31.11358 Copyright ©The Author(s) 2022.

Figure 3 Clinical characteristics of hand, foot, and mouth disease in Shiyan from 2018 to 2020. A: The constituent ratio of different enterovirus serotypes associated with hand, foot, and mouth disease cases in different age groups; B: Numbers of enterovirus-positive cases with or without fever; C: The constituent ratio of enterovirus-positive cases with or without myocardial damage. ^a $P < 0.05$. EU-positive: Enterovirus-positive; CV: Coxsackievirus.

CONCLUSION

In conclusion, CV-A6 is the most common enterovirus serotype in Shiyan City, replacing EV-A71 and CV-A16 as the HFMD pathogen. Fever and myocardial damage are more common in CV-A6-caused HFMD. CV-A6 prevalence surveillance should be prioritized.

ARTICLE HIGHLIGHTS

Research background

Before 2016, the main causative serotypes of hand, foot, and mouth disease (HFMD) were coxsackievirus A16 (CV-A16) and enterovirus A71 (EV-A71). Some regions in China have shown that CV-A6 has recently supplanted EV-A71 and CV-A16 due to the introduction of EV-A71 vaccines. Finding out Central China's epidemiological characteristics is equally important.

Research motivation

By investigating the clinical symptoms and pathogen spectrum of HFMD in Shiyan City, central China, after 2016, it will provide critical proof for future knowledge of the etiology of HFMD.

Research objectives

To investigate the epidemiological and etiological features of HFMD in Shiyan City, which may provide information on the disease's recent prevalence in central China.

Research methods

The Shiyan Center for Disease Control and Prevention HFMD data from 2016 to 2020 were examined. Between 2018 and 2020, throat swab specimens were collected from hospitalized HFMD patients in Shiyan. To detect and genotype enteroviruses, real-time reverse transcription-polymerase chain reaction and sequencing of the 5'-untranslated region were used. The effect of predominant enterovirus serotypes and the correlation between CV-A6 infection and various clinical characteristics in Shiyan HFMD patients were studied using a logistic regression model and the least absolute shrinkage and selection operator model.

Research results

The frequency of HFMD dramatically dropped in 2017 as the number of immunized persons in Shiyan grew year after year. But the prevalence of HFMD rose once more in 2018 and 2019. Between 2018 and 2020, CV-A6 superseded EV-A71 and CV-A16 as the main cause of HFMD in Shiyan. CV-A6 was associated with an increased risk of fever and myocardial damage. The limitation is that the dominant CV-A6 genotypes in Shiyan and other regions were not identified. More research is needed to determine the relationship between different CV-A6 genotypes and clinical features.

Research conclusions

The most common enterovirus serotype in Shiyan City was CV-A6, which replaced EV-A71 and CV-A16 as the HFMD pathogen.

Research perspectives

The prevention of HFMD in central China will be aided by the creation of vaccines against CV-A6 or multiple infections as well as increased CV-A6 surveillance.

ACKNOWLEDGEMENTS

We are very grateful to Jia CL for his skillful statistical analysis guidance.

FOOTNOTES

Author contributions: Li JF, Zhang CJ, and Li YW contributed equally to this study; Li JF, Zhang CJ, and Li YW designed and performed the research and co-wrote the paper; Li C, Wang SS, Zhang SC, Jiang Y, Luo XB, and Liao XJ collected the clinical specimens and the corresponding characteristics; Wu SX, and Lin L performed the serotypes identification of clinical samples; all authors have read and approved the final manuscript.

Supported by the Hubei Province Health and Family Planning A Scientific Research Project, No. WJ2017M220; the Wuhan Health Bureau Scientific Research Fund, No. WX19C11; the Joint Precision Medical Research Fund From Taihe Hospital, No. 2016JZ10; the Shiyan COVID-19 Pilot Emergency Scientific Research Project, No. 20Y19; and the Wuhan Children's Hospital Research Project, No. 2017FE007.

Institutional review board statement: This study was reviewed and approved by the Institutional Review Board of the Taihe Hospital, Affiliated Hospital of Hubei University of Medicine (2017KS035). The study was carried out following the Code of Ethics of the World Medical Association (Declaration of Helsinki) for experiments involving humans.

Informed consent statement: Patients were not required to give informed consent to the study because the analysis used anonymous clinical data that were obtained after each patient agreed to treatment by written consent.

Conflict-of-interest statement: All authors hereby declare that no conflict of interest exists.

Data sharing statement: No additional data are available.

Open-Access: This article is an open-access article that was selected by an in-house editor and fully peer-reviewed by external reviewers. It is distributed in accordance with the Creative Commons Attribution NonCommercial (CC BY-NC 4.0) license, which permits others to distribute, remix, adapt, build upon this work non-commercially, and license their derivative works on different terms, provided the original work is properly cited and the use is non-commercial. See: <https://creativecommons.org/licenses/by-nc/4.0/>

Country/Territory of origin: China

ORCID number: Jing-Feng Li 0000-0001-5682-6643; Chuan-Jie Zhang 0000-0003-0404-6615; Ya-Wei Li 0000-0002-1754-7040; Chao Li 0000-0001-8395-7147; Shi-Chao Zhang 0000-0002-4759-3662; Sha-Sha Wang 0000-0002-4725-3158; Yong Jiang 0000-0002-1412-4114; Xin-Bing Luo 0000-0001-9543-7747; Shou-Xin Wu 0000-0003-1220-4265; Ling Lin 0000-0002-6209-5610.

S-Editor: Wang LL

L-Editor: A

P-Editor: Wang LL

REFERENCES

- 1 **Esposito S, Principi N.** Hand, foot and mouth disease: current knowledge on clinical manifestations, epidemiology, aetiology and prevention. *Eur J Clin Microbiol Infect Dis* 2018; **37**: 391-398 [PMID: 29411190 DOI: 10.1007/s10096-018-3206-x]
- 2 **Sagui A, Kane SF, Lauters R, Mercado MG.** Hand-Foot-and-Mouth Disease: Rapid Evidence Review. *Am Fam Physician* 2019; **100**: 408-414 [PMID: 31573162]
- 3 **Lei X, Cui S, Zhao Z, Wang J.** Etiology, pathogenesis, antivirals and vaccines of hand, foot, and mouth disease. *Natl Sci Rev* 2015; **2**: 268-284 [DOI: 10.1093/nsr/nwv038]
- 4 **Noisumdaeng P, Korkusol A, Prasertsopon J, Sangsiriwut K, Chokephaibulkit K, Mungaomklang A, Thitithanyanont A, Buathong R, Guntapong R, Puthavathana P.** Longitudinal study on enterovirus A71 and coxsackievirus A16 genotype/subgenotype replacements in hand, foot and mouth disease patients in Thailand, 2000-2017. *Int J Infect Dis* 2019; **80**: 84-91 [PMID: 30639624 DOI: 10.1016/j.ijid.2018.12.020]
- 5 **Huang J, Liao Q, Ooi MH, Cowling BJ, Chang Z, Wu P, Liu F, Li Y, Luo L, Yu S, Yu H, Wei S.** Epidemiology of Recurrent Hand, Foot and Mouth Disease, China, 2008-2015. *Emerg Infect Dis* 2018; **24** [PMID: 29460747 DOI: 10.3201/eid2403.171303]
- 6 **Messacar K, Spence-Davison E, Osborne C, Press C, Schreiner TL, Martin J, Messer R, Maloney J, Burakoff A, Barnes M, Rogers S, Lopez AS, Routh J, Gerber SI, Oberste MS, Nix WA, Abzug MJ, Tyler KL, Herlihy R, Dominguez SR.** Clinical characteristics of enterovirus A71 neurological disease during an outbreak in children in Colorado, United States, in 2018: an observational cohort study. *Lancet Infect Dis* 2020; **20**: 230-239 [PMID: 31859216 DOI: 10.1016/S1473-3099]
- 7 **Liu SL, Pan H, Liu P, Amer S, Chan TC, Zhan J, Huo X, Liu Y, Teng Z, Wang L, Zhuang H.** Comparative epidemiology and virology of fatal and nonfatal cases of hand, foot and mouth disease in mainland China from 2008 to 2014. *Rev Med Virol* 2015; **25**: 115-128 [PMID: 25704797 DOI: 10.1002/rmv.1827]
- 8 **Mao QY, Wang Y, Bian L, Xu M, Liang Z.** EV71 vaccine, a new tool to control outbreaks of hand, foot and mouth disease (HFMD). *Expert Rev Vaccines* 2016; **15**: 599-606 [PMID: 26732723 DOI: 10.1586/14760584.2016.1138862]
- 9 **Wang J, Jiang L, Zhang C, He W, Tan Y, Ning C.** The changes in the epidemiology of hand, foot, and mouth disease after the introduction of the EV-A71 vaccine. *Vaccine* 2021; **39**: 3319-3323 [PMID: 33994239 DOI: 10.1016/j.vaccine.2021.05.009]
- 10 **Osterback R, Vuorinen T, Linna M, Susi P, Hyypää T, Waris M.** Coxsackievirus A6 and hand, foot, and mouth disease, Finland. *Emerg Infect Dis* 2009; **15**: 1485-1488 [PMID: 19788821 DOI: 10.3201/eid1509.090438]
- 11 **Centers for Disease Control and Prevention (CDC).** Notes from the field: severe hand, foot, and mouth disease associated with coxsackievirus A6 - Alabama, Connecticut, California, and Nevada, November 2011-February 2012. *MMWR Morb Mortal Wkly Rep* 2012; **61**: 213-214 [PMID: 22456122]
- 12 **Horsten HH, Kemp M, Fischer TK, Lindahl KH, Bygum A.** Atypical Hand, Foot, and Mouth Disease Caused by Coxsackievirus A6 in Denmark: A Diagnostic Mimicker. *Acta Derm Venereol* 2018; **98**: 350-354 [PMID: 29182793 DOI: 10.2340/00015555-2853]
- 13 **Gopalkrishna V, Ganorkar N.** Epidemiological and molecular characteristics of circulating CVA16, CVA6 strains and genotype distribution in hand, foot and mouth disease cases in 2017 to 2018 from Western India. *J Med Virol* 2021; **93**: 3572-3580 [PMID: 32833231 DOI: 10.1002/jmv.26454]
- 14 **Zhao TS, Du J, Sun DP, Zhu QR, Chen LY, Ye C, Wang S, Liu YQ, Cui F, Lu QB.** A review and meta-analysis of the epidemiology and clinical presentation of coxsackievirus A6 causing hand-foot-mouth disease in China and global implications. *Rev Med Virol* 2020; **30**: e2087 [PMID: 31811676 DOI: 10.1002/rmv.2087]

- 15 **Xu Y**, Zheng Y, Shi W, Guan L, Yu P, Xu J, Zhang L, Ma P. Pathogenic characteristics of hand, foot and mouth disease in Shaanxi Province, China, 2010-2016. *Sci Rep* 2020; **10**: 989 [PMID: [31969644](#) DOI: [10.1038/s41598-020-57807-z](#)]
- 16 **Xu S**, Li H, Qiao P, Xu G, Zhao D, Lin X, Qin Y, Yu H, Zhang X, Zhang W, Huang L. Neonatal hand, foot, and mouth disease due to coxsackievirus A6 in Shanghai. *BMC Pediatr* 2020; **20**: 364 [PMID: [32741368](#) DOI: [10.1186/s12887-020-02262-y](#)]
- 17 **Song Y**, Zhang Y, Ji T, Gu X, Yang Q, Zhu S, Xu W, Xu Y, Shi Y, Huang X, Li Q, Deng H, Wang X, Yan D, Yu W, Wang S, Yu D. Persistent circulation of Coxsackievirus A6 of genotype D3 in mainland of China between 2008 and 2015. *Sci Rep* 2017; **7**: 5491 [PMID: [28710474](#) DOI: [10.1038/s41598-017-05618-0](#)]
- 18 **Lu QB**, Zhang XA, Wo Y, Xu HM, Li XJ, Wang XJ, Ding SJ, Chen XD, He C, Liu LJ, Li H, Yang H, Li TY, Liu W, Cao WC. Circulation of Coxsackievirus A10 and A6 in hand-foot-mouth disease in China, 2009-2011. *PLoS One* 2012; **7**: e52073 [PMID: [23272213](#) DOI: [10.1371/journal.pone.0052073](#)]
- 19 **Li XW**, Ni X, Qian SY, Wang Q, Jiang RM, Xu WB, Zhang YC, Yu GJ, Chen Q, Shang YX, Zhao CS, Yu H, Zhang T, Liu G, Deng HL, Gao J, Ran XG, Yang QZ, Xu BL, Huang XY, Wu XD, Bao YX, Chen YP, Chen ZH, Liu QQ, Lu GP, Liu CF, Wang RB, Zhang GL, Gu F, Xu HM, Li Y, Yang T. Chinese guidelines for the diagnosis and treatment of hand, foot and mouth disease (2018 edition). *World J Pediatr* 2018; **14**: 437-447 [PMID: [30280313](#) DOI: [10.1007/s12519-018-0189-8](#)]
- 20 **Tang S**, Xie Z, Liu D, Yuan Y, Chen M, Fan X, Ding X, Yu N. Evaluation of 5'-untranslated region amplification and sequencing for enterovirus serotypes identification diagnosis. *Zhonghua Shiyao He Linchuang Bingdixue Zazhi* 2018; **32**: 488-491 [DOI: [10.3760/cma.j.issn.1003-9279.2018.05.008](#)]
- 21 **Sauerbrei W**, Royston P, Binder H. Selection of important variables and determination of functional form for continuous predictors in multivariable model building. *Stat Med* 2007; **26**: 5512-5528 [PMID: [18058845](#) DOI: [10.1002/sim.3148](#)]
- 22 **Kidd AC**, McGettrick M, Tsing S, Halligan DL, Bylesjo M, Blyth KG. Survival prediction in mesothelioma using a scalable Lasso regression model: instructions for use and initial performance using clinical predictors. *BMJ Open Respir Res* 2018; **5**: e000240 [PMID: [29468073](#) DOI: [10.1136/bmjresp-2017-000240](#)]
- 23 **Seddon JH**, Duff MF. Hand-foot-and-mouth disease: Coxsackie virus types A 5, A 10, and A 16 infections. *N Z Med J* 1971; **74**: 368-373 [PMID: [5291880](#)]
- 24 **Robinson CR**, Doane FW, Rhodes AJ. Report of an outbreak of febrile illness with pharyngeal lesions and exanthem: Toronto, summer 1957; isolation of group A Coxsackie virus. *Can Med Assoc J* 1958; **79**: 615-621 [PMID: [13585281](#)]
- 25 **Khanh TH**, Sabanathan S, Thanh TT, Thoa le PK, Thuong TC, Hang Vt, Farrar J, Hien TT, Chau Nv, van Doorn HR. Enterovirus 71-associated hand, foot, and mouth disease, Southern Vietnam, 2011. *Emerg Infect Dis* 2012; **18**: 2002-2005 [PMID: [23194699](#) DOI: [10.3201/eid1812.120929](#)]
- 26 **Chan KP**, Goh KT, Chong CY, Teo ES, Lau G, Ling AE. Epidemic hand, foot and mouth disease caused by human enterovirus 71, Singapore. *Emerg Infect Dis* 2003; **9**: 78-85 [PMID: [12533285](#) DOI: [10.3201/eid0901.020112](#)]
- 27 **McMinn P**, Stratov I, Nagarajan L, Davis S. Neurological manifestations of enterovirus 71 infection in children during an outbreak of hand, foot, and mouth disease in Western Australia. *Clin Infect Dis* 2001; **32**: 236-242 [PMID: [11170913](#) DOI: [10.1086/318454](#)]
- 28 **Chan LG**, Parashar UD, Lye MS, Ong FG, Zaki SR, Alexander JP, Ho KK, Han LL, Pallansch MA, Suleiman AB, Jegathesan M, Anderson LJ. Deaths of children during an outbreak of hand, foot, and mouth disease in sarawak, malaysia: clinical and pathological characteristics of the disease. For the Outbreak Study Group. *Clin Infect Dis* 2000; **31**: 678-683 [PMID: [11017815](#) DOI: [10.1086/314032](#)]
- 29 **Centers for Disease Control and Prevention (CDC)**. Deaths among children during an outbreak of hand, foot, and mouth disease--Taiwan, Republic of China, April-July 1998. *MMWR Morb Mortal Wkly Rep* 1998; **47**: 629-632 [PMID: [9704628](#)]
- 30 **Nagy G**, Takátsy S, Kukán E, Mihály I, Dömök I. Virological diagnosis of enterovirus type 71 infections: experiences gained during an epidemic of acute CNS diseases in Hungary in 1978. *Arch Virol* 1982; **71**: 217-227 [PMID: [6285858](#) DOI: [10.1007/BF01314873](#)]
- 31 **Ishimaru Y**, Nakano S, Yamaoka K, Takami S. Outbreaks of hand, foot, and mouth disease by enterovirus 71. High incidence of complication disorders of central nervous system. *Arch Dis Child* 1980; **55**: 583-588 [PMID: [6254449](#) DOI: [10.1136/adc.55.8.583](#)]
- 32 **Chumakov M**, Voroshilova M, Shindarov L, Lavrova I, Gracheva L, Koroleva G, Vasilenko S, Brodvarova I, Nikolova M, Gyurova S, Gacheva M, Mitov G, Ninov N, Tsykka E, Robinson I, Frolova M, Bashkirtsev V, Martiyanova L, Rodin V. Enterovirus 71 isolated from cases of epidemic poliomyelitis-like disease in Bulgaria. *Arch Virol* 1979; **60**: 329-340 [PMID: [228639](#) DOI: [10.1007/BF01317504](#)]
- 33 **FLEWETT TH**, WARIN RP, CLARKE SK. 'Hand, foot, and mouth disease' associated with Coxsackie A5 virus. *J Clin Pathol* 1963; **16**: 53-55 [PMID: [13945538](#) DOI: [10.1136/jcp.16.1.53](#)]
- 34 **Nassef C**, Ziemer C, Morrell DS. Hand-foot-and-mouth disease: a new look at a classic viral rash. *Curr Opin Pediatr* 2015; **27**: 486-491 [PMID: [26087425](#) DOI: [10.1097/MOP.0000000000000246](#)]
- 35 **Koh WM**, Bogich T, Siegel K, Jin J, Chong EY, Tan CY, Chen MI, Horby P, Cook AR. The Epidemiology of Hand, Foot and Mouth Disease in Asia: A Systematic Review and Analysis. *Pediatr Infect Dis J* 2016; **35**: e285-e300 [PMID: [27273688](#) DOI: [10.1097/INF.0000000000001242](#)]
- 36 **Nishimura Y**, Shimizu H. Cellular receptors for human enterovirus species a. *Front Microbiol* 2012; **3**: 105 [PMID: [22470371](#) DOI: [10.3389/fmicb.2012.00105](#)]
- 37 **Chang PC**, Chen SC, Chen KT. The Current Status of the Disease Caused by Enterovirus 71 Infections: Epidemiology, Pathogenesis, Molecular Epidemiology, and Vaccine Development. *Int J Environ Res Public Health* 2016; **13** [PMID: [27618078](#) DOI: [10.3390/ijerph13090890](#)]
- 38 **Li ML**, Shih SR, Tolbert BS, Brewer G. Enterovirus A71 Vaccines. *Vaccines (Basel)* 2021; **9** [PMID: [33673595](#) DOI: [10.3390/vaccines9030199](#)]
- 39 **He F**, Rui J, Deng Z, Zhang Y, Qian K, Zhu C, Yu S, Tu J, Xia W, Zhu Q, Chen S, Chen T, Zhou X. Surveillance, Epidemiology and Impact of EV-A71 Vaccination on Hand, Foot, and Mouth Disease in Nanchang, China, 2010-2019. *Front Microbiol* 2021; **12**: 811553 [PMID: [35069515](#) DOI: [10.3389/fmicb.2021.811553](#)]

- 40 **Bian L**, Gao F, Mao Q, Sun S, Wu X, Liu S, Yang X, Liang Z. Hand, foot, and mouth disease associated with coxsackievirus A10: more serious than it seems. *Expert Rev Anti Infect Ther* 2019; **17**: 233-242 [PMID: [30793637](#) DOI: [10.1080/14787210.2019.1585242](#)]
- 41 **Puenpa J**, Mauleekoonphairoj J, Linsuwanon P, Suwannakarn K, Chieochansin T, Korkong S, Theamboonlers A, Poovorawan Y. Prevalence and characterization of enterovirus infections among pediatric patients with hand foot mouth disease, herpangina and influenza like illness in Thailand, 2012. *PLoS One* 2014; **9**: e98888 [PMID: [24887237](#) DOI: [10.1371/journal.pone.0098888](#)]
- 42 **Liu X**, Mao N, Yu W, Chai Q, Wang H, Wang W, Wang L, Wang Z, Xu W. Genetic characterization of emerging coxsackievirus A12 associated with hand, foot and mouth disease in Qingdao, China. *Arch Virol* 2014; **159**: 2497-2502 [PMID: [24796551](#) DOI: [10.1007/s00705-014-2067-6](#)]
- 43 **Montes M**, Artieda J, Piñeiro LD, Gastesi M, Diez-Nieves I, Cilla G. Hand, foot, and mouth disease outbreak and coxsackievirus A6, northern Spain, 2011. *Emerg Infect Dis* 2013; **19** [PMID: [23751014](#) DOI: [10.3201/eid1904.121589](#)]
- 44 **Fujimoto T**, Iizuka S, Enomoto M, Abe K, Yamashita K, Hanaoka N, Okabe N, Yoshida H, Yasui Y, Kobayashi M, Fujii Y, Tanaka H, Yamamoto M, Shimizu H. Hand, foot, and mouth disease caused by coxsackievirus A6, Japan, 2011. *Emerg Infect Dis* 2012; **18**: 337-339 [PMID: [22304983](#) DOI: [10.3201/eid1802.111147](#)]
- 45 **Di B**, Zhang Y, Xie H, Li X, Chen C, Ding P, He P, Wang D, Geng J, Luo L, Bai Z, Yang Z, Wang M. Circulation of Coxsackievirus A6 in hand-foot-mouth disease in Guangzhou, 2010-2012. *Virol J* 2014; **11**: 157 [PMID: [25178398](#) DOI: [10.1186/1743-422X-11-157](#)]
- 46 **He YQ**, Chen L, Xu WB, Yang H, Wang HZ, Zong WP, Xian HX, Chen HL, Yao XJ, Hu ZL, Luo M, Zhang HL, Ma HW, Cheng JQ, Feng QJ, Zhao DJ. Emergence, circulation, and spatiotemporal phylogenetic analysis of coxsackievirus a6- and coxsackievirus a10-associated hand, foot, and mouth disease infections from 2008 to 2012 in Shenzhen, China. *J Clin Microbiol* 2013; **51**: 3560-3566 [PMID: [23966496](#) DOI: [10.1128/JCM.01231-13](#)]
- 47 **Wang SH**, Wang A, Liu PP, Zhang WY, Du J, Xu S, Liu GC, Zheng BS, Huan C, Zhao K, Yu XF. Divergent Pathogenic Properties of Circulating Coxsackievirus A6 Associated with Emerging Hand, Foot, and Mouth Disease. *J Virol* 2018; **92** [PMID: [29563294](#) DOI: [10.1128/JVI.00303-18](#)]
- 48 **Tan X**, Li L, Zhang B, Jorba J, Su X, Ji T, Yang D, Lv L, Li J, Xu W. Molecular epidemiology of coxsackievirus A6 associated with outbreaks of hand, foot, and mouth disease in Tianjin, China, in 2013. *Arch Virol* 2015; **160**: 1097-1104 [PMID: [25680566](#) DOI: [10.1007/s00705-015-2340-3](#)]
- 49 **Zha J**, Ma Z. Epidemiological and genetic analysis concerning the coxsackievirus A6 related endemic outbreak of hand-foot-mouth disease in Taizhou, China, during 2013. *J Med Virol* 2015; **87**: 2000-2008 [PMID: [25989289](#) DOI: [10.1002/jmv.24272](#)]
- 50 **Yan X**, Zhang ZZ, Yang ZH, Zhu CM, Hu YG, Liu QB. Clinical and Etiological Characteristics of Atypical Hand-Foot-and-Mouth Disease in Children from Chongqing, China: A Retrospective Study. *Biomed Res Int* 2015; **2015**: 802046 [PMID: [26693489](#) DOI: [10.1155/2015/802046](#)]
- 51 **Hongyan G**, Chengjie M, Qiaozhi Y, Wenhao H, Juan L, Lin P, Yanli X, Hongshan W, Xingwang L. Hand, foot and mouth disease caused by coxsackievirus A6, Beijing, 2013. *Pediatr Infect Dis J* 2014; **33**: 1302-1303 [PMID: [25037037](#) DOI: [10.1097/INF.0000000000000467](#)]
- 52 **Yu FY**, Zhu RN, Deng J, Song QW, Jia LP, Liu LY, Qian Y. [Pathogen spectrum in enteroviral infections among children in Beijing from 2010 to 2016]. *Zhonghua Er Ke Za Zhi* 2018; **56**: 575-581 [PMID: [30078237](#) DOI: [10.3760/cma.j.issn.0578-1310.2018.08.004](#)]
- 53 **Tao J**, He XY, Shi Y, Zhu G, Liu S, Zhang Z, Tang S, Zhang R, Peng B, Liu Z, Tan J, Chen Q, Wang X, Bao L, Zou L, Zhang P. Epidemiology of 45,616 suspect cases of Hand, Foot and Mouth Disease in Chongqing, China, 2011-2015. *Sci Rep* 2017; **7**: 45630 [PMID: [28422128](#) DOI: [10.1038/srep45630](#)]
- 54 **Hu L**, Maimaiti H, Zhou L, Gao J, Lu Y. Changing serotypes of hand, foot and mouth disease in Shanghai, 2017-2019. *Gut Pathog* 2022; **14**: 12 [PMID: [35313977](#) DOI: [10.1186/s13099-022-00485-1](#)]
- 55 **Cui Y**, Yang YN, Zheng RR, Xie MZ, Zhang WX, Chen LY, Du J, Yang Y, Xi L, Li H, Li HJ, Lu QB. Epidemiological characteristics of hand, foot, and mouth disease clusters during 2016-2020 in Beijing, China. *J Med Virol* 2022; **94**: 4934-4943 [PMID: [35655366](#) DOI: [10.1002/jmv.27906](#)]
- 56 **Jiang H**, Zhang Z, Rao Q, Wang X, Wang M, Du T, Tang J, Long S, Zhang J, Luo J, Pan Y, Chen J, Ma J, Liu X, Fan M, Zhang T, Sun Q. The epidemiological characteristics of enterovirus infection before and after the use of enterovirus 71 inactivated vaccine in Kunming, China. *Emerg Microbes Infect* 2021; **10**: 619-628 [PMID: [33682641](#) DOI: [10.1080/22221751.2021.1899772](#)]
- 57 **Yang F**, Yuan J, Wang X, Li J, Du J, Su H, Zhou B, Jin Q. Severe hand, foot, and mouth disease and coxsackievirus A6-Shenzhen, China. *Clin Infect Dis* 2014; **59**: 1504-1505 [PMID: [25091307](#) DOI: [10.1093/cid/ciu624](#)]
- 58 **Ramirez-Fort MK**, Downing C, Doan HQ, Benoist F, Oberste MS, Khan F, Tyring SK. Coxsackievirus A6 associated hand, foot and mouth disease in adults: clinical presentation and review of the literature. *J Clin Virol* 2014; **60**: 381-386 [PMID: [24932735](#) DOI: [10.1016/j.jcv.2014.04.023](#)]
- 59 **Harris PNA**, Wang AD, Yin M, Lee CK, Archuleta S. Atypical hand, foot, and mouth disease: eczema coxsackium can also occur in adults. *Lancet Infect Dis* 2014; **14**: 1043 [PMID: [25444404](#) DOI: [10.1016/S1473-3099](#)]
- 60 **Justino MCA**, da S Mesquita D, Souza MF, Farias FP, Dos S Alves JC, Ferreira JL, Lopes DP, Tavares FN. Atypical hand-foot-mouth disease in Belém, Amazon region, northern Brazil, with detection of coxsackievirus A6. *J Clin Virol* 2020; **126**: 104307 [PMID: [32302950](#) DOI: [10.1016/j.jcv.2020.104307](#)]
- 61 **Zhang Z**, Liu Y, Liu F, Ren M, Nie T, Cui J, Chang Z, Li Z. Basic Reproduction Number of Enterovirus 71 and Coxsackievirus A16 and A6: Evidence From Outbreaks of Hand, Foot, and Mouth Disease in China Between 2011 and 2018. *Clin Infect Dis* 2021; **73**: e2552-e2559 [PMID: [33320199](#) DOI: [10.1093/cid/ciaa1853](#)]
- 62 **Qian SS**, Wei ZN, Jin WP, Wu J, Zhou YP, Meng SL, Guo J, Wang ZJ, Shen S. Efficacy of a coxsackievirus A6 vaccine candidate in an actively immunized mouse model. *Emerg Microbes Infect* 2021; **10**: 763-773 [PMID: [33739899](#) DOI: [10.1080/22221751.2021.1906755](#)]
- 63 **Büttner CR**, Spurný R, Füzik T, Plevka P. Cryo-electron microscopy and image classification reveal the existence and

structure of the coxsackievirus A6 virion. *Commun Biol* 2022; **5**: 898 [PMID: [36056184](#) DOI: [10.1038/s42003-022-03863-2](#)]



Published by **Baishideng Publishing Group Inc**
7041 Koll Center Parkway, Suite 160, Pleasanton, CA 94566, USA

Telephone: +1-925-3991568

E-mail: bpgoffice@wjgnet.com

Help Desk: <https://www.f6publishing.com/helpdesk>

<https://www.wjgnet.com>

