

World Journal of *Clinical Cases*

World J Clin Cases 2022 November 16; 10(32): 11665-12065



Contents

Thrice Monthly Volume 10 Number 32 November 16, 2022

OPINION REVIEW

- 11665** Combined use of lactoferrin and vitamin D as a preventive and therapeutic supplement for SARS-CoV-2 infection: Current evidence

Cipriano M, Ruberti E, Tovani-Palone MR

REVIEW

- 11671** Role of adherent invasive *Escherichia coli* in pathogenesis of inflammatory bowel disease
- Zheng L, Duan SL, Dai YC, Wu SC*
- 11690** Emerging potential of ubiquitin-specific proteases and ubiquitin-specific proteases inhibitors in breast cancer treatment

Huang ML, Shen GT, Li NL

MINIREVIEWS

- 11702** Overlap of diabetic ketoacidosis and hyperosmolar hyperglycemic state
- Hassan EM, Mushtaq H, Mahmoud EE, Chhibber S, Saleem S, Issa A, Nitesh J, Jama AB, Khedr A, Boike S, Mir M, Attallah N, Surani S, Khan SA*

ORIGINAL ARTICLE

Case Control Study

- 11712** Comparing the efficacy of different dexamethasone regimens for maintenance treatment of multiple myeloma in standard-risk patients non-eligible for transplantation
- Hu SL, Liu M, Zhang JY*

Retrospective Cohort Study

- 11726** Development and validation of novel nomograms to predict survival of patients with tongue squamous cell carcinoma
- Luo XY, Zhang YM, Zhu RQ, Yang SS, Zhou LF, Zhu HY*

Retrospective Study

- 11743** Non-invasive model for predicting esophageal varices based on liver and spleen volume
- Yang LB, Zhao G, Tantai XX, Xiao CL, Qin SW, Dong L, Chang DY, Jia Y, Li H*

Clinical Trials Study

- 11753** Clinical efficacy of electromagnetic field therapy combined with traditional Chinese pain-reducing paste in myofascial pain syndrome
- Xiao J, Cao BY, Xie Z, Ji YX, Zhao XL, Yang HJ, Zhuang W, Sun HH, Liang WM*

- 11766** Endothelial injury and inflammation in patients with hyperuricemic nephropathy at chronic kidney disease stages 1-2 and 3-4

Xu L, Lu LL, Wang YT, Zhou JB, Wang CX, Xin JD, Gao JD

Observational Study

- 11775** Quality of life and symptom distress after cytoreductive surgery and hyperthermic intraperitoneal chemotherapy

Wang YF, Wang TY, Liao TT, Lin MH, Huang TH, Hsieh MC, Chen VCH, Lee LW, Huang WS, Chen CY

- 11789** Development and validation of a risk assessment model for prediabetes in China national diabetes survey

Yu LP, Dong F, Li YZ, Yang WY, Wu SN, Shan ZY, Teng WP, Zhang B

Case Control Study

- 11804** T-cell immunoglobulin mucin molecule-3, transformation growth factor β , and chemokine-12 and the prognostic status of diffuse large B-cell lymphoma

Wu H, Sun HC, Ouyang GF

META-ANALYSIS

- 11812** Prostate artery embolization on lower urinary tract symptoms related to benign prostatic hyperplasia: A systematic review and meta-analysis

Wang XY, Chai YM, Huang WH, Zhang Y

CASE REPORT

- 11827** Paraneoplastic neurological syndrome caused by cystitis glandularis: A case report and literature review

Zhao DH, Li QJ

- 11835** Neck pain and absence of cranial nerve symptom are clues of cervical myelopathy mimicking stroke: Two case reports

Zhou LL, Zhu SG, Fang Y, Huang SS, Huang JF, Hu ZD, Chen JY, Zhang X, Wang JY

- 11845** Nine-year survival of a 60-year-old woman with locally advanced pancreatic cancer under repeated open approach radiofrequency ablation: A case report

Zhang JY, Ding JM, Zhou Y, Jing X

- 11853** Laparoscopic treatment of inflammatory myofibroblastic tumor in liver: A case report

Li YY, Zang JF, Zhang C

- 11861** Survival of a patient who received extracorporeal membrane oxygenation due to postoperative myocardial infarction: A case report

Wang QQ, Jiang Y, Zhu JG, Zhang LW, Tong HJ, Shen P

- 11869** Triple hit to the kidney-dual pathological crescentic glomerulonephritis and diffuse proliferative immune complex-mediated glomerulonephritis: A case report

Ibrahim D, Brodsky SV, Satoskar AA, Biederman L, Maroz N

- 11877** Successful transcatheter arterial embolization treatment for chest wall haematoma following permanent pacemaker implantation: A case report
Zheng J, Tu XM, Gao ZY
- 11882** Brachiocephalic to left brachial vein thrombotic vasculitis accompanying mediastinal pancreatic fistula: A case report
Kokubo R, Yunaiyama D, Tajima Y, Kugai N, Okubo M, Saito K, Tsuchiya T, Itoi T
- 11889** Long survival after immunotherapy plus paclitaxel in advanced intrahepatic cholangiocarcinoma: A case report and review of literature
He MY, Yan FF, Cen KL, Shen P
- 11898** Successful treatment of pulmonary hypertension in a neonate with bronchopulmonary dysplasia: A case report and literature review
Li J, Zhao J, Yang XY, Shi J, Liu HT
- 11908** Idiopathic tenosynovitis of the wrist with multiple rice bodies: A case report and review of literature
Tian Y, Zhou HB, Yi K, Wang KJ
- 11921** Endoscopic resection of bronchial mucoepidermoid carcinoma in a young adult man: A case report and review of literature
Ding YM, Wang Q
- 11929** Blue rubber bleb nevus syndrome complicated with disseminated intravascular coagulation and intestinal obstruction: A case report
Zhai JH, Li SX, Jin G, Zhang YY, Zhong WL, Chai YF, Wang BM
- 11936** Management of symptomatic cervical facet cyst with cervical interlaminar epidural block: A case report
Hwang SM, Lee MK, Kim S
- 11942** Primary squamous cell carcinoma with sarcomatoid differentiation of the kidney associated with ureteral stone obstruction: A case report
Liu XH, Zou QM, Cao JD, Wang ZC
- 11949** Successful live birth following hysteroscopic adhesiolysis under laparoscopic observation for Asherman's syndrome: A case report
Kakinuma T, Kakinuma K, Matsuda Y, Ohwada M, Yanagida K
- 11955** What is responsible for acute myocardial infarction in combination with aplastic anemia? A case report and literature review
Zhao YN, Chen WW, Yan XY, Liu K, Liu GH, Yang P
- 11967** Repeated ventricular bigeminy by trigeminocardiac reflex despite atropine administration during superficial upper lip surgery: A case report
Cho SY, Jang BH, Jeon HJ, Kim DJ
- 11974** Testis and epididymis-unusual sites of metastatic gastric cancer: A case report and review of the literature
Ji JJ, Guan FJ, Yao Y, Sun LJ, Zhang GM

- 11980** t(4;11) translocation in hyperdiploid *de novo* adult acute myeloid leukemia: A case report
Zhang MY, Zhao Y, Zhang JH
- 11987** Sun-burn induced upper limb lymphedema 11 years following breast cancer surgery: A case report
Li M, Guo J, Zhao R, Gao JN, Li M, Wang LY
- 11993** Minimal change disease caused by polycythemia vera: A case report
Xu L, Lu LL, Gao JD
- 12000** Vitreous amyloidosis caused by a Lys55Asn variant in transthyretin: A case report
Tan Y, Tao Y, Sheng YJ, Zhang CM
- 12007** Endoscopic nasal surgery for mucocoele and pyogenic mucocoele of turbinate: Three case reports
Sun SJ, Chen AP, Wan YZ, Ji HZ
- 12015** Transcatheter arterial embolization for traumatic injury to the pharyngeal branch of the ascending pharyngeal artery: Two case reports
Yunaiyama D, Takara Y, Kobayashi T, Muraki M, Tanaka T, Okubo M, Saguchi T, Nakai M, Saito K, Tsukahara K, Ishii Y, Homma H
- 12022** Retroperitoneal leiomyoma located in the broad ligament: A case report
Zhang XS, Lin SZ, Liu YJ, Zhou L, Chen QD, Wang WQ, Li JY
- 12028** Primary testicular neuroendocrine tumor with liver lymph node metastasis: A case report and review of the literature
Xiao T, Luo LH, Guo LF, Wang LQ, Feng L
- 12036** Endodontic treatment of the maxillary first molar with palatal canal variations: A case report and review of literature
Chen K, Ran X, Wang Y
- 12045** Langerhans cell histiocytosis involving only the thymus in an adult: A case report
Li YF, Han SH, Qie P, Yin QF, Wang HE

LETTER TO THE EDITOR

- 12052** Heart failure with preserved ejection fraction: A distinct heart failure phenotype?
Triposkiadis F, Giamouzis G, Skoularigis J, Xanthopoulos A
- 12056** Insight into appropriate medication prescribing for elderly in the COVID-19 era
Omar AS, Kaddoura R
- 12059** Commentary on "Gallstone associated celiac trunk thromboembolisms complicated with splenic infarction: A case report"
Tokur O, Aydın S, Kantarci M
- 12062** Omicron targets upper airways in pediatrics, elderly and unvaccinated population
Nori W, Ghani Zghair MA

ABOUT COVER

Editorial Board Member of *World Journal of Clinical Cases*, Camelia Cristina Diaconu, FACC, FACP, FESC, MHSc, PhD, Associate Professor, Department of Internal Medicine, "Carol Davila" University of Medicine and Pharmacy, Clinical Emergency Hospital of Bucharest, Bucharest 014461, Romania. drcameliadiaconu@gmail.com

AIMS AND SCOPE

The primary aim of *World Journal of Clinical Cases* (WJCC, *World J Clin Cases*) is to provide scholars and readers from various fields of clinical medicine with a platform to publish high-quality clinical research articles and communicate their research findings online.

WJCC mainly publishes articles reporting research results and findings obtained in the field of clinical medicine and covering a wide range of topics, including case control studies, retrospective cohort studies, retrospective studies, clinical trials studies, observational studies, prospective studies, randomized controlled trials, randomized clinical trials, systematic reviews, meta-analysis, and case reports.

INDEXING/ABSTRACTING

The WJCC is now abstracted and indexed in Science Citation Index Expanded (SCIE, also known as SciSearch®), Journal Citation Reports/Science Edition, Current Contents®/Clinical Medicine, PubMed, PubMed Central, Scopus, Reference Citation Analysis, China National Knowledge Infrastructure, China Science and Technology Journal Database, and Superstar Journals Database. The 2022 Edition of Journal Citation Reports® cites the 2021 impact factor (IF) for WJCC as 1.534; IF without journal self cites: 1.491; 5-year IF: 1.599; Journal Citation Indicator: 0.28; Ranking: 135 among 172 journals in medicine, general and internal; and Quartile category: Q4. The WJCC's CiteScore for 2021 is 1.2 and Scopus CiteScore rank 2021: General Medicine is 443/826.

RESPONSIBLE EDITORS FOR THIS ISSUE

Production Editor: Hua-Ge Yin; Production Department Director: Xu Guo; Editorial Office Director: Jin-Lei Wang.

NAME OF JOURNAL

World Journal of Clinical Cases

ISSN

ISSN 2307-8960 (online)

LAUNCH DATE

April 16, 2013

FREQUENCY

Thrice Monthly

EDITORS-IN-CHIEF

Bao-Gan Peng, Jerzy Tadeusz Chudek, George Kontogeorgos, Maurizio Serati, Ja Hyeon Ku

EDITORIAL BOARD MEMBERS

<https://www.wjgnet.com/2307-8960/editorialboard.htm>

PUBLICATION DATE

November 16, 2022

COPYRIGHT

© 2022 Baishideng Publishing Group Inc

INSTRUCTIONS TO AUTHORS

<https://www.wjgnet.com/bpg/gerinfo/204>

GUIDELINES FOR ETHICS DOCUMENTS

<https://www.wjgnet.com/bpg/GerInfo/287>

GUIDELINES FOR NON-NATIVE SPEAKERS OF ENGLISH

<https://www.wjgnet.com/bpg/gerinfo/240>

PUBLICATION ETHICS

<https://www.wjgnet.com/bpg/GerInfo/288>

PUBLICATION MISCONDUCT

<https://www.wjgnet.com/bpg/gerinfo/208>

ARTICLE PROCESSING CHARGE

<https://www.wjgnet.com/bpg/gerinfo/242>

STEPS FOR SUBMITTING MANUSCRIPTS

<https://www.wjgnet.com/bpg/GerInfo/239>

ONLINE SUBMISSION

<https://www.f6publishing.com>

Management of symptomatic cervical facet cyst with cervical interlaminar epidural block: A case report

Seong Min Hwang, Min Kyu Lee, Saeyoung Kim

Specialty type: Medicine, research and experimental

Provenance and peer review: Unsolicited article; Externally peer reviewed.

Peer-review model: Single blind

Peer-review report's scientific quality classification

Grade A (Excellent): 0
Grade B (Very good): B, B
Grade C (Good): 0
Grade D (Fair): 0
Grade E (Poor): 0

P-Reviewer: Gao L, China; Naem AA, Syria

Received: June 29, 2022

Peer-review started: June 29, 2022

First decision: September 5, 2022

Revised: September 7, 2022

Accepted: October 11, 2022

Article in press: October 11, 2022

Published online: November 16, 2022



Seong Min Hwang, Min Kyu Lee, Saeyoung Kim, Department of Anesthesiology and Pain Medicine, School of Medicine, Kyungpook National University, Daegu 41944, South Korea

Corresponding author: Saeyoung Kim, MD, PhD, Professor, Department of Anesthesiology and Pain Medicine, School of Medicine, Kyungpook National University, 130 Dongdeok-ro, Jung-gu, Daegu 41944, South Korea. saeyoungkim7@gmail.com

Abstract

BACKGROUND

Symptomatic cervical facet cysts are relatively rare compared to those in the lumbar region. These cysts are usually located in the 7th cervical and 1st thoracic vertebral (C7/T1) area, and surgical excision is performed in most cases. However, facet cysts are associated with degenerative conditions, and elderly patients are often ineligible for surgical procedures. Cervical interlaminar epidural block has been used in patients with cervical radiating symptoms and achieved good results. Therefore, cervical interlaminar epidural block may be the first-choice treatment for symptomatic cervical facet cysts.

CASE SUMMARY

A 70-year-old man complained of a tingling sensation in the left hand, focused on the 4th and 5th fingers, for 1 year, and posterior neck pain for over 5 mo. The patient's numeric rating scale (NRS) score was 5/10. The patient was diagnosed with symptomatic cervical facet cyst at the left C7/T1 facet joint. Fluoroscopy-guided cervical interlaminar epidural block at the C7/T1 level with 20 mg triamcinolone and 5 mL of 0.5% lidocaine was administered. The patient's symptoms improved immediately after the block, with an NRS score of 3 points. After 3 mo, his left posterior neck pain and tingling along the left 8th cervical dermatome were relieved, with an NRS score of 2.

CONCLUSION

A cervical interlaminar epidural block is a good alternative for managing symptomatic cervical facet cysts.

Key Words: Cervical vertebrae; Cysts; Epidural; Injections; Neck pain; Therapeutics; Zygapophyseal joint; Case report

©The Author(s) 2022. Published by Baishideng Publishing Group Inc. All rights reserved.

Core Tip: Intraspinous facet cysts are usually asymptomatic and incidentally identified. However, they could be symptomatic and interfere with the patient's quality of life. Symptomatic cervical facet cysts are relatively rare compared to those in the lumbar region. Guidelines for the management of cervical facet cysts have not been well established. Several patients reported in the existing literature underwent surgery for symptomatic cervical facet cysts, but there are situations where surgery may not be possible, such as an underlying disorder or refusal of the patient. In such cases, a cervical interlaminar epidural block can be a good alternative.

Citation: Hwang SM, Lee MK, Kim S. Management of symptomatic cervical facet cyst with cervical interlaminar epidural block: A case report. *World J Clin Cases* 2022; 10(32): 11936-11941

URL: <https://www.wjgnet.com/2307-8960/full/v10/i32/11936.htm>

DOI: <https://dx.doi.org/10.12998/wjcc.v10.i32.11936>

INTRODUCTION

A facet cyst is defined as extrusion of the synovium through a capsular defect, resulting from an unstable or degenerate synovial joint. Symptomatic intraspinal facet cysts are typically located on the lumbar spine. Facet cysts of the cervical spine are rarely reported. Despite several decades of research, the etiology of intraspinal facet cysts remains unclear. Extrusion of synovial fluid through defects and tears of the facet capsule, degeneration of myxoid, and cyst formation from collagen tissue have been proposed as potential etiologies[1]. Moreover, synovial extrusion can be aggravated by hypermobility or inflammatory factors resulting in radiating symptoms. The most common treatment for symptomatic cervical facet cysts is the surgical removal of the cyst through hemilaminectomy or bilateral laminectomy, with or without instrumented fusion[2]. Non-surgical management of cervical facet cysts is rarely applicable. Here, we present a rare case of symptomatic cervical facet cyst managed with cervical interlaminar epidural block.

CASE PRESENTATION

Chief complaints

A 70-year-old man visited our pain clinic with posterior neck pain, tingling sensation, and numbness along the left 8th cervical (C8) vertebral dermatome.

History of present illness

A tingling sensation and numbness in the left hand, localized to the 4th and 5th finger, started a year earlier. The patient subsequently complained of posterior neck pain for more than 5 mo.

History of past illness

Before visiting our clinic, he was treated with oral pregabalin (150 mg/d), duloxetine (30 mg/d), and tramadol (100 mg/d) for 2 wk in the neurosurgery clinic of our hospital. However, the patient did not respond to this treatment. We used the numeric rating scale (NRS) to assess the severity of pain, and the patient's NRS score was 5 out of 10. His symptoms worsened when he was lying on his left side.

Personal and family history

The patient had hypertension and a history of angina pectoris but no history of cervical trauma. The patient had no specific family history.

Physical examination

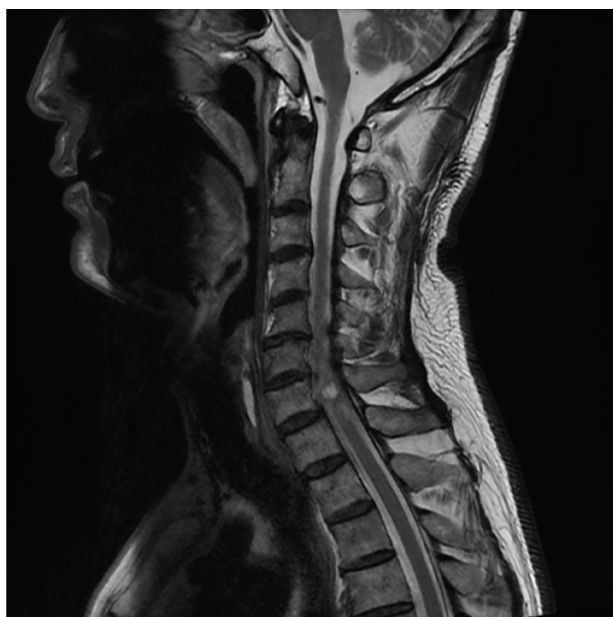Physical examination revealed sensory impairment in the left C8 dermatome, but motor functions were intact. Spurling's test showed a positive result on the left side. The deep tendon reflexes were normal.

Laboratory examinations

Laboratory examinations did not reveal any abnormalities.

Imaging examinations

Magnetic resonance imaging (MRI) of the cervical spine revealed a 6 mm × 6 mm × 10 mm intradural extramedullary tumor cyst on the left posterolateral aspect of the 7th cervical and 1st thoracic vertebral (C7/T1) facet joint (Figure 1). The cyst showed a low signal intensity on T1-weighted images. On T2-



DOI: 10.12998/wjcc.v10.i32.11938 Copyright ©The Author(s) 2022.

Figure 1 T2-weighted magnetic resonance imaging of the patient's cervical spine. Sagittal image showing a cyst at the left posterolateral aspect of the 7th cervical and 1st thoracic vertebral facet joint.

weighted images, high signal intensity in the center and low signal intensity around the rim were observed (Figure 2).

FINAL DIAGNOSIS

The patient was diagnosed with symptomatic cervical facet cyst at the left C7/T1 facet joint.

TREATMENT

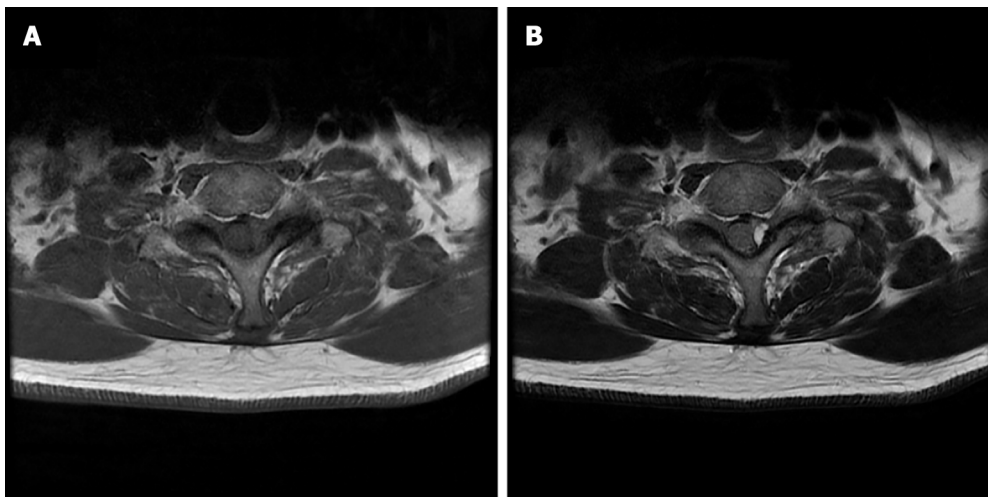
Although symptomatic cervical facet cysts are usually treated with surgical excision, the patient was worried about surgery because of his old age and cardiac condition. Therefore, we decided to perform nonsurgical nerve block. A fluoroscopy-guided cervical interlaminar epidural block was performed at the C7/T1 level using 20 mg of triamcinolone and 5 mL of 0.5% lidocaine.

OUTCOME AND FOLLOW-UP

The patient's symptoms improved immediately after the procedure, and the NRS score decreased to 3 points. The patient revisited the clinic for follow-up after 2 wk. His left posterior neck pain and tingling along the left C8 dermatome were relieved, with an NRS score of 2 points. The patient further reported that his symptoms had improved and he no longer required medication. There were no complications associated with the block procedure. At the 3 mo follow-up after the cervical interlaminar epidural block, the patient's pain was still rated as 2 on the NRS, although the numbness persisted. The patient was satisfied with the clinical outcome and refused follow-up MRI because of the symptomatic improvement and financial burden.

DISCUSSION

Cervical facet cysts were first described in 1985 by Cartwright *et al*[3]. They are often found at the C7/T1 level and are relatively uncommon compared to lumbar facet cysts[4]. Intraspinous facet cysts are usually asymptomatic and incidentally identified. However, they could be symptomatic and interfere with the patient's quality of life. The clinical presentation of symptomatic intraspinal facet cysts includes radicular pain (84%), back pain before radicular pain (50%-93%), neurologic claudication (10%-44%),



DOI: 10.12998/wjcc.v10.i32.11936 Copyright ©The Author(s) 2022.

Figure 2 Axial magnetic resonance imaging of the 7th cervical spine. A: The cyst shows low signal intensity on T1-weighted images; B: The cyst shows high signal intensity on T2-weighted images.

sensory deficits (10%-43%), motor deficits (20%-27%), and symptoms consistent with cauda equina syndrome[5]. Our patient also experienced numbness and tingling sensation along the left C8 dermatome and left posterior neck pain.

MRI is the most sensitive imaging modality for diagnosing cervical facet cysts. On MRI, these cysts appeared as well-circumscribed extradural cystic lesions close to the facet joints. These lesions have a low signal intensity on T1-weighted images and high signal intensity on T2-weighted images. Facet cysts show a typical pattern of high signal intensity at the center and low signal intensity around the rim [6]. We observed an image of the cyst at the left C7/T1 level on the T2-weighted MRI.

Guidelines for the management of cervical facet cysts have not been well established. Patients with significant neurological deficits, motor weakness, intractable pain, or multiple synovial cysts should undergo surgical treatment to achieve the best long-term outcome[5]. According to previous reports, surgical removal of symptomatic cervical facet cysts through hemilaminectomy and bilateral laminectomy, with or without instrumented fusion, is usually performed[2,4]. Although surgical treatment is generally successful, with complete removal of the cyst, from the patient's point of view, it can be a burdensome choice as first-line treatment. In addition, the possibility of complications related to surgery and anesthesia should be considered. Therefore, nonsurgical management can be an alternative to reduce the surgical burden.

Regarding symptomatic lumbar facet cysts, there have been several reports of conservative management such as percutaneous cyst aspiration and percutaneous steroid injection. Unger *et al*[7] reported a case of successful management of symptomatic L4/5 facet cysts by using L4/5 and L5/S1 transforaminal epidural steroid injections. Slipman *et al*[8] further evaluated nonsurgical managements, such as therapeutic selective nerve root block, intraarticular zygapophyseal joint corticosteroid injection, and cyst puncture for symptomatic lumbar facet cysts. They reported that with follow-up for an average of 1.4 years after the termination of management, one-third of the patients (28.6%) were found to have an excellent outcome. Lee *et al*[9] successfully managed a symptomatic L5/S1 facet joint cyst and left S1 radiculopathy using percutaneous treatment with steroid injection and distension of the cyst. Jin *et al*[10] reported successful removal of an L4/5 facet cyst by mechanical rupture under epiduroscopic guidance.

Although there have been several reports of conservative management of lumbar facet cysts, studies of cervical facet cysts are relatively rare. Kostanian *et al*[11] reported the successful management of symptomatic cervical facet cysts at C6/7 by cyst aspiration under computed tomography guidance combined with epidural injection of a local anesthetic and steroid. Tarukado *et al*[12] suggested the possibility of spontaneous regression of a symptomatic C4/5 facet cyst; thus, conservative management might be indicated for symptomatic cervical facet cysts, especially in cases of radiculopathy of the middle cervical spine.

We believe that symptoms caused by cervical facet cysts can be managed similarly to those caused by cervical herniated nucleus pulposus or cervical spinal stenosis. Therefore, a cervical interlaminar epidural block could be the first choice for the management of symptomatic cervical facet cysts. If cervical interlaminar epidural block fails, other conservative options, including image-guided aspiration of the cyst, epiduroscopic removal, or surgery, can be considered. Therefore, we performed a fluoroscopy-guided cervical interlaminar epidural block at the C7/T1 level using 20 mg of triamcinolone and 5 mL of 0.5% lidocaine as the first treatment choice to relieve symptoms. Mixtures of local anesthetics and corticosteroids have been used for epidural block. The rationale for injecting local

anesthetics is to block sensory signals. The effectiveness of local anesthetics for chronic pain is based on their anti-inflammatory actions and the alteration of multiple pathophysiological mechanisms. Moreover, corticosteroids in epidural block have been used to reduce inflammation either by inhibiting the synthesis or release of a number of proinflammatory substances or by causing a reversible local anesthetic effect[13]. The patient's symptoms were sufficiently reduced after the procedure. The patient refused follow-up cervical MRI because of symptomatic improvement and financial burden. Therefore, it was not possible to determine whether the cervical facet cyst regressed spontaneously as in a previous report[12], decreased in size compared to the previous size, or whether the cervical facet cyst persisted; however, the patient's symptoms were improved after the cervical interlaminar epidural block.

Several patients reported in the existing literature underwent surgery for symptomatic cervical facet cysts, but there are situations where surgery may not be possible, such as an underlying disorder or refusal of the patient. In such cases, a cervical interlaminar epidural block can be a good alternative.

CONCLUSION

In conclusion, there are various options for the management of symptomatic cervical facet cysts. However, standard management guidelines have not yet been established. Therefore, we need to consider the value of cervical interlaminar epidural block as an effective conservative approach, and more attention should be paid to conservative management to improve the clinical outcomes in various patient conditions.

FOOTNOTES

Author contributions: Hwang SM contributed to manuscript writing and editing; Lee MK contributed to data collection; Kim S contributed to conceptualization and supervision; all authors have read and approved the final manuscript.

Informed consent statement: All study participants or their legal guardian provided informed written consent about personal and medical data collection prior to study enrolment.

Conflict-of-interest statement: All the authors report no relevant conflicts of interest for this article.

CARE Checklist (2016) statement: The authors have read the CARE Checklist (2016), and the manuscript was prepared and revised according to the CARE Checklist (2016).

Open-Access: This article is an open-access article that was selected by an in-house editor and fully peer-reviewed by external reviewers. It is distributed in accordance with the Creative Commons Attribution NonCommercial (CC BY-NC 4.0) license, which permits others to distribute, remix, adapt, build upon this work non-commercially, and license their derivative works on different terms, provided the original work is properly cited and the use is non-commercial. See: <https://creativecommons.org/licenses/by-nc/4.0/>

Country/Territory of origin: South Korea

ORCID number: Seong Min Hwang 0000-0002-7983-6091; Min Kyu Lee 0000-0002-2391-2745; Saeyoung Kim 0000-0003-1650-3385.

S-Editor: Liu GL

L-Editor: A

P-Editor: Liu GL

REFERENCES

- 1 **Phan K**, Mobbs RJ. A rare case of cervical facet joint and synovial cyst at C5/C6. *J Clin Neurosci* 2016; **29**: 191-194 [PMID: 26916905 DOI: 10.1016/j.jocn.2016.01.005]
- 2 **Uschold T**, Panchmatia J, Fusco DJ, Abila AA, Porter RW, Theodore N. Subaxial cervical juxtafacet cysts: single institution surgical experience and literature review. *Acta Neurochir (Wien)* 2013; **155**: 299-308 [PMID: 23160630 DOI: 10.1007/s00701-012-1549-0]
- 3 **Cartwright MJ**, Nehls DG, Carrion CA, Spetzler RF. Synovial cyst of a cervical facet joint: case report. *Neurosurgery* 1985; **16**: 850-852 [PMID: 4010912 DOI: 10.1227/00006123-198506000-00024]
- 4 **Lyons MK**, Birch BD, Krauss WE, Patel NP, Nottmeier EW, Boucher OK. Subaxial cervical synovial cysts: report of 35 histologically confirmed surgically treated cases and review of the literature. *Spine (Phila Pa 1976)* 2011; **36**: E1285-E1289 [PMID: 21358479 DOI: 10.1097/BRS.0b013e31820709a8]

- 5 **Bydon M**, Papadimitriou K, Witham T, Wolinsky JP, Sciubba D, Gokaslan Z, Bydon A. Treatment of spinal synovial cysts. *World Neurosurg* 2013; **79**: 375-380 [PMID: [23022636](#) DOI: [10.1016/j.wneu.2012.08.016](#)]
- 6 **Schmid G**, Willburger R, Jergas M, Pennekamp W, Bickert U, Köster O. [Lumbar intraspinal juxtafacet cysts: MR imaging and CT-arthrography]. *Rofo* 2002; **174**: 1247-1252 [PMID: [12375197](#) DOI: [10.1055/s-2002-34561](#)]
- 7 **Unger R**, Bajaj PS. Poster 410 treatment of a lumbar facet joint synovial cyst using fluoroscopic guided transforaminal epidural steroid injection: A case report. *Pm & R*: S331-S331 [DOI: [10.1016/j.pmrj.2012.09.1020](#)]
- 8 **Slipman CW**, Lipetz JS, Wakeshima Y, Jackson HB. Nonsurgical treatment of zygapophyseal joint cyst-induced radicular pain. *Arch Phys Med Rehabil* 2000; **81**: 973-977 [PMID: [10896015](#) DOI: [10.1053/apmr.2000.5584](#)]
- 9 **Lee SJ**, Kim YK, Jung HS, Lim JB, Lee C. Percutaneous treatment with steroid injections and distension of facet synovial cyst-a case report. *Korean J Pain* 2005; **18**: 246-250 [DOI: [10.3344/kjp.2005.18.2.246](#)]
- 10 **Jin HS**, Bae JY, In CB, Choi EJ, Lee PB, Nahm FS. Epiduroscopic Removal of a Lumbar Facet Joint Cyst. *Korean J Pain* 2015; **28**: 275-279 [PMID: [26495082](#) DOI: [10.3344/kjp.2015.28.4.275](#)]
- 11 **Kostanian VJ**, Mathews MS. CT guided aspiration of a cervical synovial cyst. Case report and technical note. *Interv Neuroradiol* 2007; **13**: 295-298 [PMID: [20566122](#) DOI: [10.1177/159101990701300310](#)]
- 12 **Tarukado K**, Uemori T, Ueda S, Imamura T, Kaji K. Spontaneous regression of a subaxial cervical facet cyst. *Interdiscip Neurosurg* 2021; **23**: 100952 [DOI: [10.1016/j.inat.2020.100952](#)]
- 13 **Manchikanti L**, Knezevic NN, Navani A, Christo PJ, Limerick G, Calodney AK, Grider J, Harned ME, Cintron L, Gharibo CG, Shah S, Nampiaparampil DE, Candido KD, Soin A, Kaye AD, Kosanovic R, Magee TR, Beall DP, Atluri S, Gupta M, Helm Ii S, Wargo BW, Diwan S, Aydin SM, Boswell MV, Haney BW, Albers SL, Latchaw R, Abd-Elsayed A, Conn A, Hansen H, Simopoulos TT, Swicegood JR, Bryce DA, Singh V, Abdi S, Bakshi S, Buenaventura RM, Cabaret JA, Jameson J, Jha S, Kaye AM, Pasupuleti R, Rajput K, Sanapati MR, Sehgal N, Trescot AM, Racz GB, Gupta S, Sharma ML, Grami V, Parr AT, Knezevic E, Datta S, Patel KG, Tracy DH, Cordner HJ, Snook LT, Benyamin RM, Hirsch JA. Epidural Interventions in the Management of Chronic Spinal Pain: American Society of Interventional Pain Physicians (ASIPP) Comprehensive Evidence-Based Guidelines. *Pain Physician* 2021; **24**: S27-S208 [PMID: [33492918](#)]



Published by **Baishideng Publishing Group Inc**
7041 Koll Center Parkway, Suite 160, Pleasanton, CA 94566, USA

Telephone: +1-925-3991568

E-mail: bpgoffice@wjgnet.com

Help Desk: <https://www.f6publishing.com/helpdesk>

<https://www.wjgnet.com>

