

World Journal of *Clinical Cases*

World J Clin Cases 2022 November 16; 10(32): 11665-12065



Contents

Thrice Monthly Volume 10 Number 32 November 16, 2022

OPINION REVIEW

- 11665** Combined use of lactoferrin and vitamin D as a preventive and therapeutic supplement for SARS-CoV-2 infection: Current evidence

Cipriano M, Ruberti E, Tovani-Palone MR

REVIEW

- 11671** Role of adherent invasive *Escherichia coli* in pathogenesis of inflammatory bowel disease
- Zheng L, Duan SL, Dai YC, Wu SC*
- 11690** Emerging potential of ubiquitin-specific proteases and ubiquitin-specific proteases inhibitors in breast cancer treatment

Huang ML, Shen GT, Li NL

MINIREVIEWS

- 11702** Overlap of diabetic ketoacidosis and hyperosmolar hyperglycemic state
- Hassan EM, Mushtaq H, Mahmoud EE, Chhibber S, Saleem S, Issa A, Nitesh J, Jama AB, Khedr A, Boike S, Mir M, Attallah N, Surani S, Khan SA*

ORIGINAL ARTICLE

Case Control Study

- 11712** Comparing the efficacy of different dexamethasone regimens for maintenance treatment of multiple myeloma in standard-risk patients non-eligible for transplantation
- Hu SL, Liu M, Zhang JY*

Retrospective Cohort Study

- 11726** Development and validation of novel nomograms to predict survival of patients with tongue squamous cell carcinoma
- Luo XY, Zhang YM, Zhu RQ, Yang SS, Zhou LF, Zhu HY*

Retrospective Study

- 11743** Non-invasive model for predicting esophageal varices based on liver and spleen volume
- Yang LB, Zhao G, Tantai XX, Xiao CL, Qin SW, Dong L, Chang DY, Jia Y, Li H*

Clinical Trials Study

- 11753** Clinical efficacy of electromagnetic field therapy combined with traditional Chinese pain-reducing paste in myofascial pain syndrome
- Xiao J, Cao BY, Xie Z, Ji YX, Zhao XL, Yang HJ, Zhuang W, Sun HH, Liang WM*

- 11766** Endothelial injury and inflammation in patients with hyperuricemic nephropathy at chronic kidney disease stages 1-2 and 3-4

Xu L, Lu LL, Wang YT, Zhou JB, Wang CX, Xin JD, Gao JD

Observational Study

- 11775** Quality of life and symptom distress after cytoreductive surgery and hyperthermic intraperitoneal chemotherapy

Wang YF, Wang TY, Liao TT, Lin MH, Huang TH, Hsieh MC, Chen VCH, Lee LW, Huang WS, Chen CY

- 11789** Development and validation of a risk assessment model for prediabetes in China national diabetes survey

Yu LP, Dong F, Li YZ, Yang WY, Wu SN, Shan ZY, Teng WP, Zhang B

Case Control Study

- 11804** T-cell immunoglobulin mucin molecule-3, transformation growth factor β , and chemokine-12 and the prognostic status of diffuse large B-cell lymphoma

Wu H, Sun HC, Ouyang GF

META-ANALYSIS

- 11812** Prostate artery embolization on lower urinary tract symptoms related to benign prostatic hyperplasia: A systematic review and meta-analysis

Wang XY, Chai YM, Huang WH, Zhang Y

CASE REPORT

- 11827** Paraneoplastic neurological syndrome caused by cystitis glandularis: A case report and literature review

Zhao DH, Li QJ

- 11835** Neck pain and absence of cranial nerve symptom are clues of cervical myelopathy mimicking stroke: Two case reports

Zhou LL, Zhu SG, Fang Y, Huang SS, Huang JF, Hu ZD, Chen JY, Zhang X, Wang JY

- 11845** Nine-year survival of a 60-year-old woman with locally advanced pancreatic cancer under repeated open approach radiofrequency ablation: A case report

Zhang JY, Ding JM, Zhou Y, Jing X

- 11853** Laparoscopic treatment of inflammatory myofibroblastic tumor in liver: A case report

Li YY, Zang JF, Zhang C

- 11861** Survival of a patient who received extracorporeal membrane oxygenation due to postoperative myocardial infarction: A case report

Wang QQ, Jiang Y, Zhu JG, Zhang LW, Tong HJ, Shen P

- 11869** Triple hit to the kidney-dual pathological crescentic glomerulonephritis and diffuse proliferative immune complex-mediated glomerulonephritis: A case report

Ibrahim D, Brodsky SV, Satoskar AA, Biederman L, Maroz N

- 11877** Successful transcatheter arterial embolization treatment for chest wall haematoma following permanent pacemaker implantation: A case report
Zheng J, Tu XM, Gao ZY
- 11882** Brachiocephalic to left brachial vein thrombotic vasculitis accompanying mediastinal pancreatic fistula: A case report
Kokubo R, Yunaiyama D, Tajima Y, Kugai N, Okubo M, Saito K, Tsuchiya T, Itoi T
- 11889** Long survival after immunotherapy plus paclitaxel in advanced intrahepatic cholangiocarcinoma: A case report and review of literature
He MY, Yan FF, Cen KL, Shen P
- 11898** Successful treatment of pulmonary hypertension in a neonate with bronchopulmonary dysplasia: A case report and literature review
Li J, Zhao J, Yang XY, Shi J, Liu HT
- 11908** Idiopathic tenosynovitis of the wrist with multiple rice bodies: A case report and review of literature
Tian Y, Zhou HB, Yi K, Wang KJ
- 11921** Endoscopic resection of bronchial mucoepidermoid carcinoma in a young adult man: A case report and review of literature
Ding YM, Wang Q
- 11929** Blue rubber bleb nevus syndrome complicated with disseminated intravascular coagulation and intestinal obstruction: A case report
Zhai JH, Li SX, Jin G, Zhang YY, Zhong WL, Chai YF, Wang BM
- 11936** Management of symptomatic cervical facet cyst with cervical interlaminar epidural block: A case report
Hwang SM, Lee MK, Kim S
- 11942** Primary squamous cell carcinoma with sarcomatoid differentiation of the kidney associated with ureteral stone obstruction: A case report
Liu XH, Zou QM, Cao JD, Wang ZC
- 11949** Successful live birth following hysteroscopic adhesiolysis under laparoscopic observation for Asherman's syndrome: A case report
Kakinuma T, Kakinuma K, Matsuda Y, Ohwada M, Yanagida K
- 11955** What is responsible for acute myocardial infarction in combination with aplastic anemia? A case report and literature review
Zhao YN, Chen WW, Yan XY, Liu K, Liu GH, Yang P
- 11967** Repeated ventricular bigeminy by trigeminocardiac reflex despite atropine administration during superficial upper lip surgery: A case report
Cho SY, Jang BH, Jeon HJ, Kim DJ
- 11974** Testis and epididymis-unusual sites of metastatic gastric cancer: A case report and review of the literature
Ji JJ, Guan FJ, Yao Y, Sun LJ, Zhang GM

- 11980** t(4;11) translocation in hyperdiploid *de novo* adult acute myeloid leukemia: A case report
Zhang MY, Zhao Y, Zhang JH
- 11987** Sun-burn induced upper limb lymphedema 11 years following breast cancer surgery: A case report
Li M, Guo J, Zhao R, Gao JN, Li M, Wang LY
- 11993** Minimal change disease caused by polycythemia vera: A case report
Xu L, Lu LL, Gao JD
- 12000** Vitreous amyloidosis caused by a Lys55Asn variant in transthyretin: A case report
Tan Y, Tao Y, Sheng YJ, Zhang CM
- 12007** Endoscopic nasal surgery for mucocoele and pyogenic mucocoele of turbinate: Three case reports
Sun SJ, Chen AP, Wan YZ, Ji HZ
- 12015** Transcatheter arterial embolization for traumatic injury to the pharyngeal branch of the ascending pharyngeal artery: Two case reports
Yunaiyama D, Takara Y, Kobayashi T, Muraki M, Tanaka T, Okubo M, Saguchi T, Nakai M, Saito K, Tsukahara K, Ishii Y, Homma H
- 12022** Retroperitoneal leiomyoma located in the broad ligament: A case report
Zhang XS, Lin SZ, Liu YJ, Zhou L, Chen QD, Wang WQ, Li JY
- 12028** Primary testicular neuroendocrine tumor with liver lymph node metastasis: A case report and review of the literature
Xiao T, Luo LH, Guo LF, Wang LQ, Feng L
- 12036** Endodontic treatment of the maxillary first molar with palatal canal variations: A case report and review of literature
Chen K, Ran X, Wang Y
- 12045** Langerhans cell histiocytosis involving only the thymus in an adult: A case report
Li YF, Han SH, Qie P, Yin QF, Wang HE

LETTER TO THE EDITOR

- 12052** Heart failure with preserved ejection fraction: A distinct heart failure phenotype?
Triposkiadis F, Giamouzis G, Skoularigis J, Xanthopoulos A
- 12056** Insight into appropriate medication prescribing for elderly in the COVID-19 era
Omar AS, Kaddoura R
- 12059** Commentary on "Gallstone associated celiac trunk thromboembolisms complicated with splenic infarction: A case report"
Tokur O, Aydın S, Kantarci M
- 12062** Omicron targets upper airways in pediatrics, elderly and unvaccinated population
Nori W, Ghani Zghair MA

ABOUT COVER

Editorial Board Member of *World Journal of Clinical Cases*, Camelia Cristina Diaconu, FACC, FACP, FESC, MHSc, PhD, Associate Professor, Department of Internal Medicine, "Carol Davila" University of Medicine and Pharmacy, Clinical Emergency Hospital of Bucharest, Bucharest 014461, Romania. drcameliadiaconu@gmail.com

AIMS AND SCOPE

The primary aim of *World Journal of Clinical Cases* (WJCC, *World J Clin Cases*) is to provide scholars and readers from various fields of clinical medicine with a platform to publish high-quality clinical research articles and communicate their research findings online.

WJCC mainly publishes articles reporting research results and findings obtained in the field of clinical medicine and covering a wide range of topics, including case control studies, retrospective cohort studies, retrospective studies, clinical trials studies, observational studies, prospective studies, randomized controlled trials, randomized clinical trials, systematic reviews, meta-analysis, and case reports.

INDEXING/ABSTRACTING

The WJCC is now abstracted and indexed in Science Citation Index Expanded (SCIE, also known as SciSearch®), Journal Citation Reports/Science Edition, Current Contents®/Clinical Medicine, PubMed, PubMed Central, Scopus, Reference Citation Analysis, China National Knowledge Infrastructure, China Science and Technology Journal Database, and Superstar Journals Database. The 2022 Edition of Journal Citation Reports® cites the 2021 impact factor (IF) for WJCC as 1.534; IF without journal self cites: 1.491; 5-year IF: 1.599; Journal Citation Indicator: 0.28; Ranking: 135 among 172 journals in medicine, general and internal; and Quartile category: Q4. The WJCC's CiteScore for 2021 is 1.2 and Scopus CiteScore rank 2021: General Medicine is 443/826.

RESPONSIBLE EDITORS FOR THIS ISSUE

Production Editor: Hua-Ge Yin; Production Department Director: Xu Guo; Editorial Office Director: Jin-Lei Wang.

NAME OF JOURNAL

World Journal of Clinical Cases

ISSN

ISSN 2307-8960 (online)

LAUNCH DATE

April 16, 2013

FREQUENCY

Thrice Monthly

EDITORS-IN-CHIEF

Bao-Gan Peng, Jerzy Tadeusz Chudek, George Kontogeorgos, Maurizio Serati, Ja Hyeon Ku

EDITORIAL BOARD MEMBERS

<https://www.wjgnet.com/2307-8960/editorialboard.htm>

PUBLICATION DATE

November 16, 2022

COPYRIGHT

© 2022 Baishideng Publishing Group Inc

INSTRUCTIONS TO AUTHORS

<https://www.wjgnet.com/bpg/gerinfo/204>

GUIDELINES FOR ETHICS DOCUMENTS

<https://www.wjgnet.com/bpg/GerInfo/287>

GUIDELINES FOR NON-NATIVE SPEAKERS OF ENGLISH

<https://www.wjgnet.com/bpg/gerinfo/240>

PUBLICATION ETHICS

<https://www.wjgnet.com/bpg/GerInfo/288>

PUBLICATION MISCONDUCT

<https://www.wjgnet.com/bpg/gerinfo/208>

ARTICLE PROCESSING CHARGE

<https://www.wjgnet.com/bpg/gerinfo/242>

STEPS FOR SUBMITTING MANUSCRIPTS

<https://www.wjgnet.com/bpg/GerInfo/239>

ONLINE SUBMISSION

<https://www.f6publishing.com>



Successful live birth following hysteroscopic adhesiolysis under laparoscopic observation for Asherman's syndrome: A case report

Toshiyuki Kakinuma, Kaoru Kakinuma, Yoshio Matsuda, Michitaka Ohwada, Kaoru Yanagida

Specialty type: Obstetrics and gynecology

Provenance and peer review:

Unsolicited article; Externally peer reviewed.

Peer-review model: Single blind

Peer-review report's scientific quality classification

Grade A (Excellent): A
Grade B (Very good): 0
Grade C (Good): C
Grade D (Fair): 0
Grade E (Poor): 0

P-Reviewer: Aydin S, Turkey;
Peitsidis P, Greece

Received: July 13, 2022

Peer-review started: July 13, 2022

First decision: September 5, 2022

Revised: September 27, 2022

Accepted: October 9, 2022

Article in press: October 9, 2022

Published online: November 16, 2022



Toshiyuki Kakinuma, Kaoru Kakinuma, Yoshio Matsuda, Michitaka Ohwada, Kaoru Yanagida, Department of Obstetrics and Gynecology, International University of Health and Welfare Hospital, Nasushiobara-City 329-2763, Tochigi, Japan

Corresponding author: Toshiyuki Kakinuma, MD, PhD, Doctor, Department of Obstetrics and Gynecology, International University of Health and Welfare Hospital, 537-3, Iguchi, Nasushiobara-City 329-2763, Tochigi, Japan. kakinuma@iuhw.ac.jp

Abstract

BACKGROUND

Asherman's syndrome is characterized by reduced menstrual volume and adhesions within the uterine cavity and cervix, resulting in inability to carry a pregnancy to term, placental malformation, or infertility. We present the case of a 40-year-old woman diagnosed with Asherman's syndrome who successfully gave birth to a live full-term neonate after hysteroscopic adhesiolysis under laparoscopic observation, intrauterine device insertion, and Kaufmann therapy.

CASE SUMMARY

A 40-year-old woman (Gravida 3, Para 0) arrived at our hospital for specialist care to carry her pregnancy to term. She had previously undergone six sessions of dilation and curettage owing to a hydatidiform mole and persistent trophoblastic disease, followed by chemotherapy. She subsequently became pregnant twice, but both pregnancies resulted in spontaneous miscarriages during the first trimester. Her menstrual periods were very light and of short duration. Hysteroscopic adhesiolysis with concurrent laparoscopy was performed, and Asherman's syndrome was diagnosed. The uterine adhesions covered the area from the internal cervical os to the uterine fundus. Postoperative Kaufmann therapy was administered, and endometrial regeneration was confirmed using hysteroscopy. She became pregnant 9 mo postoperatively and delivered through elective cesarean section at 37 wk of gestation. The postpartum course was uneventful, and she was discharged on postoperative day 7.

CONCLUSION

Hysteroscopic adhesiolysis with concurrent laparoscopy enables identification and resection of the affected area and safe and accurate surgery, without complications.

Key Words: Hysteroscopic surgery; Laparoscopy; Intrauterine devices; Live birth;

Pregnancy; Case report

©The Author(s) 2022. Published by Baishideng Publishing Group Inc. All rights reserved.

Core Tip: Adhesion dissection under laparoscopic monitoring in Asherman's syndrome is useful not only for avoiding the risk of surgical complications such as uterine perforation, but also for intraperitoneal observation to investigate the cause of infertility. Kaufman therapy and the use of an indwelling intrauterine device were useful for preventing postoperative recurrence of intrauterine adhesions.

Citation: Kakinuma T, Kakinuma K, Matsuda Y, Ohwada M, Yanagida K. Successful live birth following hysteroscopic adhesiolysis under laparoscopic observation for Asherman's syndrome: A case report. *World J Clin Cases* 2022; 10(32): 11949-11954

URL: <https://www.wjgnet.com/2307-8960/full/v10/i32/11949.htm>

DOI: <https://dx.doi.org/10.12998/wjcc.v10.i32.11949>

INTRODUCTION

Asherman's syndrome is a condition in which mechanical damage to the endometrium or infection results in intrauterine adhesions (IUAs) and thinning of the endometrium, leading to menstrual abnormalities, such as hypomenorrhea, amenorrhea, and menstrual pain, as well as infertility due to implantation failure. Asherman's syndrome is usually characterized by light menstrual periods[1]. IUAs were first reported in 1895 by Fritsch, and the condition known as Asherman's syndrome was first described by Asherman in 1950[2,3]. In > 90% of reported cases, Asherman's syndrome develops following dilation and curettage (D&C)[4]; however, it has also been frequently reported after myomectomy, intrauterine infection, radiotherapy, and uterine arterial embolization (UAE) and is reportedly present in 4.6% of patients with infertility[5].

Hysteroscopic adhesion removal surgery is indicated to treat Asherman's syndrome if symptoms such as menstrual disorders and infertility are caused by uterine cavity adhesions. Monitoring during hysteroscopic surgery is required to reduce the risk of uterine perforation. In addition to surgery, the treatment of Asherman's syndrome involves appropriate postoperative management to prevent additional causes of infertility. Herein, we report the use of hysteroscopic adhesiolysis under laparoscopic monitoring to make intrapelvic observations and reduce the risk of intraoperative uterine perforation in a woman with Asherman's syndrome who subsequently gave birth successfully.

CASE PRESENTATION

Chief complaints

A 40-year-old gravida 3 para 0 (3020) woman presented to our hospital for specialist care with a desire to carry a pregnancy to term. She had attained menarche at 13 years of age, with a regular, 28-d menstrual cycle.

History of present illness

She had previously undergone six sessions of D&C for a hydatidiform mole and persistent trophoblastic disease, followed by chemotherapy (methotrexate). She had also become pregnant twice; however, both pregnancies ended in spontaneous miscarriages.

History of past illness

She had also become pregnant twice; however, both pregnancies ended in spontaneous miscarriages.

Personal and family history

She had attained menarche at 13 years of age, with a regular, 28-d menstrual cycle.

Physical examination

Hysteroscopic adhesiolysis with concurrent laparoscopy was performed, and Asherman's syndrome was diagnosed.

Laboratory examinations

The uterine adhesions covered the area from the internal cervical os to the uterine fundus.

Imaging examinations

Postoperative Kaufmann therapy was administered, and endometrial regeneration was confirmed using hysteroscopy.

FINAL DIAGNOSIS

Blood tests for hormones were unremarkable, and transvaginal ultrasonography showed endometrial thinning (4–5 mm) in the ovulatory and secretory phases. Hysterosalpingography was attempted; however, the hysterosalpingography catheter was dislodged, and the procedure failed. A flexible hysteroscope with a 3.8-mm-diameter tip was introduced into the cervical os. The tip was covered with white tissue through which an insertion route could not be managed, preventing the hysteroscope from advancing further. Asherman's syndrome was diagnosed based on these findings [American Fertility Society adhesion score, 8 points (moderate)]. Hysteroscopy with concurrent laparoscopy was conducted to examine the interior pelvic cavity for safe and effective adhesiolysis after obtaining written informed consent from the patient.

TREATMENT

Upon hysteroscopy, careful adhesiolysis was performed through blunt dissection with a monopolar electric scalpel, while observing the hysteroscopic illumination with the laparoscope from the abdominal cavity side. This prevented excessive uterine wall thinning (Figure 1A and B). The surgery was completed upon sufficient adhesiolysis, and both fallopian tube orifices were identifiable. The postoperative course is shown in Figure 2. An intrauterine device (IUD) was placed to prevent postoperative adhesions, and Kaufmann therapy was administered for 3 mo. Hysteroscopic examination performed 3 mo postoperatively showed no adhesion recurrence at the internal cervical os or in the uterine corpus or fundus, with definite endometrial regeneration (Figure 3A). Hysterosalpingography conducted during the same period demonstrated contrast egress toward the fimbriae of both fallopian tubes and subsequent leakage into the abdominal cavity (Figure 3B).

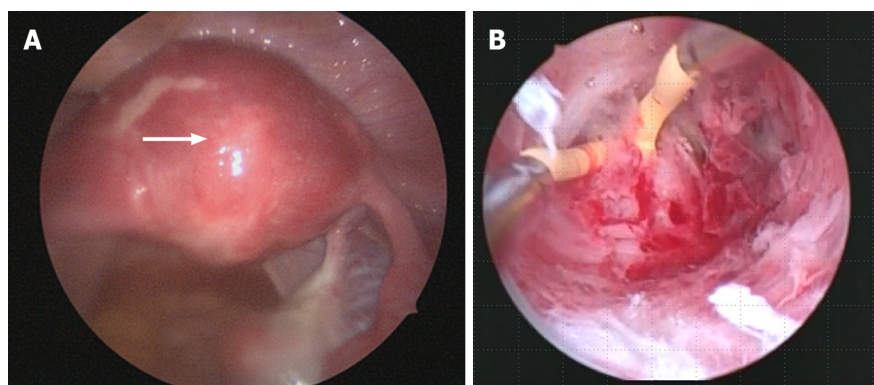
OUTCOME AND FOLLOW-UP

Postoperatively, the patient's menstruation was heavier, and the duration increased from 2 to 6 d. Following timed intercourse, she became pregnant 9 mo postoperatively. Cervical insufficiency was diagnosed at 22 wk of gestation, and a cervical cerclage (Shirodkar cerclage) was applied. The pregnancy was uneventful thereafter, and magnetic resonance imaging (MRI) performed at 34 wk of gestation showed no signs of placenta accreta or morphological abnormalities. Despite the absence of any sign of placenta accreta on diagnostic imaging, its possibility could not be excluded. Therefore, elective cesarean section was performed at 37 wk and 6 d of gestation to avoid the risk of uterine rupture. The woman delivered a live neonate weighing 2310 g with Apgar scores of 8 and 9 in the 1st and 5th minutes, respectively. The umbilical cord arterial pH was 7.25. The placenta exhibited partial adhesions (placenta increta); however, successful extrusion was achieved following blunt dissection from the muscle layer. The postpartum course was uneventful, and she was discharged on postoperative day 7.

DISCUSSION

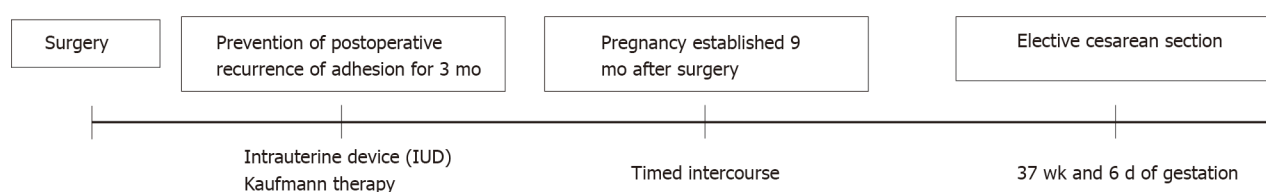
Here, we describe a case involving a 40-year-old woman with Asherman's syndrome who could conceive and successfully give birth after hysteroscopic adhesiolysis under laparoscopic monitoring. We believe that this case is unique because surgery was performed under laparoscopic monitoring. The use of a laparoscope for women with Asherman's syndrome who wish to conceive both prevents uterine perforation during surgery and allows investigation of the abdominal cavity to determine the cause of infertility during surgery. Moreover, to prevent the recurrence of adhesions, we inserted an IUD at the end of the surgery and administered Kaufmann therapy 1 mo postoperatively.

Asherman's syndrome is characterized by partial or widespread adhesions in the uterine cavity, which are associated with menstrual abnormalities, infertility, and placental abnormalities. The syndrome develops when the endometrium is damaged due to trauma or ischemia. If this damage



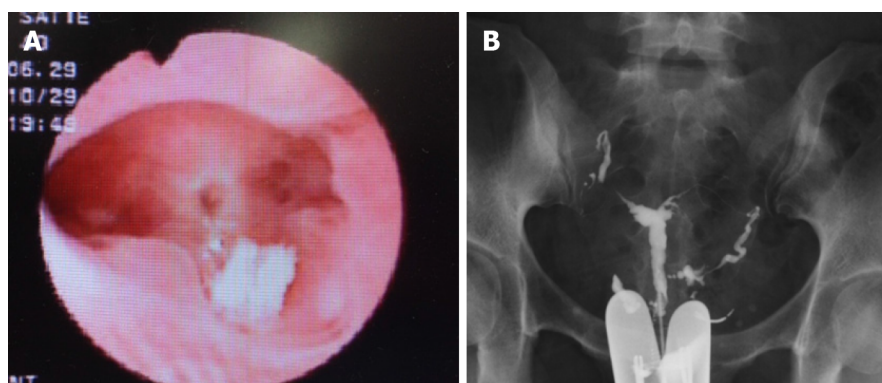
DOI: 10.12998/wjcc.v10.i32.11949 Copyright ©The Author(s) 2022.

Figure 1 Intraoperative findings. A: The hysteroscope light source was kept visible during laparoscopic observation; B: Blunt dissection of adhesion tissue was performed using a monopolar electric scalpel.



DOI: 10.12998/wjcc.v10.i32.11949 Copyright ©The Author(s) 2022.

Figure 2 Postoperative course.



DOI: 10.12998/wjcc.v10.i32.11949 Copyright ©The Author(s) 2022.

Figure 3 Postoperative findings. A: Hysteroscopy shows no intrauterine adhesions; endometrial regeneration is evident; B: Hysterosalpingography demonstrates contrast medium reaching the fimbriae of both fallopian tubes from the uterine cavity and leaking into the abdominal cavity.

extends beyond the functional layer of the endometrium into the basal layer, the endometrial epithelium cannot regenerate, and endometrial surface adhesions form. This presentation is caused by surgical abortion in many cases, although it may also develop owing to other causes, including myomectomy, intrauterine infections, radiotherapy, or UAE[5]. The absence of part or all of the endometrial tissue and the resulting IUAs prevent normal thickening of the endometrium during the menstrual cycle, causing uterine amenorrhea or uterine infertility.

In terms of its effect on pregnancy, in particular, Asherman's syndrome is responsible for high rates of infertility, miscarriage, implantation failure during assisted reproduction, and placental abnormalities [6-8]. We considered that our patient had developed severe Asherman's syndrome due to repeated D&C for a hydatidiform mole and persistent trophoblastic disease.

Surgery is indicated for treating patients with Asherman's syndrome whose IUAs are causing symptoms such as menstrual irregularities and infertility, with hysteroscopic adhesiolysis considered the gold standard treatment. IUAs have the gross appearance of white, fibrous, granulation tissue, but this appearance changes to red or pink-colored uterine muscle tissue if the hysteroscope enters the normal muscle layer; therefore, the device must be advanced cautiously when detaching the adhesions.

During the procedure, it is of paramount importance to avoid blind manipulation and to stay constantly aware of the device's orientation within the uterine cavity, using the fallopian tube orifices as a landmark, taking care not to perforate the uterus. Recent studies have reported that transabdominal ultrasonography and laparoscopy are useful for monitoring during hysteroscopic surgery[9,10]. Although laparoscopy is more surgically invasive and expensive than ultrasonography, we performed hysteroscopic adhesiolysis under laparoscopic observation to prevent complications such as endometriosis, evaluate the fallopian tubes (for patency and surrounding adhesions), and prevent the uterus from rotating. Keeping the hysteroscope's light source visible under laparoscopic observation enables safe and effective resection of IUAs.

However, adhesions commonly recur after adhesiolysis. Indeed, the more severe the adhesions, the higher the recurrence rate[1]. Therefore, care must be taken to prevent this from occurring. Methods of preventing the recurrence of adhesions include the following: (1) IUD insertion or the temporary placement of a Foley catheter within the uterus as a physical barrier to prevent contact with the damaged endometrium; (2) coating the damaged endometrium with hyaluronic acid gel or carboxymethyl cellulose as an adhesion barrier; (3) hormone therapy to promote endometrial regeneration; and (4) second-look hysteroscopy early after surgery[11-15].

For our patient, our efforts to prevent the recurrence of adhesions included IUD insertion at the end of the surgery and Kaufmann therapy which was started 1 mo postoperatively. Given that the IUD insertion should last for 3 mo, we considered that re-evaluation while the IUD was in place would be challenging; therefore, a second-look hysteroscopy was conducted 3 mo postoperatively.

The IUAs in the present case were widespread and severe. However, postoperative hysteroscopy showed that endometrial regeneration was apparent throughout the uterine cavity. Furthermore, the endometrium had thickened from 4–5 mm preoperatively to 8–9 mm postoperatively, indicating a good postoperative course.

Careful monitoring of the course of pregnancy after surgery for Asherman's syndrome is necessary. Deans *et al*[16] reviewed the data of 696 women who delivered a child after adhesiolysis. The authors found that 17 of the women exhibited placental abnormalities such as placenta accreta or placenta previa, 8 required total hysterectomy, and 2 had uterine rupture. Furthermore, the premature birth rate was 40%–50%. Guo *et al*[3] also reported higher ectopic pregnancy rates, cervical insufficiency, placenta previa, placenta accreta, premature separation of normally implanted placenta, premature rupture of membranes, stillbirth, and neonatal death in women who became pregnant after intrauterine adhesion removal, compared to the general female population[3,5]. Our patient was diagnosed with cervical insufficiency at 22 wk of gestation, and cervical cerclage was performed. Subsequently, the pregnancy was unproblematic, and MRI performed at 34 wk of gestation showed no obvious signs of placenta accreta or morphological abnormalities, such as thinning of the uterine wall. Regarding the described patient, we deliberated whether her baby should be delivered vaginally or by cesarean section. We decided to perform an elective cesarean section to ensure rapid and flexible management of placenta accreta, if present, and avoid uterine rupture. During the cesarean section, careful manual manipulation was required to detach the placenta because placental adhesions (placenta increta) were present. The manual detachment may have been more difficult after vaginal birth; therefore, a cesarean section was indeed the most appropriate option for this patient. Pregnancy and delivery outcomes post-treatment for Asherman's syndrome remain unclear, and decisions concerning the delivery method are at the individual's discretion. Further studies involving larger numbers of patients are needed to determine indicators for the methods of managing pregnancy and delivery in women with Asherman's syndrome.

CONCLUSION

We reported the treatment of a patient with Asherman's syndrome who delivered a healthy infant after hysteroscopic adhesiolysis under laparoscopic observation at our hospital. The concurrent use of laparoscopy during hysteroscopic surgery for Asherman's syndrome enabled clearer observation of the condition of the pelvic cavity and a safer procedure by the coordinated use of a hysteroscope and laparoscopy. Furthermore, measures to prevent postoperative adhesions were taken. Complications in pregnancy following surgery for Asherman's syndrome are frequent; careful perinatal management is required.

FOOTNOTES

Author contributions: Kakinuma T conceived, designed, and performed the analysis, and wrote the paper; all authors collected and contributed data/analysis tools; all authors have read and approved the final manuscript.

Informed consent statement: Informed written consent was obtained from the patient for publication of this report and any accompanying image.

Conflict-of-interest statement: All the authors declare that they have no conflict of interest to disclose.

CARE Checklist (2016) statement: The authors have read the CARE Checklist (2016), and the manuscript was prepared and revised according to the CARE Checklist (2016).

Open-Access: This article is an open-access article that was selected by an in-house editor and fully peer-reviewed by external reviewers. It is distributed in accordance with the Creative Commons Attribution NonCommercial (CC BY-NC 4.0) license, which permits others to distribute, remix, adapt, build upon this work non-commercially, and license their derivative works on different terms, provided the original work is properly cited and the use is non-commercial. See: <https://creativecommons.org/licenses/by-nc/4.0/>

Country/Territory of origin: Japan

ORCID number: Toshiyuki Kakinuma 0000-0001-7853-4860; Kaoru Kakinuma 0000-0003-4647-9582; Yoshio Matsuda 0000-0002-2890-2802; Michitaka Ohwada 0000-0002-0396-6228; Kaoru Yanagida 0000-0002-5348-3603.

S-Editor: Liu JH

L-Editor: A

P-Editor: Liu JH

REFERENCES

- 1 Hanstede M, Emanuel MH. Reproductive Outcomes of 10 Years Asherman's Surgery. *J Minim Invasive Gynecol* 2015; **22**: S14 [PMID: 27678766 DOI: 10.1016/j.jmig.2015.08.045]
- 2 Asherman JG. Traumatic intra-uterine adhesions. *J Obstet Gynaecol Br Emp* 1950; **57**: 892-896 [PMID: 14804168 DOI: 10.1111/j.1471-0528.1950.tb06053.x]
- 3 Guo EJ, Chung JPW, Poon LCY, Li TC. Reproductive outcomes after surgical treatment of asherman syndrome: A systematic review. *Best Pract Res Clin Obstet Gynaecol* 2019; **59**: 98-114 [PMID: 30713131 DOI: 10.1016/j.bpobgyn.2018.12.009]
- 4 Schenker JG, Margalioth EJ. Intrauterine adhesions: an updated appraisal. *Fertil Steril* 1982; **37**: 593-610 [PMID: 6281085 DOI: 10.1016/s0015-0282(16)46268-0]
- 5 Baradwan S, Baradwan A, Al-Jaroudi D. The association between menstrual cycle pattern and hysteroscopic march classification with endometrial thickness among infertile women with Asherman syndrome. *Medicine (Baltimore)* 2018; **97**: e11314 [PMID: 29979403 DOI: 10.1097/MD.00000000000011314]
- 6 Hanstede MMF, van der Meij E, Veersema S, Emanuel MH. Live births after Asherman syndrome treatment. *Fertil Steril* 2021; **116**: 1181-1187 [PMID: 34130799 DOI: 10.1016/j.fertnstert.2021.05.099]
- 7 Zhang Y, Zhu X, Zhang T, Zhang Y, Zhang M, Lin X. Analysis of risk factors for obstetric outcomes after hysteroscopic adhesiolysis for Asherman syndrome: A retrospective cohort study. *Int J Gynaecol Obstet* 2022; **156**: 89-94 [PMID: 33483955 DOI: 10.1002/ijgo.13616]
- 8 Wang J, Movilla P, Morales B, Wang J, Williams A, Reddy H, Chen T, Tavcar J, Morris S, Loring M, Isaacson K. Effects of Asherman Syndrome on Maternal and Neonatal Morbidity with Evaluation by Conception Method. *J Minim Invasive Gynecol* 2021; **28**: 1357-1366.e2 [PMID: 33065259 DOI: 10.1016/j.jmig.2020.10.004]
- 9 Yamamoto N, Takeuchi R, Izuchi D, Yuge N, Miyazaki M, Yasunaga M, Egashira K, Ueoka Y, Inoue Y. Hysteroscopic adhesiolysis for patients with Asherman's syndrome: menstrual and fertility outcomes. *Reprod Med Biol* 2013; **12**: 159-166 [PMID: 29662367 DOI: 10.1007/s12522-013-0149-x]
- 10 Simsir C, Var T, Namli Kalem M. Hysteroscopic treatment of Asherman's syndrome. *Cumhuriyet Med J* 2019; **41**: 443-449 [DOI: 10.7197/223.vi.579616]
- 11 Conforti A, Alviggi C, Mollo A, De Placido G, Magos A. The management of Asherman syndrome: a review of literature. *Reprod Biol Endocrinol* 2013; **11**: 118 [PMID: 24373209 DOI: 10.1186/1477-7827-11-118]
- 12 Kresowik JD, Syrop CH, Van Voorhis BJ, Ryan GL. Ultrasound is the optimal choice for guidance in difficult hysteroscopy. *Ultrasound Obstet Gynecol* 2012; **39**: 715-718 [PMID: 22173892 DOI: 10.1002/uog.11072]
- 13 Yang JH, Chen MJ, Wu MY, Chao KH, Ho HN, Yang YS. Office hysteroscopic early lysis of intrauterine adhesion after transcervical resection of multiple apposing submucous myomas. *Fertil Steril* 2008; **89**: 1254-1259 [PMID: 17686478 DOI: 10.1016/j.fertnstert.2007.05.027]
- 14 Robinson JK, Colimon LM, Isaacson KB. Postoperative adhesiolysis therapy for intrauterine adhesions (Asherman's syndrome). *Fertil Steril* 2008; **90**: 409-414 [PMID: 18571166 DOI: 10.1016/j.fertnstert.2007.06.034]
- 15 Dreisler E, Kjer JJ. Asherman's syndrome: current perspectives on diagnosis and management. *Int J Womens Health* 2019; **11**: 191-198 [PMID: 30936754 DOI: 10.2147/IJWH.S165474]
- 16 Deans R, Abbott J. Review of intrauterine adhesions. *J Minim Invasive Gynecol* 2010; **17**: 555-569 [PMID: 20656564 DOI: 10.1016/j.jmig.2010.04.016]



Published by **Baishideng Publishing Group Inc**
7041 Koll Center Parkway, Suite 160, Pleasanton, CA 94566, USA

Telephone: +1-925-3991568

E-mail: bpgoffice@wjgnet.com

Help Desk: <https://www.f6publishing.com/helpdesk>

<https://www.wjgnet.com>

