

# World Journal of *Clinical Cases*

*World J Clin Cases* 2022 November 26; 10(33): 12066-12461



## Contents

Thrice Monthly Volume 10 Number 33 November 26, 2022

## MINIREVIEWS

- 12066** Review of risk factors, clinical manifestations, rapid diagnosis, and emergency treatment of neonatal perioperative pneumothorax  
*Zhang X, Zhang N, Ren YY*

## ORIGINAL ARTICLE

## Clinical and Translational Research

- 12077** Integrative analysis of platelet-related genes for the prognosis of esophageal cancer  
*Du QC, Wang XY, Hu CK, Zhou L, Fu Z, Liu S, Wang J, Ma YY, Liu MY, Yu H*
- 12089** Comprehensive analysis of the relationship between cuproptosis-related genes and esophageal cancer prognosis  
*Xu H, Du QC, Wang XY, Zhou L, Wang J, Ma YY, Liu MY, Yu H*
- 12104** Molecular mechanisms of Baihedihuang decoction as a treatment for breast cancer related anxiety: A network pharmacology and molecular docking study  
*Li ZH, Yang GH, Wang F*
- 12116** Single-cell RNA-sequencing combined with bulk RNA-sequencing analysis of peripheral blood reveals the characteristics and key immune cell genes of ulcerative colitis  
*Dai YC, Qiao D, Fang CY, Chen QQ, Que RY, Xiao TG, Zheng L, Wang LJ, Zhang YL*

## Retrospective Study

- 12136** Diagnosis and treatment of tubal endometriosis in women undergoing laparoscopy: A case series from a single hospital  
*Jiao HN, Song W, Feng WW, Liu H*
- 12146** Different positive end expiratory pressure and tidal volume controls on lung protection and inflammatory factors during surgical anesthesia  
*Wang Y, Yang Y, Wang DM, Li J, Bao QT, Wang BB, Zhu SJ, Zou L*
- 12156** Transarterial chemoembolization combined with radiofrequency ablation in the treatment of large hepatocellular carcinoma with stage C  
*Sun SS, Li WD, Chen JL*
- 12164** Coexistence of anaplastic lymphoma kinase rearrangement in lung adenocarcinoma harbouring epidermal growth factor receptor mutation: A single-center study  
*Zhong WX, Wei XF*

**Observational Study**

- 12175** Prognostic values of optic nerve sheath diameter for comatose patients with acute stroke: An observational study

*Zhu S, Cheng C, Wang LL, Zhao DJ, Zhao YL, Liu XZ*

- 12184** Quality of care in patients with inflammatory bowel disease from a public health center in Brazil

*Takamune DM, Cury GSA, Ferrás G, Herrerias GSP, Rivera A, Barros JR, Baima JP, Saad-Hossne R, Sasaki LY*

- 12200** Comparison of the prevalence of sarcopenia in geriatric patients in Xining based on three different diagnostic criteria

*Pan SQ, Li XF, Luo MQ, Li YM*

**Prospective Study**

- 12208** Predictors of bowel damage in the long-term progression of Crohn's disease

*Fernández-Clotet A, Panés J, Ricart E, Castro-Pocheiro J, Masamunt MC, Rodríguez S, Caballol B, Ordás I, Rimola J*

**Randomized Controlled Trial**

- 12221** Protective effect of recombinant human brain natriuretic peptide against contrast-induced nephropathy in elderly acute myocardial infarction patients: A randomized controlled trial

*Zhang YJ, Yin L, Li J*

**META-ANALYSIS**

- 12230** Prognostic role of pretreatment serum ferritin concentration in lung cancer patients: A meta-analysis

*Gao Y, Ge JT*

**CASE REPORT**

- 12240** Non-surgical management of dens invaginatus type IIIB in maxillary lateral incisor with three root canals and 6-year follow-up: A case report and review of literature

*Arora S, Gill GS, Saquib SA, Saluja P, Baba SM, Khateeb SU, Abdulla AM, Bavabeedu SS, Ali ABM, Elagib MFA*

- 12247** Unusual presentation of Loeys-Dietz syndrome: A case report of clinical findings and treatment challenges

*Azrad-Daniel S, Cupa-Galvan C, Farca-Soffer S, Perez-Zincer F, Lopez-Acosta ME*

- 12257** Peroral endoscopic myotomy assisted with an elastic ring for achalasia with obvious submucosal fibrosis: A case report

*Wang BH, Li RY*

- 12261** Subclavian brachial plexus metastasis from breast cancer: A case report

*Zeng Z, Lin N, Sun LT, Chen CX*

- 12268** Case mistaken for leukemia after mRNA COVID-19 vaccine administration: A case report

*Lee SB, Park CY, Park SG, Lee HJ*

- 12278** Orthodontic-surgical treatment of an Angle Class II malocclusion patient with mandibular hypoplasia and missing maxillary first molars: A case report

*Li GF, Zhang CX, Wen J, Huang ZW, Li H*

- 12289** Multiple cranial nerve palsies with small angle exotropia following COVID-19 mRNA vaccination in an adolescent: A case report  
*Lee H, Byun JC, Kim WJ, Chang MC, Kim S*
- 12295** Surgical and nutritional interventions for endometrial receptivity: A case report and review of literature  
*Hernández-Melchor D, Palafox-Gómez C, Madrazo I, Ortiz G, Padilla-Viveros A, López-Bayghen E*
- 12305** Conversion therapy for advanced penile cancer with tislelizumab combined with chemotherapy: A case report and review of literature  
*Long XY, Zhang S, Tang LS, Li X, Liu JY*
- 12313** Endoscopic magnetic compression stricturoplasty for congenital esophageal stenosis: A case report  
*Liu SQ, Lv Y, Luo RX*
- 12319** Novel *hydroxymethylbilane synthase* gene mutation identified and confirmed in a woman with acute intermittent porphyria: A case report  
*Zhou YQ, Wang XQ, Jiang J, Huang SL, Dai ZJ, Kong QQ*
- 12328** Modified fixation for periprosthetic supracondylar femur fractures: Two case reports and review of the literature  
*Li QW, Wu B, Chen B*
- 12337** Erbium-doped yttrium aluminum garnet laser and advanced platelet-rich fibrin+ in periodontal diseases: Two case reports and review of the literature  
*Tan KS*
- 12345** Segmental artery injury during transforaminal percutaneous endoscopic lumbar discectomy: Two case reports  
*Cho WJ, Kim KW, Park HY, Kim BH, Lee JS*
- 12352** Pacemaker electrode rupture causes recurrent syncope: A case report  
*Zhu XY, Tang XH, Huang WY*
- 12358** Hybrid intercalated duct lesion of the parotid: A case report  
*Stankevicius D, Petroska D, Zaleckas L, Kutanovaite O*
- 12365** Clinical features and prognosis of multiple myeloma and orbital extramedullary disease: Seven cases report and review of literature  
*Hu WL, Song JY, Li X, Pei XJ, Zhang JJ, Shen M, Tang R, Pan ZY, Huang ZX*
- 12375** Colon mucosal injury caused by water jet malfunction during a screening colonoscopy: A case report  
*Patel P, Chen CH*
- 12380** Primary malignant pericardial mesothelioma with difficult antemortem diagnosis: A case report  
*Oka N, Orita Y, Oshita C, Nakayama H, Teragawa H*
- 12388** Typical imaging manifestation of neuronal intranuclear inclusion disease in a man with unsteady gait: A case report  
*Gao X, Shao ZD, Zhu L*

- 12395** Multimodality imaging and treatment of paranasal sinuses nuclear protein in testis carcinoma: A case report  
*Huang WP, Gao G, Qiu YK, Yang Q, Song LL, Chen Z, Gao JB, Kang L*
- 12404** T1 rectal mucinous adenocarcinoma with bilateral enlarged lateral lymph nodes and unilateral metastasis: A case report  
*Liu XW, Zhou B, Wu XY, Yu WB, Zhu RF*
- 12410** Influence of enhancing dynamic scapular recognition on shoulder disability, and pain in diabetics with frozen shoulder: A case report  
*Mohamed AA*
- 12416** Acute myocardial necrosis caused by aconitine poisoning: A case report  
*Liao YP, Shen LH, Cai LH, Chen J, Shao HQ*
- 12422** Danggui Sini decoction treatment of refractory allergic cutaneous vasculitis: A case report  
*Chen XY, Wu ZM, Wang R, Cao YH, Tao YL*
- 12430** Phlegmonous gastritis after biloma drainage: A case report and review of the literature  
*Yang KC, Kuo HY, Kang JW*
- 12440** Novel *TINF2* gene mutation in dyskeratosis congenita with extremely short telomeres: A case report  
*Picos-Cárdenas VJ, Beltrán-Ontiveros SA, Cruz-Ramos JA, Contreras-Gutiérrez JA, Arámbula-Meraz E, Angulo-Rojo C, Guadrón-Llanos AM, Leal-León EA, Cedano-Prieto DM, Meza-Espinoza JP*
- 12447** Synchronous early gastric and intestinal mucosa-associated lymphoid tissue lymphoma in a *Helicobacter pylori*-negative patient: A case report  
*Lu SN, Huang C, Li LL, Di LJ, Yao J, Tuo BG, Xie R*

**LETTER TO THE EDITOR**

- 12455** Diagnostic value of metagenomics next-generation sequencing technology in disseminated strongyloidiasis  
*Song P, Li X*
- 12458** Diagnostic value of imaging examination in autoimmune pancreatitis  
*Wang F, Peng Y, Xiao B*

**ABOUT COVER**

Editorial Board Member of *World Journal of Clinical Cases*, Cornelia Bala, MD, PhD, Professor, Department of Diabetes and Nutrition Diseases, "Iuliu Hatieganu" University of Medicine and Pharmacy, Cluj-Napoca 400006, Romania. cbala@umfcluj.ro

**AIMS AND SCOPE**

The primary aim of *World Journal of Clinical Cases* (WJCC, *World J Clin Cases*) is to provide scholars and readers from various fields of clinical medicine with a platform to publish high-quality clinical research articles and communicate their research findings online.

WJCC mainly publishes articles reporting research results and findings obtained in the field of clinical medicine and covering a wide range of topics, including case control studies, retrospective cohort studies, retrospective studies, clinical trials studies, observational studies, prospective studies, randomized controlled trials, randomized clinical trials, systematic reviews, meta-analysis, and case reports.

**INDEXING/ABSTRACTING**

The WJCC is now abstracted and indexed in Science Citation Index Expanded (SCIE, also known as SciSearch®), Journal Citation Reports/Science Edition, Current Contents®/Clinical Medicine, PubMed, PubMed Central, Scopus, Reference Citation Analysis, China National Knowledge Infrastructure, China Science and Technology Journal Database, and Superstar Journals Database. The 2022 Edition of Journal Citation Reports® cites the 2021 impact factor (IF) for WJCC as 1.534; IF without journal self cites: 1.491; 5-year IF: 1.599; Journal Citation Indicator: 0.28; Ranking: 135 among 172 journals in medicine, general and internal; and Quartile category: Q4. The WJCC's CiteScore for 2021 is 1.2 and Scopus CiteScore rank 2021: General Medicine is 443/826.

**RESPONSIBLE EDITORS FOR THIS ISSUE**

Production Editor: *Ying-Yi Yuan*; Production Department Director: *Xiang Li*; Editorial Office Director: *Jin-Lei Wang*.

**NAME OF JOURNAL**

*World Journal of Clinical Cases*

**ISSN**

ISSN 2307-8960 (online)

**LAUNCH DATE**

April 16, 2013

**FREQUENCY**

Thrice Monthly

**EDITORS-IN-CHIEF**

Bao-Gan Peng, Jerzy Tadeusz Chudek, George Kontogeorgos, Maurizio Serati, Ja Hyeon Ku

**EDITORIAL BOARD MEMBERS**

<https://www.wjgnet.com/2307-8960/editorialboard.htm>

**PUBLICATION DATE**

November 26, 2022

**COPYRIGHT**

© 2022 Baishideng Publishing Group Inc

**INSTRUCTIONS TO AUTHORS**

<https://www.wjgnet.com/bpg/gerinfo/204>

**GUIDELINES FOR ETHICS DOCUMENTS**

<https://www.wjgnet.com/bpg/GerInfo/287>

**GUIDELINES FOR NON-NATIVE SPEAKERS OF ENGLISH**

<https://www.wjgnet.com/bpg/gerinfo/240>

**PUBLICATION ETHICS**

<https://www.wjgnet.com/bpg/GerInfo/288>

**PUBLICATION MISCONDUCT**

<https://www.wjgnet.com/bpg/gerinfo/208>

**ARTICLE PROCESSING CHARGE**

<https://www.wjgnet.com/bpg/gerinfo/242>

**STEPS FOR SUBMITTING MANUSCRIPTS**

<https://www.wjgnet.com/bpg/GerInfo/239>

**ONLINE SUBMISSION**

<https://www.f6publishing.com>



## Peroral endoscopic myotomy assisted with an elastic ring for achalasia with obvious submucosal fibrosis: A case report

Bai-Hui Wang, Ru-Yuan Li

**Specialty type:** Medicine, research and experimental

**Provenance and peer review:** Unsolicited article; Externally peer reviewed.

**Peer-review model:** Single blind

**Peer-review report's scientific quality classification**

Grade A (Excellent): 0  
Grade B (Very good): 0  
Grade C (Good): C, C  
Grade D (Fair): D  
Grade E (Poor): E

**P-Reviewer:** Abe H, Japan; Hakimi T, Afghanistan; Sunjaya DB, United States; Viswanath YK, United Kingdom

**Received:** May 29, 2022

**Peer-review started:** May 29, 2022

**First decision:** June 27, 2022

**Revised:** July 18, 2022

**Accepted:** October 18, 2022

**Article in press:** October 18, 2022

**Published online:** November 26, 2022



**Bai-Hui Wang, Ru-Yuan Li,** Department of Gastroenterology, Qilu Hospital, Cheeloo College of Medicine, Qingdao 266035, Shandong Province, China

**Corresponding author:** Ru-Yuan Li, MM, Attending Doctor, Department of Gastroenterology, Qilu Hospital, Cheeloo College of Medicine, No. 758 Hefei Road, Qingdao 266035, Shandong Province, China. [liruyuan163@163.com](mailto:liruyuan163@163.com)

### Abstract

#### BACKGROUND

Peroral endoscopic myotomy (POEM) is an established treatment option for esophageal achalasia. However, technical challenges and failures exist. Submucosal fibrosis is a rare cause of aborted POEM procedures.

#### CASE SUMMARY

We performed POEM with an elastic ring for achalasia with obvious submucosal fibrosis. The short-term outcome was excellent, surgery time was significantly shorter, and success rate was higher with POEM for achalasia with obvious submucosal fibrosis.

#### CONCLUSION

POEM performed with an elastic ring is a feasible and effective endoscopic treatment modality for achalasia with obvious submucosal fibrosis.

**Key Words:** Peroral endoscopic myotomy; Elastic ring; Achalasia; Submucosal fibrosis; Case report

©The Author(s) 2022. Published by Baishideng Publishing Group Inc. All rights reserved.

**Core Tip:** Peroral endoscopic myotomy performed with an elastic ring is a feasible and effective endoscopic treatment modality for achalasia with obvious submucosal fibrosis.

**Citation:** Wang BH, Li RY. Peroral endoscopic myotomy assisted with an elastic ring for achalasia with obvious submucosal fibrosis: A case report. *World J Clin Cases* 2022; 10(33): 12257-12260

**URL:** <https://www.wjgnet.com/2307-8960/full/v10/i33/12257.htm>

**DOI:** <https://dx.doi.org/10.12998/wjcc.v10.i33.12257>

## INTRODUCTION

Submucosal fibrosis in achalasia patients is a rare cause of aborted peroral endoscopic myotomy (POEM) procedures. Implementation of new technology in achalasia is a challenge for endoscopic treatment when it comes to complex achalasia, because the dilated and tortuous esophageal lumen may make subsequent endoscopic dissection and separation of tissue planes difficult. Werner *et al*[1] reported peroral endoscopic dual myotomy (D-POEM) for achalasia with severe esophageal dilatation. Besides, he also reported open POEM (O-POEM) for achalasia with a sigmoid-shaped esophagus and achalasia with failed Heller myotomy. Wu *et al*[2] developed a modified version using a “Push and Pull” technique which reduced complications and accelerated wound recovery (Figure 1A).

## CASE PRESENTATION

### Chief complaints

A 54-year-old man who was unable to eat and drink for 1 wk presented at our hospital (Figure 1B).

### History of present illness

The patient had choking sensation for 30 years (Figure 1C).

### History of past illness

The patient had a history of ankylosing spondylitis. Physical examination on admission revealed malnutrition with a body mass index of 15.9. He had an Eckardt score of 12. A timed barium esophagram revealed that his esophagus was dilated and its lower end was narrow like a bird's beak (Figure 1D). The contrast agent was not discharged after 10 min of observation. Preoperative gastroscopy revealed significant esophageal dilation and a large amount of food residue (Figure 1E). Esophageal stenosis was observed 38 cm away from the incisors, and the cardia was 52 cm away from them. Chest computed tomography ruled out external compression. This patient had never undergone any prior endoscopic intervention (Figure 1F).

### Personal and family history

The patient's personal and family history was not remarkable.

### Physical examination

The patient was thin. Abdominal examination was normal (Figure 1G).

### Laboratory examinations

Laboratory examinations showed no abnormality.

### Imaging examinations

A timed barium esophagram revealed that the patient's esophagus was dilated and its lower end was narrow like a bird's beak. The contrast agent was not discharged after 10 min of observation (Figure 1H). Preoperative gastroscopy revealed significant esophageal dilation and a large amount of food residue. Esophageal stenosis was observed 38 cm away from the incisors, and the cardia was 52 cm away from them. Chest computed tomography ruled out external compression (Figure 1I).

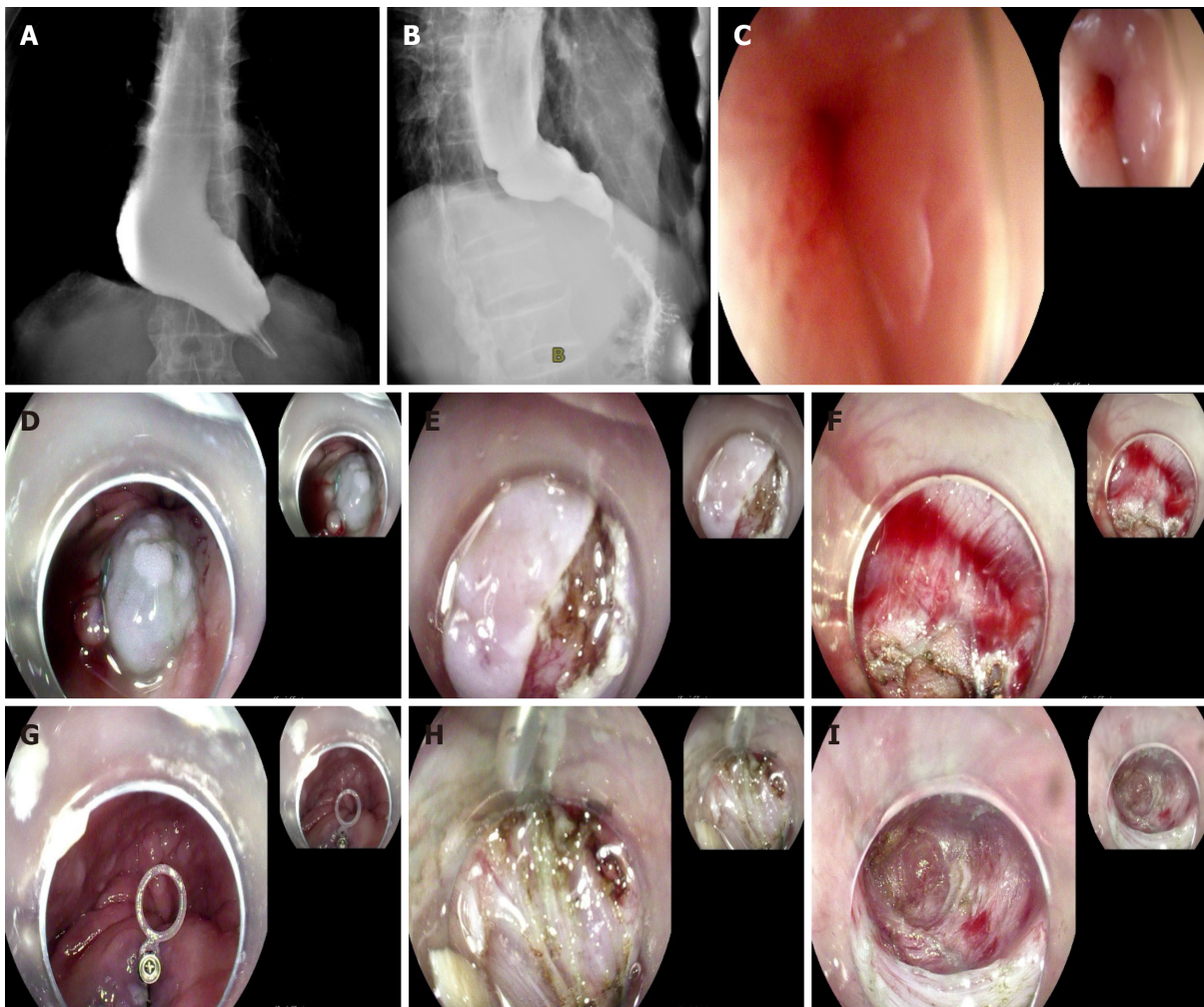
## FINAL DIAGNOSIS

The patient was diagnosed with achalasia.

## TREATMENT

Esophageal distortion was obvious in this patient, and the opening position of the tunnel was more suitable for the establishment of a complete tunnel. We used the endoscopic hood Olympus D201, and the dual knife had no water-jet function. Intraoperative submucosal injections were administered 10 cm above the cardia, resulting in a poor lift. There was obvious submucosal fibrosis. A 2-cm-long incision was made in the mucosa using the dual knife and submucosal adhesion was obvious. An elastic traction ring (patent number: ZL 2020 2 0016729.9) was used to tract the mucosa at the opening of the tunnel to the opposite side, and part of the circular muscle was cut to establish the submucosal tunnel. The elastic ring was deployed through the working channel. A clip was placed on the small ring at the initial incision site and a second clip was placed on the big ring attached to the opposing esophageal wall to





DOI: 10.12998/wjcc.v10.i33.12257 Copyright ©The Author(s) 2022.

**Figure 1 Preoperative esophagography.** A: Preoperative esophagography revealed severe esophageal dilatation and no obvious passage of barium; B: Postoperative esophagography demonstrated a rapid passage of barium from the esophagus into the stomach; C: The lamina was closed preoperatively; D: Mucosal uplift was poor after submucosal injection of 20-mL epinephrine meilan saline; E: Submucosal lift was poor after mucosal myotomy; F: Submucosal adhesion was obvious, and submucosal tunnel could not be established; G: The elastic traction ring was fixed at the tunnel opening; H: A second clip was placed to attach the ring to the opposing esophageal wall to create tension. The submucosa was exposed by means of traction of the elastic traction ring, and submucosal adhesion was obvious; I: Submucosal tunnel was established.

create tension. The tunnel was built to 2 cm below the cardia. The muscle was incised 2 cm below the tunnel opening, and full-thickness myotomy was performed from 3 cm above the cardia to 2 cm below the cardia. Lastly, we removed the titanium clip holding the traction ring opposite the tunnel opening using a pair of biopsy forceps. The operation lasted 53 min.

Postoperatively, the cardia was obviously relaxed. The patient underwent gastrointestinal decompression for 48 h and fasted for 72 h. The timed barium esophagram was repeated 4 d after the operation, and the contrast agent passed through the cardia smoothly.

## OUTCOME AND FOLLOW-UP

The symptoms of dysphagia were significantly relieved 3 wk after the operation, the Eckardt score was 2, and the patient's weight gain was 5 kg.

## DISCUSSION

Submucosal fibrosis in patients with achalasia is a rare cause of aborted POEM procedures. Over 5000 POEMs have been performed worldwide, with limited numbers of aborted procedures formally reported[1]. Zhou reported that 13 (0.77%) of 1693 POEMs (0.77%) were aborted, 12 (92.3%) of which

were due to severe submucosal fibrosis that precluded tunneling[2,3]. The implementation of new technology in achalasia is a challenge for endoscopic treatment when it comes to complex achalasia, because the dilated and tortuous esophageal lumen may render subsequent endoscopic dissection and separation of tissue planes difficult. Werner *et al*[1] reported D-POEM for achalasia with severe esophageal dilatation. Besides, he also reported O-POEM for achalasia with a sigmoid-shaped esophagus and achalasia with failed Heller myotomy. Wu *et al*[2] developed a modified version using a "Push and Pull" technique which reduced complications and accelerated wound recovery. POEM with an elastic ring helps to clarify exposure levels and facilitate tunnel construction[4].

## CONCLUSION

POEM with an elastic ring may be a feasible and effective endoscopic treatment modality for achalasia with obvious submucosal fibrosis[5-7]. We observed that the short-term outcome was excellent. This technique significantly shortened the operation time and improved the success rate of POEM for achalasia with obvious submucosal fibrosis.

## FOOTNOTES

**Author contributions:** Wang BH designed the research; Li RY performed the research.

**Informed consent statement:** Informed written consent was obtained from the patient for publication of this report and any accompanying images.

**Conflict-of-interest statement:** All authors declare that they have no conflict of interest.

**CARE Checklist (2016) statement:** All authors have read the CARE Checklist (2016), and the manuscript was prepared and revised according to the CARE Checklist (2016).

**Open-Access:** This article is an open-access article that was selected by an in-house editor and fully peer-reviewed by external reviewers. It is distributed in accordance with the Creative Commons Attribution NonCommercial (CC BY-NC 4.0) license, which permits others to distribute, remix, adapt, build upon this work non-commercially, and license their derivative works on different terms, provided the original work is properly cited and the use is non-commercial. See: <https://creativecommons.org/licenses/by-nc/4.0/>

**Country/Territory of origin:** China

**ORCID number:** Bai-Hui Wang 0000-0003-2464-3599; Ru-Yuan Li 0000-0003-0336-3221.

**S-Editor:** Wang LL

**L-Editor:** Wang TQ

**P-Editor:** Wang LL

## REFERENCES

- 1 Werner YB, Costamagna G, Swanström LL. Clinical response to peroral endoscopic myotomy in patients with idiopathic achalasia at a minimum follow-up of 2 years. *Gut* 2016; **65**: 899-906 [PMID: 25934759 DOI: 10.1136/gutjnl-2014-308649]
- 2 Wu QN, Xu XY, Zhang XC, Xu MD, Zhang YQ, Chen WF, Cai MY, Qin WZ, Hu JW, Yao LQ, Li QL, Zhou PH. Submucosal fibrosis in achalasia patients is a rare cause of aborted peroral endoscopic myotomy procedures. *Endoscopy* 2017; **49**: 736-744 [PMID: 28658680 DOI: 10.1055/s-0043-113440]
- 3 Ramchandani M, Nageshwar Reddy D, Darisetty S, Kotla R, Chavan R, Kalpala R, Galasso D, Lakhtakia S, Rao GV. Peroral endoscopic myotomy for achalasia cardia: Treatment analysis and follow up of over 200 consecutive patients at a single center. *Dig Endosc* 2016; **28**: 19-26 [PMID: 26018637 DOI: 10.1111/den.12495]
- 4 Yuan XL, Liu W, Ye LS, Yan P, Wang Y, Khan N, Hu B. Peroral endoscopic dual myotomy (dual POEM) for achalasia with severe esophageal dilatation. *Endoscopy* 2018; **50**: E179-E180 [PMID: 29742777 DOI: 10.1055/a-0603-3099]
- 5 Liu W, Liu L, Chen HL, Zeng HZ, Wu CC, Ye LS, Hu B. Open peroral endoscopic myotomy for achalasia with sigmoid-shaped esophagus. *Endoscopy* 2017; **49**: E311-E312 [PMID: 28992639 DOI: 10.1055/s-0043-119411]
- 6 Liu W, Wu CC, Hu B. Open peroral endoscopic myotomy for achalasia with failed Heller myotomy. *Dig Endosc* 2018; **30**: 268-269 [PMID: 29288508 DOI: 10.1111/den.13007]
- 7 Zhang DF, Chen WF, Xu MD, Zhong YS, Zhang YQ, Li QL, Zhou PH. Modified peroral endoscopic myotomy: a "Push and Pull" technique. *Surg Endosc* 2018; **32**: 2165-2168 [PMID: 29046961 DOI: 10.1007/s00464-017-5889-y]



Published by **Baishideng Publishing Group Inc**  
7041 Koll Center Parkway, Suite 160, Pleasanton, CA 94566, USA

**Telephone:** +1-925-3991568

**E-mail:** [bpgoffice@wjgnet.com](mailto:bpgoffice@wjgnet.com)

**Help Desk:** <https://www.f6publishing.com/helpdesk>

<https://www.wjgnet.com>

