

World Journal of *Clinical Cases*

World J Clin Cases 2022 November 26; 10(33): 12066-12461



Contents

Thrice Monthly Volume 10 Number 33 November 26, 2022

MINIREVIEWS

- 12066** Review of risk factors, clinical manifestations, rapid diagnosis, and emergency treatment of neonatal perioperative pneumothorax
Zhang X, Zhang N, Ren YY

ORIGINAL ARTICLE

Clinical and Translational Research

- 12077** Integrative analysis of platelet-related genes for the prognosis of esophageal cancer
Du QC, Wang XY, Hu CK, Zhou L, Fu Z, Liu S, Wang J, Ma YY, Liu MY, Yu H
- 12089** Comprehensive analysis of the relationship between cuproptosis-related genes and esophageal cancer prognosis
Xu H, Du QC, Wang XY, Zhou L, Wang J, Ma YY, Liu MY, Yu H
- 12104** Molecular mechanisms of Baihedihuang decoction as a treatment for breast cancer related anxiety: A network pharmacology and molecular docking study
Li ZH, Yang GH, Wang F
- 12116** Single-cell RNA-sequencing combined with bulk RNA-sequencing analysis of peripheral blood reveals the characteristics and key immune cell genes of ulcerative colitis
Dai YC, Qiao D, Fang CY, Chen QQ, Que RY, Xiao TG, Zheng L, Wang LJ, Zhang YL

Retrospective Study

- 12136** Diagnosis and treatment of tubal endometriosis in women undergoing laparoscopy: A case series from a single hospital
Jiao HN, Song W, Feng WW, Liu H
- 12146** Different positive end expiratory pressure and tidal volume controls on lung protection and inflammatory factors during surgical anesthesia
Wang Y, Yang Y, Wang DM, Li J, Bao QT, Wang BB, Zhu SJ, Zou L
- 12156** Transarterial chemoembolization combined with radiofrequency ablation in the treatment of large hepatocellular carcinoma with stage C
Sun SS, Li WD, Chen JL
- 12164** Coexistence of anaplastic lymphoma kinase rearrangement in lung adenocarcinoma harbouring epidermal growth factor receptor mutation: A single-center study
Zhong WX, Wei XF

Observational Study

- 12175** Prognostic values of optic nerve sheath diameter for comatose patients with acute stroke: An observational study

Zhu S, Cheng C, Wang LL, Zhao DJ, Zhao YL, Liu XZ

- 12184** Quality of care in patients with inflammatory bowel disease from a public health center in Brazil

Takamune DM, Cury GSA, Ferrás G, Herrerias GSP, Rivera A, Barros JR, Baima JP, Saad-Hossne R, Sasaki LY

- 12200** Comparison of the prevalence of sarcopenia in geriatric patients in Xining based on three different diagnostic criteria

Pan SQ, Li XF, Luo MQ, Li YM

Prospective Study

- 12208** Predictors of bowel damage in the long-term progression of Crohn's disease

Fernández-Clotet A, Panés J, Ricart E, Castro-Pocheiro J, Masamunt MC, Rodríguez S, Caballol B, Ordás I, Rimola J

Randomized Controlled Trial

- 12221** Protective effect of recombinant human brain natriuretic peptide against contrast-induced nephropathy in elderly acute myocardial infarction patients: A randomized controlled trial

Zhang YJ, Yin L, Li J

META-ANALYSIS

- 12230** Prognostic role of pretreatment serum ferritin concentration in lung cancer patients: A meta-analysis

Gao Y, Ge JT

CASE REPORT

- 12240** Non-surgical management of dens invaginatus type IIIB in maxillary lateral incisor with three root canals and 6-year follow-up: A case report and review of literature

Arora S, Gill GS, Saquib SA, Saluja P, Baba SM, Khateeb SU, Abdulla AM, Bavabeedu SS, Ali ABM, Elagib MFA

- 12247** Unusual presentation of Loeys-Dietz syndrome: A case report of clinical findings and treatment challenges

Azrad-Daniel S, Cupa-Galvan C, Farca-Soffer S, Perez-Zincer F, Lopez-Acosta ME

- 12257** Peroral endoscopic myotomy assisted with an elastic ring for achalasia with obvious submucosal fibrosis: A case report

Wang BH, Li RY

- 12261** Subclavian brachial plexus metastasis from breast cancer: A case report

Zeng Z, Lin N, Sun LT, Chen CX

- 12268** Case mistaken for leukemia after mRNA COVID-19 vaccine administration: A case report

Lee SB, Park CY, Park SG, Lee HJ

- 12278** Orthodontic-surgical treatment of an Angle Class II malocclusion patient with mandibular hypoplasia and missing maxillary first molars: A case report

Li GF, Zhang CX, Wen J, Huang ZW, Li H

- 12289** Multiple cranial nerve palsies with small angle exotropia following COVID-19 mRNA vaccination in an adolescent: A case report
Lee H, Byun JC, Kim WJ, Chang MC, Kim S
- 12295** Surgical and nutritional interventions for endometrial receptivity: A case report and review of literature
Hernández-Melchor D, Palafox-Gómez C, Madrazo I, Ortiz G, Padilla-Viveros A, López-Bayghen E
- 12305** Conversion therapy for advanced penile cancer with tislelizumab combined with chemotherapy: A case report and review of literature
Long XY, Zhang S, Tang LS, Li X, Liu JY
- 12313** Endoscopic magnetic compression stricturoplasty for congenital esophageal stenosis: A case report
Liu SQ, Lv Y, Luo RX
- 12319** Novel *hydroxymethylbilane synthase* gene mutation identified and confirmed in a woman with acute intermittent porphyria: A case report
Zhou YQ, Wang XQ, Jiang J, Huang SL, Dai ZJ, Kong QQ
- 12328** Modified fixation for periprosthetic supracondylar femur fractures: Two case reports and review of the literature
Li QW, Wu B, Chen B
- 12337** Erbium-doped yttrium aluminum garnet laser and advanced platelet-rich fibrin+ in periodontal diseases: Two case reports and review of the literature
Tan KS
- 12345** Segmental artery injury during transforaminal percutaneous endoscopic lumbar discectomy: Two case reports
Cho WJ, Kim KW, Park HY, Kim BH, Lee JS
- 12352** Pacemaker electrode rupture causes recurrent syncope: A case report
Zhu XY, Tang XH, Huang WY
- 12358** Hybrid intercalated duct lesion of the parotid: A case report
Stankevicius D, Petroska D, Zaleckas L, Kutanovaite O
- 12365** Clinical features and prognosis of multiple myeloma and orbital extramedullary disease: Seven cases report and review of literature
Hu WL, Song JY, Li X, Pei XJ, Zhang JJ, Shen M, Tang R, Pan ZY, Huang ZX
- 12375** Colon mucosal injury caused by water jet malfunction during a screening colonoscopy: A case report
Patel P, Chen CH
- 12380** Primary malignant pericardial mesothelioma with difficult antemortem diagnosis: A case report
Oka N, Orita Y, Oshita C, Nakayama H, Teragawa H
- 12388** Typical imaging manifestation of neuronal intranuclear inclusion disease in a man with unsteady gait: A case report
Gao X, Shao ZD, Zhu L

- 12395** Multimodality imaging and treatment of paranasal sinuses nuclear protein in testis carcinoma: A case report
Huang WP, Gao G, Qiu YK, Yang Q, Song LL, Chen Z, Gao JB, Kang L
- 12404** T1 rectal mucinous adenocarcinoma with bilateral enlarged lateral lymph nodes and unilateral metastasis: A case report
Liu XW, Zhou B, Wu XY, Yu WB, Zhu RF
- 12410** Influence of enhancing dynamic scapular recognition on shoulder disability, and pain in diabetics with frozen shoulder: A case report
Mohamed AA
- 12416** Acute myocardial necrosis caused by aconitine poisoning: A case report
Liao YP, Shen LH, Cai LH, Chen J, Shao HQ
- 12422** Danggui Sini decoction treatment of refractory allergic cutaneous vasculitis: A case report
Chen XY, Wu ZM, Wang R, Cao YH, Tao YL
- 12430** Phlegmonous gastritis after biloma drainage: A case report and review of the literature
Yang KC, Kuo HY, Kang JW
- 12440** Novel *TINF2* gene mutation in dyskeratosis congenita with extremely short telomeres: A case report
Picos-Cárdenas VJ, Beltrán-Ontiveros SA, Cruz-Ramos JA, Contreras-Gutiérrez JA, Arámbula-Meraz E, Angulo-Rojo C, Guadrón-Llanos AM, Leal-León EA, Cedano-Prieto DM, Meza-Espinoza JP
- 12447** Synchronous early gastric and intestinal mucosa-associated lymphoid tissue lymphoma in a *Helicobacter pylori*-negative patient: A case report
Lu SN, Huang C, Li LL, Di LJ, Yao J, Tuo BG, Xie R

LETTER TO THE EDITOR

- 12455** Diagnostic value of metagenomics next-generation sequencing technology in disseminated strongyloidiasis
Song P, Li X
- 12458** Diagnostic value of imaging examination in autoimmune pancreatitis
Wang F, Peng Y, Xiao B

ABOUT COVER

Editorial Board Member of *World Journal of Clinical Cases*, Cornelia Bala, MD, PhD, Professor, Department of Diabetes and Nutrition Diseases, "Iuliu Hatieganu" University of Medicine and Pharmacy, Cluj-Napoca 400006, Romania. cbala@umfcluj.ro

AIMS AND SCOPE

The primary aim of *World Journal of Clinical Cases* (WJCC, *World J Clin Cases*) is to provide scholars and readers from various fields of clinical medicine with a platform to publish high-quality clinical research articles and communicate their research findings online.

WJCC mainly publishes articles reporting research results and findings obtained in the field of clinical medicine and covering a wide range of topics, including case control studies, retrospective cohort studies, retrospective studies, clinical trials studies, observational studies, prospective studies, randomized controlled trials, randomized clinical trials, systematic reviews, meta-analysis, and case reports.

INDEXING/ABSTRACTING

The WJCC is now abstracted and indexed in Science Citation Index Expanded (SCIE, also known as SciSearch®), Journal Citation Reports/Science Edition, Current Contents®/Clinical Medicine, PubMed, PubMed Central, Scopus, Reference Citation Analysis, China National Knowledge Infrastructure, China Science and Technology Journal Database, and Superstar Journals Database. The 2022 Edition of Journal Citation Reports® cites the 2021 impact factor (IF) for WJCC as 1.534; IF without journal self cites: 1.491; 5-year IF: 1.599; Journal Citation Indicator: 0.28; Ranking: 135 among 172 journals in medicine, general and internal; and Quartile category: Q4. The WJCC's CiteScore for 2021 is 1.2 and Scopus CiteScore rank 2021: General Medicine is 443/826.

RESPONSIBLE EDITORS FOR THIS ISSUE

Production Editor: *Ying-Yi Yuan*; Production Department Director: *Xiang Li*; Editorial Office Director: *Jin-Lei Wang*.

NAME OF JOURNAL

World Journal of Clinical Cases

ISSN

ISSN 2307-8960 (online)

LAUNCH DATE

April 16, 2013

FREQUENCY

Thrice Monthly

EDITORS-IN-CHIEF

Bao-Gan Peng, Jerzy Tadeusz Chudek, George Kontogeorgos, Maurizio Serati, Ja Hyeon Ku

EDITORIAL BOARD MEMBERS

<https://www.wjgnet.com/2307-8960/editorialboard.htm>

PUBLICATION DATE

November 26, 2022

COPYRIGHT

© 2022 Baishideng Publishing Group Inc

INSTRUCTIONS TO AUTHORS

<https://www.wjgnet.com/bpg/gerinfo/204>

GUIDELINES FOR ETHICS DOCUMENTS

<https://www.wjgnet.com/bpg/GerInfo/287>

GUIDELINES FOR NON-NATIVE SPEAKERS OF ENGLISH

<https://www.wjgnet.com/bpg/gerinfo/240>

PUBLICATION ETHICS

<https://www.wjgnet.com/bpg/GerInfo/288>

PUBLICATION MISCONDUCT

<https://www.wjgnet.com/bpg/gerinfo/208>

ARTICLE PROCESSING CHARGE

<https://www.wjgnet.com/bpg/gerinfo/242>

STEPS FOR SUBMITTING MANUSCRIPTS

<https://www.wjgnet.com/bpg/GerInfo/239>

ONLINE SUBMISSION

<https://www.f6publishing.com>



Surgical and nutritional interventions for endometrial receptivity: A case report and review of literature

Dinorah Hernández-Melchor, Cecilia Palafox-Gómez, Ivan Madrazo, Ginna Ortiz, America Padilla-Viveros, Esther López-Bayghen

Specialty type: Reproductive biology

Provenance and peer review:

Unsolicited article; Externally peer reviewed.

Peer-review model: Single blind

Peer-review report's scientific quality classification

Grade A (Excellent): 0

Grade B (Very good): B

Grade C (Good): C

Grade D (Fair): 0

Grade E (Poor): 0

P-Reviewer: Elfayoumy KN, Egypt; Shuang W, China

Received: June 20, 2022

Peer-review started: June 20, 2022

First decision: August 4, 2022

Revised: August 16, 2022

Accepted: October 17, 2022

Article in press: October 17, 2022

Published online: November 26, 2022



Dinorah Hernández-Melchor, America Padilla-Viveros, Science, Technology and Society Program, Centro de Investigación y de Estudios Avanzados del Instituto Politécnico Nacional, México City 07360, CDMX, México

Dinorah Hernández-Melchor, Clinical Research, Instituto Regenera SC, México City 05320, CDMX, México

Cecilia Palafox-Gómez, Departamento de Toxicología, Centro de Investigación y de Estudios Avanzados del Instituto Politécnico Nacional, México City 07360, CDMX, México

Ivan Madrazo, Ginna Ortiz, Investigación Clínica, Instituto de Infertilidad y Genética México SC, INGENES, México City 05320, CDMX, México

Esther López-Bayghen, Departamento de Toxicología, Centro de Investigación y de Estudios Avanzados del Instituto Politécnico Nacional, México City 07360, CDMX, México

Corresponding author: Esther López-Bayghen, MSc, PhD, Academic Research, Departamento de Toxicología, Centro de Investigación y de Estudios Avanzados del Instituto Politécnico Nacional, Avenida Instituto Politécnico Nacional 2508, San Pedro Zacatenco, México City 07360, CDMX, México. ebayghen@cinvestav.mx

Abstract

BACKGROUND

Polycystic ovary syndrome (PCOS) is an endocrine disease that combines metabolic, reproductive, and psychological dysfunctions. Ovulation disorders and impaired endometrial receptivity in PCOS can cause infertility. Insulin resistance (IR) is a pathological state of inadequate response to insulin that affects reproduction in PCOS, as damage caused by IR at the endometrial level becomes an obstacle for embryo implantation. Reversing IR resulted in spontaneous pregnancies in PCOS patients, indicating that metabolic corrections improve endometrial dysfunctions. Mesenchymal stem-cell treatment has also corrected endometrial quality and lead to pregnancies in patients with Asherman's syndrome. We propose a combination of nutritional intervention with the surgical placement of stem cells to improve endometrial quality to achieve pregnancy in a PCOS patient undergoing *in vitro* fertilization (IVF) treatment.

CASE SUMMARY

After two failed IVF cycles, a metabolic intervention, consisting of a ketogenic diet

with daily consumption of 50 g of carbohydrates (CH), was indicated until pregnancy. Metabolic Syndrome was assessed using the Harmonizing Definition (3 of 5 pathologies: Central obesity, hypertension, hyperglycemia, hypertriglyceridemia, and dyslipidemia), and the Homeostatic Model Assessment of IR (HOMA-IR) was used to measure the level of IR. Once IR improved, endometrial quality improved. However, two day 5-thawed embryos (euploid, donated oocyte-partner's sperm) failed to implant, suggesting endometrial quality improvement was insufficient. Therefore, transmyometrial implantation of mesenchymal stem cells from the stromal vascular fraction of adipose tissue was performed to enrich the endometrial stem cell niche. Minimal endometrial mean thickness for embryo transfer (6.9 mm) was achieved three months after stem cell treatment and continuous dietary control of IR. Two euploid-day 5-thawed embryos (donated oocyte-partner's sperm) were transferred, and embryo implantation was confirmed on day 14 by β -hCG serum levels. Currently, a 37 wk baby girl is born.

CONCLUSION

In PCOS, endometrial quality can be improved by combining nutrient-based metabolic correction with endometrial stem cell niche enrichment.

Key Words: Polycystic ovarian syndrome; Insulin resistance; Nutritional intervention; Endometrial quality; Stem cell treatment; Case report

©The Author(s) 2022. Published by Baishideng Publishing Group Inc. All rights reserved.

Core Tip: Polycystic ovary syndrome (PCOS) is an endocrine disease that causes infertility due to ovulation disorders and impaired endometrial receptivity related to a pathological state of insulin resistance (IR). To date, endometrial dysfunctions are the rate-limiting factor for pregnancy in PCOS patients using *in vitro* fertilization. Here, an overweight PCOS patient with euploid embryos available for transfer achieved pregnancy only after a continuous nutritional intervention to correct IR and metabolic parameters and the enrichment of endometrial stem cell niche with mesenchymal stem cells from adipose tissue. In this case, endometrial thickness and receptivity were improved with a combination of nutritional and surgical interventions to achieve pregnancy.

Citation: Hernández-Melchor D, Palafox-Gómez C, Madrazo I, Ortiz G, Padilla-Viveros A, López-Bayghen E. Surgical and nutritional interventions for endometrial receptivity: A case report and review of literature. *World J Clin Cases* 2022; 10(33): 12295-12304

URL: <https://www.wjgnet.com/2307-8960/full/v10/i33/12295.htm>

DOI: <https://dx.doi.org/10.12998/wjcc.v10.i33.12295>

INTRODUCTION

Polycystic ovary syndrome (PCOS) is a complicated endocrine disease that combines metabolic, reproductive, and psychological dysfunctions. Ovulation disorders are causes of PCOS-related infertility[1]. In addition, alterations in the ability of the endometrium to accept an implanting embryo and a blastocyst's entry (endometrial receptivity) are critical factors of PCOS-related infertility[2,3]. Numerous studies have proved that hormonal disturbances and metabolic changes in PCOS patients could influence endometrial receptivity[4,5]. Insulin resistance (IR) refers to the complicated pathological state of inadequate insulin action. During *in vitro* fertilization (IVF) with oocytes from IR-PCOS patients, embryo development and quality were not affected after *in vitro* culture; however, the pregnancy rate for these patients was significantly reduced, suggesting that one of influences of decreased success is caused by compromised endometrium function due to IR-associated damage[6,7]. Some treatments to correct ovulatory issues in PCOS, which resulted in reversing IR, lead to a surge of spontaneous pregnancies[8]; however, these treatments are not well explored in combination with IVF. Moreover, little attention has been paid to the exact changes in the endometrium after metabolic correction, even though the PCOS-endometrium effect may need more robust approaches to achieve implantation and pregnancy[9].

Stem cells are a powerful tool to respond to the needs of modern medicine, given their high potential in therapeutic applications[10]. Adipose tissue has become a convenient source for stem cell extraction after lipo-aspiration under local anesthesia, yielding significant quantities with a minimum invasive technique, low risk of morbidity, minimal discomfort, and almost zero chance for other possible complications[11]. Adipose-derived mesenchymal stem cells (ADMSC) have prolonged self-renewal

ability and the capability to differentiate into various mature somatic lineages[12]. In addition, ADMSC possesses neovascularization, immune-modulating, and anti-inflammatory properties[13]. The Stromal Vascular Fraction (SVF) is the minimum manipulated heterogeneous cell population isolated from the adipose tissue with comparable regenerative potential as cultured ADMSC. SVF contains ADMSC, endothelial precursors, T-regulatory and smooth muscle cells, macrophages, pericytes, and preadipocytes[14]. Endometrial mesenchymal stem cells (EnMSCs) are adult stem cells, similar to those found in other tissue. This endometrial niche can be colonized by autologous stem cells derived from different tissues[15]. In addition, stem cell transplantation can activate endogenous endometrial stem/progenitor cells inside the uterine cavity at the sub-endometrial zone in the junction between myometrium and endometrium. In patients with Asherman's syndrome, endometrial regeneration occurs as the EnMSCs can replace the functional layer[16], correcting the endometrium to achieve a clinical pregnancy[16,17]. Therefore, we propose a combination of a continuous nutritional intervention consisting of a well-designed ketogenic diet with daily consumption of 50 g of carbohydrates (CHO) to improve IR and the surgical placement of stem cells from SVF to improve endometrial quality and achieve pregnancy in a PCOS patient.

CASE PRESENTATION

Chief complaints

A 37-year-old woman attended the Ingenes institute in México city for secondary infertility with one previous abortion in 2008 at 11 wk of gestation.

History of present illness

The patient and her current partner had been trying to conceive a pregnancy for two years, with 1 previous attempt in which the embryo implanted but resulted in an early abortion. Her periods are normal, and she does not remember any problems with her cycle. The patient was diagnosed with PCOS according to Rotterdam criteria, presenting signs of clinical hyperandrogenism (acne and hirsutism) and the polycystic ovary phenotype, which was confirmed with ultrasound (30-40 follicles in each ovary). She was counseled for IVF.

History of past illness

There is no relevant history of past illness.

Personal and family history

The patient has had a previously failed pregnancy, which resulted in an early abortion, in 2008. Moreover, the patient had uterine synechiae in 2019, which was resolved by hysteroscopic adhesiolysis. She has no other medical history associated with reproduction and no history of alcohol or drug abuse. There was no significant history reported by the partner. Lastly, there was no relevant family history of reproductive complications.

Physical examination

Upon physical examination, the patient did not present any concerning symptoms. The patient's initial body-mass index (BMI) was 29.24 kg/m². The anthropometric parameters are shown in Table 1. Due to the patient's weight and BMI, it was postulated that the patient has Metabolic Syndrome (MetS). Her waist circumference was elevated (> 80 cm for female Latinas) [18]. She was overweight and had at least one criteria of Metabolic Syndrome, according to the harmonizing definition.

Laboratory examinations

Laboratory examinations were performed to assess the patient's metabolic status with respect to the MetS harmonized definition[18]. On initial evaluation, the patient's fasting plasma glucose suggests that she is at risk for prediabetes. Two of five criteria were abnormal for MetS (waist circumference and fasting plasma glucose); systolic and diastolic blood pressure, tryglycerides, and high-density lipoprotein cholesterol (HDL-C) levels were normal. Values are presented as Biochemical parameters in Table 1.

Imaging examinations

Due to the patient's previous abortion and uterine synechiae, a sonohysterography was performed. There were no uterine synechiae or other issues associated with the uterus. However, more than 30 follicles on each ovary were detected by ultrasound (PCOS criteria).

Table 1 Cycles and interventions for the case

Categories	First cycle	Second cycle	Third cycle	Fourth cycle
Nutritional intervention	None	Caloric restriction ^a	Ketogenic diet ^b	Ketogenic diet ^c
Stem cell treatment	None	None	None	Live cells trans-myometrial injection
Anthropometric parameters (at the cycle starting point)				
Age (years)	37 (2019)	38 (2020)	39 (2021)	40 (2021)
Weight (kg)	73	69	59	59
Waist circumference (cm)	81	73	65	65
BMI (kg/m ²)	29.24	27.64	23.63	23.63
Blood pressure (mmHg)	120/80	120/78	119/80	111/74
Biochemical parameters				
Fasting glucose (mg/dL)	104	102	86	78
Urine ketones (mg/dL)	-	Negative	40-80	50
Insulin (U/mL)	-	13.89	3.20	2.4
HOMA-IR	-	2.95	0.67	0.46
Insulin resistance	-	Yes	Corrected	Corrected
Triglycerides (mg/dL)	-	89	92	82
HDL-Cholesterol (mg/dL)	-	58	62	71
IVF parameters				
Ova source	Patient	Patient	Donor	Donor
Ova collected	26	15	Not applicable	Not applicable
Own embryos frozen (day), quality	7 (day 5), BC	1 (day 5), BC 1 (day 6), BC	---	---
Endometrial intervention/treatment	None	Hysteroscopic evaluation and mild reactivation	Pentoxifylline E-Vitamin L-Arginine	Pentoxifylline E-Vitamin L-Arginine
Stem cells				
Endometrial thickness final size (mm)	3.6	4.3	5.9	6.9
Transferred thawed embryos and PGTA result	<i>n</i> = 2 Quality: BC Day 5: Euploid	<i>n</i> = 2 Quality: BC Day 5 and 6: Euploid	<i>n</i> = 2 Quality: AC and BC Day 5: Euploid	<i>n</i> = 2 Quality: AC and BC Day 5: Euploid
Transfer result	Failed	Failed	Failed	Success
β-hCG serum levels on day 14	Negative	Negative	Negative	Positive, 90.89 mUI/mL
Clinical pregnancy	-	-	-	One sac, 158 bpm week 18
Pregnancy outcome	-	-	-	Healthy baby girl, 37 wk, 2690 g; 47 cm; Apgar 9

^aStandard 1800 calorie-diet with 55% carbohydrate content.^bNutritional intervention inducing ketosis with a maximal consumption of 50 g of carbohydrates/day (15% on an 1800 calorie diet).^cNI controlling fasting glucose and urine ketones; carbohydrates/d: 50 g before the transfer, 100 g after embryo transfer, and 150 g during pregnancy.

MULTIDISCIPLINARY EXPERT CONSULTATION

There is no multidisciplinary expert consultation.

FINAL DIAGNOSIS

At the initial consultation, infertility associated with PCOS was diagnosed with IR.

TREATMENT

First IVF attempt

In 2019, the patient underwent standard controlled ovarian stimulation (Gonal 150 UI and Merapur 150 UI). The stimulus was prolonged until the diameter of the leading follicles was > 18 mm. Afterward, recombinant human chorionic gonadotropin was administered. After 36 h, the oocytes were retrieved with ultrasound guidance. All 14-18 mm follicles were aspirated. Ova was collected, fertilized by intracytoplasmic sperm injection with the partner's sperm, and then cultured. The yields and quality of embryos are depicted in Table 1. Embryos were cryopreserved using the vitrification technique, thawed, and transferred after standard endometrial preparation. Two embryos were transferred. The endometrial mean thickness (EMT) was sub-optimal, and a thin endometrium was diagnosed (EMT = 3.6 mm). On day 14, there was no detectable amount of β -hCG.

Second IVF attempt

As the patient was overweight and following an unbalanced standard American 2000 calories diet with 45% CHO, 47% fat, and 7% protein content (direct food intake questionnaire), a caloric restriction diet (averaging a total of approximately 1800 calories) was advised with macronutrients adjustment to 55% CHO, 25% protein and 25% fat. This resulted in a 4-kg weight loss but not a BMI reduction to normal weight status. The standard controlled ovarian stimulation protocol was repeated as before. Hysteroscopy was performed because of the thin endometrium diagnosis (EMT=3.6 mm). Again, we ruled out synechiae and found a normal cervical channel, normal uterine cavity, and a visible and permeable ostium; no other abnormalities were found. Gentle endometrial reactivation was performed. Endometrial preparation was carried out using primogyn (estradiol valerate) with incremental dosing for 12 d (2 mg/d for four days, 4 mg/d for four days, and 6 mg/d for four days)[19]. Luteal phase support was carried out with utrogestan (300 mg/vaginal, three times a day). Two cryopreserved embryos were thawed and transferred. On day 14, there was no detectable amount of β -hCG.

Third attempt at IVF

Because the patient's initial BMI was 29.24 kg/m² and PCOS diagnosis, metabolic parameters were assessed (Table 1). Triglycerides and HDL-C were within the normal range. Fasting glucose was above the normal range, suggesting the patient was prediabetic. In addition, IR was calculated using HOMA-IR (Table 1). The patient had significant IR. A nutritional intervention was started to correct for IR, with a secondary goal to increase endometrium and ova quality. The patient was instructed to follow a ketogenic diet, which typical consists of 1800 calories/day, daily consumption of ≤ 50 g of total CHO (15% or less), 1.5 g of protein per kilogram of body weight (25% maximum), with the remainder being fat (approximately 60%). The patient auto-registered all food consumption in the MyFitnessPal app, and the dietician confirmed the macros every week, correcting them when needed. In addition, the patient received nutritional education (video) that focused on controlling the glucose load. The purpose was to teach food choices and avoid ultra-processed food, starches, juices, bread, sweets, sugared beverages, and CHO-rich food (rice, beans, tortilla, legumes). The patient was followed *via* electronic messaging every two to three days, inquiring about any doubts, symptoms, changes in weight, fasting glucose, ketone detection in urine, and counseling about the general guidelines. Before the start and during all nutritional interventions, the patient auto-monitored their urinary ketone levels using the Ketone Test Strips (acetoacetate), measuring at least twice a week with MUNDO-Keto reactive strips. Once, laboratory tests confirmation of improve IR and with the patient's approval, the physician and the specialist in Reproductive Medicine moved to ova donation. Donated oocytes were fertilized by ICSI with the partner's sperm, which produced four embryos (two day 5 and two day 6 embryos). Before all embryos were vitrified, Preimplantation Genetic Testing for Aneuploidies (PGT-A) was performed following a standardized protocol[20]. Endometrial preparation consisted of Primogyn (same as described before) while adding 400 mg of Pentoxifylline twice a day, 1 g of L-Arginine (vasodilator), and 1 g of Vitamin E daily (vascular and antioxidant effects), which improved the EMT (Table 1). Embryo transfer was performed with one embryo AC and one embryo BC. Both embryos failed to implant.

Fourth IVF attempt

Autologous mesenchymal stem cells in the SVF of adipose tissue were placed in the patient's uterine cavity to improve endometrial quality. Micro liposuction was performed to obtain 20 mL of abdominal fat. Adipose tissue was washed, mechanically disaggregated, and treated with collagenase type I to isolate SVF. A total of 6.27×10^7 live cells were isolated and transmyometrial injected. Changes in the

EMT were monitored for three months until an EMT of 6.9 mm was reached. Two Day 5, euploid-thawed embryos (from oocyte donor and partner's sperm) were transferred. The uterine transfers occurred during a controlled endometrial development cycle for frozen embryos, free of gonadotropin stimulation, but with the addition of Pentoxifylline, L-Arginine, and E-Vitamin (same as described before). The ketogenic intervention was sustained until pregnancy was achieved. Embryo implantation was determined on day 14 by serum β -hCG concentrations (>10 mUI/mL) and by the presence of a fetal heartbeat using ultrasound at six weeks (Table 1).

OUTCOME AND FOLLOW-UP

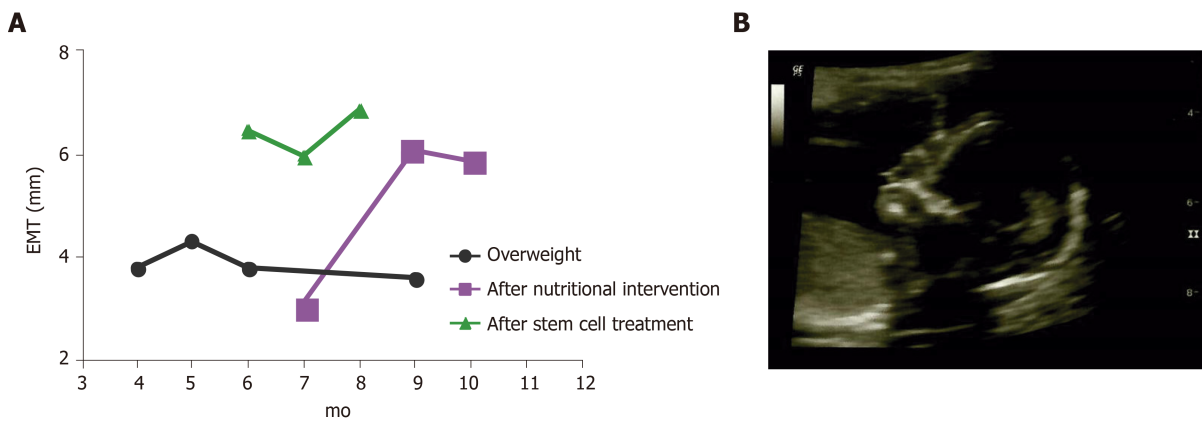
Table 1 depicts all results and details of the interventions during the four IVF cycles. After induction and maintenance of nutritional ketosis, IR was corrected. As a result, BMI decreased to 23.63 kg/m² and the final fasting glucose was 78 mg/dL. Figure 1A shows the changes in the EMT after the two major interventions: nutritional ketosis and endometrial regeneration. Pregnancy was finally achieved after a continuous dietary intervention, which resulted in metabolic normalization when complemented with endometrial reparation using mesenchymal stem cells and the transfer of euploid embryos from donated ova. One gestational sac with a fetal heartbeat was detected *via* the ultrasound at week 6. The gestational sac presented with 158 beats per minute, normal amniotic liquid, and the absence of ultrasound markers for chromosomopathies. No apparent structural alterations were detected at week 18 (Figure 1B). Metabolic control continued to avoid the risk of gestational diabetes with the proper caloric increase by trimester and 100 g - 150 g of CHO for daily consumption. Pregnancy resulted in the born of a healthy baby girl at 37 wk (2690 g; 47 cm; Apgar 9).

DISCUSSION

In a PCOS-related infertility case, a patient achieved pregnancy after combining interventions, specifically implementing a ketogenic diet, and improving the endometrium receptivity with mesenchymal stem cells. The most concerning problem with PCOS is infertility at the reproductive age, as this degenerative disease predisposes women to reproductive complications and possible infertility. Lower pregnancy rates are observed in obese PCOS compared to non-obese PCOS patients[21,22], demonstrating a crucial metabolic component for PCOS women concerning fertility. IR-PCOS patients develop sub-optimal oocytes, with fewer MII oocytes[23]. Moreover, IR-PCOS patients have lower pregnancy rates after IVF, even if oocyte development, embryo quality[7], or risk for embryonic aneuploidy was not affected[24], suggesting that the effects of IR on endometrial function and embryo implantation underlie the decreased pregnancy rates[7].

Evidence in adult women indicated that treatment of IR, either by lifestyle changes or pharmacological support, improves reproductive and metabolic abnormalities[25]. Thus, it was expected that the nutritional intervention would improve the reproduction potential of our PCOS patients. IR is mainly caused due to a constant glucose overload, leading to continuous hyperinsulinemia; therefore, restricting glucose exposure *via* dietary modifications should improve IR and reproductive outcomes for PCOS women[26]. Therefore, it is crucial to determine a subject's IR status before considering any intervention containing a diet. However, not all diet modifications are optimal for PCOS. Here, a low caloric diet with standard macro nutrients distribution improved weight but did not correct IR (Table 1). Diets with lower carbohydrate content are more likely to improve IR in PCOS women with severe IR[19, 27,28]. In this case, a diet modification with CHO limitation to a maximal daily consumption of 50 g successfully corrected IR and improved pregnancy chances. Even when Metformin is widely used for IR as an important insulin sensitizer, a recent meta-analysis shows that Metformin does not improve insulin sensitivity over hypocaloric diets in women with polycystic ovary syndrome[19]. When pre- and post-intervention values for fasting plasma glucose, fasting plasma insulin, and IR indices (HOMA-IR, ISI, and QUICKI) were compared, any benefit of using Metformin was already achieved when a diet intervention was implemented. This means that adding Metformin to hypocaloric diets did not improve serum glucose or insulin concentrations, or IR in PCOS women, but controlling the CHO intake does.

In PCOS patients, endometrial tissue function is altered due to abnormal glucose homeostasis and insulin action[29], presumably due to GLUT4 alterations. GLUT4 is the main glucose transporter in charge of glucose uptake at the cellular level, regulated by insulin through protein synthesis and translocation. Hyperinsulinemia and PCOS are conditions associated with decreased GLUT4 expression at the endometrial level[30]. Lifestyle modification (physical exercise and low CHO/high protein diet) improves glucose homeostasis in PCOS patients. Consequently, the endometrial function is restored due to GLUT4 down-regulation, resulting from the up-regulation of endometrial IRS1 and GLUT1[31]. In support of this, we show that a continuous and closely supervised nutritional intervention resulted in total correction in IR, complete normalization of metabolic parameters, and improved endometrial growth. Improving endometrial function may be a necessary approach for PCOS-related infertility[9], as for improving metabolic health was not enough to resolve the patient's reproductive issues. The uterine



DOI: 10.12998/wjcc.v10.i33.12295 Copyright ©The Author(s) 2022.

Figure 1 The endometrial mean thickness along with the two major interventions. A: Endometrial quality was assessed by determining the endometrial mean thickness, the physician performed measurements under ultrasonographic guidance; B: Current ultrasound at the time of submission of the single gestational sac due to treating the ketogenic diet with endometrium preparation with mesenchymal stem cells, the sonogram is at 16 wk after embryo transfer.

lining in our patient improved after the nutritional intervention (Figure 1), with the EMT consistently increasing above 6 mm. Nevertheless, considering past failed embryo transfers and lack of abnormalities in the uterine cavity, additional support for endometrial development and embryo implantation was explored. Generally, an endometrial thickness of 7 mm is the cut-off point for a “good endometrium, adequate for embryo transfer”, and a value below 6 mm may result in unfavorable IVF outcomes[32]. The endometrium is an exceptional tissue that monthly undergoes cyclic proliferation, differentiation, disintegration, shedding, and repair under hormonal command, going through approximately 450 regeneration cycles over women's reproductive lifetime[33]. Endometrium's regenerative ability is attributed to stem/progenitor cells residing in the basalis layer of the tissue[34]. EnMSCs exhibit immunomodulatory and anti-inflammatory functions[35]. It has been proposed that the endometrial niche can be colonized by autologous stem cells derived from other tissues when there is a lack of EnMSCs[15]. Colonizing improved endometrial quality in dysfunctional conditions in Asherman's syndrome[16,17] and refractory endometrium[11]. Sub-endometrial application of autologous ADMSC led to an endometrial thickness increase in 80% of patients, a pregnancy rate of 52%, and a live birth rate of 36%[11].

Three mechanisms of action have been proposed for stem cell therapy to improve endometrial quality in the injured uterus of murine models: (1) Stem cell engraftment followed by trans-differentiation; (2) Environment modulation through trophic factors; and (3) Angiogenesis promotion. First, mesenchymal stem cells are highly proliferative cells that can transdifferentiate into various non-hematopoietic cell types. This differentiation potential in transplanted bone marrow-derived stem cells allows stem cell engraftment in the uterus, then differentiation into an endometrial phenotype expressing vimentin and lacking CD45 expression[36]. Second, LIF and integrins are regulators of endometrial function, markers for endometrial receptivity, and essential proteins for embryo implantation. Expression of cytokeratin, vimentin, integrin $\alpha\gamma\beta 3$, and LIF significantly increased after bone marrow-derived stem cells were transplanted, mimicking levels found in normal conditions, suggesting that stem cell treatments improve endometrial thickness but also contribute to endometrial receptivity[37]. Last, human endometrial mesenchymal stem cells derived from menstrual blood (MenSCs) have been demonstrated to promote angiogenesis in treating an endometrial injury. Newly formed blood vessels were observed after MenSCs were transplanted *in vivo* under the control of the AKT and ERK signaling pathways, suggesting that revascularization and angiogenesis can improve the injured endometrium. Furthermore, this revascularization process allows paracrine signaling (cytokines and growth factors) to repair injured tissues[38]. SVF is a minimum manipulated heterogeneous cell pool containing ADMSC and is efficiently obtained *via* minimal liposuction. Its use has been extended and represents a convenient source for stem cells[39]. Considering its therapeutic potential, comparable to cultured ADSC[14], we propose a surgical intervention to implant SVF-containing stem cells into the patient's uterus to achieve minimal EMT for embryo transfer. Three months after stem cell treatment, endometrial thickness improved up to 6.9 mm, allowing successful embryo implantation and pregnancy. We assume that more than one of the proposed mechanisms for stem cell therapy helped in our case. The endometrium thickness was improved, and receptivity and paracrine signaling were boosted, allowing successful embryo implantation.

Our study has two significant limitations. First, the patient's advanced maternal age. The effect age has on the result presented here still needs to be investigated. Nevertheless, we demonstrate that for certain circumstances, the use of a ketogenic diet and stem cell treatment maybe required for even the transfer euploid embryos. Lastly, the quality of the SVF was not specifically measured, with respect to

the other components of the fluid. It is possible other components, such as endothelial precursors, macrophages, pericytes, and preadipocytes as well as the concentration of cytokine and adipokine, could improve or inhibit the effect present here.

CONCLUSION

We show that a continuous nutritional intervention resulted in correction of IR, normalization of metabolic parameters, and improved endometrial growth. Furthermore, stem cell treatment improved endometrial quality concerning endometrial thickness and receptivity. We conclude that correcting IR in PCOS patients may improve reproductive outcomes and stem cell treatment, using SVF, could become a handy intervention to improve endometrial receptivity.

ACKNOWLEDGEMENTS

We want to express our gratitude to this study's participant and the IVF and medical staff at Ingenes SC and Regenera SC. In addition, we would like to thank Dr. Leonardo M P for his critical reading of the manuscript.

FOOTNOTES

Author contributions: Hernández-Melchor D, Palafox-Gómez C, and López-Bayghen E conceived the project. Ortiz G and Madrazo I performed the surgical procedures; Hernández-Melchor D and Palafox-Gómez C performed clinical data acquisition while Ortiz G and Madrazo I handled the case as the clinicians, collecting information regarding the parental history and *in vitro* fertilization data. López-Bayghen E, Hernández-Melchor D, and Palafox-Gómez C analyzed the data. López-Bayghen E and Hernández-Melchor D drafted the article. America Padilla critically revised the manuscript; all authors have approved the final version of the manuscript.

Supported by the National Council of Science and Technology of Mexico (CONACYT), No. 790971 (to Hernández-Melchor D), and No. 781208 to (to Palafox-Gómez C).

Informed consent statement: The patient and her partner provided written informed consent to participate in this study under the Declaration of Helsinki. Written informed consent was obtained from them for their anonymized information published in this article.

Conflict-of-interest statement: The authors have no relevant financial or non-financial interests to disclose.

CARE Checklist (2016) statement: The authors have read the CARE Checklist (2016), and the manuscript was prepared and revised according to the CARE Checklist (2016).

Open-Access: This article is an open-access article that was selected by an in-house editor and fully peer-reviewed by external reviewers. It is distributed in accordance with the Creative Commons Attribution NonCommercial (CC BY-NC 4.0) license, which permits others to distribute, remix, adapt, build upon this work non-commercially, and license their derivative works on different terms, provided the original work is properly cited and the use is non-commercial. See: <https://creativecommons.org/licenses/by-nc/4.0/>

Country/Territory of origin: Mexico

ORCID number: Dinorah Hernández-Melchor 0000-0002-1577-7803; Cecilia Palafox-Gómez 0000-0002-7335-6740; Ivan Madrazo 0000-0001-6333-0398; Ginna Ortiz 0000-0002-7713-1004; America Padilla-Viveros 0000-0003-3438-4463; Esther López-Bayghen 0000-0002-2849-7587.

S-Editor: Xing YX

L-Editor: A

P-Editor: Xing YX

REFERENCES

- 1 Niño OMS, da Costa CS, Torres KM, Zanol JF, Freitas-Lima LC, Miranda-Alves L, Graceli JB. High-refined carbohydrate diet leads to polycystic ovary syndrome-like features and reduced ovarian reserve in female rats. *Toxicol Lett* 2020; **332**: 42-55 [PMID: 32629074 DOI: 10.1016/j.toxlet.2020.07.002]
- 2 Bai X, Zheng L, Li D, Xu Y. Research progress of endometrial receptivity in patients with polycystic ovary syndrome: a

- systematic review. *Reprod Biol Endocrinol* 2021; **19**: 122 [PMID: [34362377](#) DOI: [10.1186/s12958-021-00802-4](#)]
- 3 **Lopes IM**, Baracat MC, Simões Mde J, Simões RS, Baracat EC, Soares JM Jr. Endometrium in women with polycystic ovary syndrome during the window of implantation. *Rev Assoc Med Bras (1992)* 2011; **57**: 702-709 [PMID: [22249553](#) DOI: [10.1590/s0104-42302011000600020](#)]
 - 4 **Ejzenberg D**, Gomes TJO, Monteleone PAA, Serafini PC, Soares-Jr JM, Baracat EC. Prognostic factors for pregnancy after intrauterine insemination. *Int J Gynaecol Obstet* 2019; **147**: 65-72 [PMID: [31242330](#) DOI: [10.1002/ijgo.12898](#)]
 - 5 **Giordano MV**, Giordano LA, Gomes RC, Simões RS, Nader HB, Giordano MG, Baracat EC, Soares Júnior JM. The evaluation of endometrial sulfate glycosaminoglycans in women with polycystic ovary syndrome. *Gynecol Endocrinol* 2015; **31**: 278-281 [PMID: [25434369](#) DOI: [10.3109/09513590.2014.989980](#)]
 - 6 **Qi J**, Wang W, Zhu Q, He Y, Lu Y, Wang Y, Li X, Chen ZJ, Sun Y. Local Cortisol Elevation Contributes to Endometrial Insulin Resistance in Polycystic Ovary Syndrome. *J Clin Endocrinol Metab* 2018; **103**: 2457-2467 [PMID: [29618067](#) DOI: [10.1210/je.2017-02459](#)]
 - 7 **Chang EM**, Han JE, Seok HH, Lee DR, Yoon TK, Lee WS. Insulin resistance does not affect early embryo development but lowers implantation rate in in vitro maturation-in vitro fertilization-embryo transfer cycle. *Clin Endocrinol (Oxf)* 2013; **79**: 93-99 [PMID: [23176069](#) DOI: [10.1111/cen.12099](#)]
 - 8 **Liu Y**, Li J, Yan Z, Liu D, Ma J, Tong N. Improvement of Insulin Sensitivity Increases Pregnancy Rate in Infertile PCOS Women: A Systemic Review. *Front Endocrinol (Lausanne)* 2021; **12**: 657889 [PMID: [33859621](#) DOI: [10.3389/fendo.2021.657889](#)]
 - 9 **Jiang NX**, Li XL. The Disorders of Endometrial Receptivity in PCOS and Its Mechanisms. *Reprod Sci* 2022; **29**: 2465-2476 [PMID: [34046867](#) DOI: [10.1007/s43032-021-00629-9](#)]
 - 10 **Andrzejewska A**, Lukomska B, Janowski M. Concise Review: Mesenchymal Stem Cells: From Roots to Boost. *Stem Cells* 2019; **37**: 855-864 [PMID: [30977255](#) DOI: [10.1002/stem.3016](#)]
 - 11 **Sudoma I**, Pylyp L, Kremenska Y, Goncharova Y. Application of autologous adipose-derived stem cells for thin endometrium treatment in patients with failed ART programs. *J Stem Cell Ther Transplant* 2019; **3**: 1-8 [DOI: [10.29328/journal.jscett.1001013](#)]
 - 12 **Dominici M**, Le Blanc K, Mueller I, Slaper-Cortenbach I, Marini F, Krause D, Deans R, Keating A, Prockop Dj, Horwitz E. Minimal criteria for defining multipotent mesenchymal stromal cells. The International Society for Cellular Therapy position statement. *Cytotherapy* 2006; **8**: 315-317 [PMID: [16923606](#) DOI: [10.1080/14653240600855905](#)]
 - 13 **Feist V**, Meidinger S, Locke MB. From bench to bedside: use of human adipose-derived stem cells. *Stem Cells Cloning* 2015; **8**: 149-162 [PMID: [26586955](#) DOI: [10.2147/SCCAA.S64373](#)]
 - 14 **Nguyen A**, Guo J, Banyard DA, Fadavi D, Toranto JD, Wirth GA, Paydar KZ, Evans GR, Widgerow AD. Stromal vascular fraction: A regenerative reality? *J Plast Reconstr Aesthet Surg* 2016; **69**: 170-179 [PMID: [26565755](#) DOI: [10.1016/j.bjps.2015.10.015](#)]
 - 15 **Ogawa R**. The importance of adipose-derived stem cells and vascularized tissue regeneration in the field of tissue transplantation. *Curr Stem Cell Res Ther* 2006; **1**: 13-20 [PMID: [18220849](#) DOI: [10.2174/157488806775269043](#)]
 - 16 **Singh N**, Mohanty S, Seth T, Shankar M, Bhaskaran S, Dharmendra S. Autologous stem cell transplantation in refractory Asherman's syndrome: A novel cell based therapy. *J Hum Reprod Sci* 2014; **7**: 93-98 [PMID: [25191021](#) DOI: [10.4103/0974-1208.138864](#)]
 - 17 **Santamaria X**, Cabanillas S, Cervelló I, Arbona C, Raga F, Ferro J, Palmero J, Remohí J, Pellicer A, Simón C. Autologous cell therapy with CD133+ bone marrow-derived stem cells for refractory Asherman's syndrome and endometrial atrophy: a pilot cohort study. *Hum Reprod* 2016; **31**: 1087-1096 [PMID: [27005892](#) DOI: [10.1093/humrep/dew042](#)]
 - 18 **Alberti KG**, Eckel RH, Grundy SM, Zimmet PZ, Cleeman JI, Donato KA, Fruchart JC, James WP, Loria CM, Smith SC Jr; International Diabetes Federation Task Force on Epidemiology and Prevention; National Heart, Lung, and Blood Institute; American Heart Association; World Heart Federation; International Atherosclerosis Society; International Association for the Study of Obesity. Harmonizing the metabolic syndrome: a joint interim statement of the International Diabetes Federation Task Force on Epidemiology and Prevention; National Heart, Lung, and Blood Institute; American Heart Association; World Heart Federation; International Atherosclerosis Society; and International Association for the Study of Obesity. *Circulation* 2009; **120**: 1640-1645 [PMID: [19805654](#) DOI: [10.1161/CIRCULATIONAHA.109.192644](#)]
 - 19 **Garcia-Hernandez SC**, Porchia LM, Pacheco-Soto BT, López-Bayghen E, Gonzalez-Mejia ME. Metformin does not improve insulin sensitivity over hypocaloric diets in women with polycystic ovary syndrome: a systematic review of 12 studies. *Gynecol Endocrinol* 2021; **37**: 968-976 [PMID: [33899646](#) DOI: [10.1080/09513590.2021.1913114](#)]
 - 20 **Schaeffer E**, López-Bayghen B, Neumann A, Porchia LM, Camacho R, Garrido E, Gómez R, Camargo F, López-Bayghen E. Whole Genome Amplification of Day 3 or Day 5 Human Embryos Biopsies Provides a Suitable DNA Template for PCR-Based Techniques for Genotyping, a Complement of Preimplantation Genetic Testing. *Biomed Res Int* 2017; **2017**: 1209158 [PMID: [28717645](#) DOI: [10.1155/2017/1209158](#)]
 - 21 **Tziomalos K**, Dinas K. Obesity and Outcome of Assisted Reproduction in Patients With Polycystic Ovary Syndrome. *Front Endocrinol (Lausanne)* 2018; **9**: 149 [PMID: [29670581](#) DOI: [10.3389/fendo.2018.00149](#)]
 - 22 **Bailey AP**, Hawkins LK, Missmer SA, Correia KF, Yanushpolsky EH. Effect of body mass index on in vitro fertilization outcomes in women with polycystic ovary syndrome. *Am J Obstet Gynecol* 2014; **211**: 163.e1-163.e6 [PMID: [24657792](#) DOI: [10.1016/j.ajog.2014.03.035](#)]
 - 23 **Hassani F**, Oryan S, Eftekhari-Yazdi P, Bazrgar M, Moini A, Nasiri N, Ghaheeri A. Association between The Number of Retrieved Mature Oocytes and Insulin Resistance or Sensitivity in Infertile Women with Polycystic Ovary Syndrome. *Int J Fertil Steril* 2019; **12**: 310-315 [PMID: [30291692](#) DOI: [10.22074/ijfs.2019.5422](#)]
 - 24 **Weghofer A**, Munne S, Chen S, Barad D, Gleicher N. Lack of association between polycystic ovary syndrome and embryonic aneuploidy. *Fertil Steril* 2007; **88**: 900-905 [PMID: [17433813](#) DOI: [10.1016/j.fertnstert.2006.12.018](#)]
 - 25 **Marshall JC**, Dunaif A. Should all women with PCOS be treated for insulin resistance? *Fertil Steril* 2012; **97**: 18-22 [PMID: [22192137](#) DOI: [10.1016/j.fertnstert.2011.11.036](#)]
 - 26 **Hajishafiee N**, Ghiasvand R, Feizi A, Askari G. Dietary patterns and ovulatory infertility: a case-control study. *Journal of Nutritional Sciences and Dietetics* 2017; **3** [DOI: [10.21203/rs.3.rs-19352/v1](#)]

- 27 **Alwahab UA**, Pantalone KM, Burguera B. A ketogenic diet may restore fertility in women with polycystic ovary syndrome: a case series. *AACE Clin Case Rep* 2018; **4**: e427-e431 [DOI: [10.4158/accr-2018-0026](https://doi.org/10.4158/accr-2018-0026)]
- 28 **Mavropoulos JC**, Yancy WS, Hepburn J, Westman EC. The effects of a low-carbohydrate, ketogenic diet on the polycystic ovary syndrome: a pilot study. *Nutr Metab (Lond)* 2005; **2**: 35 [PMID: [16359551](https://pubmed.ncbi.nlm.nih.gov/16359551/) DOI: [10.1186/1743-7075-2-35](https://doi.org/10.1186/1743-7075-2-35)]
- 29 **Oróstica L**, Astorga I, Plaza-Parrochia F, Vera C, García V, Carvajal R, Gabler F, Romero C, Vega M. Proinflammatory environment and role of TNF- α in endometrial function of obese women having polycystic ovarian syndrome. *Int J Obes (Lond)* 2016; **40**: 1715-1722 [PMID: [27569685](https://pubmed.ncbi.nlm.nih.gov/27569685/) DOI: [10.1038/ijo.2016.154](https://doi.org/10.1038/ijo.2016.154)]
- 30 **Mioni R**, Chiarelli S, Xamin N, Zuliani L, Granzotto M, Mozzanega B, Maffei P, Martini C, Blandamura S, Siculo N, Vettor R. Evidence for the presence of glucose transporter 4 in the endometrium and its regulation in polycystic ovary syndrome patients. *J Clin Endocrinol Metab* 2004; **89**: 4089-4096 [PMID: [15292352](https://pubmed.ncbi.nlm.nih.gov/15292352/) DOI: [10.1210/jc.2003-032028](https://doi.org/10.1210/jc.2003-032028)]
- 31 **Ujvari D**, Hulchiy M, Calaby A, Nybacka Å, Byström B, Hirschberg AL. Lifestyle intervention up-regulates gene and protein levels of molecules involved in insulin signaling in the endometrium of overweight/obese women with polycystic ovary syndrome. *Hum Reprod* 2014; **29**: 1526-1535 [PMID: [24842895](https://pubmed.ncbi.nlm.nih.gov/24842895/) DOI: [10.1093/humrep/deu114](https://doi.org/10.1093/humrep/deu114)]
- 32 **Liu KE**, Hartman M, Hartman A, Luo ZC, Mahutte N. The impact of a thin endometrial lining on fresh and frozen-thaw IVF outcomes: an analysis of over 40 000 embryo transfers. *Hum Reprod* 2018; **33**: 1883-1888 [PMID: [30239738](https://pubmed.ncbi.nlm.nih.gov/30239738/) DOI: [10.1093/humrep/dey281](https://doi.org/10.1093/humrep/dey281)]
- 33 **Jabbour HN**, Kelly RW, Fraser HM, Critchley HO. Endocrine regulation of menstruation. *Endocr Rev* 2006; **27**: 17-46 [PMID: [16160098](https://pubmed.ncbi.nlm.nih.gov/16160098/) DOI: [10.1210/er.2004-0021](https://doi.org/10.1210/er.2004-0021)]
- 34 **Cousins FL**, Pandoy R, Jin S, Gargett CE. The Elusive Endometrial Epithelial Stem/Progenitor Cells. *Front Cell Dev Biol* 2021; **9**: 640319 [PMID: [33898428](https://pubmed.ncbi.nlm.nih.gov/33898428/) DOI: [10.3389/fcell.2021.640319](https://doi.org/10.3389/fcell.2021.640319)]
- 35 **Bozorgmehr M**, Gurung S, Darzi S, Nikoo S, Kazemnejad S, Zarnani AH, Gargett CE. Endometrial and Menstrual Blood Mesenchymal Stem/Stromal Cells: Biological Properties and Clinical Application. *Front Cell Dev Biol* 2020; **8**: 497 [PMID: [32742977](https://pubmed.ncbi.nlm.nih.gov/32742977/) DOI: [10.3389/fcell.2020.00497](https://doi.org/10.3389/fcell.2020.00497)]
- 36 **Lee YJ**, Yi KW. Bone marrow-derived stem cells contribute to regeneration of the endometrium. *Clin Exp Reprod Med* 2018; **45**: 149-153 [PMID: [30538944](https://pubmed.ncbi.nlm.nih.gov/30538944/) DOI: [10.5653/cerm.2018.45.4.149](https://doi.org/10.5653/cerm.2018.45.4.149)]
- 37 **Zhao J**, Zhang Q, Wang Y, Li Y. Uterine infusion with bone marrow mesenchymal stem cells improves endometrium thickness in a rat model of thin endometrium. *Reprod Sci* 2015; **22**: 181-188 [PMID: [24947483](https://pubmed.ncbi.nlm.nih.gov/24947483/) DOI: [10.1177/1933719114537715](https://doi.org/10.1177/1933719114537715)]
- 38 **Zhang Y**, Lin X, Dai Y, Hu X, Zhu H, Jiang Y, Zhang S. Endometrial stem cells repair injured endometrium and induce angiogenesis via AKT and ERK pathways. *Reproduction* 2016; **152**: 389-402 [PMID: [27486270](https://pubmed.ncbi.nlm.nih.gov/27486270/) DOI: [10.1530/REP-16-0286](https://doi.org/10.1530/REP-16-0286)]
- 39 **Zuk PA**, Zhu M, Mizuno H, Huang J, Futrell JW, Katz AJ, Benhaim P, Lorenz HP, Hedrick MH. Multilineage cells from human adipose tissue: implications for cell-based therapies. *Tissue Eng* 2001; **7**: 211-228 [PMID: [11304456](https://pubmed.ncbi.nlm.nih.gov/11304456/) DOI: [10.1089/107632701300062859](https://doi.org/10.1089/107632701300062859)]



Published by **Baishideng Publishing Group Inc**
7041 Koll Center Parkway, Suite 160, Pleasanton, CA 94566, USA

Telephone: +1-925-3991568

E-mail: bpgoffice@wjgnet.com

Help Desk: <https://www.f6publishing.com/helpdesk>

<https://www.wjgnet.com>

