

# World Journal of *Clinical Cases*

*World J Clin Cases* 2022 December 6; 10(34): 12462-12803



## Contents

Thrice Monthly Volume 10 Number 34 December 6, 2022

## FIELD OF VISION

- 12462 Problematics of neurosurgical service during the COVID-19 pandemic in Slovenia  
*Munda M, Bosnjak R, Velnar T*

## MINIREVIEWS

- 12470 Circulating angiotensin converting enzyme 2 and COVID-19  
*Leowattana W, Leowattana T, Leowattana P*
- 12484 Evaluation of gut dysbiosis using serum and fecal bile acid profiles  
*Monma T, Iwamoto J, Ueda H, Tamamushi M, Kakizaki F, Konishi N, Yara S, Miyazaki T, Hirayama T, Ikegami T, Honda A*
- 12494 Pediatric kidney transplantation during the COVID-19 pandemic  
*Tamura H*

## ORIGINAL ARTICLE

## Clinical and Translational Research

- 12500 *Coptis*, *Pinellia*, and *Scutellaria* as a promising new drug combination for treatment of *Helicobacter pylori* infection  
*Yu Z, Sheng WD, Yin X, Bin Y*

## Case Control Study

- 12515 Effects of illness perception on negative emotions and fatigue in chronic rheumatic diseases: Rumination as a possible mediator  
*Lu Y, Jin X, Feng LW, Tang C, Neo M, Ho RC*

## Retrospective Study

- 12532 Significance of incidental focal fluorine-18 fluorodeoxyglucose uptake in colon/rectum, thyroid, and prostate: With a brief literature review  
*Lee H, Hwang KH*
- 12543 Follow-up study on ThinPrep cytology test-positive patients in tropical regions  
*Chen YC, Liang CN, Wang XF, Wang MF, Huang XN, Hu JD*
- 12551 Effect of teach-back health education combined with structured psychological nursing on adverse emotion and patient cooperation during  $^{99m}\text{Tc}$ -3PRGD2.SPECT/CT  
*Gong WN, Zhang YH, Niu J, Li XB*
- 12559 Nosocomial infection and spread of SARS-CoV-2 infection among hospital staff, patients and caregivers  
*Cheng CC, Fann LY, Chou YC, Liu CC, Hu HY, Chu D*

**Observational Study**

- 12566** Effectiveness and safety of generic and brand direct acting antivirals for treatment of chronic hepatitis C  
*Abdulla M, Al Ghareeb AM, Husain HAHY, Mohammed N, Al Qamish J*

- 12578** Influence of group B *streptococcus* and vaginal cleanliness on the vaginal microbiome of pregnant women  
*Liao Q, Zhang XF, Mi X, Jin F, Sun HM, Wang QX*

**Randomized Controlled Trial**

- 12587** Clinical study on tri-tongue acupuncture combined with low-frequency electrical stimulation for treating post-stroke dysarthria  
*Man B, Li WW, Xu JF, Wang Q*

**META-ANALYSIS**

- 12594** Three-dimensional time-of-flight magnetic resonance angiography combined with high resolution T2-weighted imaging in preoperative evaluation of microvascular decompression  
*Liang C, Yang L, Zhang BB, Guo SW, Li RC*

**CASE REPORT**

- 12605** Acute cytomegalovirus hepatitis in an immunocompetent patient: A case report  
*Wang JP, Lin BZ, Lin CL, Chen KY, Lin TJ*
- 12610** Long-term results of extended Boari flap technique for management of complete ureteral avulsion: A case report  
*Zhong MZ, Huang WN, Huang GX, Zhang EP, Gan L*
- 12617** Amyloid  $\beta$ -related angiitis of the central nervous system occurring after COVID-19 vaccination: A case report  
*Kizawa M, Iwasaki Y*
- 12623** Pseudoileus caused by primary visceral myopathy in a Han Chinese patient with a rare *MYH11* mutation: A case report  
*Li N, Song YM, Zhang XD, Zhao XS, He XY, Yu LF, Zou DW*
- 12631** Emergent use of tube tip in pharynx technique in "cannot intubate cannot oxygenate" situation: A case report  
*Lin TC, Lai YW, Wu SH*
- 12637** Inflammatory myofibroblastic tumor of the central nervous system: A case report  
*Su ZJ, Guo ZS, Wan HT, Hong XY*
- 12648** Atypical aggressive vertebral hemangioma of the sacrum with postoperative recurrence: A case report  
*Wang GX, Chen YQ, Wang Y, Gao CP*
- 12654** Closed reduction of hip dislocation associated with ipsilateral lower extremity fractures: A case report and review of the literature  
*Xu Y, Lv M, Yu SQ, Liu GP*

- 12665** Repair of a large patellar cartilage defect using human umbilical cord blood-derived mesenchymal stem cells: A case report  
*Song JS, Hong KT, Song KJ, Kim SJ*
- 12671** Abdominal bronchogenic cyst: A rare case report  
*Li C, Zhang XW, Zhao CA, Liu M*
- 12678** Malignant fibrous histiocytoma of the axilla with breast cancer: A case report  
*Gao N, Yang AQ, Xu HR, Li L*
- 12684** Rapid hemostasis of the residual inguinal access sites during endovascular procedures: A case report  
*Kim H, Lee K, Cho S, Joh JH*
- 12690** Formation of granulation tissue on bilateral vocal cords after double-lumen endotracheal intubation: A case report  
*Xiong XJ, Wang L, Li T*
- 12696** Giant cellular leiomyoma in the broad ligament of the uterus: A case report  
*Yan J, Li Y, Long XY, Li DC, Li SJ*
- 12703** Pomolidomide for relapsed/refractory light chain amyloidosis after resistance to both bortezomib and daratumumab: A case report  
*Li X, Pan XH, Fang Q, Liang Y*
- 12711** Ureteral- artificial iliac artery fistula: A case report  
*Feng T, Zhao X, Zhu L, Chen W, Gao YL, Wei JL*
- 12717** How to manage isolated tension non-surgical pneumoperitoneum during bronchoscopy? A case report  
*Baima YJ, Shi DD, Shi XY, Yang L, Zhang YT, Xiao BS, Wang HY, He HY*
- 12726** Amiodarone-induced muscle tremor in an elderly patient: A case report  
*Zhu XY, Tang XH, Yu H*
- 12734** Surgical treatment of Pitt-Hopkins syndrome associated with strabismus and early-onset myopia: Two case reports  
*Huang Y, Di Y, Zhang XX, Li XY, Fang WY, Qiao T*
- 12742** Massive low-grade myxoid liposarcoma of the floor of the mouth: A case report and review of literature  
*Kugimoto T, Yamagata Y, Ohsako T, Hirai H, Nishii N, Kayamori K, Ikeda T, Harada H*
- 12750** Gingival enlargement induced by cyclosporine in Medullary aplasia: A case report  
*Victory Rodríguez G, Ruiz Gutiérrez ADC, Gómez Sandoval JR, Lomeli Martínez SM*
- 12761** Compound heterozygous mutations in PMFBP1 cause acephalic spermatozoa syndrome: A case report  
*Deng TQ, Xie YL, Pu JB, Xuan J, Li XM*
- 12768** Colonic tubular duplication combined with congenital megacolon: A case report  
*Zhang ZM, Kong S, Gao XX, Jia XH, Zheng CN*

- 12775** Perforated duodenal ulcer secondary to deferasirox use in a child successfully managed with laparoscopic drainage: A case report  
*Alshehri A, Alsinan TA*
- 12781** Complication after nipple-areolar complex tattooing performed by a non-medical person: A case report  
*Byeon JY, Kim TH, Choi HJ*
- 12787** Interventional urethral balloon dilatation before endoscopic visual internal urethrotomy for post-traumatic bulbous urethral stricture: A case report  
*Ha JY, Lee MS*
- 12793** Regression of gastric endoscopic submucosal dissection induced polypoid nodular scar after *Helicobacter pylori* eradication: A case report  
*Jin BC, Ahn AR, Kim SH, Seo SY*
- 12799** Congenital absence of the right coronary artery: A case report  
*Zhu XY, Tang XH*

**ABOUT COVER**

Editorial Board Member of *World Journal of Clinical Cases*, Giuseppe Lanza, MD, MSc, PhD, Associate Professor, Department of Surgery and Medical-Surgical Specialties, University of Catania, Catania 95123, Italy. glanza@oasi.en.it

**AIMS AND SCOPE**

The primary aim of *World Journal of Clinical Cases* (WJCC, *World J Clin Cases*) is to provide scholars and readers from various fields of clinical medicine with a platform to publish high-quality clinical research articles and communicate their research findings online.

WJCC mainly publishes articles reporting research results and findings obtained in the field of clinical medicine and covering a wide range of topics, including case control studies, retrospective cohort studies, retrospective studies, clinical trials studies, observational studies, prospective studies, randomized controlled trials, randomized clinical trials, systematic reviews, meta-analysis, and case reports.

**INDEXING/ABSTRACTING**

The WJCC is now abstracted and indexed in Science Citation Index Expanded (SCIE, also known as SciSearch®), Journal Citation Reports/Science Edition, Current Contents®/Clinical Medicine, PubMed, PubMed Central, Scopus, Reference Citation Analysis, China National Knowledge Infrastructure, China Science and Technology Journal Database, and Superstar Journals Database. The 2022 Edition of Journal Citation Reports® cites the 2021 impact factor (IF) for WJCC as 1.534; IF without journal self cites: 1.491; 5-year IF: 1.599; Journal Citation Indicator: 0.28; Ranking: 135 among 172 journals in medicine, general and internal; and Quartile category: Q4. The WJCC's CiteScore for 2021 is 1.2 and Scopus CiteScore rank 2021: General Medicine is 443/826.

**RESPONSIBLE EDITORS FOR THIS ISSUE**

Production Editor: Si Zhao; Production Department Director: Xu Guo; Editorial Office Director: Jin-Lei Wang.

**NAME OF JOURNAL**

*World Journal of Clinical Cases*

**ISSN**

ISSN 2307-8960 (online)

**LAUNCH DATE**

April 16, 2013

**FREQUENCY**

Thrice Monthly

**EDITORS-IN-CHIEF**

Bao-Gan Peng, Jerzy Tadeusz Chudek, George Kontogeorgos, Maurizio Serati, Ja Hyeon Ku

**EDITORIAL BOARD MEMBERS**

<https://www.wjnet.com/2307-8960/editorialboard.htm>

**PUBLICATION DATE**

December 6, 2022

**COPYRIGHT**

© 2022 Baishideng Publishing Group Inc

**INSTRUCTIONS TO AUTHORS**

<https://www.wjnet.com/bpg/gerinfo/204>

**GUIDELINES FOR ETHICS DOCUMENTS**

<https://www.wjnet.com/bpg/GerInfo/287>

**GUIDELINES FOR NON-NATIVE SPEAKERS OF ENGLISH**

<https://www.wjnet.com/bpg/gerinfo/240>

**PUBLICATION ETHICS**

<https://www.wjnet.com/bpg/GerInfo/288>

**PUBLICATION MISCONDUCT**

<https://www.wjnet.com/bpg/gerinfo/208>

**ARTICLE PROCESSING CHARGE**

<https://www.wjnet.com/bpg/gerinfo/242>

**STEPS FOR SUBMITTING MANUSCRIPTS**

<https://www.wjnet.com/bpg/GerInfo/239>

**ONLINE SUBMISSION**

<https://www.f6publishing.com>



## Long-term results of extended Boari flap technique for management of complete ureteral avulsion: A case report

Ming-Zhu Zhong, Wei-Na Huang, Gui-Xiao Huang, En-Pu Zhang, Lu Gan

**Specialty type:** Urology and nephrology

**Provenance and peer review:** Unsolicited article; Externally peer reviewed.

**Peer-review model:** Single blind

**Peer-review report's scientific quality classification**

Grade A (Excellent): 0  
Grade B (Very good): B, B  
Grade C (Good): C, C  
Grade D (Fair): 0  
Grade E (Poor): E

**P-Reviewer:** Kaewput W, Thailand; Leowattana W, Thailand; Markic D, Croatia; Shrestha AB, Egypt; Vyshka G, Albania

**Received:** June 9, 2022

**Peer-review started:** June 9, 2022

**First decision:** July 29, 2022

**Revised:** August 15, 2022

**Accepted:** November 7, 2022

**Article in press:** November 7, 2022

**Published online:** December 6, 2022



**Ming-Zhu Zhong, Wei-Na Huang,** Department of Urology, Shenzhen Baoan Shiyuan People's Hospital, Shenzhen 518108, Guangdong Province, China

**Gui-Xiao Huang, En-Pu Zhang, Lu Gan,** Department of Urology, The Third Affiliated Hospital of Shenzhen University, Shenzhen 518005, Guangdong Province, China

**Corresponding author:** Ming-Zhu Zhong, MD, PhD, Chief Doctor, Director, Department of Urology, Shenzhen Baoan Shiyuan People's Hospital, No. 11 Jixiang Road, Baoan District, Shenzhen 518108, Guangdong Province, China. [zhongmz@163.com](mailto:zhongmz@163.com)

### Abstract

#### BACKGROUND

Ureteroscopy is well-established as a primary treatment modality for urolithiasis. Ureteral avulsion, particularly complete or full-length avulsion with a resultant long segment of the ureter left attached to the ureteroscope, is a rare but devastating complication of the procedure. Management of this complication is challenging. Moreover, general consensus regarding the optimal management is undetermined. We report our experience of managing a complete ureteral avulsion case *via* an extended Boari flap technique with long-term results.

#### CASE SUMMARY

A 41-year-old female patient subjected to complete ureteral avulsion caused by ureteroscopy was referred to our hospital. A modified, extended Boari flap technique was successfully performed to repair the full-length ureteral defect. Maximal mobilization of the bladder and affected kidney followed by psoas hitch and downward nephropexy maximized the probability of a tension-free anastomosis. Meticulous blood supply preservation to the flap also contributed to the success. During the 4-year study period, no complications except for a mild urinary frequency and a slightly lower maximum urinary flow rate were reported. The patient was satisfied with the surgical outcomes.

#### CONCLUSION

The extended Boari flap procedure is a feasible and preferred technique to manage complete ureteral avulsion, particularly in emergencies.

**Key Words:** Ureteral avulsion; Ureteroscopy; Complication; Reconstruction; Boari flap; Case report

**Core Tip:** Management of complete ureteral avulsion caused by ureteroscopy is challenging. In the presented case, a modified, extended Boari flap technique was successfully performed to repair the full-length ureteral defect. During the 4-year study period, no complications except for a mild urinary frequency and a slightly lower maximum urinary flow rate were reported. The patient was satisfied with the surgical outcomes. This manuscript suggests the importance of the extended Boari flap procedure as a feasible and favorable treatment option to manage complete ureteral avulsion; moreover, ileal ureteral substitution or renal autotransplantation may be reserved as the second choice.

**Citation:** Zhong MZ, Huang WN, Huang GX, Zhang EP, Gan L. Long-term results of extended Boari flap technique for management of complete ureteral avulsion: A case report. *World J Clin Cases* 2022; 10(34): 12610-12616

**URL:** <https://www.wjgnet.com/2307-8960/full/v10/i34/12610.htm>

**DOI:** <https://dx.doi.org/10.12998/wjcc.v10.i34.12610>

## INTRODUCTION

Ureteroscopy (URS) is well-established as a primary treatment modality for urolithiasis. Albeit not challenging in general, it may occasionally result in severe complications, of which complete or full-length ureteral avulsion may be the most disastrous. Treatment options for this complication typically include ileal ureteral substitution, renal autotransplantation, Boari flap technique, and even nephrectomy; however, there has been no consensus regarding the hierarchy of treatment selection[1,2]. Moreover, all of these treatments are challenging. We present a case of ureteral avulsion as a complication of URS, managed *via* an extended Boari flap technique, and we describe the long-term results.

## CASE PRESENTATION

### Chief complaints

A 41-year-old female patient was referred to our hospital owing to ureteral avulsion caused by URS.

### History of present illness

The patient, with left proximal ureteral calculus and associated mild hydronephrosis, underwent a left 8/9.8-Fr semirigid URS and laser lithotripsy at an outside clinic. The stone was completely fragmented. On withdrawal of the scope, the operator felt the impacted scope in the ureter, and ureteral avulsion occurred. The patient reportedly had an avulsion at the upper ureter and was finally transferred to our hospital for definitive management after refusals by several hospitals.

### History of past illness

The patient was a hepatitis B carrier and had a history of multiple uterine leiomyomas; however, she did not have any surgical history.

### Personal and family history

The patient's personal and family history was unremarkable.

### Physical examination

The patient presented with body weakness but was clinically stable, with a blood pressure of 129/83 mmHg and heart rate of 93 bpm at admission. She was 156 cm tall and 53 kg in weight, with a body mass index of 22 kg/m<sup>2</sup>.

### Laboratory examinations

Laboratory test results revealed anemia, with a hemoglobin level of 79 g/L. The results for the other tested parameters were normal or with little clinical significance.

### Imaging examinations

Computed tomography urography (CTU) was performed, confirming complete avulsion at the



proximal ureter just below the ureteropelvic junction (UPJ) (Figure 1).

### **Intraoperative findings**

Management options were discussed with the patient and her husband, including ureteral reconstruction using a Boari flap, ileal ureteral substitution, renal autotransplantation, and nephrectomy as the last resort, and the patient was informed that the final decision had to be made in the operating room. The patient was brought to the operating room and placed in a supine position. A midline incision was performed, followed by mobilization of the descending colon and exposure of the retroperitoneum. The perirenal hematoma was cleared, and a ureteral stump was identified just below the UPJ above the lower pole level. Additionally, the distal ureter was “missing” at the entire left retroperitoneum, and full-length ureteral avulsion was confirmed.

---

## **FINAL DIAGNOSIS**

---

The final diagnosis was left-sided complete ureteral avulsion injury caused by URS.

---

## **TREATMENT**

---

We first attempted using a Boari flap. The bladder was thoroughly mobilized to the endopelvic fascia caudally. Bilateral medial umbilical ligaments were transected at the initial level, with superior vesical vessels of both sides preserved. Traction was placed on the dome of the highly compliant bladder toward the ureteral stump, with the assistant placing a countertraction on the left kidney caudally. Then, the gap was distinctly shorter than the length between the bladder neck and dome. Furthermore, the decision was made to perform a Boari flap technique for ureteral reconstruction. The left kidney was thoroughly mobilized, and the bladder attachments, such as the peritoneum near the bladder pedicles, which restrained bladder traction, were further dissected to achieve the smallest gap possible. The assistant retracted the bladder toward the ureteral stump with his hands turning the bladder into a long sac-like pouch. Hence, a trapezoidal flap with the apex starting from the bladder neck was made obliquely on the anterior wall of the bladder using low-power monopolar cautery. Surprisingly, a long isolated devitalized ureter was noticed within the bladder, which was thought to be placed by the operator after removing the “scabbard” of the ureter on the ureteroscope *in vitro* (Figure 2). Excessive cautery was avoided to minimize blood supply damage. The apex and base measured 2.5 cm and 5 cm, respectively. Subsequently, the flap was fixed to the psoas muscle above the common iliac artery, avoiding the genitofemoral nerve by two interrupted sutures using 2-0 PDS sutures. The lower pole of the left kidney was also fixed to the psoas muscle caudally. These procedures ensured a tension-free anastomosis despite an enlarged uterus caused by multiple uterine leiomyomas. The remnant of the proximal ureter was trimmed and spatulated dorsally and then anastomosed end-to-end to the bladder flap starting dorsally using interrupted 3-0 Monocryl sutures. The bladder flap was then tubularized over a 6F Double-J stent with a running 3-0 Monocryl suture closing the mucosa layer and a second layer of 2-0 Monocryl closing the detrusor muscle (Figure 3). A watertight reconstruction was confirmed. Intraoperative blood loss was limited; however, two units of red blood cells were transfused owing to preexistent anemia.

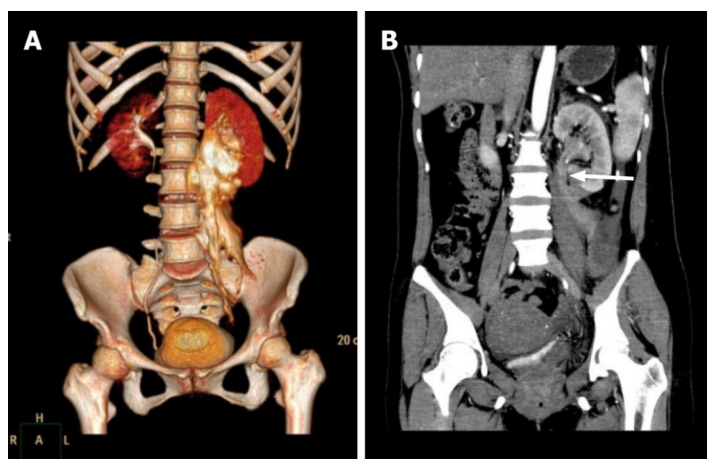
---

## **OUTCOME AND FOLLOW-UP**

---

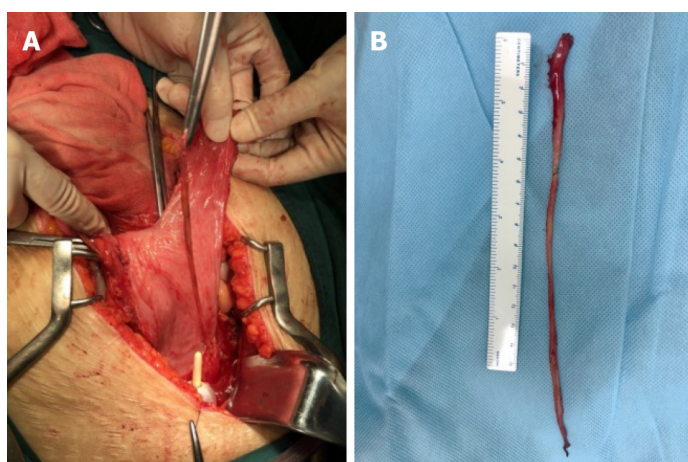
Postoperative recovery was uneventful. The Foley catheter was left in place for 14 d, at which time a CTU demonstrated a drumstick-like bladder without leakage. Cystoscopy and stent removal were performed after 2 mo; subsequently, a CTU demonstrated mild hydronephrosis in the left kidney as the baseline (Figure 4). Ultrasonography confirmed no hydronephrosis in both kidneys 1 mo later. Since then, the patient was followed up every 3–6 mo by ultrasonography, urine test, renal function test, and occasionally, urodynamics.

The patient complained of frequent urination postoperatively. She needed to urinate every 1–2 h in the daytime and 3–4 times at night in the first 3 mo after stent removal. Frequency gradually improved to 2–3 times per night in the following 6 mo. The urodynamic analysis results demonstrated normal bladder function except for a slightly lower maximum urinary flow rate at 5 and 13 mo with bladder volume tests of approximately 200 mL. After 18 mo, the patient reported approximately the same urination habits as before, with once or twice nighttime urination and bladder volume ranging from 200 to 250 mL. She did not report any urinary tract infection or lumbar pain during urination, indicating subclinical or no reflux. Neither hydronephrosis on both sides nor renal function damage was documented during the 48-mo follow-up. The patient was satisfied with the surgical outcomes.



DOI: 10.12998/wjcc.v10.i34.12610 Copyright ©The Author(s) 2022.

**Figure 1 Preoperative computed tomography.** A: Computed tomography (CT) urography three-dimensional reconstruction showed retroperitoneal contrast extravasation with the most severe site in the ureteropelvic junction (UPJ) region; B: Enhanced CT showed left ureteral disruption just below the UPJ (white arrow).



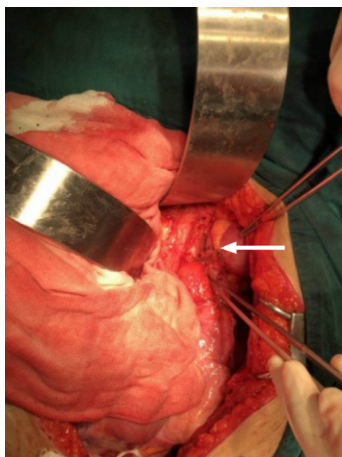
DOI: 10.12998/wjcc.v10.i34.12610 Copyright ©The Author(s) 2022.

**Figure 2 The completely avulsed ureter.** A: A long isolated devitalized ureter was noticed within the bladder intraoperatively; B: The full-length avulsed ureter *in vitro*.

## DISCUSSION

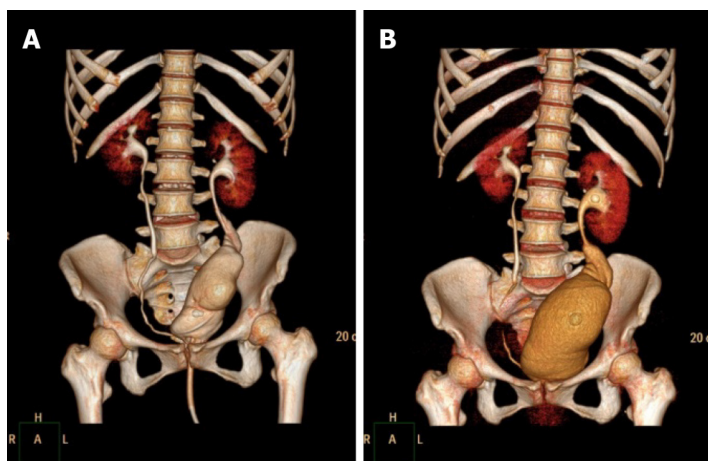
Ureteral avulsion is rare; however, it is a devastating complication that may occur during URS. Complete ureteral avulsion, defined as a two-point ureteral avulsion with one point at the intramural ureter and the other at the proximal ureter up to the UPJ, is nearly a catastrophe that may induce a nephrectomy[3,4]. Complete ureteral avulsion often occurs during a semirigid URS in these consecutive processes: (1) The operator finds it difficult to advance the ureterscope and feels restricted in the ureter owing to a relatively small ureteric lumen size; (2) Excessive force on the ureterscope, of which the outer caliber is gradually larger towards the base, makes it wedged into the ureter until tightly impacted; (3) Further force results in a complete avulsion of the intramural ureter from the bladder wall; and (4) On withdrawal of the ureterscope, because the ureter is already tightly impacted and because the operator is usually startled at that time, a second avulsion occurs at the UPJ or site where the stone is impacted, as it has been weakened by mucosa inflammation or the microtrauma caused by lithotripsy [5].

Considering the same inner lining with the ureter and relatively small anatomical changes to the patient, a Boari flap for ureteral reconstruction is an ideal treatment option if it is technically feasible with acceptable surgical complications. Owing to the complexity of the Boari flap technique, particularly for a full-length avulsion case in an emergency setting, many operators may opt for an ileal ureteral substitution, as it has no length limit when harvested to bridge a ureteral defect and achieve a tension-free anastomosis[1,6-9]. However, it results in extra bowel-related complications, such as ileus, intestinal leakage, mucus production, recurrent pyelonephritis, hyperchloremic metabolic acidosis, and impaired renal function, thus making it an unfavorable option for many operators[6-10]. Alternatively, renal



DOI: 10.12998/wjcc.v10.i34.12610 Copyright ©The Author(s) 2022.

**Figure 3 Ureteral reconstruction with an extended Boari flap intraoperatively.** The white arrow shows a tension-free anastomosis.



DOI: 10.12998/wjcc.v10.i34.12610 Copyright ©The Author(s) 2022.

**Figure 4 Postoperative computed tomography urography.** A and B: Computed tomography urography three-dimensional reconstruction at 14 d (A) and 2 mo postoperatively. Note that bladder volume is visibly larger at 2 mo postoperatively.

autotransplantation can eliminate even a full-length ureteral defect without those bowel-related complications[11-13]. However, it requires an experienced renal transplantation team which may be unavailable for most hospitals, especially in an emergency setting. Furthermore, even in the expert's hands, the risk of graft loss is reportedly up to 14.4% [11,14,15], not to mention the sense of insecurity felt by relocating the kidney from the retroperitoneum to the palpable iliac fossa.

The Boari flap technique is typically applied in the repair of a mid-ureteral defect. Previous reports have indicated the application of this technique in upper and even full-length ureteral defects[10,16,17]. However, owing to the complexity and challenge of the technique itself, most of the available literature was limited to small case series or case reports without long-term outcomes. The detailed techniques and complications with long-term follow-up data must be further elucidated. In the presented case, a modified, extended Boari flap technique was performed to repair the full-length ureteral defect with satisfactory long-term results for the patient. Several principles and techniques have been applied to achieve this success. First, maximal mobilization of the entire bladder and ipsilateral kidney is fundamental, guaranteeing the longest bladder flap and the most effective downward nephropexy, and thereafter, a tension-free anastomosis. We also presented our techniques for constructing an extended Boari flap, which is less complicated than L-shaped or S-shaped flaps[10,17]. Second, meticulous blood supply preservation with intact bilateral superior vesical arteries and minimal use of electrocautery also contributed to the success.

The main limitations of our study are that it is a case report and that right ureteral avulsion may confront different conditions, as it is associated with a much shorter renal vein than the left. However, the present case involved a concomitant enlarged uterus which increased the actual distance between the bladder and the ureter remnant. In addition, contemporary bladder flap reconstruction studies did not show any different outcomes regarding the surgical side[10,17]. Therefore, our presented techniques

might also be applied successfully in right-sided cases. In any case, managing complete ureteral avulsion is challenging. Prevention of ureteral avulsion is always the most rewarding measure. One should never forcefully manipulate a ureteroscope during the operation, and a smaller caliber scope or a second-stage surgery is always a safer choice when confronting difficulties during ureteroscope advancement.

## CONCLUSION

The use of the Boari bladder flap is a feasible and preferred technique to manage complete ureteral avulsion. Maximal mobilization of the bladder and affected kidney followed by psoas hitch and downward nephropexy would maximize the success of a tension-free anastomosis, and thereby, minimize the need for ileal ureteral substitution or renal autotransplantation. However, more cases of ureteral avulsion on both sides with substantial experience are required to fully elucidate its limitations and make modifications accordingly.

## FOOTNOTES

**Author contributions:** Zhong MZ designed and drafted the manuscript; Huang WN contributed to manuscript revision; Huang GX, Zhang EP, and Gan L collected the clinical data; Zhong MZ, Huang GX, Zhang EP, and Gan L discussed management options for and provided medical care to the patient; all authors have read and approved the final manuscript.

**Informed consent statement:** Written informed consent was obtained from the patient for publication of this report and any accompanying images.

**Conflict-of-interest statement:** The authors declare that they have no conflict of interest to disclose.

**CARE Checklist (2016) statement:** The authors have read the CARE Checklist (2016), and the manuscript was prepared and revised according to the CARE Checklist (2016).

**Open-Access:** This article is an open-access article that was selected by an in-house editor and fully peer-reviewed by external reviewers. It is distributed in accordance with the Creative Commons Attribution NonCommercial (CC BY-NC 4.0) license, which permits others to distribute, remix, adapt, build upon this work non-commercially, and license their derivative works on different terms, provided the original work is properly cited and the use is non-commercial. See: <https://creativecommons.org/licenses/by-nc/4.0/>

**Country/Territory of origin:** China

**ORCID number:** Ming-Zhu Zhong 0000-0002-4041-7164.

**S-Editor:** Xing YX

**L-Editor:** Wang TQ

**P-Editor:** Xing YX

## REFERENCES

- 1 Yuan C, Li Z, Wang J, Zhang P, Meng C, Li D, Gao J, Guan H, Zhu W, Lu B, Zhang Z, Feng N, Yang K, Li X, Zhou L. Ileal ureteral replacement for the management of ureteral avulsion during ureteroscopic lithotripsy: a case series. *BMC Surg* 2022; **22**: 262 [PMID: 35799183 DOI: 10.1186/s12893-022-01690-0]
- 2 Ragonese M, Foschi N, Pinto F, Di Gianfrancesco L, Bassi P, Racioppi M. Immediate ileal ureter replacement for ureteral avulsion during ureteroscopy. *IJU Case Rep* 2020; **3**: 241-243 [PMID: 33163914 DOI: 10.1002/iju.12202]
- 3 Kuddah Y, Noegroho BS, Abriansyah AT, Mustafa A. Inverted mucosa and avulsion ureteral injury in ureteroscopic procedure: A very rare complication of a common procedure in urology. *Urol Case Rep* 2021; **37**: 101605 [PMID: 33665126 DOI: 10.1016/j.eucr.2021.101605]
- 4 Ordon M, Schuler TD, Honey RJ. Ureteral avulsion during contemporary ureteroscopic stone management: "the scabbard avulsion". *J Endourol* 2011; **25**: 1259-1262 [PMID: 21774664 DOI: 10.1089/end.2011.0008]
- 5 Gaizauskas A, Markevicius M, Gaizauskas S, Zelvyas A. Possible complications of ureteroscopy in modern endourological era: two-point or "scabbard" avulsion. *Case Rep Urol* 2014; **2014**: 308093 [PMID: 25610699 DOI: 10.1155/2014/308093]
- 6 Chung BI, Hamawy KJ, Zinman LN, Libertino JA. The use of bowel for ureteral replacement for complex ureteral reconstruction: long-term results. *J Urol* 2006; **175**: 179-83; discussion 183 [PMID: 16406903 DOI: 10.1016/S0022-5347(05)00061-3]
- 7 Kocot A, Kalogirou C, Vergho D, Riedmiller H. Long-term results of ileal ureteric replacement: a 25-year single-centre

- experience. *BJU Int* 2017; **120**: 273-279 [PMID: [28220579](#) DOI: [10.1111/bju.13825](#)]
- 8 **Zhong W**, Hong P, Ding G, Yang K, Li X, Bao J, Bao G, Cui L, Men C, Li Z, Zhang P, Chu N, Zhou L. Technical considerations and outcomes for ileal ureter replacement: a retrospective study in China. *BMC Surg* 2019; **19**: 9 [PMID: [30658620](#) DOI: [10.1186/s12893-019-0472-1](#)]
- 9 **Sevinc C**, Balaban M, Ozkaptan O, Yucetas U, Karadeniz T. The management of total avulsion of the ureter from both ends: Our experience and literature review. *Arch Ital Urol Androl* 2016; **88**: 97-100 [PMID: [27377083](#) DOI: [10.4081/aiua.2016.2.97](#)]
- 10 **Mauck RJ**, Hudak SJ, Terlecki RP, Morey AF. Central role of Boari bladder flap and downward nephropexy in upper ureteral reconstruction. *J Urol* 2011; **186**: 1345-1349 [PMID: [21855904](#) DOI: [10.1016/j.juro.2011.05.086](#)]
- 11 **Meng MV**, Freise CE, Stoller ML. Expanded experience with laparoscopic nephrectomy and autotransplantation for severe ureteral injury. *J Urol* 2003; **169**: 1363-1367 [PMID: [12629362](#) DOI: [10.1097/01.ju.0000054927.18678.5e](#)]
- 12 **Alizadeh M**, Valizadeh R, Rahimi MM. Immediate successful renal autotransplantation after proximal ureteral avulsion following ureteroscopy: a case report. *J Surg Case Rep* 2017; **2017**: rjx028 [PMID: [28458835](#) DOI: [10.1093/jscr/rjx028](#)]
- 13 **Shekarriz B**, Lu H, Duh Q, Freise CE, Stoller ML. Laparoscopic nephrectomy and autotransplantation for severe iatrogenic ureteral injuries. *Urology* 2001; **58**: 540-543 [PMID: [11597534](#) DOI: [10.1016/s0090-4295\(01\)01316-4](#)]
- 14 **Vrakas G**, Sullivan M. Current Review of Renal Autotransplantation in the UK. *Curr Urol Rep* 2020; **21**: 33 [PMID: [32666391](#) DOI: [10.1007/s11934-020-00986-z](#)]
- 15 **Yakupoglu YK**, Aki FT, Kordan Y, Ozden E, Tonyali S, Bostanci Y, Vuruskan H, Bilen CY, Sarikaya S. Renal Autotransplantation at Three Academic Institutions in Turkey. *Urol Int* 2016; **97**: 466-472 [PMID: [27505010](#) DOI: [10.1159/000448482](#)]
- 16 **Grzególkowski P**, Lemiński A, Słojewski M. Extended Boari-flap technique as a reconstruction method of total ureteric avulsion. *Cent European J Urol* 2017; **70**: 188-191 [PMID: [28721288](#) DOI: [10.5173/cej.2017.927](#)]
- 17 **Li Y**, Li C, Yang S, Song C, Liao W, Xiong Y. Reconstructing full-length ureteral defects using a spiral bladder muscle flap with vascular pedicles. *Urology* 2014; **83**: 1199-1204 [PMID: [24767531](#) DOI: [10.1016/j.urology.2014.01.027](#)]





Published by **Baishideng Publishing Group Inc**  
7041 Koll Center Parkway, Suite 160, Pleasanton, CA 94566, USA

**Telephone:** +1-925-3991568

**E-mail:** [bpgoffice@wjgnet.com](mailto:bpgoffice@wjgnet.com)

**Help Desk:** <https://www.f6publishing.com/helpdesk>

<https://www.wjgnet.com>

