

World Journal of *Clinical Cases*

World J Clin Cases 2022 December 6; 10(34): 12462-12803



Contents

Thrice Monthly Volume 10 Number 34 December 6, 2022

FIELD OF VISION

- 12462** Problematics of neurosurgical service during the COVID-19 pandemic in Slovenia
Munda M, Bosnjak R, Velnar T

MINIREVIEWS

- 12470** Circulating angiotensin converting enzyme 2 and COVID-19
Leowattana W, Leowattana T, Leowattana P
- 12484** Evaluation of gut dysbiosis using serum and fecal bile acid profiles
Monma T, Iwamoto J, Ueda H, Tamamushi M, Kakizaki F, Konishi N, Yara S, Miyazaki T, Hirayama T, Ikegami T, Honda A
- 12494** Pediatric kidney transplantation during the COVID-19 pandemic
Tamura H

ORIGINAL ARTICLE

Clinical and Translational Research

- 12500** *Coptis*, *Pinellia*, and *Scutellaria* as a promising new drug combination for treatment of *Helicobacter pylori* infection
Yu Z, Sheng WD, Yin X, Bin Y

Case Control Study

- 12515** Effects of illness perception on negative emotions and fatigue in chronic rheumatic diseases: Rumination as a possible mediator
Lu Y, Jin X, Feng LW, Tang C, Neo M, Ho RC

Retrospective Study

- 12532** Significance of incidental focal fluorine-18 fluorodeoxyglucose uptake in colon/rectum, thyroid, and prostate: With a brief literature review
Lee H, Hwang KH
- 12543** Follow-up study on ThinPrep cytology test-positive patients in tropical regions
Chen YC, Liang CN, Wang XF, Wang MF, Huang XN, Hu JD
- 12551** Effect of teach-back health education combined with structured psychological nursing on adverse emotion and patient cooperation during ^{99m}Tc -3PRGD2.SPECT/CT
Gong WN, Zhang YH, Niu J, Li XB
- 12559** Nosocomial infection and spread of SARS-CoV-2 infection among hospital staff, patients and caregivers
Cheng CC, Fann LY, Chou YC, Liu CC, Hu HY, Chu D

Observational Study

- 12566** Effectiveness and safety of generic and brand direct acting antivirals for treatment of chronic hepatitis C
Abdulla M, Al Ghareeb AM, Husain HAHY, Mohammed N, Al Qamish J

- 12578** Influence of group B *streptococcus* and vaginal cleanliness on the vaginal microbiome of pregnant women
Liao Q, Zhang XF, Mi X, Jin F, Sun HM, Wang QX

Randomized Controlled Trial

- 12587** Clinical study on tri-tongue acupuncture combined with low-frequency electrical stimulation for treating post-stroke dysarthria
Man B, Li WW, Xu JF, Wang Q

META-ANALYSIS

- 12594** Three-dimensional time-of-flight magnetic resonance angiography combined with high resolution T2-weighted imaging in preoperative evaluation of microvascular decompression
Liang C, Yang L, Zhang BB, Guo SW, Li RC

CASE REPORT

- 12605** Acute cytomegalovirus hepatitis in an immunocompetent patient: A case report
Wang JP, Lin BZ, Lin CL, Chen KY, Lin TJ
- 12610** Long-term results of extended Boari flap technique for management of complete ureteral avulsion: A case report
Zhong MZ, Huang WN, Huang GX, Zhang EP, Gan L
- 12617** Amyloid β -related angiitis of the central nervous system occurring after COVID-19 vaccination: A case report
Kizawa M, Iwasaki Y
- 12623** Pseudoileus caused by primary visceral myopathy in a Han Chinese patient with a rare *MYH11* mutation: A case report
Li N, Song YM, Zhang XD, Zhao XS, He XY, Yu LF, Zou DW
- 12631** Emergent use of tube tip in pharynx technique in "cannot intubate cannot oxygenate" situation: A case report
Lin TC, Lai YW, Wu SH
- 12637** Inflammatory myofibroblastic tumor of the central nervous system: A case report
Su ZJ, Guo ZS, Wan HT, Hong XY
- 12648** Atypical aggressive vertebral hemangioma of the sacrum with postoperative recurrence: A case report
Wang GX, Chen YQ, Wang Y, Gao CP
- 12654** Closed reduction of hip dislocation associated with ipsilateral lower extremity fractures: A case report and review of the literature
Xu Y, Lv M, Yu SQ, Liu GP

- 12665** Repair of a large patellar cartilage defect using human umbilical cord blood-derived mesenchymal stem cells: A case report
Song JS, Hong KT, Song KJ, Kim SJ
- 12671** Abdominal bronchogenic cyst: A rare case report
Li C, Zhang XW, Zhao CA, Liu M
- 12678** Malignant fibrous histiocytoma of the axilla with breast cancer: A case report
Gao N, Yang AQ, Xu HR, Li L
- 12684** Rapid hemostasis of the residual inguinal access sites during endovascular procedures: A case report
Kim H, Lee K, Cho S, Joh JH
- 12690** Formation of granulation tissue on bilateral vocal cords after double-lumen endotracheal intubation: A case report
Xiong XJ, Wang L, Li T
- 12696** Giant cellular leiomyoma in the broad ligament of the uterus: A case report
Yan J, Li Y, Long XY, Li DC, Li SJ
- 12703** Pomolidomide for relapsed/refractory light chain amyloidosis after resistance to both bortezomib and daratumumab: A case report
Li X, Pan XH, Fang Q, Liang Y
- 12711** Ureteral- artificial iliac artery fistula: A case report
Feng T, Zhao X, Zhu L, Chen W, Gao YL, Wei JL
- 12717** How to manage isolated tension non-surgical pneumoperitoneum during bronchoscopy? A case report
Baima YJ, Shi DD, Shi XY, Yang L, Zhang YT, Xiao BS, Wang HY, He HY
- 12726** Amiodarone-induced muscle tremor in an elderly patient: A case report
Zhu XY, Tang XH, Yu H
- 12734** Surgical treatment of Pitt-Hopkins syndrome associated with strabismus and early-onset myopia: Two case reports
Huang Y, Di Y, Zhang XX, Li XY, Fang WY, Qiao T
- 12742** Massive low-grade myxoid liposarcoma of the floor of the mouth: A case report and review of literature
Kugimoto T, Yamagata Y, Ohsako T, Hirai H, Nishii N, Kayamori K, Ikeda T, Harada H
- 12750** Gingival enlargement induced by cyclosporine in Medullary aplasia: A case report
Victory Rodríguez G, Ruiz Gutiérrez ADC, Gómez Sandoval JR, Lomeli Martínez SM
- 12761** Compound heterozygous mutations in PMFBP1 cause acephalic spermatozoa syndrome: A case report
Deng TQ, Xie YL, Pu JB, Xuan J, Li XM
- 12768** Colonic tubular duplication combined with congenital megacolon: A case report
Zhang ZM, Kong S, Gao XX, Jia XH, Zheng CN

- 12775** Perforated duodenal ulcer secondary to deferasirox use in a child successfully managed with laparoscopic drainage: A case report
Alshehri A, Alsinan TA
- 12781** Complication after nipple-areolar complex tattooing performed by a non-medical person: A case report
Byeon JY, Kim TH, Choi HJ
- 12787** Interventional urethral balloon dilatation before endoscopic visual internal urethrotomy for post-traumatic bulbous urethral stricture: A case report
Ha JY, Lee MS
- 12793** Regression of gastric endoscopic submucosal dissection induced polypoid nodular scar after *Helicobacter pylori* eradication: A case report
Jin BC, Ahn AR, Kim SH, Seo SY
- 12799** Congenital absence of the right coronary artery: A case report
Zhu XY, Tang XH

ABOUT COVER

Editorial Board Member of *World Journal of Clinical Cases*, Giuseppe Lanza, MD, MSc, PhD, Associate Professor, Department of Surgery and Medical-Surgical Specialties, University of Catania, Catania 95123, Italy.
glanza@oasi.en.it

AIMS AND SCOPE

The primary aim of *World Journal of Clinical Cases* (WJCC, *World J Clin Cases*) is to provide scholars and readers from various fields of clinical medicine with a platform to publish high-quality clinical research articles and communicate their research findings online.

WJCC mainly publishes articles reporting research results and findings obtained in the field of clinical medicine and covering a wide range of topics, including case control studies, retrospective cohort studies, retrospective studies, clinical trials studies, observational studies, prospective studies, randomized controlled trials, randomized clinical trials, systematic reviews, meta-analysis, and case reports.

INDEXING/ABSTRACTING

The WJCC is now abstracted and indexed in Science Citation Index Expanded (SCIE, also known as SciSearch®), Journal Citation Reports/Science Edition, Current Contents®/Clinical Medicine, PubMed, PubMed Central, Scopus, Reference Citation Analysis, China National Knowledge Infrastructure, China Science and Technology Journal Database, and Superstar Journals Database. The 2022 Edition of Journal Citation Reports® cites the 2021 impact factor (IF) for WJCC as 1.534; IF without journal self cites: 1.491; 5-year IF: 1.599; Journal Citation Indicator: 0.28; Ranking: 135 among 172 journals in medicine, general and internal; and Quartile category: Q4. The WJCC's CiteScore for 2021 is 1.2 and Scopus CiteScore rank 2021: General Medicine is 443/826.

RESPONSIBLE EDITORS FOR THIS ISSUE

Production Editor: Si Zhao; Production Department Director: Xu Guo; Editorial Office Director: Jin-Lei Wang.

NAME OF JOURNAL

World Journal of Clinical Cases

ISSN

ISSN 2307-8960 (online)

LAUNCH DATE

April 16, 2013

FREQUENCY

Thrice Monthly

EDITORS-IN-CHIEF

Bao-Gan Peng, Jerzy Tadeusz Chudek, George Kontogeorgos, Maurizio Serati, Ja Hyeon Ku

EDITORIAL BOARD MEMBERS

<https://www.wjnet.com/2307-8960/editorialboard.htm>

PUBLICATION DATE

December 6, 2022

COPYRIGHT

© 2022 Baishideng Publishing Group Inc

INSTRUCTIONS TO AUTHORS

<https://www.wjnet.com/bpg/gerinfo/204>

GUIDELINES FOR ETHICS DOCUMENTS

<https://www.wjnet.com/bpg/GerInfo/287>

GUIDELINES FOR NON-NATIVE SPEAKERS OF ENGLISH

<https://www.wjnet.com/bpg/gerinfo/240>

PUBLICATION ETHICS

<https://www.wjnet.com/bpg/GerInfo/288>

PUBLICATION MISCONDUCT

<https://www.wjnet.com/bpg/gerinfo/208>

ARTICLE PROCESSING CHARGE

<https://www.wjnet.com/bpg/gerinfo/242>

STEPS FOR SUBMITTING MANUSCRIPTS

<https://www.wjnet.com/bpg/GerInfo/239>

ONLINE SUBMISSION

<https://www.f6publishing.com>



How to manage isolated tension non-surgical pneumoperitonium during bronchoscopy? A case report

Yang-Jin Baima, Dan-Dan Shi, Xing-Ya Shi, Li Yang, Yun-Tao Zhang, Ba-Sang Xiao, He-Yan Wang, Hang-Yong He

Specialty type: Medicine, research and experimental

Provenance and peer review:

Unsolicited article; Externally peer reviewed.

Peer-review model: Single blind

Peer-review report's scientific quality classification

Grade A (Excellent): 0
Grade B (Very good): B
Grade C (Good): C, C, C
Grade D (Fair): 0
Grade E (Poor): 0

P-Reviewer: Agrawal P, United States; Ferreira GSA, Brazil; Ishida T, Japan

Received: August 31, 2022

Peer-review started: August 29, 2022

First decision: September 26, 2022

Revised: October 5, 2022

Accepted: October 31, 2022

Article in press: October 31, 2022

Published online: December 6, 2022



Yang-Jin Baima, Dan-Dan Shi, Xing-Ya Shi, Li Yang, Yun-Tao Zhang, Ba-Sang Xiao, Department of Pulmonary Medicine, Lhasa People's Hospital, Lhasa 850013, Tibet Autonomous Region, China

He-Yan Wang, Department of Critical Care Medicine, The Sixth Hospital of Guiyang, School of Basic Medicine, Guizhou University of Traditional Chinese Medicine, Guiyang 550002, Guizhou Province, China

Hang-Yong He, Department of Respiratory and Critical Care Medicine, Beijing Institute of Respiratory Medicine, Beijing Key Laboratory of Respiratory and Pulmonary Circulation, Beijing Chao-Yang Hospital, Capital Medical University, Beijing 100020, China

Corresponding author: Hang-Yong He, MD, Chief Physician, Department of Respiratory and Critical Care Medicine, Beijing Institute of Respiratory Medicine, Beijing Key Laboratory of Respiratory and Pulmonary Circulation, Beijing Chao-Yang Hospital, Capital Medical University, No. 8 Gongren Tiyechang Nanlu, Chaoyang District, Beijing 100020, China. yonghang2004@sina.com

Abstract

BACKGROUND

Tension pneumoperitonium is a rare complication during bronchoscopy that can cause acute respiratory and hemodynamic failure, with fatal consequences. Isolated pneumoperitonium during bronchoscopy usually results from ruptures of the abdominal viscera that need surgical repair. Non-surgical pneumoperitoneum (NSP) refers to some pneumoperitoneum that could be relieved without surgery and only by conservative therapy. However, the clinical experience of managing tension pneumoperitonium during bronchoscopy is limited and controversial.

CASE SUMMARY

A 51-year-old female was admitted to our hospital for cough with bloody sputum of seven days. On the 8th day of her admission, a bronchoscopy was arranged for bronchial-alveolar lavage to detect possible pathogens in the lower respiratory tract, as oxygen was delivered *via* a 12 F nasopharyngeal cannula, approximately 5-6 cm from the tip of the catheter, with a flow rate of 5-10 L/min. After four minutes of bronchoscopy, the patient suddenly vomited 20 mL of water, followed by severe abdominal pain, while physical examination revealed obvious

abdominal distension, as well as hardness and tenderness of the whole abdomen, which was considered pneumoperitonium, and the bronchoscopy was terminated immediately. A computer tomography scan indicated isolated tension pneumoperitonium, and abdominal decompression was performed with a drainage tube, after which her symptoms were relieved. A multidisciplinary expert consultation discussed her situation and a laparotomy was suggested, but finally refused by her family. She had no signs of peritonitis and was finally discharged 5 d after bronchoscopy with a good recovery.

CONCLUSION

The possibility of tension pneumoperitonium during bronchoscopy should be guarded against, and given its serious clinical consequences, cardiopulmonary instability should be treated immediately. Varied strategies could be adopted according to whether it is complicated with pneumothorax or pneumomediastinum, and the presence of peritonitis. When considering NSP, conservative therapy maybe a reasonable option with good recovery. An algorithm for the management of pneumoperitonium during bronchoscopy is proposed, based on the features of the case series reviewed and our case reported.

Key Words: Pneumoperitonium; Tension; Isolated; Non-surgical; Bronchoscopy; Case report

©The Author(s) 2022. Published by Baishideng Publishing Group Inc. All rights reserved.

Core Tip: Tension pneumoperitonium is a rare complication during bronchoscopy that can cause serious consequences. Isolated pneumoperitonium during bronchoscopy usually results from ruptures of the abdominal viscera that need surgical repair. Nonsurgical pneumoperitoneum (NSP) refers to some pneumoperitonium that could be relieved without surgery and only by conservative therapy. However, the clinical experience of managing tension pneumoperitonium during bronchoscopy is limited and controversial. Herein, we describe a rare case of isolated tension pneumoperitonium during bronchoscopy, which was recovered with no signs of peritonitis by conservative therapy. An algorithm for the management of pneumoperitonium during bronchoscopy is proposed.

Citation: Baima YJ, Shi DD, Shi XY, Yang L, Zhang YT, Xiao BS, Wang HY, He HY. How to manage isolated tension non-surgical pneumoperitonium during bronchoscopy? A case report. *World J Clin Cases* 2022; 10(34): 12717-12725

URL: <https://www.wjgnet.com/2307-8960/full/v10/i34/12717.htm>

DOI: <https://dx.doi.org/10.12998/wjcc.v10.i34.12717>

INTRODUCTION

Pneumoperitonium is a rare complication during bronchoscopy[1,2]. Tension pneumoperitonium may cause acute respiratory and hemodynamic failure[1,2], and can give rise to fatal consequences[3,4]. When pneumoperitonium is complicated with pneumothorax or pneumomediastinum, it is usually due to high positive pressure ventilation or airway/alveolar rupture[2,5]. Isolated pneumoperitonium during bronchoscopy is usually caused by ruptures of the abdominal viscera that need surgical repair[3,6]. Some pneumoperitonium could be relieved without surgery and only by conservative therapy, which is known as non-surgical pneumoperitoneum (NSP)[6]. When tension pneumoperitonium occurs during bronchoscopy, prompt diagnosis and life support should be performed, and whether it is an NSP should be confirmed, which may help the patient avoid surgical procedures and get a good recovery with conservative treatment[7]. However, given the limited and controversial clinical experience in the management of tension pneumoperitonium during bronchoscopy, we recount a rare case of isolated tension pneumoperitonium during bronchoscopy that was relieved by conservative therapy.

CASE PRESENTATION

Chief complaints

A 51-year-old female was admitted to our hospital for cough with bloody sputum of seven days.

History of present illness

A 51-year-old female was admitted to our hospital for cough with bloody sputum for 7 d, with chest pain, dyspnea after exercise, and with no fever.

History of past illness

Her past medical history includes right knee arthroplasty one month before admission, and tubal ligation for twenty-seven years.

Personal and family history

She had no trauma history, no other special diseases, or family genetic history.

Physical examination

Vital signs at admission: Temperature 36.3 °C, Pulse 98 bpm, respiratory rate (RR) 20 bpm, blood pressure (BP) 131/96 mmHg, pulse oxygen saturation (SpO₂) 81% (at room air), body mass index 28. She was alert, with moist rales in both lower lobe.

Laboratory examinations

At admission, her C reactive protein was 189.66 mg/L, Arterial Blood Gas showed pH 7.44, PaCO₂ 32.2 mmHg, PaO₂ 45 mmHg; Fibrinogen 5.59 g/L, D-dimer 2.41 mg/L. Her blood cell count, procalcitonin and brain natriuretic peptide were in normal range.

Imaging examinations

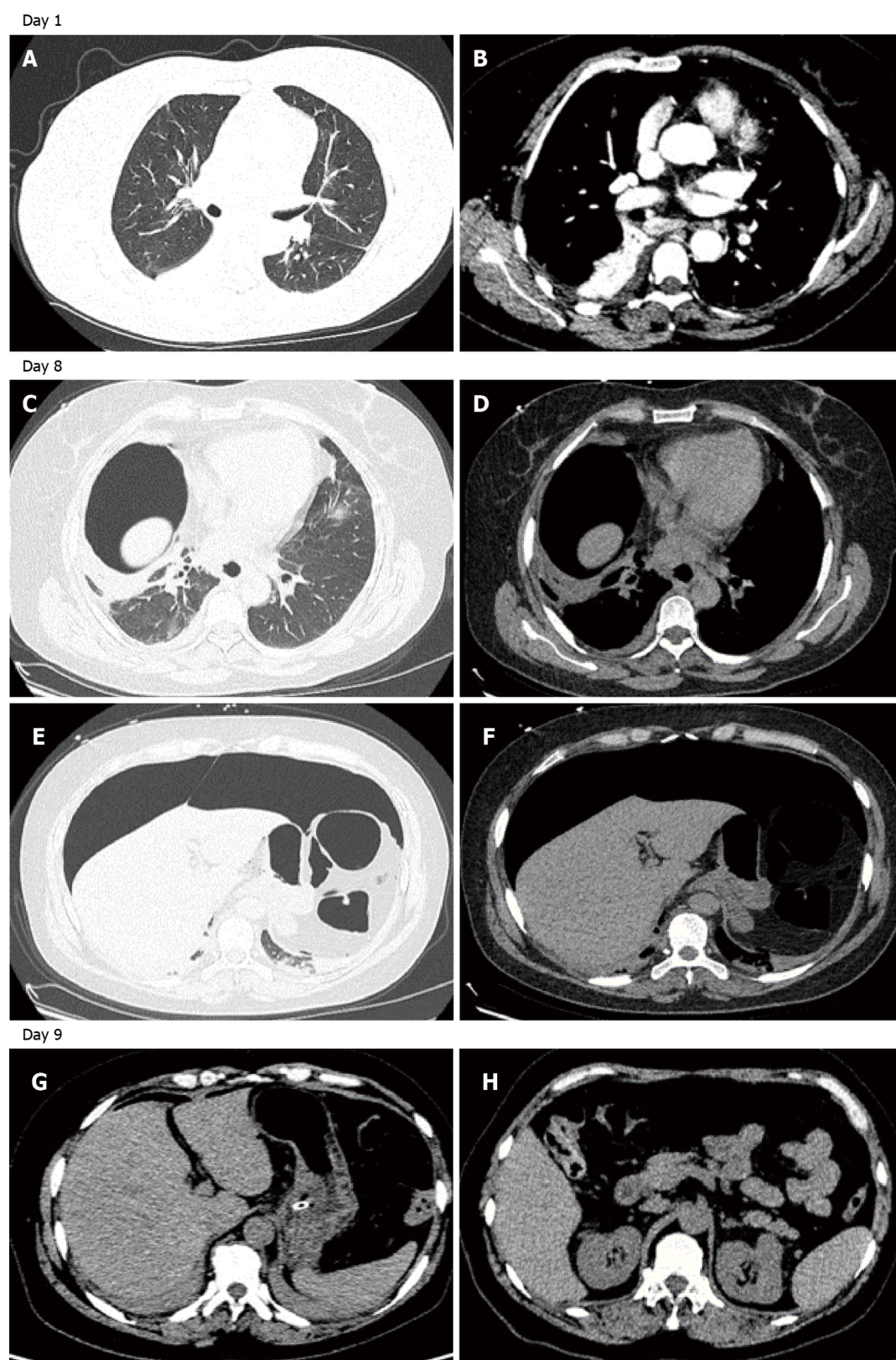
Her chest computer tomography (CT) showed infiltrates in the bilateral pulmonary lobes, localized consolidation in the right lower pulmonary lobe, and bilateral basal pleural effusions (**Figure 1A and B**).

FINAL DIAGNOSIS

Community-acquired pneumonia.

TREATMENT

She was treated with Amoxicillin-clavulanate 1.2 g every eight hours for one week. Sputum cultures were obtained prior to antibiotic treatment and were not found to be positive. And as the patient did not have a high fever on admission, no blood culture was obtained. On the 8th day of her admission, a bronchoscopy was arranged for bronchial-alveolar lavage to detect the possible pathogens in the lower respiratory tract. Local anesthesia was initially administered with lidocaine 2% aerosol inhalation for 30 min. Midazolam 3 mg was injected intravenously 1 min before the operation, and oxygen was supplied via a 12 F nasopharyngeal cannula (NPC), approximately 5-6 cm from the tip of the catheter to the nostril, with the oxygen flow rate of 5-10 L/min. Preoperative vital signs were BP 125/86 mmHg, pulse 90 bpm, RR 16 bpm, SpO₂ 88% (with NPC 5 L/min). After four minutes of bronchoscopy, the patient suddenly vomited 20 mL of water, followed by severe abdominal pain. Vital signs were BP 195/91 mmHg, pulse 135 bpm, RR 25 bpm, SpO₂ 89%. She was immediately given nimodipine, and the flow of oxygen was increased to 15 L/min, with consideration of treatment in the intensive care unit, including ventilator management. Physical examination revealed obvious abdominal distension, as well as hardness and tenderness of the whole abdomen. Pneumoperitonium was considered and the bronchoscopy was stopped immediately, followed by emergency decompression by inserting a gastric tube for gastrointestinal (GI) decompression. Ultrasound of the abdomen indicated a tension pneumoperitonium with no significant effusion, while thoracic and abdominal CT scans indicate massive gas accumulation in the abdominal cavity with no pneumothorax or pneumomediastinum (**Figure 1C-F**). An abdominal decompression with a drainage tube into the abdominal cavity was therefore performed. The drainage tube was a single lumen catheter (8 Fr) inserted percutaneously with a needle and guidewire, and was kept in place for 2 d. And the patient was sent back to the general ward with relief of symptoms. Six hours after which, the patient presented with approximately 20 mL of coffee-colored vomit with no signs of peritonitis. A multidisciplinary expert consultation discussed her situation and a laparotomy was suggested, but finally refused by her family. A contrast abdominal CT scan was done the following day (Day 9), which showed much less gas in the abdominal cavity than on the previous day's CT (**Figure 1G and H**).



DOI: 10.12998/wjcc.v10.i34.12717 Copyright ©The Author(s) 2022.

Figure 1 Chest and abdominal computed tomography scan of the patient on day 1, day 8, and day 9. A and B: Thoracic enhanced computed tomography (CT)-scan on admission showed infiltration and fibrotic foci were scattered in the bilateral pulmonary lobe, with localized consolidation of the right lower lobe, and bilateral pleural effusions; C-F: Thoracic and abdominal CT-scan on day 8 taken after needle decompression demonstrating the presence of a large anterior pneumoperitoneum without fluid collections and pneumothorax or pneumomediastinum; G and H: Abdominal enhanced CT-scan on day 9 showed gas accumulation in the right abdominal wall, free gas in the abdominal cavity is less than in the previous CT exam.

OUTCOME AND FOLLOW-UP

The subsequent clinical course was uneventful. Her bronchoalveolar lavage fluid sample was negative for metagenomic next generation sequencing (mNGS), ruling out corona virus disease 2019, tuberculosis, or nontuberculous mycobacterial infection. With mycoplasma pneumoniae detected by mNGS, moxifloxacin was given to her. And the patient was eventually discharged 5 d after bronchoscopy and recovered well.

DISCUSSION

Pneumoperitonium was a rare complication during bronchoscopy. We searched Pubmed data base and found only eight cases were reported during the last 20 years. As shown in [Table 1](#), eight previously published cases and the current case with pneumoperitonium during bronchoscopy were reviewed. A total of nine cases were reported, including eight adults and one child. 22% (2/9) of the patients had pneumoperitonium during rigid bronchoscopy, while 78% had it at fiberoptic bronchoscopy. Four patients (44%) underwent transbronchial lung biopsy (TBLB) or transbronchial needle aspiration (TBNA). NPC was the most common oxygen supply method in six patients (66%), while the remaining one and two patients used a bag mask and mechanical ventilation (MV), respectively. In addition, sudden onset of abdominal pain or distension was the most common clinical presentation, as shown in three and five patients, respectively. However, a cardiorespiratory arrest was present in one case. Only 4 (44%) patients had isolated pneumoperitonium, and pneumothorax/pneumomediastinum were complicated with pneumoperitonium in the other 5 cases. Most of the reported cases were tension pneumoperitonium. Hypotension and respiratory failure were also present in five cases. Six patients were intubated after pneumoperitonium, while only one patient died after pneumoperitonium and the other eight recovered well. Four patients had laparotomy/laparoscopy, and gastric ruptures were found in only 3 cases.

The mechanism of pneumoperitonium during bronchoscopy is manifested by high-pressure air in the ruptured airway, alveoli, or hollow viscus[5,8,9]. In some cases, such as rigid bronchoscopy[5,8], TBLB [1], TBNA[2,6], or foreign body removal[5], pneumoperitonium occurs as an intro-airway procedural complication. Damage to the airway or the alveoli may occur due to these procedures, leading to pneumoperitonium[10]. Also, pneumothorax and pneumomediastinum could be found more frequently in these types of pneumoperitonium[11-15]. Additionally, the “Macklin” effect is one of the mechanisms related to pneumothorax or pneumomediastinum complicated with pneumoperitonium[16].

Isolated pneumoperitonium without complicated pneumothorax or pneumomediastinum is more likely to be associated with an air source from the lesion of GI tract[3,8]. However, one previously reported case showed that isolated pneumoperitonium could also be seen after TBNA[6]. Therefore, when isolated pneumoperitonium was present during bronchoscopy without an intro-airway procedure, it should be considered that there is a high possibility that the pneumoperitonium is of GI source. It was described[17] that some patients undergoing bronchoscopy under sedation and oxygen delivery by NPC experienced the development of pneumoperitoneum secondary to gastric rupture due to multiple factors, such as the reduced muscle tone in the pharynx induced by anesthesia, and thus air entering the stomach with one-way valve mechanism, resulting in NPC dislocation in the esophagus. With these risk factors, the large amounts of air supplied by the oxygen supply tube may enter the GI tract, inducing high air pressure in the hollow viscus and eventually leading to perforation at its most vulnerable site of the gastrointestinal wall. And it was speculated that when the perforation occurs in the ventral side of the GI tract, and most patients have very little content left in the GI tract after the bronchoscopy preparation, air could be the only substance that leaks into the peritoneum, with no other GI content entering into the peritoneum and causing peritonitis.

Tension pneumoperitonium was reported in the majority of the cases we reviewed, and in more than half of these cases there was acute circulatory or respiratory failure[3,4,6,8] or cardiopulmonary arrest [9], which may lead to a fatal outcome[18]. The initial step in treatment should be prompt resuscitation and life support. Tension barotrauma should be confirmed by radiological examination as soon as possible after the patient's vital signs have stabilized. At the same time, a needle or tube decompression should be considered for a better venous return and respiratory compliance, which could further improve the cardiopulmonary status. If a tension pneumoperitonium is caused by gastric or intestinal microperforation, showing only pneumoperitoneum during bronchoscopy without signs of peritonitis, non-surgical pneumoperitonium should be considered, and it could be cured by a needle or tube decompression[6].

Only four out of the nine patients with pneumoperitonium eventually underwent laparotomy or laparoscopy in our review. Three of the patients who underwent laparotomy that were confirmed gastric rupture but got repaired and recovered well, while the other patient died when his family refused the laparotomy. In addition to this, four patients who were radiologically found negative to have visceral rupture were closely monitored and eventually diagnosed with NSP and recovered with conservative therapy. Therefore, it should always be borne in mind that NSP is a form of pneumoperi-

Table 1 Case series reported pneumoperitoneum associated with bronchoscopy

Ref.	Age	Sex	BSP type	Biopsy procedure	O2 supply	Symptoms during BSP	PT or PM	Isolated PP	Tension PP	Respiratory or hemodynamic failure	Intubaion and MV	Viscus rupture	Laparotomy or Conservative treatment	Outcome
Nikolaev <i>et al</i> [1], 2003	82	F	Fiberoptic	TBLB	NPC	Sudden stuporotic bradycardic	PT + PM	No	Yes	No	Intubation air-bag	No	Laparoscopy	Discharged 3 d later
Abraham <i>et al</i> [2], 2011	76	F	Fiberoptic	TBNA	NPC	Abdominal pain	PM	No	Yes	No	No	No	Conservative observation in ICU	Discharged 2 d later
Dastidar[5], 2013	14 mo	M	Rigid	Foreign body removal	MV	Distended abdomen	PT + PM	No	No	No	Aborted	No	Conservative observation in ICU	Discharged 1 d later
Bednarz <i>et al</i> [8], 2015	42	F	Rigid	No	Bag mask	Respiratory arrest distended abdomen	No	Yes	Yes	RF and shock	Intubation	Gastric rupture	Emergent laparotomy	Recovered
El-kersh and Karnib[3], 2017	61	F	Fiberoptic	No	NPC	Abdominal pain tachycardia tachypnea	No	Yes	Yes	RF	Intubation	Gastric rupture	Emergent laparotomy	Recovered
Muriana <i>et al</i> [6], 2018	80	M	Fiberoptic	EBUS TBNA	NPC	Distended abdomen severe bradycardia arterial hypotension	No	Yes	Yes	RF and shock	Intubation	No	Needle decompression	Discharged 13 d later
Po <i>et al</i> [4], 2021	80	M	Fiberoptic	BALF	MV	Distended abdomen persistent hypotension	PM	No	Yes	Shock	Intubation	NA	Refused laparotomy by family	Died
Pereira <i>et al</i> [9], 2021	61	F	Fiberoptic	No	NPC	Sudden abdominal distension; cardiorespiratory arrest	PT + PM	No	Yes	RF and shock	Bag-mask ventilation & intubation	Gastric laceration	Needle decompression exploratory laparotomy	Discharged 4 d later
This case	51	F	Fiberoptic	No	NPC	Abdominal pain	No	Yes	Yes	No	No	No	Needle decompression	Discharged 5 d later
In summary	42-82 yr	F 6 M 3	Fiberoptic 7 Rigid 2	TBLB 1 TBNA 2 Foreign body 1	NPC 6 MV 2 bag mask 1	Abdominal pain 3 Distended abdomen 5 hypotension 2 cardiorespiratory arrest 1	PT + PM 3 PM 2 No 4	No 5 Yes 4	Yes 9 No 1	RF + shock 3 RF 1 Shock 1 No 4	Intubation 6 No 2	Gastric rupture 3 No 6	Conservative observation 2 Laparotomy 4 Needle decompression3	Discharged 8 Died 1

BSP: Bronchoscopy; IV: Intravenous; TBLB: Transbronchial lung biopsy; PT: Pneumothorax; PM: Pneumomediastinum; PP: Pneumoperitonium; MV: Mechanical ventilation; EBUS: Endobronchial ultrasound guidance; TBNA: Tranbronchila needle aspiration; NA: Not available; NPC: Nasopharyngeal cannula; RF: Respiratory failure.

tonium complicated with bronchoscopy, for which surgical procedure could be avoided with a good outcome[6,7,19].

High flow oxygen supply or high positive pressure ventilation maybe a significant cause of pneumoperitonium during bronchoscopy[20]. Besides, mechanical ventilation, bag-mask ventilation, and high flow NPC have also been reported as causes of pneumoperitonium in other clinical circumstances, such as sedation or surgical procedures[14,20]. NPC was considered the most probable cause of

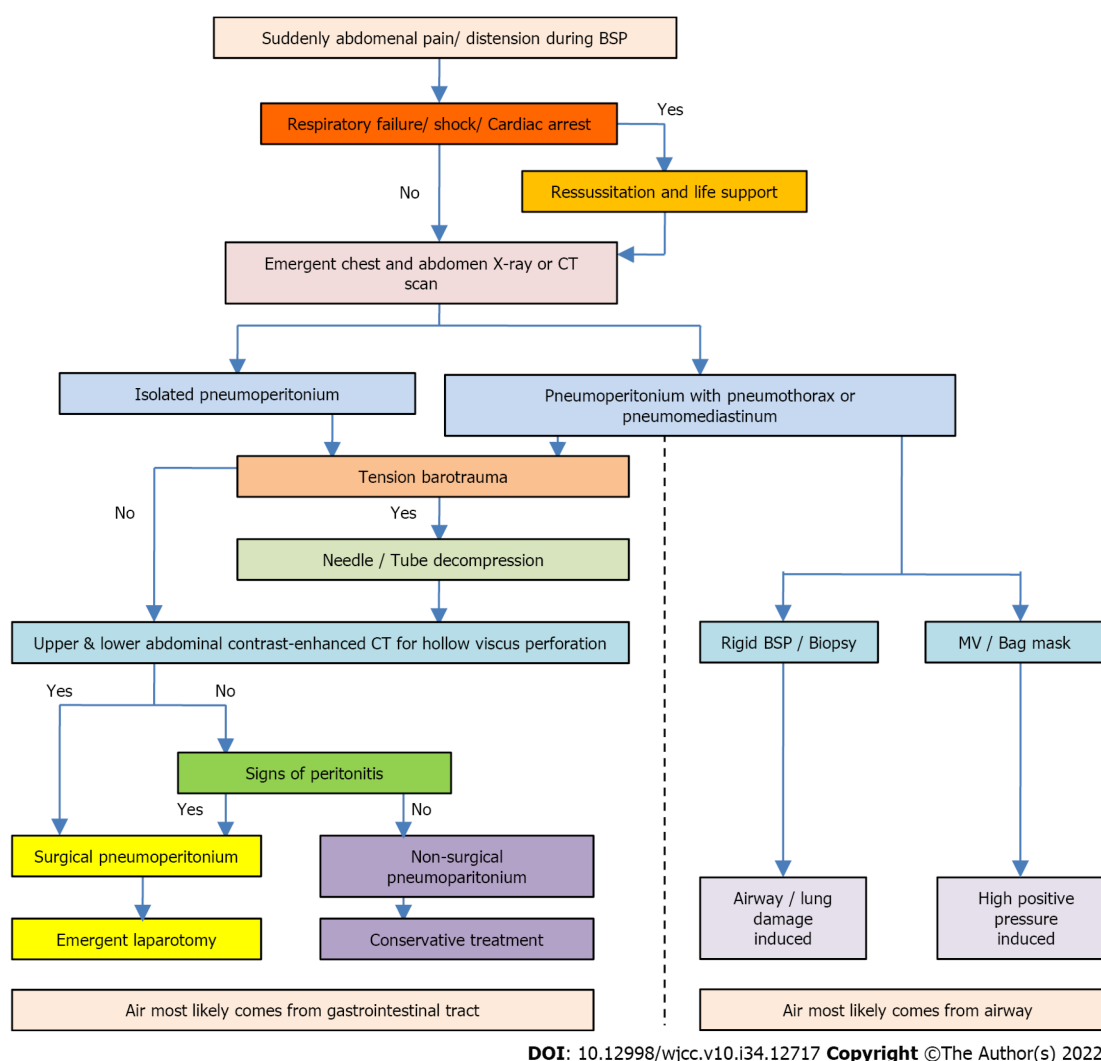


Figure 2 Protocol for the management of pneumoperitonium during bronchoscopy. BSP: Bronchoscopy; MV: Mechanical ventilation; CT: Computed tomography.

isolated pneumoperitonium during bronchoscopy without biopsy in three cases, based on our review of previous cases, including the case we report here. Therefore, clinicians should be aware of the risk of pneumoperitonium when a high flow NPC oxygen supply is used during bronchoscopy and should monitor this complication closely during the procedure. And furthermore, not only should cardiopulmonary monitoring and resuscitation kits be prepared, but decompression kits should be prepared at the bedside during bronchoscopy for high-risk patients undergoing, for example, high flow NPC, positive ventilation, deep sedation, and invasive procedures. And when using NPC oxygenation, confirm the position of the catheter.

A protocol for the management of pneumoperitonium during bronchoscopy is proposed in **Figure 2**, based on the features of the case series reviewed and our case reported.

CONCLUSION

In summary, due to the serious clinical consequences, attention should be paid to the possibility of tension pneumoperitonium during bronchoscopy while the unstable cardiopulmonary status should be treated immediately. And meanwhile, varied treatments could be adopted according to whether pneumoperitonium is complicated with pneumothorax or pneumomediastinum, and whether there are signs of persistent peritonitis. When NSP is considered, conservative therapy maybe a reasonable option with good recovery. Furthermore, patients at high risk should be closely monitored.

FOOTNOTES

Author contributions: All authors made substantial contributions to conception and design, acquisition of data, or analysis and interpretation of data, reviewed and approved the final manuscript, contributed significantly to this study; Wang HY and He HY take full responsibility for the integrity of the submission and publication, and are involved in the study design; Shi DD, Baima YJ, Wang HY and He HY had full access to all the data in the study and took responsibility for the integrity of the data and the accuracy of the data analysis, and were responsible for data verification, analysis, and drafting of the manuscript; Zhang YT, Yang L and Xiao BS had full access to all the data in the study and took responsibility for the integrity of the data and the accuracy of the data analysis; Shi DD and Baima YJ were responsible for the data collection; Baima YJ and Shi DD made equal contributions.

Supported by Science and Technology Program of Tibet Autonomous Region, No. XZ202201ZY0037G.

Informed consent statement: Informed written consent was obtained from the patient for publication of this report and any accompanying images.

Conflict-of-interest statement: All the authors report no relevant conflicts of interest for this article.

CARE Checklist (2016) statement: The authors have read the CARE Checklist (2016), and the manuscript was prepared and revised according to the CARE Checklist (2016).

Open-Access: This article is an open-access article that was selected by an in-house editor and fully peer-reviewed by external reviewers. It is distributed in accordance with the Creative Commons Attribution NonCommercial (CC BY-NC 4.0) license, which permits others to distribute, remix, adapt, build upon this work non-commercially, and license their derivative works on different terms, provided the original work is properly cited and the use is non-commercial. See: <https://creativecommons.org/licenses/by-nc/4.0/>

Country/Territory of origin: China

ORCID number: Yang-Jin Baima 0000-0003-0418-5818; Dan-Dan Shi 0000-0001-8107-8974; Xing-Ya Shi 0000-0003-1552-7609; Li Yang 0000-0002-8305-4770; Yun-Tao Zhang 0000-0002-9461-6767; Ba-Sang Xiao 0000-0001-9240-0615; He-Yan Wang 0000-0003-0797-9234; Hang-Yong He 0000-0001-9972-0929.

S-Editor: Wei ZH

L-Editor: A

P-Editor: Wei ZH

REFERENCES

- 1 Nikolaev IS, Zamir D, Weiler Z. Pneumoperitoneum complicating bronchoscopy. *Isr Med Assoc J* 2003; **5**: 131-132 [PMID: 12674668]
- 2 Abraham GE 3rd, Sumrall BH, Bowling MR. The air apparent: a rare complication during flexible bronchoscopy. *Am J Med Sci* 2011; **341**: 243-245 [PMID: 21446082 DOI: 10.1097/maj.0b013e3182019f7a]
- 3 El-Kersh K, Karnib H. Tension Pneumoperitoneum Associated with Nasopharyngeal Catheter Oxygen Delivery during Bronchoscopy. *Am J Respir Crit Care Med* 2017; **196**: 785-786 [PMID: 28661180 DOI: 10.1164/rccm.201701-0181IM]
- 4 Po PL, Bai HF, Lin CH, Lin CC. Pneumomediastinum that progression to tension pneumoperitoneum after bronchioloalveolar lavage: A case report. *Respir Med Case Rep* 2021; **32**: 101341 [PMID: 33489748 DOI: 10.1016/j.rmcr.2021.101341]
- 5 Dastidar A. Pneumomediastinum, pneumoperitoneum and pneumothorax following iatrogenic perforation of bronchus: successful conservative management of a potentially serious complication. *J Pediatr Surg* 2013; **48**: 456-458 [PMID: 23414886 DOI: 10.1016/j.jpedsurg.2012.11.042]
- 6 Muriana P, Carretta A, Ciriaco P, Rossetti F, Negri G. Isolated tension pneumoperitoneum following endobronchial ultrasound-guided transbronchial needle aspiration complicated by cardiac peri-arrest: A case report. *Monaldi Arch Chest Dis* 2018; **88**: 999 [PMID: 30539597 DOI: 10.4081/monaldi.2018.999]
- 7 Ahmed K, Amine EG, Abdelbaki A, Jihene A, Khaoula M, Yamina H, Mohamed B. Airway management: induced tension pneumoperitoneum. *Pan Afr Med J* 2016; **25**: 125 [PMID: 28292087 DOI: 10.11604/pamj.2016.25.125.9038]
- 8 Bednarsz S, Filipovic M, Schoch O, Mauermann E. Gastric rupture after bag-mask-ventilation. *Respir Med Case Rep* 2015; **16**: 1-2 [PMID: 26744639 DOI: 10.1016/j.rmcr.2015.05.014]
- 9 Pereira IS, Ferreira L, Tinoco E, Shiang T, Oliveira A, Pereira AI. Gastric rupture during fiberoptic bronchoscopy, a rare complication of oxygen administration by nasopharyngeal cannula: a case report. *Braz J Anesthesiol* 2021; **1**-3 [PMID: 34973305 DOI: 10.1016/j.bjane.2021.12.009]
- 10 Mancino L, Michieletto L, Trani B, Zamperlin A, Ceron L. Pneumomediastinum after transbronchial lung biopsy. *J Bronchology Interv Pulmonol* 2010; **17**: 167-168 [PMID: 23168738 DOI: 10.1097/LBR.0b013e3181da29ea]
- 11 Naughton M, Irving L, McKenzie A. Pneumomediastinum after a transbronchial biopsy. *Thorax* 1991; **46**: 606-607 [PMID: 1926036 DOI: 10.1136/thx.46.8.606]
- 12 Lantsberg L, Rosenzweig V. Pneumomediastinum causing pneumoperitoneum. *Chest* 1992; **101**: 1176 [PMID: 1555448 DOI: 10.1378/chest.101.4.1176]

- 13 **Kourounis G**, Lim QX, Rashid T, Gurunathan S. A rare case of simultaneous pneumoperitoneum and pneumomediastinum with a review of the literature. *Ann R Coll Surg Engl* 2017; **99**: e241-e243 [PMID: [29022798](#) DOI: [10.1308/rcsann.2017.0165](#)]
- 14 **Fraipont V**, Lambermont B, Ghaye B, Moonen M, Edzang L, D'Orio V, Marcelle R. Unusual complication after percutaneous dilatational tracheostomy: pneumoperitoneum with abdominal compartment syndrome. *Intensive Care Med* 1999; **25**: 1334-1335 [PMID: [10654224](#) DOI: [10.1007/s001340051071](#)]
- 15 **Madan K**, Mehta S, Gupta N, Hadda V, Mohan A, Guleria R. Pneumomediastinum and Extensive Subcutaneous Emphysema after Cryoprobe Transbronchial Lung Biopsy. *Ann Am Thorac Soc* 2016; **13**: 2101-2103 [PMID: [27831814](#) DOI: [10.1513/AnnalsATS.201605-395LE](#)]
- 16 **Romero KJ**, Trujillo MH. Spontaneous pneumomediastinum and subcutaneous emphysema in asthma exacerbation: The Macklin effect. *Heart Lung* 2010; **39**: 444-447 [PMID: [20561891](#) DOI: [10.1016/j.hrtlng.2009.10.001](#)]
- 17 **Giménez Velando A**, Rodríguez Nieto MJ, Flandes Aldeyturriaga J. Gastric Perforation During Bronchoscopy For The Delivery Of Oxygen Therapy By Nasopharyngeal Cannula. *Arch Bronconeumol (Engl Ed)* 2018; **54**: 293-294 [PMID: [29198602](#) DOI: [10.1016/j.arbres.2017.10.010](#)]
- 18 **Gross A**, Diacon AH. Cardiac tamponade following transbronchial needle aspiration. *Respiration* 2011; **82**: 56-59 [PMID: [21430355](#) DOI: [10.1159/000323870](#)]
- 19 **Mularski RA**, Sippel JM, Osborne ML. Pneumoperitoneum: a review of nonsurgical causes. *Crit Care Med* 2000; **28**: 2638-2644 [PMID: [10921609](#) DOI: [10.1097/00003246-200007000-00078](#)]
- 20 **Chapman N**. Gastric rupture and pneumoperitoneum caused by oxygen insufflation via a fiberoptic bronchoscope. *Anesth Analg* 2008; **106**: 1592 [PMID: [18420894](#) DOI: [10.1213/ane.0b013e31816a3111](#)]



Published by **Baishideng Publishing Group Inc**
7041 Koll Center Parkway, Suite 160, Pleasanton, CA 94566, USA

Telephone: +1-925-3991568

E-mail: bpgoffice@wjgnet.com

Help Desk: <https://www.f6publishing.com/helpdesk>

<https://www.wjgnet.com>

