

World Journal of *Clinical Cases*

World J Clin Cases 2022 December 6; 10(34): 12462-12803



Contents

Thrice Monthly Volume 10 Number 34 December 6, 2022

FIELD OF VISION

- 12462** Problematics of neurosurgical service during the COVID-19 pandemic in Slovenia
Munda M, Bosnjak R, Velnar T

MINIREVIEWS

- 12470** Circulating angiotensin converting enzyme 2 and COVID-19
Leowattana W, Leowattana T, Leowattana P
- 12484** Evaluation of gut dysbiosis using serum and fecal bile acid profiles
Monma T, Iwamoto J, Ueda H, Tamamushi M, Kakizaki F, Konishi N, Yara S, Miyazaki T, Hirayama T, Ikegami T, Honda A
- 12494** Pediatric kidney transplantation during the COVID-19 pandemic
Tamura H

ORIGINAL ARTICLE

Clinical and Translational Research

- 12500** *Coptis*, *Pinellia*, and *Scutellaria* as a promising new drug combination for treatment of *Helicobacter pylori* infection
Yu Z, Sheng WD, Yin X, Bin Y

Case Control Study

- 12515** Effects of illness perception on negative emotions and fatigue in chronic rheumatic diseases: Rumination as a possible mediator
Lu Y, Jin X, Feng LW, Tang C, Neo M, Ho RC

Retrospective Study

- 12532** Significance of incidental focal fluorine-18 fluorodeoxyglucose uptake in colon/rectum, thyroid, and prostate: With a brief literature review
Lee H, Hwang KH
- 12543** Follow-up study on ThinPrep cytology test-positive patients in tropical regions
Chen YC, Liang CN, Wang XF, Wang MF, Huang XN, Hu JD
- 12551** Effect of teach-back health education combined with structured psychological nursing on adverse emotion and patient cooperation during ^{99m}Tc -3PRGD2.SPECT/CT
Gong WN, Zhang YH, Niu J, Li XB
- 12559** Nosocomial infection and spread of SARS-CoV-2 infection among hospital staff, patients and caregivers
Cheng CC, Fann LY, Chou YC, Liu CC, Hu HY, Chu D

Observational Study

- 12566** Effectiveness and safety of generic and brand direct acting antivirals for treatment of chronic hepatitis C
Abdulla M, Al Ghareeb AM, Husain HAHY, Mohammed N, Al Qamish J
- 12578** Influence of group B *streptococcus* and vaginal cleanliness on the vaginal microbiome of pregnant women
Liao Q, Zhang XF, Mi X, Jin F, Sun HM, Wang QX

Randomized Controlled Trial

- 12587** Clinical study on tri-tongue acupuncture combined with low-frequency electrical stimulation for treating post-stroke dysarthria
Man B, Li WW, Xu JF, Wang Q

META-ANALYSIS

- 12594** Three-dimensional time-of-flight magnetic resonance angiography combined with high resolution T2-weighted imaging in preoperative evaluation of microvascular decompression
Liang C, Yang L, Zhang BB, Guo SW, Li RC

CASE REPORT

- 12605** Acute cytomegalovirus hepatitis in an immunocompetent patient: A case report
Wang JP, Lin BZ, Lin CL, Chen KY, Lin TJ
- 12610** Long-term results of extended Boari flap technique for management of complete ureteral avulsion: A case report
Zhong MZ, Huang WN, Huang GX, Zhang EP, Gan L
- 12617** Amyloid β -related angiitis of the central nervous system occurring after COVID-19 vaccination: A case report
Kizawa M, Iwasaki Y
- 12623** Pseudoileus caused by primary visceral myopathy in a Han Chinese patient with a rare *MYH11* mutation: A case report
Li N, Song YM, Zhang XD, Zhao XS, He XY, Yu LF, Zou DW
- 12631** Emergent use of tube tip in pharynx technique in "cannot intubate cannot oxygenate" situation: A case report
Lin TC, Lai YW, Wu SH
- 12637** Inflammatory myofibroblastic tumor of the central nervous system: A case report
Su ZJ, Guo ZS, Wan HT, Hong XY
- 12648** Atypical aggressive vertebral hemangioma of the sacrum with postoperative recurrence: A case report
Wang GX, Chen YQ, Wang Y, Gao CP
- 12654** Closed reduction of hip dislocation associated with ipsilateral lower extremity fractures: A case report and review of the literature
Xu Y, Lv M, Yu SQ, Liu GP

- 12665** Repair of a large patellar cartilage defect using human umbilical cord blood-derived mesenchymal stem cells: A case report
Song JS, Hong KT, Song KJ, Kim SJ
- 12671** Abdominal bronchogenic cyst: A rare case report
Li C, Zhang XW, Zhao CA, Liu M
- 12678** Malignant fibrous histiocytoma of the axilla with breast cancer: A case report
Gao N, Yang AQ, Xu HR, Li L
- 12684** Rapid hemostasis of the residual inguinal access sites during endovascular procedures: A case report
Kim H, Lee K, Cho S, Joh JH
- 12690** Formation of granulation tissue on bilateral vocal cords after double-lumen endotracheal intubation: A case report
Xiong XJ, Wang L, Li T
- 12696** Giant cellular leiomyoma in the broad ligament of the uterus: A case report
Yan J, Li Y, Long XY, Li DC, Li SJ
- 12703** Pomolidomide for relapsed/refractory light chain amyloidosis after resistance to both bortezomib and daratumumab: A case report
Li X, Pan XH, Fang Q, Liang Y
- 12711** Ureteral- artificial iliac artery fistula: A case report
Feng T, Zhao X, Zhu L, Chen W, Gao YL, Wei JL
- 12717** How to manage isolated tension non-surgical pneumoperitoneum during bronchoscopy? A case report
Baima YJ, Shi DD, Shi XY, Yang L, Zhang YT, Xiao BS, Wang HY, He HY
- 12726** Amiodarone-induced muscle tremor in an elderly patient: A case report
Zhu XY, Tang XH, Yu H
- 12734** Surgical treatment of Pitt-Hopkins syndrome associated with strabismus and early-onset myopia: Two case reports
Huang Y, Di Y, Zhang XX, Li XY, Fang WY, Qiao T
- 12742** Massive low-grade myxoid liposarcoma of the floor of the mouth: A case report and review of literature
Kugimoto T, Yamagata Y, Ohsako T, Hirai H, Nishii N, Kayamori K, Ikeda T, Harada H
- 12750** Gingival enlargement induced by cyclosporine in Medullary aplasia: A case report
Victory Rodríguez G, Ruiz Gutiérrez ADC, Gómez Sandoval JR, Lomeli Martínez SM
- 12761** Compound heterozygous mutations in PMFBP1 cause acephalic spermatozoa syndrome: A case report
Deng TQ, Xie YL, Pu JB, Xuan J, Li XM
- 12768** Colonic tubular duplication combined with congenital megacolon: A case report
Zhang ZM, Kong S, Gao XX, Jia XH, Zheng CN

- 12775** Perforated duodenal ulcer secondary to deferasirox use in a child successfully managed with laparoscopic drainage: A case report
Alshehri A, Alsinan TA
- 12781** Complication after nipple-areolar complex tattooing performed by a non-medical person: A case report
Byeon JY, Kim TH, Choi HJ
- 12787** Interventional urethral balloon dilatation before endoscopic visual internal urethrotomy for post-traumatic bulbous urethral stricture: A case report
Ha JY, Lee MS
- 12793** Regression of gastric endoscopic submucosal dissection induced polypoid nodular scar after *Helicobacter pylori* eradication: A case report
Jin BC, Ahn AR, Kim SH, Seo SY
- 12799** Congenital absence of the right coronary artery: A case report
Zhu XY, Tang XH

ABOUT COVER

Editorial Board Member of *World Journal of Clinical Cases*, Giuseppe Lanza, MD, MSc, PhD, Associate Professor, Department of Surgery and Medical-Surgical Specialties, University of Catania, Catania 95123, Italy.
glanza@oasi.en.it

AIMS AND SCOPE

The primary aim of *World Journal of Clinical Cases* (WJCC, *World J Clin Cases*) is to provide scholars and readers from various fields of clinical medicine with a platform to publish high-quality clinical research articles and communicate their research findings online.

WJCC mainly publishes articles reporting research results and findings obtained in the field of clinical medicine and covering a wide range of topics, including case control studies, retrospective cohort studies, retrospective studies, clinical trials studies, observational studies, prospective studies, randomized controlled trials, randomized clinical trials, systematic reviews, meta-analysis, and case reports.

INDEXING/ABSTRACTING

The WJCC is now abstracted and indexed in Science Citation Index Expanded (SCIE, also known as SciSearch®), Journal Citation Reports/Science Edition, Current Contents®/Clinical Medicine, PubMed, PubMed Central, Scopus, Reference Citation Analysis, China National Knowledge Infrastructure, China Science and Technology Journal Database, and Superstar Journals Database. The 2022 Edition of Journal Citation Reports® cites the 2021 impact factor (IF) for WJCC as 1.534; IF without journal self cites: 1.491; 5-year IF: 1.599; Journal Citation Indicator: 0.28; Ranking: 135 among 172 journals in medicine, general and internal; and Quartile category: Q4. The WJCC's CiteScore for 2021 is 1.2 and Scopus CiteScore rank 2021: General Medicine is 443/826.

RESPONSIBLE EDITORS FOR THIS ISSUE

Production Editor: Si Zhao; Production Department Director: Xu Guo; Editorial Office Director: Jin-Lei Wang.

NAME OF JOURNAL

World Journal of Clinical Cases

ISSN

ISSN 2307-8960 (online)

LAUNCH DATE

April 16, 2013

FREQUENCY

Thrice Monthly

EDITORS-IN-CHIEF

Bao-Gan Peng, Jerzy Tadeusz Chudek, George Kontogeorgos, Maurizio Serati, Ja Hyeon Ku

EDITORIAL BOARD MEMBERS

<https://www.wjnet.com/2307-8960/editorialboard.htm>

PUBLICATION DATE

December 6, 2022

COPYRIGHT

© 2022 Baishideng Publishing Group Inc

INSTRUCTIONS TO AUTHORS

<https://www.wjnet.com/bpg/gerinfo/204>

GUIDELINES FOR ETHICS DOCUMENTS

<https://www.wjnet.com/bpg/GerInfo/287>

GUIDELINES FOR NON-NATIVE SPEAKERS OF ENGLISH

<https://www.wjnet.com/bpg/gerinfo/240>

PUBLICATION ETHICS

<https://www.wjnet.com/bpg/GerInfo/288>

PUBLICATION MISCONDUCT

<https://www.wjnet.com/bpg/gerinfo/208>

ARTICLE PROCESSING CHARGE

<https://www.wjnet.com/bpg/gerinfo/242>

STEPS FOR SUBMITTING MANUSCRIPTS

<https://www.wjnet.com/bpg/GerInfo/239>

ONLINE SUBMISSION

<https://www.f6publishing.com>



Compound heterozygous mutations in PMFBP1 cause acephalic spermatozoa syndrome: A case report

Tian-Qin Deng, Yu-Li Xie, Jiang-Bo Pu, Jiang Xuan, Xue-Mei Li

Specialty type: Andrology

Provenance and peer review:

Unsolicited article; Externally peer reviewed.

Peer-review model: Single blind

Peer-review report's scientific quality classification

Grade A (Excellent): 0

Grade B (Very good): 0

Grade C (Good): C, C

Grade D (Fair): 0

Grade E (Poor): 0

P-Reviewer: Hegazy AA, Egypt; Zhang C, China

Received: September 11, 2022

Peer-review started: September 11, 2022

First decision: October 13, 2022

Revised: October 20, 2022

Accepted: November 4, 2022

Article in press: November 4, 2022

Published online: December 6, 2022



Tian-Qin Deng, Jiang-Bo Pu, Jiang Xuan, Xue-Mei Li, Reproductive Medical Center, Affiliated Shenzhen Maternity & Child Healthcare Hospital, Southern Medical University, Shenzhen 518028, Guangdong Province, China

Yu-Li Xie, Newborn Screening Center, Affiliated Shenzhen Maternity & Child Healthcare Hospital, Southern Medical University, Shenzhen 518028, Guangdong Province, China

Corresponding author: Tian-Qin Deng, PhD, Chief Doctor, Reproductive Medical Center, Affiliated Shenzhen Maternity & Child Healthcare Hospital, Southern Medical University, No. 3012 Fuqiang Road, Shenzhen 518028, Guangdong Province, China. tianqin02@163.com

Abstract

BACKGROUND

Acephalic spermatozoa syndrome (ASS) is an extremely rare form of severe teratozoospermia, where in most of the sperm either appear to lack heads or have disconnected or poorly connected heads and tails.

CASE SUMMARY

We reported the case of a male patient with secondary infertility whose sperm showed typical ASS upon morphological analysis. Whole-exome sequencing was performed on the patient's peripheral blood, which revealed two heterozygous variants of the *PMFBP1* gene: *PMFBP1*c.414+1G>T (p.?) and *PMFBP1*c.393del (p.C132Afs*3).

CONCLUSION

It is speculated that the compound homozygous mutation of *PMFBP1* may be the cause of ASS. We conducted a literature review in order to provide the basis for genetic counseling and clinical diagnosis of patients with ASS.

Key Words: Acephalic spermatozoa syndrome; PMFBP1; Infertility; Male; Sperm; Case report

©The Author(s) 2022. Published by Baishideng Publishing Group Inc. All rights reserved.

Core Tip: Acephalic spermatozoa syndrome (ASS) is an extremely rare form of teratozoospermia. Patients with ASS are often unable to conceive naturally, and intracytoplasmic sperm injection is the main method used for such patients to produce biological offspring. Recent studies have shown that ASS is associated with inherited genetic mutations.

Citation: Deng TQ, Xie YL, Pu JB, Xuan J, Li XM. Compound heterozygous mutations in PMFBP1 cause acephalic spermatozoa syndrome: A case report. *World J Clin Cases* 2022; 10(34): 12761-12767

URL: <https://www.wjgnet.com/2307-8960/full/v10/i34/12761.htm>

DOI: <https://dx.doi.org/10.12998/wjcc.v10.i34.12761>

INTRODUCTION

According to World Health Organization (WHO) estimates, 15% of the couples of childbearing ages face fertility issues, with 50% attributed to male factors[1]. Sperm quality remains an important indicator of male fertility, with the main manifestations of poor quality being oligospermia, asthenozoospermia, teratozoospermia, or azoospermia. Acephalic spermatozoa syndrome (ASS) (OMIM: 617187) is an extremely rare form of teratozoospermia[2]. Patients with ASS are often unable to conceive naturally, and intracytoplasmic sperm injection (ICSI) is the main method used for such patients to produce biological offspring[3]. In recent years, the development of next-generation sequencing has provided a technical basis for genetic research on ASS. To date, the followings have been identified as causative genes related to azoospermia: *SUN5*, *BRDT*, *PMFBP1*, *TSGA10*, *HOOK1*, *DNAH6*, and *CEP112*[4-10]. Here we report a case of ASS caused by a heterozygous mutation in the polyamine modulated factor 1 binding protein 1 (PMFBP1) gene.

CASE PRESENTATION

Chief complaints

A 31-year-old male patient attended the outpatient clinic of our hospital's reproductive medicine center with a complaint of "three years without pregnancy despite not using contraception".

History of present illness

Three years without pregnancy.

History of past illness

In 2014, the patient's wife had undergone an induced abortion, and the patient had undergone a high ligation of his left varicocele in 2018; however, sperm quality did not appear to have improved upon re-examination after the surgery.

Personal and family history

The patient has no history of hypertension or diabetes. Her parents were non-consanguineous and had no family history of hereditary diseases.

Physical examination

In terms of appearance, the patient's height was 165 cm, weight was 65 kg, and body mass index was 23.88 Kg/m². Specialist examination showed that his pubic hair was distributed like an inverted triangle, his penis measured approximately 6 cm long when flaccid, the urethral opening showed no visible abnormalities, bilateral testicular volume was approximately 12 mL with a tough texture, the bilateral vas deferens and epididymis showed no observable abnormalities upon palpation, and no varicocele was found.

Laboratory examinations

Through two routine semen analyses and rapid morphology staining (Diff-Quik method), the patient was diagnosed with secondary infertility and ASS. Given the patient's informed consent, 5 mL of his peripheral blood was collected. Our study was approved by the Ethics Committee of the Shenzhen Maternal and Child Health Care Hospital and was conducted with the patient's informed consent.

Computer-assisted semen analysis and sperm morphology inspection

After three to five days of abstinence, the patient masturbated to enable sperm extraction, which was

liquified in a water bath at 37°C. Analyses were conducted twice according to the WHO laboratory manual (Fifth Edition)[11]. Eosin staining was conducted to detect sperm viability and sperm morphology was determined after staining the sperm smear using a rapid staining solution (Diff-Quik method), and 200 sperms were counted. Morphological defects were divided into four categories: normal, abnormal head-neck configuration, detached heads, and headless, and the percentage of each category was calculated.

Karyotyping and Y chromosome microdeletion testing

Peripheral blood was collected and used for karyotype analysis through cell culture and Y chromosome microdeletion testing through PCR-capillary electrophoresis.

DNA Library Preparation

For exome sequencing, we fragmented 1-3 µg of genomic DNA, extracted from each sample, to an average size of 180 bp with a Bioruptorsonicator (Diagenode). Paired-end sequencing libraries then were prepared using a DNA sampleprep reagent set 1 (NEBNext). Library preparation included end repair, adapter ligation and PCR enrichment, and was carried out as recommended by Illumina protocols.

Targeted genes enrichment and sequencing

The amplified DNA was captured using GenCap Deafness capture kit (MyGenostics GenCap Enrichment technologies). The DNA probes were designed to tile along the exon regions and the known non-exon pathogenic region of human genes. The capture experiment was conducted according to manufacturer's protocol. The PCR product was purified using SPRI beads (Beckman Coulter) according to manufacturer's protocol. The enrichment libraries were sequenced on Illumina HiSeq X ten sequencer for paired read 150 bp.

Bioinformatics analysis

After sequencing, the raw data were saved as a FASTQ format, then followed the bioinformatics analysis, the data would be transformed to VCF format, variants were further annotated by ANNOVA Rand associated with multiple databases, such as, 1000 genome, ESP6500, dbSNP, EXAC, Inhouse (MyGenostics), HGMD, and predicted by SIFT, PolyPhen-2, MutationTaster, GERP++.

Variants selected

five steps using to select the potential pathogenic mutations in downstream analysis: (1) Mutation reads should be more than 5, mutation ratio should be no less than 30%; (2) Removing the mutation, the frequency of which showed more than 5% in 1000 g, ESP6500 and Inhouse database; (3) If the mutations existed in InNormal database (MyGenostics), then dropped; (4) Removing the synonymous; and (5) After (1),(2),(3), if the mutations were synonymous and they were reported in HGMD, left them. When finished above jobs, the mutations which were left should be the pathogenic mutations.

Computer-assisted semen and sperm morphology analysis results

When performed under conditions of low sperm activity, neither method revealed morphologically normal sperm. High percentages of sperm with abnormal head-neck connections, detached heads, and headless sperm were observed, indicating complete teratozoospermia with oligoasthenozoospermia (Table 1). Eosin staining showed that there were no normal sperms in the semen; instead, some were intact (with head and tail at an angle), most had headless, and very few had sperm heads without tails (Figure 1).

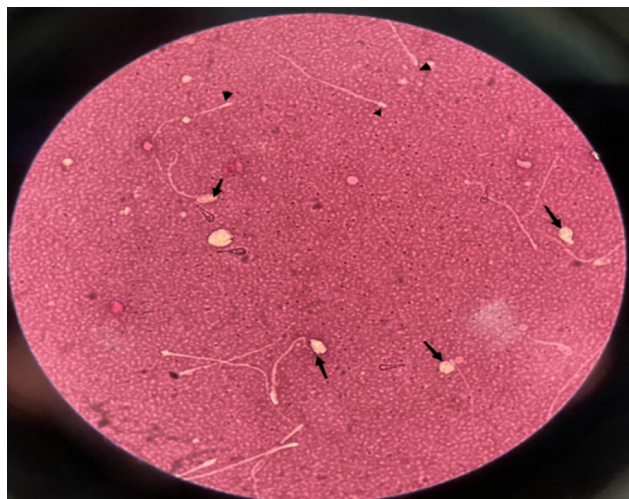
Karyotyping and Y chromosome microdeletion results

Peripheral blood karyotype analysis (G banding): 46, XY; Y chromosome microdeletion: no deletion observed.

Whole-exome sequencing results

We analyzed exons and adjacent splicing regions of genes associated with male infertility, with a focus on known pathogenic genes related to severe oligozoospermia and the patient's clinical background. We found two heterozygous variants of the *PMFBP1* gene (Figure 2): *PMFBP1*c.414+1G>T (p.?) and *PMFBP1*c.393del (p.C132Afs*3). The heterozygous splicing variant c.414+1G>T (p.?) of gene *PMFBP1* was in intron 4 (the *PMFBP1* gene contains 20 introns) and was likely to interfere with the mRNA splicing signal. This was a classical splicing variant, which may lead to loss of amino acids but might not destroy the reading frame. The heterozygous frameshift variant c.393del (p.C132Afs*3) of the *PMFBP1* gene caused the replacement of cysteine by alanine at position 132, followed by a frameshift and a premature stop codon, resulting in the early termination of protein coding. The detected frameshift mutation may lead to > 10% amino acid loss, resulting in the occurrence of nonsense-mediated mRNA decay, which may be a non-functional mutation. According to the American College of Medical

Table 1 Computer-assisted semen and sperm morphology analysis		
Parameter	December 29, 2021	March 25, 2022
Semen volume (mL)	2.0	2.8
Semen concentration (10 ⁶ /mL)	10.65	11.28
Rapidly progressive (%)	3.61	2.27
Sperm motility (%)	25.30	6.82
Sperm survival (%)	50	45
Proportion of morphologically normal sperm (%)	0	0



DOI: 10.12998/wjcc.v10.i34.12761 Copyright ©The Author(s) 2022.

Figure 1 Eosin staining (Y-E): Arrows, tailless sperm heads; triangles, headless sperm tails.

Genetics and Genomics Guidelines, these variants are probable pathogenic variants (Table 2)[12].

FINAL DIAGNOSIS

Combined with the patient’s Whole-exome sequencing and *semen* results, the final diagnosis was acephalic spermatozoa syndrome.

TREATMENT

The patient was recommended assisted reproductive technology, the sperm with head-tail junction were selected for ICSI. Due to the low proportion of the sperm with head-tail junction in the semen sample and the fragility of the head-tail junction, we used the upstream method to process the semen samples. Base on the Racowesky method, if D3 blastomeres ≥ 6 were considered as high-quality embryos (I-II). According to the condition of embryos and endometrium of patients, one or two fresh high-quality embryo was transferred, and luteal support was performed after transfer.

OUTCOME AND FOLLOW-UP

On the third day, two embryos were obtained, and one blastocyst was obtained on the fifth day. His wife did not conceive during the two transplants, now there are no available embryos.

Table 2 Bioinformatics software analysis of the *PMFBP1* gene

Gene	Chromosomal location (hg19)	Mutation name	Group frequency in East Asian population	Zygote type	Mutation rating	Related diseases
PMFBP1	chr16:72188109	NM_031293.3: c.414+1G>T (p.)	0.00021	Heterozygous	Probable pathogen	Spermatogenesis Disease Type 31 (618112, AR)
PMFBP1	chr16:72188131	NM_031293.3: c.393del (p.C132Afs*3)	Not recorded	Heterozygous	Probable pathogen	

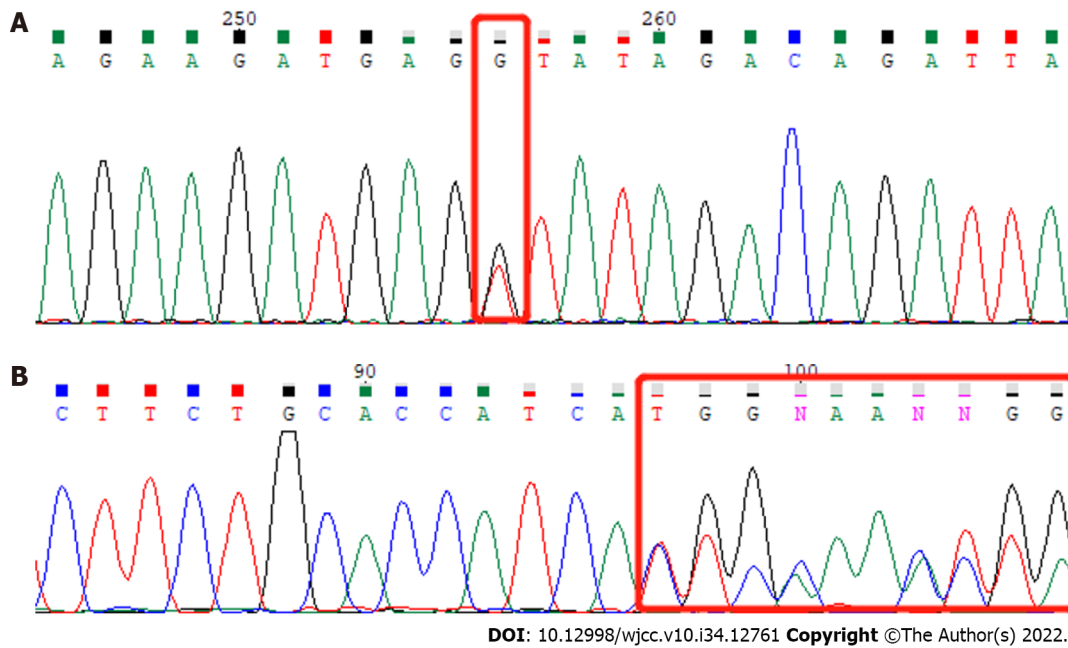


Figure 2 Whole-exome sequencing. Red box indicates mutation site. A: PMFBP1 NM_031293.3: c.414+1G>T (p.?); B: PMFBP1 NM_031293.3: c.393del (p.C132Afs*3).

DISCUSSION

ASS can initially be diagnosed by observing sperm morphology under light microscopy; 30 to 100% of the sperms in patients' semen appear to be headless, have disconnected or loosely connected heads and tails, or have "very small heads" preceding the flagella, which appear as opaque dots[13]. There are individual differences in semen quality parameters of patients, where most have oligoasthenozoospermia, but some may also have normal sperm counts. The *PMFBP1* gene is located on chromosome 16 (q22.2) and contains 27 exons. The coding region of the gene consists of 3024 bases and encodes 1007 amino acids[14]. The *PMFBP1* gene is highly expressed in both human and mouse testes[15]. In animal testes, the PMFBP1 protein is localized in the implantation fossa and basal body of the sperm and located between the SUN5 and SPATA6 proteins, forming a "sandwich" structure[16]. PMFBP1 may act as a scaffolding protein to stabilize the sperm's head and tail. Spermatogenic failure 31 (OMIM 618112) can be caused by homozygous or compound heterozygous variants of the *PMFBP1* gene and is often inherited in an autosomal recessive pattern[14]. Its main clinical manifestations are oligospermia, with a large proportion of immotile sperm and a high proportion (90%) of acephalic sperm. Many sperms have abnormal head-tail connections or are tailless, with a very small proportion of sperm appearing morphologically normal. Approximately 34.61% of ASS cases are related to mutations in the *PMFBP1* gene.

Normal sperm necks consist of an implantation fossa, basal body, proximal centriole, and its surrounding segmented columns. ASS can be divided into three subtypes, which are I, II, and III, according to ultrastructural observations of the breakage site near the midpiece[17]. Mutations in the *SUN5*, *PMFBP1*, and *HOOK1* genes are related to type II ASS occurrence[8]. Studies have reported no significant differences in the sperm quality of patients with ASS and with *PMFBP1*, *SUN5*, *BRDT*, and *TSGA10* mutations; however, other studies show that patients with ASS caused by *PMFBP1* mutations not only have rounded or amorphous heads in ejaculated sperm but also have lower sperm concentration, suggesting that *PMFBP1* mutations cause a more severe phenotype of acephalic sperm.

The efficacy of drug treatment in ASS is not clear, and patients are often unable to conceive naturally. ICSI is the primary method used for patients to produce biological offspring, wherein sperms with abnormal head-tail connections and sperms that are headless or tailless can be injected into the egg cytoplasm[18]. If the patient's ejaculate does not contain any sperm heads, testicular puncture can be performed to extract testicular sperm for ICSI. Some ASS patients have had success in producing offspring; however, some patients were unable to conceive high-quality embryos even with ICSI adjuvant therapy, possibly due to genetic mutation. For Type I ASS patients, ICSI outcomes were poor due to a lack of distal centrioles[16]; Type II ASS patients typically achieved better ICSI outcomes than those of other subtypes, with successful cases of pregnancies and live births[14]. Mutations in the *TSGA10* and *BRDT* genes are associated with type III ASS, which often lead to embryonic developmental arrest due to paternal centriole defects, resulting in clinical pregnancy failure[19].

CONCLUSION

The pathogenic onset of ASS is attributed to mutations in the *PMFBP1* gene. A novel *PMFBP1* genetic mutation provides accurate genetic diagnosis for patients with ASS and serves as theoretical support and practical guidance for the application of assisted reproductive therapy.

FOOTNOTES

Author contributions: Xie YL, Pu JB, and Jiang X actively participated in collection and diagnosis of the patient; Deng TQ wrote the manuscript; Li XM revised the manuscript; all authors have read and approved the final manuscript.

Supported by Shenzhen Key Medical Discipline Construction Fund, Grant/Award, No. SZXK031.

Informed consent statement: A written informed consent was obtained from the patient for publication of this case report.

Conflict-of-interest statement: All the authors have nothing to disclose.

CARE Checklist (2016) statement: The authors have read the CARE Checklist (2016), and the manuscript was prepared and revised according to the CARE Checklist (2016).

Open-Access: This article is an open-access article that was selected by an in-house editor and fully peer-reviewed by external reviewers. It is distributed in accordance with the Creative Commons Attribution NonCommercial (CC BY-NC 4.0) license, which permits others to distribute, remix, adapt, build upon this work non-commercially, and license their derivative works on different terms, provided the original work is properly cited and the use is non-commercial. See: <https://creativecommons.org/licenses/by-nc/4.0/>

Country/Territory of origin: China

ORCID number: Tian-Qin Deng 0000-0002-1994-0794.

S-Editor: Liu JH

L-Editor: A

P-Editor: Liu JH

REFERENCES

- 1 **Boivin J**, Bunting L, Collins JA, Nygren KG. International estimates of infertility prevalence and treatment-seeking: potential need and demand for infertility medical care. *Hum Reprod* 2007; **22**: 1506-1512 [PMID: 17376819 DOI: 10.1093/humrep/dem046]
- 2 **Perotti ME**, Giarola A, Gioria M. Ultrastructural study of the decapitated sperm defect in an infertile man. *J Reprod Fertil* 1981; **63**: 543-549 [PMID: 7299757 DOI: 10.1530/jrf.0.0630543]
- 3 **Elkhatib RA**, Paci M, Longepied G, Saias-Magnan J, Courbière B, Guichaoua MR, Lévy N, Metzler-Guillemain C, Mitchell MJ. Homozygous deletion of SUN5 in three men with decapitated spermatozoa. *Hum Mol Genet* 2017; **26**: 3167-3171 [PMID: 28541472 DOI: 10.1093/hmg/ddx200]
- 4 **Zhu F**, Wang F, Yang X, Zhang J, Wu H, Zhang Z, He X, Zhou P, Wei Z, Gecz J, Cao Y. Biallelic SUN5 Mutations Cause Autosomal-Recessive Acephalic Spermatozoa Syndrome. *Am J Hum Genet* 2016; **99**: 1405 [PMID: 27912045 DOI: 10.1016/j.ajhg.2016.11.002]
- 5 **Pivot-Pajot C**, Caron C, Govin J, Vion A, Rousseaux S, Khochbin S. Acetylation-dependent chromatin reorganization by BRDT, a testis-specific bromodomain-containing protein. *Mol Cell Biol* 2003; **23**: 5354-5365 [PMID: 12861021 DOI: 10.1128/MCB.23.15.5354-5365.2003]

- 6 **Sha YW**, Wang X, Xu X, Ding L, Liu WS, Li P, Su ZY, Chen J, Mei LB, Zheng LK, Wang HL, Kong SB, You M, Wu JF. Biallelic mutations in PMFBP1 cause acephalic spermatozoa. *Clin Genet* 2019; **95**: 277-286 [PMID: [30298696](#) DOI: [10.1111/cge.13461](#)]
- 7 **Ye Y**, Wei X, Sha Y, Li N, Yan X, Cheng L, Qiao D, Zhou W, Wu R, Liu Q, Li Y. Loss-of-function mutation in TSGA10 causes acephalic spermatozoa phenotype in human. *Mol Genet Genomic Med* 2020; **8**: e1284 [PMID: [32410354](#) DOI: [10.1002/mgg3.1284](#)]
- 8 **Chen H**, Zhu Y, Zhu Z, Zhi E, Lu K, Wang X, Liu F, Li Z, Xia W. Detection of heterozygous mutation in hook microtubule-tethering protein 1 in three patients with decapitated and decaudated spermatozoa syndrome. *J Med Genet* 2018; **55**: 150-157 [PMID: [29330334](#) DOI: [10.1136/jmedgenet-2016-104404](#).]
- 9 **Cannarella R**, Condorelli RA, Duca Y, La Vignera S, Calogero AE. New insights into the genetics of spermatogenic failure: a review of the literature. *Hum Genet* 2019; **138**: 125-140 [PMID: [30656449](#) DOI: [10.1007/s00439-019-01974-1](#)]
- 10 **Kumar A**, Rajendran V, Sethumadhavan R, Purohit R. CEP proteins: the knights of centrosome dynasty. *Protoplasma* 2013; **250**: 965-983 [PMID: [23456457](#) DOI: [10.1007/s00709-013-0488-9](#)]
- 11 **World Health Organization**. WHO laboratory manual for the examination and processing of human semen. Ed. 5. Geneva, Switzerland: WHO Press; 2010
- 12 **Brandt T**, Sack LM, Arjona D, Tan D, Mei H, Cui H, Gao H, Bean LJH, Ankala A, Del Gaudio D, Knight Johnson A, Vincent LM, Reavey C, Lai A, Richard G, Meck JM. Adapting ACMG/AMP sequence variant classification guidelines for single-gene copy number variants. *Genet Med* 2020; **22**: 336-344 [PMID: [31534211](#) DOI: [10.1038/s41436-019-0655-2](#)]
- 13 **Perotti ME**, Gioria M. Fine structure and morphogenesis of "headless" human spermatozoa associated with infertility. *Cell Biol Int Rep* 1981; **5**: 113 [PMID: [7226245](#) DOI: [10.1016/0309-1651\(81\)90018-7](#)]
- 14 **Ohuchi J**, Arai T, Kon Y, Asano A, Yamauchi H, Watanabe T. Characterization of a novel gene, sperm-tail-associated protein (Stap), in mouse post-meiotic testicular germ cells. *Mol Reprod Dev* 2001; **59**: 350-358 [PMID: [11468771](#) DOI: [10.1002/mrd.1041](#)]
- 15 **Zhu F**, Liu C, Wang F, Yang X, Zhang J, Wu H, Zhang Z, He X, Zhou P, Wei Z, Shang Y, Wang L, Zhang R, Ouyang YC, Sun QY, Cao Y, Li W. Mutations in PMFBP1 Cause Acephalic Spermatozoa Syndrome. *Am J Hum Genet* 2018; **103**: 188-199 [PMID: [30032984](#) DOI: [10.1016/j.ajhg.2018.06.010](#)]
- 16 **Wu B**, Gao H, Liu C, Li W. The coupling apparatus of the sperm head and tail†. *Biol Reprod* 2020; **102**: 988-998 [PMID: [31995163](#) DOI: [10.1093/biolre/iaaa016](#)]
- 17 **Nie H**, Tang Y, Qin W. Beyond Acephalic Spermatozoa: The Complexity of Intracytoplasmic Sperm Injection Outcomes. *Biomed Res Int* 2020; **2020**: 6279795 [PMID: [32104701](#) DOI: [10.1155/2020/6279795](#)]
- 18 **Fang J**, Zhang J, Zhu F, Yang X, Cui Y, Liu J. Patients with acephalic spermatozoa syndrome linked to SUN5 mutations have a favorable pregnancy outcome from ICSI. *Hum Reprod* 2018; **33**: 372-377 [PMID: [29329387](#) DOI: [10.1093/humrep/dex382](#)]
- 19 **Li L**, Sha Y, Wang X, Li P, Wang J, Kee K, Wang B. Whole-exome sequencing identified a homozygous BRDT mutation in a patient with acephalic spermatozoa. *Oncotarget* 2017; **8**: 19914-19922 [PMID: [28199965](#) DOI: [10.18632/oncotarget.15251](#)]



Published by **Baishideng Publishing Group Inc**
7041 Koll Center Parkway, Suite 160, Pleasanton, CA 94566, USA

Telephone: +1-925-3991568

E-mail: bpgoffice@wjgnet.com

Help Desk: <https://www.f6publishing.com/helpdesk>

<https://www.wjgnet.com>

