

World Journal of *Clinical Cases*

World J Clin Cases 2022 February 6; 10(4): 1140-1456



Contents

Thrice Monthly Volume 10 Number 4 February 6, 2022

REVIEW

- 1140 COVID-19: Gastrointestinal manifestations, liver injury and recommendations
Ozkurt Z, Çınar Tanrıverdi E

ORIGINAL ARTICLE

Retrospective Study

- 1164 Continuous intravenous infusion of recombinant human endostatin using infusion pump plus chemotherapy in non-small cell lung cancer
Qin ZQ, Yang SF, Chen Y, Hong CJ, Zhao TW, Yuan GR, Yang L, Gao L, Wang X, Lu LQ
- 1172 Sequential sagittal alignment changes in the cervical spine after occipitocervical fusion
Zhu C, Wang LN, Chen TY, Mao LL, Yang X, Feng GJ, Liu LM, Song YM
- 1182 Importance of the creation of a short musculofascial tunnel in peritoneal dialysis catheter placement
Lee CY, Tsai MK, Chen YT, Zhan YJ, Wang ML, Chen CC
- 1190 Clinical effect of methimazole combined with selenium in the treatment of toxic diffuse goiter in children
Zhang XH, Yuan GP, Chen TL
- 1198 Clinical study on the minimally invasive percutaneous nephrolithotomy treatment of upper urinary calculi
Xu XJ, Zhang J, Li M, Hou JQ

Observational Study

- 1206 Comparison of diagnostic validity of two autism rating scales for suspected autism in a large Chinese sample
Chu JH, Bian F, Yan RY, Li YL, Cui YH, Li Y
- 1217 Doctor-led intensive diet education on health-related quality of life in patients with chronic renal failure and hyperphosphatemia
Feng XD, Xie X, He R, Li F, Tang GZ

SYSTEMATIC REVIEWS

- 1226 What are the self-management experiences of the elderly with diabetes? A systematic review of qualitative research
Li TJ, Zhou J, Ma JJ, Luo HY, Ye XM

META-ANALYSIS

- 1242 Comparison of the clinical performance of i-gel and Ambu laryngeal masks in anaesthetised paediatric patients: A meta-analysis
Bao D, Yu Y, Xiong W, Wang YX, Liang Y, Li L, Liu B, Jin X

CASE REPORT

- 1255** Autogenous iliotibial band enhancement combined with tendon lengthening plasty to treat patella baja: A case report
Tang DZ, Liu Q, Pan JK, Chen YM, Zhu WH
- 1263** Sintilimab-induced autoimmune diabetes: A case report and review of the literature
Yang J, Wang Y, Tong XM
- 1278** Unicentric Castleman disease was misdiagnosed as pancreatic mass: A case report
Zhai HY, Zhu XY, Zhou GM, Zhu L, Guo DD, Zhang H
- 1286** Iguratimod in treatment of primary Sjögren's syndrome concomitant with autoimmune hemolytic anemia: A case report
Zhang J, Wang X, Tian JJ, Zhu R, Duo RX, Huang YC, Shen HL
- 1291** Primary central nervous system lymphoma presenting as a single choroidal lesion mimicking metastasis: A case report
Jang HR, Lim KH, Lee K
- 1296** Surgical treatment of acute cholecystitis in patients with confirmed COVID-19: Ten case reports and review of literature
Bozada-Gutiérrez K, Trejo-Avila M, Chávez-Hernández F, Parraguirre-Martínez S, Valenzuela-Salazar C, Herrera-Esquivel J, Moreno-Portillo M
- 1311** Hydrogen inhalation promotes recovery of a patient in persistent vegetative state from intracerebral hemorrhage: A case report and literature review
Huang Y, Xiao FM, Tang WJ, Qiao J, Wei HF, Xie YY, Wei YZ
- 1320** Ultrasound-guided needle release plus corticosteroid injection of superficial radial nerve: A case report
Zeng Z, Chen CX
- 1326** Inverted Y ureteral duplication with an ectopic ureter and multiple urinary calculi: A case report
Ye WX, Ren LG, Chen L
- 1333** Multiple miscarriages in a female patient with two-chambered heart and situs inversus totalis: A case report
Duan HZ, Liu JJ, Zhang XJ, Zhang J, Yu AY
- 1341** Chidamide combined with traditional chemotherapy for primary cutaneous aggressive epidermotropic CD8+ cytotoxic T-cell lymphoma: A case report
He ZD, Yang HY, Zhou SS, Wang M, Mo QL, Huang FX, Peng ZG
- 1349** Fatal rhabdomyolysis and disseminated intravascular coagulation after total knee arthroplasty under spinal anesthesia: A case report
Yun DH, Suk EH, Ju W, Seo EH, Kang H
- 1357** Left atrial appendage occlusion in a mirror-image dextrocardia: A case report and review of literature
Tian B, Ma C, Su JW, Luo J, Sun HX, Su J, Ning ZP

- 1366** Imaging presentation of biliary adenofibroma: A case report
Li SP, Wang P, Deng KX
- 1373** Multiple gouty tophi in the head and neck with normal serum uric acid: A case report and review of literatures
Song Y, Kang ZW, Liu Y
- 1381** Toxic epidermal necrolysis induced by ritodrine in pregnancy: A case report
Liu WY, Zhang JR, Xu XM, Ye TY
- 1388** Direct antiglobulin test-negative autoimmune hemolytic anemia in a patient with β -thalassemia minor during pregnancy: A case report
Zhou Y, Ding YL, Zhang LJ, Peng M, Huang J
- 1394** External penetrating laryngeal trauma caused by a metal fragment: A Case Report
Qiu ZH, Zeng J, Zuo Q, Liu ZQ
- 1401** Antegrade in situ laser fenestration of aortic stent graft during endovascular aortic repair: A case report
Wang ZW, Qiao ZT, Li MX, Bai HL, Liu YF, Bai T
- 1410** Hoffa's fracture in an adolescent treated with an innovative surgical procedure: A case report
Jiang ZX, Wang P, Ye SX, Xie XP, Wang CX, Wang Y
- 1417** Hemizygous deletion in the OTC gene results in ornithine transcarbamylase deficiency: A case report
Wang LP, Luo HZ, Song M, Yang ZZ, Yang F, Cao YT, Chen J
- 1423** Langerhans cell histiocytosis presenting as an isolated brain tumour: A case report
Liang HX, Yang YL, Zhang Q, Xie Z, Liu ET, Wang SX
- 1432** Inflammatory myofibroblastic tumor after breast prosthesis: A case report and literature review
Zhou P, Chen YH, Lu JH, Jin CC, Xu XH, Gong XH
- 1441** Eustachian tube involvement in a patient with relapsing polychondritis detected by magnetic resonance imaging: A case report
Yunaiyama D, Aoki A, Kobayashi H, Someya M, Okubo M, Saito K
- 1447** Endoscopic clipping for the secondary prophylaxis of bleeding gastric varices in a patient with cirrhosis: A case report
Yang GC, Mo YX, Zhang WH, Zhou LB, Huang XM, Cao LM

LETTER TO THE EDITOR

- 1454** Rituximab as a treatment for human immunodeficiency virus-associated nemaline myopathy: What does the literature have to tell us?
Gonçalves Júnior J, Shinjo SK

ABOUT COVER

Editorial Board Member of *World Journal of Clinical Cases*, Nicoleta-Monica Popa-Fotea, MD, PhD, Assistant Professor, Department of Cardio-thoracic, University of Medicine and Pharmacy, Bucharest 050474, Romania. nicoleta.popa-fotea@drd.umfcd.ro

AIMS AND SCOPE

The primary aim of *World Journal of Clinical Cases* (WJCC, *World J Clin Cases*) is to provide scholars and readers from various fields of clinical medicine with a platform to publish high-quality clinical research articles and communicate their research findings online.

WJCC mainly publishes articles reporting research results and findings obtained in the field of clinical medicine and covering a wide range of topics, including case control studies, retrospective cohort studies, retrospective studies, clinical trials studies, observational studies, prospective studies, randomized controlled trials, randomized clinical trials, systematic reviews, meta-analysis, and case reports.

INDEXING/ABSTRACTING

The WJCC is now indexed in Science Citation Index Expanded (also known as SciSearch®), Journal Citation Reports/Science Edition, Scopus, PubMed, and PubMed Central. The 2021 Edition of Journal Citation Reports® cites the 2020 impact factor (IF) for WJCC as 1.337; IF without journal self cites: 1.301; 5-year IF: 1.742; Journal Citation Indicator: 0.33; Ranking: 119 among 169 journals in medicine, general and internal; and Quartile category: Q3. The WJCC's CiteScore for 2020 is 0.8 and Scopus CiteScore rank 2020: General Medicine is 493/793.

RESPONSIBLE EDITORS FOR THIS ISSUE

Production Editor: Hua-Ge Yin, Production Department Director: Xu Guo, Editorial Office Director: Jin-Lei Wang.

NAME OF JOURNAL

World Journal of Clinical Cases

ISSN

ISSN 2307-8960 (online)

LAUNCH DATE

April 16, 2013

FREQUENCY

Thrice Monthly

EDITORS-IN-CHIEF

Bao-Gan Peng, Jerzy Tadeusz Chudek, George Kontogeorgos, Maurizio Serati, Ja Hyeon Ku

EDITORIAL BOARD MEMBERS

<https://www.wjgnet.com/2307-8960/editorialboard.htm>

PUBLICATION DATE

February 6, 2022

COPYRIGHT

© 2022 Baishideng Publishing Group Inc

INSTRUCTIONS TO AUTHORS

<https://www.wjgnet.com/bpg/gerinfo/204>

GUIDELINES FOR ETHICS DOCUMENTS

<https://www.wjgnet.com/bpg/GerInfo/287>

GUIDELINES FOR NON-NATIVE SPEAKERS OF ENGLISH

<https://www.wjgnet.com/bpg/gerinfo/240>

PUBLICATION ETHICS

<https://www.wjgnet.com/bpg/GerInfo/288>

PUBLICATION MISCONDUCT

<https://www.wjgnet.com/bpg/gerinfo/208>

ARTICLE PROCESSING CHARGE

<https://www.wjgnet.com/bpg/gerinfo/242>

STEPS FOR SUBMITTING MANUSCRIPTS

<https://www.wjgnet.com/bpg/GerInfo/239>

ONLINE SUBMISSION

<https://www.f6publishing.com>

Direct antiglobulin test-negative autoimmune hemolytic anemia in a patient with β -thalassemia minor during pregnancy: A case report

Yang Zhou, Yi-Ling Ding, Li-Juan Zhang, Mei Peng, Jian Huang

ORCID number: Yang Zhou 0000-0001-9322-1520; Yi-Ling Ding 0000-0002-0750-6042; Li-Juan Zhang 0000-0001-6115-5215; Mei Peng 0000-0002-8725-4497; Jian Huang 0000-0002-7604-7820.

Author contributions: Zhou Y reviewed the literature and contributed to manuscript drafting; Ding YL and Peng M were responsible for making critical revisions related to important intellectual content of the manuscript; Zhang LJ and Huang J were the patient's obstetricians, and responsible for the revision of the manuscript for important intellectual content; all authors issued final approval for the version to be submitted.

Informed consent statement: Informed written consent was obtained from the patient for publication of this report and any accompanying images.

Conflict-of-interest statement: The authors declare that they have no conflict of interest to disclose.

CARE Checklist (2016) statement: The authors have read the CARE Checklist (2016), and the manuscript was prepared and revised according to the CARE Checklist (2016).

Country/Territory of origin: China

Yang Zhou, Yi-Ling Ding, Li-Juan Zhang, Mei Peng, Jian Huang, Department of Obstetrics and Gynecology, The Second Xiangya Hospital, Central South University, Changsha 410011, Hunan Province, China

Corresponding author: Jian Huang, MD, PhD, Associate Professor, Department of Obstetrics and Gynecology, The Second Xiangya Hospital, Central South University, No. 139 Renmin Middle Road, Changsha 410011, Hunan Province, China. huangjian2566@126.com

Abstract

BACKGROUND

Severe refractory anemia during pregnancy can cause serious maternal and fetal complications. If the cause cannot be identified in time and accurately, blind symptomatic support treatment may cause serious economic burden. Thalassemia minor pregnancy is commonly considered uneventful, and the condition of anemia rarely progresses during pregnancy. Autoimmune hemolytic anemia (AIHA) is rare during pregnancy with no exact incidence available.

CASE SUMMARY

We report the case of a 30-year-old β -thalassemia minor multiparous patient experiencing severe refractory anemia throughout pregnancy. We monitored the patient closely, carried out a full differential diagnosis, made a diagnosis of direct antiglobulin test-negative AIHA, and treated her with prednisone and intravenous immunoglobulin. The patient gave birth to a healthy full-term baby.

CONCLUSION

Coombs-negative AIHA should be suspected in cases of severe hemolytic anemia in pregnant patients with and without other hematological diseases.

Key Words: Maternal anemia; β -thalassemia minor; Autoimmune hemolytic anemia; Direct antiglobulin test; Pregnancy; Case report

©The Author(s) 2022. Published by Baishideng Publishing Group Inc. All rights reserved.

Core Tip: Severe maternal anemia can cause serious adverse effects with a significant increase in maternal and neonatal mortality. We report the successful diagnosis and

Specialty type: Obstetrics and gynecology

Provenance and peer review:

Unsolicited article; Externally peer reviewed.

Peer-review model: Single blind

Peer-review report's scientific quality classification

Grade A (Excellent): A

Grade B (Very good): B

Grade C (Good): 0

Grade D (Fair): 0

Grade E (Poor): 0

Open-Access: This article is an open-access article that was selected by an in-house editor and fully peer-reviewed by external reviewers. It is distributed in accordance with the Creative Commons Attribution NonCommercial (CC BY-NC 4.0) license, which permits others to distribute, remix, adapt, build upon this work non-commercially, and license their derivative works on different terms, provided the original work is properly cited and the use is non-commercial. See: <http://creativecommons.org/licenses/by-nc/4.0/>

Received: September 4, 2021

Peer-review started: September 4, 2021

First decision: November 22, 2021

Revised: November 27, 2021

Accepted: December 25, 2021

Article in press: December 25, 2021

Published online: February 6, 2022

P-Reviewer: Naem AA, Tolunay HE

S-Editor: Li X

L-Editor: Wang TQ

P-Editor: Li X



treatment of direct antiglobulin test test-negative autoimmune hemolytic anemia in a patient with β -thalassemia minor during pregnancy. The findings from this case report suggest that maternal anemia can have multiple etiologies, and blood transfusion is not always the appropriate treatment.

Citation: Zhou Y, Ding YL, Zhang LJ, Peng M, Huang J. Direct antiglobulin test-negative autoimmune hemolytic anemia in a patient with β -thalassemia minor during pregnancy: A case report. *World J Clin Cases* 2022; 10(4): 1388-1393

URL: <https://www.wjgnet.com/2307-8960/full/v10/i4/1388.htm>

DOI: <https://dx.doi.org/10.12998/wjcc.v10.i4.1388>

INTRODUCTION

As an autosomal inherited hemoglobin (Hb) disorder, due to the absence or reduced synthesis of the globin chains of Hb, thalassemia has two main types, α - and β -thalassemia. Over 300 types of β -globin gene mutations have been reported causing varying degrees of reduced β -globin synthesis, usually categorized as minor, intermedia, or major on the basis of their clinical manifestations and dependence on blood transfusion[1]. China has a high prevalence of thalassemia, especially in the south of the Yangtze River. From epidemiological data, the thalassemia carrier population in China is over 30 million, among which over 1% has the major or intermedia type[2]. Patients with asymptomatic β -thalassemia minor, also known as silent carriers, who have mild microcytic, hypochromic anemia or even a normal Hb level, usually require little medical care.

Pregnancy complications are considered uncommon among β -thalassemia minor patients[3]. Aside from accurate and timely antenatal counseling, β -thalassemia minor patients do not require more frequent antenatal check-ups than normal, as this type of anemia during pregnancy rarely progresses to a serious condition that can cause significant adverse effects with a high risk of maternal mortality.

We report the case of a 30-year-old multipara with β -thalassemia minor who experienced severe hemolytic anemia throughout pregnancy. Fortunately, the maternal and fetal outcome was favorable following diagnosis and treatment. To our knowledge, this is the first report of such a case.

CASE PRESENTATION

Chief complaints

A 30-year-old woman, gravida 2 para 1, presented with fatigue, chest tightness, and shortness of breath for over 1 mo after activities at the 17-wk gestation.

History of present illness

The patient was diagnosed with severe anemia at a local hospital. Her Hb level was 40 g/L and she had several blood transfusions, but her Hb did not increase as expected and began to drop when the transfusion stopped.

History of past illness

Signs of anemia had not been taken seriously until the patient was hospitalized for pleuritis in 2019, when she was found to be an IVS-II-654(C>T) carrier. Her husband is not a carrier of thalassemia trait. Special medication history (other than Vitamin Complex Tablets) and transfusion history before this pregnancy were denied.

Personal and family history

No contributory personal history or similar family history.

Physical examination

The patient's vital signs were normal. She had a pale appearance, her uterus size matched the gestational age, and fetal heart rate was normal.

Laboratory examinations

The patient was referred to our hospital at the 25-wk gestation. Laboratory investigations showed severe anemia, with an Hb level of 39 g/L, mean corpuscular Hb of 22.5 pg, mean corpuscular volume of 74.6 fL, and fraction of Hb A₂ of 4.7%, as well as a raised bilirubin level of 34.8 μmol/L, direct bilirubin level of 15.9 μmol/L, raised lactate dehydrogenase (LDH) level of 392.5 U/L, reticulocyte count of 3.15%, and haptoglobin below the detection limit. The ferritin level was 291.57 ng/mL, and B12 and folate levels were normal. Oral glucose tolerance test and other routine prenatal blood test results were within the normal range. We performed TORCH (comprising toxoplasmosis, *Treponema pallidum*, rubella, cytomegalovirus, herpes virus, and hepatitis viruses) serology to rule out preceding infection. Signs of intravascular hemolysis that could not be ascribed to β-thalassemia minor were observed.

Imaging examinations

Abdominal ultrasound showed a spleen diameter of 68 mm. Echocardiography demonstrated a left atrial diameter of 40 mm and mild mitral, tricuspid, and aortic regurgitation.

Further diagnostic work-up

We carried out a multidisciplinary consultation on the third day after the patient's admission. Taking expert opinions from a hematologist and rheumatologist, we performed further examinations. Bone marrow cytology suggested active proliferation of erythrocytes. Flow cytometry showed normal erythrocyte levels of CD55 and CD59. Connective tissue screening including antinuclear antibody and extractable nuclear antigen was also negative. A normal complement C3 level and slightly decreased C4 level were detected. We performed the direct antiglobulin test (DAT; also referred to as the "Coombs" test) including IgG and C3 several times; however, the results were negative. According to the principle of exclusion, the patient's severe hemolytic anemia could be due to autoimmune reasons. On the other hand, the patient's intermediate Down's screening indicated a high risk of trisomy 21; thus, a prenatal diagnosis was performed. The karyotype of the fetus was normal and copy number variation-sequencing did not find any disease-causing gene mutations.

MULTIDISCIPLINARY EXPERT CONSULTATION

Ming-Yang Deng, MD, PhD, Assistant Professor, Department of Hematopathology, The Second Xiangya Hospital, Central South University

According to the patient's test results, the presence of intravascular hemolysis was basically established; however, the gene sequencing did not match thalassemia major. Erythrocyte CD55 and CD59 should be analyzed to rule out paroxysmal nocturnal hemoglobinuria.

Jing Tian, MD, PhD, Assistant Professor, Department of Rheumatology and Immunology, The Second Xiangya Hospital, Central South University

The evidence for connective tissue disease was insufficient.

FINAL DIAGNOSIS

DAT-negative autoimmune hemolytic anemia (AIHA) during pregnancy.

TREATMENT

The patient was given red blood cell (RBC) transfusions with other symptomatic and supportive treatment, and the growth parameters and middle cerebral artery peak systolic velocity (MCA-PSV) of the fetus were monitored. Fortunately, fetal growth and development matched the gestational age and the MCA-PSV did not increase. The patient was discharged 2 wk later and underwent strict follow-up. She returned to her hometown for 1 mo, and at the 31-wk gestation, she underwent echocardiographic re-examination at the local hospital, which showed an atrial septal aneurysm 35 mm × 14

mm in size, indicating anemic cardiomyopathy. She was admitted to our hospital for the second time. Her blood tests still suggested severe hemolytic anemia, but this time we were very cautious regarding blood transfusion in order to avoid heart overload. We suspected that the hemolysis was due to autoimmune factors, and after discussions with the patient and her family, she was given corticosteroid and immunoglobulin therapy. She received prednisone 30 mg orally qd and intravenous immunoglobulin (IVIG) 20 g/d for 3 d. Her Hb level rose to > 80 g/L. The patient's Hb and LDH values throughout pregnancy in relation to medication administration and RBC transfusion are shown in [Figure 1](#). At 38+ wk gestation, she was given vaginal misoprostol to induce labor, following echocardiography which found no abnormalities.

OUTCOME AND FOLLOW-UP

A live 3255-g boy was born by normal vaginal delivery. The neonate was transferred to the Neonatology Department 35 h after birth due to hyperbilirubinemia. Blood test results showed no sign of hemolysis; however, Hb was 136 g/L, white blood cell count was $9.07 \times 10^9/L$, platelet count was $314 \times 10^9/L$, and inflammatory indicators were elevated, indicating neonatal infection, and he had inherited the same IVS-II-654(C>T) mutation from his mother. The neonate was discharged after antibiotic treatment and phototherapy 10 d later. The mother discontinued oral corticosteroid postnatally, and maintained an Hb level above 90 g/L.

DISCUSSION

β -thalassemia carriers are asymptomatic; however, little research is available on the pregnancy outcome of β -thalassemia carriers, although it has been reported that the incidence of intrauterine growth retardation and oligohydramnios is higher[3-5]. It is recommended that pregnant women with mild thalassemia should follow the health care guidelines for normal pregnancy[6]. Thalassemia carriers tend to become more anemic during pregnancy, and it is commonly believed that this is due to physiological hemodilution[3]. It has been reported that only 3% of pregnant β -thalassemia carriers have an Hb level lower than 80 g/L, which can be associated with maternal clinical symptoms of anemia and adverse neonatal outcomes[3]. In this case, hemoglobinopathy itself might be a cause of hemolysis anemia, but it is difficult to ascribe severe and acute hemolytic anemia to simply β -thalassemia minor.

AIHA is characterized by the production of RBC autoantibodies, accelerating their destruction[7]. The incidence of AIHA in the general population is 1/100,000[8]. AIHA is rare during pregnancy, and the exact incidence has not been reported[9,10]. It has been reported that ovarian teratomas were suggested as a possible trigger of AIHA in pregnant and non-pregnant patients[11]. The diagnosis is generally based on the presence of anemia along with signs of hemolysis such as reticulocytosis, low haptoglobin, increased LDH, elevated indirect bilirubin, and a positive DAT. DAT-negative AIHA, as in our patient, only occurs in 5%-10% of all cases, and requires more specific detection with new diagnostic tools[7,9]. Due to insufficient knowledge and conditions, we did not perform a more sensitive DAT test such as anti-IgA and IgM antisera[12], and there is still room for improvement in this area. The prognosis is usually favorable once an accurate diagnosis of AIHA has been made, patients usually respond to first-line corticosteroids, and AIHA resolves after delivery[13]. Other treatments include RBC transfusions and IVIG. It was reported that cyclosporine A was safe and effective in a case of β -thalassemia major, AIHA, and insulin treated diabetes mellitus when first-line corticosteroids were unsuitable[14]. Research focused on AIHA in patients with thalassemia is very limited. Available reports are usually on alloimmunization in thalassemia major patients after receiving multiple blood transfusions. A multicenter study showed that erythrocyte autoantibodies occurred in 6.5% of chronically or intermittently transfused thalassemia patients[15]. As reported, the presence of underlying RBC autoantibodies may be predictors of AIHA in β -thalassemia patients[16]. Our thalassemia patient was not transfusion dependent, and as pregnancy is a semi-allogeneic process, we thought that there might be potential links between these three pathological processes.

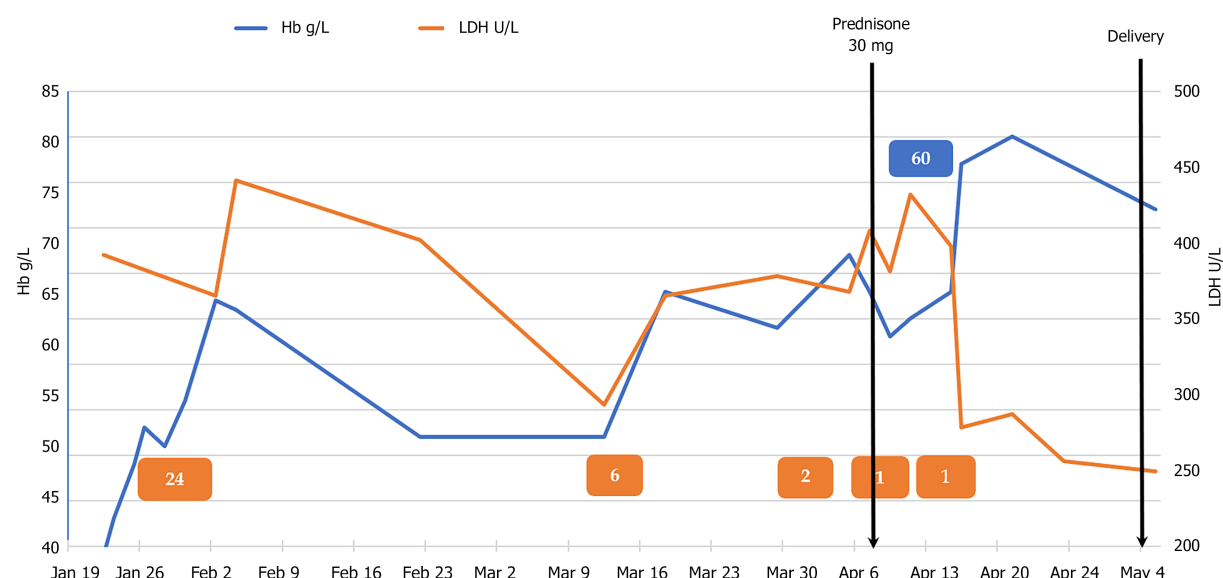


Figure 1 Hemoglobin and lactate dehydrogenase values throughout pregnancy in relation to medication administration and red blood cell transfusion. Orange boxes indicate approximately when red blood cells were administered and the number of units transfused; Blue boxes indicate when intravenous immunoglobulin was administered and the doses given; black lines indicate when a specific medication was administered and important events (prednisone was continued daily until after delivery). Hb: Hemoglobin; LDH: Lactate dehydrogenase.

CONCLUSION

We report a rare case of severe refractory anemia during pregnancy. Following various examinations, the underlying cause of the anemia was finally identified, and the patient received timely treatment. Very little research has been carried out on AIHA in pregnant patients with thalassemia. Little is known about possible pathologic process and ignoring it can lead to delays in treatment and adverse pregnancy outcome. We suggested that DAT-negative AIHA should be suspected in cases of severe hemolytic anemia in pregnant patients with and without other hematological diseases. Hopefully, there will be more detailed and in-depth studies carried out on this issue in the future.

ACKNOWLEDGEMENTS

Special thanks to the nurses and physicians for their care of this patient.

REFERENCES

- 1 **Taher AT**, Weatherall DJ, Cappellini MD. Thalassaemia. *Lancet* 2018; **391**: 155-167 [PMID: 28774421 DOI: 10.1016/S0140-6736(17)31822-6]
- 2 **Society of Perinatal Medicine**; Chinese Medical Association; Obstetric Subgroup; Society of Obstetrics and Gynecology; Chinese Medical Association. Experts' consensus on thalassaemia during pregnancy. *Zhonghua Weichan Yixue Zazhi* 2020; **23**: 577-584 [DOI: 10.3760/cma.j.cn113903-20200401-00293]
- 3 **Tsatalas C**, Chalkia P, Pantelidou D, Margaritis D, Bourikas G, Spanoudakis E. Pregnancy in beta-thalassaemia trait carriers: an uneventful journey. *Hematology* 2009; **14**: 301-303 [PMID: 19843388 DOI: 10.1179/102453309X439791]
- 4 **Leung TY**, Lao TT. Thalassaemia in pregnancy. *Best Pract Res Clin Obstet Gynaecol* 2012; **26**: 37-51 [PMID: 22079388 DOI: 10.1016/j.bpobgyn.2011.10.009]
- 5 **Sheiner E**, Levy A, Yerushalmi R, Katz M. Beta-thalassemia minor during pregnancy. *Obstet Gynecol* 2004; **103**: 1273-1277 [PMID: 15172864 DOI: 10.1097/01.AOG.0000126575.34482.fb]
- 6 **Royal College of Obstetricians and Gynaecologists**. Management of Beta Thalassaemia in Pregnancy. Green-top Guideline No. 66. March 2014. Available from: https://www.rcog.org.uk/globalassets/documents/guidelines/gtg_66_thalassaemia.pdf
- 7 **Barcellini W**, Fattizzo B. The Changing Landscape of Autoimmune Hemolytic Anemia. *Front Immunol* 2020; **11**: 946 [PMID: 32655543 DOI: 10.3389/fimmu.2020.00946]

- 8 **Rigal D**, Meyer F. [Autoimmune haemolytic anemia: diagnosis strategy and new treatments]. *Transfus Clin Biol* 2011; **18**: 277-285 [PMID: [21474357](#) DOI: [10.1016/j.traccli.2011.03.002](#)]
- 9 **Kamesaki T**. [Diagnosis and classification of direct antiglobulin test-negative autoimmune hemolytic anemia]. *Rinsho Ketsueki* 2021; **62**: 456-462 [PMID: [34108329](#) DOI: [10.11406/rinketsu.62.456](#)]
- 10 **Maroto A**, Martinez-Diago C, Tio G, Sagues M, Borrell A, Bonmati A, Teixidor M, Adrados C, Torrent S, Alvarez E. Autoimmune hemolytic anemia in pregnancy: a challenge for maternal and fetal follow-up. *J Matern Fetal Neonatal Med* 2020; 1-3 [PMID: [32098549](#) DOI: [10.1080/14767058.2020.1732344](#)]
- 11 **Felemban AA**, Rashidi ZA, Almatrafi MH, Alsahabi JA. Autoimmune hemolytic anemia and ovarian dermoid cysts in pregnancy. *Saudi Med J* 2019; **40**: 397-400 [PMID: [30957135](#) DOI: [10.15537/smj.2019.4.24107](#)]
- 12 **Genty I**, Michel M, Hermine O, Schaeffer A, Godeau B, Rochant H. [Characteristics of autoimmune hemolytic anemia in adults: retrospective analysis of 83 cases]. *Rev Med Interne* 2002; **23**: 901-909 [PMID: [12481390](#) DOI: [10.1016/s0248-8663\(02\)00688-4](#)]
- 13 **Fattizzo B**, Ferraresi M, Giannotta JA, Barcellini W. Secondary Hemophagocytic Lymphohistiocytosis and Autoimmune Cytopenias: Case Description and Review of the Literature. *J Clin Med* 2021; **10** [PMID: [33672504](#) DOI: [10.3390/jcm10040870](#)]
- 14 **Agapidou A**, Vlachaki E, Theodoridis T, Economou M, Perifanis V. Cyclosporine therapy during pregnancy in a patient with β -thalassemia major and autoimmune haemolytic anemia: a case report and review of the literature. *Hippokratia* 2013; **17**: 85-87 [PMID: [23935353](#)]
- 15 **Vichinsky E**, Neumayr L, Trimble S, Giardina PJ, Cohen AR, Coates T, Boudreaux J, Neufeld EJ, Kenney K, Grant A, Thompson AA; CDC Thalassemia Investigators. Transfusion complications in thalassemia patients: a report from the Centers for Disease Control and Prevention (CME). *Transfusion* 2014; **54**: 972-81; quiz 971 [PMID: [23889533](#) DOI: [10.1111/trf.12348](#)]
- 16 **Khaled MB**, Ouederni M, Sahli N, Dhoub N, Abdelaziz AB, Rekaya S, Kouki R, Kaabi H, Slama H, Mellouli F, Bejaoui M. Predictors of autoimmune hemolytic anemia in beta-thalassemia patients with underlying red blood cells autoantibodies. *Blood Cells Mol Dis* 2019; **79**: 102342 [PMID: [31302454](#) DOI: [10.1016/j.bcmd.2019.102342](#)]



Published by **Baishideng Publishing Group Inc**
7041 Koll Center Parkway, Suite 160, Pleasanton, CA 94566, USA

Telephone: +1-925-3991568

E-mail: bpgoffice@wjgnet.com

Help Desk: <https://www.f6publishing.com/helpdesk>

<https://www.wjgnet.com>

