

World Journal of *Clinical Cases*

World J Clin Cases 2022 February 26; 10(6): 1754-2052



Contents

Thrice Monthly Volume 10 Number 6 February 26, 2022

OPINION REVIEW

- 1754 Gut-brain axis: Focus on gut metabolites short-chain fatty acids
Guo C, Huo YJ, Li Y, Han Y, Zhou D

MINIREVIEWS

- 1764 Association between direct-acting antiviral agents in hepatitis C virus treatment and hepatocellular carcinoma occurrence and recurrence: The endless debate
Kamal A, Elsheaita A, Abdelnabi M

ORIGINAL ARTICLE

Retrospective Cohort Study

- 1775 Effects of bilirubin on perioperative myocardial infarction and its long-term prognosis in patients undergoing percutaneous coronary intervention
Li Y, Li DB, Zhao LD, Lv QB, Wang Y, Ren YF, Zhang WB
- 1787 Disease exacerbation is common in inflammatory bowel disease patients treated with immune checkpoint inhibitors for malignancy
Rubin SJS, Balabanis T, Gubatan J, Habtezion A
- 1795 Multidrug-resistant organisms in intensive care units and logistic analysis of risk factors
Han Y, Zhang J, Zhang HZ, Zhang XY, Wang YM

Retrospective Study

- 1806 Change and impact of left ventricular global longitudinal strain during transcatheter aortic valve implantation
Zhang H, Xie JJ, Li RJ, Wang YL, Niu BR, Song L, Li J, Yang Y

Observational Study

- 1815 Early detection of noise-induced hearing loss
Meng ZL, Chen F, Zhao F, Gu HL, Zheng Y
- 1826 Empathetic nursing with mindful cognitive therapy for fatigue, depression, and negative emotions in leukemia patients undergoing long-term chemotherapy
Lu YY, Lu XM, Shao CY, Wang CC, Xu TT, Zhang BL

Prospective Study

- 1834 Superior pancreatic lymphadenectomy with portal vein priority *via* posterior common hepatic artery approach in laparoscopic radical gastrectomy
Zhang YJ, Xiang RC, Li J, Liu Y, Xie SM, An L, Li HL, Mai G

Randomized Controlled Trial

- 1843** Systematic nursing interventions in gastric cancer: A randomized controlled study
He F, He RX

META-ANALYSIS

- 1852** Impact of adding opioids to paravertebral blocks in breast cancer surgery patients: A systematic review and meta-analysis
Chen MH, Chen Z, Zhao D

CASE REPORT

- 1863** Multiple different remote epidural hematomas after craniotomy: A case report
He Q, Tao CY, Fu RH, You C
- 1869** Tuberculous pericarditis-a silent and challenging disease: A case report
Lucero OD, Bustos MM, Ariza Rodríguez DJ, Perez JC
- 1876** Transileocolic endovascular treatment by a hybrid approach for severe acute portal vein thrombosis with bowel necrosis: Two case reports
Shirai S, Ueda T, Sugihara F, Yasui D, Saito H, Furuki H, Kim S, Yoshida H, Yokobori S, Hayashi H, Kumita SI
- 1883** Efficacy of EGFR-TKI sequential therapy in patients with EGFR exon 19 insertion-positive non-small-cell lung cancer: A case report
Shan BB, Li Y, Zhao C, An XQ, Zhang QM
- 1889** Novel compound heterozygous variants in the TAF6 gene in a patient with Alazami-Yuan syndrome: A case report
Lin SZ, Feng JH, Sun LP, Ma HW, Wang WQ, Li JY
- 1896** Asymmetric limb weakness in Guillain-Barré syndrome: Three case reports
Hu M, Li X, Wong HY, Feng XG, Wang YZ, Zhang GR
- 1903** Modified treatment of knee osteoarthritis complicated with femoral varus deformity: A case report
Xu SM, Li W, Zhang DB, Bi HY, Gu GS
- 1909** Novel HNF1A gene mutation in maturity-onset diabetes of the young: A case report
Xu Q, Kan CX, Hou NN, Sun XD
- 1914** Cerebral corridor creator for resection of trigone ventricular tumors: Two case reports
Liu XW, Lu WR, Zhang TY, Hou XS, Fa ZQ, Zhang SZ
- 1922** Left abdominal wall proliferative myositis resection and patch repair: A case report
Xing RW, Nie HQ, Zhou XF, Zhang FF, Mou YH
- 1929** Concurrent ankylosing spondylitis and myelodysplastic syndrome: A case report
Xu GH, Lin J, Chen WQ

- 1937** Life-threatening subclavian artery bleeding following percutaneous coronary intervention with stent implantation: A case report and review of literature
Shi F, Zhang Y, Sun LX, Long S
- 1946** Cryptogenic organizing pneumonia associated with pregnancy: A case report
Lee YJ, Kim YS
- 1952** Eosinophilia complicated with venous thromboembolism: A case report
Su WQ, Fu YZ, Liu SY, Cao MJ, Xue YB, Suo FF, Liu WC
- 1961** Neck and mediastinal hematoma caused by a foreign body in the esophagus with diagnostic difficulties: A case report
Wang LP, Zhou ZY, Huang XP, Bai YJ, Shi HX, Sheng D
- 1966** Therapeutic endoscopy of a Dieulafoy lesion in a 10-year-old girl: A case report
Chen Y, Sun M, Teng X
- 1973** Cavernous hemangioma of an intrapancreatic accessory spleen mimicking a pancreatic tumor: A case report
Huang JY, Yang R, Li JW, Lu Q, Luo Y
- 1981** Surgery and antibiotics for the treatment of lupus nephritis with cerebral abscesses: A case report
Hu QD, Liao LS, Zhang Y, Zhang Q, Liu J
- 1991** Median arcuate ligamentum syndrome: Four case reports
Kim JE, Rhee PL
- 1998** Novel ABCB4 mutations in an infertile female with progressive familial intrahepatic cholestasis type 3: A case report
Liu TF, He JJ, Wang L, Zhang LY
- 2007** Primary duodenal dedifferentiated liposarcoma: A case report and literature review
Kim NI, Lee JS, Choi C, Nam JH, Choi YD, Kim HJ, Kim SS
- 2015** Implant site development using titanium plate and platelet-rich fibrin for congenitally missed maxillary lateral incisors: A case report
Zhang TS, Mudalal M, Ren SC, Zhou YM
- 2023** Successful embolization of an intrahepatic portosystemic shunt using balloon-occluded retrograde transvenous obliteration: A case report
Saito H, Murata S, Sugihara F, Ueda T, Yasui D, Miki I, Hayashi H, Kumita SI
- 2030** Bilateral pneumothorax and pneumomediastinum during colonoscopy in a patient with intestinal Behcet's disease: A case report
Mu T, Feng H
- 2036** Acute kidney injury due to intravenous detergent poisoning: A case report
Park S, Ryu HS, Lee JK, Park SS, Kwon SJ, Hwang WM, Yun SR, Park MH, Park Y

- 2045** Vaginal enterocele after cystectomy: A case report

Liu SH, Zhang YH, Niu HT, Tian DX, Qin F, Jiao W

ABOUT COVER

Editorial Board Member of *World Journal of Clinical Cases*, Navdeep Singh, MBBS, MS, Assistant Professor, Division of Transplantation, Department of Surgery, The Ohio State University, Columbus, OH 43210, United States.
navdeep.singh@osumc.edu

AIMS AND SCOPE

The primary aim of *World Journal of Clinical Cases* (WJCC, *World J Clin Cases*) is to provide scholars and readers from various fields of clinical medicine with a platform to publish high-quality clinical research articles and communicate their research findings online.

WJCC mainly publishes articles reporting research results and findings obtained in the field of clinical medicine and covering a wide range of topics, including case control studies, retrospective cohort studies, retrospective studies, clinical trials studies, observational studies, prospective studies, randomized controlled trials, randomized clinical trials, systematic reviews, meta-analysis, and case reports.

INDEXING/ABSTRACTING

The WJCC is now indexed in Science Citation Index Expanded (also known as SciSearch®), Journal Citation Reports/Science Edition, Scopus, PubMed, and PubMed Central. The 2021 Edition of Journal Citation Reports® cites the 2020 impact factor (IF) for WJCC as 1.337; IF without journal self cites: 1.301; 5-year IF: 1.742; Journal Citation Indicator: 0.33; Ranking: 119 among 169 journals in medicine, general and internal; and Quartile category: Q3. The WJCC's CiteScore for 2020 is 0.8 and Scopus CiteScore rank 2020: General Medicine is 493/793.

RESPONSIBLE EDITORS FOR THIS ISSUE

Production Editor: *Ying-Yi Yuan*, Production Department Director: *Xu Guo*, Editorial Office Director: *Jin-Lei Wang*.

NAME OF JOURNAL

World Journal of Clinical Cases

ISSN

ISSN 2307-8960 (online)

LAUNCH DATE

April 16, 2013

FREQUENCY

Thrice Monthly

EDITORS-IN-CHIEF

Bao-Gan Peng, Jerzy Tadeusz Chudek, George Kontogeorgos, Maurizio Serati, Ja Hyeon Ku

EDITORIAL BOARD MEMBERS

<https://www.wjgnet.com/2307-8960/editorialboard.htm>

PUBLICATION DATE

February 26, 2022

COPYRIGHT

© 2022 Baishideng Publishing Group Inc

INSTRUCTIONS TO AUTHORS

<https://www.wjgnet.com/bpg/gerinfo/204>

GUIDELINES FOR ETHICS DOCUMENTS

<https://www.wjgnet.com/bpg/GerInfo/287>

GUIDELINES FOR NON-NATIVE SPEAKERS OF ENGLISH

<https://www.wjgnet.com/bpg/gerinfo/240>

PUBLICATION ETHICS

<https://www.wjgnet.com/bpg/GerInfo/288>

PUBLICATION MISCONDUCT

<https://www.wjgnet.com/bpg/gerinfo/208>

ARTICLE PROCESSING CHARGE

<https://www.wjgnet.com/bpg/gerinfo/242>

STEPS FOR SUBMITTING MANUSCRIPTS

<https://www.wjgnet.com/bpg/GerInfo/239>

ONLINE SUBMISSION

<https://www.f6publishing.com>



Eosinophilia complicated with venous thromboembolism: A case report

Wei-Qiang Su, Yan-Zhong Fu, Shu-Yan Liu, Meng-Jie Cao, Ya-Bin Xue, Fei-Fei Suo, Wen-Chao Liu

Specialty type: Hematology

Provenance and peer review:

Unsolicited article; externally peer reviewed.

Peer-review model: Single blind

Peer-review report's scientific quality classification

Grade A (Excellent): 0

Grade B (Very good): 0

Grade C (Good): C, C

Grade D (Fair): 0

Grade E (Poor): 0

P-Reviewer: Gupta T, Joalsen I

Received: August 28, 2021

Peer-review started: August 28, 2021

First decision: November 17, 2021

Revised: December 1, 2021

Accepted: January 19, 2022

Article in press: January 19, 2022

Published online: February 26, 2022



Wei-Qiang Su, Yan-Zhong Fu, Ya-Bin Xue, Fei-Fei Suo, Department of Vascular Surgery, The Second People's Hospital of Jiaozuo City, Jiaozuo 454000, Henan Province, China

Shu-Yan Liu, Department of Endocrine, The Second People's Hospital of Jiaozuo City, Jiaozuo 454000, Henan Province, China

Meng-Jie Cao, Department of Neurology, The Second Hospital of Hebei Medical University, Shijiazhuang 050000, Hebei Province, China

Wen-Chao Liu, Clinical Laboratory, The Second People's Hospital of Jiaozuo City, Jiaozuo 454000, Henan Province, China

Corresponding author: Yan-Zhong Fu, MBBS, Chief Doctor, Department of Vascular Surgery, The Second People's Hospital of Jiaozuo City, No. 17 Minzhu South Road, Jiaozuo 454000, Henan Province, China. fyzxj1995@sina.com

Abstract

BACKGROUND

Eosinophilia is an increase of more than $0.5 \times 10^9/L$ in the number of eosinophils; it is a systemic condition with an unknown etiology and is often accompanied by multiple impaired organ functions. The clinical manifestations of the disease are highly variable and diverse, rendering identification of the diagnosis challenging; hence, diagnosis and treatment are often delayed. Very few reports of this disease exist globally, especially with rare manifestations of cerebral venous sinus thrombosis and hemorrhage.

CASE SUMMARY

A 32-year-old woman with eosinophilia presented to the hospital with bilateral lower-limb edema as the first clinical manifestation, followed by an extensive maculopapular rash throughout the body. She subsequently developed cerebral venous sinus thrombosis along with bilateral lower-limb deep vein thrombosis. Two weeks earlier, she had received a single course of antibiotics from a local hospital for a low-grade fever and sore throat. After various treatments were administered for anticoagulation, maintaining blood circulation, and relieving blood stasis, the lower extremity edema improved significantly; however, the patient's eosinophil count gradually increased. She experienced cerebral venous sinus thrombosis, cerebral hemorrhage, and deep vein thrombosis of the lower limbs before being declared brain dead. In this case report, we have elaborated the diagnosis and management of deep vein thrombosis manifested as eosinophilia,

thrombocytopenia, and elevated D-dimer levels.

CONCLUSION

Because proper diagnosis is challenging, clinical vigilance is required for patients with eosinophilia, as it can lead to thrombus formation.

Key Words: Eosinophilia; Venous thromboembolism; Diagnosis; Management; Venous thrombosis; Case report

©The Author(s) 2022. Published by Baishideng Publishing Group Inc. All rights reserved.

Core Tip: A 32-year-old woman with eosinophilia developed venous thromboembolism as the disease progressed, complicated by cerebral venous sinus thrombosis and bleeding, until death. As eosinophilia can cause the blood to be in a hypercoagulable state, this may have been the main cause of the patient's venous thromboembolism. Therefore, eosinophilia is one of the risk factors of venous thromboembolism, which should arouse clinical attention.

Citation: Su WQ, Fu YZ, Liu SY, Cao MJ, Xue YB, Suo FF, Liu WC. Eosinophilia complicated with venous thromboembolism: A case report. *World J Clin Cases* 2022; 10(6): 1952-1960

URL: <https://www.wjgnet.com/2307-8960/full/v10/i6/1952.htm>

DOI: <https://dx.doi.org/10.12998/wjcc.v10.i6.1952>

INTRODUCTION

Eosinophilia is defined as an eosinophil count of more than $0.5 \times 10^9/L$ in healthy individuals. It is a systemic condition with an unknown etiology and is often accompanied by multiple impaired organ functions that include multi-system involvement, such as gastrointestinal, dermatological, central nervous, cardiovascular, and portal venous systems. The most commonly involved organs are the skin, heart, and brain; however, venous thromboembolism (VTE), membranous nephropathy, ocular manifestations, and torticollis have also been reported[1-3]. The clinical manifestations of the disease are highly variable and diverse, rendering the diagnosis challenging; hence, diagnosis and treatment are often delayed. Very few reports of this disease exist globally, especially with rare manifestations such as cerebral venous sinus thrombosis and hemorrhage.

This is a case report of a patient with eosinophilia who initially presented with bilateral lower-limb edema, followed by an extensive maculopapular rash throughout the body. She subsequently developed cerebral venous sinus thrombosis along with bilateral lower-limb deep vein thrombosis. Further, we describe the diagnosis and management of deep vein thrombosis manifested as eosinophilia, thrombocytopenia, and elevated D-dimer levels.

CASE PRESENTATION

Chief complaints

A 32-year-old woman presented to the hospital with the chief complaint of bilateral lower limb swelling for two days.

History of present illness

The patient had developed bilateral lower limb edema two days earlier, with increased severity on the right thigh; however, the superficial veins of the lower extremities were not tortuous. Color Doppler ultrasound of the lower extremities revealed insufficiency of the right common femoral venous valve, and the patient was admitted to our hospital for further treatment.

History of past illness

Two weeks prior, the patient had suffered from a low-grade fever that peaked at 37.3 °C, which was accompanied by a sore throat. She had received a single course of antibiotics from a local hospital, the specifications of which could not be ascertained. Following symptomatic improvement, no further investigations were performed or treatment administered. The patient did not experience discomfort, such as chills or chest tightness.

Personal and family history

There was no history of drug allergy, family history of inherited or systemic diseases, and no history of special exposure.

Physical examination

On admission to the hospital, the patient's vital signs were within the normal limits, with the presence of bilateral palpable enlarged superficial inguinal lymph nodes. Bilateral lower-limb pitting edema to the mid-thigh was observed, with increased severity on the right side. Furthermore, a mass of approximately 5 cm × 3 cm was palpated on the lateral aspect of the right thigh, which was firm in consistency, non-pulsating, and non-tender. The pulsations of the bilateral dorsal foot arteries were maintained. On cardiopulmonary examination, no abnormalities were detected.

Laboratory examinations

The total leucocyte count in the blood was $10.31 \times 10^9/L$, comprising 60.3% neutrophils and 15.5% eosinophils; the eosinophil count was $1.60 \times 10^9/L$; hemoglobin level was 124 g/L; and platelet count was $224 \times 10^9/L$. The level of high-sensitivity C-reactive protein (hs-CRP) in the blood was 7.31 mg/L; serum electrolyte potassium level was 3.06 mmol/L; and degradation product, D-dimer level was 0.64 mg/L fibrinogen equivalent units (FEU). Liver and kidney function, and routine urine and stool test results were within normal limits; stool test results for liver fluke eggs, fungi, and infectious diseases tests were all negative.

Imaging examinations

Chest radiography revealed no abnormalities in the heart, lungs, and diaphragm; cardiac color ultrasound revealed minimal tricuspid regurgitation and reduced left ventricular diastolic function (35%), while the left ventricular ejection fraction was normal (63%). Superficial inguinal color ultrasound revealed five hypoechoic nodules in the right groin area, the largest measuring approximately 22 mm × 7 mm, and approximately six enlarged left superficial inguinal lymph nodes, the largest measuring approximately 24 mm × 7 mm.

Treatment

After admission, the patient received 4000 U of low-molecular-weight heparin once daily to promote blood circulation and relieve stasis, reduce platelet aggregation, improve valvular function, and prevent infection. After treatment, the lower-limb edema reduced; however, the mass on the lateral right thigh was still palpable. On Day 7 of admission, the patient developed pain in the lateral thigh mass of the right lower limb following intermittent pneumatic compression therapy. Emergency bedside color Doppler ultrasound revealed lower limb muscle edema and no obvious abnormalities in the lower limb vessels. The blood tests were repeated and revealed a leucocyte count of $13.77 \times 10^9/L$, comprising 59.5% neutrophils and 26.4% eosinophils; hs-CRP, 8.50 mg/L; D-dimer, 1.28 mg/L FEU; and fibrin (proto) degradation product, 5.40 mg/L.

Following the administration of 10 mg morphine hydrochloride injection subcutaneously, the patient's pain was relieved. Computed tomography (CT) scan of the lower abdomen revealed right thigh subcutaneous edema of approximately 18 cm × 15 cm adjacent to five further enlarged right deep inguinal lymph nodes, the largest measuring approximately 22 mm × 8 mm. Magnetic resonance imaging (MRI) revealed soft tissue swelling and exudative-like changes in the superior portion of the right mid-thigh, with five enlarged deep inguinal lymph nodes adjacent to the iliac vessels, the largest measuring approximately 24 mm × 8 mm.

On Day 10 of admission, the patient developed extensive erythematous macules throughout the body. Anti-allergic treatment was administered, including dexamethasone 5 mg intravenously (once), 5% glucose injection + calcium gluconate 20 mL intravenous infusion, and loratadine tablets 10 mg once daily orally; anticoagulation treatment was discontinued.

Further diagnostic work-up

The rheumatology and immunology departments were consulted, and color Doppler ultrasound was performed for further examination of the superficial lymph nodes. No obvious enlarged lymph node echo in the bilateral supraclavicular fossae were noticed; however, multiple bilateral axillary lymph nodal echoes were observed, the largest of those measuring approximately 11 mm × 7 mm and 14 mm × 6 mm on the right and left sides, respectively. CT of the chest and upper abdomen revealed bilateral pleural effusion, suspected to be inflammatory exudates (Figure 1); mild enlargement of the bilateral axillary lymph nodes was observed, the largest of those measuring approximately 11 mm × 7 mm and 14 mm × 6 mm on the right and left sides, respectively.

Blood tests were repeated again on Day 10 and revealed a leucocyte count of $15.58 \times 10^9/L$, comprising 46.5% neutrophils and 36.7% eosinophils; eosinophil count, $5.72 \times 10^9/L$; platelet concentration, $108 \times 10^9/L$; hs-CRP, 32.52 mg/L; erythrocyte sedimentation rate, 28 mm/h; D-dimer, 4.18 mg/L FEU; fibrin (proto) degradation product, 5.86 mg/L; and aspartate aminotransferase (for myocardial enzyme spectrum) 88 U/L; the remaining parameters were within normal limits. Liver

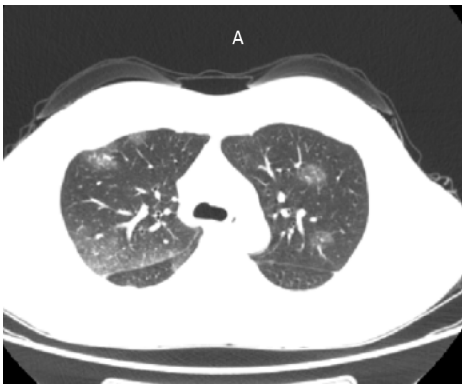


Figure 1 Computed tomography of the chest and upper abdomen reveals bilateral pleural effusion, with suspected involvement of inflammatory exudates.

function tests revealed alanine aminotransferase, 69 U/L; aspartate aminotransferase, 88 U/L; and serum potassium, 2.96 mmol/L.

A hematology consultation was recommended to further improve the related parameters. The antineutrophil cytoplasmic antibodies, antinuclear antibody spectrum, anticardiolipin antibodies, and direct Coombs test results were all negative, while thyroid function test results were within normal limits. The immune function tests revealed, immunoglobulin E, 348.81 IU/mL; complement C3, 0.83 g/L; and cytomegalovirus IgG antibody, 279.273 AU/L. The leucocyte count was $12.13 \times 10^9/L$, comprising 23.1% neutrophils and 58.1% eosinophils; eosinophil count, $7.06 \times 10^9/L$; and platelet count, $120 \times 10^9/L$.

On Day 14 of admission, the patient was transferred to the rheumatology department for further treatment. Screening tests for gynecological tumors and respiratory viral infections were negative. Bone marrow aspiration and biopsy results were consistent with high eosinophilia and did not support the morphological changes associated with myelodysplastic syndrome, plasma cell myeloma, or lymphoma; the anti-allergic treatment was continued. On Day 15 of admission, rashes over the entire body subsided significantly. Blood tests revealed a leucocyte count of $15.57 \times 10^9/L$, comprising 33.4% neutrophils and 53.3% eosinophils; eosinophil count, $8.3 \times 10^9/L$; and platelet count, $80 \times 10^9/L$.

At 3:00 AM on Day 18 of admission, the patient complained of headache, involuntary movements of the right upper limb, and decreased sensation in both the right limbs; she had no other symptoms, such as diplopia and cough. The results of an urgent cranial MRI + magnetic resonance angiography (MRA) + magnetic resonance venography (MRV) revealed the following (Figure 2): (1) Abnormal signals on the left side at the fronto-parietal junction, indicating the formation of a hematoma; (2) Abnormal signals in the right frontal lobe, indicating the possibility of a small amount of hemorrhage; (3) Hypertrophy of the left inferior turbinate; (4) No obvious abnormalities observed on the MRA scan; and (5) Brain MRV revealing (I) Superior sagittal abnormal changes in the blood vessels above the sinus and in the adjacent areas, indicating the possibility of venous sinus thrombosis and (II) Narrowing in the left transverse sinus compared to the opposite side. The patient was transferred to the neurology department for further diagnosis and treatment.

Physical examination following the transfer revealed the following findings: bilateral pupils reactive and equidistant, central position of the tongue, reduced muscle tone of the right limbs, right upper limb muscle strength level 2, and right lower limb muscle strength level 3. The pain on the right side decreased, no pathological reflex was elicited, and meningeal irritation sign was negative. The patient underwent a lumbar puncture; the pressure was 230 mm H₂O during the procedure; 20% mannitol injection 125 mL was administered every 8 h and citicoline injection 1.0 g was administered once daily.

On Day 18 of admission, an episode of projectile vomiting occurred, along with gradual loss of consciousness and limb stiffness. An urgent head CT revealed increased left frontal and parietal hemorrhage, subarachnoid hemorrhage of 15 mm \times 20 mm, midline-shift, and worsening of the brain swelling; the patient underwent neurosurgery on the same day. During the surgery, brain tissue swelling, multiple subarachnoid hemorrhages on the surface, venous congestion and stasis, disappearance of brain tissue pulsation, and a fistula at the superior frontal region with a dark red hematoma at a depth of approximately 1 cm were observed. Anterior and posterior exploration of the hematoma was performed, and it was drained. Venous blood was oozing from multiple points. The bleeding was controlled while removing the dead brain tissue.

After surgery, the left and right pupils measured 3.5 mm and 2.5 mm, respectively, and bilateral loss of response to light was observed. On Day 19 of admission (postoperative day 1), a venous color Doppler ultrasound revealed no thrombosis in the lower limb, and no obvious abnormalities in the heart were observed on the color Doppler ultrasound. Blood tests revealed a leucocyte count of $13.33 \times 10^9/L$, comprising 65.0% neutrophils and 9.3% eosinophils; eosinophil count, $1.24 \times 10^9/L$; and platelet

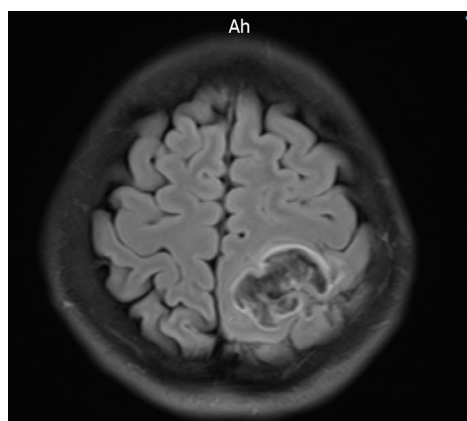


Figure 2 Abnormal signals on the left side at the fronto-parietal junction, indicating the formation of a hematoma.

count, $40 \times 10^9/L$. Liver function tests revealed albumin, 25.4 g/L and alanine aminotransferase, 50 U/L.

On Day 20 of admission (postoperative day 2), the blood test results revealed a leucocyte count of $11.03 \times 10^9/L$, comprising 78.7% neutrophils and 8.6% eosinophils; eosinophil count, $0.95 \times 10^9/L$; and platelet count, $47 \times 10^9/L$.

FINAL DIAGNOSIS

(1) Secondary (reactive) eosinophilia; (2) VTE; (3) Cerebral venous sinus thrombosis; and (4) Cerebral hemorrhage.

TREATMENT

On Day 12 of admission, low-molecular-weight heparin and amoxicillin/potassium clavulanate were discontinued; potassium chloride sustained-release tablets 1 g twice daily and loratadine oral tablets 10 mg once daily were initiated.

OUTCOME AND FOLLOW-UP

On Day 30 of admission (postoperative day 12), lower limb venous Color Doppler ultrasound revealed left lower limb femoral vein, popliteal vein, and posterior tibial vein thrombosis, indicating ineffective anticoagulation treatment due to the occurrence of cerebral hemorrhage; the patient was declared brain dead.

MANAGEMENT PROCESS

First treatment: Low-molecular-weight heparin 4000 U once daily for 9 d, amoxicillin/potassium clavulanate 1.2 g every 12 h for 12 d.

Second treatment: 20% mannitol injection 125 mL every 8 h, citicoline injection 1.0 g once daily for 2 d.

Third treatment: 20% mannitol injection 125 mL every 8 h, cefoperazone/sulbactam injection 3 g every 8 h, methylprednisolone sodium succinate 3 g every 12 h for 10 d.

DISCUSSION

Causes of VTE

The patient was a young woman with no history of tropical travel; she had a history of pre-infection and was admitted to the hospital with bilateral lower-limb edema as the chief complaint along with the presence of risk factors for thrombosis. After various treatments were administered for anticoagulation,

maintaining blood circulation, and relieving blood stasis, the lower extremity edema improved significantly; however, the patient's eosinophil count gradually increased (Figure 3). She experienced cerebral venous sinus thrombosis, cerebral hemorrhage, and deep vein thrombosis of the lower limbs before being declared brain dead.

There are three elements of VTE: (1) Stagnation of blood flow; (2) Hypercoagulable state of blood; and (3) Injury of blood vessel walls. The initiating factor of VTE in this patient was considered to be reactive eosinophilia. While participating in the normal immune defense response, eosinophils can also cause tissue cell damage. Eosinophils can act on the body's blood coagulation and anticoagulation system. On the one hand, it promotes blood coagulation and on the other hand inhibits anticoagulation, which eventually leads to thrombosis. There are three main mechanisms of eosinophilia that can act on the body through multiple pathways to cause VTE[4]: (1) Major basic protein (MBP), eosinophil cationic protein (ECP), eosinophil peroxidase (EPO), and ethylene glycol dinitrate are released through degranulation. These cytotoxic cations can damage the vascular endothelial cells. At the same time, MBP, ECP, and EPO can also increase the activity of tissue factor, factor VII, factor X, and other coagulation factors; activate the endogenous coagulation pathway; inhibit the production of activated protein C; and cause blood hypercoagulability; (2) Eosinophils can directly activate tissue factors and platelet-activating factors; leukotrienes activate exogenous coagulation pathways, activate and aggregate platelets, and promote thrombosis; and (3) Direct infiltration causes vascular endothelial cell damage. Activated eosinophils can also express CD40 Ligand (CD40L), and the CD40/CD40L system plays a role in inflammation, endothelial cell dysfunction, platelet activation and coagulation activation. Through the effects of all the above aspects, eventually thrombin and fibrin are continuously generated, which eventually leads to thrombus formation.

Reasons for elevated eosinophils

Eosinophilia is often accompanied by independent diseases; at present, there is no uniform standard for the classification of eosinophil count; values $< 1.0 \times 10^9/L$, $(1.0-5.0) \times 10^9/L$, and $> 5.0 \times 10^9/L$ generally indicate mild, moderate, and severe rise, respectively. Hypereosinophilic syndrome (HES) can be divided into four categories: hereditary (familial) HES, primary (tumor) HES, secondary (reactive) HES, and idiopathic HES[5]. We believe that the cause of HES in our patient was drug cross-reactivity due to previous antibiotic administration; thus, the patient developed secondary HES.

The most common secondary causes of eosinophilia are parasitic infections, drug allergies, allergic conditions, skin diseases, and respiratory and gastrointestinal tract diseases; however, the cause of the findings observed in our patient was not clear. The patient underwent several blood tests in our hospital, including tests for parasitic infection, asthma, skin diseases, and tests for other related causes. Prior to hospital admission, the patient's blood test results revealed a normal eosinophil count, and a single course of antibiotics was administered (the specific medication is unknown). Therefore, based on the relevant adverse drug reactions identified, clinicians should consider the possibility of cross-allergic reactions to drugs in patients with eosinophilia; thus, adverse reactions to drugs during clinical administration should be predicted and evaluated. This emphasizes the importance of understanding and observing drug allergic reactions to minimize the occurrence of drug-induced diseases. In this case, the causes of death were cerebral venous sinus thrombosis and cerebral hemorrhage. Considering that eosinophilia is caused by the hypercoagulation of blood, it should attract clinical attention; however, the mechanism underlying eosinophilia leading to thrombosis has not been fully elucidated. Nevertheless, patients with eosinophilia are considered to be in a prethrombotic state and tend to develop thrombosis [6-8].

Causes of muscle edema of the right lower extremity

The patient's right thigh was swollen and painful. MRI revealed that the soft tissue in the upper and middle part of the right thigh was swollen with exudative-like changes. Considering the patient's increased eosinophil count, the edema could have been attributed to eosinophilic fasciitis, a connective tissue disease that is usually caused by overwork and a response to immunosuppression[9]. Biopsy is an important means of diagnosis of eosinophilic fasciitis. Fascial skin biopsy showed evidential fascia thickening and infiltration of lymphocytes and plasma cells, giving rise to inflammatory conditions[10]. Fascia fibrosis was also detected. However, the patient did not undergo a muscle biopsy as she had a decreased eosinophil count during follow-up treatment. Moreover, the symptoms of edema of the right thigh muscle disappeared, which also indirectly supports the possibility of eosinophilia.

Related treatment of eosinophilia with VTE

This patient had increased eosinophils and a progressive decline in the platelet count (Figure 4). The mechanism underlying this phenomenon could be that eosinophils inhibit bone marrow megakaryocytes, causing the megakaryocytes to mature and become plaque-producing. The reduction of megakaryocytes reduces the number of platelets circulating in the peripheral blood, and further platelets are consumed by the thrombus, thereby exacerbating thrombocytopenia. On one hand, glucocorticoid therapy can effectively control the eosinophil count and avoid target organ damage; on the other hand, it can also restore the number of platelets[2]. However, the patient's condition progressed rapidly, and she was not treated with glucocorticoids before hemodynamic diseases were

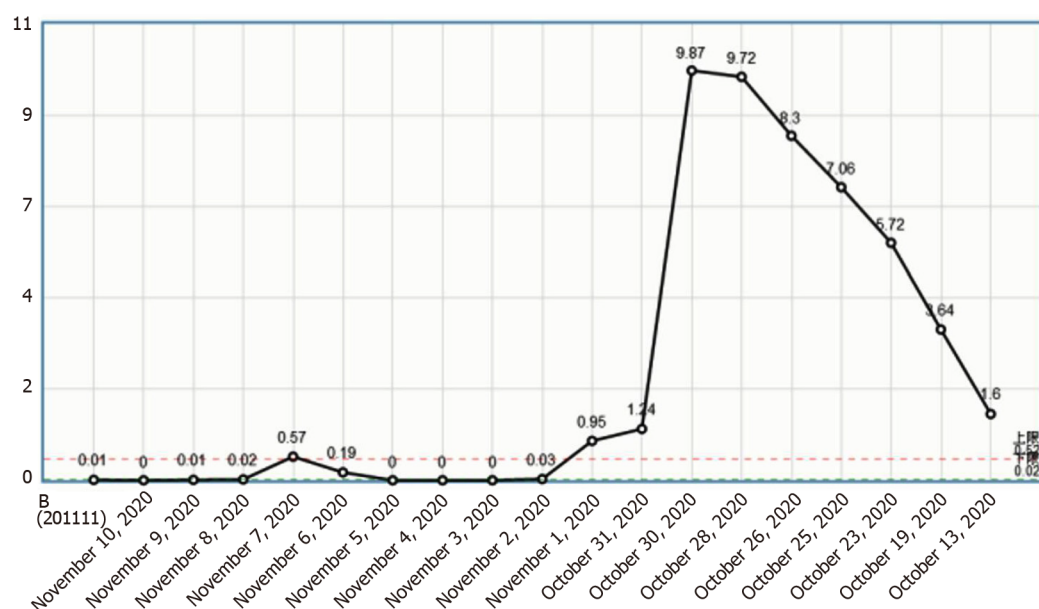


Figure 3 Change curve of the eosinophil count.

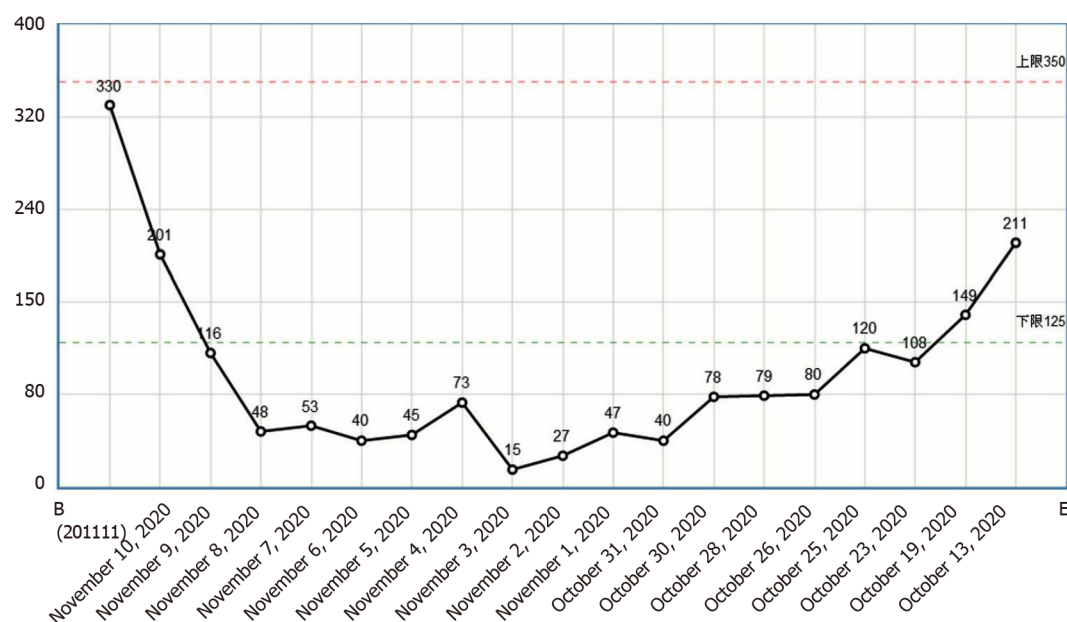


Figure 4 Change curve of the platelet count.

ruled out, which caused platelet activation and aggregation followed by thrombosis. Clinical vigilance is required for eosinophilia because a high eosinophil count can cause vascular endothelial damage and easily lead to thrombus formation[11]; however, the most important cause of VTE events is the release of basic proteins and other substances following degranulation. The eosinophil count indicates the degree of organ damage; therefore, the authors recommend routine peripheral blood smears for patients with eosinophilia to observe whether there are changes in degranulation. If there are changes in degranulation (Figure 5), active treatment to avoid organ damage and VTE events is recommended. For patients with unexplained eosinophilia, active administration of glucocorticoids is recommended in the absence of contraindications for glucocorticoids; similarly, anticoagulation therapy is recommended as soon as possible in the absence of contraindications for anticoagulation therapy. The ultimate goal is to reduce the eosinophil count and to prevent VTE events, especially fatal adverse events such as cerebral venous sinus thrombosis and pulmonary embolism.

This patient had increased eosinophil and D-dimer levels (Figure 6). She was admitted to the hospital with edema of bilateral lower extremities and administered preventive doses of anticoagulant therapy. Anticoagulation therapy was discontinued for allergen screening during follow-up treatment. Cerebral venous sinus thrombosis and deep vein thrombosis of the lower extremities occurred. Due to the

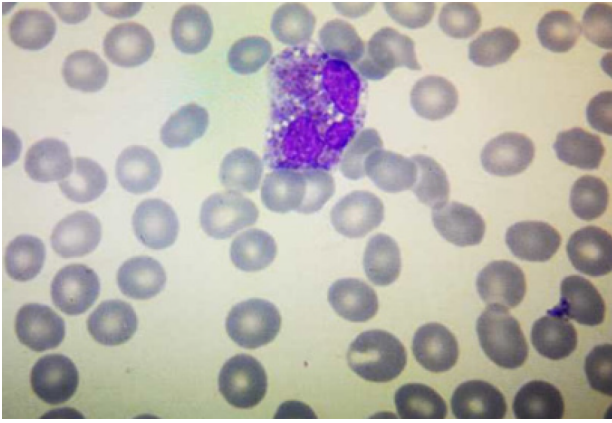


Figure 5 Eosinophil degranulation.

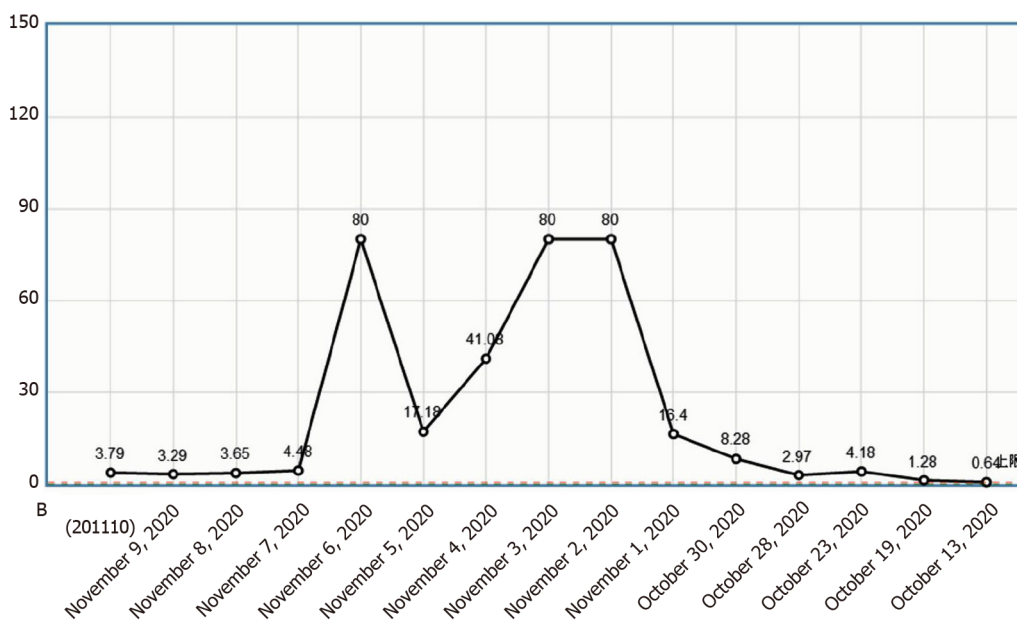


Figure 6 D-dimer change curve.

combination of cerebral hemorrhage and thrombocytopenia, anticoagulation therapy was not administered. Anticoagulation therapy may benefit patients in the context of assessing the risk of bleeding; however, further studies are warranted.

In patients with eosinophilia, the skin is one of the most frequently affected organs; pathological features of eosinophilia include eosinophil infiltration and/or eosinophil degranulation[12]. Skin biopsy shows inflammatory changes in blood vessels, and the surrounding blood vessels are mainly infiltrated by mild to moderate eosinophils and monocytes[2]. In 2006, Caputo *et al*[13] proposed seven classifications for eosinophilic cellulitis: fixed drug eruption, plaque, bullous, granuloma annulare, papule, papule nodular, and urticaria-like. The patient's skin over the entire body was covered in rashes, which was accompanied by itching, especially at night. Considering that this may be related to diurnal fluctuations in the release of glucocorticoids from the adrenal cortex, the patient was administered symptomatic treatments such as loratadine, levocetirizine, and calcium gluconate; the rash over her body subsided, and the skin and mucous membranes returned to normal.

CONCLUSION

In conclusion, eosinophilia can cause hypercoagulation of the blood, which can cause thrombosis in the veins of the lower extremities and heart, or even embolisms in the blood vessels of the lungs and brain. Early diagnosis is difficult; hence, vigilance is recommended to prevent a high mortality rate.

FOOTNOTES

Author contributions: Fu YZ and Su WQ were vascular surgeons who participated in the drafting of the manuscript and reviewed the literature; Xue YB and Suo FF were responsible for the collection of medical history data and literature; Liu SY participated in the revision of the manuscript; Cao MJ and Liu WC reviewed the literature and provided imaging examinations, especially blood smears; all authors issued final approval for the version to be submitted.

Informed consent statement: Verbal informed consent was obtained from the patient's family.

Conflict-of-interest statement: The authors declare that they have no conflict of interest.

CARE Checklist (2016) statement: The authors have read the CARE Checklist (2016), and the manuscript was prepared and revised according to the CARE Checklist (2016).

Open-Access: This article is an open-access article that was selected by an in-house editor and fully peer-reviewed by external reviewers. It is distributed in accordance with the Creative Commons Attribution NonCommercial (CC BY-NC 4.0) license, which permits others to distribute, remix, adapt, build upon this work non-commercially, and license their derivative works on different terms, provided the original work is properly cited and the use is non-commercial. See: <https://creativecommons.org/licenses/by-nc/4.0/>

Country/Territory of origin: China

ORCID number: Wei-Qiang Su 0000-0001-8011-0872; Yan-Zhong Fu 0000-0002-3054-8259; Shu-Yan Liu 0000-0001-7336-1307; Meng-Jie Cao 0000-0002-3257-9606; Ya-Bin Xue 0000-0003-2887-4220; Fei-Fei Suo 0000-0001-5413-431X; Wen-Chao Liu 0000-0003-2393-4968.

S-Editor: Liu JH

L-Editor: A

P-Editor: Liu JH

REFERENCES

- Li D, Xu L, Lin D, Jiang S, Feng S, Zhu L. Acute pulmonary embolism and deep vein thrombosis secondary to idiopathic hypereosinophilic syndrome. *Respir Med Case Rep* 2018; **25**: 213-215 [PMID: 30237972 DOI: 10.1016/j.rmcr.2018.09.006]
- Kim JA, Kim N, Choi HS, Choung HK, Khwarg SI. Eyelid Swelling and Subconjunctival Infiltration as Ophthalmic Manifestations in a Child with Idiopathic Hypereosinophilic Syndrome. *Korean J Ophthalmol* 2018; **32**: 517-518 [PMID: 30549476 DOI: 10.3341/kjo.2018.0057]
- Das JK, Gupta K, Deshmukh S, Shrivastava R. A rare case of hypereosinophilic syndrome presenting with unilateral proptosis and torticollis. *Indian J Ophthalmol* 2018; **66**: 1508-1511 [PMID: 30249857 DOI: 10.4103/ijo.IJO_316_18]
- Noh HR, Magpantay GG. Hypereosinophilic syndrome. *Allergy Asthma Proc* 2017; **38**: 78-81 [PMID: 28052805 DOI: 10.2500/aap.2017.38.3995]
- Leukemia and Lymphoma Group, Chinese Society of Hematology; Chinese Medical Association. [Chinese expert consensus on the diagnosis and treatment of eosinophilia (2017)]. *Zhonghua Xueyexue Zazhi* 2017; **38**: 561-565 [PMID: 28810320 DOI: 10.3760/cma.j.issn.0253-2727.2017.07.001]
- Maino A, Rossio R, Cugno M, Marzano AV, Tedeschi A. Hypereosinophilic syndrome, Churg-Strauss syndrome and parasitic diseases: possible links between eosinophilia and thrombosis. *Curr Vasc Pharmacol* 2012; **10**: 670-675 [PMID: 22272911 DOI: 10.2174/157016112801784594]
- Sneeboer MMS, Majoor CJ, de Kievit A, Meijers JCM, van der Poll T, Kamphuisen PW, Bel EH. Prothrombotic state in patients with severe and prednisolone-dependent asthma. *J Allergy Clin Immunol* 2016; **137**: 1727-1732 [PMID: 26714414 DOI: 10.1016/j.jaci.2015.10.038]
- Ames PR. Recurrent abdominal thrombosis despite heparin thromboprophylaxis in a patient with transient eosinophilia. *Clin Appl Thromb Hemost* 2011; **17**: 229-231 [PMID: 19671564 DOI: 10.1177/1076029609343450]
- Dong N, Dong XY. [Pediatric idiopathic hypereosinophilic syndrome with pulmonary embolism: a case report and review of literature]. *Zhonghua Er Ke Za Zhi* 2017; **55**: 775-779 [PMID: 29050117 DOI: 10.3760/cma.j.issn.0578-1310.2017.10.013]
- Ihn H. Eosinophilic fasciitis: From pathophysiology to treatment. *Allergol Int* 2019; **68**: 437-439 [PMID: 30910631 DOI: 10.1016/j.alit.2019.03.001]
- Sturdy A, Stratton R, Perez-Machado M, Lamb L. Case of eosinophilic fasciitis during military training in a Nepalese British infantry soldier. *BMJ Mil Health* 2020; **166**: 277-278 [PMID: 32139410 DOI: 10.1136/jramc-2019-001273]
- Peckruhn M, Elsner P, Tittelbach J. Eosinophilic dermatoses. *J Dtsch Dermatol Ges* 2019; **17**: 1039-1051 [PMID: 31562692 DOI: 10.1111/ddg.13943]
- Caputo R, Marzano AV, Vezzoli P, Lunardon L. Wells syndrome in adults and children: a report of 19 cases. *Arch Dermatol* 2006; **142**: 1157-1161 [PMID: 16983003 DOI: 10.1001/archderm.142.9.1157]



Published by **Baishideng Publishing Group Inc**
7041 Koll Center Parkway, Suite 160, Pleasanton, CA 94566, USA

Telephone: +1-925-3991568

E-mail: bpgoffice@wjgnet.com

Help Desk: <https://www.f6publishing.com/helpdesk>

<https://www.wjgnet.com>

