


# World Journal of *Clinical Cases*

*World J Clin Cases* 2022 March 6; 10(7): 2053-2361



**FIELD OF VISION**

- 2053 Personalized treatment - which interaction ingredients should be focused to capture the unconscious  
*Steinmair D, Löffler-Stastka H*

**MINIREVIEWS**

- 2063 Patterns of liver profile disturbance in patients with COVID-19  
*Shousha HI, Ramadan A, Lithy R, El-Kassas M*

**ORIGINAL ARTICLE****Clinical and Translational Research**

- 2072 Prognostic and biological role of the N-Myc downstream-regulated gene family in hepatocellular carcinoma  
*Yin X, Yu H, He XK, Yan SX*

**Case Control Study**

- 2087 Usefulness of the acromioclavicular joint cross-sectional area as a diagnostic image parameter of acromioclavicular osteoarthritis  
*Joo Y, Moon JY, Han JY, Bang YS, Kang KN, Lim YS, Choi YS, Kim YU*
- 2095 Correlation between betatrophin/angiogenin-likeprotein3/lipoprotein lipase pathway and severity of coronary artery disease in Kazakh patients with coronary heart disease  
*Qin L, Rehemuding R, Ainiwaer A, Ma X*

**Retrospective Study**

- 2106 Postoperative adverse cardiac events in acute myocardial infarction with high thrombus load and best time for stent implantation  
*Zhuo MF, Zhang KL, Shen XB, Lin WC, Hu B, Cai HP, Huang G*
- 2115 Develop a nomogram to predict overall survival of patients with borderline ovarian tumors  
*Gong XQ, Zhang Y*

**Clinical Trials Study**

- 2127 Diagnostic performance of Neutrophil CD64 index, procalcitonin, and C-reactive protein for early sepsis in hematological patients  
*Shang YX, Zheng Z, Wang M, Guo HX, Chen YJ, Wu Y, Li X, Li Q, Cui JY, Ren XX, Wang LR*
- 2138 Previously unexplored etiology for femoral head necrosis: Metagenomics detects no pathogens in necrotic femoral head tissue  
*Liu C, Li W, Zhang C, Pang F, Wang DW*

**Observational Study**

- 2147** Association of types of diabetes and insulin dependency on birth outcomes  
*Xaverius PK, Howard SW, Kiel D, Thurman JE, Wankum E, Carter C, Fang C, Carriere R*
- 2159** Pathological pattern of endometrial abnormalities in postmenopausal women with bleeding or thickened endometrium  
*Xue H, Shen WJ, Zhang Y*
- 2166** *In vitro* maturation of human oocytes maintaining good development potential for rescue intracytoplasmic sperm injection with fresh sperm  
*Dong YQ, Chen CQ, Huang YQ, Liu D, Zhang XQ, Liu FH*
- 2174** Ultrasound-guided paravertebral nerve block anesthesia on the stress response and hemodynamics among lung cancer patients  
*Zhen SQ, Jin M, Chen YX, Li JH, Wang H, Chen HX*

**META-ANALYSIS**

- 2184** Prognostic value of YKL-40 in colorectal carcinoma patients: A meta-analysis  
*Wang J, Qi S, Zhu YB, Ding L*
- 2194** Prognostic value of neutrophil/lymphocyte, platelet/lymphocyte, lymphocyte/monocyte ratios and Glasgow prognostic score in osteosarcoma: A meta-analysis  
*Peng LP, Li J, Li XF*

**CASE REPORT**

- 2206** Endovascular stent-graft treatment for aorto-esophageal fistula induced by an esophageal fishbone: Two cases report  
*Gong H, Wei W, Huang Z, Hu Y, Liu XL, Hu Z*
- 2216** Quetiapine-related acute lung injury: A case report  
*Huang YX, He GX, Zhang WJ, Li BW, Weng HX, Luo WC*
- 2222** Primary hepatic neuroendocrine neoplasm diagnosed by somatostatin receptor scintigraphy: A case report  
*Akabane M, Kobayashi Y, Kinowaki K, Okubo S, Shindoh J, Hashimoto M*
- 2229** Multidisciplinary non-surgical treatment of advanced periodontitis: A case report  
*Li LJ, Yan X, Yu Q, Yan FH, Tan BC*
- 2247** Flip-over of blood vessel intima caused by vascular closure device: A case report  
*Sun LX, Yang XS, Zhang DW, Zhao B, Li LL, Zhang Q, Hao QZ*
- 2253** Huge gastric plexiform fibromyxoma presenting as pyemia by rupture of tumor: A case report  
*Zhang R, Xia LG, Huang KB, Chen ND*
- 2261** Intestinal intussusception caused by intestinal duplication and ectopic pancreas: A case report and review of literature  
*Wang TL, Gong XS, Wang J, Long CY*

- 2268** Mixed neuroendocrine-nonneuroendocrine neoplasm of the ampulla: Four case reports  
*Wang Y, Zhang Z, Wang C, Xi SH, Wang XM*
- 2275** Y-shaped shunt for the treatment of Dandy-Walker malformation combined with giant arachnoid cysts: A case report  
*Dong ZQ, Jia YF, Gao ZS, Li Q, Niu L, Yang Q, Pan YW, Li Q*
- 2281** Posterior reversible encephalopathy syndrome in a patient with metastatic breast cancer: A case report  
*Song CH, Lee SJ, Jeon HR*
- 2286** Multiple skin abscesses associated with bacteremia caused by *Burkholderia gladioli*: A case report  
*Wang YT, Li XW, Xu PY, Yang C, Xu JC*
- 2294** Giant infected hepatic cyst causing exclusion pancreatitis: A case report  
*Kenzaka T, Sato Y, Nishisaki H*
- 2301** Cutaneous leishmaniasis presenting with painless ulcer on the right forearm: A case report  
*Zhuang L, Su J, Tu P*
- 2307** Gastrointestinal amyloidosis in a patient with smoldering multiple myeloma: A case report  
*Liu AL, Ding XL, Liu H, Zhao WJ, Jing X, Zhou X, Mao T, Tian ZB, Wu J*
- 2315** Breast and dorsal spine relapse of granulocytic sarcoma after allogeneic stem cell transplantation for acute myelomonocytic leukemia: A case report  
*Li Y, Xie YD, He SJ, Hu JM, Li ZS, Qu SH*
- 2322** Synchronous but separate neuroendocrine tumor and high-grade dysplasia/adenoma of the gall bladder: A case report  
*Hsiao TH, Wu CC, Tseng HH, Chen JH*
- 2330** Novel mutations of the Alström syndrome 1 gene in an infant with dilated cardiomyopathy: A case report  
*Jiang P, Xiao L, Guo Y, Hu R, Zhang BY, He Y*
- 2336** Acute esophageal obstruction after ingestion of psyllium seed husk powder: A case report  
*Shin S, Kim JH, Mun YH, Chung HS*
- 2341** Spontaneous dissection of proximal left main coronary artery in a healthy adolescent presenting with syncope: A case report  
*Liu SF, Zhao YN, Jia CW, Ma TY, Cai SD, Gao F*
- 2351** Relationship between treatment types and blood-brain barrier disruption in patients with acute ischemic stroke: Two case reports  
*Seo Y, Kim J, Chang MC, Huh H, Lee EH*
- 2357** Ultrasound-guided rectus sheath block for anterior cutaneous nerve entrapment syndrome after laparoscopic surgery: A case report  
*Sawada R, Watanabe K, Tokumine J, Lefor AK, Ando T, Yoroze T*

**ABOUT COVER**

Editorial Board Member of *World Journal of Clinical Cases*, Feng Yin, MD, PhD, Assistant Professor, Department of Pathology and Anatomic Sciences, University of Missouri, Columbia, MO 65212, United States.  
fengyin@health.missouri.edu

**AIMS AND SCOPE**

The primary aim of *World Journal of Clinical Cases* (WJCC, *World J Clin Cases*) is to provide scholars and readers from various fields of clinical medicine with a platform to publish high-quality clinical research articles and communicate their research findings online.

WJCC mainly publishes articles reporting research results and findings obtained in the field of clinical medicine and covering a wide range of topics, including case control studies, retrospective cohort studies, retrospective studies, clinical trials studies, observational studies, prospective studies, randomized controlled trials, randomized clinical trials, systematic reviews, meta-analysis, and case reports.

**INDEXING/ABSTRACTING**

The WJCC is now indexed in Science Citation Index Expanded (also known as SciSearch®), Journal Citation Reports/Science Edition, Scopus, PubMed, and PubMed Central. The 2021 Edition of Journal Citation Reports® cites the 2020 impact factor (IF) for WJCC as 1.337; IF without journal self cites: 1.301; 5-year IF: 1.742; Journal Citation Indicator: 0.33; Ranking: 119 among 169 journals in medicine, general and internal; and Quartile category: Q3. The WJCC's CiteScore for 2020 is 0.8 and Scopus CiteScore rank 2020: General Medicine is 493/793.

**RESPONSIBLE EDITORS FOR THIS ISSUE**

Production Editor: Lin-YuTong Wang; Production Department Director: Xiang Li; Editorial Office Director: Jin-Lai Wang.

**NAME OF JOURNAL**

*World Journal of Clinical Cases*

**ISSN**

ISSN 2307-8960 (online)

**LAUNCH DATE**

April 16, 2013

**FREQUENCY**

Thrice Monthly

**EDITORS-IN-CHIEF**

Bao-Gan Peng, Jerzy Tadeusz Chudek, George Kontogeorgos, Maurizio Serati, Ja Hyeon Ku

**EDITORIAL BOARD MEMBERS**

<https://www.wjgnet.com/2307-8960/editorialboard.htm>

**PUBLICATION DATE**

March 6, 2022

**COPYRIGHT**

© 2022 Baishideng Publishing Group Inc

**INSTRUCTIONS TO AUTHORS**

<https://www.wjgnet.com/bpg/gerinfo/204>

**GUIDELINES FOR ETHICS DOCUMENTS**

<https://www.wjgnet.com/bpg/GerInfo/287>

**GUIDELINES FOR NON-NATIVE SPEAKERS OF ENGLISH**

<https://www.wjgnet.com/bpg/gerinfo/240>

**PUBLICATION ETHICS**

<https://www.wjgnet.com/bpg/GerInfo/288>

**PUBLICATION MISCONDUCT**

<https://www.wjgnet.com/bpg/gerinfo/208>

**ARTICLE PROCESSING CHARGE**

<https://www.wjgnet.com/bpg/gerinfo/242>

**STEPS FOR SUBMITTING MANUSCRIPTS**

<https://www.wjgnet.com/bpg/GerInfo/239>

**ONLINE SUBMISSION**

<https://www.f6publishing.com>



## Endovascular stent-graft treatment for aorto-esophageal fistula induced by an esophageal fishbone: Two cases report

Hang Gong, Wei Wei, Zhong Huang, Ying Hu, Xian-Li Liu, Zhen Hu

**Specialty type:** Cardiac and cardiovascular systems

**Provenance and peer review:** Unsolicited article; externally peer reviewed.

**Peer-review model:** Single blind

**Peer-review report's scientific quality classification**

Grade A (Excellent): 0  
Grade B (Very good): B  
Grade C (Good): C, C  
Grade D (Fair): 0  
Grade E (Poor): 0

**P-Reviewer:** Costache RS, Mezzetto L

**Received:** October 10, 2021

**Peer-review started:** October 10, 2021

**First decision:** November 11, 2021

**Revised:** November 21, 2021

**Accepted:** January 17, 2022

**Article in press:** January 17, 2022

**Published online:** March 6, 2022



**Hang Gong, Wei Wei, Zhong Huang, Zhen Hu,** Department of Gastroenterology, Zigong First People's Hospital, Zigong 643000, Sichuan Province, China

**Ying Hu,** Department of Gastroenterology, Luzhou People's Hospital, Luzhou 646000, Sichuan Province, China

**Xian-Li Liu,** Department of Ultrasound, Zigong TCM Hospital, Zigong 643000, Sichuan Province, China

**Corresponding author:** Hang Gong, MMed, Doctor, Department of Gastroenterology, Zigong First People's Hospital, No. 42 Shangyihao Road, Zigong 643000, Sichuan Province, China. [343311398@qq.com](mailto:343311398@qq.com)

### Abstract

#### BACKGROUND

Aorto-esophageal fistula (AEF) induced by esophageal fishbones is a rare complication of esophageal foreign bodies and is very difficult to treat. Although the current view suggests that endovascular stent-graft treatment is useful for AEF, whether a subsequent thoracic operation is necessary remains controversial. The purpose of this report is to describe our experience using endovascular stent-graft treatment without combined thoracic operations for the treatment of AEF in two specific cases.

#### CASE SUMMARY

We presented two cases of patients complaining of retrosternal discomfort treated in our department for an aorto-esophageal fistula caused by the accidental ingestion of a fishbone. The two patients were effectively managed with combined means of endoscopic, medical (broad-spectrum antibiotic therapy, fasting, gastrointestinal decompression, etc.) and endovascular stent-graft treatment. The main difference in treatment was that the first patient presented with hematemesis after endoscopic removal of the fishbone. Subsequently, the patient underwent endovascular stent-graft treatment. The second case was managed with endoscopic removal of the fishbone with simultaneous endovascular stent-graft treatment, without any signs of hematemesis or melena. Both patients had successful postoperative management and were discharged home. Long-term follow-up is ongoing.

#### CONCLUSION

The treatment decision-making process should depend on the patients' specific

situations. Our practice indicates that endovascular stent-graft treatment without combined thoracic operations could be a valuable alternative in selected patients.

**Key Words:** Aortoesophageal fistula; Foreign body; Esophagus; Endovascular treatment; Case report

©The Author(s) 2022. Published by Baishideng Publishing Group Inc. All rights reserved.

**Core Tip:** Esophageal foreign body is the most common cause of aortoesophageal fistula. Aortoesophageal fistula is easily confused with other upper gastrointestinal bleeding, and it is very dangerous and has serious consequences. In this work, we presented two cases of perforation of esophagus due to foreign body and analyzed the 8 similar cases recorded in PubMed, MEDLINE from January 2000 to October 2021. This pooled analysis of involving endovascular stent-graft treatment of aortoesophageal fistula or other aortic injury secondary to foreign body, in view of clinical course, imaging, treatment and prognosis may provide a better understanding of aortoesophageal fistula.

**Citation:** Gong H, Wei W, Huang Z, Hu Y, Liu XL, Hu Z. Endovascular stent-graft treatment for aortoesophageal fistula induced by an esophageal fishbone: Two cases report. *World J Clin Cases* 2022; 10(7): 2206-2215

**URL:** <https://www.wjgnet.com/2307-8960/full/v10/i7/2206.htm>

**DOI:** <https://dx.doi.org/10.12998/wjcc.v10.i7.2206>

## INTRODUCTION

Esophageal foreign bodies are one of the most common reasons for emergency treatment, and fishbones are one of the most common esophageal foreign bodies. Regions of esophageal stenosis are the most common sites of esophageal obstruction and perforation[1]. The main causes of aortoesophageal fistula (AEF) are aneurysms, ingestion of foreign bodies, and advanced esophageal cancer. AEF is a rare disease with high mortality, with an annual incidence of 0.007 per million[2]. AEF is easily confused with other causes of upper gastrointestinal bleeding, is very dangerous and has serious consequences [3]. Currently, considerable controversy remains regarding the appropriate management strategies for this disease. Here, we present our successful experience in managing two consecutive patients with AEF using endovascular stent-graft treatment with multidisciplinary integrated management without combined thoracic operations.

## CASE PRESENTATION

### Chief complaints

**Case 1:** A 71-year-old Chinese woman presented to our department complaining of ingestion of a fish bone foreign body, with worsening retrosternal chest pain for 4 d.

**Case 2:** A 48-year-old man presented to the emergency room with a history of intense retrosternal discomfort lasting for 2 d after swallowing a fish bone.

### History of present illness

**Case 1:** There were no complaints of fever, haematemesis, or any other symptoms.

**Case 2:** There were no other symptoms.

### History of past illness

No special circumstances.

### Personal and family history

No special circumstances.

### Physical examination

No obvious abnormal physical examinations.



## Laboratory examinations

**Case 1:** No obvious abnormal laboratory markers were observed.

**Case 2:** A routine blood analysis showed a white blood cell (WBC) counting of  $11.34 \times 10^9/L$ .

## Imaging examinations

**Case 1:** Esophagogastroduodenoscopy (EGD) (Figure 1A) and chest computed tomography angiography (CTA) (Figure 1B-D) showed that a fish bone (length 2.0 cm) penetrated the wall of the esophagus and entered the thoracic aorta.

**Case 2:** Chest CTA (Figure 2) confirmed that the fishbone puncturing through the esophageal wall was tightly appressed to the descending aortic wall, with mediastinal hematoma.

## FINAL DIAGNOSIS

### Case 1

Perforation of the esophagus due to a foreign body with AEF.

### Case 2

Perforation of the esophagus due to a foreign body without exclusion of perforating wounds to the descending aorta.

## TREATMENT

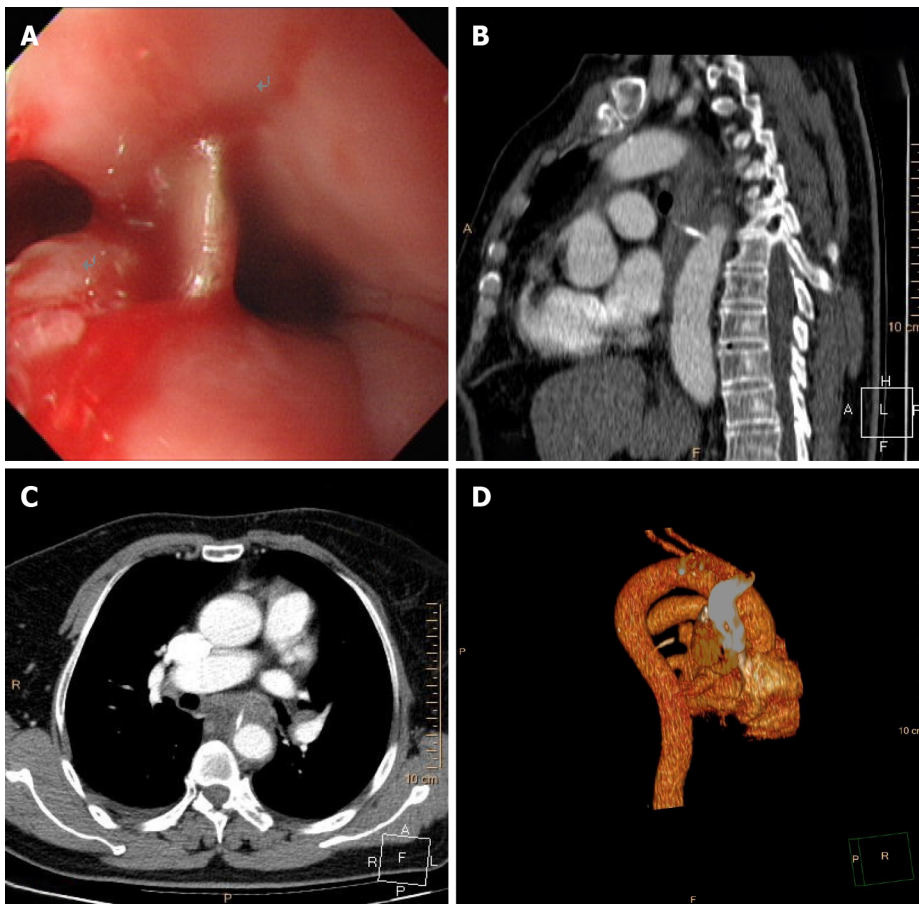
### Case 1

According to the wishes of the patient and her family, the patient was transferred to an affiliated hospital of a provincial medical college for further treatment. The foreign body was removed from the mouth using biopsy forceps by a local endoscopist on the first day after transfer to the hospital. However, the patient coughed up blood several times the next morning. The management of the patient is unclear due to a lack of medical records. She requested discharge from the affiliated hospital after fluid resuscitation, with relatively steady vital signs. Eventually, the patient was referred to the intensive care unit (ICU) of our hospital for evaluation and remediation. A reexamination with chest CTA (Figure 3) demonstrated thoracic aorta extravasation of contrast medium and swollen and thickened walls of the middle esophagus. We collaborated closely with a multidisciplinary team comprising gastroenterology, cardiovascular medicine, vascular surgery, and cardiothoracic surgery specialists. The patient underwent closure of the perforated aortic cavity *via* a minimally invasive interventional technique performed by vascular surgeons, with cardiothoracic teams on standby in case conversion to open surgery was necessary. An endovascular stent graft (30 mm  $\times$  200 mm, Ankura™, Shenzhen, China) was placed inside the descending aorta, and intraoperative high-pressure angiography confirmed successful results, with no extravasation of contrast medium. The patient underwent continuous broad-spectrum antibiotic therapy (intravenous vancomycin for 1 wk, piperacillin-tazobactam and metronidazole for 4 wk), nasogastric tube decompression and total parenteral nutrition for 3 wk after the intervention, during which she was constantly observed for indications of secondary or delayed bleeding or fever. The final chest CTA (Figure 4) demonstrated that the thoracic aortic stent graft was in the thoracic aorta and unobstructed without contrast agent extravasation. In addition, the swollen and thickened wall of the middle esophagus was significantly improved.

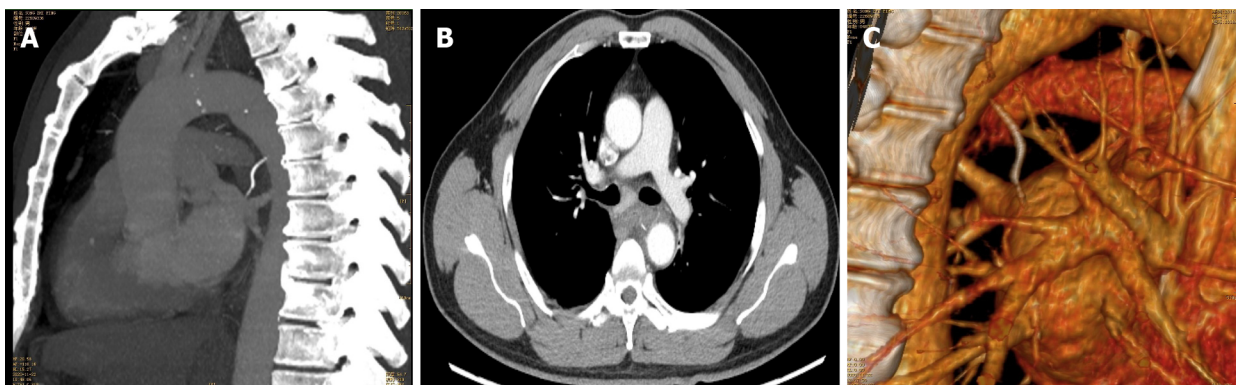
### Case 2

After a multidisciplinary consultation, including gastroenterology, cardiovascular medicine, vascular surgery, and cardiothoracic surgery specialists, an aorta impaled by a foreign body was suspected. The angiographic catheter was first guided into the thoracic aorta, and arteriography revealed a 1 cm vascular niche in the descending aorta. Then, an endovascular stent graft that had not yet been released was delivered to the selected location by a vascular surgeon. EGD showed that both ends of the fish bones inserted into the esophageal wall 28 cm from the incisors (Figure 5A); The fish bone was gently removed endoscopically (Figure 5B), with subsequent active blood spurting noted in the esophageal defect (Figure 5C). At the critical moment, the aortal stent graft (28 mm  $\times$  200 mm, Ankura™, Shenzhen, China) was immediately released by a vascular surgeon, and angiography showed that the aortal defect was closed well. After endoscopic irrigation with normal saline, two longitudinal ulcers were observed (Figure 5D). A nasogastric tube was inserted to drain the digestive juice. After intervention, the patient fasted and received broad-spectrum antibiotic therapy (intravenous vancomycin for 1 wk, cefoperazone-sulbactam and metronidazole for 3 wk). After spending one day in the ICU because of a fever, the patient was transferred back to our department. No active bleeding was observed. He had no fever and



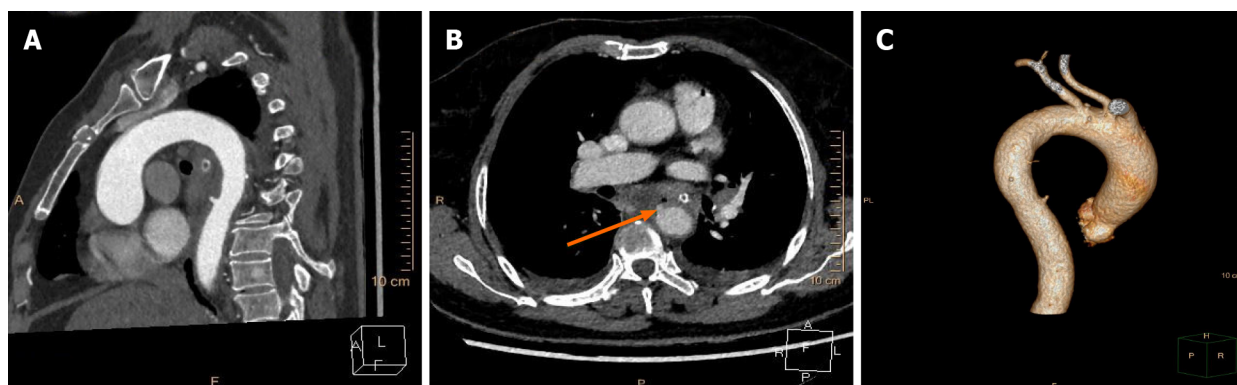


**Figure 1 Esophagogastrroduodenoscopy and chest computed tomography angiography.** A: Esophagogastrroduodenoscopy shows a straight fishbone penetrating the wall of the esophagus, with overflowing purulent secretion, 25 cm from the incisors. The other three pictures reveal preoperative chest computed tomography angiography of the fishbone (length 2.0 cm) penetrating the wall of the esophagus and into the thoracic aorta; B: Sagittal view; C: Axial view; D: Three-dimensional reconstruction.

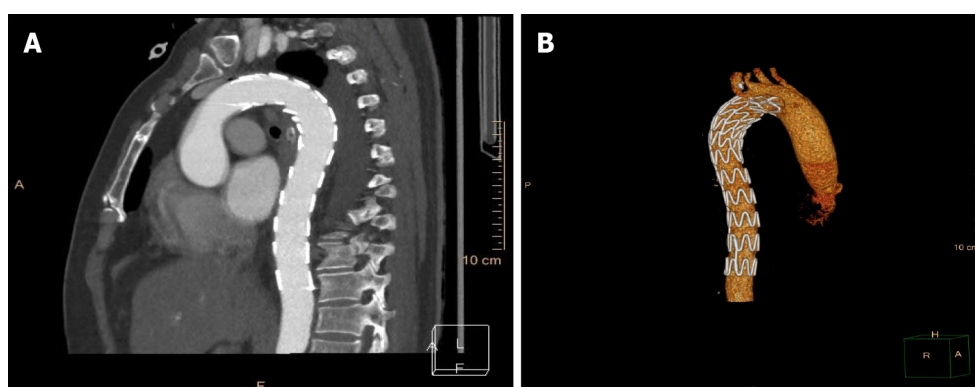


**Figure 2 Preoperative chest computed tomography angiography shows a fishbone puncturing through the esophageal wall, tightly appressed to the descending aortic wall, accompanied by mediastinal hematoma.** A: Sagittal view; B: Axial view; C: Three-dimensional reconstruction.

no hematemesis or melena. CTA showed a well-positioned aortic stent graft and no contrast extravasation from the aorta (Figure 6). On the 7<sup>th</sup> day after the operation, esophageal imaging with meglumine diatrizoate demonstrated no leakage (Figure 7), and the gastrointestinal decompression tube was removed.



**Figure 3** Chest computed tomography angiography images after removal of the fishbone in case 1. Extravasation of contrast agent presented a small nodular shadow in the thoracic aorta, and the wall of the middle esophagus was swollen and thickened. A: Sagittal view; B: Axial view; C: Three-dimensional reconstruction.



**Figure 4** Chest computed tomography angiography images after endovascular stent-graft treatment in case 1. The stent-graft was seen in the thoracic aorta without obstruction or contrast agent extravasation, and the swollen and thickened wall of the middle esophagus was significantly improved. A: Sagittal view; B: Three-dimensional reconstruction.

## OUTCOME AND FOLLOW-UP

### Case 1

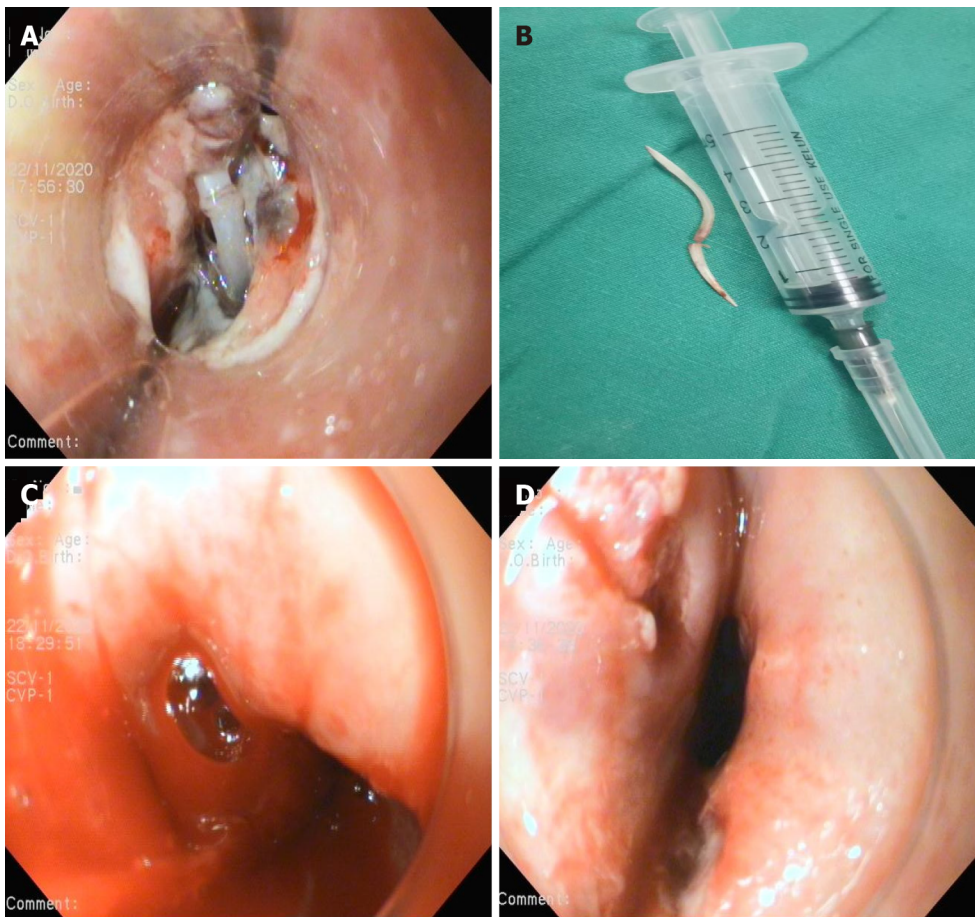
The patient started oral intake on the 21<sup>st</sup> postoperative day and was discharged on day 28; later, her treatment was changed to oral antibiotics for 4 wk. The patient's symptoms improved without fever and hematemesis. The patient was alive at the 19-mo follow-up.

### Case 2

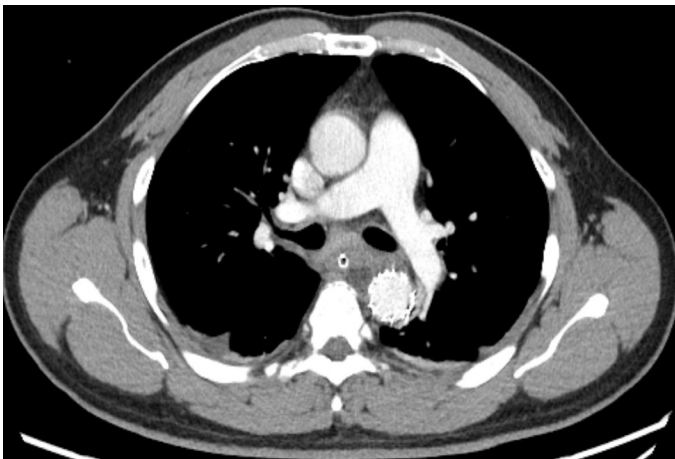
The patient started liquid intake on the 7<sup>th</sup> postoperative day and was discharged on day 21, with a home therapy antibiotic course for 4 wk. The patient was symptom-free and alive at the 5-mo follow-up.

## DISCUSSION

The treatments of AEF mainly include the following: (1) Enteral feeding with broad-spectrum antibiotics and proton pump inhibitors, as well as percutaneous endoscopic gastrostomy or esophageal fistula bypass, but these approaches are often ineffective due to recurrent bleeding and severe infection[4]; (2) Endovascular stent-graft treatment is a rapid, minimally invasive and effective alternative to emergent surgical treatment of AEF and can quickly identify the bleeding site and achieve hemostasis through stent implantation[5]; and (3) Surgical repair is the typical treatment approach and was considered the only definitive treatment for foreign body-related AEF before the emergence of endovascular treatment, with in-hospital mortality and reintervention rate of nearly 40% and 50%, respectively[6,7]. A left thoracotomy followed by aortic replacement with a prosthetic/cryopreserved homograft is the typical approach for open AEF repair[7]. The popularization of endovascular therapy has provided more treatment options for AEF. A study[8] have attempted to close aortic ruptures during the acute phase using endovascular therapy, especially for patients with significant upper gastrointestinal bleeding in



**Figure 5 Esophageal view during Esophagogastroduodenoscopy.** A: Both ends of the fishbone inserted into the esophageal wall, 28 cm from the incisors; B: The endoscopically removed fishbone; C: Active blood spurring was noted in the esophageal defect after removal of the fishbone; D: Two longitudinal ulcers were present.



**Figure 6 Postoperative computed tomography angiography of case 2 shows a well-positioned aortic stent graft and no contrast extravasation from the aorta.**

poor general condition who are not suitable for open surgery. In a systematic review, endovascular treatment for AEF offered encouraging perioperative outcomes, with an acceptable 30-d mortality rate (19.4%) [9]. However, when fistulas are present in the aorta and esophagus and are markedly contaminated, the use of endovascular stent grafts to close the contaminated fistula can lead to long-term artificial stent infection and a remarkable increase in the area of the aorta that needs to be resected. Currently, there are two main areas of controversy. First, it is questionable whether thoracic operations can be completely replaced by endovascular therapy. Second, if endovascular therapy cannot be fully substituted for thoracic surgery, it is unclear when further thoracic surgery should be performed.



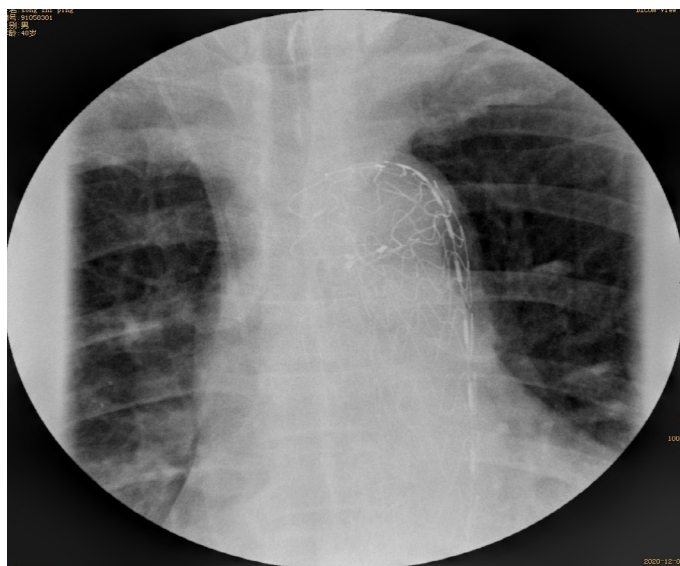


Figure 7 Esophageal imaging with meglumine diatrizoate demonstrates no leakage.

In this paper, we compiled the reports of esophageal foreign bodies complicated with AEF or other aortic injuries in recent years, all of which involve endovascular stent treatment[10-17] (Table 1). These experiences indicate that endovascular stent treatment seems to be gaining popularity as a preferred method for AEF, and the severity of infection throughout the course of the disease is directly related to the prognosis of the patient. With regard to the management of esophageal fistula, we consider that the healing of the esophageal fistula could be assessed through esophageal imaging with meglumine diatrizoate and EGD a few days after removal of the foreign body and that the esophagus could be repaired by a viable pedicle flap of the omentum or a pedicled intercostal muscle flap or even through reconstitution of the gastrointestinal tract if a fistula exists[11,12,15]. More notably, Mezzetto *et al*[14] reported that the presence of a low-flow esophageal fistula could be endoscopically closed by long clips after removal of the foreign body. With regard to surgical management, thoracic surgery may not be necessary if the mediastinal infection gradually improves or if no obvious signs of infection are observed for several days after the operation, as reported by Mezzetto *et al*[14] and Zeng *et al*[17]. In the presence of obvious signs of infection and chest imaging suggestive of aortic pseudoaneurysm, most experts decided to perform immediate thoracic surgery after endovascular treatment for adequate mediastinal debridement, irrigation and drainage[10,11,13,15]. However, Kelly *et al*[12] reported successful treatment of a patient who had evidence of sepsis, high fever and hypotension with a stent that became infected 51 d after a single insertion of an endovascular stent graft; the patient later underwent definitive open surgical repair in which the stent was removed, the aorta was replaced with a homograft and covered with a left trapezius flap under deep hypothermic arrest, and the gastrointestinal tract was reconstituted. Conversely, in the case of an infected endovascular aorta stent for which no further surgery was performed due to the presence of comorbid conditions, the patient ultimately died, as reported by Rawala *et al*[16].

Our two cases were unique in that they involved the process of improving clinical competence. AEF is a life-threatening complication, and discharge to a peripheral hospital should be avoided. Based on the presence of such clinical complications, angio-computed tomography should be performed in all cases of foreign body removal, even if the patient is clinically asymptomatic. In the first case, 1 d after removal of the esophageal foreign body, the patient suddenly suffered from hematemesis and other conditions, which were suggested to be caused by aortoclasia. The patient was in critical condition and could have died at any time. We performed timely and effective thoracic aorta stent-graft placement and closed the aortic fistula to achieve hemostasis. Based on our experience with the first case, a combined plan was drafted for endoscopic removal of the fishbone with simultaneous closure of the aortic defect using minimally invasive endovascular treatment in the second case. The patient's hemoglobin was within normal limits, without hematemesis or melena. The order of events involving endoscopic fishbone removal and endovascular stent placement is another concern; a prematurely placed stent could be damaged by the foreign body impaling the aortic wall from the esophagus. We ensured persistent jejunal nutrient and an anti-infectious state (especially against gram-positive bacteria) after conducting sufficient multidisciplinary discussions. Because there were no clinical signs of infection in either patient, we did not perform thoracic surgery at a later stage. It is unprecedented that 2 continuous patients did not develop mediastinal infection and gradually resumed a normal diet. Because the esophageal fistulas were small, the esophagus was allowed to heal naturally. Thus, we did not place sutures through thoracic surgery. Conversely, patients with AEF and clinical signs of infection who are

**Table 1 Cases involving endovascular treatment of aorto-esophageal fistula or other aortic injury secondary to foreign body**

No.	Sex	Age	Foreign body	Signs of infection	Aortal injury	Esophagoscopy	Surgical Management	The time interval between endovascular treatment and thoracic operations	Prognosis
Case 1	Male	22 yr	Chicken bone	WBC count of $19.96 \times 10^9/L$	CTA demonstrated a mediastinal esophageal fistula with an aortic pseudoaneurysm at the descending aorta	Esophageal stent-graft was implanted to isolate the esophageal perforation followed by the placement of a three-lumen gastro-jejunal tube	Two F16 silicone tubes were placed in the pleural cavity and the mediastinum to facilitate postoperative drainage after mediastinal debridement and irrigation using the thoracoscope.	Immediately	Successful salvage
Case 2	Male	32 yr	Fishbone	No abnormalities	CTA demonstrated an AEF	Emergency gastroscopy could not identify a bleeding focus due to massive amounts of clot and fresh blood	The esophagus was primarily repaired and reinforced by a pedicled intercostal muscle flap to cover the exposed stent-graft through a right thoracotomy	Immediately	Successful salvage
Case 3	Male	59 yr	Fishbone	Evidence of sepsis with a high fever and hypotension	CTA demonstrated an AEF	There was some active bleeding after the fishbone was removed by gastroscopy	The stent became infected and definitive open surgical repair involved removing the stent, replacing the aorta with a homograft and coverage with a left trapezius flap while under deep hypothermic arrest, and reconstitution of the gastrointestinal tract	53 d	Successful salvage
Case 4	Male	25 yr	Fishbone	WBC count of $15.7 \times 10^9/L$	CTA demonstrated a large aortic pseudoaneurysm was seen on the descending aorta but not a punctured aorta	Not done	Two drainage tubes were placed in the left thoracic cavity and the mediastinum after the pseudoaneurysm was opened and mediastinal debridement and irrigation were performed by exploratory thoracotomy	Immediately	Successful salvage
Case 5	Male	79 yr	Goat bone	WBC count of $12.4 \times 10^9/L$ with a high fever	CTA demonstrated the presence of a focal irregularity of the aortic medial profile at the level of the thoracic aorta, suspected for an adventitial tear	The bone fragment was endoscopically removed and an endoscopic closure of the esophageal laceration by means of 2 long clips was performed.	Not done	Not done	Successful salvage
Case 6	Male	40 yr	Chicken bone	WBC count of $10.9 \times 10^9/L$	CTA demonstrated an AEF and a large saccular pseudoaneurysm at the aortic isthmus, accompanied by mediastinal hematoma and bilateral pleural effusion	Esophagoscopy showed fresh and clotted blood coming from two irregular mural ulcers in the upper and middle thirds of the esophagus	After careful debridement, the dead space between the aorta and esophagus was filled with a viable pedicle flap of the omentum by an exploratory left thoracotomy. Two chest tubes were placed for mediastinal irrigation and	Immediately	Successful salvage

							drainage		
Case 7	Female	80 yr	Not mentioned	Elevated WBC count and MRSA-positive blood cultures	CT demonstrated a thoracic aorta aneurysm and an AEF	A mass was compressing the distal third of the esophagus, and an ulcer was present. An esophageal stent was placed to cover the whole esophagus	Not done	Not done	Died 3 months after the thoracic aorta stent was placed
Case 8	Male	58 yr	Duck bone	Not mentioned	CTA confirmed a descending intramural hematoma	The duck bone was removed gently using an endoscope	Not done	Not done	Successful salvage

WBC: White blood cell; AEF: Aortoesophageal fistula; CTA: Computed tomography angiography; CT: Computed tomography; MRSA: Methicillin-resistant staphylococcus aureus.

in good physical condition and considered low risk for open surgery should be considered for thoracic surgery.

## CONCLUSION

Based on our limited experience with these two cases, we suggest that the management options for AEF patients should depend on the severity of the mediastinal infection, recovery from the esophageal fistula, extent of aortic injury, and the patients' general condition. Our cases indicate that endovascular stent-graft treatment without combined thoracic operations could be a valuable alternative in selected patients.

## FOOTNOTES

**Author contributions:** Gong H and Wei W conceived of the study, designed it, and acquired the data; Gong H participated in the design of the study, coordination, and analysis of the data; Gong H and Wei W drafted the manuscript; Huang Z, Hu Y, Liu XL and Hu Z participated in the manuscript preparation and critical revision; all authors read and approved the manuscript.

**Informed consent statement:** Consent was obtained from the patients for publication of this report and any accompanying images.

**Conflict-of-interest statement:** The authors declare that they have no competing interests.

**CARE Checklist (2016) statement:** The authors have read the CARE Checklist (2016), and the manuscript was prepared and revised according to the CARE Checklist (2016).

**Open-Access:** This article is an open-access article that was selected by an in-house editor and fully peer-reviewed by external reviewers. It is distributed in accordance with the Creative Commons Attribution NonCommercial (CC BY-NC 4.0) license, which permits others to distribute, remix, adapt, build upon this work non-commercially, and license their derivative works on different terms, provided the original work is properly cited and the use is non-commercial. See: <https://creativecommons.org/licenses/by-nc/4.0/>

**Country/Territory of origin:** China

**ORCID number:** Hang Gong 0000-0001-5985-1254; Wei Wei 0000-0002-1377-4369; Zhong Huang 0000-0001-8100-959X; Ying Hu 0000-0002-0555-0541; Xian-Li Liu 0000-0003-4363-8488; Zhen Hu 0000-0001-6436-9497.

**S-Editor:** Liu JH

**L-Editor:** A

**P-Editor:** Liu JH

## REFERENCES

- 1 Tao K, Cheng H, Hu Z, Kong M. An aorto-oesophageal fistula treated with endovascular aortic repair: the fate of untreated

- oesophageal lesion on endoscopic follow-up. *Interact Cardiovasc Thorac Surg* 2017; **25**: 990-992 [PMID: [29049528](#) DOI: [10.1093/icvts/ivx167](#)]
- 2 **Beuran M**, Negoï I, Negoï RI, Hostiuc S, Paun S. Primary Aortoduodenal Fistula: First you Should Suspect it. *Braz J Cardiovasc Surg* 2016; **31**: 261-263 [PMID: [27737411](#) DOI: [10.5935/1678-9741.20160049](#)]
  - 3 **Dolega-Kozierowski B**, Sokratous K, Dyś K, Lis M, Ferenc S, Drelichowski S, Witkiewicz W. Aortoesophageal fistula as a complication of thoracic aorta aneurism stent grafting - a case report and literature review. *Pol J Radiol* 2012; **77**: 77-80 [PMID: [23269943](#) DOI: [10.12659/pjr.883635](#)]
  - 4 **Tao M**, Shlomovitz E, Darling G, Roche-Nagle G. Secondary aorto-esophageal fistula after thoracic aortic aneurysm endovascular repair treated by covered esophageal stenting. *World J Clin Cases* 2016; **4**: 233-237 [PMID: [27574612](#) DOI: [10.12998/wjcc.v4.i8.233](#)]
  - 5 **Okita Y**, Yamanaka K, Okada K, Matsumori M, Inoue T, Fukase K, Sakamoto T, Miyahara S, Shirasaka T, Izawa N, Ohara T, Nomura Y, Nakai H, Gotake Y, Kano H. Strategies for the treatment of aorto-oesophageal fistula. *Eur J Cardiothorac Surg* 2014; **46**: 894-900 [PMID: [24618390](#) DOI: [10.1093/ejcts/ezu094](#)]
  - 6 **Sia KJ**, Ashok GD, Ahmad FM, Kong CK. Aorto-oesophageal fistula and aortic pseudoaneurysm caused by a swallowed fish bone. *Hong Kong Med J* 2013; **19**: 542-544 [PMID: [24310662](#) DOI: [10.12809/hkmj133668](#)]
  - 7 **Kieffer E**, Chiche L, Gomes D. Aortoesophageal fistula: value of in situ aortic allograft replacement. *Ann Surg* 2003; **238**: 283-290 [PMID: [12894023](#) DOI: [10.1097/01.sla.0000080828.37493.e0](#)]
  - 8 **Chiesa R**, Melissano G, Marone EM, Kahlberg A, Marrocco-Trischitta MM, Tshomba Y. Endovascular treatment of aortoesophageal and aortobronchial fistulae. *J Vasc Surg* 2010; **51**: 1195-1202 [PMID: [20304579](#) DOI: [10.1016/j.jvs.2009.10.130](#)]
  - 9 **Canaud L**, Ozdemir BA, Bee WW, Bahia S, Holt P, Thompson M. Thoracic endovascular aortic repair in management of aortoesophageal fistulas. *J Vasc Surg* 2014; **59**: 248-254 [PMID: [24199764](#) DOI: [10.1016/j.jvs.2013.07.117](#)]
  - 10 **Chen X**, Li J, Chen J, Zhou Y, Zhang Y, Ding H, Huang S, Zhang Z. A combined minimally invasive approach for the treatment of aortoesophageal fistula caused by the ingestion of a chicken bone: case report and literature review. *Clinics (Sao Paulo)* 2012; **67**: 195-197 [PMID: [22358249](#) DOI: [10.6061/clinics/2012\(02\)19](#)]
  - 11 **Assink J**, Vierhout BP, Snellen JP, Benner PM, Paul MA, Cuesta MA, Wisselink W. Emergency endovascular repair of an aortoesophageal fistula caused by a foreign body. *J Endovasc Ther* 2005; **12**: 129-133 [PMID: [15683264](#) DOI: [10.1583/04-1401R.1](#)]
  - 12 **Kelly SL**, Peters P, Ogg MJ, Li A, Smithers BM. Successful management of an aortoesophageal fistula caused by a fish bone--case report and review of literature. *J Cardiothorac Surg* 2009; **4**: 21 [PMID: [19422725](#) DOI: [10.1186/1749-8090-4-21](#)]
  - 13 **Xi EP**, Zhu J, Zhu SB, Liu Y, Yin GL, Zhang Y, Zhang XM, Dong YQ. Surgical treatment of aortoesophageal fistula induced by a foreign body in the esophagus: 40 years of experience at a single hospital. *Surg Endosc* 2013; **27**: 3412-3416 [PMID: [23529574](#) DOI: [10.1007/s00464-013-2926-3](#)]
  - 14 **Mezzetto L**, Treppiedi E, Scorsone L, Giacomuzzi S, Perandini S, Macri M, Veraldi GF. Thoracic Aortic Pseudoaneurysm after Esophageal Perforation and Mediastinitis Caused by Accidental Ingestion of a Mutton Bone: A Case Report on Staged Endoscopic and Endovascular Treatments. *Ann Vasc Surg* 2016; **30**: 307.e15-307.e19 [PMID: [26520422](#) DOI: [10.1016/j.avsg.2015.07.025](#)]
  - 15 **Shen JY**, Zhang HW, Fan KJ, Liao H, Zhang EY, Hu J. Aortoesophageal fistula and arch pseudoaneurysm after removing of a swallowed chicken bone: a case report of one-stage hybrid treatment. *BMC Surg* 2018; **18**: 3 [PMID: [29325526](#) DOI: [10.1186/s12893-018-0335-1](#)]
  - 16 **Rawala MS**, Badami V, Rizvi SB, Nanjundappa A. Aortoesophageal Fistula: A Fatal Complication of Thoracic Endovascular Aortic Stent-Graft Placement. *Am J Case Rep* 2018; **19**: 1258-1261 [PMID: [30348937](#) DOI: [10.12659/AJCR.911441](#)]
  - 17 **Zeng L**, Shu W, Ma H, Hu J. Aortic injury caused by esophageal foreign body-case reports of 3 patients and literature review. *Medicine (Baltimore)* 2020; **99**: e20849 [PMID: [32590781](#) DOI: [10.1097/MD.00000000000020849](#)]





Published by **Baishideng Publishing Group Inc**  
7041 Koll Center Parkway, Suite 160, Pleasanton, CA 94566, USA

**Telephone:** +1-925-3991568

**E-mail:** [bpgoffice@wjgnet.com](mailto:bpgoffice@wjgnet.com)

**Help Desk:** <https://www.f6publishing.com/helpdesk>

<https://www.wjgnet.com>

