


World Journal of *Clinical Cases*

World J Clin Cases 2022 March 6; 10(7): 2053-2361



Contents

Thrice Monthly Volume 10 Number 7 March 6, 2022

FIELD OF VISION

- 2053** Personalized treatment - which interaction ingredients should be focused to capture the unconscious
Steinmair D, Löffler-Stastka H

MINIREVIEWS

- 2063** Patterns of liver profile disturbance in patients with COVID-19
Shousha HI, Ramadan A, Lithy R, El-Kassas M

ORIGINAL ARTICLE

Clinical and Translational Research

- 2072** Prognostic and biological role of the N-Myc downstream-regulated gene family in hepatocellular carcinoma
Yin X, Yu H, He XK, Yan SX

Case Control Study

- 2087** Usefulness of the acromioclavicular joint cross-sectional area as a diagnostic image parameter of acromioclavicular osteoarthritis
Joo Y, Moon JY, Han JY, Bang YS, Kang KN, Lim YS, Choi YS, Kim YU
- 2095** Correlation between betatrophin/angiogenin-likeprotein3/lipoprotein lipase pathway and severity of coronary artery disease in Kazakh patients with coronary heart disease
Qin L, Rehemuding R, Ainiwaer A, Ma X

Retrospective Study

- 2106** Postoperative adverse cardiac events in acute myocardial infarction with high thrombus load and best time for stent implantation
Zhuo MF, Zhang KL, Shen XB, Lin WC, Hu B, Cai HP, Huang G
- 2115** Develop a nomogram to predict overall survival of patients with borderline ovarian tumors
Gong XQ, Zhang Y

Clinical Trials Study

- 2127** Diagnostic performance of Neutrophil CD64 index, procalcitonin, and C-reactive protein for early sepsis in hematological patients
Shang YX, Zheng Z, Wang M, Guo HX, Chen YJ, Wu Y, Li X, Li Q, Cui JY, Ren XX, Wang LR
- 2138** Previously unexplored etiology for femoral head necrosis: Metagenomics detects no pathogens in necrotic femoral head tissue
Liu C, Li W, Zhang C, Pang F, Wang DW

Observational Study

- 2147** Association of types of diabetes and insulin dependency on birth outcomes
Xaverius PK, Howard SW, Kiel D, Thurman JE, Wankum E, Carter C, Fang C, Carriere R
- 2159** Pathological pattern of endometrial abnormalities in postmenopausal women with bleeding or thickened endometrium
Xue H, Shen WJ, Zhang Y
- 2166** *In vitro* maturation of human oocytes maintaining good development potential for rescue intracytoplasmic sperm injection with fresh sperm
Dong YQ, Chen CQ, Huang YQ, Liu D, Zhang XQ, Liu FH
- 2174** Ultrasound-guided paravertebral nerve block anesthesia on the stress response and hemodynamics among lung cancer patients
Zhen SQ, Jin M, Chen YX, Li JH, Wang H, Chen HX

META-ANALYSIS

- 2184** Prognostic value of YKL-40 in colorectal carcinoma patients: A meta-analysis
Wang J, Qi S, Zhu YB, Ding L
- 2194** Prognostic value of neutrophil/lymphocyte, platelet/lymphocyte, lymphocyte/monocyte ratios and Glasgow prognostic score in osteosarcoma: A meta-analysis
Peng LP, Li J, Li XF

CASE REPORT

- 2206** Endovascular stent-graft treatment for aorto-esophageal fistula induced by an esophageal fishbone: Two cases report
Gong H, Wei W, Huang Z, Hu Y, Liu XL, Hu Z
- 2216** Quetiapine-related acute lung injury: A case report
Huang YX, He GX, Zhang WJ, Li BW, Weng HX, Luo WC
- 2222** Primary hepatic neuroendocrine neoplasm diagnosed by somatostatin receptor scintigraphy: A case report
Akane M, Kobayashi Y, Kinowaki K, Okubo S, Shindoh J, Hashimoto M
- 2229** Multidisciplinary non-surgical treatment of advanced periodontitis: A case report
Li LJ, Yan X, Yu Q, Yan FH, Tan BC
- 2247** Flip-over of blood vessel intima caused by vascular closure device: A case report
Sun LX, Yang XS, Zhang DW, Zhao B, Li LL, Zhang Q, Hao QZ
- 2253** Huge gastric plexiform fibromyxoma presenting as pyemia by rupture of tumor: A case report
Zhang R, Xia LG, Huang KB, Chen ND
- 2261** Intestinal intussusception caused by intestinal duplication and ectopic pancreas: A case report and review of literature
Wang TL, Gong XS, Wang J, Long CY

- 2268** Mixed neuroendocrine-nonneuroendocrine neoplasm of the ampulla: Four case reports
Wang Y, Zhang Z, Wang C, Xi SH, Wang XM
- 2275** Y-shaped shunt for the treatment of Dandy-Walker malformation combined with giant arachnoid cysts: A case report
Dong ZQ, Jia YF, Gao ZS, Li Q, Niu L, Yang Q, Pan YW, Li Q
- 2281** Posterior reversible encephalopathy syndrome in a patient with metastatic breast cancer: A case report
Song CH, Lee SJ, Jeon HR
- 2286** Multiple skin abscesses associated with bacteremia caused by *Burkholderia gladioli*: A case report
Wang YT, Li XW, Xu PY, Yang C, Xu JC
- 2294** Giant infected hepatic cyst causing exclusion pancreatitis: A case report
Kenzaka T, Sato Y, Nishisaki H
- 2301** Cutaneous leishmaniasis presenting with painless ulcer on the right forearm: A case report
Zhuang L, Su J, Tu P
- 2307** Gastrointestinal amyloidosis in a patient with smoldering multiple myeloma: A case report
Liu AL, Ding XL, Liu H, Zhao WJ, Jing X, Zhou X, Mao T, Tian ZB, Wu J
- 2315** Breast and dorsal spine relapse of granulocytic sarcoma after allogeneic stem cell transplantation for acute myelomonocytic leukemia: A case report
Li Y, Xie YD, He SJ, Hu JM, Li ZS, Qu SH
- 2322** Synchronous but separate neuroendocrine tumor and high-grade dysplasia/adenoma of the gall bladder: A case report
Hsiao TH, Wu CC, Tseng HH, Chen JH
- 2330** Novel mutations of the Alström syndrome 1 gene in an infant with dilated cardiomyopathy: A case report
Jiang P, Xiao L, Guo Y, Hu R, Zhang BY, He Y
- 2336** Acute esophageal obstruction after ingestion of psyllium seed husk powder: A case report
Shin S, Kim JH, Mun YH, Chung HS
- 2341** Spontaneous dissection of proximal left main coronary artery in a healthy adolescent presenting with syncope: A case report
Liu SF, Zhao YN, Jia CW, Ma TY, Cai SD, Gao F
- 2351** Relationship between treatment types and blood-brain barrier disruption in patients with acute ischemic stroke: Two case reports
Seo Y, Kim J, Chang MC, Huh H, Lee EH
- 2357** Ultrasound-guided rectus sheath block for anterior cutaneous nerve entrapment syndrome after laparoscopic surgery: A case report
Sawada R, Watanabe K, Tokumine J, Lefor AK, Ando T, Yoroze T

ABOUT COVER

Editorial Board Member of *World Journal of Clinical Cases*, Feng Yin, MD, PhD, Assistant Professor, Department of Pathology and Anatomic Sciences, University of Missouri, Columbia, MO 65212, United States.
fengyin@health.missouri.edu

AIMS AND SCOPE

The primary aim of *World Journal of Clinical Cases* (WJCC, *World J Clin Cases*) is to provide scholars and readers from various fields of clinical medicine with a platform to publish high-quality clinical research articles and communicate their research findings online.

WJCC mainly publishes articles reporting research results and findings obtained in the field of clinical medicine and covering a wide range of topics, including case control studies, retrospective cohort studies, retrospective studies, clinical trials studies, observational studies, prospective studies, randomized controlled trials, randomized clinical trials, systematic reviews, meta-analysis, and case reports.

INDEXING/ABSTRACTING

The WJCC is now indexed in Science Citation Index Expanded (also known as SciSearch®), Journal Citation Reports/Science Edition, Scopus, PubMed, and PubMed Central. The 2021 Edition of Journal Citation Reports® cites the 2020 impact factor (IF) for WJCC as 1.337; IF without journal self cites: 1.301; 5-year IF: 1.742; Journal Citation Indicator: 0.33; Ranking: 119 among 169 journals in medicine, general and internal; and Quartile category: Q3. The WJCC's CiteScore for 2020 is 0.8 and Scopus CiteScore rank 2020: General Medicine is 493/793.

RESPONSIBLE EDITORS FOR THIS ISSUE

Production Editor: Lin-YuTong Wang; Production Department Director: Xiang Li; Editorial Office Director: Jin-Lai Wang.

NAME OF JOURNAL

World Journal of Clinical Cases

ISSN

ISSN 2307-8960 (online)

LAUNCH DATE

April 16, 2013

FREQUENCY

Thrice Monthly

EDITORS-IN-CHIEF

Bao-Gan Peng, Jerzy Tadeusz Chudek, George Kontogeorgos, Maurizio Serati, Ja Hyeon Ku

EDITORIAL BOARD MEMBERS

<https://www.wjgnet.com/2307-8960/editorialboard.htm>

PUBLICATION DATE

March 6, 2022

COPYRIGHT

© 2022 Baishideng Publishing Group Inc

INSTRUCTIONS TO AUTHORS

<https://www.wjgnet.com/bpg/gerinfo/204>

GUIDELINES FOR ETHICS DOCUMENTS

<https://www.wjgnet.com/bpg/GerInfo/287>

GUIDELINES FOR NON-NATIVE SPEAKERS OF ENGLISH

<https://www.wjgnet.com/bpg/gerinfo/240>

PUBLICATION ETHICS

<https://www.wjgnet.com/bpg/GerInfo/288>

PUBLICATION MISCONDUCT

<https://www.wjgnet.com/bpg/gerinfo/208>

ARTICLE PROCESSING CHARGE

<https://www.wjgnet.com/bpg/gerinfo/242>

STEPS FOR SUBMITTING MANUSCRIPTS

<https://www.wjgnet.com/bpg/GerInfo/239>

ONLINE SUBMISSION

<https://www.f6publishing.com>



Y-shaped shunt for the treatment of Dandy-Walker malformation combined with giant arachnoid cysts: A case report

Zhi-Qiang Dong, Yan-Fei Jia, Zhen-Shan Gao, Qiao Li, Liang Niu, Qiang Yang, Ya-Wen Pan, Qiang Li

Specialty type: Clinical neurology

Provenance and peer review:

Unsolicited article; Externally peer reviewed.

Peer-review model: Single blind

Peer-review report's scientific quality classification

Grade A (Excellent): 0

Grade B (Very good): B

Grade C (Good): C, C, C, C

Grade D (Fair): D

Grade E (Poor): 0

P-Reviewer: Dhali A, Elpek GO, Naswhan AJ, Teragawa H

Received: July 21, 2021

Peer-review started: July 21, 2021

First decision: September 1, 2021

Revised: September 25, 2021

Accepted: January 25, 2022

Article in press: January 25, 2022

Published online: March 6, 2022



Zhi-Qiang Dong, Yan-Fei Jia, Zhen-Shan Gao, Qiao Li, Liang Niu, Qiang Yang, Ya-Wen Pan, Qiang Li, Department of Neurosurgery, The Second Hospital of Lanzhou University, Lanzhou 730030, Gansu Province, China

Zhi-Qiang Dong, Ya-Wen Pan, Qiang Li, Institute of Neurology, The Second Hospital of Lanzhou University, Lanzhou 730030, Gansu Province, China

Corresponding author: Qiang Li, MD, Doctor, Department of Neurosurgery, The Second Hospital of Lanzhou University, No. 82 Cuiyingmen, Chengguan District, Lanzhou 730030, Gansu Province, China. strong908@163.com

Abstract

BACKGROUND

Dandy-Walker malformation (DWM) was first reported in 1914. In this case report, a pediatric case was complicated with giant and isolated arachnoid cysts in the right cerebellar hemisphere along with the typical DWM.

CASE SUMMARY

The patient was at 20 mo old boy, with the complaint of staggering for more than 2 mo. He was admitted to the hospital due to high intracranial pressure and staggering. At admission, the patient had typical manifestations of high intracranial pressure, including vomiting, poor appetite and feeding difficulty. Physical examination revealed increased head circumference, closed anterior fontanelle, unstable standing, staggering, leaning right while walking and ataxia. After admission, he was diagnosed with DWM accompanied by giant isolated arachnoid cysts in the posterior fossa. He underwent Y-shaped three-way valve repair for treating differential pressure between the supratentorial hydrocephalus and the subtentorial arachnoid cysts at once. The child recovered well after the surgery.

CONCLUSION

In this case, supratentorial and subtentorial shunts were placed, which solved the problem of differential pressure between the supratentorial and subtentorial parts simultaneously. This provides useful information regarding treatment exploration in this rare disease.

Key Words: Arachnoid cyst; Cysto-peritoneal shunt; Dandy-Walker malformation; Ventriculoperitoneal shunt; Case report

Core Tip: Dandy-Walker malformation (DWM) is a rare congenital malformation characterized by partial or complete dysplasia of the cerebellar vermis, cystic dilation of the four ventricles, upward displacement of the tentorium, increased anteroposterior diameter of the posterior fossa, and connection between the posterior fossa cysts with the four ventricles in most cases. DWM with giant isolated arachnoid cysts in the posterior fossa was treated with a combination of supratentorial and subtentorial cyst shunts safely and effectively.

Citation: Dong ZQ, Jia YF, Gao ZS, Li Q, Niu L, Yang Q, Pan YW, Li Q. Y-shaped shunt for the treatment of Dandy-Walker malformation combined with giant arachnoid cysts: A case report. *World J Clin Cases* 2022; 10(7): 2275-2280

URL: <https://www.wjgnet.com/2307-8960/full/v10/i7/2275.htm>

DOI: <https://dx.doi.org/10.12998/wjcc.v10.i7.2275>

INTRODUCTION

Dandy-Walker malformation (DWM) was first reported by Dandy and Blackfan[1] in 1914. It is a rare congenital malformation characterized by partial or complete dysplasia of the cerebellar vermis, cystic dilation of the four ventricles, upward displacement of the tentorium, increased anteroposterior diameter of the posterior fossa, and connection between the posterior fossa cysts with the four ventricles in most cases[2]. According to the latest epidemiological survey in Europe, the incidence rates of DWM are 6.79/100000 and 2.74/100000 in infants and live births, respectively[3]. The diagnosis of DWM mainly relies on imaging. The magnetic resonance imaging (MRI) manifestations of DWM are: (1) Presence of giant arachnoid cysts in the posterior fossa that communicate with the fourth ventricle, with elevated tentorium cerebelli and torcular herophili due to pressure; (2) Developmental abnormality or deficiency of cerebellar vermis, which might be accompanied by cerebellar hemisphere dysplasia and forward displacement of the brain stem due to pressure; (3) Significant dilation of the three ventricles and the lateral ventricles, as well as hypoplasia of the corpus callosum; and (4) Hydrocephalus in about 70%-90% of patients[4]. Differential diagnosis included: (1) Giant arachnoid cysts in the posterior fossa, which manifest as cysts of cerebrospinal fluid density, but are not connected with the fourth ventricle. The cysts might be separated by trabeculae, and the fourth ventricle remained normal. The cerebellar vermis appeared normal, but was shifted; and (2) Enlarged cisterna magna, in which cysts are present in different sizes, normally ranging from 2-6 cm. The cerebellar vermis, cerebellar hemisphere and the fourth ventricle appeared normal, with no occupying effect, no hydrocephalus, and normal size of the posterior fossa. In this case report, typical characteristics of DWM were found, and were accompanied by giant and isolated arachnoid cysts in the posterior fossa, warranting different preoperative evaluation and intraoperative treatment.

CASE PRESENTATION

Chief complaints

Family members complained that the child could not walk steadily for 2 mo.

History of present illness

The family members reported that the child was admitted to a local hospital due to fever, diarrhea and vomiting 2 mo ago, and was diagnosed with a cold. He was administered intramuscular injections of antibiotics for 5 d (specific drugs unknown), and showed improvement in his condition. However, staggering occurred again, and the boy was unable to sit or stand. The family members brought him to our hospital for further care, and the patient was admitted in the inpatient department of our Pediatric Neurology Department.

Physical examination

Physical examination at the time of admission revealed increased head circumference (52 cm), closed anterior fontanelle, unstable standing, staggering, and ataxic gait.

Laboratory examinations

Blood routine examination showed that leukocyte elevation. Urine routine, fecal routine and occult blood examination, blood biochemistry, immune indexes and infection indexes were normal.

Imaging examinations

Brain computed tomography (CT) and MRI revealed significantly dilated supratentorial ventricles, capped edema at bilateral frontal angles, huge occupying cysts in the right cerebellar hemisphere, and compression displacement in the right cerebellar hemisphere and the four ventricles (Figure 1).

The patient was a 20 mo old boy, initial diagnosis revealed DWM with giant isolated arachnoid cysts in the posterior fossa. After admission, the patient underwent stereotaxic aspiration for arachnoid cysts in the posterior fossa, confirming that the cystic fluid was cerebrospinal fluid and excluding malignant lesions. After stereotaxic aspiration, the cysts were significantly shrunk, but the supratentorial hydrocephalus showed no improvement. It was speculated that aqueduct obstruction due to adhesion rather than compression would result in occlusion between the supratentorial and subtentorial parts; meanwhile, unobstructed aqueduct and blocked fourth ventricle outlet would result in obstructive hydrocephalus between the supratentorial and subarachnoid spaces. Neither a cysto-peritoneal shunt (C-P shunt) nor a ventriculoperitoneal shunt (V-P shunt) alone solved the hydrocephalus at the same time, and the patient underwent a combination of supratentorial-infratentorial shunt placement for the hydrocephalus and isolated cysts. Preoperative cystic fluid analysis confirmed that the cystic fluid was clear, and the typical arachnoid cysts included proteins at 0.32 (reference: 0.24-0.44 g/L), glucose at 2.9 (reference: 2.4-4.4 mmol/L), and chlorine at 116.1 (reference: 119.0-129.0 mmol/L). They were colorless and transparent, with negative Pandy's test and white blood cell at 4.0 (reference: $0.00-8.00 \times 10^6/L$).

For the surgical procedure, the occipital puncture point was located 5 cm above the external occipital protuberance and 2.5 cm lateral to the midline. A U-shaped incision was made on the scalp (Figure 2A and C). Then, a bone hole of 3-mm diameter was made using a bone drill, which was 10 cm in depth and directed 2 cm above the midpoint of the ipsilateral superciliary arch. Afterwards, a longitudinal incision was made at the posterosuperior part of the ear, and a supratentorial adjustable pump (Medtronic, Strata® II Shunt Assembly, Regular, with BioGlide®; pressure, 80 cmH₂O) was placed behind the ear, connected to a three-way valve (Medtronic Catheter Connector, 3-Way) (Figure 2D). A subtentorial puncture was performed at 5 cm lateral to the midline and 2 cm below the transverse sinus. A U-shaped incision was made on the scalp (Figure 2A and C), and a 3-mm diameter bone hole was made using a bone drill, which was 3 cm in depth and directed to the vertical bone plate. A drainage tube was connected to the ordinary non-adjustable pump (Medtronic, Delta® shunt Kit, Regular, Performance Level 1.5), and further connected to the three-way valve. The other end of the three-way valve was connected to the end of the abdominal cavity, as in general shunt therapy (Figure 2B).

After the surgery, the child had no significant complications, and showed improvement with regarding to the symptoms of staggering and high intracranial pressure. On the third day after operation, he could walk independently. Postoperative CT showed significant improvement of supratentorial hydrocephalus and shrunk cysts in the posterior fossa, and the compressed cerebellar hemisphere was restored (Figure 3A). In addition, the incision healed well postoperatively, and the child's mental state was improved significantly (Figure 3B). The child was depressed before operation.

FINAL DIAGNOSIS

Initial diagnosis revealed DWM with giant isolated arachnoid cysts in the posterior fossa.

TREATMENT

The patient underwent a combined shunt for supratentorial hydrocephalus and infratentorial giant solitary arachnoid cysts.

OUTCOME AND FOLLOW-UP

The patient had no complications, such as fever, subdural effusion and hematoma after operation, and recovered well. The patient was followed-up for 2 years, and could walk independently; high intracranial pressure had disappeared and he was feeding normally.

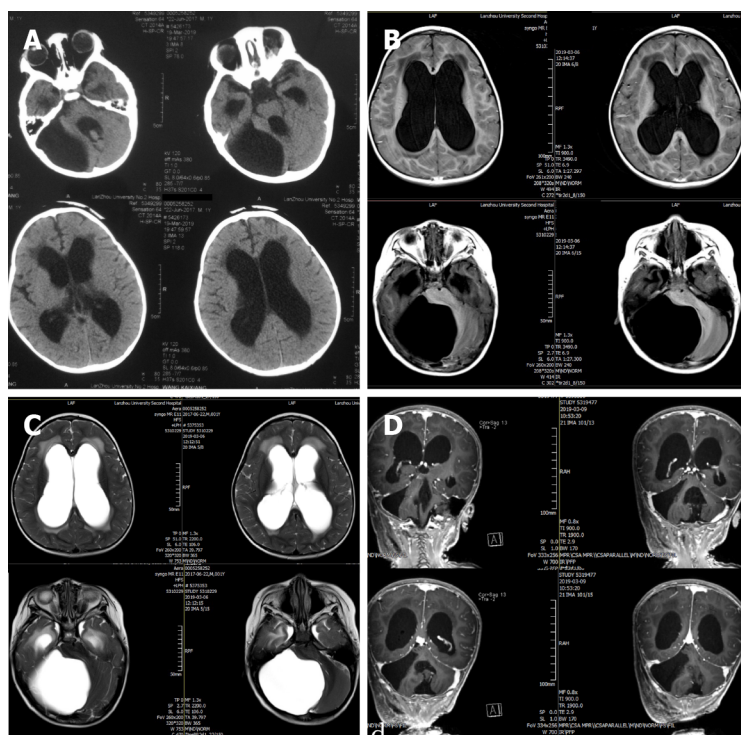


Figure 1 Preoperative imaging examination. A: Preoperative brain computed tomography revealed significantly dilated supratentorial ventricles, capped edema at bilateral frontal angles, huge occupying cysts in the right cerebellar hemisphere, and compression displacement in the right cerebellar hemisphere and the four ventricles; B and C: Preoperative magnetic resonance imaging T1 and T2 scans revealed significantly dilated lateral ventricle, capped edema at bilateral frontal angles, huge occupying cysts in the right cerebellar hemisphere and compression displacement in the right cerebellar hemisphere and the four ventricles; D: The sagittal position of cranial enhanced magnetic resonance also shows the above signs.

DISCUSSION

About 20% of patients with DWM had no clinical symptoms and require no treatment. Experts around the world continue to debate regarding the treatment of patients with DWM and hydrocephalus. Mohanty *et al*[5] retrospectively analyzed the surgical methods utilized in 72 children with DWM. The initial surgical treatments included V-P shunt placement in 21 patients, C-P shunt placement in 24, and combined V-P and C-P shunt insertion in 3. Twenty-one patients underwent endoscopic procedures and 3 cases underwent membrane excision *via* a posterior fossa craniectomy. The authors believed that neuroendoscopy is a good surgical method for DWM. Mohanty *et al*[5] pointed out hernia above posterior fossa cysts as a potential complication of V-P shunting alone, which rapidly deteriorates the clinical symptoms. In addition, C-P shunting alone is associated with a risk of chronic inferior herniation of the cerebral hemisphere through tentorial notch or causes tethering of the brain stem[6-8]. Kumar *et al*[9] compared different treatment methods and outcomes in 42 patients, and proposed V-P shunting should be followed by C-P shunting as posterior fossa cysts did not disappear or the symptoms recurred after V-P shunt placement. Meanwhile, if C-P shunting alone is implemented, this should be followed by V-P shunt placement as well due to continuous dilation of lateral ventricles. Hence, lateral ventricle and cyst shunting was performed to decompress the posterior fossa cysts and lateral ventricle simultaneously, thereby achieving the purpose of clinical cure. Generally, cyst fenestration is suitable for patients without hydrocephalus.

CONCLUSION

The child in the current case report suffered from cerebellar vermis dysplasia, accompanied by giant isolated arachnoid cysts in the posterior fossa, with the arachnoid cysts not connected to the occipital cistern. The supratentorial ventricle was enlarged, and there was an obvious capped edema at the bilateral frontal angle. Regardless of aqueduct obstruction status, the supratentorial or ventriculoperitoneal shunt alone did not solve the problem of arachnoid cysts that compressed the cerebellum as well as the brain stem. After sufficient preoperative evaluation, the patient received a ventriculoperitoneal shunt (adjustable anti-siphonic diverter pump) combined with a arachnoid cyst (medium pressure non-adjustable diverter pump)-peritoneal shunt, during which the Y-shaped three-way valve was finally used to simultaneously solve the problem of different pressures between the supratentorial

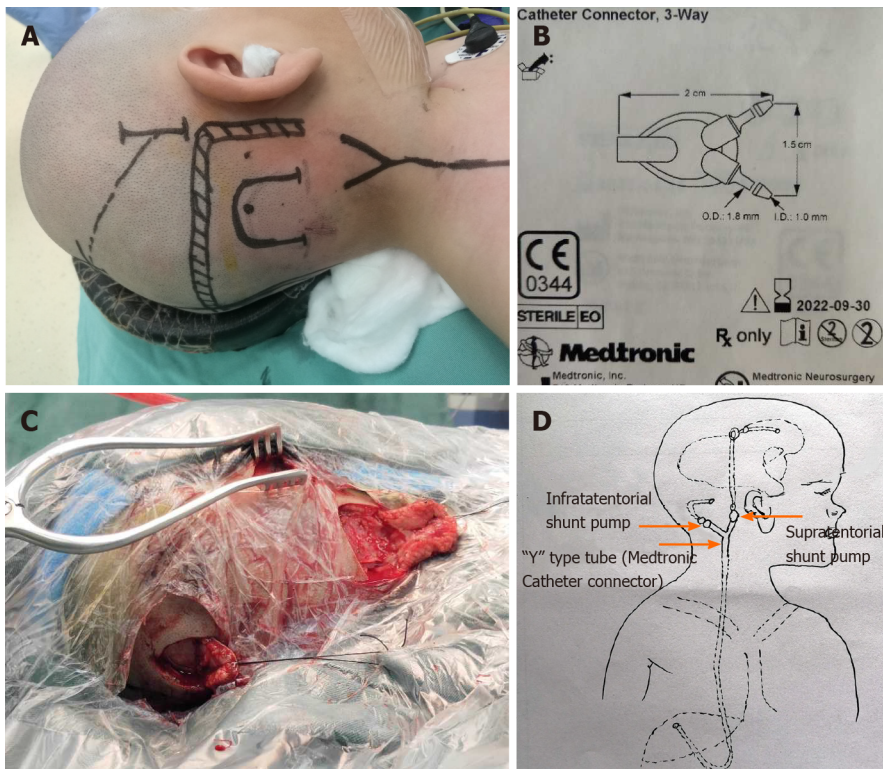


Figure 2 Surgical position, method. A: Patient position and incision design during surgery; B: Medtronic catheter connector; C: Intraoperative incision; D: A supratentorial adjustable pump was placed behind the ear, connected to a three-way valve; a drainage tube for cerebellar hemispheric cysts was connected to the ordinary non-adjustable pump, and then connected to the three-way valve. The other end of the three-way valve was connected to the end of the abdominal cavity, as in general shunt therapy. Citation for Figure 2B: The authors have obtained the permission for figure using from the Medtronic (see [Supplementary material](#)).

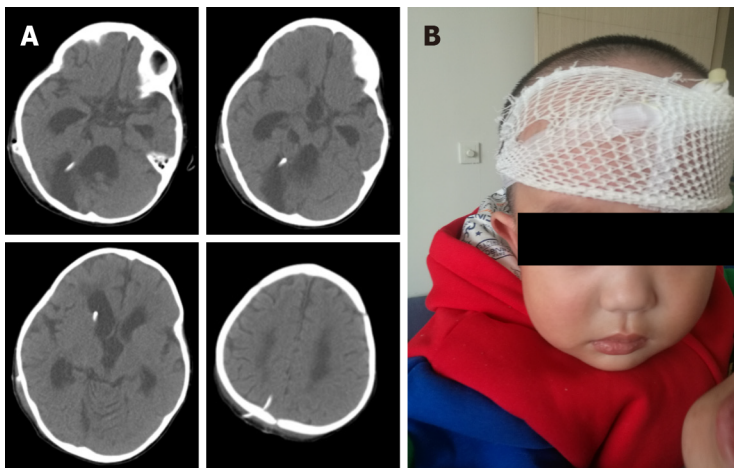


Figure 3 Postoperative imaging examination and child status. A: Postoperative brain computed tomography showing shrunk lateral ventricles and disappeared capped edema at the bilateral frontal angle; the head ends of the drainage tube in the lateral ventricle and posterior fossa cysts were well-positioned; B: Postoperative status of the child: Brain computed tomography at 1 mo postoperatively revealed significantly shrunk lateral ventricle; the head ends of the drainage tube in the lateral ventricle and posterior fossa cysts were well-positioned. The cysts were significantly shrunk and there was cerebellar vermis dysplasia.

hydrocephalus and the subtentorial arachnoid cyst induced by Dandy-Walker malformation. The patient had no complications, such as fever, subdural effusion and hematoma after operation, and recovered well. Therefore, the abovementioned procedure has a positive effect on the prognosis of patient. The patient was followed-up for 2 years, and could walk independently; the high intracranial pressure had disappeared, and the boy was feeding normally. Nonetheless, the efficacy of the surgery is subjected to long-term follow-up. To the best of our knowledge, this is the first case report of DWM with giant isolated arachnoid cysts in the posterior fossa, which was treated with a combination of supratentorial and subtentorial cyst shunts.

FOOTNOTES

Author contributions: Dong ZQ conceived and coordinated the study, designed, performed and analyzed the experiments, and wrote the paper; Jia YF, Gao ZS, Li Q, Niu L, Yang Q, Pan YW and Li Q carried out data collection and analysis, and revised the paper; all authors reviewed the results and approved the final version of the manuscript.

Informed consent statement: Written informed consent was obtained from the patient's guardian.

Conflict-of-interest statement: The authors declare that they have no conflict of interest.

CARE Checklist (2016) statement: The authors have read the CARE Checklist (2016), and the manuscript was prepared and revised according to the CARE Checklist (2016).

Open-Access: This article is an open-access article that was selected by an in-house editor and fully peer-reviewed by external reviewers. It is distributed in accordance with the Creative Commons Attribution NonCommercial (CC BY-NC 4.0) license, which permits others to distribute, remix, adapt, build upon this work non-commercially, and license their derivative works on different terms, provided the original work is properly cited and the use is non-commercial. See: <https://creativecommons.org/licenses/by-nc/4.0/>

Country/Territory of origin: China

ORCID number: Zhi-Qiang Dong 0000-0001-9353-5896; Yan-Fei Jia 0000-0003-0476-9987; Zhen-Shan Gao 0000-0003-0039-9608; Qiao Li 0000-0002-9455-4180; Liang Niu 0000-0002-5266-2909; Qiang Yang 0000-0003-0226-992X; Ya-Wen Pan 0000-0002-2247-8027; Qiang Li 0000-0001-9815-2229.

S-Editor: Yan JP

L-Editor: A

P-Editor: Yan JP

REFERENCES

- 1 **Dandy WE**, Blackfan KD. Internal hydrocephalus: an experimental, clinical and pathological study. *Am J Dis Child* 1914; **8**: 406-482
- 2 **Karande V**, Andrade NN. Dandy-Walker Syndrome with Giant Cell Lesions and Cherubism. *Ann Maxillofac Surg* 2018; **8**: 131-136 [PMID: 29963440 DOI: 10.4103/ams.ams_34_16]
- 3 **Santoro M**, Coi A, Barišić I, Garne E, Addor MC, Bergman JEH, Bianchi F, Boban L, Braz P, Caverro-Carbonell C, Gatt M, Haeusler M, Kinsner-Ovaskainen A, Klungsoyr K, Kurinczuk JJ, Lelong N, Luyt K, Materna-Kiryluk A, Mokoroa O, Mullaney C, Nelen V, Neville AJ, O'Mahony MT, Perthuis I, Randrianaivo H, Rankin J, Rissmann A, Rouget F, Schaub B, Tucker D, Wellesley D, Yevtushok L, Pierini A. Epidemiology of Dandy-Walker Malformation in Europe: A EUROCAT Population-Based Registry Study. *Neuroepidemiology* 2019; **53**: 169-179 [PMID: 31302658 DOI: 10.1159/000501238]
- 4 **Reith W**, Haussmann A. [Dandy-Walker malformation]. *Radiologe* 2018; **58**: 629-635 [PMID: 29797040 DOI: 10.1007/s00117-018-0403-7]
- 5 **Mohanty A**, Biswas A, Satish S, Praharaj SS, Sastry KV. Treatment options for Dandy-Walker malformation. *J Neurosurg* 2006; **105**: 348-356 [PMID: 17328256 DOI: 10.3171/ped.2006.105.5.348]
- 6 **Wang AN**, Carson BS. Upward herniation of the posterior fossa cyst in the shunted child. *Surg Neurol* 1987; **28**: 215-220 [PMID: 3629448 DOI: 10.1016/0090-3019(87)90137-6]
- 7 **Naidich TP**, Radkowski MA, McLone DG, Leestma J. Chronic cerebral herniation in shunted Dandy-Walker malformation. *Radiology* 1986; **158**: 431-434 [PMID: 3941868 DOI: 10.1148/radiology.158.2.3941868]
- 8 **Liu JC**, Ciacci JD, George TM. Brainstem tethering in Dandy-Walker syndrome: a complication of cystoperitoneal shunting. Case report. *J Neurosurg* 1995; **83**: 1072-1074 [PMID: 7490623 DOI: 10.3171/jns.1995.83.6.1072]
- 9 **Kumar R**, Jain MK, Chhabra DK. Dandy-Walker syndrome: different modalities of treatment and outcome in 42 cases. *Childs Nerv Syst* 2001; **17**: 348-352 [PMID: 11417415 DOI: 10.1007/s003810000425]



Published by **Baishideng Publishing Group Inc**
7041 Koll Center Parkway, Suite 160, Pleasanton, CA 94566, USA

Telephone: +1-925-3991568

E-mail: bpgoffice@wjgnet.com

Help Desk: <https://www.f6publishing.com/helpdesk>

<https://www.wjgnet.com>

