

# World Journal of *Clinical Cases*

*World J Clin Cases* 2022 March 26; 10(9): 2660-2975



## Contents

Thrice Monthly Volume 10 Number 9 March 26, 2022

## REVIEW

- 2660 Role of metabolites derived from gut microbiota in inflammatory bowel disease  
*Zheng L, Wen XL, Duan SL*

## MINIREVIEWS

- 2678 Roles of Wnt/ $\beta$ -catenin signaling pathway related microRNAs in esophageal cancer  
*Chu CY, Wang R, Liu XL*
- 2687 Animal models applied to acute-on-chronic liver failure: Are new models required to understand the human condition?  
*Gama JFG, Cardoso LMDF, Lagrota-Candido JM, Alves LA*

## ORIGINAL ARTICLE

## Case Control Study

- 2700 Associations between coagulation factor XII, coagulation factor XI, and stability of venous thromboembolism: A case-control study  
*Meng Y, Li Y, Ye YJ, Ma Q, Zhang JB, Qin H, Deng YY, Tian HY*

## Retrospective Cohort Study

- 2710 Nomogram to predict the risk of endoscopic removal failure with forceps/baskets for treating submandibular stones  
*Huang Y, Liang PS, Yang YC, Cai WX, Tao Q*
- 2721 Association between anesthesia technique and complications after hip surgery in the elderly population  
*Guo LS, Wang LN, Xiao JB, Zhong M, Zhao GF*

## Retrospective Study

- 2733 Perforating and nonperforating indications in repeated surgeries for Crohn's disease  
*Shen WS, Huang XH, Liu RQ, Li CY, Li Y, Zhu WM*
- 2743 Treatment of *Pneumocystis jirovecii* pneumonia in non-human immunodeficiency virus-infected patients using a combination of trimethoprim-sulfamethoxazole and caspofungin  
*Wu HH, Fang SY, Chen YX, Feng LF*
- 2751 Acute kidney injury in traumatic brain injury intensive care unit patients  
*Huang ZY, Liu Y, Huang HF, Huang SH, Wang JX, Tian JF, Zeng WX, Lv RG, Jiang S, Gao JL, Gao Y, Yu XX*
- 2764 Enucleation combined with guided bone regeneration in small and medium-sized odontogenic jaw cysts  
*Cao YT, Gu QH, Wang YW, Jiang Q*

**Clinical Trials Study**

- 2773 Determination of the ED<sub>95</sub> of intranasal sufentanil combined with intranasal dexmedetomidine for moderate sedation during endoscopic ultrasonography

*Zou Y, Li N, Shao LJZ, Liu FK, Xue FS, Tao X*

**Observational Study**

- 2783 Overexpression of Ubiquilin4 is associated with poor prognosis in patients with cervical cancer

*Wang LN, Huang KJ, Wang L, Cheng HY*

**Randomized Clinical Trial**

- 2792 Peplau's interpersonal relationship theory combined with bladder function training on patients with prostate cancer

*Yang XH, Wu LF, Yan XY, Zhou Y, Liu X*

**SYSTEMATIC REVIEWS**

- 2801 Efficacy of bone grafts in jaw cystic lesions: A systematic review

*Wang J, Yao QY, Zhu HY*

**CASE REPORT**

- 2811 Short stature associated with a novel mutation in the aggrecan gene: A case report and literature review

*Yin LP, Zheng HX, Zhu H*

- 2818 Treatment with sorafenib plus camrelizumab after splenectomy for primary splenic angiosarcoma with liver metastasis: A case report and literature review

*Pan D, Li TP, Xiong JH, Wang SB, Chen YX, Li JF, Xiao Q*

- 2829 Sarcomatoid intrahepatic cholangiocarcinoma with good patient prognosis after treatment with Huaier granules following hepatectomy: A case report

*Feng JY, Li XP, Wu ZY, Ying LP, Xin C, Dai ZZ, Shen Y, Wu YF*

- 2836 Sequential occurrence of T790M mutation and small cell lung cancer transformation in EGFR-positive lung adenocarcinoma: A case report

*Hong E, Chen XE, Mao J, Zhou JJ, Chen L, Xu JY, Tao W*

- 2844 Early diagnosis of Gitelman syndrome in a young child: A case report

*Wu CY, Tsai MH, Chen CC, Kao CH*

- 2851 Congenital intestinal malrotation with gastric wall defects causing extensive gut necrosis and short gut syndrome: A case report

*Wang Y, Gu Y, Ma D, Guo WX, Zhang YF*

- 2858 Delusional parasitosis as premotor symptom of parkinson's disease: A case report

*Oh M, Kim JW, Lee SM*

- 2864** Laninamivir-induced ischemic enterocolitis: A case report  
*Suzuki C, Kenzaka T*
- 2871** Intramural pregnancy after *in vitro* fertilization and embryo transfer: A case report  
*Xie QJ, Li X, Ni DY, Ji H, Zhao C, Ling XF*
- 2878** Bilateral ureteral reimplantation in a patient with an intraperitoneal ectopic bipenis: A case report  
*Jia YT, Shi BL, Zhang J, Li YY, Zhu J*
- 2883** Lumbar disc sequestration mimicking a tumor: Report of four cases and a literature review  
*Li ST, Zhang T, Shi XW, Liu H, Yang CW, Zhen P, Li SK*
- 2895** Parasitic leiomyoma in the trocar site after laparoscopic myomectomy: A case report  
*Roh CK, Kwon HJ, Jung MJ*
- 2901** Giant nontraumatic myositis ossificans in a child: A case report  
*Xia AN, Wang JS*
- 2908** Paradoxical carbon dioxide embolism during laparoscopic hepatectomy without intracardiac shunt: A case report  
*Jeon S, Hong JM, Lee HJ, Kim Y, Kang H, Hwang BY, Lee D, Jung YH*
- 2916** Local hyperthermia combined with chemotherapy for the treatment of multiple recurrences of *undifferentiated pleomorphic sarcoma*: A case report  
*Zhou YT, Wang RY, Zhang Y, Li DY, Yu J*
- 2923** Acute coronary artery stent thrombosis caused by a spasm: A case report  
*Meng LP, Wang P, Peng F*
- 2931** Turner syndrome with primary myelofibrosis, cirrhosis and ovarian cystic mass: A case report  
*Xu LW, Su YZ, Tao HF*
- 2938** Esophageal myoepithelial carcinoma: Four case reports  
*Lu H, Zhao HP, Liu YY, Yu J, Wang R, Gao JB*
- 2948** Ipsilateral hemifacial microsomia with dextrocardia and pulmonary hypoplasia: A case report  
*Guo R, Chang SH, Wang BQ, Zhang QG*
- 2954** Upper gastrointestinal bleeding from a Mallory-Weiss tear associated with transesophageal echocardiography during successful cardiopulmonary resuscitation: A case report  
*Tang MM, Fang DF, Liu B*
- 2961** Malignant struma ovarii with papillary carcinoma combined with retroperitoneal lymph node metastasis: A case report  
*Xiao W, Zhou JR, Chen D*

- 2969** Occult colon cancer with sepsis as the primary manifestation identified by bone marrow puncture: A case report

*Wang HJ, Zhou CJ*

**ABOUT COVER**

Editorial Board Member of *World Journal of Clinical Cases*, Arunchai Chang, MD, Assistant Professor, Lecturer, Staff Physician, Division of Gastroenterology, Department of Internal Medicine, Hatyai Hospital, Hatyai 90110, Songkhla, Thailand. busmdcu58@gmail.com

**AIMS AND SCOPE**

The primary aim of *World Journal of Clinical Cases* (WJCC, *World J Clin Cases*) is to provide scholars and readers from various fields of clinical medicine with a platform to publish high-quality clinical research articles and communicate their research findings online.

WJCC mainly publishes articles reporting research results and findings obtained in the field of clinical medicine and covering a wide range of topics, including case control studies, retrospective cohort studies, retrospective studies, clinical trials studies, observational studies, prospective studies, randomized controlled trials, randomized clinical trials, systematic reviews, meta-analysis, and case reports.

**INDEXING/ABSTRACTING**

The WJCC is now indexed in Science Citation Index Expanded (also known as SciSearch®), Journal Citation Reports/Science Edition, Scopus, PubMed, and PubMed Central. The 2021 Edition of Journal Citation Reports® cites the 2020 impact factor (IF) for WJCC as 1.337; IF without journal self cites: 1.301; 5-year IF: 1.742; Journal Citation Indicator: 0.33; Ranking: 119 among 169 journals in medicine, general and internal; and Quartile category: Q3. The WJCC's CiteScore for 2020 is 0.8 and Scopus CiteScore rank 2020: General Medicine is 493/793.

**RESPONSIBLE EDITORS FOR THIS ISSUE**

Production Editor: *Ying-Yi Yuan*, Production Department Director: *Xiang Li*, Editorial Office Director: *Jin-Lei Wang*.

**NAME OF JOURNAL**

*World Journal of Clinical Cases*

**ISSN**

ISSN 2307-8960 (online)

**LAUNCH DATE**

April 16, 2013

**FREQUENCY**

Thrice Monthly

**EDITORS-IN-CHIEF**

Bao-Gan Peng, Jerzy Tadeusz Chudek, George Kontogeorgos, Maurizio Serati, Ja Hyeon Ku

**EDITORIAL BOARD MEMBERS**

<https://www.wjgnet.com/2307-8960/editorialboard.htm>

**PUBLICATION DATE**

March 26, 2022

**COPYRIGHT**

© 2022 Baishideng Publishing Group Inc

**INSTRUCTIONS TO AUTHORS**

<https://www.wjgnet.com/bpg/gerinfo/204>

**GUIDELINES FOR ETHICS DOCUMENTS**

<https://www.wjgnet.com/bpg/GerInfo/287>

**GUIDELINES FOR NON-NATIVE SPEAKERS OF ENGLISH**

<https://www.wjgnet.com/bpg/gerinfo/240>

**PUBLICATION ETHICS**

<https://www.wjgnet.com/bpg/GerInfo/288>

**PUBLICATION MISCONDUCT**

<https://www.wjgnet.com/bpg/gerinfo/208>

**ARTICLE PROCESSING CHARGE**

<https://www.wjgnet.com/bpg/gerinfo/242>

**STEPS FOR SUBMITTING MANUSCRIPTS**

<https://www.wjgnet.com/bpg/GerInfo/239>

**ONLINE SUBMISSION**

<https://www.f6publishing.com>



## Laninamivir-induced ischemic enterocolitis: A case report

Chihiro Suzuki, Tsuneaki Kenzaka

**Specialty type:** Medicine, general and internal

**Provenance and peer review:** Unsolicited article; Externally peer reviewed.

**Peer-review model:** Single blind

**Peer-review report's scientific quality classification**

Grade A (Excellent): 0  
Grade B (Very good): 0  
Grade C (Good): C, C  
Grade D (Fair): 0  
Grade E (Poor): 0

**P-Reviewer:** Pichon M, Vunnam SR

**Received:** September 10, 2021

**Peer-review started:** September 10, 2021

**First decision:** October 25, 2021

**Revised:** October 29, 2021

**Accepted:** February 12, 2022

**Article in press:** February 12, 2022

**Published online:** March 26, 2022



**Chihiro Suzuki, Tsuneaki Kenzaka**, Department of Internal Medicine, Hyogo Prefectural Tamba Medical Center, Tanba 669-3495, Japan

**Tsuneaki Kenzaka**, Division of Community Medicine and Career Development, Kobe University Graduate School of Medicine, Kobe 652-0032, Japan

**Corresponding author:** Tsuneaki Kenzaka, PhD, Professor, Division of Community Medicine and Career Development, Kobe University Graduate School of Medicine, Division of Community Medicine and Career Development, Kobe University Graduate School of Medicine, 2-1-5, Arata-cho, Hyogo-ku, Kobe, Hyogo 652-0032, Japan.

[smile.kenzaka@jichi.ac.jp](mailto:smile.kenzaka@jichi.ac.jp)

### Abstract

#### BACKGROUND

Neuraminidase inhibitor-associated acute hemorrhagic colitis is rare. We report a case of ischemic enterocolitis that was likely caused by laninamivir.

#### CASE SUMMARY

A 54-year-old female patient with influenza type A was administered 40 mg of laninamivir *via* inhalation once. On the same day, the patient experienced bloody stools and lower abdominal pain. A contrast-enhanced abdominal computed tomography showed edema-like changes from the descending colon to the sigmoid colon, which suggested ischemic enterocolitis.

#### CONCLUSION

We treated a patient with ischemic enterocolitis caused by laninamivir, a rare but similar symptom following the administration of oseltamivir.

**Key Words:** Hemorrhagic colitis; Ischemic enterocolitis; Laninamivir; Influenza; Neuraminidase inhibitor; Case report

©The Author(s) 2022. Published by Baishideng Publishing Group Inc. All rights reserved.

**Core Tip:** Although a clear mechanism underlying oseltamivir-associated hemorrhagic enteritis/ischemic enterocolitis has not been elucidated, the simultaneous occurrence of the following two factors has been considered responsible for the condition: (1) Local angiospasm and vasculitis due to the effect of an allergic reaction to oseltamivir; and (2) Hypoperfusion in the intestinal tract due to the effect of dehydration caused by influenza. Laninamivir is considered to demonstrate the same mechanism as oseltamivir.

**Citation:** Suzuki C, Kenzaka T. Laninamivir-induced ischemic enterocolitis: A case report. *World J Clin Cases* 2022; 10(9): 2864-2870

**URL:** <https://www.wjgnet.com/2307-8960/full/v10/i9/2864.htm>

**DOI:** <https://dx.doi.org/10.12998/wjcc.v10.i9.2864>

## INTRODUCTION

Influenza is an infectious disease with a repetitive winter cycle. According to a report from the National Institute of Infectious Diseases, Japan, of a total population of 126 million in the country, an estimated 12 million individuals (population ratio, 9.5%) were affected by influenza during the 2018–2019 season, and 7.28 million individuals were affected during the 2019–2020 season (population ratio: 5.7%)[1]. In 2018, 3325 deaths were reportedly due to influenza[1]. In a meta-analysis of placebo-controlled clinical studies of oseltamivir in all adults, the oseltamivir group was observed to have a shortened duration of seasonal influenza and a reduced risk of hospitalization[2]. Additionally, a decrease in the influenza-associated mortality rate has been reported with the administration of neuraminidase inhibitors as the first-line of treatment[3].

Neuraminidase inhibitors approved in Japan include oral oseltamivir, inhaled zanamivir and laninamivir, and intravenous peramivir. Adverse reactions to neuraminidase inhibitors are usually mild; however, they can cause bronchospasm in patients with asthma or chronic obstructive pulmonary disease[4] and other relatively common adverse reactions such as nausea/vomiting and diarrhea. Similarly, rare occurrences of acute hemorrhagic colitis (hemorrhagic enterocolitis/ischemic enterocolitis) associated with neuraminidase inhibitors have been reported[5].

Here, we report the case of a patient with ischemic enterocolitis that was considered to have been caused by laninamivir.

## CASE PRESENTATION

### Chief complaints

Lower abdominal pain and bloody stools.

### History of present illness

During winter, a 54-year-old female patient with no significant medical history presented with general malaise and a fever of 39.2°C. The next day (the second day of symptom onset), the patient visited a nearby medical institution.

Her blood pressure was 115/60 mmHg, and her pulse rate was regular with 77 beats/min.

At the same institution, the patient was diagnosed with influenza type A using a rapid antigen kit (Quick Navi-Flu2 Influenza Diagnostic Kit, Otsuka Pharmaceutical Co., Ltd. Tokushima, Japan), and she was administered a dose of 40 mg laninamivir *via* inhalation. Approximately three hours after inhalation on the same day, the patient reportedly experienced bloody stools and lower abdominal pain while sleeping at night. On the third day of symptom onset, the patient visited our institution and was hospitalized due to persistent intermittent lower abdominal pain every 20 min and bloody stools at a frequency of ten times a day. No oral medication, including any anti-platelets/anticoagulants, was prescribed.

### History of past illness

Nothing in particular.

### Personal and family history

Nothing in particular.



### Physical examination

Upon clinical examination, the patient appeared lucid. Her blood pressure was 125/67 mmHg, pulse rate was regular with 67 beats/min, body temperature was 36.7°C, respiratory rate was 16 breaths/min, and SpO<sub>2</sub> was 97% at room air. No pallor was observed on the palpebral conjunctiva. Heart sounds were regular, and there were no cardiac murmurs. Breath sounds were clear. The abdomen was flat and soft, with tenderness on the left flank. There was no rebound tenderness or muscle guarding. Bowel peristaltic sounds did not increase or decrease, and no palpable mass or hemorrhage was observed on rectal examination. There was no edema in the extremities, and no signs of cyanosis were observed. Her mouth was dry, and the capillary refilling time was four seconds, which suggested dehydration.

### Laboratory examinations

Blood test results revealed the following: white blood cell count, 7810/ $\mu$ L; hemoglobin, 12.9 g/dL; platelet count,  $20.7 \times 10^4$ / $\mu$ L; L-dimer, 1.0  $\mu$ g/mL; blood urea nitrogen, 17.7 mg/dL; creatinine, 0.47 mg/dL; creatinine kinase, 75 U/L; aspartate aminotransferase, 17 U/L; alanine aminotransferase, 13 U/L; lactate dehydrogenase, 155 U/L; alkaline phosphatase, 210 U/L; C-reactive protein, 3.08 mg/dL; and glycated hemoglobin A1c, 5.9%. She had no abnormalities, such as diabetes mellitus or liver dysfunction, which could manifest in ischemic episodes. Stool culture tests were performed for normal intestinal flora alone, and *Salmonella* growth was not observed. Polymerase chain reaction was not performed to detect bacteria in stools, and the stool was negative for *Clostridium difficile* toxin A and B.

### Imaging examinations

Abdominal contrast-enhanced computed tomography showed edema-like changes that extended from the descending colon to the sigmoid colon (Figure 1).

## FINAL DIAGNOSIS

Based on the patient's clinical symptoms and imaging, her condition was diagnosed as ischemic enterocolitis.

## TREATMENT

Fluid replacement was administered for bowel rest, and food and drink intake was withheld. For influenza type A, laninamivir had been administered *via* inhalation two days ago, and the patient was kept in a private room and followed up with symptomatic treatment. On the second day of hospitalization, fresh blood in the stool disappeared, and abdominal pain improved. On the third day of hospitalization, the patient started eating again, which did not worsen the symptoms. The patient was discharged on the fifth day of hospitalization.

## OUTCOME AND FOLLOW-UP

Lower gastrointestinal endoscopy performed following hospital discharge (8 d after admission) showed a longitudinal ulcer extending from the descending colon to the sigmoid colon and circumferential edema-like changes (Figure 2). Histopathological examination of the same region (Figure 3) revealed stromal edema, hemorrhage, and inflammatory cell infiltration, with a prominent tendency for detachment of the superficial epithelium. These findings were consistent with those observed in ischemic enterocolitis. She had a score of seven points on the Naranjo algorithm for the adverse drug reaction causality assessment scale[6]. Therefore, the patient was diagnosed with laninamivir-induced ischemic enterocolitis. No recurrence of ischemic enterocolitis has been observed in the last five years since the patient presented to us.

## DISCUSSION

We present a case of ischemic enterocolitis that was considered to be caused by laninamivir. Although there have been a few reports of acute hemorrhagic colitis caused by neuraminidase inhibitors, to the best of our knowledge, this is the first reported case of acute hemorrhagic colitis caused by laninamivir.

In total, 13 reports of acute hemorrhagic colitis associated with neuraminidase inhibitors, which were published between 2005 and 2020, are shown in Table 1[5,7-14]. All previous cases have been attributed to oseltamivir. The age of onset ranged from 12 to 61 years, and there have been no reports of onset among the elderly. Among the 13 patients, nine were female individuals. The time of onset was four

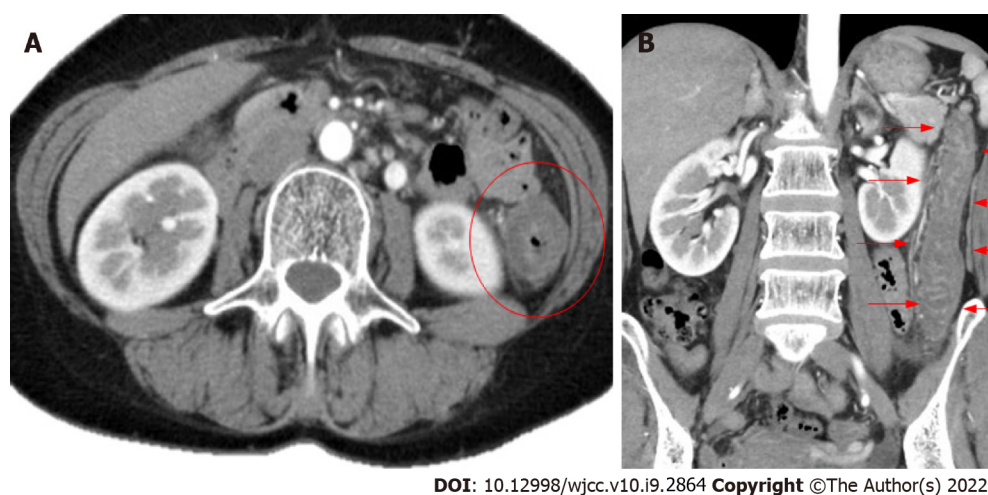
Table 1 Summary of reports of acute hemorrhagic colitis associated with neuraminidase inhibitors

Patient	Ref.	Publication year	Age (yr)	Sex	Influenza type	Medication used	Time from use of medication to onset	Symptoms	Endoscopic findings
1	[5]	2005	58	Female	A	Oseltamivir	2 d	Diarrhea, abdominal pain, and bloody stools	Longitudinal ulcer from the descending colon to the left side of the transverse colon
2	[7]	2006	28	Female	B	Oseltamivir	2 d	Bloody stools	Erosion, edema, and hemorrhage on the left side of the transverse colon
3	[8]	2007	20	Female	Unknown	Oseltamivir	2 d	Melena and abdominal pain	Erosion, redness, and edema in the descending colon
4	[8]	2007	50	Female	Unknown	Oseltamivir	2 d	Diarrhea, bloody stools, abdominal pain	Erosion and suspicion of ischemic enterocolitis on the left side of the colon
5	[8]	2007	30	Male	Unknown	Oseltamivir	2 d	Abdominal pain, diarrhea, and melena	Edema-like necrotic material and suspicion of ischemic enterocolitis from the sigmoid to the descending colon
6	[8]	2007	28	Female	Unknown	Oseltamivir	2 d	Abdominal pain and bloody stools	Hemorrhage, erosion, edema, and redness on the left side of the transverse colon
7	[8]	2007	50	Female	A	Oseltamivir	2 d	Bloody stools	Redness and ulceration in the descending colon
8	[9]	2013	32	Female	A	Oseltamivir	2 d	Bloody stools and tenesmus	Redness, ulcer, and mucosal edema in the rectum
9	[10]	2007	61	Male	A	Oseltamivir	1 d	Abdominal pain, diarrhea, and bloody stools	Mucosal edema, hemorrhage, and longitudinal ulcer in the entire colon
10	[11]	2011	40	Female	A	Oseltamivir	4 h	Abdominal pain, diarrhea, and bloody stools	Redness, edema, erosion, and hemorrhage in the descending colon
11	[12]	2015	31	Female	A	Oseltamivir	2 d	Abdominal pain and bloody diarrhea	Not performed
12	[13]	2016	12	Male	Unknown	Oseltamivir	4 d	Bloody stools	Not performed
13	[14]	2020	14	Male	A	Oseltamivir	Immediately after (time not specified)	Abdominal pain, nausea, and bloody stools	Findings of ischemic enterocolitis (details not specified)

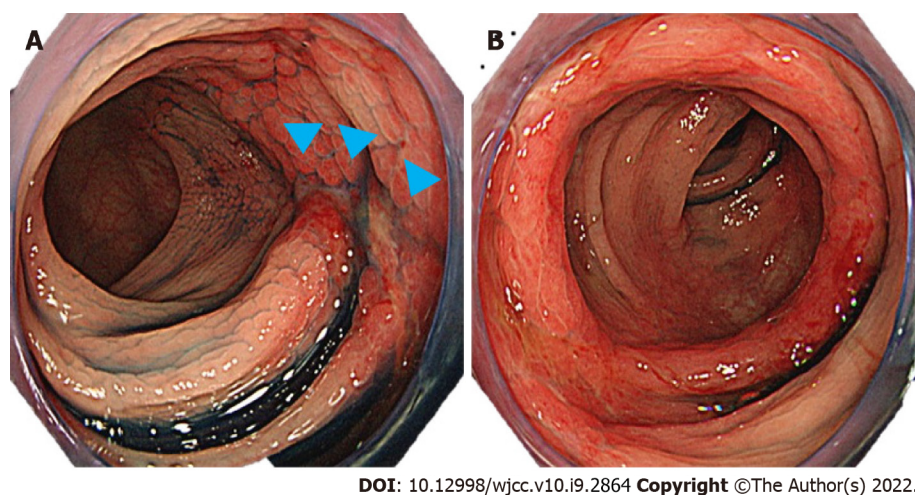
days following oral administration of oseltamivir in one patient; however, in the remaining patients, acute onset was observed immediately-to-within two days following the oral administration of oseltamivir. The descending colon was the most common site of onset. The outcome was favorable after discontinuation of the drug and conservative treatment; however, in patient 13, the hemoglobin level decreased to 3.8 mg/dL, which necessitated red blood cell transfusions.

Our patient was a middle-aged female individual without any risk factors; however, she developed ischemic enterocolitis within half a day after the administration of laninamivir *via* inhalation. Consistent with the previously reported patient who experienced hemorrhagic enteritis/ischemic enterocolitis after the oral administration of oseltamivir[5,7], this patient was diagnosed with ischemic enterocolitis induced by laninamivir, which is a neuraminidase inhibitor similar to oseltamivir.

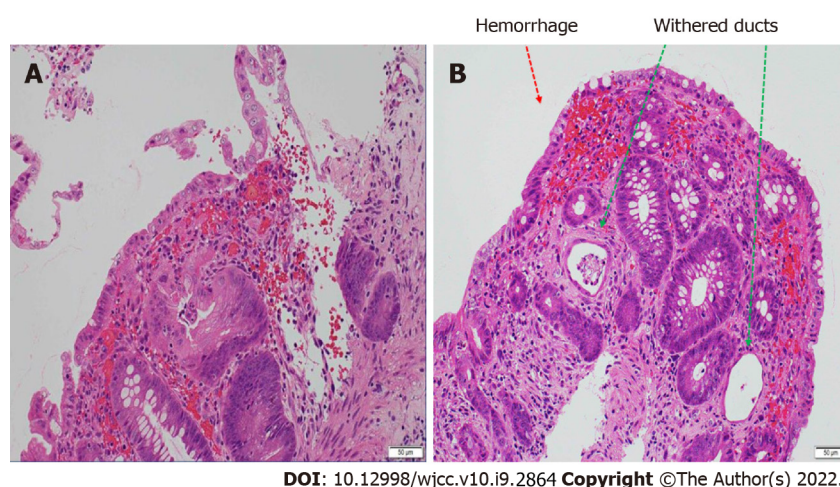
Although a clear mechanism underlying oseltamivir-associated hemorrhagic enteritis/ischemic enterocolitis has not been elucidated, simultaneous occurrence of the following two factors has been considered responsible for the condition: (1) Local angiospasm and vasculitis due to the effect of an allergic reaction to oseltamivir; and (2) Hypoperfusion in the intestinal tract due to the effect of dehydration caused by influenza[9,12]. Laninamivir is considered to demonstrate the same mechanism as oseltamivir. Approximately three hours after inhalation, she reportedly experienced bloody stools and lower abdominal pain. In addition, she developed certain symptoms shortly after inhalation and a possible allergic reaction. Similarly, she was dehydrated based on physical findings. Therefore, the mechanism underlying oseltamivir-associated ischemic enterocolitis in this patient is considered related to these factors.



**Figure 1 Contrast-enhanced abdominal computed tomography.** A: Horizontal slice; B: Coronal slice edema-like changes are observed from the descending colon to the sigmoid colon (red circle, red arrow).



**Figure 2 Lower gastrointestinal endoscopy.** A: Longitudinal ulcer (sagittal head); B: Edema-like changes are observed.



**Figure 3 Histopathological examination of lesions in the colon (hematoxylin-eosin staining).** A: Stromal edema and hemorrhage, infiltration of inflammatory cells, and a tendency for detachment of superficial epithelial are observed; B: Withered ducts (green arrow) and hemorrhage (red arrow) are observed.

During treatment for influenza, attention should be paid not only to respiratory tract symptoms such as pyrexia, cough, and sputum but also to abdominal symptoms.

## CONCLUSION

In conclusion, we treated a patient with ischemic enterocolitis that was considered to be caused by laninamivir. The onset of ischemic enterocolitis, although rare, has been reported following the administration of oseltamivir. Similarly, laninamivir may cause similar abdominal symptoms through the same mechanism; thus, caution should be exercised during the administration of this medication.

## FOOTNOTES

**Author contributions:** Suzuki C managed the case and redaction and correction of the manuscript; Kenzaka T assisted with redaction, correction, and reconstruction of the manuscript; All authors read and approved the final manuscript.

**Informed consent statement:** Written informed consent was obtained from the patient for publication of this case report and accompanying images. A copy of the written consent is available for review by the Editor of this journal.

**Conflict-of-interest statement:** The authors declare that they have no competing interests.

**CARE Checklist (2016) statement:** The authors have read the CARE Checklist statement, and the manuscript was prepared and revised according to the CARE Checklist statement.

**Open-Access:** This article is an open-access article that was selected by an in-house editor and fully peer-reviewed by external reviewers. It is distributed in accordance with the Creative Commons Attribution NonCommercial (CC BY-NC 4.0) license, which permits others to distribute, remix, adapt, build upon this work non-commercially, and license their derivative works on different terms, provided the original work is properly cited and the use is non-commercial. See: <https://creativecommons.org/licenses/by-nc/4.0/>

**Country/Territory of origin:** Japan

**ORCID number:** Chihiro Suzuki 0000-0002-2011-6006; Tsuneaki Kenzaka 0000-0002-3120-6605.

**S-Editor:** Ma YJ

**L-Editor:** A

**P-Editor:** Ma YJ

## REFERENCES

- 1 **National Institute of Infectious Diseases.** Infectious Agents Surveillance Report (IASR). Influenza 2019/20 season. IASR; 41: 191-193. [cited January 31, 2021] Available from: <https://www.niid.go.jp/niid/ja/flu-m/flu-iasrtpc/9961-489t.html>
- 2 **Dobson J,** Whitley RJ, Pocock S, Monto AS. Oseltamivir treatment for influenza in adults: a meta-analysis of randomised controlled trials. *Lancet* 2015; **385**: 1729-1737 [PMID: 25640810 DOI: 10.1016/S0140-6736(14)62449-1]
- 3 **Muthuri SG,** Venkatesan S, Myles PR, Leonardi-Bee J, Al Khuwaitir TS, Al Mamun A, Anovadiya AP, Azziz-Baumgartner E, Báez C, Bassetti M, Beovic B, Bertisch B, Bonmarin I, Booy R, Borja-Aburto VH, Burgmann H, Cao B, Carratala J, Denholm JT, Dominguez SR, Duarte PA, Dubnov-Raz G, Echavarría M, Fanella S, Gao Z, Gérardin P, Giannella M, Gubbels S, Herberg J, Iglesias AL, Hoger PH, Hu X, Islam QT, Jiménez MF, Kandeel A, Keijzers G, Khalili H, Knight M, Kudo K, Kuznierz G, Kuzman I, Kwan AM, Amine IL, Langenegger E, Lankarani KB, Leo YS, Linko R, Liu P, Madanat F, Mayo-Montero E, McGeer A, Memish Z, Metan G, Mickiene A, Mikić D, Mohn KG, Moradi A, Nymadawa P, Oliva ME, Ozkan M, Parekh D, Paul M, Polack FP, Rath BA, Rodríguez AH, Sarrouf EB, Seale AC, Sertogullarindan B, Siqueira MM, Skret-Magierlo J, Stephan F, Talarek E, Tang JW, To KK, Torres A, Törün SH, Tran D, Uyeki TM, Van Zwoel A, Vaudry W, Vidmar T, Yokota RT, Zarogoulidis P; PRIDE Consortium Investigators, Nguyen-Van-Tam JS. Effectiveness of neuraminidase inhibitors in reducing mortality in patients admitted to hospital with influenza A H1N1pdm09 virus infection: a meta-analysis of individual participant data. *Lancet Respir Med* 2014; **2**: 395-404 [PMID: 24815805 DOI: 10.1016/S2213-2600(14)70041-4]
- 4 **Relenza dear doctor letter in EU follow U.S. advisory.** In: "The Pink Sheet" F-D-C Reports, Chevy Chase, MD. January 31, 2000, p20
- 5 **Nara N,** Oshimoto H, Hirouchi K, Toyoda M, Katakai K, Masuda J, Matsumoto J, Arai T. A case of ischemic colitis induced by oseltamivir phosphate. *Prog Dig Endosc* 2005; **67**: 114-115 (article in Japanese)
- 6 **Naranjo CA,** Busto U, Sellers EM, Sandor P, Ruiz I, Roberts EA, Janecek E, Domecq C, Greenblatt DJ. A method for estimating the probability of adverse drug reactions. *Clin Pharmacol Ther* 1981; **30**: 239-245 [PMID: 7249508 DOI: 10.1038/clpt.1981.154]



- 7 **Yoneda S**, Kobayashi Y, Nunoi T, Takeda K, Matsumori A, Andoh M, Tsujinoue H, Nishimura K, Fukui H. [Acute hemorrhagic colitis induced by the neuraminidase inhibitor oseltamivir]. *Nihon Shokakibyō Gakkai Zasshi* 2006; **103**: 1270-1273 [PMID: [17085909](#) DOI: [10.11405/nisshoshi.103.1270](#)]
- 8 **Abe A**, Sugiura N, Akiike T, Ito K, Aruga A, Kaneda S, Nakano M. A case of colon ulcer induced by oseltamivir phosphate. *Prog Dig Endosc* 2007; **70**: 110-111 (article in Japanese)
- 9 **Chen YH**, Lai HJ. Acute hemorrhagic colitis after oral administration of oseltamivir for influenza. *Gastrointest Endosc* 2013; **77**: 976 [PMID: [23684098](#) DOI: [10.1016/j.gie.2013.01.033](#)]
- 10 **Matsushita M**, Nishihara H, Nishiyama R, Kobayashi Y. Acute hemorrhagic colitis associated with oral administration of oseltamivir for the treatment of influenza A. *J Infect Chemother* 2007; **13**: 267-269 [PMID: [17721691](#) DOI: [10.1007/s10156-007-0527-6](#)]
- 11 **Nakagawa Y**, Nagai T, Okawara H, Nakashima H, Hisamatsu A, Shuto M, Yamauchi M, Kai S, Yokoyama S, Murakami K, Fujioka T. Acute hemorrhagic colitis induced by the oral administration of oseltamivir used for influenza A treatment. *Endoscopy* 2011; **43** Suppl 2 UCTN: E261 [PMID: [21837605](#) DOI: [10.1055/s-0030-1256524](#)]
- 12 **Manickam P**, Mogrovejo E, Cappell MS. Oseltamivir-induced acute hemorrhagic colitis. *Minerva Gastroenterol Dietol* 2015; **61**: 299-301 [PMID: [26657929](#)]
- 13 **Beraldi-Magalhães F**, Batista V, Cordeiro-Santos M. Oseltamivir as a cause of acute enterorrhagia. *Braz J Infect Dis* 2016; **20**: 521 [PMID: [27542865](#) DOI: [10.1016/j.bjid.2016.07.010](#)]
- 14 **Abe Y**, Tsukano S, Izumita Y, Yamanaka T. Hemorrhagic colitis can be a life-threatening side effect of oseltamivir. *Pediatr Int* 2020; **62**: 634-635 [DOI: [10.1111/ped.14138](#)]



Published by **Baishideng Publishing Group Inc**  
7041 Koll Center Parkway, Suite 160, Pleasanton, CA 94566, USA

**Telephone:** +1-925-3991568

**E-mail:** [bpgoffice@wjgnet.com](mailto:bpgoffice@wjgnet.com)

**Help Desk:** <https://www.f6publishing.com/helpdesk>

<https://www.wjgnet.com>

