

World Journal of *Clinical Cases*

World J Clin Cases 2023 January 6; 11(1): 1-254



Contents

Thrice Monthly Volume 11 Number 1 January 6, 2023

EDITORIAL

- 1 Impact of gut-brain interaction in emerging neurological disorders
Lin MS, Wang YC, Chen WJ, Kung WM

OPINION REVIEW

- 7 Postoperative diarrhea in Crohn's disease: Pathogenesis, diagnosis, and therapy
Wu EH, Guo Z, Zhu WM

REVIEW

- 17 Endplate role in the degenerative disc disease: A brief review
Velmar T, Gradisnik L
- 30 Challenges for clinicians treating autoimmune pancreatitis: Current perspectives
Kim SH, Lee YC, Chon HK

MINIREVIEWS

- 47 Intestinal microecology-based treatment for inflammatory bowel disease: Progress and prospects
Yan XX, Wu D
- 57 Rehabilitation care of patients with neurogenic bladder after spinal cord injury: A literature review
Xiang L, Li H, Xie QQ, Siau CS, Xie Z, Zhu MT, Zhou B, Li ZP, Wang SB
- 65 Role of natural products and intestinal flora on type 2 diabetes mellitus treatment
Aydin OC, Aydin S, Barun S
- 73 Role of the extracellular matrix in COVID-19
Huang JJ, Wang CW, Liu Y, Zhang YY, Yang NB, Yu YC, Jiang Q, Song QF, Qian GQ
- 84 Diabetic wounds and artificial intelligence: A mini-review
Tehsin S, Kausar S, Jameel A

ORIGINAL ARTICLE

Clinical and Translational Research

- 92 Identification of a four-miRNA signature predicts the prognosis of papillary thyroid cancer
Yang F, Zhou YL

Retrospective Cohort Study

- 104** Completion of 6-mo isoniazid preventive treatment among eligible under six children: A cross-sectional study, Lagos, Nigeria
Adepoju VA, Adelekan A, Agbaje A, Quaitey F, Ademola-Kay T, Udoekpo AU, Sokoya OD

Retrospective Study

- 116** Impact of central venous port implantation method and access choice on outcomes
Erdemir A, Rasa HK

CASE REPORT

- 127** Extracorporeal shock wave for plantar flexor spasticity in spinal cord injury: A case report and review of literature
Comino-Suárez N, Gómez-Soriano J, Ceruelo-Abajo S, Vargas-Baquero E, Esclarín A, Avendaño-Coy J
- 135** Polyneuropathy organomegaly endocrinopathy M-protein and skin changes syndrome with ascites as an early-stage manifestation: A case report
Zhou XL, Chang YH, Li L, Ren J, Wu XL, Zhang X, Wu P, Tang SH
- 143** Devastating complication of negative pressure wound therapy after deep inferior epigastric perforator free flap surgery: A case report
Lim S, Lee DY, Kim B, Yoon JS, Han YS, Eo S
- 150** Adult focal β -cell nesidioblastosis: A case report
Tu K, Zhao LJ, Gu J
- 157** Anesthesia with ciprofol in cardiac surgery with cardiopulmonary bypass: A case report
Yu L, Bischof E, Lu HH
- 164** Thymic lipofibroadenomas: Three case reports
Yang MQ, Wang ZQ, Chen LQ, Gao SM, Fu XN, Zhang HN, Zhang KX, Xu HT
- 172** Perforation of levonorgestrel-releasing intrauterine system found at one month after insertion: A case report
Zhang GR, Yu X
- 177** Drug-induced sarcoidosis-like reaction three months after BNT162b2 mRNA COVID-19 vaccination: A case report and review of literature
Kim SR, Kim SK, Fujii T, Kobayashi H, Okuda T, Hayakumo T, Nakai A, Fujii Y, Suzuki R, Sasase N, Otani A, Koma YI, Sasaki M, Kumabe T, Nakashima O
- 187** Hyponatremic encephalopathy due to polyethylene glycol-based bowel preparation for colonoscopy: A case report
Zhao Y, Dong HS
- 193** Post-traumatic heterotopic ossification in front of the ankle joint for 23 years: A case report and review of literature
Xu Z, Rao ZZ, Tang ZW, Song ZQ, Zeng M, Gong HL, Wen J

- 201** Extraskelatal Ewing sarcoma of the stomach: A rare case report
Shu Q, Luo JN, Liu XL, Jing M, Mou TG, Xie F
- 210** Ochronotic arthropathy of bilateral hip joints: A case report
Yap San Min N, Rafi U, Wang J, He B, Fan L
- 218** Pembrolizumab-induced psoriatic arthritis treated with disease-modifying anti-rheumatic drugs in a patient with gastric cancer: A case report
Kim S, Sun JH, Kim H, Kim HK, Yang Y, Lee JS, Choi IA, Han HS
- 225** High-flow priapism due to bilateral cavernous artery fistulas treated by unilateral embolization: A case report
Li G, Liu Y, Wang HY, Du FZ, Zuo ZW
- 233** Malignant transformation of pulmonary bronchiolar adenoma into mucinous adenocarcinoma: A case report
Liu XL, Miao CF, Li M, Li P
- 242** Cystic artery pseudoaneurysm: A case report
Liu YL, Hsieh CT, Yeh YJ, Liu H
- 249** Congenital stapes suprastructure fixation presenting with fluctuating auditory symptoms: A case report
Choi S, Park SH, Kim JS, Chang J

ABOUT COVER

Editorial Board Member of *World Journal of Clinical Cases*, Gabriel Lucca de Oliveira Salvador, MD, Academic Research, Professor, Department of Radiology and Internal Medicine, Federal University of Parana, Curitiba 80060-900, Parana, Brazil. glucca11@gmail.com

AIMS AND SCOPE

The primary aim of *World Journal of Clinical Cases* (WJCC, *World J Clin Cases*) is to provide scholars and readers from various fields of clinical medicine with a platform to publish high-quality clinical research articles and communicate their research findings online.

WJCC mainly publishes articles reporting research results and findings obtained in the field of clinical medicine and covering a wide range of topics, including case control studies, retrospective cohort studies, retrospective studies, clinical trials studies, observational studies, prospective studies, randomized controlled trials, randomized clinical trials, systematic reviews, meta-analysis, and case reports.

INDEXING/ABSTRACTING

The WJCC is now abstracted and indexed in Science Citation Index Expanded (SCIE, also known as SciSearch®), Journal Citation Reports/Science Edition, Current Contents®/Clinical Medicine, PubMed, PubMed Central, Scopus, Reference Citation Analysis, China National Knowledge Infrastructure, China Science and Technology Journal Database, and Superstar Journals Database. The 2022 Edition of Journal Citation Reports® cites the 2021 impact factor (IF) for WJCC as 1.534; IF without journal self cites: 1.491; 5-year IF: 1.599; Journal Citation Indicator: 0.28; Ranking: 135 among 172 journals in medicine, general and internal; and Quartile category: Q4. The WJCC's CiteScore for 2021 is 1.2 and Scopus CiteScore rank 2021: General Medicine is 443/826.

RESPONSIBLE EDITORS FOR THIS ISSUE

Production Editor: Si Zhao; Production Department Director: Xiang Li; Editorial Office Director: Jin-Lei Wang.

NAME OF JOURNAL

World Journal of Clinical Cases

ISSN

ISSN 2307-8960 (online)

LAUNCH DATE

April 16, 2013

FREQUENCY

Thrice Monthly

EDITORS-IN-CHIEF

Bao-Gan Peng, Jerzy Tadeusz Chudek, George Kontogeorgos, Maurizio Serati, Ja Hyeon Ku

EDITORIAL BOARD MEMBERS

<https://www.wjgnet.com/2307-8960/editorialboard.htm>

PUBLICATION DATE

January 6, 2023

COPYRIGHT

© 2023 Baishideng Publishing Group Inc

INSTRUCTIONS TO AUTHORS

<https://www.wjgnet.com/bpg/gerinfo/204>

GUIDELINES FOR ETHICS DOCUMENTS

<https://www.wjgnet.com/bpg/GerInfo/287>

GUIDELINES FOR NON-NATIVE SPEAKERS OF ENGLISH

<https://www.wjgnet.com/bpg/gerinfo/240>

PUBLICATION ETHICS

<https://www.wjgnet.com/bpg/GerInfo/288>

PUBLICATION MISCONDUCT

<https://www.wjgnet.com/bpg/gerinfo/208>

ARTICLE PROCESSING CHARGE

<https://www.wjgnet.com/bpg/gerinfo/242>

STEPS FOR SUBMITTING MANUSCRIPTS

<https://www.wjgnet.com/bpg/GerInfo/239>

ONLINE SUBMISSION

<https://www.f6publishing.com>



Perforation of levonorgestrel-releasing intrauterine system found at one month after insertion: A case report

Guo-Rui Zhang, Xin Yu

Specialty type: Obstetrics and gynecology

Provenance and peer review:

Unsolicited article; Externally peer reviewed.

Peer-review model: Single blind

Peer-review report's scientific quality classification

Grade A (Excellent): 0

Grade B (Very good): B

Grade C (Good): C, C

Grade D (Fair): 0

Grade E (Poor): 0

P-Reviewer: Hegazy AA, Egypt; Shelat VG, Singapore

Received: August 30, 2022

Peer-review started: August 30, 2022

First decision: November 22, 2022

Revised: December 3, 2022

Accepted: December 19, 2022

Article in press: December 19, 2022

Published online: January 6, 2023



Guo-Rui Zhang, Xin Yu, Department of Obstetrics and Gynecology, State Key Laboratory of Complex, Severe and Rare Diseases, National Clinical Research Center for Obstetric & Gynecologic Diseases, Peking Union Medical College Hospital, Chinese Academy of Medical Sciences and Peking Union Medical College, Beijing 100730, China

Corresponding author: Xin Yu, MD, Professor, Department of Obstetrics and Gynecology, State Key Laboratory of Complex, Severe and Rare Diseases, National Clinical Research Center for Obstetric & Gynecologic Diseases, Peking Union Medical College Hospital, Chinese Academy of Medical Sciences and Peking Union Medical College, No. 1 Shuaifuyuan, Wangfujing, Beijing 100730, China. yuxpunch@126.com

Abstract

BACKGROUND

The levonorgestrel-releasing intrauterine system (LNG-IUS) is widely used in contraception, menorrhagia, dysmenorrhea and to prevent endometrial hyperplasia during estrogen supplementation. Perforation is more often seen after early postpartum placement. Perforation of the LNG-IUS occurring one month after placement is rare.

CASE SUMMARY

A 42-year-old female complained of progressive dysmenorrhea and increased menstrual volume. She was diagnosed with adenomyosis and the LNG-IUS was inserted in her uterine cavity. Routine ultrasound examination one month later revealed that the intra-uterine device (IUD) was not found in the uterine cavity, and further X-ray and pelvic magnetic resonance imaging showed an abnormal signal area in the left posterior region of the uterus. Laparoscopic exploratory surgery was performed and the LNG-IUS was found in the left uterosacral ligament.

CONCLUSION

Perforation of a LNG-IUS occurring one month after placement is rare, and is more common in inexperienced operators and after early postpartum placement. When the operation is difficult, ultrasound monitoring is recommended to reduce the risk of IUD perforation. For patients with inadequate surgery, postoperative imaging is recommended to detect potential risks as soon as possible.

Key Words: Levonorgestrel-releasing intrauterine system; Perforation; Malposition; Case report

©The Author(s) 2023. Published by Baishideng Publishing Group Inc. All rights reserved.

Core Tip: Perforation of a levonorgestrel-releasing intrauterine system occurring one month after placement is rare. We report a patient who underwent levonorgestrel-releasing intrauterine system placement due to adenomyosis, and perforation was found one month later. Perforation is more common in inexperienced operators and after early postpartum placement. When the operation is difficult, ultrasound monitoring is recommended to reduce the risk of intra-uterine device perforation. Postoperative imaging is recommended to detect potential risks as soon as possible.

Citation: Zhang GR, Yu X. Perforation of levonorgestrel-releasing intrauterine system found at one month after insertion: A case report. *World J Clin Cases* 2023; 11(1): 172-176

URL: <https://www.wjgnet.com/2307-8960/full/v11/i1/172.htm>

DOI: <https://dx.doi.org/10.12998/wjcc.v11.i1.172>

INTRODUCTION

The levonorgestrel-releasing intrauterine system (LNG-IUS) is a widely used effective intrauterine progesterone release system. The most common adverse effects of the LNG-IUS include pelvic pain, dysmenorrhea, heavy menstrual bleeding, infection and malposition[1,2]. Perforation of the LNG-IUS is rare. We report a case of LNG-IUS perforation found one month after insertion.

CASE PRESENTATION

Chief complaints

A 42-year-old female patient complained of intermittent lower abdominal pain, with a visual analogue score of 2 points, and anal distension.

History of present illness

The patient had progressive dysmenorrhea and increased menstrual volume over the past years. She was diagnosed with adenomyosis and the LNG-IUS was placed in her uterine cavity by a certified doctor in November, 2021. Routine ultrasound examination in December, 2021 showed a strong echo area 0.6 cm × 0.2 cm in size in the uterine cavity, and no echo due to the intra-uterine device (IUD) was detected in the uterine cavity. The patient denied a history of vaginal exclusion of contraceptives. Hysteroscopy was performed in December 2021, and no IUD was found in the uterine cavity.

History of previous disease

The patient had no previous disease history.

Personal history and family history

Gravidity 7 and parity 2 were noted. Menstrual history was 4-5 d/28 d. Her previous contraceptive method was the use of condoms. The patient had no history of family or genetic diseases.

Physical examination

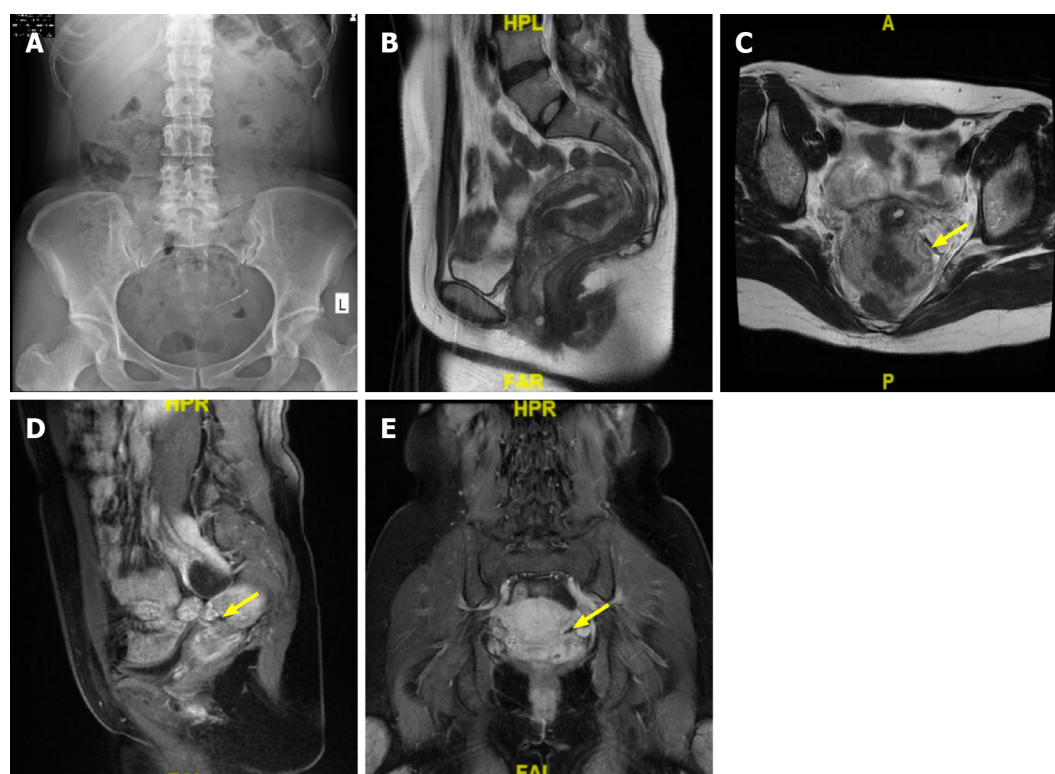
Gynecological examination showed that the uterus was posterior, tough and flexible. Bimanual examination showed that a tough cord was felt in the left side of the uterus, with positive tenderness.

Laboratory examinations

Laboratory examinations showed that the total number of white blood cells was $4.65 \times 10^9/L$, and the proportion of neutrophils was 51.6%.

Imaging examinations

X-ray showed that a radiopaque T-shaped device was visible in the pelvis. Transvaginal ultrasonography revealed that the uterus was 5.9 cm × 7.5 cm × 5.2 cm in size; the endometrium was 0.4 cm thick; the muscular layer showed uneven echo patterns, with a thickness of 2.2 cm in the anterior muscular layer and 2.7 cm in the posterior; no echo area was detected in the left ovary, which was 3.5 cm × 2.3 cm in size, with a clear boundary and no blood flow signal. Pelvic magnetic resonance imaging presented abnormal signal in the left posterior area of the uterus (Figure 1).



DOI: 10.12998/wjcc.v11.i1.172 Copyright ©The Author(s) 2023.

Figure 1 X-ray and magnetic resonance imaging of the malpositioned levonorgestrel-releasing intrauterine system. A: X-ray shows that a radiopaque T-shape device is visible in the pelvis; B: The uterus is in the retroflexed position; C: The malpositioned levonorgestrel-releasing intrauterine system (yellow arrow) was seen in axial; D: Sagittal; E: Coronal position.

FINAL DIAGNOSIS

Extrauterine device malposition.

TREATMENT

Given the possibility of IUD malposition, the patient underwent emergency laparoscopic exploratory surgery. During the operation, an intact LNG-IUS with a tail wire was found near the left uterosacral ligament (Figure 2), without adhesion to the surrounding tissues. After thorough examination, no rupture was found in the uterus. A 3 cm diameter cyst with clear fluid inside was found in the left ovary and was removed. A new LNG-IUS was inserted in the uterine cavity.

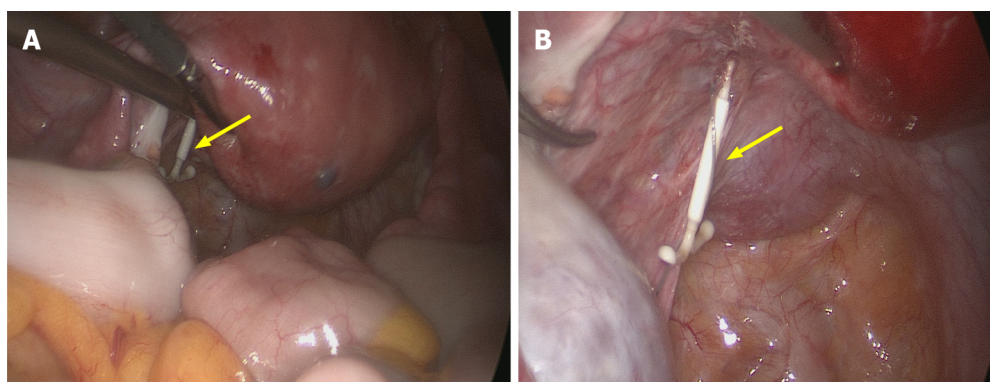
OUTCOME AND FOLLOW-UP

The patient was discharged after recovery. Postoperative pathology showed that the left ovarian cyst was a follicular cyst.

DISCUSSION

The LNG-IUS is an effective intrauterine progesterone release system, which is widely used in contraception, menorrhagia, dysmenorrhea and to prevent endometrial hyperplasia during estrogen supplementation[2]. The LNG-IUS is also a radiopaque T-shaped device, approved for up to 5 years of use.

The adverse effects of IUDs include pelvic pain, heavy menstrual bleeding, dysmenorrhea, infection and malposition. IUD malposition, with a rate ranging from 10.4% to 25%, is described as expulsion, embedding, displacement and perforation[2]. Malposition often occurs with abnormal bleeding and pain, but may also be asymptomatic. Perforation is an IUD that penetrates through both the myometrium and the serosa.



DOI: 10.12998/wjcc.v11.i1.172 Copyright ©The Author(s) 2023.

Figure 2 During the operation, an intact levonorgestrel-releasing intrauterine system with a tail wire was found near the left uterosacral ligament. A: During the operation, the uterus is in the retroflexed position and an intact levonorgestrel-releasing intrauterine system with a tail wire is found near the left uterosacral ligament (A, yellow arrow); B: Without adhesion to the surrounding tissues (B, yellow arrow).

The overall perforation rate is 2.1 per 1000 insertions for LNG-IUS users and 1.6 per 1000 insertions for copper-IUD users[3]. Perforation is more often seen in inexperienced operators and after early postpartum placement[4]. Malposition is more common in the condition of retroflexed uterine positions (7.6% *vs* 1.8%). Multivariable logistic regression has revealed that the anterior midline position and absence of uterine anomalies are factors associated with a lower incidence of IUD malposition[5]. The repositioned uterus may be a potential cause of uterine perforation upon insertion of the device. Therefore, doctors should take care in these cases.

Ultrasonography serves as the first-line imaging method to evaluate position of IUD in patients presenting with abnormal bleeding, pelvic pain, or absent retrieval strings[6]. If an IUD is not detected on initial ultrasonography, further abdominal radiographs are recommended to locate the IUD[7]. Cross-sectional imaging can provide clues and strategies for surgical planning, as well as to evaluate potential complications such as abscess formation or bowel injury.

Surgical removal of IUDs is the main treatment strategy. In a previous report, laparoscopic surgeries to remove perforated IUDs were successfully achieved in 64.2% of cases (115/179)[8]. However 22.5% (27/120) of laparoscopic surgeries were converted to trans-abdominal operations in another report, and an overall rate of open surgery was 27.9%[9]. The most common location of malpositioned IUDs include the omentum and around the uterus[8]. Intra-abdominal adhesions are more common in the copper-IUD group than LNG-IUS group (58% *vs* 20%)[8].

CONCLUSION

This case report shows that during placement of an IUD, uterine position should be confirmed by gynecological examination before surgery, and the operation should be performed with care. When the operation is difficult, ultrasound monitoring is recommended to reduce the risk of IUD perforation. Postoperative imaging is recommended to detect potential risks as soon as possible.

ACKNOWLEDGEMENTS

We thank the patient for the consent to publish this case report.

FOOTNOTES

Author contributions: Zhang GR collected the data, imaging, and surgical reports and wrote the initial draft of the manuscript and subsequent revisions; Yu X is the senior author who was the treating surgeon and was responsible for overseeing the report and editing the manuscript; both authors read and approved the final manuscript.

Supported by National High Level Hospital Clinical Research Funding, No. 2022-PUMCH-A-232

Informed consent statement: The patient provided informed consent as evidenced by her signature.

Conflict-of-interest statement: All the authors declare that they have no conflicts of interest.

CARE Checklist (2016) statement: The authors have read the CARE Checklist (2016), and the manuscript was prepared and revised following the CARE Checklist (2016).

Open-Access: This article is an open-access article that was selected by an in-house editor and fully peer-reviewed by external reviewers. It is distributed in accordance with the Creative Commons Attribution NonCommercial (CC BY-NC 4.0) license, which permits others to distribute, remix, adapt, build upon this work non-commercially, and license their derivative works on different terms, provided the original work is properly cited and the use is non-commercial. See: <https://creativecommons.org/licenses/by-nc/4.0/>

Country/Territory of origin: China

ORCID number: Guo-Rui Zhang [0000-0001-5676-1413](#); Xin Yu [0000-0001-7280-3177](#).

S-Editor: Liu JH

L-Editor: A

P-Editor: Liu JH

REFERENCES

- 1 **Hegazy RA**, Hegazy AA, Etman WM. Bilateral Tubo-ovarian actinomycosis in perimenopausal woman with neglected intrauterine device: A case report and review of literature. *J Medical Case Repo* 2021; **3**: 1-5 [DOI: [10.51737/2766-4589.2020.018](#)]
- 2 **Evans AT**, Szlachetka K, Thornburg LL. Ultrasound Assessment of the Intrauterine Device. *Obstet Gynecol Clin North Am* 2019; **46**: 661-681 [PMID: [31677748](#) DOI: [10.1016/j.ogc.2019.07.005](#)]
- 3 **Barnett C**, Moehner S, Do Minh T, Heinemann K. Perforation risk and intra-uterine devices: results of the EURAS-IUD 5-year extension study. *Eur J Contracept Reprod Health Care* 2017; **22**: 424-428 [PMID: [29322856](#) DOI: [10.1080/13625187.2017.1412427](#)]
- 4 **Cole M**, Thomas S, Mercer BM, Arora KS. Impact of training level on postplacental levonorgestrel 52 mg intrauterine device expulsion. *Contraception* 2019; **99**: 94-97 [PMID: [30452904](#) DOI: [10.1016/j.contraception.2018.11.003](#)]
- 5 **Gerkowicz SA**, Fiorentino DG, Kovacs AP, Arheart KL, Verma U. Uterine structural abnormality and intrauterine device malposition: analysis of ultrasonographic and demographic variables of 517 patients. *Am J Obstet Gynecol* 2019; **220**: 183.e1-183.e8 [PMID: [30419198](#) DOI: [10.1016/j.ajog.2018.11.122](#)]
- 6 **Connolly CT**, Fox NS. Incidence and Risk Factors for a Malpositioned Intrauterine Device Detected on Three-Dimensional Ultrasound Within Eight Weeks of Placement. *J Ultrasound Med* 2022; **41**: 1525-1536 [PMID: [34580900](#) DOI: [10.1002/jum.15836](#)]
- 7 **Kaislasuo J**, Suhonen S, Gissler M, Lähteenmäki P, Heikinheimo O. Uterine perforation caused by intrauterine devices: clinical course and treatment. *Hum Reprod* 2013; **28**: 1546-1551 [PMID: [23526304](#) DOI: [10.1093/humrep/det074](#)]
- 8 **Gill RS**, Mok D, Hudson M, Shi X, Birch DW, Karmali S. Laparoscopic removal of an intra-abdominal intrauterine device: case and systematic review. *Contraception* 2012; **85**: 15-18 [PMID: [22067801](#) DOI: [10.1016/j.contraception.2011.04.015](#)]
- 9 **Mosley FR**, Shahi N, Kurer MA. Elective surgical removal of migrated intrauterine contraceptive devices from within the peritoneal cavity: a comparison between open and laparoscopic removal. *JSLS* 2012; **16**: 236-241 [PMID: [23477171](#) DOI: [10.4293/108680812x13427982377265](#)]



Published by **Baishideng Publishing Group Inc**
7041 Koll Center Parkway, Suite 160, Pleasanton, CA 94566, USA

Telephone: +1-925-3991568

E-mail: bpgoffice@wjgnet.com

Help Desk: <https://www.f6publishing.com/helpdesk>

<https://www.wjgnet.com>

