

# World Journal of *Clinical Cases*

*World J Clin Cases* 2023 April 6; 11(10): 2123-2362



## Contents

Thrice Monthly Volume 11 Number 10 April 6, 2023

### EVIDENCE REVIEW

- 2123** Fractional flow reserve and non-hyperemic indices: Essential tools for percutaneous coronary interventions  
*Boutaleb AM, Ghafari C, Ungureanu C, Carlier S*

### REVIEW

- 2140** Diagnosis, treatment protocols, and outcomes of liver transplant recipients infected with COVID-19  
*Hashem M, El-Kassas M*

### MINIREVIEWS

- 2160** Treatment of stellate ganglion block in diseases: Its role and application prospect  
*Deng JJ, Zhang CL, Liu DW, Huang T, Xu J, Liu QY, Zhang YN*
- 2168** Clinical application of SARS-CoV-2 antibody detection and monoclonal antibody therapies against COVID-19  
*Sun J, Yang ZD, Xie X, Li L, Zeng HS, Gong B, Xu JQ, Wu JH, Qu BB, Song GW*
- 2181** Cheesy material on macroscopic on-site evaluation after endoscopic ultrasound-guided fine-needle biopsy: Don't miss the tuberculosis  
*Delsa H, Bellahammou K, Okasha HH, Ghalim F*
- 2189** Liver manifestations in COVID-19 patients: A review article  
*Helou M, Nasr J, El Osta N, Jabbour E, Husni R*
- 2201** Breast reconstruction: Review of current autologous and implant-based techniques and long-term oncologic outcome  
*Malekpour M, Malekpour F, Wang HTH*
- 2213** Update on the current management of persistent and recurrent primary hyperparathyroidism after parathyroidectomy  
*Pavlidis ET, Pavlidis TE*

### ORIGINAL ARTICLE

#### Retrospective Study

- 2226** Hepatobiliary system and intestinal injury in new coronavirus infection (COVID-19): A retrospective study  
*Kozlov KV, Zhdanov KV, Ratnikova AK, Ratnikov VA, Tishkov AV, Grinevich V, Kravchuk YA, Miklush PI, Nikiforova PO, Gordienko VV, Popov AF, Andryukov BG*
- 2237** Impact of lockdown policies during the COVID-19 outbreak on a trauma center of a tertiary hospital in China  
*Shen BS, Cheng WY, Liang ZR, Tang Q, Li KY*

**Observational Study**

- 2246** Interaction between the left ventricular ejection fraction and left ventricular strain and its relationship with coronary stenosis  
*Gui HY, Liu SW, Zhu DF*

**CASE REPORT**

- 2254** Neonatal hyperinsulinism with an *ABCC8* mutation: A case report  
*Liu MT, Yang HX*
- 2260** Unilateral contrast-induced encephalopathy with contrast medium exudation: A case report  
*Zhang ZY, Lv H, Wang PJ, Zhao DY, Zhang LY, Wang JY, Hao JH*
- 2267** Diagnosis and treatment of primary seminoma of the prostate: A case report and review of literature  
*Cao ZL, Lian BJ, Chen WY, Fang XD, Jin HY, Zhang K, Qi XP*
- 2276** Primary intra-abdominal paraganglioma: A case report  
*Guo W, Li WW, Chen MJ, Hu LY, Wang XG*
- 2282** Successful surgical treatment of bronchopleural fistula caused by severe pulmonary tuberculosis: A case report and review of literature  
*Shen L, Jiang YH, Dai XY*
- 2290** Clinical and genetic features of Kenny-Caffey syndrome type 2 with multiple electrolyte disturbances: A case report  
*Yuan N, Lu L, Xing XP, Wang O, Jiang Y, Wu J, He MH, Wang XJ, Cao LW*
- 2301** Dupilumab for treatment of severe atopic dermatitis accompanied by lichenoid amyloidosis in adults: Two case reports  
*Zhao XQ, Zhu WJ, Mou Y, Xu M, Xia JX*
- 2308** Reabsorption of intervertebral disc prolapse after conservative treatment with traditional Chinese medicine: A case report  
*Wang CA, Zhao HF, Ju J, Kong L, Sun CJ, Zheng YK, Zhang F, Hou GJ, Guo CC, Cao SN, Wang DD, Shi B*
- 2315** Development of subdural empyema from subdural effusion after suppurative encephalitis: A case report  
*Yang RX, Chen B, Zhang Y, Yang Y, Xie S, He L, Shi J*
- 2321** Treatment of periprosthetic knee infection and coexistent periprosthetic fracture: A case report and literature review  
*Hao LJ, Wen PF, Zhang YM, Song W, Chen J, Ma T*
- 2329** Formation of a rare curve-shaped thoracolith documented on serial chest computed tomography images: A case report  
*Hsu FC, Huang TW, Pu TW*
- 2336** Neurofibromatosis type 1 with multiple gastrointestinal stromal tumors: A case report  
*Yao MQ, Jiang YP, Yi BH, Yang Y, Sun DZ, Fan JX*

- 2343** Coexisting cytomegalovirus colitis in an immunocompetent patient with *Clostridioides difficile* colitis: A case report  
*Kim JH, Kim HS, Jeong HW*
- 2349** Paradoxical vocal fold motion masquerading as post-anesthetic respiratory distress: A case report  
*Baek J, Jee DL, Choi YS, Kim SW, Choi EK*
- 2355** Full neurological recovery from severe nonexertional heat stroke with multiple organ dysfunction: A case report  
*Du F, Zheng JW, Zhao YB, Yang K, Li HN*

**ABOUT COVER**

Editorial Board Member of *World Journal of Clinical Cases*, Abdullah Gul, MD, PhD, Associate Professor, Department of Urology, University of Health Sciences Turkey, Bursa Yuksek Ihtisas Training and Research Hospital, Bursa 16310, Turkey. dr\_abdullahgul@hotmail.com

**AIMS AND SCOPE**

The primary aim of *World Journal of Clinical Cases (WJCC, World J Clin Cases)* is to provide scholars and readers from various fields of clinical medicine with a platform to publish high-quality clinical research articles and communicate their research findings online.

*WJCC* mainly publishes articles reporting research results and findings obtained in the field of clinical medicine and covering a wide range of topics, including case control studies, retrospective cohort studies, retrospective studies, clinical trials studies, observational studies, prospective studies, randomized controlled trials, randomized clinical trials, systematic reviews, meta-analysis, and case reports.

**INDEXING/ABSTRACTING**

The *WJCC* is now abstracted and indexed in Science Citation Index Expanded (SCIE, also known as SciSearch®), Journal Citation Reports/Science Edition, Current Contents®/Clinical Medicine, PubMed, PubMed Central, Scopus, Reference Citation Analysis, China National Knowledge Infrastructure, China Science and Technology Journal Database, and Superstar Journals Database. The 2022 Edition of Journal Citation Reports® cites the 2021 impact factor (IF) for *WJCC* as 1.534; IF without journal self cites: 1.491; 5-year IF: 1.599; Journal Citation Indicator: 0.28; Ranking: 135 among 172 journals in medicine, general and internal; and Quartile category: Q4. The *WJCC*'s CiteScore for 2021 is 1.2 and Scopus CiteScore rank 2021: General Medicine is 443/826.

**RESPONSIBLE EDITORS FOR THIS ISSUE**

Production Editor: *Xu Guo*; Production Department Director: *Xiang Li*; Editorial Office Director: *Jin-Lei Wang*.

**NAME OF JOURNAL**

*World Journal of Clinical Cases*

**ISSN**

ISSN 2307-8960 (online)

**LAUNCH DATE**

April 16, 2013

**FREQUENCY**

Thrice Monthly

**EDITORS-IN-CHIEF**

Bao-Gan Peng, Jerzy Tadeusz Chudek, George Kontogeorgos, Maurizio Serati, Ja Hyeon Ku

**EDITORIAL BOARD MEMBERS**

<https://www.wjgnet.com/2307-8960/editorialboard.htm>

**PUBLICATION DATE**

April 6, 2023

**COPYRIGHT**

© 2023 Baishideng Publishing Group Inc

**INSTRUCTIONS TO AUTHORS**

<https://www.wjgnet.com/bpg/gerinfo/204>

**GUIDELINES FOR ETHICS DOCUMENTS**

<https://www.wjgnet.com/bpg/GerInfo/287>

**GUIDELINES FOR NON-NATIVE SPEAKERS OF ENGLISH**

<https://www.wjgnet.com/bpg/gerinfo/240>

**PUBLICATION ETHICS**

<https://www.wjgnet.com/bpg/GerInfo/288>

**PUBLICATION MISCONDUCT**

<https://www.wjgnet.com/bpg/gerinfo/208>

**ARTICLE PROCESSING CHARGE**

<https://www.wjgnet.com/bpg/gerinfo/242>

**STEPS FOR SUBMITTING MANUSCRIPTS**

<https://www.wjgnet.com/bpg/GerInfo/239>

**ONLINE SUBMISSION**

<https://www.f6publishing.com>



## Liver manifestations in COVID-19 patients: A review article

Mariana Helou, Janane Nasr, Nour El Osta, Elsy Jabbour, Rola Husni

**Specialty type:** Medicine, research and experimental

**Provenance and peer review:** Invited article; Externally peer reviewed.

**Peer-review model:** Single blind

**Peer-review report's scientific quality classification**

Grade A (Excellent): 0  
Grade B (Very good): B  
Grade C (Good): C, C  
Grade D (Fair): 0  
Grade E (Poor): 0

**P-Reviewer:** Al-Ani RM, Iraq; He YH, China; Omar BJ, India

**Received:** December 27, 2022

**Peer-review started:** December 27, 2022

**First decision:** January 30, 2023

**Revised:** February 9, 2023

**Accepted:** March 10, 2023

**Article in press:** March 10, 2023

**Published online:** April 6, 2023



**Mariana Helou**, Division of Emergency Medicine, Department of Internal Medicine, Lebanese American University Medical Center, Lebanese American University School of Medicine, Beirut 1102-2801, Lebanon

**Janane Nasr, Rola Husni**, Division of Infectious Diseases, Department of Internal Medicine, Lebanese American University, School of Medicine, Beirut 1102-2801, Lebanon

**Nour El Osta, Elsy Jabbour**, Division of Emergency, Department of Internal Medicine, Lebanese American University, School of Medicine, Beirut 1102-2801, Lebanon

**Corresponding author:** Rola Husni, MD, Professor, Division of Infectious Diseases, Department of Internal Medicine, Lebanese American University, School of Medicine, Zahar Street, Beirut 1102-2801, Lebanon. [roula.husni@lau.edu.lb](mailto:roula.husni@lau.edu.lb)

### Abstract

The coronavirus disease 2019 (COVID-19) initially presented as a disease that affected the lungs. Then, studies revealed that it intricately affected disparate organs in the human body, with the liver being one of the most affected organs. This review aimed to assess the association between COVID-19 and liver function, shedding light on its clinical implication. However, its exact pathophysiology remains unclear, involving many factors, such as active viral replication in the liver cells, direct cytotoxic effects of the virus on the liver or adverse reactions to viral antigens. Liver symptoms are mild-to-moderate transaminase elevation. In some patients, with underlying liver disease, more serious outcomes are observed. Thus, liver function should be meticulously considered in patients with COVID-19.

**Key Words:** COVID-19; Liver injury; Liver disease; Liver manifestations

©The Author(s) 2023. Published by Baishideng Publishing Group Inc. All rights reserved.

**Core Tip:** Coronavirus disease or coronavirus disease 2019 (COVID-19) is not only a respiratory illness but it can also affect the gastrointestinal system particularly the liver. Although the exact pathophysiology is unknown, more serious outcomes are seen when there is an underlying liver disease. Meticulous attention should be given to liver function in patients with COVID-19 infection.

**Citation:** Helou M, Nasr J, El Osta N, Jabbour E, Husni R. Liver manifestations in COVID-19 patients: A review article. *World J Clin Cases* 2023; 11(10): 2189-2200

**URL:** <https://www.wjgnet.com/2307-8960/full/v11/i10/2189.htm>

**DOI:** <https://dx.doi.org/10.12998/wjcc.v11.i10.2189>

## INTRODUCTION

In December 2019, several cases of virus-induced respiratory pneumonia were reported in Wuhan, China. By March 2020, the virus severe acute respiratory syndrome coronavirus 2 (SARS-CoV-2) had already spread to other countries and infected thousands of individuals worldwide, which made the World Health Organization to declare a global pandemic. The disease initially presented with symptoms affecting the pulmonary system. Although some infected individuals could remain asymptomatic, most individuals with coronavirus disease 2019 (COVID-19) had reported fever, cough, fatigue, headache, and anosmia as the most common symptoms. However, approximately 15% of people suffered from severe COVID-19, including pneumonia with respiratory compromise, coagulopathies, strokes, multi-organ failure, and death[1]. Severe COVID-19 was most commonly reported in elderly people, men, and those with preexisting comorbidities, such as hypertension, diabetes, and coronary artery disease[2].

Studies showed that the impact of COVID-19 can extend from the pulmonary to other systems in the body and can affect disparate organs. Extrapulmonary manifestations involved cardiovascular, renal, gastrointestinal tract, reproductive, nervous, hematologic, and immune system symptoms[3]. The liver was found to be one of the affected organs following a COVID-19 infection. Several studies of liver dysfunction and elevated liver function tests such as alanine aminotransferase (ALT) and/or aspartate aminotransferase (AST) in patients without previous liver disease were reported shortly after the declaration of the COVID-19 pandemic[4]. For instance, one Chinese study demonstrated that nearly half of patients manifest liver dysfunction during their illness.

Researchers tried to investigate the possible causes of liver involvement during the COVID-19 infection. Direct hepatotoxicity resulting from the natural evolution of the disease, liver damage from the medication used for COVID-19 treatment, or the potential role of other comorbidities could be considered as factors causing liver dysfunction during the COVID-19 infection. Others reported that ongoing inflammatory processes and hypoxia following the COVID-19 infection may cause liver injury [5]. Nevertheless, the exact reasons behind liver damage remain unclear. Hence, multiple possible mechanisms contribute to these manifestations[6].

This review aimed to assess the association between SARS-CoV-2 and liver function, shedding light on its clinical implication. It also presents a perspective on the appropriate management of patients with COVID-19 with liver injury.

This narrative review was conducted following the Preferred Reporting Items for Systematic Reviews and Meta-Analyses (PRISMA) guidelines (Figure 1). Electronic databases and online sources were searched up to August 2022 using The Cochrane Library, the Reference Citation Analysis (<https://www.referencecitationanalysis.com/>) database, Medline, Embase, and Google Scholar. The following keywords were combined and used to identify relevant studies: “COVID-19” and “liver” and “liver injury” and “liver manifestations” and “liver tests.” The articles were reviewed, and duplicates were excluded. An initial scan for titles and abstracts was performed, and then, full papers were kept for assessment. We included all articles written in the English language, published within the last 2 years after the COVID-19 pandemic, and where full texts were available. We excluded gray literature and studies not written in English.

The results of the literature search are summarized in a PRISMA flowchart (Figure 1). A total of 58 manuscripts were included in this review.

## LIVER INJURY DUE TO COVID-19

COVID-19 manifestations are variable, with different clinical presentations, such as myalgia, fever, fatigue, headache, nausea vomiting, diarrhea, sore throat, nasal congestion, taste and smell abnormalities, confusion, chest pain, and abdominal pain[7].

The gastro-intestinal (GI) tract is a prominent extrapulmonary site for COVID-19 involvement. Many patients complain of GI symptoms, such as nausea, diarrhea, and abdominal pain at the early stages of COVID-19, with studies estimating that number between 10% and 15%[8]. A meta-analysis of 12797 patients from 11 countries found that diarrhea is the most common GI presentation in patients with COVID-19 (12%), followed by nausea (9%), vomiting (9%), and abdominal pain (6%)[9, 10]. In critical patients, GI symptoms tend to be more severe, ranging from ileal (55.8%) to bowel ischemia (3.8%) among other serious complications[10].



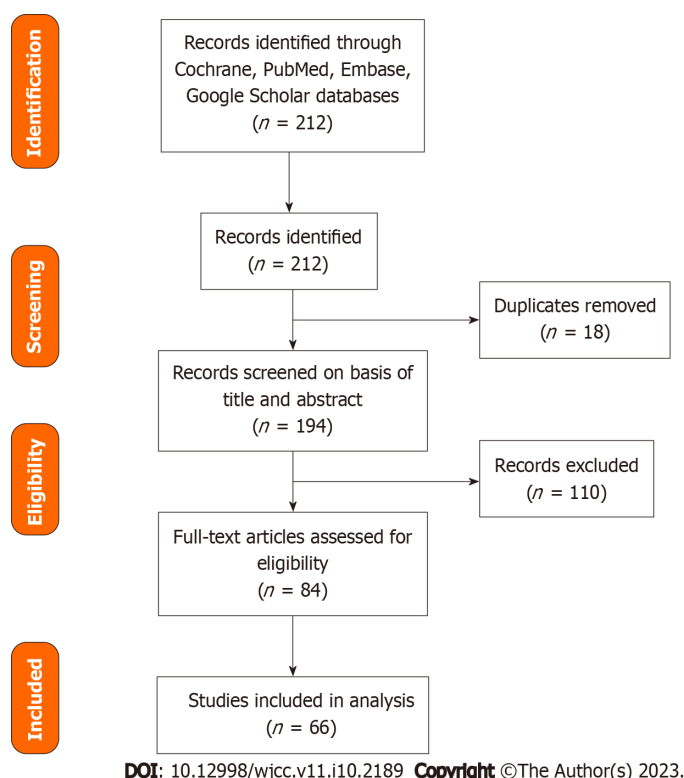


Figure 1 Prisma flowchart.

Symptoms may persist throughout the disease course and even after its finished, indicating a possible direct involvement and viral invasion of the GI tract. Stool samples of up to 50% of hospitalized patients infected with COVID-19 had the virus detectable in their stool samples, and some of them can still test positive for the viral for up to 1 wk after viral clearance from the lungs[11]. Histologically, biopsies taken from the esophagus, stomach, duodenum, and rectum of patients with COVID-19 revealed the presence of viral ribonucleic acid RNAs[8,11]. As for the liver in infected patients, a polymerase chain reaction of the liver tissue confirmed the presence of viral deoxyribonucleic acid DNAs[12-14]. COVID-19 was detected in the cytoplasm of hepatocytes, resulting in mitochondrial swelling, endoplasmic reticulum system dilatation, and cell membrane impairment[15].

The incidence rate of liver injuries in patients with COVID-19 varies greatly. An abnormal liver function was defined as an elevation of any parameter (ALT, AST, alkaline phosphatase, gamma-glutamyl transferase, and total bilirubin). Liver injury is defined as mild (< 2 times upper level of normal), moderate (2-5 times upper level of normal), and severe (> 5 times upper level of normal)[16, 17]. Studies found that liver injury in patients with SARS-CoV-2 infection is between 14%-53%[16,17]. In a retrospective cohort study conducted by Phipps *et al*[18] on 2273 COVID-19 patients in the United States, 45% had mild, 21% had moderate, and 6.4% had a severe liver injury[18]. The severity of liver injury was significantly associated with the severity of the COVID-19 disease[19]. Moderate and severe liver injury was found to be more common in patients who required admission to the Intensive Care Unit[18]. However, even asymptomatic infected patients with COVID-19 have the same viral load, and consequently, liver damage can happen with elevation of liver enzymes, but to a lesser extended than the severe symptomatic patients[19]. Liver injury is more common in patients with high viral load. Thus, the risk of initial liver injury may be increased in patients infected with Delta mutations and having relatively large viral loads[19]. A study by Deng *et al*[20] compared liver injury in patients with Delta and Omicron variant-infected patients. The extended of inflammation and liver injury was similar among the two groups. However, male gender and high peak viral load were independent factors associated with liver injury[20]. A study conducted in young children with COVID-19 and liver injury showed that these patients have a milder course with less radiological and laboratory changes compared to adults[21].

A Chinese study of 1100 patients reported that AST and ALT levels were elevated in 18% and 20% of patients with non-severe COVID-19, as compared with 56% and 28% of patients with severe COVID-19, respectively, which can promote AST and ALT elevation of reaching up to 7590 and 1445 U/L, respectively, in some severe cases[22,23]. In patients with fatal COVID-19, the incidence of liver damage could range between 58.06% and 78%[24]. ALT elevation tends to peak between days 4 and 17 of hospitalization[25,26]. Other symptoms of liver dysfunction are hypoalbuminemia, increased prothrombin time, elevated serum bilirubin levels, hypoglycemia, and hyperammonemia[16].



Table 1 summarizes the different types of liver injury seen in COVID-19 patient[22-24,27-35].

## **PATHOPHYSIOLOGY**

The pathophysiology of COVID-19's impact on the liver remains unclear. Several potential theories could explain the COVID-19 method affecting the liver.

One theory is that COVID-19 might contribute to liver damage through active viral replication in liver cells. A suggested mechanism for direct injury is hepatocytes apoptosis. This happens through viral proteins in specific protein 7a that can trigger cellular apoptosis in the liver but also in different organs, such as the lungs and kidneys. This cellular destruction is described by Tan *et al*[25]. Another possible entry of the virus is through receptors. Three receptors are the most commonly involved in this: Transmembrane serine protease 2 (TMPRSS2), Furin, and angiotensin converting enzyme 2 (ACE2) proteins. ACE2 receptors are present abundantly in the liver and the gastrointestinal mucosa. The virus binds to ACE2 receptors, abundantly present in the liver cells and GI mucosa[26]. The COVID-19 was detected inside the cytoplasm of the hepatocytes, leading to dilatation of the endoplasmic reticulum system, mitochondrial swelling, and cell membrane impairment. These receptors are more prevalent in the bile duct cells (53%) than in the liver cells (2.6%)[36,37]. Liver dysfunction can happen through bile duct damage more than a direct cytotoxic effect of the virus on the liver[26]. However, even though the ACE2 receptors are more commonly present in cholangiocytes than hepatocytes, a cholestatic pattern is less likely observed, and serum aminotransferase elevation is usually the common presentation. A possible reason for this is that other contributing factors are in cause and can raise the serum aminotransferase levels in liver injury. As example, a study discusses the possibility of the presence of co-receptors on the liver or an increase of the ACE2 receptors on liver cell surfaces[15]. This could explain the damage detected in the livers of patients with COVID-19, who showed signs of microvascular steatosis on post-mortem biopsies[38].

Another pathway for viral entry is TMPRSS2 found on hepatocytes, cholangiocytes, erythroid cells, and sinusoidal endothelial cells in the liver. Furin is another transmembrane serine protease that is present in all cell types[14,15,39]. Viral receptors expression on cell membranes is dynamic, upregulated by viral entry or even preexisting liver diseases[40].

Liver damage could also be caused by the adverse reactions to viral antigens. Respiratory viruses such the influenza virus, parvovirus, and respiratory syncytial virus bronchiolitis can all induce liver dysfunction with mild elevation of the liver enzyme levels to acute liver failure[16]. SARS-CoV-2 is speculated to affect the liver by SARS-CoV-2 viral antigens, in the form of nucleocapsids and spike proteins[12].

Immune dysregulation caused by COVID-19 plays a role in liver damage. COVID-19 leads to an inflammation in the lungs with elevation in serum inflammatory markers and production of pro-inflammatory cytokines, such as tumor necrosis factors (TNF- $\alpha$ ), procalcitonin, C-reactive protein (CRP) and interleukins (IL-1, IL-2, IL-6, IL-8, IL-10, IL-17). Interferons are released, initiating a cascade that induces the expression of genes responsible for antiviral activity and viral replication disruption[41]. However, the consequence of rapid viral proliferation is a generalized inflammatory reaction with elevated inflammatory markers[26,42,43]. This can indirectly contribute to liver damage[26,42,43]. Research conducted on severe cases of COVID-19 have demonstrated the involvement of granulocyte-colony stimulating factor, TNF- $\alpha$ , interferon-inducible protein-10, monocyte chemotactic protein 1, and macrophage inflammatory protein 1 alpha, T helper 17, CD8 T cells, and IL-2, IL-6, IL-7, IL-10 in the immune response[44]. Moreover, inflammatory reaction and activation of the coagulation cascade resulting in a pro-thrombotic state in the blood can disrupt the gut vascular barrier and exacerbate liver injury[45].

Hypoxemia can also be a cause of liver injury. Cases of severe COVID-19 generally ends in sepsis state particularly when patients have gut microbiota imbalance and pre-existing liver disease[44]. Hepatic damage post sepsis is usually associated with shock, cholestasis, drug toxicity, and inflammation[44]. Severe infection with hemodynamic instability and shock compromises blood supply to vital organs, including the liver. The result is hypoxic ischemia of the liver, characterized by centrilobular hepatocellular necrosis that can progress to irreversible hypoxic injury[16]. Hypoxemia is one cause of liver injury with bad prognosis[44]. Recent data shows that hypoxic liver injury in COVID-19 patients is caused by metabolic acidosis with calcium overloading and abnormality in the mitochondrial permeability transition pore protein[44].

Hepatotoxic drugs are a common cause of liver injury in COVID-19 patients. Combinations of antiviral, steroid, and antibiotic drugs were all used to decrease symptom severity and prevent potentially fatal complications. Since most of these drugs were metabolized in the liver, medications used for the treatment of COVID-19 can induce liver dysfunction[46]. The rate of drug-induced liver injury was found to be approximately 25% in a meta-analysis of 20874 patients with COVID-19[47,48]. Remdesivir, tocilizumab, lopinavir/ritonavir, ribavirin, hydroxychloroquine, steroids, and macrolides, all used for the treatment of COVID-19, can cause hepatotoxicity[49].

Antiviral treatments for COVID-19 are prescribed to approximately 50% of critical patients, and these drugs cause hepatotoxicity. Evidence suggests that the use of lopinavir or ritonavir can contribute to

**Table 1 Liver injury in coronavirus disease 2019 patients in different trials**

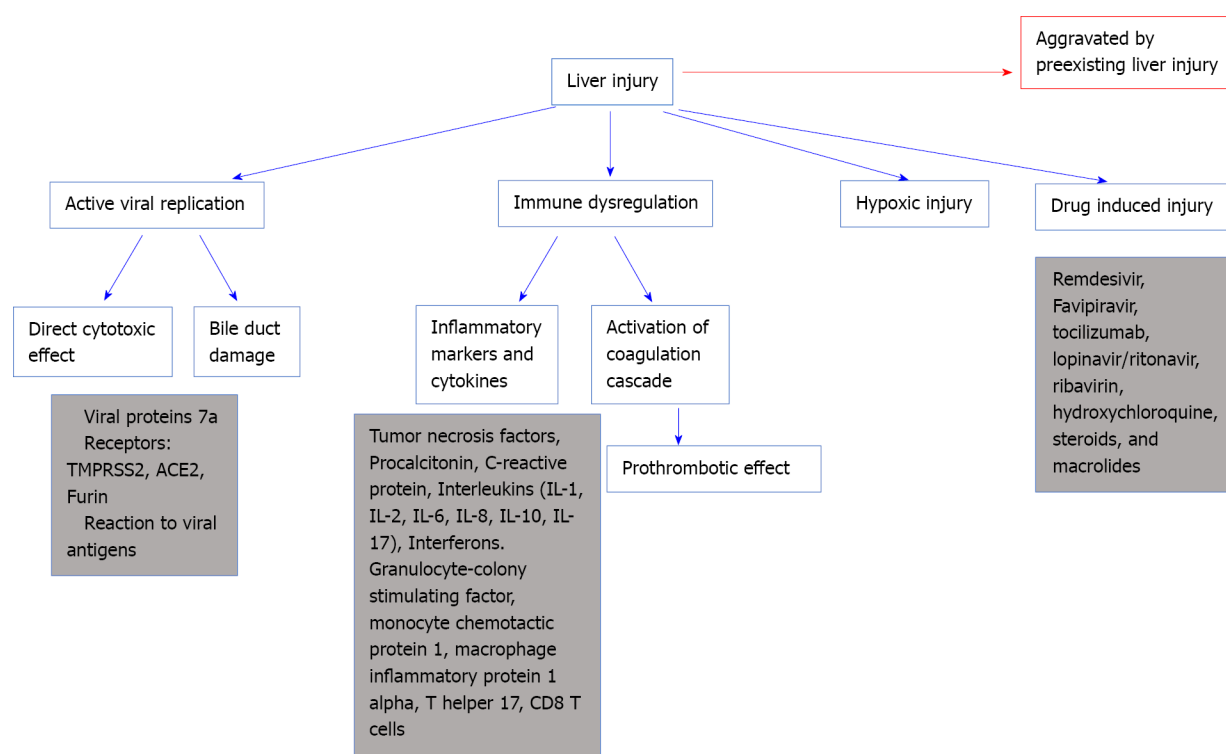
| Ref.                    | Number of patients infected with COVID-19 | Patients with liver injury (percentage) | Patients with preexisting liver damage (percentage) | Elevated indicators  | Mortality   |
|-------------------------|---|---|---|--|---|
| Chen <i>et al</i> [23]  | 99  | 43 (43.4)                               | -   | 43 patients had differing degrees of liver function abnormality. Prothrombin time increased by 5%, one patient had severe liver function damage (ALT: 7590 U/L, AST: 1445 U/L) | 11% (day 24)  |
| Wang <i>et al</i> [27]  | 69  | 42 (60.9)                               | 1 (1)   | Abnormal ALT: 33%; abnormal AST: 28%   | 7.5% (day 19)   |
| Cai <i>et al</i> [28]   | 298                                       | 44 (14.8)                               | 8 (2.7)   | Abnormal ALT: 13.1%; abnormal AST: 8.4%  | 1% (day 55)   |
| Zhang <i>et al</i> [29] | 82 death cases                            | 64 (78.0)                               | 2 (2.4)   | Abnormal ALT: 30.6%; abnormal AST: 61.1%; abnormal total bilirubin 30.6%   | ALT (> 40 U/L), AST (> 40 U/L), and TBIL (> 20.5 mmol/L) increased in 30.6%, 61.1%, and 30.6% cases |
| Wang <i>et al</i> [30]  | 138                                       | 55 (39.9)                               | 4 (29)  | Abnormal ALT: 17.4%; abnormal AST: 22.5%   | 4.3% (day 33)   |
| Li <i>et al</i> [31]    | 85  | 33 (38.8)                               | 6 (7)   | Abnormal ALT: 38.8%  | -   |
| Yang <i>et al</i> [32]  | 52  | 15 (28.9)                               | 15 (29)   | -  | 62% (day 28)  |
| Fan <i>et al</i> [33]   | 148                                       | 75 (50.7)                               | 6 (8)   | Abnormal ALT: 18.2%; abnormal AST: 21.6%   | 0.67% (day 11)  |
| Huang <i>et al</i> [24] | 41  | 15 (36.6)                               | 1 (2)   | Abnormal AST: 37%  | 15% (day 17)  |
| Guan <i>et al</i> [22]  | 67  | 22 (32)                                 | Hepatitis B: 2.1%                                   | Abnormal ALT: 21.3%; abnormal AST: 22.2%   | 22% (day 51)  |
| Shi <i>et al</i> [34]   | 81  | 42 (53)                                 | Hepatitis or liver cirrhosis in 9% of cases         | Abnormal AST: 53%  | 5% (day 50)   |
| Xu <i>et al</i> [35]    | 62  | 4 (12)                                  | 7 (11)  | Levels of AST increased in 10 (16%) patients   | 0% (day 34)   |

COVID-19: Coronavirus disease 2019; AST: Aspartate aminotransferase; ALT: Alanine aminotransferase; TBIL: Total bilirubin.

liver injury in patients with COVID-19, as those with liver injury were found to have higher usage rates of these medications compared with those with normal livers[33]. Patients treated with lopinavir/ritonavir show commonly liver damage, and liver injury is 3.58 times greater in patients receiving treatment compared with patients who did not receive treatment[50]. Liver damage is increased by 12.1% after drug treatment[50]. Ribavirin-induced hemolysis could exacerbate tissue hypoxia and further liver ischemia and injury. The National Health Commission of the People's Republic of China had to stipulate that treatment for long term with these drugs, especially in high doses, can lead to hepatotoxicity[26]. Remdesivir was approved in May 2020 for the treatment of COVID-19. Remdesivir is metabolized by Cytochromes P450. The treatment with remdesivir reduces the hospitalization time for COVID-19 patients and accelerates recovery[44]. In COVID-19 patients treated by remdesivir, reversible elevations of ALT and AST were found with 6% of patients having a marked increase in AST and ALT while only 2% having a life-threatening situation[44].

Chinese drugs used by individuals to treat their infections may also induce liver injury[7]. Further, many patients infected with COVID-19 firstly present with fever, cough, and fatigue; and many of them self-medicate using antipyretics, such as acetaminophen, a known hepatotoxic medication. Moreover, herbal products, used for cough or pain, may have a deleterious effect on liver function[7]. Patients with preexisting liver diseases or chronic hepatitis are more susceptible to drug-induced liver damage, and thereby, special consideration must be given before prescribing any drug[7].

Figure 2 shows different mechanisms of liver injury in COVID-19.



DOI: 10.12998/wjcc.v11.i10.2189 Copyright ©The Author(s) 2023.

**Figure 2 Mechanisms of liver injury from coronavirus disease 2019 infection.** IL: Interleukin; ACE2: Angiotensin converting enzyme 2; TMPRSS2: Transmembrane serine protease 2.

## COVID-19 IN PATIENTS WITH CHRONIC LIVER DISEASE

Early evidence denied the likelihood of increased risk of COVID-19 infection in patients with chronic yet well-managed hepatitis B or C. However, COVID-19 could still affect liver function in these patients through hepatic decompensation of the already depleted hepatic reserves, and reactivation of hepatitis viral replication following the immunocompromised state that SARS-CoV-2 induces in these patients [51]. Furthermore, patients with preexisting liver diseases tend to have co-existing comorbidities, such as diabetes, hypertension, and cardiovascular disease that also confer higher chances of severe diseases to these patients. To date, no studies confirmed that patients with liver disorders are at increased risk of being infected; however, these patients may have other risk factors that may complicate the course of infection, making it more severe, such as diabetes, anemia, and cardiovascular disorders [49].

Chen *et al* [52] found that chronic hepatitis B patients are more prone to COVID-19 infection [52]; however, other studies showed that chronic viral hepatitis is not proportional to the severity of COVID-19 infection [22,53]. Regarding viral hepatitis treatment in patients co-infected with COVID-19, the American Association for the Study of Liver Diseases (AASLD) recommends to continue the treatment for hepatitis B and C if already started before the COVID-19 infection and considers initiating hepatitis B treatment in patients suspected of hepatitis B flare; however, studies are still lacking. Starting the treatment for hepatitis C in a patient with COVID-19 is not yet routinely warranted.

## COVID-19 AND NONALCOHOLIC STEATOHEPATITIS

Nonalcoholic fatty liver disease (NAFLD) was found to be associated with a more severe COVID-19 disease course and protracted viral shedding time [54]. Patients with NAFLD had a higher probability of disease progression and higher risk of elevating liver tests upon admission to discharge [47]. This could be caused by hepatic macrophage dysfunction and imbalance between M1 macrophages, promoters of inflammation and M2 macrophages, suppressors of inflammation observed in patients with NAFLD and by excessive production of cytokines, such as TNF- $\alpha$  by the adipose and Kupffer cells [38,54].

Obesity was found to increase mortality risks in patients with COVID-19 and was associated with a higher likelihood of needing invasive ventilation. ACE2 receptors are predominantly found in the adipose tissues, which might facilitate COVID-19 invasion in the fat tissues. Patients with nonalcoholic steatohepatitis (NASH) generally have disrupted inflammatory mechanisms, making them more vulnerable. Thus, close monitoring is advisable in these patients. These deleterious effects are

compounded when considering that obese patients are also highly at higher risk for NASH[6].

Some studies reportedly undermined NAFLD's role in COVID-19-associated liver damage. A series of 155 patients hospitalized for COVID-19 infection showed that steatosis (present in 43% of the cases) was not associated with mortality[55]. A larger study conducted on 745 patients from 29 countries having chronic liver disease and cirrhosis found that the odds ratio for death in patients with NAFLD was 1.01 (95% confidence interval: 0.57-1.79)[56].

Mushtaq *et al*[57] studied 589 symptomatic COVID-19 patients with who were hospitalized in the state of Qatar. They found that NAFLD predicts mild to moderate liver injury while it does not predicts mortality, disease severity or disease progression[57].

These inconsistent findings require more, larger studies to assess the presence of increased mortality risk in patients with NAFLD and NASH infected with COVID-19.

## COVID-19 AND PREEXISTING CHRONIC LIVER DISEASE

Patients with chronic liver disease and cirrhosis would be more prone to COVID-19 induced liver injury than those without preexisting liver damage. A meta-analysis of 5595 patients infected with COVID-19 showed that 3% of patients with preexisting liver disease had higher rates of severe complications (57.335) and mortality (17.65%) than those without the chronic liver disease[58].

Patients with cirrhosis are known to be a high-risk population and prone to higher rates of mortality when infected with COVID-19[59]. In a national registry study, Marjot *et al*[56] found that patients with cirrhosis had a mortality rate of 32% while patients with no cirrhosis had a rate of 8%, with higher rates of liver decompensation observed in the former group[56]. Lung injury is the primary cause of death in patients with COVID-19, and liver dysfunction helps exacerbate this injury[60]. Cirrhosis have been associated with inflammation and dysregulation of the immune system. This dysregulation may explain the increased severity and mortality due to COVID-19. Additionally, in cirrhosis, coagulation disorders, cirrhotic decompensation, cytokine release, and exacerbation of ascites or encephalopathy all strain the already depleted liver reserves and increase mortality rates[59].

Studies on the impact of COVID-19 on patients with alcohol-associated liver disease (ALD) are limited[39]. Nevertheless, data show that patients with COVID-19 and alcohol-related cirrhosis also exhibited increased mortality, a finding consistent with other patients with liver cirrhosis[61]. Kim *et al* [62] supported these findings through their study of 867 patients with chronic liver disease having a COVID-19 infection, demonstrating that patients with ALD had an increased risk of poor survival and higher risk of mortality rate[62]. ALD is associated with danger-associated molecular patterns that induce an inflammatory state with cytokine release[63]. In patients with ALD, the superimposed cytokine storm caused by COVID-19 could increase the inflammatory process and results in worse outcomes[39].

Hepatocellular carcinoma (HCC) and COVID-19 infection are also associated with poor outcomes. Chinese patients with underlying malignancies infected with COVID-19 were found to have higher odds of being infected with SARS-CoV-2 and progressing to more severe disease forms. As in any other malignancy, HCC is associated with poor immunity and hypoproteinemia, in addition to chemotherapy that promotes further immunosuppression, leading to the recommendation of deferring locoregional treatments wherever possible and gradually phasing out immunological anticancer therapies when at risk of COVID-19 disease[64].

## PATIENTS WHO UNDERWENT A LIVER TRANSPLANT

Many centers for liver transplantation had to cut down their procedures because of the COVID-19 crisis. Yet, current evidence suggests that liver transplant recipients who are on immunosuppressants have the same fatality rate as the rest of the population[39].

Management of liver transplant recipients infected with COVID-19 is challenging because of drug-drug interactions and the right immunosuppressant levels. Current evidence supports continuing immunosuppressive treatment in liver transplant recipients and preventing dose reduction. It remains unclear whether steroids help liver transplant patients with COVID-19, as it was proven to help hospitalized COVID-19 patients[56].

The benefit of vaccination should be heightened in patients with chronic liver disease due to their imbalanced immune system, from their disease, and immunosuppressive treatment.

## TREATMENT OF LIVER DISEASE

The advancement of developing the best therapy for COVID-19 evolves at a high pace. Yet, little is known about the ideal treatment for liver injury. AASLD recommends continuing treatment of viral

hepatitis in patients with co-infection with COVID-19 and prevention of hepatitis flare. If steroids are to be prescribed, the risk of hepatitis flare should be evaluated. Most liver damages caused by COVID-19 infection are temporary and rarely result in liver failure. However, when severe liver dysfunction increases, prompt assessment, and screening for underlying diseases and previous history of liver diseases are warranted. Exposure to hepatotoxic agents such as alcohol and drug chemicals should be examined, as should the circulation and ventilation statuses of the patient.

Liver function tests should be routinely measured to preclude further liver damage. Furthermore, other etiologies for liver injury should be considered. If AST and lactate dehydrogenase are elevated but ALT levels are normal, the skeletal muscle or cardiac origin of elevation should be considered. L-ornithine-L-aspartate could be effective in hepatic encephalopathy with elevated ammonia levels[44]. However this is only used as a complimentary treatment. Probiotics can also be considered, they restore gut microbiota dysbiosis and prevent any infections. Ursodeoxycholic acid 500 mg/d protect hepatic function from injury due to its anti-inflammatory and immunomodulating activities. Nevertheless, further studies are needed to confirm this benefit[5,44]. N-acetylcysteine could be used in COVID-19 patients, it causes obvious drop in inflammatory markers in particular CRP and ferritin levels. In addition, NAC blocked hemolysis and liver enzyme elevation. Further studies for this treatment are needed[44].

The treatment of COVID-19-induced liver injury is dependent on the severity of the damage and the identification and treatment of underlying causes if present. Patients with mildly elevated liver enzymes do not need hepatoprotective drugs. Patients with severe liver dysfunction require treatment with hepatoprotective, jaundice-reducing, and anti-inflammatory drugs, such as polyene phosphatidylcholine, glycylic acid, bicyclol, and vitamin E. In critically ill patients, special consideration should be taken for the extent of liver injury and the number of medications used. This minimizes the risk of drug-drug interactions and eschews the risk of aggravating the liver injury by selecting an antiviral drug with minimal hepatotoxicity. One group of antivirals could be glycyrrhizic acid derivatives as shown by[65]. Glycyrrhizin has been used for several years as an anti-inflammatory of choice for liver disease protection.

Inconsistent findings have been reported in the literature on whether anticoagulation increases the risk of bleeding in cirrhotic patients with COVID-19 since they are excluded from the majority of published studies related to thromboprophylaxis. However, an Italian multicenter study conducted on 40 patients reassured no increased hemorrhagic risk among cirrhotic patients admitted with COVID-19.

Effects of the COVID-19 vaccine on specific organs, such as the liver and GI tract remain unknown. Further study is required to evaluate the long-term effects of the vaccine based on the GI tract.

## PROGNOSIS

Liver injury in patients with mild COVID-19 is usually transient and does not require treatment. Liver failure is also rarely reported.

Despite using elevated serum aminotransferases as indicators of liver injury during COVID-19 infection, a direct correlation between elevated liver enzymes and COVID-19 severity could not be demonstrated. However, patients with severe COVID-19 disease tend to have more elevated liver function tests than those with mild disease. After recovery, liver enzymes gradually return to their normal levels. Further noteworthy consequences of COVID-19-induced liver injury, especially for elderly individuals, include the activation of fibrinolytic and clotting pathways and innate immune system dysregulation.

The prognostic correlation with elevated liver enzymes remains debatable. No evidence showed that higher liver enzymes are associated with higher mortality risk. Age, associated comorbidities, and preexisting alcohol-related liver disease are the main risk factors for poor outcomes[66].

Fan *et al*[33] concluded in their trial on 148 hospitalized patients that abnormal liver functions are associated with prolonged hospitalization[33].

Comparable results were drawn from other studies. Wang *et al*[27] also concluded that the male sex predisposes to more liver damage[27].

## CONCLUSION

Despite the lack of evidence to elucidate the mechanisms of liver injury induced by COVID-19 infection, this review provides a comprehensive approach to several theories investigated. Further research is needed to clarify the factors in cause and determine factors that might exacerbate liver injury in COVID-19 infected patients. Meticulous attention should be kept on the liver of patients with COVID-19 infection, especially during hospitalization. It is not clear yet on how to treat liver damage in patients with COVID-19 infection. There are no clear guidelines for proper treatment of liver injury in COVID-19 patients. Comparative studies might be needed for better evidence.



## FOOTNOTES

**Author contributions:** Authors have contributed equally in the writing; All authors had full access to all of the data in the study and can take responsibility for the integrity and accuracy of the data.

**Conflict-of-interest statement:** All the authors report no relevant conflicts of interest for this article.

**Open-Access:** This article is an open-access article that was selected by an in-house editor and fully peer-reviewed by external reviewers. It is distributed in accordance with the Creative Commons Attribution NonCommercial (CC BY-NC 4.0) license, which permits others to distribute, remix, adapt, build upon this work non-commercially, and license their derivative works on different terms, provided the original work is properly cited and the use is non-commercial. See: <https://creativecommons.org/Licenses/by-nc/4.0/>

**Country/Territory of origin:** Lebanon

**ORCID number:** Mariana Helou 0000-0001-8626-8988; Rola Husni 0000-0001-5892-7608.

**S-Editor:** Fan JR

**L-Editor:** A

**P-Editor:** Fan JR

## REFERENCES

- Berlin DA, Gulick RM, Martinez FJ. Severe Covid-19. *N Engl J Med* 2020; **383**: 2451-2460 [PMID: 32412710 DOI: 10.1056/NEJMc2009575]
- Williamson EJ, Walker AJ, Bhaskaran K, Bacon S, Bates C, Morton CE, Curtis HJ, Mehrkar A, Evans D, Inglesby P, Cockburn J, McDonald HI, MacKenna B, Tomlinson L, Douglas IJ, Rentsch CT, Mathur R, Wong AYS, Grieve R, Harrison D, Forbes H, Schultze A, Croker R, Parry J, Hester F, Harper S, Perera R, Evans SJW, Smeeth L, Goldacre B. Factors associated with COVID-19-related death using OpenSAFELY. *Nature* 2020; **584**: 430-436 [PMID: 32640463 DOI: 10.1038/s41586-020-2521-4]
- Zheng KI, Feng G, Liu WY, Targher G, Byrne CD, Zheng MH. Extrapulmonary complications of COVID-19: A multisystem disease? *J Med Virol* 2021; **93**: 323-335 [PMID: 32648973 DOI: 10.1002/jmv.26294]
- Cai Q, Huang D, Yu H, Zhu Z, Xia Z, Su Y, Li Z, Zhou G, Gou J, Qu J, Sun Y, Liu Y, He Q, Chen J, Liu L, Xu L. COVID-19: Abnormal liver function tests. *J Hepatol* 2020; **73**: 566-574 [PMID: 32298767 DOI: 10.1016/j.jhep.2020.04.006]
- Cichoż-Lach H, Michalak A. Liver injury in the era of COVID-19. *World J Gastroenterol* 2021; **27**: 377-390 [PMID: 33584070 DOI: 10.3748/wjg.v27.i5.377]
- Metawea MI, Yousif WI, Moheb I. COVID 19 and liver: An A-Z literature review. *Dig Liver Dis* 2021; **53**: 146-152 [PMID: 32988758 DOI: 10.1016/j.dld.2020.09.010]
- Yang RX, Zheng RD, Fan JG. Etiology and management of liver injury in patients with COVID-19. *World J Gastroenterol* 2020; **26**: 4753-4762 [PMID: 32921955 DOI: 10.3748/wjg.v26.i32.4753]
- Lin L, Jiang X, Zhang Z, Huang S, Fang Z, Gu Z, Gao L, Shi H, Mai L, Liu Y, Lin X, Lai R, Yan Z, Li X, Shan H. Gastrointestinal symptoms of 95 cases with SARS-CoV-2 infection. *Gut* 2020; **69**: 997-1001 [PMID: 32241899 DOI: 10.1136/gutjnl-2020-321013]
- Tariq R, Saha S, Furqan F, Hassett L, Pardi D, Khanna S. Prevalence and Mortality of COVID-19 Patients With Gastrointestinal Symptoms: A Systematic Review and Meta-analysis. *Mayo Clin Proc* 2020; **95**: 1632-1648 [PMID: 32753138 DOI: 10.1016/j.mayocp.2020.06.003]
- Bhurwal A, Minacapelli CD, Orosz E, Gupta K, Tait C, Dalal I, Zhang C, Zhao E, Rustgi VK. COVID-19 status quo: Emphasis on gastrointestinal and liver manifestations. *World J Gastroenterol* 2021; **27**: 7969-7981 [PMID: 35046624 DOI: 10.3748/wjg.v27.i46.7969]
- Xiao F, Tang M, Zheng X, Liu Y, Li X, Shan H. Evidence for Gastrointestinal Infection of SARS-CoV-2. *Gastroenterology* 2020; **158**: 1831-1833.e3 [PMID: 32142773 DOI: 10.1053/j.gastro.2020.02.055]
- Cheung CCL, Goh D, Lim X, Tien TZ, Lim JCT, Lee JN, Tan B, Tay ZEA, Wan WY, Chen EX, Nerurkar SN, Loong S, Cheow PC, Chan CY, Koh YX, Tan TT, Kalimuddin S, Tai WMD, Ng JL, Low JG, Yeong J, Lim KH. Residual SARS-CoV-2 viral antigens detected in GI and hepatic tissues from five recovered patients with COVID-19. *Gut* 2022; **71**: 226-229 [PMID: 34083386 DOI: 10.1136/gutjnl-2021-324280]
- Tian D, Ye Q. Hepatic complications of COVID-19 and its treatment. *J Med Virol* 2020; **92**: 1818-1824 [PMID: 32437004 DOI: 10.1002/jmv.26036]
- Song M, Li ZL, Zhou YJ, Tian G, Ye T, Zeng ZR, Deng J, Wan H, Li Q, Liu JB. Gastrointestinal involvement of COVID-19 and potential faecal transmission of SARS-CoV-2. *J Zhejiang Univ Sci B* 2020; **21**: 749-751 [PMID: 32893532 DOI: 10.1631/jzus.B2000253]
- Wang Y, Liu S, Liu H, Li W, Lin F, Jiang L, Li X, Xu P, Zhang L, Zhao L, Cao Y, Kang J, Yang J, Li L, Liu X, Li Y, Nie R, Mu J, Lu F, Zhao S, Lu J, Zhao J. SARS-CoV-2 infection of the liver directly contributes to hepatic impairment in patients with COVID-19. *J Hepatol* 2020; **73**: 807-816 [PMID: 32437830 DOI: 10.1016/j.jhep.2020.05.002]
- Vargas-Mendoza N, García-Machorro J, Angeles-Valencia M, Martínez-Archundia M, Madrigal-Santillán EO, Morales-González Á, Anguiano-Robledo L, Morales-González JA. Liver disorders in COVID-19, nutritional approaches and the use of phytochemicals. *World J Gastroenterol* 2021; **27**: 5630-5665 [PMID: 34629792 DOI: 10.3748/wjg.v27.i34.5630]

- 17 **Zhou F**, Xia J, Yuan HX, Sun Y, Zhang Y. Liver injury in COVID-19: Known and unknown. *World J Clin Cases* 2021; **9**: 4980-4989 [PMID: [34307548](#) DOI: [10.12998/wjcc.v9.i19.4980](#)]
- 18 **Phipps MM**, Barraza LH, LaSota ED, Sobieszczyk ME, Pereira MR, Zheng EX, Fox AN, Zucker J, Verna EC. Acute Liver Injury in COVID-19: Prevalence and Association with Clinical Outcomes in a Large U.S. Cohort. *Hepatology* 2020; **72**: 807-817 [PMID: [32473607](#) DOI: [10.1002/hep.31404](#)]
- 19 **Choi CW**, Sung HK, Jeong JY, Lim DH, Choi J, Kwon HC, Nam S, Kim Y, Chin B. Changing Features of Liver Injury in COVID-19 Patients: Impact of Infection with the SARS-CoV-2 Delta (B.1.617.2) Variants. *Infect Chemother* 2022; **54**: 744-756 [PMID: [36596683](#) DOI: [10.3947/ic.2022.0122](#)]
- 20 **Deng H**, Lin H, Mai Y, Liu H, Chen W. Clinical features and predictive factors related to liver injury in SARS-CoV-2 Delta and Omicron variant-infected patients. *Eur J Gastroenterol Hepatol* 2022; **34**: 933-939 [PMID: [35482929](#) DOI: [10.1097/MEG.0000000000002381](#)]
- 21 **Xu Y**, Li X, Zhu B, Liang H, Fang C, Gong Y, Guo Q, Sun X, Zhao D, Shen J, Zhang H, Liu H, Xia H, Tang J, Zhang K, Gong S. Characteristics of pediatric SARS-CoV-2 infection and potential evidence for persistent fecal viral shedding. *Nat Med* 2020; **26**: 502-505 [PMID: [32284613](#) DOI: [10.1038/s41591-020-0817-4](#)]
- 22 **Guan WJ**, Ni ZY, Hu Y, Liang WH, Ou CQ, He JX, Liu L, Shan H, Lei CL, Hui DSC, Du B, Li LJ, Zeng G, Yuen KY, Chen RC, Tang CL, Wang T, Chen PY, Xiang J, Li SY, Wang JL, Liang ZJ, Peng YX, Wei L, Liu Y, Hu YH, Peng P, Wang JM, Liu JY, Chen Z, Li G, Zheng ZJ, Qiu SQ, Luo J, Ye CJ, Zhu SY, Zhong NS; China Medical Treatment Expert Group for Covid-19. Clinical Characteristics of Coronavirus Disease 2019 in China. *N Engl J Med* 2020; **382**: 1708-1720 [PMID: [32109013](#) DOI: [10.1056/NEJMoa2002032](#)]
- 23 **Chen N**, Zhou M, Dong X, Qu J, Gong F, Han Y, Qiu Y, Wang J, Liu Y, Wei Y, Xia J, Yu T, Zhang X, Zhang L. Epidemiological and clinical characteristics of 99 cases of 2019 novel coronavirus pneumonia in Wuhan, China: a descriptive study. *Lancet* 2020; **395**: 507-513 [PMID: [32007143](#) DOI: [10.1016/S0140-6736\(20\)30211-7](#)]
- 24 **Huang C**, Wang Y, Li X, Ren L, Zhao J, Hu Y, Zhang L, Fan G, Xu J, Gu X, Cheng Z, Yu T, Xia J, Wei Y, Wu W, Xie X, Yin W, Li H, Liu M, Xiao Y, Gao H, Guo L, Xie J, Wang G, Jiang R, Gao Z, Jin Q, Wang J, Cao B. Clinical features of patients infected with 2019 novel coronavirus in Wuhan, China. *Lancet* 2020; **395**: 497-506 [PMID: [31986264](#) DOI: [10.1016/S0140-6736\(20\)30183-5](#)]
- 25 **Tan YJ**, Fielding BC, Goh PY, Shen S, Tan TH, Lim SG, Hong W. Overexpression of 7a, a protein specifically encoded by the severe acute respiratory syndrome coronavirus, induces apoptosis via a caspase-dependent pathway. *J Virol* 2004; **78**: 14043-14047 [PMID: [15564512](#) DOI: [10.1128/JVI.78.24.14043-14047.2004](#)]
- 26 **Wu J**, Song S, Cao HC, Li LJ. Liver diseases in COVID-19: Etiology, treatment and prognosis. *World J Gastroenterol* 2020; **26**: 2286-2293 [PMID: [32476793](#) DOI: [10.3748/wjg.v26.i19.2286](#)]
- 27 **Wang Z**, Yang B, Li Q, Wen L, Zhang R. Clinical Features of 69 Cases With Coronavirus Disease 2019 in Wuhan, China. *Clin Infect Dis* 2020; **71**: 769-777 [PMID: [32176772](#) DOI: [10.1093/cid/ciaa272](#)]
- 28 **Cai Q**, Huang D, Ou P, Yu H, Zhu Z, Xia Z, Su Y, Ma Z, Zhang Y, Li Z, He Q, Liu L, Fu Y, Chen J. COVID-19 in a designated infectious diseases hospital outside Hubei Province, China. *Allergy* 2020; **75**: 1742-1752 [PMID: [32239761](#) DOI: [10.1111/all.14309](#)]
- 29 **Zhang B**, Zhou X, Qiu Y, Song Y, Feng F, Feng J, Song Q, Jia Q, Wang J. Clinical characteristics of 82 cases of death from COVID-19. *PLoS One* 2020; **15**: e0235458 [PMID: [32645044](#) DOI: [10.1371/journal.pone.0235458](#)]
- 30 **Wang D**, Hu B, Hu C, Zhu F, Liu X, Zhang J, Wang B, Xiang H, Cheng Z, Xiong Y, Zhao Y, Li Y, Wang X, Peng Z. Clinical Characteristics of 138 Hospitalized Patients With 2019 Novel Coronavirus-Infected Pneumonia in Wuhan, China. *JAMA* 2020; **323**: 1061-1069 [PMID: [32031570](#) DOI: [10.1001/jama.2020.1585](#)]
- 31 **Li L**, Li S, Xu MM, Yu PF, Zheng SJ, Duan ZP, Liu J, Chen Y, Li JF. Risk factors related to hepatic injury in patients with corona virus disease 2019. 2020 Preprint. Available from: medRxiv:2020.02.28.20028514 [DOI: [10.1101/2020.02.28.20028514](#)]
- 32 **Yang X**, Yu Y, Xu J, Shu H, Xia J, Liu H, Wu Y, Zhang L, Yu Z, Fang M, Yu T, Wang Y, Pan S, Zou X, Yuan S, Shang Y. Clinical course and outcomes of critically ill patients with SARS-CoV-2 pneumonia in Wuhan, China: a single-centered, retrospective, observational study. *Lancet Respir Med* 2020; **8**: 475-481 [PMID: [32105632](#) DOI: [10.1016/S2213-2600\(20\)30079-5](#)]
- 33 **Fan Z**, Chen L, Li J, Cheng X, Yang J, Tian C, Zhang Y, Huang S, Liu Z, Cheng J. Clinical Features of COVID-19-Related Liver Functional Abnormality. *Clin Gastroenterol Hepatol* 2020; **18**: 1561-1566 [PMID: [32283325](#) DOI: [10.1016/j.cgh.2020.04.002](#)]
- 34 **Shi H**, Han X, Jiang N, Cao Y, Alwalid O, Gu J, Fan Y, Zheng C. Radiological findings from 81 patients with COVID-19 pneumonia in Wuhan, China: a descriptive study. *Lancet Infect Dis* 2020; **20**: 425-434 [PMID: [32105637](#) DOI: [10.1016/S1473-3099\(20\)30086-4](#)]
- 35 **Xu XW**, Wu XX, Jiang XG, Xu KJ, Ying LJ, Ma CL, Li SB, Wang HY, Zhang S, Gao HN, Sheng JF, Cai HL, Qiu YQ, Li LJ. Clinical findings in a group of patients infected with the 2019 novel coronavirus (SARS-Cov-2) outside of Wuhan, China: retrospective case series. *BMJ* 2020; **368**: m606 [PMID: [32075786](#) DOI: [10.1136/bmj.m606](#)]
- 36 **Zhao Y**, Zhao Z, Wang Y, Zhou Y, Ma Y, Zuo W. Single-Cell RNA Expression Profiling of ACE2, the Receptor of SARS-CoV-2. *Am J Respir Crit Care Med* 2020; **202**: 756-759 [PMID: [32663409](#) DOI: [10.1164/rccm.202001-0179LE](#)]
- 37 **Zhang H**, Kang Z, Gong H, Xu D, Wang J, Li Z, Cui X, Xiao J, Meng T, Zhou W, Liu J, Xu H. The digestive system is a potential route of 2019-nCov infection: a bioinformatics analysis based on single-cell transcriptomes. 2020 Preprint. Available from: BioRxiv:2020.01.30.927806 [DOI: [10.1101/2020.01.30.927806](#)]
- 38 **Xu Z**, Shi L, Wang Y, Zhang J, Huang L, Zhang C, Liu S, Zhao P, Liu H, Zhu L, Tai Y, Bai C, Gao T, Song J, Xia P, Dong J, Zhao J, Wang FS. Pathological findings of COVID-19 associated with acute respiratory distress syndrome. *Lancet Respir Med* 2020; **8**: 420-422 [PMID: [32085846](#) DOI: [10.1016/S2213-2600\(20\)30076-X](#)]
- 39 **Dawood DRM**, Salum GM, El-Meguid MA. The Impact of COVID-19 on Liver Injury. *Am J Med Sci* 2022; **363**: 94-103 [PMID: [34752738](#) DOI: [10.1016/j.amjms.2021.11.001](#)]
- 40 **Paizis G**, Tikellis C, Cooper ME, Schembri JM, Lew RA, Smith AI, Shaw T, Warner FJ, Zuilli A, Burrell LM, Angus PW. Chronic liver injury in rats and humans upregulates the novel enzyme angiotensin converting enzyme 2. *Gut* 2005; **54**:



- 1790-1796 [PMID: 16166274 DOI: 10.1136/gut.2004.062398]
- 41 **Bouayad A.** Innate immune evasion by SARS-CoV-2: Comparison with SARS-CoV. *Rev Med Virol* 2020; **30**: 1-9 [PMID: 32734714 DOI: 10.1002/rmv.2135]
  - 42 **Pedersen SF,** Ho YC. SARS-CoV-2: a storm is raging. *J Clin Invest* 2020; **130**: 2202-2205 [PMID: 32217834 DOI: 10.1172/JCI137647]
  - 43 **McGonagle D,** Sharif K, O'Regan A, Bridgewood C. The Role of Cytokines including Interleukin-6 in COVID-19 induced Pneumonia and Macrophage Activation Syndrome-Like Disease. *Autoimmun Rev* 2020; **19**: 102537 [PMID: 32251717 DOI: 10.1016/j.autrev.2020.102537]
  - 44 **Sivandzadeh GR,** Askari H, Safarpour AR, Ejtehadi F, Raeis-Abdollahi E, Vaez Lari A, Abazari MF, Tarkesh F, Bagheri Lankarani K. COVID-19 infection and liver injury: Clinical features, biomarkers, potential mechanisms, treatment, and management challenges. *World J Clin Cases* 2021; **9**: 6178-6200 [PMID: 34434987 DOI: 10.12998/wjcc.v9.i22.6178]
  - 45 **de Lucena TMC,** da Silva Santos AF, de Lima BR, de Albuquerque Borborema ME, de Azevêdo Silva J. Mechanism of inflammatory response in associated comorbidities in COVID-19. *Diabetes Metab Syndr* 2020; **14**: 597-600 [PMID: 32417709 DOI: 10.1016/j.dsx.2020.05.025]
  - 46 **Rismanbaf A,** Zarei S. Liver and Kidney Injuries in COVID-19 and Their Effects on Drug Therapy; a Letter to Editor. *Arch Acad Emerg Med* 2020; **8**: e17 [PMID: 32185369]
  - 47 **Kulkarni AV,** Kumar P, Tevethia HV, Premkumar M, Arab JP, Candia R, Talukdar R, Sharma M, Qi X, Rao PN, Reddy DN. Systematic review with meta-analysis: liver manifestations and outcomes in COVID-19. *Aliment Pharmacol Ther* 2020; **52**: 584-599 [PMID: 32638436 DOI: 10.1111/apt.15916]
  - 48 **Yang Z,** Xu M, Yi JQ, Jia WD. Clinical characteristics and mechanism of liver damage in patients with severe acute respiratory syndrome. *Hepatobiliary Pancreat Dis Int* 2005; **4**: 60-63 [PMID: 15730921]
  - 49 **Amin M.** COVID-19 and the liver: overview. *Eur J Gastroenterol Hepatol* 2021; **33**: 309-311 [PMID: 32558697 DOI: 10.1097/MEG.0000000000001808]
  - 50 **Jiang S,** Wang R, Li L, Hong D, Ru R, Rao Y, Miao J, Chen N, Wu X, Ye Z, Hu Y, Xie M, Zuo M, Lu X, Qiu Y, Liang T. Liver Injury in Critically Ill and Non-critically Ill COVID-19 Patients: A Multicenter, Retrospective, Observational Study. *Front Med (Lausanne)* 2020; **7**: 347 [PMID: 32656222 DOI: 10.3389/fmed.2020.00347]
  - 51 **Zhou F,** Yu T, Du R, Fan G, Liu Y, Liu Z, Xiang J, Wang Y, Song B, Gu X, Guan L, Wei Y, Li H, Wu X, Xu J, Tu S, Zhang Y, Chen H, Cao B. Clinical course and risk factors for mortality of adult inpatients with COVID-19 in Wuhan, China: a retrospective cohort study. *Lancet* 2020; **395**: 1054-1062 [PMID: 32171076 DOI: 10.1016/S0140-6736(20)30566-3]
  - 52 **Chen X,** Jiang Q, Ma Z, Ling J, Hu W, Cao Q, Mo P, Yao L, Yang R, Gao S, Gui X, Hou W, Xiong Y, Li J, Zhang Y. Clinical Characteristics of Hospitalized Patients with SARS-CoV-2 and Hepatitis B Virus Co-infection. *Virol Sin* 2020; **35**: 842-845 [PMID: 32839868 DOI: 10.1007/s12250-020-00276-5]
  - 53 **Zhang C,** Shi L, Wang FS. Liver injury in COVID-19: management and challenges. *Lancet Gastroenterol Hepatol* 2020; **5**: 428-430 [PMID: 32145190 DOI: 10.1016/S2468-1253(20)30057-1]
  - 54 **Ji D,** Qin E, Xu J, Zhang D, Cheng G, Wang Y, Lau G. Non-alcoholic fatty liver diseases in patients with COVID-19: A retrospective study. *J Hepatol* 2020; **73**: 451-453 [PMID: 32278005 DOI: 10.1016/j.jhep.2020.03.044]
  - 55 **Lopez-Mendez I,** Aquino-Matus J, Gall SM, Prieto-Nava JD, Juarez-Hernandez E, Uribe M, Castro-Narro G. Association of liver steatosis and fibrosis with clinical outcomes in patients with SARS-CoV-2 infection (COVID-19). *Ann Hepatol* 2021; **20**: 100271 [PMID: 33099028 DOI: 10.1016/j.aohp.2020.09.015]
  - 56 **Marjot T,** Webb GJ, Barritt AS 4th, Moon AM, Stamataki Z, Wong VW, Barnes E. COVID-19 and liver disease: mechanistic and clinical perspectives. *Nat Rev Gastroenterol Hepatol* 2021; **18**: 348-364 [PMID: 33692570 DOI: 10.1038/s41575-021-00426-4]
  - 57 **Mushtaq K,** Khan MU, Iqbal F, Alsoub DH, Chaudhry HS, Ata F, Iqbal P, Elfert K, Balaraju G, Almaslamani M, Al-Ejji K, AlKaabi S, Kamel YM. NAFLD is a predictor of liver injury in COVID-19 hospitalized patients but not of mortality, disease severity on the presentation or progression - The debate continues. *J Hepatol* 2021; **74**: 482-484 [PMID: 33223215 DOI: 10.1016/j.jhep.2020.09.006]
  - 58 **Oyelade T,** Alqahtani J, Canciani G. Prognosis of COVID-19 in Patients with Liver and Kidney Diseases: An Early Systematic Review and Meta-Analysis. *Trop Med Infect Dis* 2020; **5** [PMID: 32429038 DOI: 10.3390/tropicalmed5020080]
  - 59 **Qi X,** Liu Y, Wang J, Fallowfield JA, Li X, Shi J, Pan H, Zou S, Zhang H, Chen Z, Li F, Luo Y, Mei M, Liu H, Wang Z, Li J, Yang H, Xiang H, Liu T, Zheng MH, Liu C, Huang Y, Xu D, Kang N, He Q, Gu Y, Zhang G, Shao C, Liu D, Zhang L, Kawada N, Jiang Z, Wang F, Xiong B, Takehara T, Rockey DC; COVID-Cirrhosis-CHESS Group. Clinical course and risk factors for mortality of COVID-19 patients with pre-existing cirrhosis: a multicentre cohort study. *Gut* 2021; **70**: 433-436 [PMID: 32434831 DOI: 10.1136/gutjnl-2020-321666]
  - 60 **Shah BA,** Ahmed W, Dhobi GN, Shah NN, Khursheed SQ, Haq I. Validity of pneumonia severity index and CURB-65 severity scoring systems in community acquired pneumonia in an Indian setting. *Indian J Chest Dis Allied Sci* 2010; **52**: 9-17 [PMID: 20364609]
  - 61 **Kushner T,** Cafardi J. Chronic Liver Disease and COVID-19: Alcohol Use Disorder/Alcohol-Associated Liver Disease, Nonalcoholic Fatty Liver Disease/Nonalcoholic Steatohepatitis, Autoimmune Liver Disease, and Compensated Cirrhosis. *Clin Liver Dis (Hoboken)* 2020; **15**: 195-199 [PMID: 32537135 DOI: 10.1002/cld.974]
  - 62 **Kim D,** Adeniji N, Latt N, Kumar S, Bloom PP, Aby ES, Perumalswami P, Roytman M, Li M, Vogel AS, Catana AM, Wegermann K, Carr RM, Aloman C, Chen VL, Rabiee A, Sadowski B, Nguyen V, Dunn W, Chavin KD, Zhou K, Lizaola-Mayo B, Moghe A, Debes J, Lee TH, Branch AD, Viveiros K, Chan W, Chascsa DM, Kwo P, Dhanasekaran R. Predictors of Outcomes of COVID-19 in Patients With Chronic Liver Disease: US Multi-center Study. *Clin Gastroenterol Hepatol* 2021; **19**: 1469-1479.e19 [PMID: 32950749 DOI: 10.1016/j.cgh.2020.09.027]
  - 63 **Sarin SK,** Choudhury A, Lau GK, Zheng MH, Ji D, Abd-Elslam S, Hwang J, Qi X, Cua IH, Suh JI, Park JG, Puthachon O, Kaewdech A, Piratvisuth T, Treeprasertsuk S, Park S, Wejnaruemarn S, Payawal DA, Baatarkhuu O, Ahn SH, Yeo CD, Alonzo UR, Chinbayar T, Loho IM, Yokosuka O, Jafri W, Tan S, Soo LI, Tanwandee T, Gani R, Anand L, Esmail ES,

- Khalaf M, Alam S, Lin CY, Chuang WL, Soin AS, Garg HK, Kalista K, Batsukh B, Purnomo HD, Dara VP, Rathi P, Al Mahtab M, Shukla A, Sharma MK, Omata M; APASL COVID Task Force, APASL COVID Liver Injury Spectrum Study (APCOLIS Study-NCT 04345640). Pre-existing liver disease is associated with poor outcome in patients with SARS CoV2 infection; The APCOLIS Study (APASL COVID-19 Liver Injury Spectrum Study). *Hepatol Int* 2020; **14**: 690-700 [PMID: 32623632 DOI: 10.1007/s12072-020-10072-8]
- 64 **Boettler T**, Newsome PN, Mondelli MU, Maticic M, Cordero E, Cornberg M, Berg T. Care of patients with liver disease during the COVID-19 pandemic: EASL-ESCMID position paper. *JHEP Rep* 2020; **2**: 100113 [PMID: 32289115 DOI: 10.1016/j.jhepr.2020.100113]
- 65 **Li JY**, Cao HY, Liu P, Cheng GH, Sun MY. Glycyrrhizic acid in the treatment of liver diseases: literature review. *Biomed Res Int* 2014; **2014**: 872139 [PMID: 24963489 DOI: 10.1155/2014/872139]
- 66 **Spearman CW**, Aghemo A, Valenti L, Sonderup MW. COVID-19 and the liver: A 2021 update. *Liver Int* 2021; **41**: 1988-1998 [PMID: 34152690 DOI: 10.1111/liv.14984]



Published by **Baishideng Publishing Group Inc**  
7041 Koll Center Parkway, Suite 160, Pleasanton, CA 94566, USA

**Telephone:** +1-925-3991568

**E-mail:** [bpgoffice@wjgnet.com](mailto:bpgoffice@wjgnet.com)

**Help Desk:** <https://www.f6publishing.com/helpdesk>

<https://www.wjgnet.com>

