

# World Journal of *Clinical Cases*

*World J Clin Cases* 2023 April 26; 11(12): 2582-2854



## Contents

Thrice Monthly Volume 11 Number 12 April 26, 2023

### REVIEW

- 2582** Controversies in the management of acute pancreatitis: An update  
*Manrai M, Dawra S, Singh AK, Jha DK, Kochhar R*
- 2604** Classification of osteogenesis imperfecta: Importance for prophylaxis and genetic counseling  
*Panzaru MC, Florea A, Caba L, Gorduza EV*

### MINIREVIEWS

- 2621** Emerging role of dual biologic therapy for the treatment of inflammatory bowel disease  
*McCormack MD, Wahedna NA, Aldulaimi D, Hawker P*
- 2631** Pancreatic cancer and depression  
*Michoglou K, Ravinthiranathan A, San Ti S, Dolly S, Thillai K*
- 2637** Mediastinal lesions in children  
*Çinar HG, Gulmez AO, Üner Ç, Aydin S*
- 2657** Exit strategies in inflammatory bowel disease: Looking beyond anti-tumor necrosis factors  
*Crispino F, Michielan A, Grova M, Tieppo C, Mazza M, Rogger TM, Armelao F*
- 2670** Medicinal cannabis products for the treatment of acute pain  
*Fiore M, Alfieri A, Di Franco S, Petrou S, Damiani G, Pace MC*
- 2677** Role of in vitamin D in irritable bowel syndrome  
*Yu XL, Wu QQ, He LP, Zheng YF*

### ORIGINAL ARTICLE

#### Retrospective Cohort Study

- 2684** Analysis of oxidative stress and antioxidative potential in premature ovarian insufficiency  
*Kakinuma K, Kakinuma T*

#### Retrospective Study

- 2694** Surgical management of pituitary adenoma during pregnancy  
*Jia XY, Guo XP, Yao Y, Deng K, Lian W, Xing B*
- 2708** Role of pre-existing incomplete intestinal metaplasia in gastric adenocarcinoma: A retrospective case series analysis  
*Bogdanova I, Polaka I, Aleksandraviča I, Dzērve Z, Anarkulova L, Novika V, Tolmanis I, Leja M*

**Observational Study**

- 2716** Severe/critical COVID-19 early warning system based on machine learning algorithms using novel imaging scores  
*Li QY, An ZY, Pan ZH, Wang ZZ, Wang YR, Zhang XG, Shen N*
- 2729** Mediating effect of mindfulness level on the relationship between marital quality and postpartum depression among primiparas  
*Yang J, Lin XZ, Guo QW, Wang CL, Yang RY, Zhang JW, Zeng Y*
- 2740** Ferric carboxymaltose for anemia in Crohn's disease patients at a tertiary center: A retrospective observational cohort study  
*Siqueira NSN, Pascoal LB, Rodrigues BL, de Castro MM, Martins ASC, Araiho DOS, Gomes LEM, Camargo MG, Ayrizono MLS, Leal RF*

**META-ANALYSIS**

- 2753** Is metaphyseal ulnar shortening osteotomy superior to diaphyseal ulnar shortening osteotomy in the treatment of ulnar impaction syndrome? A meta-analysis  
*Deng HL, Lu ML, Tang ZM, Mao QL, Zhao JM*
- 2766** Relationship between body mass index and short-term postoperative prognosis in patients undergoing colorectal cancer surgery  
*Li Y, Deng JJ, Jiang J*

**CASE REPORT**

- 2780** Cardiac amyloidosis presenting as pulmonary arterial hypertension: A case report  
*Gao M, Zhang WH, Zhang ZG, Yang N, Tong Q, Chen LP*
- 2788** Short-term outcome of total knee replacement in a patient with hemophilia: A case report and review of literature  
*Yin DL, Lin JM, Li YH, Chen P, Zeng MD*
- 2796** Modified inferior oblique anterior transposition for dissociated vertical deviation combined with superior oblique palsy: A case report  
*Zong Y, Wang Z, Jiang WL, Yang X*
- 2803** Treatment of talipes equinovarus after triceps surae intramuscular hemangioma surgery by Ilizarov technology in adults: A case report  
*Chen ZX, Wang MY, Zhang C, Ding ZQ, Chen W*
- 2811** Open surgery: Still a great option to treat patients with post-traumatic arteriovenous fistulas: A case report  
*Kalinin R, Suchkov I, Mzhavanadze N, Borisova Y, Panin I*
- 2817** Recovery from Bell's palsy after treatment using uncultured umbilical cord-derived mesenchymal stem cells: A case report  
*Ahn H, Jung WJ, Lee SY, Lee KH*

- 2825** Pancreatic neuroendocrine tumor detected by technetium-99m methoxy-2-isobutylisonitrile single photon emission computed tomography/computed tomography: A case report  
*Liu CJ, Yang HJ, Peng YC, Huang DY*
- 2832** Furazolidone-induced pulmonary toxicity in *Helicobacter pylori* infection: Two case reports  
*Ye Y, Shi ZL, Ren ZC, Sun YL*
- 2839** Efficacy of anlotinib combined with radioiodine to treat scalp metastasis of papillary thyroid cancer: A case report and review of literature  
*Zhang LY, Cai SJ, Liang BY, Yan SY, Wang B, Li MY, Zhao WX*
- 2848** Endoscopic ultrasound-guided transrectal drainage of a pelvic abscess after Hinchey II sigmoid colon diverticulitis: A case report  
*Drnovšek J, Čebren Ž, Grosek J, Janež J*

**ABOUT COVER**

Editorial Board Member of *World Journal of Clinical Cases*, Mohamed Eltayeb Abdelrahman Naiem, MBBS, MD, Assistant Professor, Surgeon, Department of Surgery, Faculty of Medicine, University of Khartoum, Khartoum 102, Sudan. m-altayeb@live.com

**AIMS AND SCOPE**

The primary aim of *World Journal of Clinical Cases* (WJCC, *World J Clin Cases*) is to provide scholars and readers from various fields of clinical medicine with a platform to publish high-quality clinical research articles and communicate their research findings online.

WJCC mainly publishes articles reporting research results and findings obtained in the field of clinical medicine and covering a wide range of topics, including case control studies, retrospective cohort studies, retrospective studies, clinical trials studies, observational studies, prospective studies, randomized controlled trials, randomized clinical trials, systematic reviews, meta-analysis, and case reports.

**INDEXING/ABSTRACTING**

The WJCC is now abstracted and indexed in Science Citation Index Expanded (SCIE, also known as SciSearch®), Journal Citation Reports/Science Edition, Current Contents®/Clinical Medicine, PubMed, PubMed Central, Scopus, Reference Citation Analysis, China National Knowledge Infrastructure, China Science and Technology Journal Database, and Superstar Journals Database. The 2022 Edition of Journal Citation Reports® cites the 2021 impact factor (IF) for WJCC as 1.534; IF without journal self cites: 1.491; 5-year IF: 1.599; Journal Citation Indicator: 0.28; Ranking: 135 among 172 journals in medicine, general and internal; and Quartile category: Q4. The WJCC's CiteScore for 2021 is 1.2 and Scopus CiteScore rank 2021: General Medicine is 443/826.

**RESPONSIBLE EDITORS FOR THIS ISSUE**

Production Editor: *Ying-Yi Yuan*; Production Department Director: *Xu Guo*; Editorial Office Director: *Jin-Lei Wang*.

**NAME OF JOURNAL**

*World Journal of Clinical Cases*

**ISSN**

ISSN 2307-8960 (online)

**LAUNCH DATE**

April 16, 2013

**FREQUENCY**

Thrice Monthly

**EDITORS-IN-CHIEF**

Bao-Gan Peng, Jerzy Tadeusz Chudek, George Kontogeorgos, Maurizio Serati, Ja Hyeon Ku

**EDITORIAL BOARD MEMBERS**

<https://www.wjgnet.com/2307-8960/editorialboard.htm>

**PUBLICATION DATE**

April 26, 2023

**COPYRIGHT**

© 2023 Baishideng Publishing Group Inc

**INSTRUCTIONS TO AUTHORS**

<https://www.wjgnet.com/bpg/gerinfo/204>

**GUIDELINES FOR ETHICS DOCUMENTS**

<https://www.wjgnet.com/bpg/GerInfo/287>

**GUIDELINES FOR NON-NATIVE SPEAKERS OF ENGLISH**

<https://www.wjgnet.com/bpg/gerinfo/240>

**PUBLICATION ETHICS**

<https://www.wjgnet.com/bpg/GerInfo/288>

**PUBLICATION MISCONDUCT**

<https://www.wjgnet.com/bpg/gerinfo/208>

**ARTICLE PROCESSING CHARGE**

<https://www.wjgnet.com/bpg/gerinfo/242>

**STEPS FOR SUBMITTING MANUSCRIPTS**

<https://www.wjgnet.com/bpg/GerInfo/239>

**ONLINE SUBMISSION**

<https://www.f6publishing.com>



Retrospective Study

## Surgical management of pituitary adenoma during pregnancy

Xin-Yu Jia, Xiao-Peng Guo, Yong Yao, Kan Deng, Wei Lian, Bing Xing

**Specialty type:** Medicine, research and experimental

**Provenance and peer review:** Unsolicited article; Externally peer reviewed.

**Peer-review model:** Single blind

**Peer-review report's scientific quality classification**

Grade A (Excellent): 0  
Grade B (Very good): B  
Grade C (Good): 0  
Grade D (Fair): 0  
Grade E (Poor): 0

**P-Reviewer:** Tolunay HE, Turkey

**Received:** November 22, 2022

**Peer-review started:** November 22, 2022

**First decision:** February 14, 2023

**Revised:** March 1, 2023

**Accepted:** March 24, 2023

**Article in press:** March 24, 2023

**Published online:** April 26, 2023



**Xin-Yu Jia**, Department of Plastic Surgery, Plastic Surgery Hospital, Chinese Academy of Medical Sciences and Peking Union Medical College, Beijing 100144, China

**Xin-Yu Jia, Xiao-Peng Guo, Yong Yao, Kan Deng, Wei Lian, Bing Xing**, Department of Neurosurgery, Key Laboratory of Endocrinology of Ministry of Health, China Pituitary Adenoma Specialist Council, Peking Union Medical College Hospital, Chinese Academy of Medical Sciences and Peking Union Medical College Hospital, Beijing 100730, China

**Xin-Yu Jia**, Department of Plastic Surgery, Chinese Academy of Medical Sciences and Peking Union Medical College, Beijing 100730, China

**Xiao-Peng Guo, Yong Yao, Kan Deng, Wei Lian, Bing Xing**, Department of Neurosurgery, Medical Research Center, State Key Laboratory of Complex Severe and Rare Diseases, Peking Union Medical College Hospital, Chinese Academy of Medical Sciences and Peking Union Medical College Hospital, Beijing 100730, China

**Corresponding author:** Bing Xing, MD, Neurosurgeon, Professor, Department of Neurosurgery, Key Laboratory of Endocrinology of Ministry of Health, China Pituitary Adenoma Specialist Council, Peking Union Medical College Hospital, Chinese Academy of Medical Sciences and Peking Union Medical College Hospital, No. 1 Shufuyuan, Dongcheng District, Beijing 100730, China. [xingbingemail@aliyun.com](mailto:xingbingemail@aliyun.com)

### Abstract

#### BACKGROUND

Although conservative treatment is typically recommended for pregnant patients with pituitary adenoma (PA), surgical treatment is occasionally necessary for those with acute symptoms. Currently, surgical interventions utilized among these patients is poorly studied.

#### AIM

To evaluate the surgical indications, timing, perioperative precautions and postoperative complications of PAs during pregnancy and to provide comprehensive guidance.

#### METHODS

Six patients with PAs who underwent surgical treatment during pregnancy at Peking Union Medical College Hospital between January 1990 and June 2021 were recruited for this study. Another 35 pregnant patients who were profiled in the literature were included in our analysis.

## RESULTS

The 41 enrolled patients had acute symptoms including visual field defects, severe headaches or vision loss that required emergency pituitary surgeries. PA apoplexies were found in 23 patients. The majority of patients (55.9%) underwent surgery in the second trimester of pregnancy. A multidisciplinary team was involved in patient care from the preoperative period through the postpartum period. With the exception of 1 patient who underwent an induced abortion and 1 fetus that died due to a nuchal cord, 39 patients delivered successfully. Among them, 37 fetuses were healthy until the most recent follow-up.

## CONCLUSION

PA surgery during pregnancy is effective and safe during the second and third trimesters. Pregnant patients requiring emergency PA surgery require multidisciplinary evaluation and healthcare management.

**Key Words:** Pituitary adenoma; Pregnancy; Surgery; Surgical indication; Surgical timing

©The Author(s) 2023. Published by Baishideng Publishing Group Inc. All rights reserved.

**Core Tip:** Although clinicians generally recommend conservative treatment for patients with pituitary adenomas (PAs), surgical treatment is occasionally necessary. Currently, surgical interventions utilized among these patients is poorly studied. This study investigated the surgical interventions utilized for patients with PAs occurring during pregnancy. We found that in the second and third trimesters transsphenoidal PA surgery is a safe and effective approach for emergency conditions arising during pregnancy and may be conducted after a multidisciplinary team evaluation. These strategies may open up new avenues for the treatment of PAs during pregnancy in the future.

**Citation:** Jia XY, Guo XP, Yao Y, Deng K, Lian W, Xing B. Surgical management of pituitary adenoma during pregnancy. *World J Clin Cases* 2023; 11(12): 2694-2707

**URL:** <https://www.wjgnet.com/2307-8960/full/v11/i12/2694.htm>

**DOI:** <https://dx.doi.org/10.12998/wjcc.v11.i12.2694>

## INTRODUCTION

Pituitary adenoma (PA) is the second most common primary brain tumor, accounting for 15% to 17% of brain tumors and 25% of benign brain tumors[1]. Although PAs can occur at any age, those occurring in pregnant patients have unique characteristics. Pregnancy can cause the enlargement of pre-existing PAs that may compress the meningeal, contributing to acute symptoms such as severe headache and visual defects. These symptoms can affect maternal health and fetal development[2]. In addition, hormone-secreting PAs may lead to increased levels of hormones, such as adrenocorticotrophic hormone (ACTH) and thyroid-stimulating hormone (TSH), resulting in poor prognoses[1,3].

During pregnancy, some PAs can be controlled by conservative treatment. For example, patients with prolactinomas are treated with oral dopamine agonists (DAs)[1,4-6]. Although there is no evidence that somatostatin analogues (SSAs) are safe for the fetus during pregnancy, SSAs are effective in reducing tumor size and decreasing growth hormone (GH) and insulin-like growth factor 1 (IGF1) levels in acromegaly[7,8]. However, some pregnant patients with acute compression symptoms, such as visual defects and severe headache, as well as non-prolactinoma patients with pathologically high hormone levels may accept surgical treatment in clinical practice. Surgical treatment may also be chosen if the problem cannot be solved by conservative treatment or potential side effects rule out pharmacological treatment. These patients pose a challenge to neurosurgeons in terms of surgical timing, surgical indications, anesthesia risk and perioperative treatment. At present, few case reports on the surgical treatment of pregnant PA patients are available, and adequate knowledge and experience regarding this surgical intervention are lacking.

The pituitary specialty at the Peking Union Medical College Hospital (PUMCH) has a long history[9], and the Neurosurgery Department of PUMCH is the founding unit of the China Pituitary Adenoma Specialist Council and the China Pituitary Disease Registry Network. The endocrinology department at PUMCH is known as a leader in endocrinology[10]. In this study, we summarized the clinical presentation, imaging features, surgical indications, perioperative management and other vital considerations of 6 pregnant PA patients surgically treated at our hospital. We also included 35 similar patients reported in the literature. Our goal was to provide suggestions for the management of pregnant PA patients to physicians in neurosurgery, endocrinology, obstetrics/gynecology, ophthalmology, and



other related specialties.

## MATERIALS AND METHODS

### *Patient enrolment at PUMCH*

Six pregnant patients with PAs admitted to the neurosurgery department of PUMCH between January 1990 and June 2021 were retrospectively analyzed. All patients underwent surgery for PAs during pregnancy. The data collected included clinical symptoms, imaging features, perioperative treatment, pathological classification, and postoperative follow-up. All procedures involving human participants were performed in accordance with the ethical standards of the Institutional Ethics Committee of Peking Union Medical College Hospital at the Chinese Academy of Medical Sciences and Peking Union Medical College and with the 1964 Declaration of Helsinki and its later amendments or comparable ethical standards. Informed consent was obtained from all participants included in the study.

### *Additional cases from the literature and data extraction*

We performed a literature search using PubMed to identify relevant studies published between January 1990 and June 2021. Our search used the MeSH terms “pituitary adenoma,” “pregnancy” and “surgery.” Citation indices were used to expand the search for relevant studies. The search was limited to studies written in English and were included only when sufficient data were available. Some studies without details of cases, such as those describing clinical symptoms, imaging findings, surgical timing and specific pathology, were not included[11].

After reading and reviewing relevant literature, only patients with PAs who underwent surgery during pregnancy were included. Patients treated with conservative treatment alone as well as those who received treatment for pathological non-PA were excluded.

Patients with duplicate reports due to multiple articles published by the same clinical center at different times were manually removed. Based on the above criteria, 30 studies screened, resulting in the inclusion of 35 patients.

### *Statistical analysis*

Statistical analysis was performed using Statistical Package for the Social Sciences (SPSS) software (version 22.0; IBM Corp., Armonk, NY, United States). Measurement data conforming to a normal distribution were represented by. Enumeration data were expressed as percentages or ratios. Paired-sample *t*-tests were used for preoperative and postoperative comparisons. Statistical significance was set at  $P < 0.05$ .

## RESULTS

### *Clinical characteristics*

Forty-one patients with PAs who underwent surgery during pregnancy were included. A summary of their clinical characteristics is provided in Table 1, which includes 6 cases from our center and 35 cases from the PubMed database. The ages of 3 patients were not reported. The age of the remaining 38 patients ranged from 21 years to 41 years, with a mean age of  $29.7 \pm 5.3$  years.

The clinical presentations of the 41 patients were as follows: visual field defects in 28 cases (68.3%) (bitemporal hemianopsia in 23 cases, unilateral temporal hemianopsia in 5 cases; Figure 1); headaches in 27 cases (65.9%); vision loss in 20 cases (48.8%) (15 cases binocular, 5 cases monocular); Cushing syndrome in 7 cases (17.1%); acromegaly in 6 cases (14.6%); oculomotor paralysis in 4 cases (9.8%); diabetes insipidus in 2 cases (4.9%); and hyperthyroidism in 2 cases (4.9%).

### *Image data*

The imaging data of the 41 patients are shown in Supplementary Table 1. Magnetic resonance imaging (MRI) was obtained for 37 of the patients (90.2%). Contrast-enhanced MRI was performed in 3 cases (7.3%), in which 1 case was obtained before pregnancy and 2 cases were obtained during pregnancy. Cranial enhanced computed tomography was performed in 1 case (2.4%) without MRI. The tumor sizes in the 27 patients with available data ranged from 0.4 cm to 4.0 cm (average:  $2.1 \pm 0.9$  cm). Pituitary microadenomas were found in 2 patients. Up to 92.6% of patients (25 cases) had pituitary macroadenoma.

Twenty-seven patients underwent T1 weighted imaging (T1WI), yielding hypointensity in 11.1% of cases (3/27), isointensity in 37.0% of cases (10/27), isointensity and hypointensity in 3.7% of cases (1/27), isointensity and hyperintensity in 29.6% of cases (8/27), and hyperintensity in 18.5% of cases (5/27). Three types of T1WI for cases with pituitary apoplexy were shown in Figure 2. None of the images showed hypointensity on T1WI.

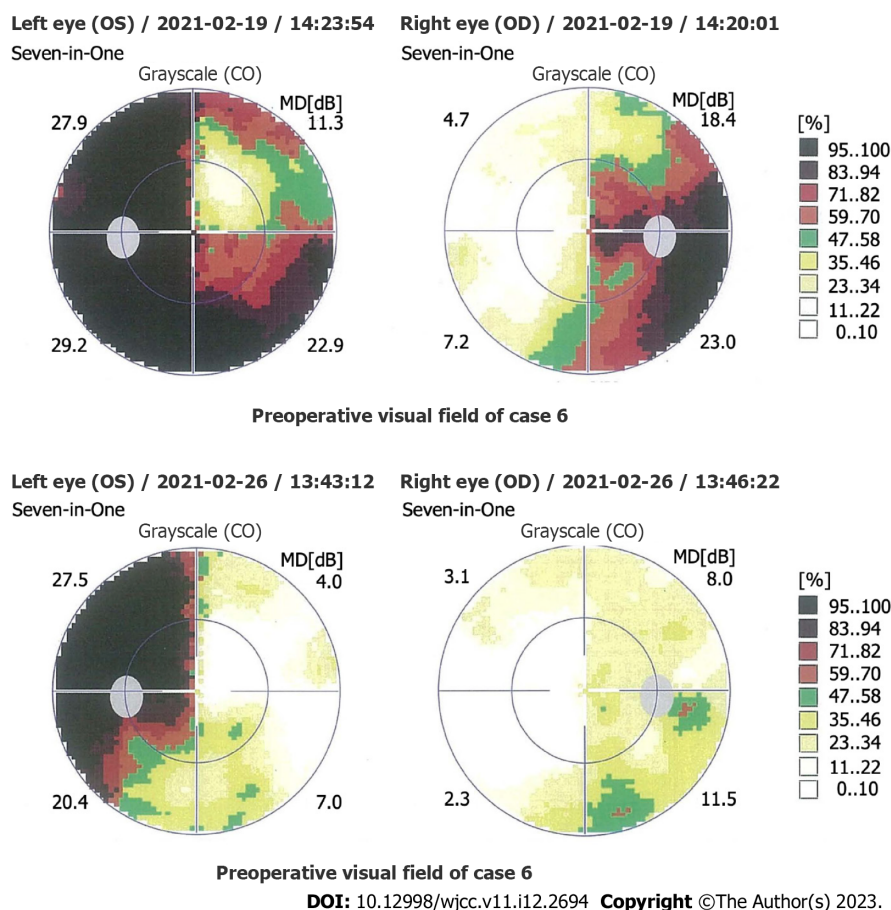


Table 1 Basic information and clinical symptoms of pregnant patients who underwent surgery for pituitary adenoma

Data source	Case	Age, yr	Sex	Clinical symptoms							
				Headache	Vision loss	Visual field	OP	DI	HT	CS	Acromegaly
Peking Union Medical College Hospital	1	29	F	No	Bi	BTH	No	No	No	No	No
	2	36	F	Yes	Bi	BTH	No	No	No	No	No
	3	34	F	No	Bi	BTH	Yes	Yes	No	No	No
	4	32	F	No	No	No	No	No	Yes	No	No
	5	37	F	Yes	Mo	BTH	No	No	No	No	No
	6	28	F	Yes	Bi	BTH	No	No	No	No	No
Jallad <i>et al</i> [16]	7	25	F	Yes	No	BTH	No	No	No	No	Yes
	8	27	F	Yes	No	BTH	No	No	No	No	Yes
	9	27	F	Yes	No	BTH	No	No	No	No	Yes
Chaiamnuay <i>et al</i> [17]	10	39	F	Yes	No	UTH	No	No	Yes	No	No
Guven <i>et al</i> [18]	11	32	F	No	Bi	BTH	No	No	No	No	Yes
Zhong <i>et al</i> [38]	12	29	F	No	Bi	No	No	No	No	No	No
Jemel <i>et al</i> [19]	13	35	F	Yes	No	BTH	No	No	No	No	No
	14	30	F	Yes	Bi	BTH	No	No	No	No	No
Xia <i>et al</i> [20]	15	25	F	Yes	Bi	BTH	No	No	No	No	No
Yamaguchi <i>et al</i> [21]	16	35	F	Yes	Bi	UTH	No	No	No	No	No
Tandon <i>et al</i> [22]	17	27	F	Yes	Mo	BTH	No	No	No	No	No
Parihar <i>et al</i> [36]	18	22	F	Yes	Bi	No	No	No	No	No	No
Gondim <i>et al</i> [23]	19	29	F	Yes	Mo	UTH	Yes	No	No	No	No
Witek <i>et al</i> [24]	20	25	F	Yes	Bi	BTH	No	No	No	No	No
Kita <i>et al</i> [25]	21	26	F	Yes	No	BTH	No	No	No	No	No
Nossek <i>et al</i> [26]	22	29	F	No	Bi	No	No	No	No	No	No
	23	34	F	No	No	BTH	No	No	No	No	No
Iuliano and Laws[27]	24	28	F	Yes	No	No	No	No	No	No	No
	25	35	F	Yes	Mo	UTH	Yes	No	No	No	No
Hayes <i>et al</i> [28]	26	41	F	Yes	No	BTH	No	No	No	No	No
Boronat <i>et al</i> [52]	27	26	F	No	No	No	No	No	No	Yes	No
Abbassy <i>et al</i> [37]	28	38	F	Yes	No	No	No	No	No	Yes	No
Coyne <i>et al</i> [53]	29	22	F	No	No	No	No	No	No	Yes	No
Pinette <i>et al</i> [54]	30	33	F	No	No	No	No	No	No	Yes	No
Ross <i>et al</i> [55]	31	24	F	No	No	No	No	No	No	Yes	No
Mellor <i>et al</i> [51]	32	40	F	No	No	No	No	No	No	Yes	No
Karaca <i>et al</i> [15]	33	NA	F	No	No	No	Yes	No	No	No	Yes
Jolly <i>et al</i> [56]	34	30	F	No	No	No	No	No	No	Yes	No
Galvão <i>et al</i> [29]	35	NA	F	Yes	Bi	BTH	No	No	No	No	No
Abid <i>et al</i> [30]	36	25	F	Yes	Bi	BTH	No	No	No	No	No
Barraud <i>et al</i> [31]	37	NA	F	Yes	No	BTH	No	No	No	No	No
Freeman <i>et al</i> [32]	38	22	F	Yes	Mo	BTH	No	Yes	No	No	No
Lunardi <i>et al</i> [33]	39	21	F	Yes	Bi	BTH	No	No	No	No	Yes

Oguz <i>et al</i> [34]	40	26	F	Yes	No	UTH	No	No	No	No	No
O'Neal[35]	41	27	F	Yes	No	BTH	No	No	No	No	No

Bi: Binocular; BTH: Bitemporal hemianopsia; CS: Cushing syndrome; DI: Diabetes insipidus; F: Female; HT: Hyperthyroidism; Mo: Monocular; OP: Oculomotor paralysis; NA: Not available; UTH: Unilateral temporal hemianopsia.



**Figure 1 Comparison of the preoperative and postoperative visual fields for Case 6.** Preoperative visual field examination showed bitemporal hemianopsia, which was more severe in the left eye. Three days after surgery, examination revealed a partial temporal visual field defect in the left eye and a standard visual field in the right eye.

Ten patients underwent T2 weighted imaging, yielding hypointensity in 10.0% of cases (1/10), hyperintensity in 40.0% of cases (4/10) and isointensity and hyperintensity in 50.0% of cases (5/10). Three of the four patients who underwent contrast-enhanced MRI showed no enhancement. The remaining case showed inhomogeneous enhancement.

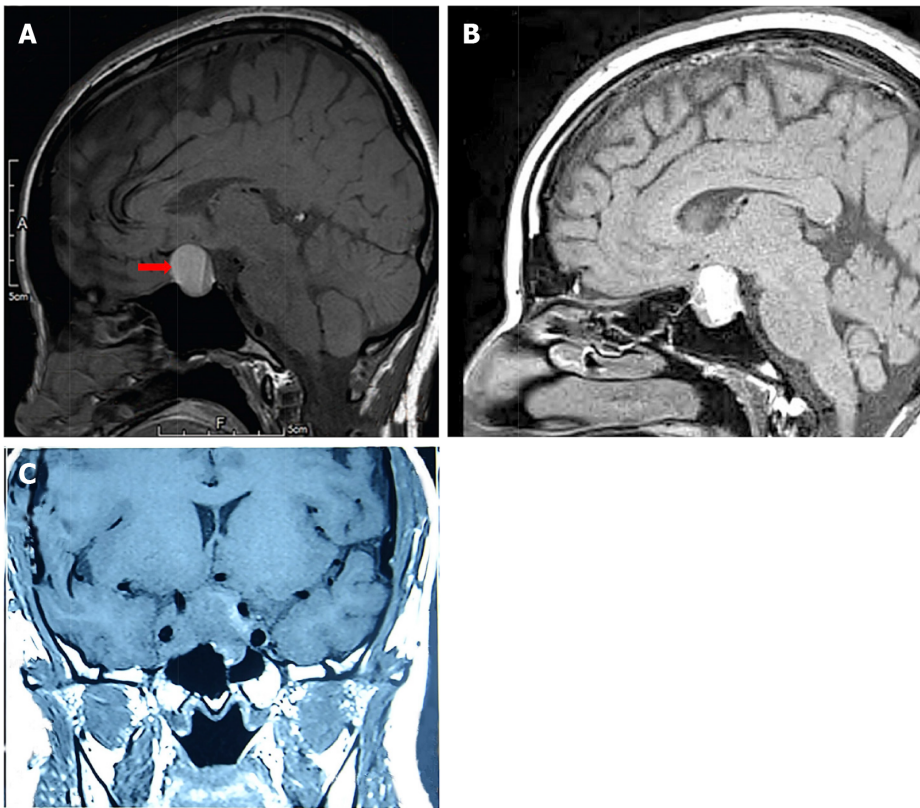
The Knosp classification was reported in 20 patients. In 5 cases (25.0%), the classification was invasive (Knosp classification III or IV). In 15 cases (75.0%), the classification was non-invasive. Five patients were in the highest unilateral Knosp classification IV (25.0%). Two patients (10.0%) were in Knosp classification II. Nine patients (45.0%) were in Knosp classification I, and four patients (20.0%) were in Knosp classification 0.

### Hormone levels

Changes in hormone levels in the 41 patients were shown in [Supplementary Table 2](#). Complete hormone monitoring was performed in 8 of 13 patients with prolactinoma. Prolactin levels decreased after operation, and the difference was statistically significant ( $P < 0.05$ ).

GH levels in 4 patients with complete hormone monitoring decreased postoperatively, although without statistical significance ( $P = 0.085$ ). One patient (Case 11) had higher IGF1 on the 2<sup>nd</sup> day after surgery. However, the IGF1 level returned to normal after 6 mo. The IGF1 difference in the other 3 patients was not statistically significant ( $P = 0.115$ ).

ACTH levels of the 3 patients completing hormone monitoring increased preoperatively and sharply decreased postoperatively. The difference was statistically significant ( $P < 0.05$ ). However, among 2



DOI: 10.12998/wjcc.v11.i12.2694 Copyright ©The Author(s) 2023.

**Figure 2** Three typical images of pituitary adenoma apoplexy. A: Sagittal T1 weighted imaging (T1WI) showed isointensity and hyperintensity with a visible liquid level (Case 15); B: Sagittal T1WI showed mixed intensity (mainly hyperintensity) (Case 40); C: Coronal T1WI showed isointensity (Case 5).

patients with decreased TSH levels postoperatively, the difference was not statistically significant ( $P = 0.308$ ).

#### **Perioperative conservative treatment**

Perioperative conservative treatments for the 41 patients are shown in Table 2. Twenty-two patients did not receive conservative treatment. Among the remaining 19 patients, bromocriptine was used most frequently (57.9%, 11/19), including for 6 patients with prolactinoma, 3 patients with non-functioning PA, 1 patient with TSH-secreting PA, and 1 patient without pathological classification. The second most frequent preoperative drug group was glucocorticoids, including 5 patients with non-functioning PA, 1 patient with prolactinoma and 1 patient without pathological classification. Cabergoline, also a DA, ranked third with only 2 patients, including 1 patient with non-functioning PA and 1 patient with GH-secreting PA. Drugs also used for preoperative medication included sandostatin, thyroxine, propylthiouracil, alpha-methyldopa and 1-desamino-8-D-arginine vasopressin. Postoperatively, 30 patients received conservative treatment, comprising 13 cases of glucocorticoid treatment, 7 cases of thyroxine treatment, 5 cases of arginine-vasopressin treatment, and 5 cases of desmopressin treatment.

#### **Operations and pathological classifications**

All 41 patients underwent transsphenoidal surgery under general anesthesia. No patients were treated with craniotomy. With the exception of 7 patients who did not report their specific gestation, the surgical gestation of the other 34 patients ranged from 11 wk to 36 wk, with an average of  $25.1 \pm 7.1$  wk. Two cases were in the first trimester (gestation < 14 wk; 5.9%), 19 cases in the second trimester (14 wk ≤ gestation < 28 wk; 55.9%, 19/34), and 13 cases in the third trimester (gestation ≥ 28 wk; 38.2%, 13/34).

Three cases (from PubMed) did not have pathologic classification reported. There were 13 cases (34.2%) of prolactinoma, 10 cases (26.3%) of non-functioning PA, 7 cases (18.4%) of ACTH-secreting PA, 6 cases (15.8%) of GH-secreting PA, and 2 cases (5.3%) of TSH-secreting PA.

#### **Follow-up information**

Ten patients with non-functioning PA were not in remission, and twenty-six patients (63.4%) were in endocrine remission. Four patients (9.8%) were in endocrine control, and one patient (2.4%) relapsed. In terms of pregnancy outcomes, 1 patient underwent an induced abortion at 16 wk, and 1 fetus died due to a nuchal cord at 33 wk of gestation. The remaining 39 patients delivered 37 healthy fetuses successfully. One fetus died of a congenital diaphragmatic hernia within 36 h after caesarean section at

Table 2 Treatment and follow-up outcomes of pregnant patients who underwent surgery for pituitary adenoma

Ref.	Case	Treatment					Follow up	
		Medical therapy			Operation	Delivery		
		Pre	Post					
Peking Union Medical College Hospital	1	Bromocriptine	No	12 <sup>th</sup> W TSS	40 <sup>th</sup> W CS	NF PA	ER	H
	2	No	No	32 <sup>nd</sup> W TSS	Full term CS	NF PA	ER	H
	3	No	No	22 <sup>nd</sup> W TSS	38 <sup>th</sup> W CS	NF PA	ER	H
	4	Sandostatin	No	26 <sup>th</sup> W TSS	38 <sup>th</sup> W CS	TSH PA	ER	H
	5	Bromocriptine	No	35 <sup>th</sup> W TSS	35 <sup>th</sup> W CS	PRL PA	ER	H
	6	Prednisone, thyroxine	Prednisone, thyroxine	30 <sup>th</sup> W TSS	39 <sup>th</sup> W CS	NF PA	ER	H
Jallad <i>et al</i> [16]	7	No	No	3 <sup>rd</sup> Mon TSS	38 <sup>th</sup> W CS	GH PA	ER	H
	8	No	No	4 <sup>th</sup> Mon TSS	16 <sup>th</sup> W A	GH PA	EC	A
	9	Cabergoline	No	4 <sup>th</sup> Mon TSS	39 <sup>th</sup> W CS	GH PA	ER	H
Chaiamnuay <i>et al</i> [17]	10	Propylthiouracil, bromocriptine	No	27 <sup>th</sup> W TSS	39 <sup>th</sup> W CS	TSH PA	ER	H
Güven <i>et al</i> [18]	11	No	Octreotide	34 <sup>th</sup> W TSS	34 <sup>th</sup> W CS	GH PA	EC	H
Zhong <i>et al</i> [38]	12	No	Cortisone, thyroxine	22 <sup>nd</sup> W TSS	40 <sup>th</sup> W VD	NF PA	ER	H
Jemel <i>et al</i> [19]	13	Cabergoline, hydrocortisone	No	22 <sup>nd</sup> W TSS	37 <sup>th</sup> W VD	NF PA	ER	H
	14	Corticosteroids	No	24 <sup>th</sup> W TSS	38 <sup>th</sup> W VD	NF PA	ER	H
Xia <i>et al</i> [20]	15	No	No	24 <sup>th</sup> W TSS	38 <sup>th</sup> W CS	PRL PA	ER	H
Yamaguchi <i>et al</i> [21]	16	No	Methyl prednisolone	36 <sup>th</sup> W TSS	37 <sup>th</sup> W CS	PRL PA, Optic neuritis	ER	H
Tandon <i>et al</i> [22]	17	Bromocriptine	Desmopressin	36 <sup>th</sup> W TSS	37 <sup>th</sup> W CS	PRL PA	ER	H
Parihar <i>et al</i> [36]	18	No	No	20 <sup>th</sup> W TSS	Full term VD	PRL PA	ER	H
Gondim <i>et al</i> [23]	19	Bromocriptine	Thyroxine, hydrocortisone	32 <sup>nd</sup> W TSS	39 <sup>th</sup> W VD	PRL PA	EC	H
Witek <i>et al</i> [24]	20	Bromocriptine	Hydrocortisone	20 <sup>th</sup> W TSS	38 <sup>th</sup> W CS	PRL PA	ER	H
Kita <i>et al</i> [25]	21	No	DDAVP	27 <sup>th</sup> W TSS	40 <sup>th</sup> W VD	NF PA	ER	H
Nossek <i>et al</i> [26]	22	No	No	33 <sup>rd</sup> W TSS	35 <sup>th</sup> W CS	PA	ER	LAS
	23	No	No	31 <sup>st</sup> W TSS	40 <sup>th</sup> W VD	PA	ER	H
Iuliano and Laws [27]	24	Bromocriptine, dexamethasone	No	30 <sup>th</sup> W TSS	39 <sup>th</sup> W CS	NF PA	ER	H
	25	Bromocriptine, dexamethasone	Levothyroxine, hydrocortisone	33 <sup>rd</sup> W TSS	39 <sup>th</sup> W CS	NF PA	ER	H
Hayes <i>et al</i> [28]	26	Corticosteroids	No	18 <sup>th</sup> W TSS	Full term VD	PRL PA	ER	H
Boronat <i>et al</i> [52]	27	Alpha-metildopa	Metyrapone	16 <sup>th</sup> W TSS	34 <sup>th</sup> W VD	ACTH PA	R	H
Abbassy <i>et al</i> [37]	28	No	Hydrocortisone, desmopressin	18 <sup>th</sup> W TSS	39 <sup>th</sup> W VD	ACTH PA	ER	H
Coyne <i>et al</i> [53]	29	No	Hydrocortisone, desmopressin	14 <sup>th</sup> W TSS	38 <sup>th</sup> W VD	ACTH PA	ER	H
Pinette <i>et al</i> [54]	30	No	Atenolol	16 <sup>th</sup> W TSS	-	ACTH PA	ER	D
Ross <i>et al</i> [55]	31	No	Dexamethasone	18 <sup>th</sup> W TSS	37 <sup>th</sup> W CS	ACTH PA	ER	H
Mellor <i>et al</i> [51]	32	No	Hydrocortisone	Mid-trimester TSS	34 <sup>th</sup> W CS	ACTH PA	ER	H
Karaca <i>et al</i> [15]	33	No	No	11 <sup>th</sup> W TSS	39 <sup>th</sup> W CS	GH PA	ER	H
Jolly <i>et al</i> [56]	34	No	Hydrocortisone,	23 <sup>rd</sup> W TSS	38 <sup>th</sup> W CS	ACTH PA	ER	D

			metformin, labetalol, nifedipine					
Galvão <i>et al</i> [29]	35	No	No	2 <sup>nd</sup> trimester TSS	-	PRL PA	ER	H
Abid <i>et al</i> [30]	36	Bromocriptine	Lisuride hydrogen	27 <sup>th</sup> W TSS	39 <sup>th</sup> W VD	PRL PA	ER	H
Barraud <i>et al</i> [31]	37	Bromocriptine	No	4 <sup>th</sup> Mon TSS	-	PRL PA	ER	H
Freeman <i>et al</i> [32]	38	DDAVP	Hydrocortisone, thyroxine, DDAVP	32 <sup>nd</sup> W TSS	39 <sup>th</sup> W VD	PRL PA	ER	H
Lunardi <i>et al</i> [33]	39	No	No	6 <sup>th</sup> Mon TSS	Full term VD	GH PA	EC	H
Oguz <i>et al</i> [34]	40	No	Levothyroxine	23 <sup>rd</sup> W TSS	37 <sup>th</sup> W CS	PRL PA	ER	H
O'Neal[35]	41	Hydrocortisone, bromocriptine	No	29 <sup>th</sup> W TSS	37 <sup>th</sup> W VD	PA	ER	H

A: Abortion; ACTH: Adrenocorticotrophic hormone; CS: Cesarean section; D: Death; DDAVP: 1-Desamino-8-D-arginine vasopressin; EC: Endocrine control; ER: Endocrine remission; GH: Growth hormone; H: Healthy; I: Infant; LAS: Low Apgar score; M: Maternal; NA: Not available; NF: Nonfunctional; PA: Pituitary adenoma; Post: Postoperatively; Pre: Preoperatively; PRL: Prolactin; R: Recurrence; TSH: Thyroid stimulating hormone; TSS: Transsphenoidal surgery; VD: Vaginal delivery.

38 wk of gestation, and one fetus survived with a low Apgar score after caesarean section at 35 wk of gestation. Twenty-two patients underwent caesarean section (59.5%), and fifteen patients chose vaginal delivery (40.5%). The method of delivery was unknown for 2 patients.

Delivery gestation was not reported in 6 of the 39 patients. Of the remaining 33 patients, gestation ranged from 34 wk to 40 wk, averaging  $37.8 \pm 1.7$  wk. Premature delivery (28 wk  $\leq$  gestation < 37 wk) occurred in 5 cases (15.2%), and full-term delivery (37 wk  $\leq$  gestation < 42 wk) occurred in 28 cases (84.8%).

## DISCUSSION

During pregnancy, physicians may face many challenges when diagnosing and treating PAs. Although conservative treatment is recommended for most pregnant patients with PAs, some patients must accept surgery due to visual defects, severe headaches and high hormone secretion levels that cannot be alleviated after conservative treatment[7,12-15]. We summarized the data of 41 patients with PAs who underwent surgery during pregnancy. To our knowledge, this is the most comprehensive report of surgical treatment of PAs in pregnant patients.

### Clinical characteristics

Here, the three most common clinical symptoms of these patients were visual field defects (68.3%), headaches (65.9%) and vision loss (48.8%). Previous studies showed that the two most common clinical symptoms of PA patients with apoplexy during pregnancy were headaches and visual impairment[19, 34], which is similar to our study.

The pituitary gland and pre-existing PAs may enlarge during pregnancy[2,39], and the risk is greater in patients with macroadenomas than in those with microadenomas[1]. This observation was confirmed here. In prolactinomas, the most common type of PA, the risk of symptomatic tumor enlargement during pregnancy was 27.9% for patients with macroadenomas and only 2.2% for patients with microadenomas[40]. Although 2 patients in our study had pituitary microadenomas, their surgical indications were intractable diabetes insipidus and Cushing syndrome rather than symptomatic tumor enlargement[15,37].

### Conservative treatment during pregnancy

Conservative treatment during pregnancy primarily includes DA treatment for prolactinomas[1] and SSA treatment for GH-secreting PAs[1,7]. Although there is no evidence that SSAs increase the risk of fetal malformation[6,41-43], discontinuation of all medication except DAs during pregnancy is recommended to ensure fetal health to the maximum extent possible[7,8,44]. Resuming other treatments is recommended only when symptoms leading to poor prognoses, such as visual defects or severe headaches, occur. When patients do not achieve significant remission after conservative treatment, clinicians should consider surgical treatment as soon as possible following a multidisciplinary evaluation[8,12,44]. Additionally, to ensure maternal health and fetal development, hormone deficiencies, such as glucocorticoid or thyroxine, should be treated[45].



### Indications for surgery during pregnancy

Patients with macroadenomas have a higher risk of symptomatic progression during pregnancy[1]. However, the size of the PA is not the criterion. The severity of visual defects and headaches should be used as surgical indications for PA during pregnancy[12,13]. Some microadenomas are also associated with adverse effects on maternal and fetal health due to high hormone levels[46]. Based on our results, the surgical indications during pregnancy are summarized as follows.

**Visual defects:** PAs are more likely to compress the optic chiasm during pregnancy, leading to visual defects[2]. When conservative treatment cannot relieve visual impairment, clinicians should conduct a multidisciplinary evaluation to balance visual defects with pregnancy safety and decide whether to treat surgically as soon as possible. Although the recovery rate of the visual field can be as high as 80%[47] to 95.7%[48], the severity and duration of visual impairment are essential factors for postoperative visual prognosis. Irreversible adverse effects caused by severe visual impairment during pregnancy should be avoided[48].

**Severe headache:** Sudden, severe headache is the most common symptom of PA with apoplexy, primarily due to the enlargement of the PA during pregnancy, increased pressure on the sella turcica, and dural pressure[45]. Headache is often accompanied by nausea, vomiting, eye muscle paralysis and impairment of consciousness. Because severe headache can induce contractions, surgery is indicated if the multidisciplinary evaluation considers that the headache is due to mass effect and that pain medication would affect fetal health[49].

**Hormonal abnormalities:** Some PAs, such as ACTH-secreting PA and TSH-secreting PA, can cause ovulation disorders in women of reproductive age[50]. This type of patient should be treated before pregnancy as early as possible. Nevertheless, a few patients have unintended pregnancies after diagnosis[37,51,52] or are diagnosed during pregnancy[53-56]. High hormone secretion during pregnancy is closely related to several complications and poor prognoses[46,50]. Surgical treatment with appropriate timing is the most effective method for reducing hormone levels in such patients[12,17,44].

### Operative timing during pregnancy

The timing of transsphenoidal surgery depends on the potential risks and benefits, including maternal symptoms, fetal safety and gestational weeks, which is the most critical indicator. The spontaneous abortion rate in the first trimester is approximately 12.0% *vs* 5.0% in the second and third trimesters[13]. The overall malformation incidence in pregnancy is 2.0% compared with 3.9% in the first trimester. The incidence of neural tube defects and preterm delivery is highest in the third trimester[57]. In our study, most patients also underwent surgery in the second trimester. Therefore, the second trimester is the best time for PA surgery[12-14,58,59].

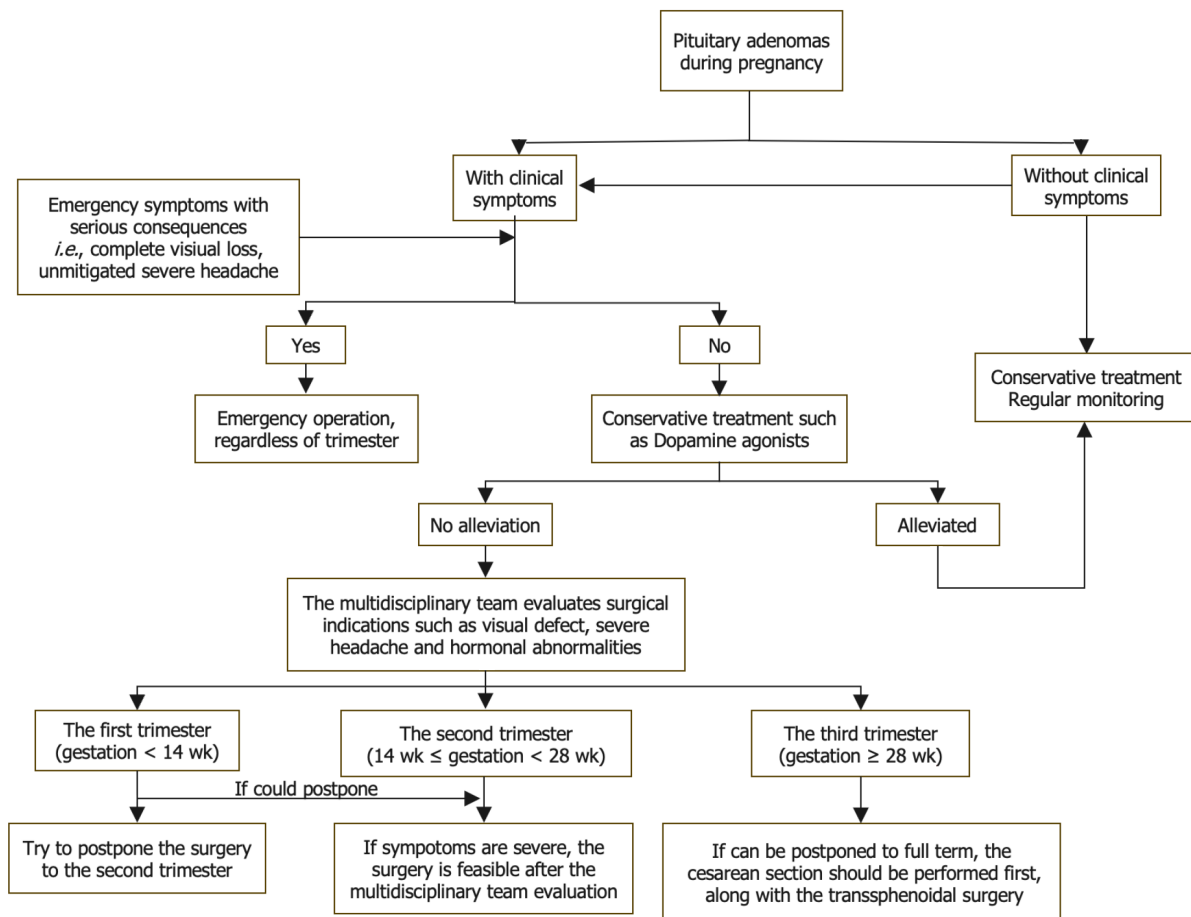
For patients in the first trimester, the surgery should be postponed until the second trimester if possible[14,15]. For patients in the third trimester, Lynch *et al*[60] recommended delaying surgery to 30 wk of gestation if possible because fetal survival can reach 90% after 27 wk of gestation. In comparison, Priddy *et al*[14] suggested induction of labor or caesarean section at 34 wk of gestation followed by surgical treatment, if possible. However, among the 13 patients in this study who underwent surgeries in the third trimester, 12 patients and fetuses were healthy. One fetus survived with a low Apgar score, but the mother was healthy. In this regard, we suggest that the balance of symptom severity and gestational weeks should be considered in the third trimester when glucocorticoids can be administered to promote fetal lung maturation. If symptoms do not worsen significantly, a caesarean section should be performed first. However, surgical treatment should then be performed promptly if symptoms progress significantly (Figure 3).

### Precautions for surgery during pregnancy

**Preoperative:** A professional multidisciplinary team should be established to conduct individualized evaluations prior to surgery for pregnant patients with PAs indicated for surgical treatment. The team should include neurosurgeons, endocrinologists, obstetricians, gynecologists, pediatricians and anesthesiologists[20,59]. MRI must be acquired before the surgery. Although fetal toxicity of gadolinium is not established, MRI without gadolinium enhancement is preferred and is sufficient to make a definitive diagnosis and plan the surgery. Given the teratogenicity of X-rays, computed tomography should be avoided[61].

Preoperative ophthalmic examination is also essential, including examinations of visual acuity, visual field, fundus and retinal nerve fiber layer, and optical coherence tomography of the ganglion cell complex[12]. The ophthalmic examination can roughly predict the postoperative recovery rates for visual impairment[48]. The possible visual sequelae include severe visual impairment, severe visual field defects and severe degeneration of the retinal nerve fiber layer/ganglion cell complex[12].

Preoperative fetal ultrasonography should be performed routinely to evaluate fetal health. Continuous fetal heart rate monitoring is feasible under the proper conditions[12]. The endocrine examination can assess pituitary function. If necessary, relevant deficient hormones should be supplemented. Preoperative operations such as enemas that can induce contractions should be avoided. After



DOI: 10.12998/wjcc.v11.i12.2694 Copyright ©The Author(s) 2023.

Figure 3 Flow diagram of treatment procedures for pituitary adenoma during pregnancy.

evaluation, patients and their families should be fully informed of the risks and benefits of surgery. Written informed consent should be obtained after weighing the advantages and disadvantages.

**Perioperative:** Inhaled anesthetics can reduce uterine tension and increase bleeding risk and cerebral perfusion pressure in a concentration-dependent manner[62]. Total intravenous anesthesia, which is preferred during pregnancy, does not affect uterine tension and can constrict the cerebrovascular system and maintain cerebral perfusion pressure[63]. The United States Food and Drug Administration Class B drugs such as propofol are recommended. However, Class C drugs, which have potential risks but can be used given sufficient expected benefit, should be carefully used after considering the advantages and disadvantages[58].

Intraoperative reduction of cardiac return can lead to severe complications such as hypotension, placental insufficiency and cerebral insufficiency. Therefore, surgeons should lower the left side of the patient below the right side to avoid compression of the inferior vena cava[12,13]. Although there is no optimal cerebral perfusion pressure target, it seems reasonable to control the mean arterial pressure 20% above the baseline[13]. During surgery, the use of diuretics and anticonvulsants should be avoided. If necessary, contractions should be suppressed to protect the fetus[12].

**Postoperative:** Fetal heart rate variation is an essential indicator of fetal health and can indicate fetal distress. Therefore, continuous fetal heart rate monitoring should be performed after the surgery[13]. If postoperative reactions such as nausea, vomiting and headache occur, Class B drugs such as pethidine can be used for symptomatic treatment. Routine ophthalmic examinations should be conducted postoperatively to evaluate visual defect recovery. If no significant improvement is observed, differential diagnoses with other diseases leading to visual impairment, such as optic neuritis, should be considered[21]. Hormone stoss therapy, neurotrophic drugs and other treatments can also be administered.

### Limitations

Although this report is the largest case series of patients undergoing surgical treatment for pituitary tumors during pregnancy, limitations of this study include biases due to the retrospective study design and follow-up differences. In addition, although we have tried to include all cases, the number of cases



is still relatively small. Therefore, we were unable to engage in analysis and discussion according to pathological classification. Prospective and multicenter studies with more cases are needed to further understand the surgical management of pituitary tumors during pregnancy.

## CONCLUSION

The surgical treatment and perioperative management of PAs during pregnancy is complex. The surgical indications and timing issues must be well understood and carefully considered with the cooperation of neurosurgery, endocrinology, obstetrics, anesthesiology, neonatology and other related specialties. In the second and third trimesters, transsphenoidal surgery is a safe and effective approach for emergency treatment during pregnancy after evaluation by a multidisciplinary team. Additionally, for patients with irregular menstrual cycles, pituitary screening is necessary. Women of reproductive age who have been diagnosed with PAs should follow the advice of their endocrinologists and neurosurgeons before pregnancy.

## ARTICLE HIGHLIGHTS

### **Research background**

Although conservative treatment is recommended for pregnant patients with pituitary adenomas (PAs), surgical treatment is occasionally necessary for those with acute symptoms.

### **Research motivation**

Surgical intervention among pregnant patients with PAs has been poorly studied.

### **Research objectives**

To evaluate the surgical indications, timing, complications and perioperative precautions of surgical treatment of PAs during pregnancy and to provide comprehensive guidance.

### **Research methods**

Six patients with PAs who underwent surgical treatment during pregnancy at Peking Union Medical College Hospital between January 1990 and June 2021 were included. Another 35 pregnant patients with PAs reported in the literature were also included. The surgical indications, timing of surgery, improvement of symptoms, postoperative complications and fetal condition were analyzed.

### **Research results**

The 41 enrolled patients had acute symptoms including visual field defects, severe headaches or vision loss requiring emergency pituitary surgeries. PA apoplexies were found in 23 patients. The majority (55.9%) of patients underwent surgery in the second trimester of pregnancy. With the exception of 1 patient who underwent an induced abortion and 1 fetus who died due to a nuchal cord, 39 patients delivered successfully, and 37 of the fetuses were healthy at the most recent follow-up.

### **Research conclusions**

PA surgery during pregnancy is effective and safe during the second and third trimesters. Pregnant patients requiring emergency PA surgery require multidisciplinary evaluation and healthcare management.

### **Research perspectives**

Multicenter, large sample, randomized controlled clinical trials are still needed to improve the standardized guidelines for the surgical treatment of pituitary tumors during pregnancy.

## FOOTNOTES

**Author contributions:** All authors contributed to the study conception and design; Jia XY, Guo XP, Yao Y, Deng K, Lian W and Xing B contributed to material preparation, data collection and analysis; Jia XY wrote the first draft of the manuscript; all authors contributed to critical revision of the manuscript; all authors read and approved the final manuscript.

**Institutional review board statement:** The Institutional Review Board of Peking Union Medical College Hospital provided approval for this study (IRB: I-23PJ338).

**Informed consent statement:** All study participants, or their legal guardian, provided informed written consent prior to study enrollment. Informed written consent was obtained from the patients for publication of this report and any accompanying images.

**Conflict-of-interest statement:** All the authors report no relevant conflicts of interest for this article.

**Data sharing statement:** No additional data are available.

**Open-Access:** This article is an open-access article that was selected by an in-house editor and fully peer-reviewed by external reviewers. It is distributed in accordance with the Creative Commons Attribution NonCommercial (CC BY-NC 4.0) license, which permits others to distribute, remix, adapt, build upon this work non-commercially, and license their derivative works on different terms, provided the original work is properly cited and the use is non-commercial. See: <https://creativecommons.org/licenses/by-nc/4.0/>

**Country/Territory of origin:** China

**ORCID number:** Xin-Yu Jia 0000-0001-5282-5053; Xiao-Peng Guo 0000-0002-4183-5560; Yong Yao 0000-0001-6982-8832; Kan Deng 0000-0001-9571-3705; Wei Lian 0000-0002-8023-5138; Bing Xing 0000-0002-3864-5168.

**Corresponding Author's Membership in Professional Societies:** China Pituitary Adenoma Specialist Council.

**S-Editor:** Gao CC

**L-Editor:** A

**P-Editor:** Zhang XD

## REFERENCES

- 1 Woodmansee WW. Pituitary Disorders in Pregnancy. *Neurol Clin* 2019; **37**: 63-83 [PMID: 30470276 DOI: 10.1016/j.neucl.2018.09.009]
- 2 Dinç H, Esen F, Demirci A, Sari A, Resit Gümele H. Pituitary dimensions and volume measurements in pregnancy and post partum. MR assessment. *Acta Radiol* 1998; **39**: 64-69 [PMID: 9498873 DOI: 10.1080/02841859809172152]
- 3 Karaca Z, Tanriverdi F, Unluhizarci K, Kelestimur F. Pregnancy and pituitary disorders. *Eur J Endocrinol* 2010; **162**: 453-475 [PMID: 19934270 DOI: 10.1530/EJE-09-0923]
- 4 Casanueva FF, Molitch ME, Schlechte JA, Abs R, Bonert V, Bronstein MD, Brue T, Cappabianca P, Colao A, Fahlbusch R, Fideleff H, Hadani M, Kelly P, Kleinberg D, Laws E, Marek J, Scanlon M, Sobrinho LG, Wass JA, Giustina A. Guidelines of the Pituitary Society for the diagnosis and management of prolactinomas. *Clin Endocrinol (Oxf)* 2006; **65**: 265-273 [PMID: 16886971 DOI: 10.1111/j.1365-2265.2006.02562.x]
- 5 Grand'Maison S, Weber F, Bédard MJ, Mahone M, Godbout A. Pituitary apoplexy in pregnancy: A case series and literature review. *Obstet Med* 2015; **8**: 177-183 [PMID: 27512477 DOI: 10.1177/1753495X15598917]
- 6 Molitch ME. Endocrinology in pregnancy: management of the pregnant patient with a prolactinoma. *Eur J Endocrinol* 2015; **172**: R205-R213 [PMID: 25805896 DOI: 10.1530/EJE-14-0848]
- 7 Laway BA. Pregnancy in acromegaly. *Ther Adv Endocrinol Metab* 2015; **6**: 267-272 [PMID: 26623004 DOI: 10.1177/2042018815603927]
- 8 Muhammad A, Neggers SJ, van der Lely AJ. Pregnancy and acromegaly. *Pituitary* 2017; **20**: 179-184 [PMID: 27568329 DOI: 10.1007/s11102-016-0740-3]
- 9 Guo X, Guo Y, Xing B, Ma W. The Initial Stage of Neurosurgery in China: Contributions from Peking Union Medical College Hospital. *World Neurosurg* 2021; **149**: 32-37 [PMID: 33388461 DOI: 10.1016/j.wneu.2020.12.122]
- 10 Wilson JD. Peking Union Medical College Hospital, a palace of endocrine treasures. *J Clin Endocrinol Metab* 1993; **76**: 815-816 [PMID: 8473387 DOI: 10.1210/jcem.76.4.8473387]
- 11 Sant' Anna BG, Musolino NRC, Gadelha MR, Marques C, Castro M, Elias PCL, Vilar L, Lyra R, Martins MRA, Quidute ARP, Abucham J, Nazato D, Garmes HM, Fontana MLC, Boguszewski CL, Bueno CB, Czepielewski MA, Portes ES, Nunes-Nogueira VS, Ribeiro-Oliveira A Jr, Francisco RPV, Bronstein MD, Glezer A. A Brazilian multicentre study evaluating pregnancies induced by cabergoline in patients harboring prolactinomas. *Pituitary* 2020; **23**: 120-128 [PMID: 31728906 DOI: 10.1007/s11102-019-01008-z]
- 12 Graillon T, Cuny T, Castinetti F, Courbière B, Cousin M, Albarel F, Morange I, Bruder N, Brue T, Dufour H. Surgical indications for pituitary tumors during pregnancy: a literature review. *Pituitary* 2020; **23**: 189-199 [PMID: 31691893 DOI: 10.1007/s11102-019-01004-3]
- 13 Chowdhury T, Chowdhury M, Schaller B, Cappellani RB, Daya J. Perioperative considerations for neurosurgical procedures in the gravid patient: Continuing Professional Development. *Can J Anaesth* 2013; **60**: 1139-1155 [PMID: 24129743 DOI: 10.1007/s12630-013-0031-7]
- 14 Priddy BH, Otto BA, Carrau RL, Prevedello DM. Management of Skull Base Tumors in the Obstetric Population: A Case Series. *World Neurosurg* 2018; **113**: e373-e382 [PMID: 29454125 DOI: 10.1016/j.wneu.2018.02.038]
- 15 Karaca Z, Yarmar S, Ozbas I, Kadioglu P, Akturk M, Kilicli F, Dokmetas HS, Colak R, Atmaca H, Canturk Z, Altuntas Y, Ozbey N, Hatipoglu N, Tanriverdi F, Unluhizarci K, Kelestimur F. How does pregnancy affect the patients with pituitary adenomas: a study on 113 pregnancies from Turkey. *J Endocrinol Invest* 2018; **41**: 129-141 [PMID: 28634705]

- DOI: [10.1007/s40618-017-0709-8](https://doi.org/10.1007/s40618-017-0709-8)]
- 16 **Jallad RS**, Shimon I, Fraenkel M, Medvedovsky V, Akirov A, Duarte FH, Bronstein MD. Outcome of pregnancies in a large cohort of women with acromegaly. *Clin Endocrinol (Oxf)* 2018; **88**: 896-907 [PMID: [29574986](https://pubmed.ncbi.nlm.nih.gov/29574986/) DOI: [10.1111/cen.13599](https://doi.org/10.1111/cen.13599)]
- 17 **Chaiamnuay S**, Moster M, Katz MR, Kim YN. Successful management of a pregnant woman with a TSH secreting pituitary adenoma with surgical and medical therapy. *Pituitary* 2003; **6**: 109-113 [PMID: [14703021](https://pubmed.ncbi.nlm.nih.gov/14703021/) DOI: [10.1023/b:pitu.0000004802.47010.00](https://doi.org/10.1023/b:pitu.0000004802.47010.00)]
- 18 **Guven S**, Durukan T, Berker M, Basaran A, Saygan-Karamursel B, Palaoglu S. A case of acromegaly in pregnancy: concomitant transsphenoidal adenomectomy and cesarean section. *J Matern Fetal Neonatal Med* 2006; **19**: 69-71 [PMID: [16492596](https://pubmed.ncbi.nlm.nih.gov/16492596/) DOI: [10.1080/14767050500434021](https://doi.org/10.1080/14767050500434021)]
- 19 **Jemel M**, Kandara H, Riahi M, Gharbi R, Nagi S, Kamoun I. Gestational pituitary apoplexy: Case series and review of the literature. *J Gynecol Obstet Hum Reprod* 2019; **48**: 873-881 [PMID: [31059861](https://pubmed.ncbi.nlm.nih.gov/31059861/) DOI: [10.1016/j.jogoh.2019.05.005](https://doi.org/10.1016/j.jogoh.2019.05.005)]
- 20 **Xia Y**, Ma X, Griffiths BB, Luo Y. Neurosurgical anesthesia for a pregnant woman with macroprolactinoma: A case report. *Medicine (Baltimore)* 2018; **97**: e12360 [PMID: [30212994](https://pubmed.ncbi.nlm.nih.gov/30212994/) DOI: [10.1097/MD.00000000000012360](https://doi.org/10.1097/MD.00000000000012360)]
- 21 **Yamaguchi R**, Kohga H, Tosaka M, Sekine A, Mizushima K, Harigaya Y, Yoshimoto Y. A Case of Optic Neuritis Concomitant with Pituitary Tumor During Pregnancy. *World Neurosurg* 2016; **93**: 488.e1-488.e4 [PMID: [27373939](https://pubmed.ncbi.nlm.nih.gov/27373939/) DOI: [10.1016/j.wneu.2016.06.103](https://doi.org/10.1016/j.wneu.2016.06.103)]
- 22 **Tandon A**, Alzate J, LaSala P, Fried MP. Endoscopic Endonasal Transsphenoidal Resection for Pituitary Apoplexy during the Third Trimester of Pregnancy. *Surg Res Pract* 2014; **2014**: 397131 [PMID: [25374951](https://pubmed.ncbi.nlm.nih.gov/25374951/) DOI: [10.1155/2014/397131](https://doi.org/10.1155/2014/397131)]
- 23 **Gondim J**, Ramos Júnior F, Pinheiro I, Schops M, Tella Júnior OI. Minimally invasive pituitary surgery in a hemorrhagic necrosis of adenoma during pregnancy. *Minim Invasive Neurosurg* 2003; **46**: 173-176 [PMID: [12872196](https://pubmed.ncbi.nlm.nih.gov/12872196/) DOI: [10.1055/s-2003-40734](https://doi.org/10.1055/s-2003-40734)]
- 24 **Witek P**, Zieliński G, Maksymowicz M, Zgliczyński W. Transsphenoidal surgery for a life-threatening prolactinoma apoplexy during pregnancy. *Neuro Endocrinol Lett* 2012; **33**: 483-488 [PMID: [23090264](https://pubmed.ncbi.nlm.nih.gov/23090264/)]
- 25 **Kita D**, Hayashi Y, Sano H, Takamura T, Tachibana O, Hamada J. Postoperative diabetes insipidus associated with pituitary apoplexy during pregnancy. *Neuro Endocrinol Lett* 2012; **33**: 107-112 [PMID: [22592189](https://pubmed.ncbi.nlm.nih.gov/22592189/)]
- 26 **Nossek E**, Ekstein M, Rimon E, Kupfermanc MJ, Ram Z. Neurosurgery and pregnancy. *Acta Neurochir (Wien)* 2011; **153**: 1727-1735 [PMID: [21660423](https://pubmed.ncbi.nlm.nih.gov/21660423/) DOI: [10.1007/s00701-011-1061-y](https://doi.org/10.1007/s00701-011-1061-y)]
- 27 **Iuliano S**, Laws ER Jr. Management of pituitary tumors in pregnancy. *Semin Neurol* 2011; **31**: 423-428 [PMID: [22113515](https://pubmed.ncbi.nlm.nih.gov/22113515/) DOI: [10.1055/s-0031-1293542](https://doi.org/10.1055/s-0031-1293542)]
- 28 **Hayes AR**, O'Sullivan AJ, Davies MA. A case of pituitary apoplexy in pregnancy. *Endocrinol Diabetes Metab Case Rep* 2014; **2014**: 140043 [PMID: [25031837](https://pubmed.ncbi.nlm.nih.gov/25031837/) DOI: [10.1530/EDM-14-0043](https://doi.org/10.1530/EDM-14-0043)]
- 29 **Galvão A**, Gonçalves D, Moreira M, Inocêncio G, Silva C, Braga J. Prolactinoma and pregnancy - a series of cases including pituitary apoplexy. *J Obstet Gynaecol* 2017; **37**: 284-287 [PMID: [27866462](https://pubmed.ncbi.nlm.nih.gov/27866462/) DOI: [10.1080/01443615.2016.1233946](https://doi.org/10.1080/01443615.2016.1233946)]
- 30 **Abid S**, Sadiq I, Anwar S, Hafeez M, Butt F. Pregnancy with macroprolactinoma. *J Coll Physicians Surg Pak* 2008; **18**: 787-788 [PMID: [19032898](https://pubmed.ncbi.nlm.nih.gov/19032898/)]
- 31 **Barraud S**, Guédra L, Delemer B, Raverot G, Ancelle D, Fèvre A, Jouanneau E, Litré CF, Wolak-Thierry A, Borson-Chazot F, Decoudier B. Evolution of macroprolactinomas during pregnancy: A cohort study of 85 pregnancies. *Clin Endocrinol (Oxf)* 2020; **92**: 421-427 [PMID: [31957911](https://pubmed.ncbi.nlm.nih.gov/31957911/) DOI: [10.1111/cen.14162](https://doi.org/10.1111/cen.14162)]
- 32 **Freeman R**, Wezenter B, Silverstein M, Kuo D, Weiss KL, Kantrowitz AB, Schubart UK. Pregnancy-associated subacute hemorrhage into a prolactinoma resulting in diabetes insipidus. *Fertil Steril* 1992; **58**: 427-429 [PMID: [1633915](https://pubmed.ncbi.nlm.nih.gov/1633915/) DOI: [10.1016/s0015-0282\(16\)55219-4](https://doi.org/10.1016/s0015-0282(16)55219-4)]
- 33 **Lunardi P**, Rizzo A, Missori P, Fraioli B. Pituitary apoplexy in an acromegalic woman operated on during pregnancy by transphenoidal approach. *Int J Gynaecol Obstet* 1991; **34**: 71-74 [PMID: [1671026](https://pubmed.ncbi.nlm.nih.gov/1671026/) DOI: [10.1016/0020-7292\(91\)90542-d](https://doi.org/10.1016/0020-7292(91)90542-d)]
- 34 **Oguz SH**, Soylemezoglu F, Dagdelen S, Erbas T. A case of atypical macroprolactinoma presenting with pituitary apoplexy during pregnancy and review of the literature. *Gynecol Endocrinol* 2020; **36**: 109-116 [PMID: [31389277](https://pubmed.ncbi.nlm.nih.gov/31389277/) DOI: [10.1080/09513590.2019.1650339](https://doi.org/10.1080/09513590.2019.1650339)]
- 35 **O'Neal MA**. Headaches complicating pregnancy and the postpartum period. *Pract Neurol* 2017; **17**: 191-202 [PMID: [28473606](https://pubmed.ncbi.nlm.nih.gov/28473606/) DOI: [10.1136/practneurol-2016-001589](https://doi.org/10.1136/practneurol-2016-001589)]
- 36 **Parihar V**, Yadav YR, Sharma D. Pituitary apoplexy in a pregnant woman. *Ann Indian Acad Neurol* 2009; **12**: 54-55 [PMID: [20151014](https://pubmed.ncbi.nlm.nih.gov/20151014/)]
- 37 **Abbassy M**, Kshetry VR, Hamrahian AH, Johnston PC, Dobri GA, Avitsian R, Woodard TD, Recinos PF. Surgical management of recurrent Cushing's disease in pregnancy: A case report. *Surg Neurol Int* 2015; **6**: S640-S645 [PMID: [26682090](https://pubmed.ncbi.nlm.nih.gov/26682090/) DOI: [10.4103/2152-7806.170472](https://doi.org/10.4103/2152-7806.170472)]
- 38 **Zhong HP**, Tang H, Zhang Y, Luo Y, Yao H, Cheng Y, Gu WT, Wei YX, Wu ZB. Multidisciplinary team efforts improve the surgical outcomes of sellar region lesions during pregnancy. *Endocrine* 2019; **66**: 477-484 [PMID: [31422527](https://pubmed.ncbi.nlm.nih.gov/31422527/) DOI: [10.1007/s12020-019-02054-0](https://doi.org/10.1007/s12020-019-02054-0)]
- 39 **Inoue T**, Hotta A, Awai M, Tanihara H. Loss of vision due to a physiologic pituitary enlargement during normal pregnancy. *Graefes Arch Clin Exp Ophthalmol* 2007; **245**: 1049-1051 [PMID: [17177036](https://pubmed.ncbi.nlm.nih.gov/17177036/) DOI: [10.1007/s00417-006-0491-3](https://doi.org/10.1007/s00417-006-0491-3)]
- 40 **Molitch ME**. Prolactinomas and pregnancy. *Clin Endocrinol (Oxf)* 2010; **73**: 147-148 [PMID: [20550542](https://pubmed.ncbi.nlm.nih.gov/20550542/) DOI: [10.1111/j.1365-2265.2010.03823.x](https://doi.org/10.1111/j.1365-2265.2010.03823.x)]
- 41 **Lebbe M**, Hubinont C, Bernard P, Maïter D. Outcome of 100 pregnancies initiated under treatment with cabergoline in hyperprolactinaemic women. *Clin Endocrinol (Oxf)* 2010; **73**: 236-242 [PMID: [20455894](https://pubmed.ncbi.nlm.nih.gov/20455894/) DOI: [10.1111/j.1365-2265.2010.03808.x](https://doi.org/10.1111/j.1365-2265.2010.03808.x)]
- 42 **Stalldecker G**, Mallea-Gil MS, Guitelman M, Alfieri A, Ballarino MC, Boero L, Chervin A, Danilowicz K, Diez S, Fainstein-Day P, García-Basavilbaso N, Glerean M, Gollan V, Katz D, Loto MG, Manavela M, Rogozinski AS, Servidio M, Vitale NM. Effects of cabergoline on pregnancy and embryo-fetal development: retrospective study on 103 pregnancies

- and a review of the literature. *Pituitary* 2010; **13**: 345-350 [PMID: 20676778 DOI: 10.1007/s11102-010-0243-6]
- 43 **Caron P**, Broussaud S, Bertherat J, Borson-Chazot F, Brue T, Cortet-Rudelli C, Chanson P. Acromegaly and pregnancy: a retrospective multicenter study of 59 pregnancies in 46 women. *J Clin Endocrinol Metab* 2010; **95**: 4680-4687 [PMID: 20660047 DOI: 10.1210/jc.2009-2331]
  - 44 **Bronstein MD**, Paraiba DB, Jallad RS. Management of pituitary tumors in pregnancy. *Nat Rev Endocrinol* 2011; **7**: 301-310 [PMID: 21403665 DOI: 10.1038/nrendo.2011.38]
  - 45 **Piantanida E**, Gallo D, Lombardi V, Tanda ML, Lai A, Ghezzi F, Minotto R, Tabano A, Cerati M, Azzolini C, Balbi S, Baruzzi F, Sessa F, Bartalena L. Pituitary apoplexy during pregnancy: a rare, but dangerous headache. *J Endocrinol Invest* 2014; **37**: 789-797 [PMID: 24916564 DOI: 10.1007/s40618-014-0095-4]
  - 46 **Bronstein MD**, Machado MC, Fragoso MC. MANAGEMENT OF ENDOCRINE DISEASE: Management of pregnant patients with Cushing's syndrome. *Eur J Endocrinol* 2015; **173**: R85-R91 [PMID: 25872515 DOI: 10.1530/EJE-14-1130]
  - 47 **Muskens IS**, Zamanipoor Najafabadi AH, Briceno V, Lamba N, Senders JT, van Furth WR, Verstegen MJT, Smith TRS, Mekary RA, Eenhorst CAE, Broekman MLD. Visual outcomes after endoscopic endonasal pituitary adenoma resection: a systematic review and meta-analysis. *Pituitary* 2017; **20**: 539-552 [PMID: 28643208 DOI: 10.1007/s11102-017-0815-9]
  - 48 **Barzaghi LR**, Medone M, Losa M, Bianchi S, Giovanelli M, Mortini P. Prognostic factors of visual field improvement after trans-sphenoidal approach for pituitary macroadenomas: review of the literature and analysis by quantitative method. *Neurosurg Rev* 2012; **35**: 369-78; discussion 378 [PMID: 22080165 DOI: 10.1007/s10143-011-0365-y]
  - 49 **Negro A**, Delaruelle Z, Ivanova TA, Khan S, Ornello R, Raffaelli B, Terrin A, Reuter U, Mitsikostas DD; European Headache Federation School of Advanced Studies (EHF-SAS). Headache and pregnancy: a systematic review. *J Headache Pain* 2017; **18**: 106 [PMID: 29052046 DOI: 10.1186/s10194-017-0816-0]
  - 50 **Kyriakos G**, Farmaki P, Voutyritsa E, Patsouras A, Quiles-Sánchez LV, Damaskos C, Stelianidi A, Pastor-Alcaraz A, Palomero-Entrenas P, Diamantis E. Cushing's syndrome in pregnancy: a review of reported cases. *Endokrynol Pol* 2021; **72**: 64-72 [PMID: 33749819 DOI: 10.5603/EP.a2020.0089]
  - 51 **Mellor A**, Harvey RD, Pobereskin LH, Sneyd JR. Cushing's disease treated by trans-sphenoidal selective adenectomy in mid-pregnancy. *Br J Anaesth* 1998; **80**: 850-852 [PMID: 9771323 DOI: 10.1093/bja/80.6.850]
  - 52 **Boronat M**, Marrero D, López-Plasencia Y, Barber M, Schamann Y, Nóvoa FJ. Successful outcome of pregnancy in a patient with Cushing's disease under treatment with ketoconazole during the first trimester of gestation. *Gynecol Endocrinol* 2011; **27**: 675-677 [PMID: 20923280 DOI: 10.3109/09513590.2010.521268]
  - 53 **Coyne TJ**, Atkinson RL, Prins JB. Adrenocorticotrophic hormone-secreting pituitary tumor associated with pregnancy: case report. *Neurosurgery* 1992; **31**: 953-5; discussion 955 [PMID: 1331848 DOI: 10.1227/00006123-199211000-00021]
  - 54 **Pinette MG**, Pan YQ, Oppenheim D, Pinette SG, Blackstone J. Bilateral inferior petrosal sinus corticotropin sampling with corticotropin-releasing hormone stimulation in a pregnant patient with Cushing's syndrome. *Am J Obstet Gynecol* 1994; **171**: 563-564 [PMID: 8059845 DOI: 10.1016/0002-9378(94)90303-4]
  - 55 **Ross RJ**, Chew SL, Perry L, Erskine K, Medbak S, Afshar F. Diagnosis and selective cure of Cushing's disease during pregnancy by transsphenoidal surgery. *Eur J Endocrinol* 1995; **132**: 722-726 [PMID: 7788013 DOI: 10.1530/eje.0.1320722]
  - 56 **Jolly K**, Darr A, Arlt W, Ahmed S, Karavitaki N. Surgery for Cushing's disease in pregnancy: our experience and a literature review. *Ann R Coll Surg Engl* 2019; **101**: e26-e31 [PMID: 30286651 DOI: 10.1308/rcsann.2018.0175]
  - 57 **Mazze RI**, Källén B. Reproductive outcome after anesthesia and operation during pregnancy: a registry study of 5405 cases. *Am J Obstet Gynecol* 1989; **161**: 1178-1185 [PMID: 2589435 DOI: 10.1016/0002-9378(89)90659-5]
  - 58 **Marulasiddappa V**, Raghavendra B, Nethra H. Anaesthetic management of a pregnant patient with intracranial space occupying lesion for craniotomy. *Indian J Anaesth* 2014; **58**: 739-741 [PMID: 25624540 DOI: 10.4103/0019-5049.147170]
  - 59 **Cohen-Gadol AA**, Friedman JA, Friedman JD, Tubbs RS, Munis JR, Meyer FB. Neurosurgical management of intracranial lesions in the pregnant patient: a 36-year institutional experience and review of the literature. *J Neurosurg* 2009; **111**: 1150-1157 [PMID: 19408979 DOI: 10.3171/2009.3.JNS081160]
  - 60 **Lynch JC**, Gouvêa F, Emmerich JC, Kokinovrachos G, Pereira C, Welling L, Kislakov S. Management strategy for brain tumour diagnosed during pregnancy. *Br J Neurosurg* 2011; **25**: 225-230 [PMID: 20825287 DOI: 10.3109/02688697.2010.508846]
  - 61 **Jain C**. ACOG Committee Opinion No. 723: Guidelines for Diagnostic Imaging During Pregnancy and Lactation. *Obstet Gynecol* 2019; **133**: 186 [PMID: 30575654 DOI: 10.1097/AOG.0000000000003049]
  - 62 **Yoo KY**, Lee JC, Yoon MH, Shin MH, Kim SJ, Kim YH, Song TB, Lee J. The effects of volatile anesthetics on spontaneous contractility of isolated human pregnant uterine muscle: a comparison among sevoflurane, desflurane, isoflurane, and halothane. *Anesth Analg* 2006; **103**: 443-447, table of contents [PMID: 16861431 DOI: 10.1213/01.ane.0000236785.17606.58]
  - 63 **Cole CD**, Gottfried ON, Gupta DK, Couldwell WT. Total intravenous anesthesia: advantages for intracranial surgery. *Neurosurgery* 2007; **61**: 369-77; discussion 377 [PMID: 18091252 DOI: 10.1227/01.neu.0000303996.74526.30]



Published by **Baishideng Publishing Group Inc**  
7041 Koll Center Parkway, Suite 160, Pleasanton, CA 94566, USA

**Telephone:** +1-925-3991568

**E-mail:** [bpgoffice@wjgnet.com](mailto:bpgoffice@wjgnet.com)

**Help Desk:** <https://www.f6publishing.com/helpdesk>

<https://www.wjgnet.com>

