

World Journal of *Clinical Cases*

World J Clin Cases 2023 May 6; 11(13): 2855-3113



Contents

Thrice Monthly Volume 11 Number 13 May 6, 2023

OPINION REVIEW

- 2855 Long-term implications of fetal growth restriction
D'Agostin M, Di Sipio Morgia C, Vento G, Nobile S

REVIEW

- 2864 Appraisal of gastric stump carcinoma and current state of affairs
Shukla A, Kalayarasan R, Gnanasekaran S, Pottakkat B
- 2874 Burden of severe infections due to carbapenem-resistant pathogens in intensive care unit
Pace MC, Corrente A, Passavanti MB, Sansone P, Petrou S, Leone S, Fiore M

MINIREVIEWS

- 2890 Individualized diabetes care: Lessons from the real-world experience
Khor XY, Pappachan JM, Jeeyavudeen MS
- 2903 Clinical management of dural defects: A review
Dong RP, Zhang Q, Yang LL, Cheng XL, Zhao JW
- 2916 Potential impact of music interventions in managing diabetic conditions
Eseadi C, Amedu AN
- 2925 Implications of obesity and adiposopathy on respiratory infections; focus on emerging challenges
Lempesis IG, Georgakopoulou VE

ORIGINAL ARTICLE

Case Control Study

- 2934 Association of C-reactive protein and complement factor H gene polymorphisms with risk of lupus nephritis in Chinese population
Li QY, Lv JM, Liu XL, Li HY, Yu F

Retrospective Study

- 2945 Comparison of the application value of transvaginal ultrasound and transabdominal ultrasound in the diagnosis of ectopic pregnancy
Hu HJ, Sun J, Feng R, Yu L

Observational Study

- 2956 Assessment of knowledge, cultural beliefs, and behavior regarding medication safety among residents in Harbin, China
Liu XT, Wang N, Zhu LQ, Wu YB

SYSTEMATIC REVIEWS

- 2966** Palliative oral care in terminal cancer patients: Integrated review
Silva ARP, Bodanezi AV, Chrun ES, Lisboa ML, de Camargo AR, Munhoz EA

META-ANALYSIS

- 2981** Effect of preoperative inspiratory muscle training on postoperative outcomes in patients undergoing cardiac surgery: A systematic review and meta-analysis
Wang J, Wang YQ, Shi J, Yu PM, Guo YQ
- 2992** Efficacy and safety of intravenous tranexamic acid in total shoulder arthroplasty: A meta-analysis
Deng HM

CASE REPORT

- 3002** Awake laparoscopic cholecystectomy: A case report and review of literature
Mazzone C, Sofia M, Sarv   I, Litrico G, Di Stefano AML, La Greca G, Latteri S
- 3010** Bilateral malignant glaucoma with bullous keratopathy: A case report
Ma YB, Dang YL
- 3017** Finger compartment syndrome due to a high-pressure washer injury: A case report
Choi JH, Choi SY, Hwang JH, Kim KS, Lee SY
- 3022** Primary dedifferentiated chondrosarcoma of the lung with a 4-year history of breast cancer: A case report
Wen H, Gong FJ, Xi JM
- 3029** Importance of proper ventilator support and pulmonary rehabilitation in obese patients with heart failure: Two case reports
Lim EH, Park SH, Won YH
- 3038** Multiple flexor tendon ruptures due to osteochondroma of the hamate: A case report
Kwon TY, Lee YK
- 3045** Fractional flow reserve measured *via* left internal mammary artery after coronary artery bypass grafting: Two case reports
Zhang LY, Gan YR, Wang YZ, Xie DX, Kou ZK, Kou XQ, Zhang YL, Li B, Mao R, Liang TX, Xie J, Jin JJ, Yang JM
- 3052** Uterine artery embolization combined with percutaneous microwave ablation for the treatment of prolapsed uterine submucosal leiomyoma: A case report
Zhang HL, Yu SY, Cao CW, Zhu JE, Li JX, Sun LP, Xu HX
- 3062** Metachronous urothelial carcinoma in the renal pelvis, bladder, and urethra: A case report
Zhang JQ, Duan Y, Wang K, Zhang XL, Jiang KH
- 3070** Unusual phenomenon-“polyp” arising from a diverticulum: A case report
Liew JJJ, Lim WS, Koh FH

- 3076** Idiopathic steno-occlusive disease with bilateral internal carotid artery occlusion: A Case Report
Hamed SA, Yousef HA
- 3086** Solitary acral persistent papular mucinosis nodule: A case report and summary of eight Korean cases
Park YJ, Shin HY, Choi WK, Lee AY, Lee SH, Hong JS
- 3092** Eosinophilic fasciitis difficult to differentiate from scleroderma: A case report
Lan TY, Wang ZH, Kong WP, Wang JP, Zhang N, Jin DE, Luo J, Tao QW, Yan ZR
- 3099** Misdiagnosis of scalp angiosarcoma: A case report
Yan ZH, li ZL, Chen XW, Lian YW, Liu LX, Duan HY
- 3105** Discrepancy among microsatellite instability detection methodologies in non-colorectal cancer: Report of 3 cases
Şenocak Taşçı E, Yıldız İ, Erdamar S, Özer L

ABOUT COVER

Editorial Board Member of *World Journal of Clinical Cases*, Jina Yun, MD, PhD, Assistant Professor, Division of Hematology-Oncology, Department of Internal Medicine, Soonchunhyang University Bucheon Hospital, Soonchunhyang University School of Medicine, Bucheon 14584, South Korea. 19983233@schmc.ac.kr

AIMS AND SCOPE

The primary aim of *World Journal of Clinical Cases* (WJCC, *World J Clin Cases*) is to provide scholars and readers from various fields of clinical medicine with a platform to publish high-quality clinical research articles and communicate their research findings online.

WJCC mainly publishes articles reporting research results and findings obtained in the field of clinical medicine and covering a wide range of topics, including case control studies, retrospective cohort studies, retrospective studies, clinical trials studies, observational studies, prospective studies, randomized controlled trials, randomized clinical trials, systematic reviews, meta-analysis, and case reports.

INDEXING/ABSTRACTING

The WJCC is now abstracted and indexed in Science Citation Index Expanded (SCIE, also known as SciSearch®), Journal Citation Reports/Science Edition, Current Contents®/Clinical Medicine, PubMed, PubMed Central, Scopus, Reference Citation Analysis, China National Knowledge Infrastructure, China Science and Technology Journal Database, and Superstar Journals Database. The 2022 Edition of Journal Citation Reports® cites the 2021 impact factor (IF) for WJCC as 1.534; IF without journal self cites: 1.491; 5-year IF: 1.599; Journal Citation Indicator: 0.28; Ranking: 135 among 172 journals in medicine, general and internal; and Quartile category: Q4. The WJCC's CiteScore for 2021 is 1.2 and Scopus CiteScore rank 2021: General Medicine is 443/826.

RESPONSIBLE EDITORS FOR THIS ISSUE

Production Editor: Si Zhao; Production Department Director: Xiang Li; Editorial Office Director: Jin-Lei Wang.

NAME OF JOURNAL

World Journal of Clinical Cases

ISSN

ISSN 2307-8960 (online)

LAUNCH DATE

April 16, 2013

FREQUENCY

Thrice Monthly

EDITORS-IN-CHIEF

Bao-Gan Peng, Jerzy Tadeusz Chudek, George Kontogeorgos, Maurizio Serati, Ja Hyeon Ku

EDITORIAL BOARD MEMBERS

<https://www.wjgnet.com/2307-8960/editorialboard.htm>

PUBLICATION DATE

May 6, 2023

COPYRIGHT

© 2023 Baishideng Publishing Group Inc

INSTRUCTIONS TO AUTHORS

<https://www.wjgnet.com/bpg/gerinfo/204>

GUIDELINES FOR ETHICS DOCUMENTS

<https://www.wjgnet.com/bpg/GerInfo/287>

GUIDELINES FOR NON-NATIVE SPEAKERS OF ENGLISH

<https://www.wjgnet.com/bpg/gerinfo/240>

PUBLICATION ETHICS

<https://www.wjgnet.com/bpg/GerInfo/288>

PUBLICATION MISCONDUCT

<https://www.wjgnet.com/bpg/gerinfo/208>

ARTICLE PROCESSING CHARGE

<https://www.wjgnet.com/bpg/gerinfo/242>

STEPS FOR SUBMITTING MANUSCRIPTS

<https://www.wjgnet.com/bpg/GerInfo/239>

ONLINE SUBMISSION

<https://www.f6publishing.com>



Unusual phenomenon-“polyp” arising from a diverticulum: A case report

Jacqueline Jin Li Liew, Wei Shyann Lim, Frederick H Koh

Specialty type: Medicine, research and experimental

Provenance and peer review: Unsolicited article; Externally peer reviewed.

Peer-review model: Single blind

Peer-review report's scientific quality classification

Grade A (Excellent): 0
Grade B (Very good): B, B
Grade C (Good): C
Grade D (Fair): 0
Grade E (Poor): 0

P-Reviewer: Bustamante-Lopez LA, Brazil; Zhang G, China; Zhao S, China

Received: January 31, 2023

Peer-review started: January 31, 2023

First decision: February 17, 2023

Revised: March 1, 2023

Accepted: April 4, 2023

Article in press: April 4, 2023

Published online: May 6, 2023



Jacqueline Jin Li Liew, Wei Shyann Lim, Yong Loo Lin School of Medicine, National University of Singapore, Singapore 117597, Singapore

Frederick H Koh, Colorectal Service, Department of General Surgery, Sengkang General Hospital, Singapore 544886, Singapore

Corresponding author: Frederick H Koh, FRCS (Ed), MBBS, MMed, Assistant Professor, Colorectal Service, Department of General Surgery, Sengkang General Hospital, 110 Sengkang E Way, Singapore 544886, Singapore. frederickkohhx@gmail.com

Abstract

BACKGROUND

Sealed perforation of colonic diverticulum is a common clinical condition and may be differentiated from an underlying malignant perforation using interval endoscopy. We present an uncommon colonoscopy finding of a healed diverticular perforation, mimicking a polyp, 6 wk post-diverticulitis-something that has not been reported in literature. We aim to shed light on the likely process that resulted in the trompe l'œil after diverticulitis. This also introduces the possibility of more targeted colonic resection in the event of a similar recurrence.

CASE SUMMARY

A middle-aged Chinese female presented with a 3-d history of non-colicky left iliac fossa pain. It was associated with fever (T_{\max} 37.6 °C), non-bloody diarrhoea and non-bloody, non-bilious vomiting. She had a history of Type 2 diabetes mellitus, well controlled on metformin. Tenderness was noted on the left iliac fossa region with no guarding or mass. Total white cell count ($11.45 \times 10^9/L$) and C-reactive protein levels (213.9 mg/L) were elevated. Computed tomography imaging of the abdomen revealed pericolic fat stranding and extraluminal air pockets fluid density with peritoneal thickening at the sigmoid colon, likely representing a sealed perforation. Six weeks after the episode, she underwent a follow-up colonoscopy. An exophytic polypoid lesion closely associated with a diverticulum was seen in the sigmoid colon. The lesion was easily “pinched” off without much effort using endoscopic forceps and sent for histology which revealed granulation tissue suggesting a healed diverticular perforation.

CONCLUSION

Granulation tissue associated with healed diverticular perforations resemble polyps. Tattooing around these sites may allow for future targeted colonic resections.

Key Words: Diverticulitis; Colonoscopy; Colonic polyps; Colorectal cancer; Diverticular perforation; Case report

©The Author(s) 2023. Published by Baishideng Publishing Group Inc. All rights reserved.

Core Tip: This case report aims to shed light on the possible morphology of a healed diverticular perforation. This is important as patients who have suffered from diverticular perforations are at increased risk of recurrence, with high likelihood of the previously perforated diverticulum being the offending cause. Recognising the appearance of granulation tissue from a possible sealed perforated diverticulum and marking the site with injectable tattoos may allow for targeted resections of the colon if recurrence occurs. This preserves more parenchyma, allows for a potentially faster surgery, and shortens recovery time while achieving an equivalent improvement in quality-of-life.

Citation: Liew JJL, Lim WS, Koh FH. Unusual phenomenon—"polyp" arising from a diverticulum: A case report. *World J Clin Cases* 2023; 11(13): 3070-3075

URL: <https://www.wjgnet.com/2307-8960/full/v11/i13/3070.htm>

DOI: <https://dx.doi.org/10.12998/wjcc.v11.i13.3070>

INTRODUCTION

Diverticular disease is a common benign condition defined by the outpouching of all layers of the intestinal mucosa[1]. Diverticular disease of the colon is common in industrialised countries. The prevalence of diverticular disease is similar in men and women. However, the prevalence of diverticular disease increases with age, ranging from 10% in those younger than 40 to 50 years old, to 70% in those above 80 years of age[2-4]. The anatomic distribution of diverticular disease also varies geographically. In the west, diverticuli are commonly limited to the sigmoid colon in 65%, sigmoid plus other colonic diverticuli in 25%, pan colonic diverticuli in 7%, and diverticuli isolated to a segment proximal to the sigmoid colon in 4% of patients[5]. Conversely, in the East, in Asian populations, the anatomic distribution is different and primarily involves the right colon with a prevalence rate of 13% to 25%[6-9].

Perforation of diverticulitis occurs secondary to bowel wall inflammation, subsequent necrosis and the loss of intestinal wall integrity. The principles for the management of diverticular perforations are dependent on the nature of the perforation. Sealed perforations are treated conservatively with antibiotics while frank and free perforations are treated surgically. Surgical management of perforated diverticuli, for instance the Hartmann Procedure, often results in stoma creation, which reduces a patient's quality-of-life[10]. Another complication of surgical management is diarrhoea caused by reduced storage capacity in the colon from extensive colonic resection in view of the inability to identify specific perforation sites. Management for a perforated diverticulitis with peritonitis is highly controversial owing to the lack of high quality data backing management options for personalised surgery [11]. Elective segmental colonic resections are commonly performed, as evidenced by an 8% risk of recurrence in one year, and a 20% risk of recurrence within ten years of patients with resolved acute diverticulitis. Nonetheless, routine follow-up colonoscopies post-acute diverticulitis episodes have a role to play in holistic patient care.

To date, the endoscopic morphology of a healed diverticular perforations has not been documented in literature.

This case report aims to educate clinical endoscopists on how to identify healed diverticular perforations. Our aim is to eventually revolutionise the presently practised elective segmental colonic resection, which is indicated in recurrent or complicated diverticulitis, by encouraging parenchymal-sparing surgeries through the demarcation of past perforation sites.

In this paper, we report about a middle-aged Chinese female who presented for a routine follow-up colonoscopy 6 wk after an episode of acute diverticulitis. Novel colonoscopy findings of the site of perforation is described in this report. These colonoscopy findings were confirmed by histology which showed granulation tissue, indicating an ongoing healing process.

CASE PRESENTATION

Chief complaints

A middle-age Chinese lady initially presented with a 3-d history of constant abdominal pain in the left iliac fossa.

History of present illness

This was associated with a fever of T_{\max} 37.6°C, non-bloody diarrhoea, and non-bloody, non-bilious vomiting.

History of past illness

She had a past medical history of Type 2 diabetes mellitus which was well controlled on 850 mg Metformin thrice a day.

Personal and family history

Family history was unremarkable for gastrointestinal malignancy. She was a non-smoker and non-drinker.

Physical examination

Physical examination on initial presentation for acute diverticulitis revealed tenderness on the left flank with no guarding. Otherwise, physical examination was unremarkable. There were no signs of chronic liver disease-no jaundice, caput medusae, scleral icterus, Dupuytren's contractures, clubbing, hepatic asterixis, gynecomastia, spider naevi, shifting dullness or pedal oedema. There are no signs of anaemia-no conjunctival pallor, no palmar crease pallor. There were no signs pointing to any kidney pathology-no renal bruits and kidneys were non-ballotable. There was no hepatomegaly or splenomegaly. Bowel sounds were active.

Laboratory examinations

Laboratory investigations revealed elevated C-reactive protein levels (213.9 mg/L) and white cell count ($11.45 \times 10^9/L$).

Imaging examinations

On a computed tomography scan of the abdomen, a confined pericolic abscess was seen (Figure 1).

FINAL DIAGNOSIS

This confirmed the presence of a Modified Hinchey Ib diverticulitis.

TREATMENT

It was managed conservatively with the following course of antibiotics for 5 d-IV ceftriaxone 2 g once a day, and IV metronidazole 500 mg thrice a day. Subsequently, the patient was started on oral co-amoxiclav for a total of 4 wk.

OUTCOME AND FOLLOW-UP

Interval follow-up colonoscopy 6 wk after the acute event revealed polyps in the sigmoid colon. One of the lesions, which was in close proximity to a diverticulum (Figure 2), was easily "pinched" off using endoscopic forceps and sent for histology, revealing an abundance of fibroblasts, keratinocytes, and endothelial cells, characteristic of granulation tissue and consistent with healing (Figure 3)[12]. Neither tubular, nor villous growth patterns were noted, ruling out a diagnosis of adenomatous polyps. Therefore, the "polyp" likely represented the previous site of diverticular perforation.

DISCUSSION

Currently there is limited literature on the appearance and possible morphologies of healed diverticular perforations. Therefore, with this case report we hope to provide an insight into how healed diverticular perforations may appear. Current literature focuses primarily on the pathophysiology, risk factors, along with the possible acute management methods of a diverticular perforation, and not its endoscopic morphology. Furthermore, reports on the endoscopic appearance of diverticular disease largely play the role of clinching the diagnosis of diverticular disease[13] as opposed to studying the possible different morphologies of diverticular disease, particularly after an episode of perforated diverticulitis. Of those that have described the endoscopic appearance of diverticular disease, some have elaborated on the possible histopathologic resemblance between the non-diverticular mucosa in such patients and other

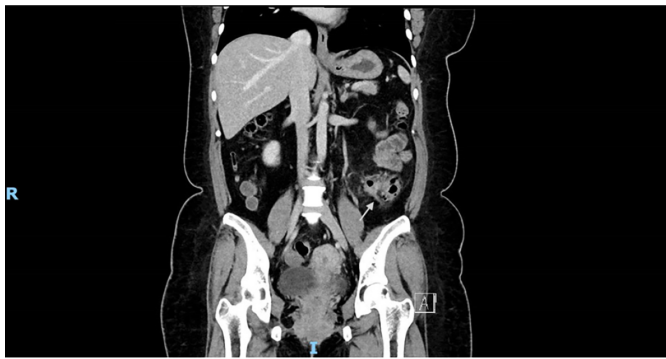

Figure 1 Computed tomography of abdomen pelvis coronal cut, showing signs of pericolic fat stranding and extraluminal air pockets fluid density with peritoneal thickening at the sigmoid colon, likely representing a sealed perforation.

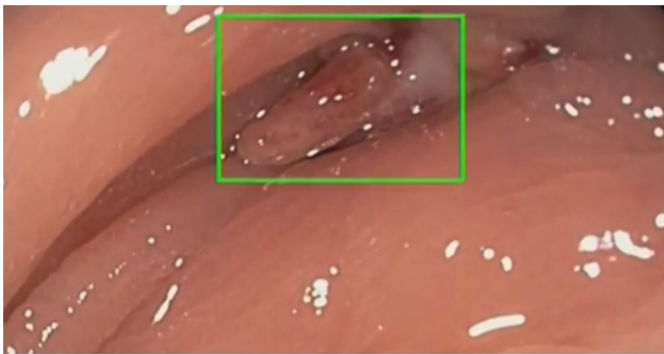

Figure 2 Endoscopic image of exophytic polypoid lesion closely associated with a diverticulum seen in the sigmoid colon.

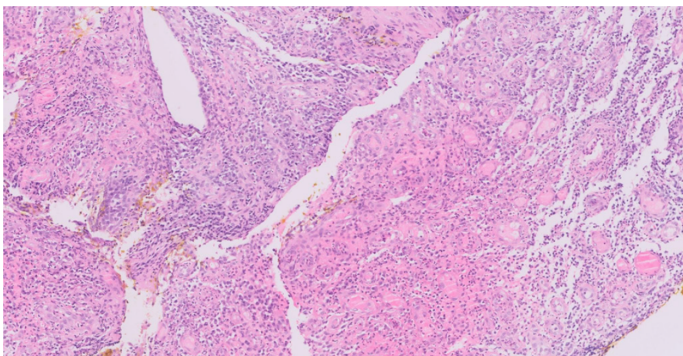


Figure 3 Hematoxylin-eosin stain at 200 × magnification revealing an abundance of fibroblasts, keratinocytes, and endothelial cells, characteristic of granulation tissue and consistent with healing.

mucosal diseases like Crohn's disease or ulcerative colitis[14,15]. Therefore, to the best of our knowledge, the presented case is the first in literature to report the development of polyp-resembling granulation tissue at the site of a previous diverticular perforation. This can potentially offer an alternative angle of management of such sealed perforations.

The rate of recurrence of diverticulitis remains relatively modest, Broderick-Villa *et al*[16] reported on 2366 of 3165 patients (75%) hospitalized with acute diverticulitis and treated nonoperatively in the Kaiser Permanente system. Eighty-six percent of those patients required no further inpatient care for diverticulitis over the 8.9 years of follow-up. Recurrence occurred in only 13.3% of patients and only 3.9% had a second recurrence[17]. Moreover, recurrence of diverticulitis is greater after an episode of complicated diverticulitis at 24%, as opposed to after an episode of uncomplicated diverticulitis at 23.4% [18]. Ultimately, the authors concluded that recurrence overall is rare and there is therefore a decreasing need for elective colectomies following episodes of diverticulitis[19]. However, if a recurrence were to

happen often enough, according to the American Society of Gastrointestinal Endoscopy, surgical resection of the offending site of recurrent diverticulitis is recommended[20]. As the actual offending diverticulum is often not identified, anatomical resection of segments of the colon is performed, which leads to significant amount of colonic length loss which may have implications on quality of life for these patients.

The utility of colonic mucosal tattoo placements lies in marking lesions for subsequent surgical resection, for later endoscopic resection, or to mark an endoscopic resection site for easy endoscopic follow-up of the resection site[21]. We propose the utility of such a mucosal tattoo to mark the potential site of a healed diverticular perforation, if successfully identified. This can potentially help guide surgical resection when the need arises with a more targeted resection. In this way, colonic length can potentially be spared to maintain quality-of-life for the affected patients. A proposal of this nature, when supported by further prospective data and larger series, can potentially modify the way we treat recurrent complicated diverticulitis.

CONCLUSION

This case report displays the morphology of granulation tissue associated with healed diverticular perforations on colonoscopy. This serves to guide endoscopists during colonoscopy to help identify sites of recent perforations. Nonetheless, biopsies of lesions resembling our findings should still be taken, to rule out other pathologies. Tattoo placements may guide clinical treatment by allowing for more targeted colonic resections in the event of recurrence of complicated diverticulitis at the same location. From our preliminary glimpse into the description of the morphology of healed perforated diverticulum, further studies may be conducted to broaden our understanding of the topic.

FOOTNOTES

Author contributions: Koh FH is responsible for research design; Liew JJL, Lim WS are responsible for research and data curation; Koh FH, Liew JJL and Lim WS analysed data; Liew JJL and Lim WS are responsible for the original draft preparation; Koh FH is responsible for reviews and editing; Liew JJL and Lim WS wrote the paper; Koh FH contributed to supervision.

Informed consent statement: Informed written consent was obtained from the patient for publication of this report and any accompanying images.

Conflict-of-interest statement: All the authors report no relevant conflicts of interest for this article.

CARE Checklist (2016) statement: The authors have read the CARE Checklist (2016), and the manuscript was prepared and revised according to the CARE Checklist (2016).

Open-Access: This article is an open-access article that was selected by an in-house editor and fully peer-reviewed by external reviewers. It is distributed in accordance with the Creative Commons Attribution NonCommercial (CC BY-NC 4.0) license, which permits others to distribute, remix, adapt, build upon this work non-commercially, and license their derivative works on different terms, provided the original work is properly cited and the use is non-commercial. See: <https://creativecommons.org/licenses/by-nc/4.0/>

Country/Territory of origin: Singapore

ORCID number: Jacqueline Jin Li Liew 0000-0002-7579-5114; Wei Shyann Lim 0000-0003-2964-1971; Frederick H Koh 0000-0002-3717-4480.

S-Editor: Hu YR

L-Editor: A

P-Editor: Zhao S

REFERENCES

- 1 Linzay CD, Pandit S. Acute Diverticulitis. [Updated 2022 Aug 8]. In: StatPearls [Internet]. Treasure Island (FL): StatPearls Publishing; 2023 Jan-. Available from: <https://www.ncbi.nlm.nih.gov/books/NBK459316/>
- 2 Jacobs DO. Clinical practice. Diverticulitis. *N Engl J Med* 2007; **357**: 2057-2066 [PMID: 18003962 DOI: 10.1056/NEJMc073228]
- 3 Ferzoco LB, Raptopoulos V, Silen W. Acute diverticulitis. *N Engl J Med* 1998; **338**: 1521-1526 [PMID: 9593792 DOI: 10.1056/NEJM199805213382107]

- 4 **Tursi A.** Acute diverticulitis of the colon--current medical therapeutic management. *Expert Opin Pharmacother* 2004; **5**: 55-59 [PMID: [14680435](#) DOI: [10.1517/14656566.5.1.55](#)]
- 5 **Parks TG.** Natural history of diverticular disease of the colon. *Clin Gastroenterol* 1975; **4**: 53-69 [PMID: [1109820](#)]
- 6 **Ngoi SS, Chia J, Goh MY, Sim E, Rauff A.** Surgical management of right colon diverticulitis. *Dis Colon Rectum* 1992; **35**: 799-802 [PMID: [1644006](#) DOI: [10.1007/BF02050332](#)]
- 7 **Wang FW, Chuang HY, Tu MS, King TM, Wang JH, Hsu CW, Hsu PI, Chen WC.** Prevalence and risk factors of asymptomatic colorectal diverticulosis in Taiwan. *BMC Gastroenterol* 2015; **15**: 40 [PMID: [25888375](#) DOI: [10.1186/s12876-015-0267-5](#)]
- 8 **Markham NI, Li AK.** Diverticulitis of the right colon--experience from Hong Kong. *Gut* 1992; **33**: 547-549 [PMID: [1582600](#) DOI: [10.1136/gut.33.4.547](#)]
- 9 **Chan CC, Lo KK, Chung EC, Lo SS, Hon TY.** Colonic diverticulosis in Hong Kong: distribution pattern and clinical significance. *Clin Radiol* 1998; **53**: 842-844 [PMID: [9833789](#) DOI: [10.1016/s0009-9260\(98\)80197-9](#)]
- 10 **Moro-Valdezate D, Royo-Aznar A, Martín-Arévalo J, Pla-Martí V, García-Botello S, León-Espinoza C, Fernández-Moreno MC, Espin-Basany E, Espí-Macías A.** Outcomes of Hartmann's procedure and subsequent intestinal restoration. Which patients are most likely to undergo reversal? *Am J Surg* 2019; **218**: 918-927 [PMID: [30853093](#) DOI: [10.1016/j.amjsurg.2019.02.025](#)]
- 11 **Nascimbeni R, Amato A, Cirocchi R, Serventi A, Laghi A, Bellini M, Tellan G, Zago M, Scarpignato C, Binda GA.** Management of perforated diverticulitis with generalized peritonitis. A multidisciplinary review and position paper. *Tech Coloproctol* 2021; **25**: 153-165 [PMID: [33155148](#) DOI: [10.1007/s10151-020-02346-y](#)]
- 12 **Reinke JM, Sorg H.** Wound repair and regeneration. *Eur Surg Res* 2012; **49**: 35-43 [PMID: [22797712](#) DOI: [10.1159/000339613](#)]
- 13 **Kim YS.** [Diagnosis and Treatment of Colonic Diverticular Disease]. *Korean J Gastroenterol* 2022; **79**: 233-243 [PMID: [35746837](#) DOI: [10.4166/kjg.2022.072](#)]
- 14 **West AB, Losada M.** The pathology of diverticulosis coli. *J Clin Gastroenterol* 2004; **38**: S11-S16 [PMID: [15115923](#) DOI: [10.1097/01.mcg.0000124005.07433.69](#)]
- 15 **Weizman AV, Nguyen GC.** Diverticular disease: epidemiology and management. *Can J Gastroenterol* 2011; **25**: 385-389 [PMID: [21876861](#) DOI: [10.1155/2011/795241](#)]
- 16 **Broderick-Villa G, Burchette RJ, Collins JC, Abbas MA, Haigh PI.** Hospitalization for acute diverticulitis does not mandate routine elective colectomy. *Arch Surg* 2005; **140**: 576-81; discussion 581 [PMID: [15967905](#) DOI: [10.1001/archsurg.140.6.576](#)]
- 17 **Rai V, Mishra N.** Surgical Management of Recurrent Uncomplicated Diverticulitis. *Clin Colon Rectal Surg* 2021; **34**: 91-95 [PMID: [33642948](#) DOI: [10.1055/s-0040-1716700](#)]
- 18 **Eglinton T, Nguyen T, Raniga S, Dixon L, Dobbs B, Frizelle FA.** Patterns of recurrence in patients with acute diverticulitis. *Br J Surg* 2010; **97**: 952-957 [PMID: [20474006](#) DOI: [10.1002/bjs.7035](#)]
- 19 **Morris AM, Regenbogen SE, Hardiman KM, Hendren S.** Sigmoid diverticulitis: a systematic review. *JAMA* 2014; **311**: 287-297 [PMID: [24430321](#) DOI: [10.1001/jama.2013.282025](#)]
- 20 **Qaseem A, Etzeandía-Ikobaltzeta I, Lin JS, Fitterman N, Shamliyan T, Wilt TJ; Clinical Guidelines Committee of the American College of Physicians*, Crandall CJ, Cooney TG, Cross JT Jr, Hicks LA, Maroto M, Mustafa RA, Obley AJ, Owens DK, Tice J, Williams JW Jr; Clinical Guidelines Committee of the American College of Physicians.** Colonoscopy for Diagnostic Evaluation and Interventions to Prevent Recurrence After Acute Left-Sided Colonic Diverticulitis: A Clinical Guideline From the American College of Physicians. *Ann Intern Med* 2022; **175**: 416-431 [PMID: [35038270](#) DOI: [10.7326/M21-2711](#)]
- 21 **Rex DK.** The Appropriate Use and Techniques of Tattooing in the Colon. *Gastroenterol Hepatol (N Y)* 2018; **14**: 314-317 [PMID: [29991940](#)]



Published by **Baishideng Publishing Group Inc**
7041 Koll Center Parkway, Suite 160, Pleasanton, CA 94566, USA

Telephone: +1-925-3991568

E-mail: bpgoffice@wjgnet.com

Help Desk: <https://www.f6publishing.com/helpdesk>

<https://www.wjgnet.com>

