

World Journal of *Clinical Cases*

World J Clin Cases 2023 May 16; 11(14): 3114-3368



Contents

Thrice Monthly Volume 11 Number 14 May 16, 2023

OPINION REVIEW

- 3114 Modernising autism spectrum disorder model engineering and treatment *via* CRISPR-Cas9: A gene reprogramming approach

Sandhu A, Kumar A, Rawat K, Gautam V, Sharma A, Saha L

REVIEW

- 3128 Burden of disability in type 2 diabetes mellitus and the moderating effects of physical activity

Oyewole OO, Ale AO, Ogunlana MO, Gurayah T

MINIREVIEWS

- 3140 Postoperative hypoxemia for patients undergoing Stanford type A aortic dissection

Liu HY, Zhang SP, Zhang CX, Gao QY, Liu YY, Ge SL

ORIGINAL ARTICLE

Case Control Study

- 3148 Impact of extended nursing model after multi-disciplinary treatment on young patient with post-stroke

Xu XY, Pang ZJ, Li MH, Wang K, Song J, Cao Y, Fang M

- 3158 Changes and significance of serum ubiquitin carboxyl-terminal hydrolase L1 and glial fibrillary acidic protein in patients with glioma

Zhu QH, Wu JK, Hou GL

Retrospective Study

- 3167 Multitrack and multianchor point screw technique combined with the Wiltse approach for lesion debridement for lumbar tuberculosis

Yuan YF, Ren ZX, Zhang C, Li GJ, Liu BZ, Li XD, Miao J, Li JF

- 3176 Clinical features and prognostic factors in 49 patients with follicular lymphoma at a single center: A retrospective analysis

Wu H, Sun HC, Ouyang GF

- 3187 Value of optical coherence tomography measurement of macular thickness and optic disc parameters for glaucoma screening in patients with high myopia

Mu H, Li RS, Yin Z, Feng ZL

Observational Study

- 3195 Comparative study of the clinical efficacy of all-inside and traditional techniques in anterior cruciate ligament reconstruction

An BJ, Wang YT, Zhao Z, Wang MX, Xing GY

- 3204** Positioning and design by computed tomography imaging in neuroendoscopic surgery of patients with chronic subdural hematoma

Wang XJ, Yin YH, Zhang LY, Wang ZF, Sun C, Cui ZM

- 3211** Evaluation of chronic idiopathic tinnitus and its psychosocial triggers

Hamed SA, Attiah FA, Fawzy M, Azzam M

- 3224** Intestinal complications in patients with Crohn's disease in the Brazilian public healthcare system between 2011 and 2020

Sasaki LY, Martins AL, Galhardi-Gasparini R, Saad-Hossne R, Ritter AMV, Barreto TB, Marcolino T, Balula B, Yang-Santos C

Randomized Controlled Trial

- 3238** Effect of non-pharmacological treatment on the full recovery of social functioning in patients with attention deficit hyperactivity disorder

Lv YB, Cheng W, Wang MH, Wang XM, Hu YL, Lv LQ

CASE REPORT

- 3248** Diagnosis of tuberculous uveitis by the macrogenome of intraocular fluid: A case report and review of the literature

Zhang YK, Guan Y, Zhao J, Wang LF

- 3256** Intragastric fish bones migrate into the liver: A case report

Dai MG, Zheng JJ, Yang J, Ye B

- 3261** Primary seminal vesicle adenocarcinoma with a history of seminal vesicle cyst: A case report and review of literature

Yao Y, Liu S, He YL, Luo L, Zhang GM

- 3267** Immune checkpoint inhibitor therapy-induced autoimmune polyendocrine syndrome type II and Crohn's disease: A case report

Gao MJ, Xu Y, Wang WB

- 3275** Late-onset mitochondrial encephalomyopathy with lactic acidosis and stroke-like episodes syndrome with mitochondrial DNA 3243A>G mutation masquerading as autoimmune encephalitis: A case report

Wang JW, Yuan XB, Chen HF

- 3282** Metastatic gastric cancer from breast carcinoma presenting with paraneoplastic rheumatic syndrome: A case report

Rech MB, da-Cruz ER, Salgado K, Balbinot RA, Balbinot SS, Soldera J

- 3288** Novel mutation of SPG4 gene in a Chinese family with hereditary spastic paraplegia: A case report

Wang J, Bu WT, Zhu MJ, Tang JY, Liu XM

- 3295** Chronic pulmonary mucormycosis caused by rhizopus microsporus mimics lung carcinoma in an immunocompetent adult: A case report

Guo XZ, Gong LH, Wang WX, Yang DS, Zhang BH, Zhou ZT, Yu XH

- 3304** Idiopathic sclerosing mesenteritis presenting with small bowel volvulus in a patient with antiphospholipid syndrome: A case report
Chennavasin P, Gururatsakul M
- 3311** *Neisseria mucosa* - A rare cause of peritoneal dialysis-related peritonitis: A case report
Ren JM, Zhang XY, Liu SY
- 3317** Rectal prolapse in a 30-year-old bladder stone male patient: A case report
Ding HX, Huang JG, Feng C, Tai SC
- 3323** Successful treatment of veno-arterial extracorporeal membrane oxygenation complicated with left ventricular thrombus by intravenous thrombolysis: A case report
Wang YD, Lin JF, Huang XY, Han XD
- 3330** Successful remimazolam sedation-epidural block in an older patient with severe chronic obstructive pulmonary disease: A case report
Yu JJ, Pei HS, Meng Y
- 3340** *De novo* mutation of NAXE (APOAIBP)-related early-onset progressive encephalopathy with brain edema and/or leukoencephalopathy-1: A case report
Ding L, Huang TT, Ying GH, Wang SY, Xu HF, Qian H, Rahman F, Lu XP, Guo H, Zheng G, Zhang G
- 3351** Iatrogenic atlantoaxial rotatory subluxation after thyroidectomy in a pediatric patient: A case report
Hong WJ, Lee JK, Hong JH, Han MS, Lee SS
- 3356** Bladder metastasis from epidermal growth factor receptor mutant lung cancer: A case report
Jin CB, Yang L
- 3362** Primary rectal mucosa-associated lymphoid tissue lymphoma treated with only endoscopic submucosal dissection: A case report
Lee WS, Noh MG, Joo YE

ABOUT COVER

Editorial Board Member of *World Journal of Clinical Cases*, Jaw-Yuan Wang, MD, PhD, Professor, Surgical Oncologist, Department of Surgery, Kaohsiung Medical University Hospital, Kaohsiung Medical University, Kaohsiung 807, Taiwan. jawyuanwang@gmail.com

AIMS AND SCOPE

The primary aim of *World Journal of Clinical Cases* (WJCC, *World J Clin Cases*) is to provide scholars and readers from various fields of clinical medicine with a platform to publish high-quality clinical research articles and communicate their research findings online.

WJCC mainly publishes articles reporting research results and findings obtained in the field of clinical medicine and covering a wide range of topics, including case control studies, retrospective cohort studies, retrospective studies, clinical trials studies, observational studies, prospective studies, randomized controlled trials, randomized clinical trials, systematic reviews, meta-analysis, and case reports.

INDEXING/ABSTRACTING

The WJCC is now abstracted and indexed in Science Citation Index Expanded (SCIE, also known as SciSearch®), Journal Citation Reports/Science Edition, Current Contents®/Clinical Medicine, PubMed, PubMed Central, Scopus, Reference Citation Analysis, China National Knowledge Infrastructure, China Science and Technology Journal Database, and Superstar Journals Database. The 2022 Edition of Journal Citation Reports® cites the 2021 impact factor (IF) for WJCC as 1.534; IF without journal self cites: 1.491; 5-year IF: 1.599; Journal Citation Indicator: 0.28; Ranking: 135 among 172 journals in medicine, general and internal; and Quartile category: Q4. The WJCC's CiteScore for 2021 is 1.2 and Scopus CiteScore rank 2021: General Medicine is 443/826.

RESPONSIBLE EDITORS FOR THIS ISSUE

Production Editor: Hua-Ge Yin; Production Department Director: Xu Guo; Editorial Office Director: Jin-Lei Wang.

NAME OF JOURNAL

World Journal of Clinical Cases

ISSN

ISSN 2307-8960 (online)

LAUNCH DATE

April 16, 2013

FREQUENCY

Thrice Monthly

EDITORS-IN-CHIEF

Bao-Gan Peng, Jerzy Tadeusz Chudek, George Kontogeorgos, Maurizio Serati, Ja Hyeon Ku

EDITORIAL BOARD MEMBERS

<https://www.wjgnet.com/2307-8960/editorialboard.htm>

PUBLICATION DATE

May 16, 2023

COPYRIGHT

© 2023 Baishideng Publishing Group Inc

INSTRUCTIONS TO AUTHORS

<https://www.wjgnet.com/bpg/gerinfo/204>

GUIDELINES FOR ETHICS DOCUMENTS

<https://www.wjgnet.com/bpg/GerInfo/287>

GUIDELINES FOR NON-NATIVE SPEAKERS OF ENGLISH

<https://www.wjgnet.com/bpg/gerinfo/240>

PUBLICATION ETHICS

<https://www.wjgnet.com/bpg/GerInfo/288>

PUBLICATION MISCONDUCT

<https://www.wjgnet.com/bpg/gerinfo/208>

ARTICLE PROCESSING CHARGE

<https://www.wjgnet.com/bpg/gerinfo/242>

STEPS FOR SUBMITTING MANUSCRIPTS

<https://www.wjgnet.com/bpg/GerInfo/239>

ONLINE SUBMISSION

<https://www.f6publishing.com>



Idiopathic sclerosing mesenteritis presenting with small bowel volvulus in a patient with antiphospholipid syndrome: A case report

Papawee Chennavasin, Montri Gururatsakul

Specialty type: Medicine, research and experimental

Provenance and peer review: Unsolicited article; Externally peer reviewed.

Peer-review model: Single blind

Peer-review report's scientific quality classification

Grade A (Excellent): 0
Grade B (Very good): B
Grade C (Good): 0
Grade D (Fair): D
Grade E (Poor): 0

P-Reviewer: Gu GL, China;
Zharikov YO, Russia

Received: January 16, 2023

Peer-review started: January 16, 2023

First decision: March 13, 2023

Revised: March 16, 2023

Accepted: April 10, 2023

Article in press: April 10, 2023

Published online: May 16, 2023



Papawee Chennavasin, Department of Surgery, Chulabhorn Hospital, Princess Srisavangavadhana College of Medicine, Chulabhorn Royal Academy, Bangkok 10210, Thailand

Montri Gururatsakul, Department of Gastroenterology and Hepatology, Chulabhorn Hospital, Princess Srisavangavadhana College of Medicine, Chulabhorn Royal Academy, Bangkok 10210, Thailand

Corresponding author: Papawee Chennavasin, MD, Surgeon, Department of Surgery, Chulabhorn Hospital, Princess Srisavangavadhana College of Medicine, Chulabhorn Royal Academy, 906 Kamphaeng Phet 6 Road Talat Bang Khen, Lak Si, Bangkok 10210, Thailand. papawee.che@cra.ac.th

Abstract

BACKGROUND

Sclerosing mesenteritis is a rare disorder involving inflammation of the mesentery. Its etiology remains unclear, but it is believed to be associated with previous abdominal surgery, trauma, autoimmune disorders, infection, or malignancy. Clinical manifestations of sclerosing mesenteritis are varied and include chronic abdominal pain, bloating, diarrhea, weight loss, formation of an intra-abdominal mass, bowel obstruction, and chylous ascites. Here, we present a case of idiopathic sclerosing mesenteritis with small bowel volvulus in a patient with antiphospholipid syndrome.

CASE SUMMARY

A 68-year-old female presented with recurrent small bowel obstruction. Imaging and pathological findings were consistent with sclerosing mesenteritis causing mesenteric and small bowel volvulus. Computed tomography scans also revealed pulmonary embolism, and the patient was started on a high dose of corticosteroid and a therapeutic dose of anticoagulants. The patient subsequently improved clinically and was discharged. The patient was also diagnosed with antiphospholipid syndrome after a hematological workup.

CONCLUSION

Sclerosing mesenteritis is a rare condition, and patients with no clear etiology should be considered for treatment with immunosuppressive therapy.

Key Words: Sclerosing mesenteritis; Mesenteric panniculitis; Small bowel obstruction; Antiphospholipid syndrome; Small bowel volvulus; Case report

Core Tip: In patients with sclerosing mesenteritis, any condition that causes chronic inflammation of mesenteric tissue should be investigated. Antiphospholipid syndrome may be linked with chronic thrombotic activity that can contribute to chronic ischemia of the mesentery. Patients with uncertain etiology should be considered for treatment with immunosuppressive therapy.

Citation: Chennavasin P, Gururatsakul M. Idiopathic sclerosing mesenteritis presenting with small bowel volvulus in a patient with antiphospholipid syndrome: A case report. *World J Clin Cases* 2023; 11(14): 3304-3310

URL: <https://www.wjgnet.com/2307-8960/full/v11/i14/3304.htm>

DOI: <https://dx.doi.org/10.12998/wjcc.v11.i14.3304>

INTRODUCTION

Sclerosing mesenteritis is a condition of mesenteric inflammation that causes thickening and fibrosis in the bowel mesentery. The disease is frequently limited to the adipose tissue of the small bowel mesentery and is unlikely to involve the omentum, peritoneum, or mesocolon[1]. Sclerosing mesenteritis was first reported in 1924 as “retractile mesenteritis and/or mesenteric panniculitis”[2]. The incidence of this condition is 0.16%–3.30%[3]. The etiology is still unclear; however, it may be associated with various conditions that cause chronic inflammation, such as previous abdominal surgery, trauma, mesenteric ischemia, cancer, infection, and autoimmune conditions. Sclerosing mesenteritis is more common in Caucasians, with a male-to-female ratio of 2-3:1[3,4]. The characteristics of sclerosing mesenteritis may differ in Asian populations since a previous study showed that 58% of Japanese patients also had mesocolon involvement[5].

Clinical manifestations of sclerosing mesenteritis can vary from asymptomatic to severe abdominal pain. It can cause small bowel obstruction, significant weight loss, and chylothorax in severe cases[6,7]. Computed tomography (CT) scans are the investigation of choice, and clinical diagnosis is made using the Coulier criteria, which are: (1) Presence of a well-defined “mass effect” on neighboring structures; (2) Inhomogeneous higher attenuation of mesenteric fat tissue than adjacent retroperitoneal or mesocolonic fat; (3) Small soft tissue nodes; (4) A hypoattenuated fatty “halo sign”; and (5) The presence of a hyperattenuating pseudocapsule, which may also surround the entire entity[8]. Tissue biopsy is recommended to exclude malignancy and confirm the diagnosis of mesenteric fibrosis, chronic inflammation, and fat necrosis[9].

We present the case of a 68-year-old female with recurrent small bowel volvulus caused by sclerosing mesenteritis who responded well to treatment with a corticosteroid. When further investigations were performed to find the cause of the sclerosing mesenteritis, the patient was also found to have antiphospholipid syndrome (APS).

CASE PRESENTATION

Chief complaints

A 68-year-old female presented at the hospital with acute abdominal pain and vomiting that had persisted for 1 d.

History of present illness

The patient developed colicky pain with bilious vomiting 1 d prior to visiting the emergency department. Her abdomen was distended, but there was no fever.

History of past illness

The patient’s medical history showed only hypertension, and there was no previous abdominal surgery or abdominal trauma.

Personal and family history

There was no significant personal or family history.

Physical examination

Physical examination revealed generalized abdominal tenderness; however, there was no evidence of peritonitis.

Laboratory examinations

Laboratory examination showed that the patient's white blood cell count was 5930 cells/ μ L, and creatinine levels had risen from 0.83 mg/dL to 1.76 mg/dL.

Imaging examinations

Abdominal X-rays showed generalized small bowel dilatation with air-fluid levels consistent with small bowel obstruction. Therefore, a CT scan of the abdomen was requested. The initial CT scan showed a thickened mesentery around the terminal ileum. At the terminal ileum, there was an abrupt change in caliber caused by rotation with upstream dilatation of the distal jejunum and ileum, consistent with high-grade small bowel obstruction. Misty mesentery and enlargement of mesenteric nodes in the right lower quadrant adjacent to the distal ileum were also observed, possibly secondary to an infection or an inflammatory process (Figure 1).

FINAL DIAGNOSIS

The patient was given the diagnosis of sclerosing mesenteritis with small bowel obstruction.

TREATMENT

An exploratory laparotomy was performed, which revealed diffuse thickening of the small bowel mesentery causing mesenteric distortion and small bowel volvulus at the level of the terminal ileum with upstream dilatation of the entire small bowel that was associated with significant mesenteric lymphadenopathy. The entire small bowel was viable after small bowel devolvulation was performed. Lymph nodes were also excised for histopathological examination, which subsequently revealed reactive lymph nodes with fat necrosis (Figure 2).

After the operation, the patient's bowel movements returned to normal. The patient was able to pass stools and tolerated a soft food diet. Further investigations were indicated to exclude occult malignancy, tuberculosis, and other underlying autoimmune conditions. However, while waiting for the results from these investigations, acute abdominal pain with abdominal distension returned on postoperative day 5. Subsequent abdominal X-ray and CT scans showed recurrent small bowel volvulus with the same misty mesentery. A second laparotomy confirmed recurrent small bowel volvulus due to inflammation, and retraction of the small bowel mesentery was observed.

Serology tests showed a positive result for antinuclear antibodies (1:160), which were homogenous with a fine granular cytoplasmic staining pattern, a normal range of IgG4 (0.285 g/L), and negative results for other autoimmune serology and tumor markers (carbohydrate antigen 19-9, alpha fetoprotein, carcinoembryonic antigen, and cancer antigen 125). Tuberculosis was not found in either tissue histopathology or in the stool. A CT scan of the chest was also performed to exclude tuberculosis or occult malignancy, both of which were negative. However, an incidental small pulmonary embolism was detected. There was no evidence of deep vein thrombosis on Doppler ultrasound of either leg. As a result, further investigation for APS was performed, and tests for anti-beta2-glycoprotein-1 (for all 3 immunoglobulin isotypes: IgA, IgG, and IgM) were found to be positive. Upon a repeat test 3 mo later, the result was still positive (Table 1).

After the second operation, the patient was diagnosed with idiopathic sclerosing mesenteritis, and treatment with high-dose corticosteroids and a therapeutic dose of low molecular weight heparin was commenced. The patient responded well to corticosteroids and did not develop further small bowel obstruction or volvulus. In addition, bowel function was normal, a normal diet was tolerated, and the patient was discharged after 2 wk with a weaning dose of oral corticosteroid over an 8-wk period.

OUTCOME AND FOLLOW-UP

At a follow-up appointment 2 mo after discharge, an upper endoscopy and a colonoscopy were performed; the results of which were unremarkable. A repeat anti-beta2-glycoprotein1 (IgA, IgG, and IgM) test at 3 mo was positive, and the patient was diagnosed with APS. As a result, the patient must continue lifelong anticoagulant therapy.

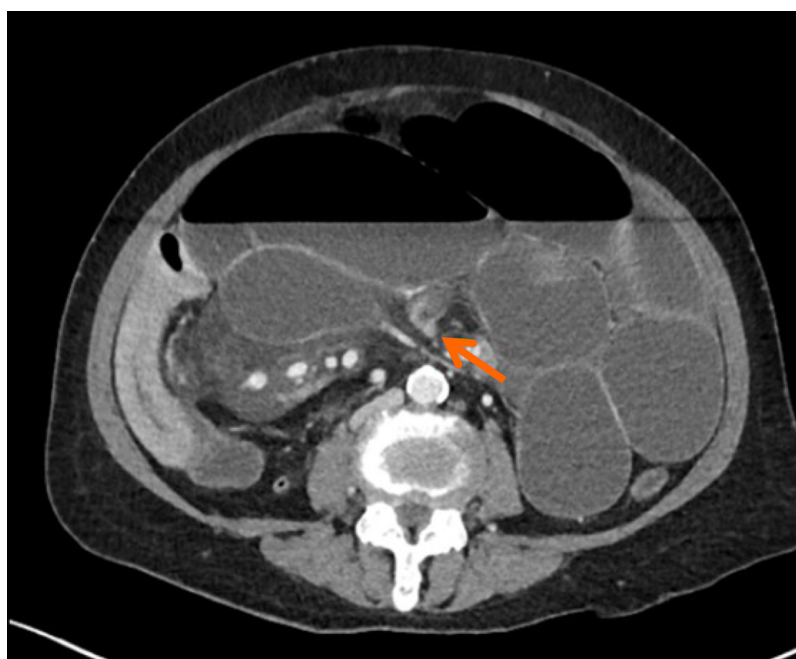DISCUSSION

Sclerosing mesenteritis refers to chronic inflammation of the mesentery. This condition is rare and is more common in Caucasian males[4]. In the present case report, the patient was an Asian female

Table 1 Blood test results

Blood test	Results
Anti-Beta 2-Glycoprotein-1 IgA/IgG/IgM	38.29 RU/mL
Anti-Beta 2-Glycoprotein-1 IgA/IgG/IgM (3 mo later)	35.69 RU/mL
Anticardiolipin IgG	7.130 U/mL
Anticardiolipin IgM	< 2 U/mL
ANA	1:160
ANA 12 specific antigen profile	Negative
Serum IgG4	0.285 g/L
Tissue IgG4	Negative
Lupus anticoagulant	Negative
C3 compliment	0.79 g/L
C4 compliment	0.14 g/L
Tissue PCR for mycobacterium tuberculosis	Not detected
Stool PCR for mycobacterium tuberculosis	Not detected
CEA	0.9 ng/mL
Alpha fetoprotein	15 ng/mL
CA 125	30 U/mL
CA 19-9	< 2 U/mL

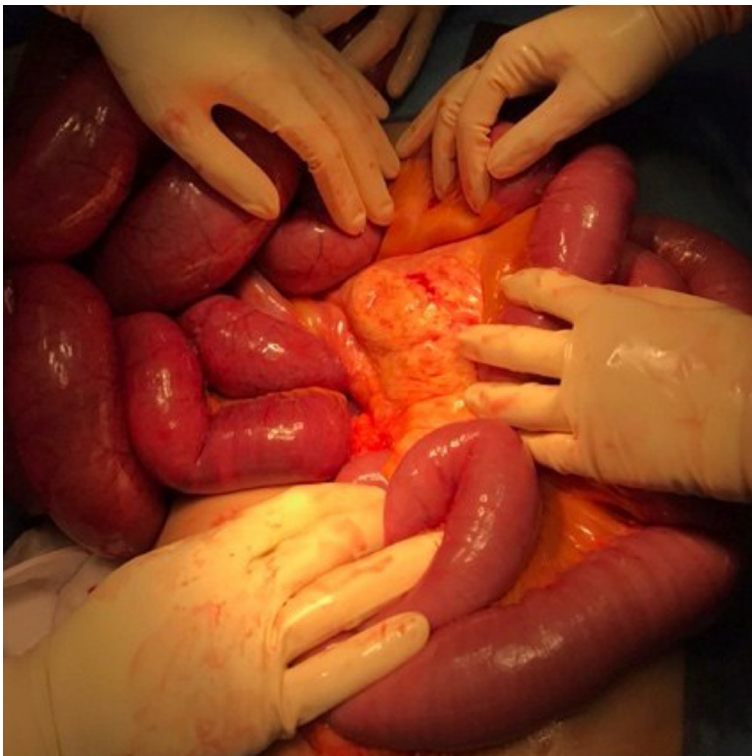
ANA: Antinuclear antibodies; CEA: Carcinoembryonic antigen; CA 19-9: Carbohydrate antigen 19-9; CA 125: Cancer antigen 125.



DOI: 10.12998/wjcc.v11.i14.3304 Copyright ©The Author(s) 2023.

Figure 1 Computed tomography scan showed a dilated small bowel and misty mesentery (orange arrow), consistent with small bowel obstruction.

without any significant underlying disease and no previous abdominal surgery. Sclerosing mesenteritis was considered to be the rare cause of small bowel obstruction. The CT scan revealed inhomogeneous higher attenuation of mesenteric fat tissue and small soft tissue nodes in the mesentery surrounded by hypodense mesenteric fat, which is consistent with the Coulier criteria[8] for sclerosing



DOI: 10.12998/wjcc.v11.i14.3304 Copyright ©The Author(s) 2023.

Figure 2 Operative findings revealed diffused mesenteric thickening with enlarged mesenteric lymph nodes and viable small bowel after detorsion.

mesenteritis. Pathological features also confirmed chronic inflammation of mesenteric fat without evidence of malignancy.

Several studies have reported patients with sclerosing mesenteritis who have small bowel obstruction, and the majority of these cases required surgical intervention to correct the obstruction followed by treatment with an immunosuppressive medication[10-12]. Surgery may be performed to correct gut obstruction, but it is not a curative treatment[13]. Our patient was diagnosed with idiopathic sclerosing mesenteritis. After the first operation was performed, we did not administer any immunosuppressive medication immediately because we were waiting for all the results to exclude other primary causes, including infection and cancer. Subsequently, the patient developed recurrent small bowel volvulus and required a second exploratory operation. The patient responded well to treatment with corticosteroids.

The etiology of sclerosing mesenteritis is unclear; however, it is generally associated with chronic inflammation of mesenteric tissue. This may be caused by previous abdominal surgery, trauma, mesenteric ischemia, cancer, infection, or autoimmune disease[13]. In this case, the patient was also subsequently diagnosed with APS after an incidental finding of pulmonary embolism during the diagnostic workup. Only a few case reports have shown chronic thrombosis-associated chronic mesenteric ischemia. One case report detailed sclerosing mesenteritis with sacroiliitis[14], and another reported sclerosing mesenteritis with Factor V Leiden[15]. Both cases raise the possibility of a link between mesenteric ischemia and chronic thrombotic activity.

Thrombosis can affect vessels of any size in APS patients; however, a gastrointestinal manifestation in APS is uncommon[16]. To date, there has been no reports of a potential association between APS and sclerosing mesenteritis; however, it is thought that chronic venous thrombosis may cause mesenteric ischemia in APS patients[17]. In the case of our patient, it is possible that the small veins in the small bowel mesentery were affected by chronic venous thrombosis causing chronic inflammation that led to sclerosing mesenteritis. Therefore, it is necessary to investigate hypercoagulable states in patients with sclerosing mesenteritis.

CONCLUSION

Sclerosing mesenteritis is a chronic inflammation of the mesentery that is commonly caused by other medical conditions, including infection, autoimmune conditions, and malignancy. Symptomatic patients with unclear etiology should be considered for treatment with immunosuppressive medications. In

addition, while rare, chronic thrombotic conditions can also cause sclerosing mesenteritis, and they should also be considered.

ACKNOWLEDGEMENTS

We thank Edanz (www.edanz.com/ac) for editing a draft of this manuscript.

FOOTNOTES

Author contributions: Chennavasin P designed the research study and wrote the manuscript; Gururatsakul M revised the manuscript and performed language editing; and all authors read and approved the final manuscript.

Informed consent statement: Inform consent was obtained from the patient for publication of this report and any accompanying images.

Conflict-of-interest statement: All authors report having no relevant conflicts of interest for this article.

CARE Checklist (2016) statement: The authors have read the CARE Checklist (2016), and the manuscript was prepared and revised according to the CARE Checklist (2016).

Open-Access: This article is an open-access article that was selected by an in-house editor and fully peer-reviewed by external reviewers. It is distributed in accordance with the Creative Commons Attribution NonCommercial (CC BY-NC 4.0) license, which permits others to distribute, remix, adapt, build upon this work non-commercially, and license their derivative works on different terms, provided the original work is properly cited and the use is non-commercial. See: <https://creativecommons.org/licenses/by-nc/4.0/>

Country/Territory of origin: Thailand

ORCID number: Papawee Chennavasin 0000-0002-0466-1610.

S-Editor: Liu XF

L-Editor: Filipodia

P-Editor: Zhang YL

REFERENCES

- 1 **Buragina G**, Magenta Biasina A, Carrafiello G. Clinical and radiological features of mesenteric panniculitis: a critical overview. *Acta Biomed* 2019; **90**: 411-422 [PMID: 31910164 DOI: 10.23750/abm.v90i4.7696]
- 2 **Green MS**, Chhabra R, Goyal H. Sclerosing mesenteritis: a comprehensive clinical review. *Ann Transl Med* 2018; **6**: 336 [PMID: 30306075 DOI: 10.21037/atm.2018.07.01]
- 3 **Protin-Catteau L**, Thiéfin G, Barbe C, Jolly D, Soyer P, Hoeffel C. Mesenteric panniculitis: review of consecutive abdominal MDCT examinations with a matched-pair analysis. *Acta Radiol* 2016; **57**: 1438-1444 [PMID: 26868171 DOI: 10.1177/0284185116629829]
- 4 **Sharma P**, Yadav S, Needham CM, Feuerstadt P. Sclerosing mesenteritis: a systematic review of 192 cases. *Clin J Gastroenterol* 2017; **10**: 103-111 [PMID: 28197781 DOI: 10.1007/s12328-017-0716-5]
- 5 **Endo K**, Moroi R, Sugimura M, Fujishima F, Naitoh T, Tanaka N, Shiga H, Kakuta Y, Takahashi S, Kinouchi Y, Shimosegawa T. Refractory sclerosing mesenteritis involving the small intestinal mesentery: a case report and literature review. *Intern Med* 2014; **53**: 1419-1427 [PMID: 24990334 DOI: 10.2169/internalmedicine.53.1813]
- 6 **Akram S**, Pardi DS, Schaffner JA, Smyrk TC. Sclerosing mesenteritis: clinical features, treatment, and outcome in ninety-two patients. *Clin Gastroenterol Hepatol* 2007; **5**: 589-96; quiz 523 [PMID: 17478346 DOI: 10.1016/j.cgh.2007.02.032]
- 7 **Nyberg L**, Björk J, Björkdahl P, Ekberg O, Sjöberg K, Vigren L. Sclerosing mesenteritis and mesenteric panniculitis - clinical experience and radiological features. *BMC Gastroenterol* 2017; **17**: 75 [PMID: 28610559 DOI: 10.1186/s12876-017-0632-7]
- 8 **Coulter B**. Mesenteric panniculitis. Part 1: MDCT--pictorial review. *JBR-BTR* 2011; **94**: 229-240 [PMID: 22191287 DOI: 10.5334/jbr-btr.658]
- 9 **Emory TS**, Monihan JM, Carr NJ, Sobin LH. Sclerosing mesenteritis, mesenteric panniculitis and mesenteric lipodystrophy: a single entity? *Am J Surg Pathol* 1997; **21**: 392-398 [PMID: 9130985 DOI: 10.1097/00000478-199704000-00004]
- 10 **Allen PB**, De Cruz P, Efthymiou M, Fox A, Taylor AC, Desmond PV. An Interesting Case of Recurrent Small Bowel Obstruction. *Case Rep Gastroenterol* 2009; **3**: 408-413 [PMID: 21103263 DOI: 10.1159/000254708]
- 11 **Corado SC**, Almeida H, Baltazar JR. A severe case of sclerosing mesenteritis. *BMJ Case Rep* 2019; **12** [PMID: 31289157 DOI: 10.1136/bcr-2018-229035]
- 12 **Haikal A**, Thimmanagari K. Colon Perforation As Initial Presentation of Refractory and Complicated Sclerosing

- Mesenteritis. *Cureus* 2021; **13**: e17142 [PMID: [34532177](#) DOI: [10.7759/cureus.17142](#)]
- 13 **Danford CJ**, Lin SC, Wolf JL. Sclerosing Mesenteritis. *Am J Gastroenterol* 2019; **114**: 867-873 [PMID: [30829677](#) DOI: [10.14309/ajg.0000000000000167](#)]
- 14 **Rothlein LR**, Shaheen AW, Vavalle JP, Smith SV, Renner JB, Shaheen NJ, Tarrant TK. Sclerosing mesenteritis successfully treated with a TNF antagonist. *BMJ Case Rep* 2010; **2010** [PMID: [22802373](#) DOI: [10.1136/bcr.07.2010.3145](#)]
- 15 **Reddington H**, Ballinger Z, Abghari M, Modukuru V, Wallack M. Sclerosing Mesenteritis in a Patient Heterozygous for Factor V Leiden. *Am J Case Rep* 2020; **21**: e926332 [PMID: [33017382](#) DOI: [10.12659/AJCR.926332](#)]
- 16 **Cervera R**, Serrano R, Pons-Estel GJ, Ceberio-Hualde L, Shoenfeld Y, de Ramón E, Buonaiuto V, Jacobsen S, Zeher MM, Tarr T, Tincani A, Taglietti M, Theodossades G, Nomikou E, Galeazzi M, Bellisai F, Meroni PL, Derksen RH, de Groot PG, Baleva M, Mosca M, Bombardieri S, Houssiau F, Gris JC, Quéré I, Hachulla E, Vasconcelos C, Fernández-Nebro A, Haro M, Amoura Z, Miyara M, Tektonidou M, Espinosa G, Bertolaccini ML, Khamashta MA; Euro-Phospholipid Project Group (European Forum on Antiphospholipid Antibodies). Morbidity and mortality in the antiphospholipid syndrome during a 10-year period: a multicentre prospective study of 1000 patients. *Ann Rheum Dis* 2015; **74**: 1011-1018 [PMID: [24464962](#) DOI: [10.1136/annrheumdis-2013-204838](#)]
- 17 **Zou X**, Fan Z, Zhao L, Xu W, Zhang J, Jiang Z. Gastrointestinal symptoms as the first manifestation of antiphospholipid syndrome. *BMC Gastroenterol* 2021; **21**: 148 [PMID: [33794795](#) DOI: [10.1186/s12876-021-01736-2](#)]



Published by **Baishideng Publishing Group Inc**
7041 Koll Center Parkway, Suite 160, Pleasanton, CA 94566, USA

Telephone: +1-925-3991568

E-mail: bpgoffice@wjgnet.com

Help Desk: <https://www.f6publishing.com/helpdesk>

<https://www.wjgnet.com>

