


# World Journal of *Clinical Cases*

*World J Clin Cases* 2023 May 16; 11(14): 3114-3368



## Contents

Thrice Monthly Volume 11 Number 14 May 16, 2023

## OPINION REVIEW

- 3114 Modernising autism spectrum disorder model engineering and treatment *via* CRISPR-Cas9: A gene reprogramming approach

*Sandhu A, Kumar A, Rawat K, Gautam V, Sharma A, Saha L*

## REVIEW

- 3128 Burden of disability in type 2 diabetes mellitus and the moderating effects of physical activity

*Oyewole OO, Ale AO, Ogunlana MO, Gurayah T*

## MINIREVIEWS

- 3140 Postoperative hypoxemia for patients undergoing Stanford type A aortic dissection

*Liu HY, Zhang SP, Zhang CX, Gao QY, Liu YY, Ge SL*

## ORIGINAL ARTICLE

## Case Control Study

- 3148 Impact of extended nursing model after multi-disciplinary treatment on young patient with post-stroke

*Xu XY, Pang ZJ, Li MH, Wang K, Song J, Cao Y, Fang M*

- 3158 Changes and significance of serum ubiquitin carboxyl-terminal hydrolase L1 and glial fibrillary acidic protein in patients with glioma

*Zhu QH, Wu JK, Hou GL*

## Retrospective Study

- 3167 Multitrack and multianchor point screw technique combined with the Wiltse approach for lesion debridement for lumbar tuberculosis

*Yuan YF, Ren ZX, Zhang C, Li GJ, Liu BZ, Li XD, Miao J, Li JF*

- 3176 Clinical features and prognostic factors in 49 patients with follicular lymphoma at a single center: A retrospective analysis

*Wu H, Sun HC, Ouyang GF*

- 3187 Value of optical coherence tomography measurement of macular thickness and optic disc parameters for glaucoma screening in patients with high myopia

*Mu H, Li RS, Yin Z, Feng ZL*

## Observational Study

- 3195 Comparative study of the clinical efficacy of all-inside and traditional techniques in anterior cruciate ligament reconstruction

*An BJ, Wang YT, Zhao Z, Wang MX, Xing GY*

- 3204** Positioning and design by computed tomography imaging in neuroendoscopic surgery of patients with chronic subdural hematoma

*Wang XJ, Yin YH, Zhang LY, Wang ZF, Sun C, Cui ZM*

- 3211** Evaluation of chronic idiopathic tinnitus and its psychosocial triggers

*Hamed SA, Attiah FA, Fawzy M, Azzam M*

- 3224** Intestinal complications in patients with Crohn's disease in the Brazilian public healthcare system between 2011 and 2020

*Sasaki LY, Martins AL, Galhardi-Gasparini R, Saad-Hossne R, Ritter AMV, Barreto TB, Marcolino T, Balula B, Yang-Santos C*

### Randomized Controlled Trial

- 3238** Effect of non-pharmacological treatment on the full recovery of social functioning in patients with attention deficit hyperactivity disorder

*Lv YB, Cheng W, Wang MH, Wang XM, Hu YL, Lv LQ*

### CASE REPORT

- 3248** Diagnosis of tuberculous uveitis by the macrogenome of intraocular fluid: A case report and review of the literature

*Zhang YK, Guan Y, Zhao J, Wang LF*

- 3256** Intragastric fish bones migrate into the liver: A case report

*Dai MG, Zheng JJ, Yang J, Ye B*

- 3261** Primary seminal vesicle adenocarcinoma with a history of seminal vesicle cyst: A case report and review of literature

*Yao Y, Liu S, He YL, Luo L, Zhang GM*

- 3267** Immune checkpoint inhibitor therapy-induced autoimmune polyendocrine syndrome type II and Crohn's disease: A case report

*Gao MJ, Xu Y, Wang WB*

- 3275** Late-onset mitochondrial encephalomyopathy with lactic acidosis and stroke-like episodes syndrome with mitochondrial DNA 3243A>G mutation masquerading as autoimmune encephalitis: A case report

*Wang JW, Yuan XB, Chen HF*

- 3282** Metastatic gastric cancer from breast carcinoma presenting with paraneoplastic rheumatic syndrome: A case report

*Rech MB, da-Cruz ER, Salgado K, Balbinot RA, Balbinot SS, Soldera J*

- 3288** Novel mutation of SPG4 gene in a Chinese family with hereditary spastic paraplegia: A case report

*Wang J, Bu WT, Zhu MJ, Tang JY, Liu XM*

- 3295** Chronic pulmonary mucormycosis caused by rhizopus microsporus mimics lung carcinoma in an immunocompetent adult: A case report

*Guo XZ, Gong LH, Wang WX, Yang DS, Zhang BH, Zhou ZT, Yu XH*

- 3304** Idiopathic sclerosing mesenteritis presenting with small bowel volvulus in a patient with antiphospholipid syndrome: A case report  
*Chennavasin P, Gururatsakul M*
- 3311** *Neisseria mucosa* - A rare cause of peritoneal dialysis-related peritonitis: A case report  
*Ren JM, Zhang XY, Liu SY*
- 3317** Rectal prolapse in a 30-year-old bladder stone male patient: A case report  
*Ding HX, Huang JG, Feng C, Tai SC*
- 3323** Successful treatment of veno-arterial extracorporeal membrane oxygenation complicated with left ventricular thrombus by intravenous thrombolysis: A case report  
*Wang YD, Lin JF, Huang XY, Han XD*
- 3330** Successful remimazolam sedation-epidural block in an older patient with severe chronic obstructive pulmonary disease: A case report  
*Yu JJ, Pei HS, Meng Y*
- 3340** *De novo* mutation of NAXE (APOAIBP)-related early-onset progressive encephalopathy with brain edema and/or leukoencephalopathy-1: A case report  
*Ding L, Huang TT, Ying GH, Wang SY, Xu HF, Qian H, Rahman F, Lu XP, Guo H, Zheng G, Zhang G*
- 3351** Iatrogenic atlantoaxial rotatory subluxation after thyroidectomy in a pediatric patient: A case report  
*Hong WJ, Lee JK, Hong JH, Han MS, Lee SS*
- 3356** Bladder metastasis from epidermal growth factor receptor mutant lung cancer: A case report  
*Jin CB, Yang L*
- 3362** Primary rectal mucosa-associated lymphoid tissue lymphoma treated with only endoscopic submucosal dissection: A case report  
*Lee WS, Noh MG, Joo YE*

**ABOUT COVER**

Editorial Board Member of *World Journal of Clinical Cases*, Jaw-Yuan Wang, MD, PhD, Professor, Surgical Oncologist, Department of Surgery, Kaohsiung Medical University Hospital, Kaohsiung Medical University, Kaohsiung 807, Taiwan. jawyuanwang@gmail.com

**AIMS AND SCOPE**

The primary aim of *World Journal of Clinical Cases* (WJCC, *World J Clin Cases*) is to provide scholars and readers from various fields of clinical medicine with a platform to publish high-quality clinical research articles and communicate their research findings online.

WJCC mainly publishes articles reporting research results and findings obtained in the field of clinical medicine and covering a wide range of topics, including case control studies, retrospective cohort studies, retrospective studies, clinical trials studies, observational studies, prospective studies, randomized controlled trials, randomized clinical trials, systematic reviews, meta-analysis, and case reports.

**INDEXING/ABSTRACTING**

The WJCC is now abstracted and indexed in Science Citation Index Expanded (SCIE, also known as SciSearch®), Journal Citation Reports/Science Edition, Current Contents®/Clinical Medicine, PubMed, PubMed Central, Scopus, Reference Citation Analysis, China National Knowledge Infrastructure, China Science and Technology Journal Database, and Superstar Journals Database. The 2022 Edition of Journal Citation Reports® cites the 2021 impact factor (IF) for WJCC as 1.534; IF without journal self cites: 1.491; 5-year IF: 1.599; Journal Citation Indicator: 0.28; Ranking: 135 among 172 journals in medicine, general and internal; and Quartile category: Q4. The WJCC's CiteScore for 2021 is 1.2 and Scopus CiteScore rank 2021: General Medicine is 443/826.

**RESPONSIBLE EDITORS FOR THIS ISSUE**

Production Editor: Hua-Ge Yin; Production Department Director: Xu Guo; Editorial Office Director: Jin-Lei Wang.

**NAME OF JOURNAL**

*World Journal of Clinical Cases*

**ISSN**

ISSN 2307-8960 (online)

**LAUNCH DATE**

April 16, 2013

**FREQUENCY**

Thrice Monthly

**EDITORS-IN-CHIEF**

Bao-Gan Peng, Jerzy Tadeusz Chudek, George Kontogeorgos, Maurizio Serati, Ja Hyeon Ku

**EDITORIAL BOARD MEMBERS**

<https://www.wjgnet.com/2307-8960/editorialboard.htm>

**PUBLICATION DATE**

May 16, 2023

**COPYRIGHT**

© 2023 Baishideng Publishing Group Inc

**INSTRUCTIONS TO AUTHORS**

<https://www.wjgnet.com/bpg/gerinfo/204>

**GUIDELINES FOR ETHICS DOCUMENTS**

<https://www.wjgnet.com/bpg/GerInfo/287>

**GUIDELINES FOR NON-NATIVE SPEAKERS OF ENGLISH**

<https://www.wjgnet.com/bpg/gerinfo/240>

**PUBLICATION ETHICS**

<https://www.wjgnet.com/bpg/GerInfo/288>

**PUBLICATION MISCONDUCT**

<https://www.wjgnet.com/bpg/gerinfo/208>

**ARTICLE PROCESSING CHARGE**

<https://www.wjgnet.com/bpg/gerinfo/242>

**STEPS FOR SUBMITTING MANUSCRIPTS**

<https://www.wjgnet.com/bpg/GerInfo/239>

**ONLINE SUBMISSION**

<https://www.f6publishing.com>





## *Neisseria mucosa* - A rare cause of peritoneal dialysis-related peritonitis: A case report

Jian-Min Ren, Xiao-Yao Zhang, Si-Yu Liu

**Specialty type:** Medicine, research and experimental

**Provenance and peer review:** Unsolicited article; Externally peer reviewed.

**Peer-review model:** Single blind

**Peer-review report's scientific quality classification**

Grade A (Excellent): 0  
Grade B (Very good): 0  
Grade C (Good): C, C  
Grade D (Fair): 0  
Grade E (Poor): 0

**P-Reviewer:** Ferreira GSA, Brazil; Suwanto D, Indonesia

**Received:** February 2, 2023

**Peer-review started:** February 2, 2023

**First decision:** February 17, 2023

**Revised:** February 23, 2023

**Accepted:** March 30, 2023

**Article in press:** March 30, 2023

**Published online:** May 16, 2023



**Jian-Min Ren, Si-Yu Liu,** Department of Clinical Laboratory, The Fifth Affiliated Hospital of Wenzhou Medical University, Lishui 323000, Zhejiang Province, China

**Xiao-Yao Zhang,** Department of Rehabilitation, The Fifth Affiliated Hospital of Wenzhou Medical University, Lishui 323000, Zhejiang Province, China

**Si-Yu Liu,** The Key Laboratory of Imaging Diagnosis and Minimally Invasive Interventional Research of Zhejiang Province, Zhejiang University Lishui Hospital, Lishui 323000, Zhejiang Province, China

**Corresponding author:** Si-Yu Liu, MD, Deputy Director, Department of Clinical Laboratory, The Fifth Affiliated Hospital of Wenzhou Medical University, No. 289 Kuocang Road, Liandu District, Lishui 323000, Zhejiang Province, China. [77744832@qq.com](mailto:77744832@qq.com)

### Abstract

#### BACKGROUND

*Neisseria mucosa* is a gram negative diplococcus belonging to the genus *Neisseria* found commonly in the upper respiratory tract. It is typically a commensal organism when it is parasitic on oral and nasal mucosa. To our knowledge, it does not cause disease in healthy individuals with normal immunity, but can be pathogenic in those with impaired immune function or change in bacterial colonization site. *Neisseria mucosa* has been reported to cause bacterial meningitis, conjunctivitis, pneumonia, endocarditis, peritonitis and urethritis. However, peritoneal dialysis-related peritonitis caused by *Neisseria mucosa* is extremely rare in clinical practice, which has not previously been reported in China.

#### CASE SUMMARY

A 55-year-old female presented to the nephrology clinic with upper abdominal pain without apparent cause, accompanied by nausea, vomiting and diarrhea for two days. The patient had a history of Stage 5 chronic kidney disease for five years, combined with renal hypertension and renal anemia, and was treated with peritoneal dialysis for renal replacement therapy. The patient was subsequently diagnosed with peritoneal dialysis-related peritonitis. Routine examination of peritoneal dialysis fluid showed abdominal infection, and the results of microbial culture of the peritoneal dialysis fluid confirmed *Neisseria mucosa*. Imi-penem/cilastatin 1.0 g q12h was added to peritoneal dialysis fluid for anti-infection treatment. After 24 d, the patient underwent upper extremity arteriovenous fistulation. One month later, the patient was discharged home in a clinically stable state.

## CONCLUSION

Peritonitis caused by *Neisseria mucosa* is rare. Patients with home-based self-dialysis cannot guarantee good medical and health conditions, and require education on self-protection.

**Key Words:** Peritoneal dialysis; Peritonitis; *Neisseria mucosa*; Case report

©The Author(s) 2023. Published by Baishideng Publishing Group Inc. All rights reserved.

**Core Tip:** *Neisseria mucosa* is part of the normal human flora when it is parasitic in the oral and nasal mucosa, and rarely causes infection. However, it may be associated with severe disease when patients undergo invasive, instrumented procedures or have underlying conditions, as shown in the present patient who was undergoing continuous ambulatory peritoneal dialysis. In addition, the infection was also closely related to the patient's health behavior and habits during peritoneal dialysis. Treatment should be based on antimicrobial susceptibility testing and a sufficient and full course of antimicrobial therapy should be given.

**Citation:** Ren JM, Zhang XY, Liu SY. *Neisseria mucosa* - A rare cause of peritoneal dialysis-related peritonitis: A case report. *World J Clin Cases* 2023; 11(14): 3311-3316

**URL:** <https://www.wjgnet.com/2307-8960/full/v11/i14/3311.htm>

**DOI:** <https://dx.doi.org/10.12998/wjcc.v11.i14.3311>

## INTRODUCTION

The Gram-negative diplococci *Neisseria* are commensal bacteria of mucosal surfaces in humans[1]. Two major subspecies, *Neisseria meningitidis* and *Neisseria gonorrhoeae*, are pathogenic in humans, while most other subspecies such as *Neisseria mucosa* are recognized as non-pathogenic. *Neisseria mucosa* is generally not pathogenic in healthy individuals with normal immunity, but can be pathogenic in those with impaired immune function or changes in bacterial colonization sites.

It has been reported that *Neisseria mucosa* is associated with meningitis, endocarditis, pneumonia, bacteremia, arthritis, peritonitis, endophthalmitis and urethritis[2-7]. We herein report the first case of refractory peritoneal dialysis-related peritonitis caused by *Neisseria mucosa* in mainland China.

## CASE PRESENTATION

### Chief complaints

A 55-year-old Chinese female presented to the nephrology clinic with the complaint of abdominal pain for 2 d.

### History of present illness

Symptoms started 2 d before presentation with no obvious cause of upper abdominal pain (the Visual analogue scale was 2), with nausea, vomiting of gastric contents, and diarrhea, with no chills, fever, chest tightness, shortness of breath, edema, hematemesis, or melena.

### History of past illness

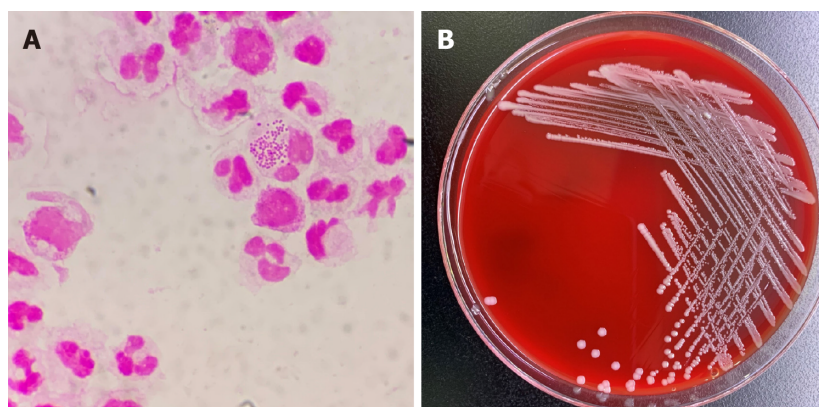
The patient was diagnosed with Stage 5 chronic kidney disease five years ago, combined with renal hypertension and renal anemia. She was treated with peritoneal dialysis for renal replacement therapy, and with compound  $\alpha$ -keto acid tablets, amlodipine tablets, and clonidine tablets.

### Personal and family history

The patient denied a history of hepatitis, tuberculosis and other infectious diseases, diabetes, cardiovascular and cerebrovascular disease, and had no family history of malignant tumors.

### Physical examination

On initial evaluation, vital signs revealed a temperature of 36.5 °C, pulse rate of 98 bpm, blood pressure of 116/77 mmHg and a respiration rate of 19 breaths/min. The patient was conscious and oriented without chills, diarrhea, chest tightness, chest pain or any other discomfort. No yellowing of the skin or eyes was observed. Both lungs were clear, no dry or moist crackles (rales) were heard. Furthermore, the



DOI: 10.12998/wjcc.v11.i14.3311 Copyright ©The Author(s) 2023.

**Figure 1** Smear examination and bacterial culture results of peritoneal dialysis fluid. A: Gram staining of peritoneal dialysate specimens after centrifugation (×1000); B: Colony morphology on a blood agar plate at 35 °C, 5% CO<sub>2</sub> and cultured for 48 h.

abdomen was flat, an abdominal tube was visible on the right lower abdomen, the tunnel had a little exudation, and the tunnel score was 1 point. No tenderness, rebound pain, enlarged liver or spleen, and no tapping pain in both kidneys were observed. No edema was noted in both ankles, limb muscle strength was Grade V, and Babbitt negative.

### Laboratory examinations

Routine blood examination showed the following results: Leukocyte count  $6.0 \times 10^9/L$ , neutrophil percentage 89.7%, hemoglobin 108 g/L; high sensitivity C reactive protein 244.94 mg/L. On the day of admission, routine examination of peritoneal dialysis fluid was performed after disinfection which showed that the fluid was colorless, turbid, with a white blood cell count of 6000/ $\mu L$ , and neutrophils of 95%. The Lifanta test was positive, and dialysate bacterial smear examination showed Gram-negative cocci identified by Gram staining (Figure 1A).

Blood electrolyte results were: Potassium 3.52 mmol/L, sodium 131.9 mmol/L, and chlorine 89.0 mmol/L. After admission, peritoneal dialysis fluid was collected for bacterial smear examination. The peritoneal dialysis fluid was cultured on a Columbia blood agar plate for 48 h, and 2-4 mm, gray-white, round, moist, and raised colonies were observed (Figure 1B). The pure culture was identified as *Neisseria mucosa/mucosa* by a Vitek MS mass spectrometer. In order to obtain accurate identification results, 16sRNA sequencing was performed. The results showed that the sequence was 99.85% consistent with *Neisseria mucosa* (GenBank No. NR\_117696.1). Combined with the colony characteristics, the strain was finally identified as *Neisseria mucosa*.

### Imaging examinations

Hepatobiliary system, spleen, pancreas, kidneys and ureters were examined by brightness-mode ultrasound, and the patient was found to have a right kidney cyst and ascites. She was admitted to hospital after an initial diagnosis of peritonitis. Routine enhanced computed tomography (CT) of the abdomen and pelvis showed that the patient had multiple cysts in both kidneys and pelvic effusion. There was no evidence of intra-abdominal abscess or a focus of infection. Two weeks later, reexamination with CT showed that after treatment of peritonitis, peritoneal thickening has not been completely absorbed caused by peritonitis (Figure 2).

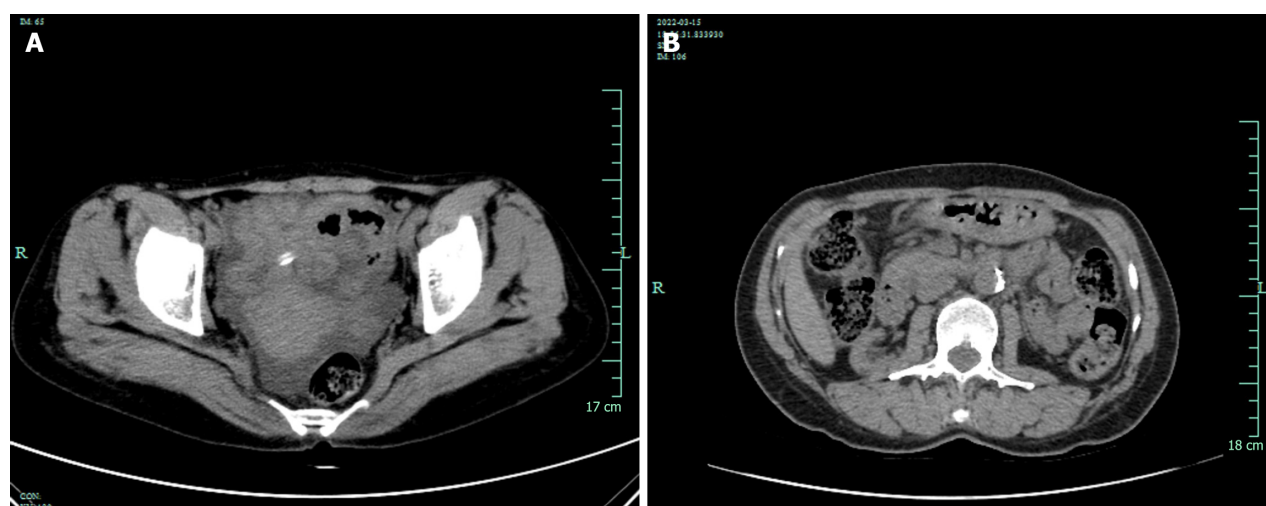
## FINAL DIAGNOSIS

Combined with the patient's medical history, the final diagnosis was peritoneal dialysis-related peritonitis caused by *Neisseria mucosa*.

## TREATMENT

For adequate coverage of Gram-positive and Gram-negative organisms, the empirical antibiotic therapy given was vancomycin 1000 mg qd combined with imipenem/cilastatin 1.0 g q12h added to peritoneal dialysis fluid. In addition, 2.5% dialysate 2 L + 1.5% dialysate 6 L/d continuous ambulatory peritoneal dialysis was carried out to eliminate toxins and maintain water, electrolyte, and acid-base balance. Vancomycin was discontinued after the pathogen was identified, and imipenem/cilastatin injection 1.0





DOI: 10.12998/wjcc.v11.i14.3311 Copyright ©The Author(s) 2023.

**Figure 2** Computed tomography results before and after treatment. A: Before treatment, computed tomography (CT) showed ascites without obvious thickening of the membrane; B: CT reexamination showed that peritoneal thickening has not been completely absorbed caused by peritonitis after treatment.

g q12h for anti-infection treatment was continued. After 8 d, the patient's dialysate was clear and her condition had improved. Ceftazidime injection 1.0 g qd was added to the dialysate for follow-up anti-inflammatory treatment.

## OUTCOME AND FOLLOW-UP

On the 24<sup>th</sup> day of hospitalization, arteriovenous fistulation of the upper extremity was performed. The purpose of surgical treatment is to change his treatment plan from peritoneal dialysis to hemodialysis three months after the operation. The patient was discharged in a stable condition after one month. Two weeks after discharge, the patient was again hospitalized due to peritoneal dialysis-related peritonitis. The same organism-*Neisseria mucosa* was cultured from the patient's peritoneal dialysis fluid. After a detailed medical history enquiry, it was found that the patient frequently used her mouth to open the cap of the dialysate bottle during peritoneal dialysis at home. During her second hospitalization, the patient was treated with imipenem/cilastatin injection 1.0 g q12h added to peritoneal dialysis fluid for 20 d and was cured. The patient is currently undergoing close follow-up observation.

## DISCUSSION

*Neisseria* species other than *Neisseria meningitidis* and *Neisseria gonorrhoeae*, such as *Neisseria mucosa*, *Neisseria subflava*, *Neisseria lactamica*, *Neisseria cinerea*, and *Neisseria mucosa*, are unusual pathogens in humans[8]. *Neisseria mucosa*, originally described as *Diplococcus mucosus* by von Lingelsheim in 1906, frequently colonizes the nasopharynx and dolphin respiratory tract[9]. It was gram-negative diplococcus, with large colonies and mucus type, often fused together. Most strains do not produce pigment, or light gray to light yellow. It can decompose glucose, maltose, fructose and sucrose. It is difficult to distinguish from *Neisseria mucosa* during mass spectrometry identification. Based on whole genome sequencing analysis, *Neisseria mucosa* is the same species as *Neisseria rhesus* and *Neisseria mucosa*, and *Neisseria mucosa* has priority naming rights. Therefore, we further identified the pathogen of this infection as *Neisseria mucosa* by 16sRNA sequencing, combined with biochemical reaction characteristics and colony morphology. According to the literature, *Neisseria* can cause meningitis, conjunctivitis, pneumonia, endocarditis, urethritis and peritonitis[2-6]. There are few reports of peritoneal dialysis-related peritonitis caused by *Neisseria mucosa*. To our knowledge, the first case was reported in 1993 and only 5 cases have been reported so far. Patients were aged 17 to 68 years, with no specificity, and ultimately received effective treatment[10-14]. This is the first case report of peritoneal dialysis-associated peritonitis caused by *Neisseria mucosa* in mainland China.

The patient was diagnosed with Stage 5 chronic kidney disease, combined with renal hypertension, renal anemia, and maintenance peritoneal dialysis for more than 5 years. Therefore, the patient's immune function and nutritional status were poor, and the peritoneal self-defense function was impaired. Combined with the significant increase in systemic infection indicators, the leukocytes in peritoneal dialysis fluid were chemotactic and were mainly polymorphonuclear neutrophils. Bacterial smears and culture results confirmed the diagnosis of peritoneal dialysis-associated peritonitis caused

by *Neisseria mucosa*.

The patient was treated with antibiotics added to peritoneal dialysis fluid for anti-inflammatory treatment. According to the Clinical and Laboratory Standards Institute[3], there is no accepted standard for assessing the antimicrobial sensitivity of *Neisseria mucosa*. We provide *in vitro* drug sensitivity test results for reference: Penicillin G (0.125 µg/mL), ceftriaxone (0.25 µg/mL), meropenem (0.125 µg/mL), combined with the International Society of Peritoneal Dialysis (ISPD) guidelines for the treatment of abdominal infection[15], the first treatment with imipenem/cilastatin resulted in significant improvement, and 8 d after treatment with ceftazidime, the clinical symptoms disappeared.

However, the patient was readmitted to hospital due to peritonitis caused by *Neisseria mucosa* two weeks later, according to ISPD peritonitis guideline recommendations in 2022[16]. The patient's second infection was defined as a relapse. The reason for the second infection may be that the first treatment did not involve removal of the peritoneal dialysis tube, resulting in a small amount of bacterial colonization. In addition, after a detailed medical history enquiry, it was found that the patient frequently used her mouth to open the cap of the dialysate bottle during peritoneal dialysis at home. Therefore, it is speculated that the patient's *Neisseria mucosa* was derived from the peritoneal dialysis fluid contaminated by her own saliva and caused repeat peritonitis.

In summary, we report a case of peritoneal dialysis-related peritonitis caused by repeated infection with *Neisseria mucosa*. There are few reports on infections caused by *Neisseria mucosa*. The pathogenic mechanism, infection route and treatment plan of *Neisseria mucosa* require further study. Peritoneal dialysis patients, due to long-term impaired renal function and low immunity, should pay attention to the prevention of peritonitis. In particular, in home-based self-dialysis patients, medical and health conditions are poor; thus, education on relevant protective measures is needed.

## CONCLUSION

Peritoneal dialysis patients, due to long-term impaired renal function and low immunity, should pay attention to the prevention of peritonitis. *Neisseria mucosa*, as part of the normal flora of the human oral cavity, rarely causes infection in the body, especially the abdominal cavity. Peritonitis caused by *Neisseria mucosa* is very rare. *Neisseria mucosa* was detected during two hospitalizations for peritonitis in this case, which may have been related to the patient's habit of opening the peritoneal dialysis fluid cap using her mouth. Unfortunately, we were unable to confirm whether *Neisseria mucosa* from the patient's mouth was the same strain as the two isolated strains. However, this case demonstrates that home-based self-dialysis patients, because they cannot guarantee good medical and health conditions, need to be repeatedly educated and protected.

## FOOTNOTES

**Author contributions:** Ren JM contributed to manuscript writing and editing, and data collection; Zhang XY contributed to data analysis; Liu SY contributed to conceptualization and supervision; all authors have read and approved the final manuscript.

**Informed consent statement:** Informed written consent was obtained from the patient for publication of this report and any accompanying images.

**Conflict-of-interest statement:** All the authors report no relevant conflicts of interest for this article.

**CARE Checklist (2016) statement:** The authors have read the CARE Checklist (2016), and the manuscript was prepared and revised according to the CARE Checklist (2016).

**Open-Access:** This article is an open-access article that was selected by an in-house editor and fully peer-reviewed by external reviewers. It is distributed in accordance with the Creative Commons Attribution NonCommercial (CC BY-NC 4.0) license, which permits others to distribute, remix, adapt, build upon this work non-commercially, and license their derivative works on different terms, provided the original work is properly cited and the use is non-commercial. See: <https://creativecommons.org/licenses/by-nc/4.0/>

**Country/Territory of origin:** China

**ORCID number:** Jian-Min Ren 0000-0001-6005-0374; Xiao-Yao Zhang 0000-0002-5144-7027; Si-Yu Liu 0000-0001-7475-0267.

**S-Editor:** Hu YR

**L-Editor:** A

**P-Editor:** Chen YX

## REFERENCES

- 1 **Zapun A**, Morlot C, Taha MK. Resistance to  $\beta$ -Lactams in *Neisseria* ssp Due to Chromosomally Encoded Penicillin-Binding Proteins. *Antibiotics (Basel)* 2016; **5** [PMID: [27690121](#) DOI: [10.3390/antibiotics5040035](#)]
- 2 **Altdorfer A**, Pirotte BF, Gaspard L, Gregoire E, Firre E, Moerman F, Moonen M, Sanoussi A, Van Esbroeck M, Mori M. Infective endocarditis caused by *Neisseria mucosa* on a prosthetic pulmonary valve with false positive serology for *Coxiella burnetii* - The first described case. *IDCases* 2021; **24**: e01146 [PMID: [34026536](#) DOI: [10.1016/j.idcr.2021.e01146](#)]
- 3 **Khan KN**, Saxena R, Choti M, Ariyamuthu VK. *Neisseria mucosa* Peritonitis in the Setting of a Migrated Intrauterine Device. *Adv Perit Dial* 2018; **34**: 47-49 [PMID: [30480537](#)]
- 4 **Osses DF**, Dijkmans AC, van Meurs AH, Froeling FM. *Neisseria Mucosa*: A New Urinary Tract Pathogen? *Curr Urol* 2017; **10**: 108-110 [PMID: [28785197](#) DOI: [10.1159/000447161](#)]
- 5 **Mechergui A**, Achour W, Baaboura R, Ouertani H, Lakhali A, Torjemane L, Othman TB, Hassen AB. Case report of bacteremia due to *Neisseria mucosa*. *APMIS* 2014; **122**: 359-361 [PMID: [23905778](#) DOI: [10.1111/apm.12144](#)]
- 6 **Durán E**, Salvo S, Gil J, Sanjoaquin I. [Pneumonia and bacteremia due to *Neisseria mucosa* in a human immunodeficient virus seropositive patient parenteral drug abuser]. *Enferm Infecc Microbiol Clin* 2011; **29**: 236-237 [PMID: [21354666](#) DOI: [10.1016/j.eimc.2010.09.006](#)]
- 7 **Gini GA**. Ocular infection in a newborn caused by *Neisseria mucosa*. *J Clin Microbiol* 1987; **25**: 1574-1575 [PMID: [3624452](#) DOI: [10.1128/jcm.25.8.1574-1575.1987](#)]
- 8 **John EB**, Raphael D, Martin JB. Mandell, Douglas, and Bennett's principles and practice of infectious diseases, 9th ed. Elsevier, 2019: 3049-3135
- 9 **Jin Y**, Xu H, Yao Q, Gu B, Wang Z, Wang T, Yu X, Lu Y, Zheng B, Zhang Y. Confirmation of the Need for Reclassification of *Neisseria mucosa* and *Neisseria sicca* Using Average Nucleotide Identity Blast and Phylogenetic Analysis of Whole-Genome Sequencing: Hinted by Clinical Misclassification of a *Neisseria mucosa* Strain. *Front Microbiol* 2021; **12**: 780183 [PMID: [35281306](#) DOI: [10.3389/fmicb.2021.780183](#)]
- 10 **Arora S**, Chitkara NL. Non-pathogenic neisserian *Neisseria catarrhalis*--as cause of meningitis. *J Assoc Physicians India* 1973; **21**: 255-257 [PMID: [4792800](#)]
- 11 **Macia M**, Vega N, Elcuaz R, Aterido T, Palop L. *Neisseria mucosa* peritonitis in CAPD: another case of the "nonpathogenic" *Neisseriae* infection. *Perit Dial Int* 1993; **13**: 72-73 [PMID: [8443288](#) DOI: [10.1177/089686089301300121](#)]
- 12 **Lee WC**, Yang WC, Chen TW, Huang CH, Lin CC. Unusual presentation of *Neisseria mucosa* peritonitis with persistent ultrafiltration failure and clear effluent. *Perit Dial Int* 2003; **23**: 198-199 [PMID: [12713091](#) DOI: [10.1177/089686080302300219](#)]
- 13 **Shetty AK**, Nagaraj SK, Lorentz WB, Bitzan M. Peritonitis due to *Neisseria mucosa* in an adolescent receiving peritoneal dialysis. *Infection* 2005; **33**: 390-392 [PMID: [16258875](#) DOI: [10.1007/s15010-005-5074-4](#)]
- 14 **Awdisho A**, Bermudez M. A Case Report of *Neisseria Mucosa* Peritonitis in a Chronic Ambulatory Peritoneal Dialysis Patient. *Infect Dis Rep* 2016; **8**: 6950 [PMID: [28191300](#) DOI: [10.4081/idr.2016.6950](#)]
- 15 **Humphries R**, Bobenchik AM, Hindler JA, Schuetz AN. Overview of Changes to the Clinical and Laboratory Standards Institute Performance Standards for Antimicrobial Susceptibility Testing, M100, 31st Edition. *J Clin Microbiol* 2021; **59**: e0021321 [PMID: [34550809](#) DOI: [10.1128/JCM.00213-21](#)]
- 16 **Li PK**, Chow KM, Cho Y, Fan S, Figueiredo AE, Harris T, Kanjanabuch T, Kim YL, Madero M, Malyszko J, Mehrotra R, Okpechi IG, Perl J, Piraino B, Runnegar N, Teitelbaum I, Wong JK, Yu X, Johnson DW. ISPD peritonitis guideline recommendations: 2022 update on prevention and treatment. *Perit Dial Int* 2022; **42**: 110-153 [PMID: [35264029](#) DOI: [10.1177/08968608221080586](#)]



Published by **Baishideng Publishing Group Inc**  
7041 Koll Center Parkway, Suite 160, Pleasanton, CA 94566, USA

**Telephone:** +1-925-3991568

**E-mail:** [bpgoffice@wjgnet.com](mailto:bpgoffice@wjgnet.com)

**Help Desk:** <https://www.f6publishing.com/helpdesk>

<https://www.wjgnet.com>

