

# World Journal of *Clinical Cases*

*World J Clin Cases* 2023 May 26; 11(15): 3369-3663



## Contents

Thrice Monthly Volume 11 Number 15 May 26, 2023

## REVIEW

- 3369 Superior mesenteric artery syndrome: Diagnosis and management  
*Oka A, Awoniyi M, Hasegawa N, Yoshida Y, Tobita H, Ishimura N, Ishihara S*

## MINIREVIEWS

- 3385 Astrocytes in the central nervous system and their functions in health and disease: A review  
*Gradisnik L, Velnar T*
- 3395 Progress in diagnosis and treatment of acute injury to the anterior talofibular ligament  
*Chen RP, Wang QH, Li MY, Su XF, Wang DY, Liu XH, Li ZL*
- 3408 Synchronous manifestation of colorectal cancer and intraductal papillary mucinous neoplasms  
*Mirchev MB, Boeva I, Peshevska-Sekulovska M, Stoitsov V, Peruhova M*
- 3418 Clinical infections in neurosurgical oncology: An overview  
*Velnar T, Kocivnik N, Bosnjak R*
- 3434 Effectiveness and safety of subthreshold vibration over suprathreshold vibration in treatment of muscle fatigue in elderly people  
*Mohamed AA, Khaled E, Hesham A, Khalf A*

## ORIGINAL ARTICLE

## Clinical and Translational Research

- 3444 Establishment of a prognostic model related to tregs and natural killer cells infiltration in bladder cancer  
*Yang YJ, Xu XQ, Zhang YC, Hu PC, Yang WX*

## Retrospective Study

- 3457 New native tissue repair for pelvic organ prolapse: Medium-term outcomes of laparoscopic vaginal stump-round ligament fixation  
*Kakinuma T, Kaneko A, Kakinuma K, Imai K, Takeshima N, Ohwada M*
- 3464 Demographic characteristics of patients who underwent anterior cruciate ligament reconstruction at a tertiary care hospital in India  
*Malv SK, Mahmood A, Vatsya P, Garika SS, Mittal R, Nagar M*
- 3471 Usefulness of transcatheter arterial embolization for eighty-three patients with secondary postpartum hemorrhage: Focusing on difference in angiographic findings  
*Kim BM, Jeon GS, Choi MJ, Hong NS*
- 3481 Chronic otitis media and middle ear variants: Is there relation?  
*Gökharman FD, Şenbil DC, Aydın S, Karavaş E, Özdemir Ö, Yalçın AG, Koşar PN*

**Observational Study**

- 3491** Observation of the effect of angiojet to treat acute lower extremity arterial embolization  
*Meng XH, Xie XP, Liu YC, Huang CP, Wang LJ, Liu HY, Fang X, Zhang GH*
- 3502** Outbreak of methanol-induced optic neuropathy in early COVID-19 era; effectiveness of erythropoietin and methylprednisolone therapy  
*Tabatabaei SA, Amini M, Haydar AA, Soleimani M, Cheraqpour K, Shahriari M, Hassanian-Moghaddam H, Zamani N, Akbari MR*

**META-ANALYSIS**

- 3511** Impact of heart failure on outcomes in patients with sepsis: A systematic review and meta-analysis  
*Zhu MY, Tang XK, Gao Y, Xu JJ, Gong YQ*

**CASE REPORT**

- 3522** New clinical application of digital intraoral scanning technology in occlusal reconstruction: A case report  
*Hou C, Zhu HZ, Xue B, Song HJ, Yang YB, Wang XX, Sun HQ*
- 3533** Rare adult neuronal ceroid lipofuscinosis associated with *CLN6* gene mutations: A case report  
*Wang XQ, Chen CB, Zhao WJ, Fu GB, Zhai Y*
- 3542** Enzyme replacement therapy in two patients with classic Fabry disease from the same family tree: Two case reports  
*Harigane Y, Morimoto I, Suzuki O, Temmoku J, Sakamoto T, Nakamura K, Machii K, Miyata M*
- 3552** Immune-mediated necrotizing myopathy: Report of two cases  
*Chen BH, Zhu XM, Xie L, Hu HQ*
- 3560** Retroperitoneal cavernous hemangioma misdiagnosed as lymphatic cyst: A case report and review of the literature  
*Hou XF, Zhao ZX, Liu LX, Zhang H*
- 3571** Malignant melanoma resection and reconstruction with the first manifestation of lumbar metastasis: A case report  
*Guo ZX, Zhao XL, Zhao ZY, Zhu QY, Wang ZY, Xu M*
- 3578** Promising way to address massive intragastric clotting in patients with acute upper gastrointestinal bleeding: A case report  
*Liu SX, Shi B, Liu YF, Shan JY, Sun B*
- 3583** Pyogenic spondylitis caused by *Escherichia coli*: A case report and literature review  
*Zou LC, Qian J, Bian ZY, Wang XP, Xie T*
- 3592** Primary ovarian choriocarcinoma occurring in a postmenopausal woman: A case report  
*Dai GL, Tang FR, Wang DQ*

- 3599** Treatment of severe open bite and mandibular condyle anterior displacement by mini-screws and four second molars extraction: A case report  
*Huang ZW, Yang R, Gong C, Zhang CX, Wen J, Li H*
- 3612** Application of apical negative pressure irrigation in the nonsurgical treatment of radicular cysts: A case report  
*Chen GP, Zhang YZ, Ling DH*
- 3619** Treatment of postherpetic neuralgia by bone marrow aspirate injection: A case report  
*Honda Pazili T*
- 3625** Non-target lung embolization during portal vein embolization due to an unrecognized portosystemic venous fistula: A case report  
*Alharbi SR, Bin Nasif M, Alwaily HB*
- 3631** Acute abdomen caused by spontaneous rupture of degenerative hysteromyoma during pregnancy: A case report  
*Xu Y, Shen X, Pan XY, Gao S*
- 3637** Atypical progress of frozen shoulder after COVID-19 vaccination: A case report  
*Jo HS, Kim HM, Han JY, Park HK*
- 3643** Co-existing squamous cell carcinoma and chronic myelomonocytic leukemia with *ASXL1* and *EZH2* gene mutations: A case report  
*Deng LJ, Dong Y, Li MM, Sun CG*
- 3651** Diagnosis based on electromagnetic navigational bronchoscopy-guided biopsied peripheral lung lesions in a 10-year-old girl: A case report  
*Meng FZ, Chen QH, Gao M, Zeng L, Lin JR, Zheng JY*
- 3658** Relationship between intralobar pulmonary sequestration and type A aortic dissection: A case report  
*Wang YJ, Chen YY, Lin GH*

**ABOUT COVER**

Editorial Board Member of *World Journal of Clinical Cases*, Gulali Aktas, MD, Professor, Department of Internal Medicine, Abant Izzet Baysal University Hospital, Bolu 14030, Turkey. draliaktas@yahoo.com

**AIMS AND SCOPE**

The primary aim of *World Journal of Clinical Cases* (WJCC, *World J Clin Cases*) is to provide scholars and readers from various fields of clinical medicine with a platform to publish high-quality clinical research articles and communicate their research findings online.

WJCC mainly publishes articles reporting research results and findings obtained in the field of clinical medicine and covering a wide range of topics, including case control studies, retrospective cohort studies, retrospective studies, clinical trials studies, observational studies, prospective studies, randomized controlled trials, randomized clinical trials, systematic reviews, meta-analysis, and case reports.

**INDEXING/ABSTRACTING**

The WJCC is now abstracted and indexed in Science Citation Index Expanded (SCIE, also known as SciSearch®), Journal Citation Reports/Science Edition, Current Contents®/Clinical Medicine, PubMed, PubMed Central, Scopus, Reference Citation Analysis, China National Knowledge Infrastructure, China Science and Technology Journal Database, and Superstar Journals Database. The 2022 Edition of Journal Citation Reports® cites the 2021 impact factor (IF) for WJCC as 1.534; IF without journal self cites: 1.491; 5-year IF: 1.599; Journal Citation Indicator: 0.28; Ranking: 135 among 172 journals in medicine, general and internal; and Quartile category: Q4. The WJCC's CiteScore for 2021 is 1.2 and Scopus CiteScore rank 2021: General Medicine is 443/826.

**RESPONSIBLE EDITORS FOR THIS ISSUE**

Production Editor: *Ying-Yi Yuan*; Production Department Director: *Xiang Li*; Editorial Office Director: *Jin-Lei Wang*.

**NAME OF JOURNAL**

*World Journal of Clinical Cases*

**ISSN**

ISSN 2307-8960 (online)

**LAUNCH DATE**

April 16, 2013

**FREQUENCY**

Thrice Monthly

**EDITORS-IN-CHIEF**

Bao-Gan Peng, Jerzy Tadeusz Chudek, George Kontogeorgos, Maurizio Serati, Ja Hyeon Ku

**EDITORIAL BOARD MEMBERS**

<https://www.wjgnet.com/2307-8960/editorialboard.htm>

**PUBLICATION DATE**

May 26, 2023

**COPYRIGHT**

© 2023 Baishideng Publishing Group Inc

**INSTRUCTIONS TO AUTHORS**

<https://www.wjgnet.com/bpg/gerinfo/204>

**GUIDELINES FOR ETHICS DOCUMENTS**

<https://www.wjgnet.com/bpg/GerInfo/287>

**GUIDELINES FOR NON-NATIVE SPEAKERS OF ENGLISH**

<https://www.wjgnet.com/bpg/gerinfo/240>

**PUBLICATION ETHICS**

<https://www.wjgnet.com/bpg/GerInfo/288>

**PUBLICATION MISCONDUCT**

<https://www.wjgnet.com/bpg/gerinfo/208>

**ARTICLE PROCESSING CHARGE**

<https://www.wjgnet.com/bpg/gerinfo/242>

**STEPS FOR SUBMITTING MANUSCRIPTS**

<https://www.wjgnet.com/bpg/GerInfo/239>

**ONLINE SUBMISSION**

<https://www.f6publishing.com>



Retrospective Study

# New native tissue repair for pelvic organ prolapse: Medium-term outcomes of laparoscopic vaginal stump-round ligament fixation

Toshiyuki Kakinuma, Ayaka Kaneko, Kaoru Kakinuma, Ken Imai, Nobuhiro Takeshima, Michitaka Ohwada

**Specialty type:** Medicine, research and experimental

**Provenance and peer review:**

Unsolicited article; Externally peer reviewed.

**Peer-review model:** Single blind

**Peer-review report's scientific quality classification**

Grade A (Excellent): 0  
Grade B (Very good): B, B  
Grade C (Good): C, C, C  
Grade D (Fair): D  
Grade E (Poor): 0

**P-Reviewer:** He Z, China; Hegazy AA, Egypt; Martín Del Olmo JC, Spain; Samara AA, Greece

**Received:** January 9, 2023

**Peer-review started:** January 9, 2023

**First decision:** February 2, 2023

**Revised:** March 2, 2023

**Accepted:** April 14, 2023

**Article in press:** April 14, 2023

**Published online:** May 26, 2023



**Toshiyuki Kakinuma, Ayaka Kaneko, Kaoru Kakinuma, Ken Imai, Nobuhiro Takeshima, Michitaka Ohwada**, Department of Obstetrics and Gynecology, International University of Health and Welfare, Nasushiobara 329-2763, Japan

**Corresponding author:** Toshiyuki Kakinuma, MD, PhD, Doctor, Professor, Department of Obstetrics and Gynecology, International University of Health and Welfare, 537-3, Iguchi, Nasushiobara 329-2763, Japan. [tokakinuma@gmail.com](mailto:tokakinuma@gmail.com)

## Abstract

### BACKGROUND

Laparoscopic sacrocolpopexy for pelvic organ prolapse (POP) is a new and widely used approach; however, ever since the United States Food and Drug Administration warned against the use of surgical mesh, repairs performed using patients' tissues [*i.e.* native tissue repair (NTR)] instead of mesh have attracted much attention. At our hospital, laparoscopic sacrocolpopexy (the Shull method) was introduced in 2017. However, patients with more severe POP who have a long vaginal canal and overextended uterosacral ligaments may not be candidates for this procedure.

### AIM

To validate a new NTR treatment for POP, we examined patients undergoing laparoscopic vaginal stump-round ligament fixation (the Kakinuma method).

### METHODS

The study patients were 30 individuals with POP who underwent surgery using the Kakinuma method between January 2020 and December 2021 and who were followed up for > 12 mo after surgery. We retrospectively examined surgical outcomes for surgery duration, blood loss, intraoperative complications, and incidence of recurrence. The Kakinuma method involves round ligament suturing and fixation on both sides, effectively lifting the vaginal stump after laparoscopic hysterectomy.

### RESULTS

The patients' mean age was  $66.5 \pm 9.1$  (45-82) years, gravidity was  $3.1 \pm 1.4$  (2-7), parity was  $2.5 \pm 0.6$  (2-4) times, and body mass index was  $24.5 \pm 3.3$  (20.9-32.8) kg/m<sup>2</sup>. According to the POP quantification stage classification, there were 8 patients with stage II, 11 with stage III, and 11 with stage IV. The mean surgery duration was  $113.4 \pm 22.6$  (88-148) min, and the mean blood loss was  $26.5 \pm 39.7$

(10-150) mL. There were no perioperative complications. None of the patients exhibited reduced activities of daily living or cognitive impairment after hospital discharge. No cases of POP recurrence were observed 12 mo after the operation.

### CONCLUSION

The Kakinuma method, similar to conventional NTR, may be an effective treatment for POP.

**Key Words:** Pelvic organ prolapse; Native tissue repair; Laparoscopic surgery; Round ligament; Kakinuma method

©The Author(s) 2023. Published by Baishideng Publishing Group Inc. All rights reserved.

**Core Tip:** The conventional method of performing repairs using patients' own tissues [also called native tissue repair (NTR)] instead of using mesh is being reconsidered. NTR surgical techniques include vaginal stump–uterosacral ligament fixation (Shull method), which has reported satisfactory surgical outcomes. Many patients with severe pelvic organ prolapse have long vaginal canals and overstretched sacral uterine ligaments, which prevent effective repair using the Shull method. The Kakinuma method (laparoscopic vaginal stump–round ligament fixation) lifts the vaginal stump to an anatomically higher position. This method is an effective treatment method for pelvic organ prolapse, similar to conventional NTR.

**Citation:** Kakinuma T, Kaneko A, Kakinuma K, Imai K, Takeshima N, Ohwada M. New native tissue repair for pelvic organ prolapse: Medium-term outcomes of laparoscopic vaginal stump–round ligament fixation. *World J Clin Cases* 2023; 11(15): 3457-3463

**URL:** <https://www.wjgnet.com/2307-8960/full/v11/i15/3457.htm>

**DOI:** <https://dx.doi.org/10.12998/wjcc.v11.i15.3457>

## INTRODUCTION

Pelvic organ prolapse (POP) is caused by factors such as high parity and aging and refers to the abnormal positioning of pelvic organs caused by the loosening of pelvic floor muscles and endopelvic fascia. POP often manifests as a pelvic floor hernia.

Epidemiological surveys in Western countries have reported that POP is observed in 44% of women who have experienced vaginal childbirth[1], and 11%-20% of women undergo surgery for POP or urinary incontinence by age 80 years[2-4]. As the overall population ages, the prevalence of POP has also been increasing[5,6]. POP frequently occurs in middle-aged and older women and considerably impacts their quality of life (QOL). The treatment of POP aims to eliminate serious symptoms, such as lower urinary tract symptoms, sexual dysfunction, and the feeling of organ prolapse, and improve QOL by correcting organ position. Pelvic floor exercises are effective for the functional recovery of pelvic floor muscles in early-stage mild POP and can prevent exacerbation of symptoms[7]. The method of fixing the uterus to the deep part of the vagina by pessary placement is a popular conservative therapy [8]. Surgery is selected for patients with complications such as vaginal ulcers due to pessary insertion and when QOL does not improve even after conservative treatment[9].

In Japan, anterior and posterior colporrhaphies have traditionally been performed as surgical procedures following total vaginal hysterectomy. However, this surgical technique has the disadvantages of a high recurrence rate (20%-30%) and lack of consideration for postoperative sexual function[2,10].

With the relatively recent introduction of mesh surgery, surgical therapy for POP has made dramatic progress. However, it is associated with problems such as postoperative infection and dyspareunia due to mesh dislodging (erosion) and hardening. In addition, the United States Food and Drug Administration had issued an alert against it[11]. Consequently, there is a strong impetus to revisit repairs that use patients' own tissues instead of mesh (referred to as native tissue repair or NTR), a conventional method. NTR techniques include vaginal stump–uterosacral ligament fixation (Shull method), which involves reconstruction of the vaginal canal axis without mesh, similar to laparoscopic sacrocolpopexy (LSC). Satisfactory outcomes have previously been reported for the laparoscopic Shull method[12]. However, effective surgical repair using the Shull method may not be possible for patients with more severe POP, *e.g.*, patients with long vaginal canals and overextended uterosacral ligaments, given that this method only fixes the vaginal stump and uterosacral ligaments. The round ligament gains some muscle fibers during prenatal development and eventually assumes an anatomically higher position than the uterosacral ligaments[13].



To solve this problem, we devised a novel laparoscopic vaginal stump-round ligament fixation (the Kakinuma method) for laparoscopic fixation of the vaginal stump to the round ligaments (histologically strong tissues that are anatomically higher than the uterosacral ligaments) for patients with moderate-to-severe POP. This paper comprised a preliminary clinical investigation of the efficacy and safety of the Kakinuma method for treating POP.

## MATERIALS AND METHODS

This study was conducted with the approval of the relevant ethical board. The subjects were 30 patients who underwent laparoscopic vaginal stump-round ligament fixation (Kakinuma method) for POP following informed consent from January 2020 to December 2021 and could be followed up for more than 12 mo after surgery. We retrospectively examined surgical outcomes for surgery duration, blood loss, intraoperative complications, and incidence of recurrence.

The Kakinuma method was performed with a pneumoperitoneum pressure of 10 mmHg using a 10-mm 0° rigid mirror in the lithotomy position with a 20° head-down tilt under general anesthesia. Using the open method, a trocar was placed using the modified diamond configuration, with a 12-mm camera port at the umbilical region and 5-mm ports at three sites in the lower abdomen. The surgical trocar was positioned 3 cm medial to the anterior superior iliac spines and their midpoints. After incising the vesicouterine pouch, the round and ovarian suspensory ligaments were cut. After identifying the uterine artery and ureter, the main uterine artery trunk was ligated. The bladder was separated from the cervix, and the bilateral cardinal ligaments and parauterine tissues were ligated and cut. The vaginal canal was released from the posterior vaginal fornix, and the uterus was transvaginally removed after incising the vaginal canal circumferentially from the vaginal lumen along the vaginal portion of the cervix. The vaginal stump was closed by continuous suture with 1-0 absorbable thread after laparoscopically ligating both stumps with 1-0 absorbable thread. Then, the vaginal stump was continuously sutured to the round ligament on both sides by 2-0 delayed absorbable thread (Figure 1), and the vaginal stump was lifted (Figure 2).

In cases where the round ligaments were overextended, we resected the redundant round ligaments so that the vaginal stump was 4–5 cm from the vaginal opening. Next, the vaginal stump was lifted by suturing it to the round ligaments. After confirming no bleeding in the abdominal cavity, an anti-adhesion agent was sprayed, and the surgery was completed.

## RESULTS

Background data for the 30 study patients are presented in Table 1. Numerical data are shown as the mean  $\pm$  standard deviation. The mean age was  $66.5 \pm 9.1$  (45–82) years, body mass index was  $24.5 \pm 3.3$  (20.9–32.8) kg/m<sup>2</sup>, gravidity was  $3.1 \pm 1.4$  (2–7), and parity was  $2.5 \pm 0.6$  (2–4) times. According to the POP quantification stage classification, there were 8 patients with stage II, 11 with stage III, and 11 with stage IV. Surgical outcomes are shown in Table 2. The mean surgery duration was  $113.4 \pm 22.6$  (88–148) min, the mean blood loss was  $26.5 \pm 39.7$  (10–150) mL, and there were no perioperative complications. The mean follow-up period was  $20.5 \pm 6.8$  (12–31) mo. No patients demonstrated recurrent POP.

## DISCUSSION

This study examined the usefulness and safety of a new repair technique using patients' own tissues (NTR) for POP, a general term for conditions such as urethrocele, cystocele, uterine prolapse, enterocele, and rectocele according to the site of prolapse. POP treatment aims to relieve symptoms by anatomically restoring the abnormal positioning of these prolapsed organs. Conservative therapies for POP include physical methods, such as pelvic floor exercises, and noninvasive repair methods using a pessary. For patients with organ prolapses of moderate or severe POP, surgery is the preferred treatment[5,6].

Patients with more severe POP tend to be older. Consequently, each patient's general medical status and social background must be considered when selecting the surgical technique. In Japan, total hysterectomy and colporrhaphy have been used as traditional surgical therapies. However, it is difficult to treat POP with only suture repair by cutting off surplus mucosa of the vaginal wall. The recurrence rate is high and does not constitute a radical treatment in many cases. In 2004, transvaginal mesh surgery that replaced pubic cervical and rectal vaginal fascia, the most important pelvic floor support, with mesh was reported[14] and became widely popular. However, since approximately 2006, complications such as mesh exposure and incision wound erosion have been reported, and the Food and Drug Administration has issued an alert against it[11].

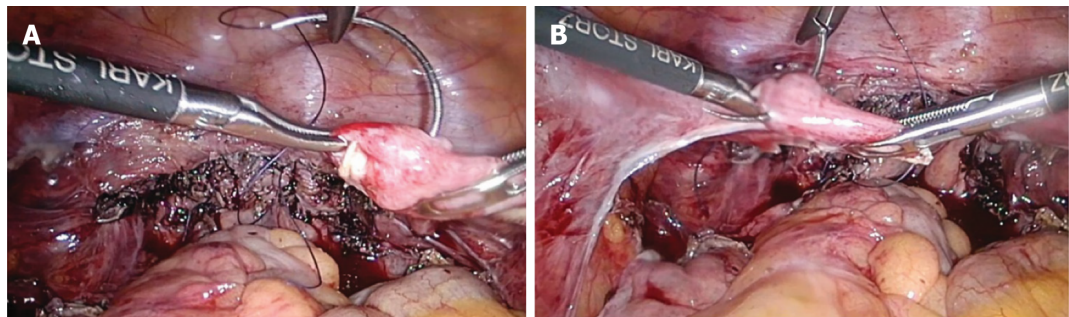
On the contrary, an abdominal technique that lifts the vaginal stump to the promontory was reported in 1957. Abdominal sacral fixation emerged with the subsequent popularization of mesh; however, the



Table 1 Patient background	
Feature	Value
Age in yr	66.5 ± 9.1
Body mass index in kg/m <sup>2</sup>	24.5 ± 3.3
Gravidity, times	3.1 ± 1.4
Parity, times	2.5 ± 0.6
POP-Q stage, <i>n</i> cases	
I	0
II	8
III	11
IV	11

POP-Q: Pelvic organ prolapse quantification.

Table 2 Surgical outcomes	
Outcome	Value
Surgical duration in min	113.4 ± 22.6
Blood loss in mL	26.5 ± 39.7
Surgical complications	None
Postoperative follow-up period in mo	20.5 ± 6.8
Recurrent cases	None

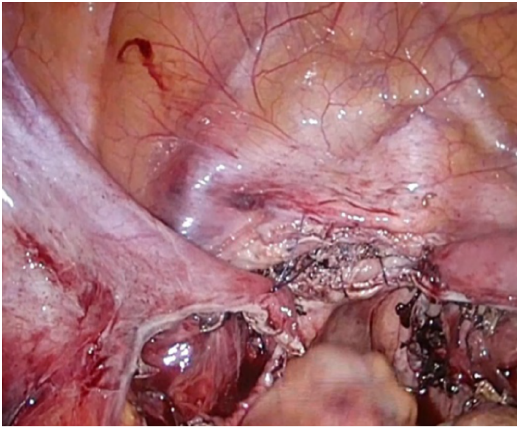


DOI: 10.12998/wjcc.v11.i15.3457 Copyright ©The Author(s) 2023.

**Figure 1** The vaginal stump was continuously sutured to the round ligament on both sides by 2-0 delayed absorbable thread. A: Right round ligament; B: Left round ligament.

highly invasive nature of the surgery and intraoperative complications, such as major bleeding from the sacrum, limited its popularity[15,16]. However, laparoscopic surgery has also been covered by national health insurance since April 2014 in Japan, with the development of laparoscopic technology. Despite its less invasive nature, LSC produces treatment effects equivalent to laparotomy[17]; consequently, the popularity of this method has continued to grow. However, this surgery still uses mesh. As described above, concerns remain about complications associated with foreign objects. In addition, this surgical technique retains the cervix following upper cervical amputation. This necessitates regular postoperative cervical cancer examinations that decrease a patient's QOL.

These considerations have led some surgeons to revisit NTR, a conventional technique that does not employ mesh[18,19]. Standard NTR is based on the vaginal technique, and vaginal stump fixation is performed after a total hysterectomy. Vaginal stump fixation can be achieved using the Shull method, which fixes it to the uterosacral ligaments. The usefulness of the Shull method has been reported in recent years[12]. This method is characterized by lifting the vaginal canal in the physiological direction; however, it involves the risk of ureter injury because of its proximity to the uterosacral ligaments.



DOI: 10.12998/wjcc.v11.i15.3457 Copyright ©The Author(s) 2023.

**Figure 2** The vaginal stump is fixed to the round ligament on both sides so that it is 4–5 cm from the vaginal opening.

Some patients with severe POP also demonstrate long vaginal canals and overextended uterosacral ligaments. Consequently, effective repair may not be possible using conventional techniques that fix only the vaginal stump and uterosacral ligaments.

To address these limitations, we developed a novel, modified form of NTR technique that anyone can perform. Herein, we describe the laparoscopic vaginal stump-round ligament fixation method (Kakinuma method) that can fix the vaginal stump to the round ligaments after a total laparoscopic hysterectomy. Anatomically, the round ligaments reside in a higher position in the body, are strong, and have no proximal important organs.

Historically, POP surgery was performed transvaginally. However, establishing an adequate visual field using this method is difficult. Laparoscopic surgery allows for sharing a clear, magnified visual field and is useful for training. Recently, total laparoscopic hysterectomy has become a basic surgical technique for obstetricians and gynecologists that does not require special surgical equipment and tools. There are no important organs around round ligaments anatomically. Therefore, the surgical technique is not particularly difficult and is minimally influenced by surgeons' skills. We observed no surgery-related complications among our patients. In addition, for patients with overextended round ligaments, sufficient vaginal stump lifting is possible by fixing the vaginal stump after partially removing the round ligaments. This positions the vaginal stump 4–5 cm from the vaginal opening.

This study recruited patients who could be followed up for more than 12 mo after surgery, and there were no reported instances of POP recurrence. However, long-term outcomes remain unclear. We are collecting additional cases over a longer follow-up period to fill this knowledge gap. Future studies should compare the Kakinuma method to other LSC methods that use mesh and evaluate recurrence-related factors. Additionally, future studies should examine outcomes such as recurrence rate, recurrence time, and POP quantification stages in recurrent cases. Countermeasures used to treat POP recurrence should also be examined.

The limited number of examined cases is a limitation of this study. Future efficacy and safety examinations of the Kakinuma method will be needed, and additional cases with longer-term follow-ups are required. We are currently working on comparing the Kakinuma method with other NTR-based repair strategies for patients with moderate-to-severe POP.

## CONCLUSION

The novel Kakinuma method safely and effectively lifts the vaginal stump to an anatomically higher position. It may be an effective surgical treatment for POP, similar to conventional NTR, and can be used successfully in patients unable to tolerate conventional NTR approaches.

## ARTICLE HIGHLIGHTS

### Research background

Laparoscopic sacrocolpopexy for pelvic organ prolapse (POP) had been gaining popularity as a new approach. However, since the United States Food and Drug Administration alert against the use of mesh, native tissue repair (NTR) using the patient's own tissue without mesh has gained attention.

## Research motivation

Vaginal stump sacral uterine ligament fixation (Shull method) is a feasible surgical procedure for NTR with good results. However, in severe POP, the length of the vaginal canal and overstretching of the sacral uterine ligament may prevent effective repair by simply fixing the vaginal stump and sacral uterine ligament.

## Research objectives

To solve this problem, an operation to fix the vaginal stump to the round ligament, which is a histologically tough tissue that is anatomically higher than the sacral uterine ligament, is performed laparoscopically; thus, inferior vaginal stump-round ligament fixation (the Kakinuma method) was devised. This study aimed to investigate the efficacy and safety of the Kakinuma method in POP.

## Research methods

From January 2020 to December 2021, 30 patients who underwent the Kakinuma method for POP were examined, and the operative time, bleeding amount, recurrence rate, *etc* were investigated.

## Research results

The average age was  $66.5 \pm 9.1$  years, the number of deliveries was  $2.5 \pm 0.6$ , body mass index was  $24.5 \pm 3.3$ , and the POP quantification stage classification was stage II in 8 cases, stage III in 11, and stage IV in 11. The average operating time was  $113.4 \pm 22.6$  min, the average blood loss was  $26.5 \pm 39.7$  mL, there were no perioperative complications, and no cases of POP recurrence were observed.

## Research conclusions

The Kakinuma method in POP could be a safe and effective treatment similar to conventional NTR.

## Research perspectives

Future studies including more patients should examine outcomes such as recurrence rate, recurrence time, and POP quantification stages in recurrent cases. We are currently comparing the Kakinuma method with other NTR-based repair strategies for patients with moderate-to-severe POP.

## FOOTNOTES

**Author contributions:** Kakinuma T contributed to methodology, software, validation, formal analysis, writing-original draft preparation, writing-review and editing, visualization, supervision, and project administration; Kakinuma T, Kakinuma K, Kaneko A, Imai K, Takeshima N, and Ohwada M collected data and performed the research; All authors contributed to investigation, resources, data curation, and read and agreed to the published version.

**Institutional review board statement:** The study was approved by the Ethics Committee of the International University of Health and Welfare Hospital, No. 21-B-463.

**Informed consent statement:** All patients provided written and oral informed consent for the procedure and study participation after a proper explanation of the risks and benefits of the surgical procedure.

**Conflict-of-interest statement:** All authors report having no relevant conflicts of interest for this article.

**Data sharing statement:** All data generated or analyzed during this study are included in this article and its supplementary material files. Further inquiries can be directed to the corresponding author at [tokakinuma@gmail.com](mailto:tokakinuma@gmail.com).

**Open-Access:** This article is an open-access article that was selected by an in-house editor and fully peer-reviewed by external reviewers. It is distributed in accordance with the Creative Commons Attribution NonCommercial (CC BY-NC 4.0) license, which permits others to distribute, remix, adapt, build upon this work non-commercially, and license their derivative works on different terms, provided the original work is properly cited and the use is non-commercial. See: <https://creativecommons.org/licenses/by-nc/4.0/>

**Country/Territory of origin:** Japan

**ORCID number:** Toshiyuki Kakinuma 0000-0001-7853-4860; Michitaka Ohwada 0000-0002-0396-6228.

**S-Editor:** Li L

**L-Editor:** Filipodia

**P-Editor:** Zhao S

## REFERENCES

- 1 Samuelsson EC, Victor FT, Tibblin G, Svärdsudd KF. Signs of genital prolapse in a Swedish population of women 20 to 59 years of age and possible related factors. *Am J Obstet Gynecol* 1999; **180**: 299-305 [PMID: 9988790 DOI: 10.1016/s0002-9378(99)70203-6]
- 2 Olsen AL, Smith VJ, Bergstrom JO, Colling JC, Clark AL. Epidemiology of surgically managed pelvic organ prolapse and urinary incontinence. *Obstet Gynecol* 1997; **89**: 501-506 [PMID: 9083302 DOI: 10.1016/S0029-7844(97)00058-6]
- 3 Fialkow MF, Newton KM, Lentz GM, Weiss NS. Lifetime risk of surgical management for pelvic organ prolapse or urinary incontinence. *Int Urogynecol J Pelvic Floor Dysfunct* 2008; **19**: 437-440 [PMID: 17896064 DOI: 10.1007/s00192-007-0459-9]
- 4 Wu JM, Matthews CA, Conover MM, Pate V, Jonsson Funk M. Lifetime risk of stress urinary incontinence or pelvic organ prolapse surgery. *Obstet Gynecol* 2014; **123**: 1201-1206 [PMID: 24807341 DOI: 10.1097/AOG.0000000000000286]
- 5 Iglesia CB, Smithling KR. Pelvic Organ Prolapse. *Am Fam Physician* 2017; **96**: 179-185 [PMID: 28762694]
- 6 Weintraub AY, Gliner H, Marcus-Braun N. Narrative review of the epidemiology, diagnosis and pathophysiology of pelvic organ prolapse. *Int Braz J Urol* 2020; **46**: 5-14 [PMID: 31851453 DOI: 10.1590/S1677-5538.IBJU.2018.0581]
- 7 Hagen S, Stark D. Conservative prevention and management of pelvic organ prolapse in women. *Cochrane Database Syst Rev* 2011; CD003882 [PMID: 22161382 DOI: 10.1002/14651858.CD003882.pub4]
- 8 de Albuquerque Coelho SC, de Castro EB, Juliato CR. Female pelvic organ prolapse using pessaries: systematic review. *Int Urogynecol J* 2016; **27**: 1797-1803 [PMID: 26992725 DOI: 10.1007/s00192-016-2991-y]
- 9 Doae M, Moradi-Lakeh M, Nourmohammadi A, Razavi-Ratki SK, Nojomi M. Management of pelvic organ prolapse and quality of life: a systematic review and meta-analysis. *Int Urogynecol J* 2014; **25**: 153-163 [PMID: 23783578 DOI: 10.1007/s00192-013-2141-8]
- 10 Auwad W, Bombieri L, Adekanmi O, Waterfield M, Freeman R. The development of pelvic organ prolapse after colposuspension: a prospective, long-term follow-up study on the prevalence and predisposing factors. *Int Urogynecol J Pelvic Floor Dysfunct* 2006; **17**: 389-394 [PMID: 16249832 DOI: 10.1007/s00192-005-0024-3]
- 11 United States Food and Drug Administration. FDA takes action to protect women's health, orders manufacturers of surgical mesh intended for transvaginal repair of pelvic organ prolapse to stop selling all devices. Apr 16, 2019. [cited 28 Dec 2022]. Available from: <https://www.fda.gov/news-events/press-announcements/fda-takes-action-protect-womens-health-orders-manufacturers-surgical-mesh-intended-transvaginal>
- 12 Shull BL, Bachofen C, Coates KW, Kuehl TJ. A transvaginal approach to repair of apical and other associated sites of pelvic organ prolapse with uterosacral ligaments. *Am J Obstet Gynecol* 2000; **183**: 1365-73; discussion 1373 [PMID: 11120498 DOI: 10.1067/mob.2000.110910]
- 13 Bellier A, Cavalié G, Marnas G, Chaffanjon P. The round ligament of the uterus: Questioning its distal insertion. *Morphologie* 2018; **102**: 55-60 [PMID: 29731327 DOI: 10.1016/j.morpho.2018.04.001]
- 14 Debodinance P, Berrocal J, Clavé H, Cosson M, Garbin O, Jacquetin B, Rosenthal C, Salet-Lizée D, Villet R. [Changing attitudes on the surgical treatment of urogenital prolapse: birth of the tension-free vaginal mesh]. *J Gynecol Obstet Biol Reprod (Paris)* 2004; **33**: 577-588 [PMID: 15550876 DOI: 10.1016/s0368-2315(04)96598-2]
- 15 Gadonneix P, Ercoli A, Scambia G, Villet R. The use of laparoscopic sacrocolpopexy in the management of pelvic organ prolapse. *Curr Opin Obstet Gynecol* 2005; **17**: 376-380 [PMID: 15976543 DOI: 10.1097/01.gco.0000175355.48802.7b]
- 16 Coolen AWM, van Oudheusden AMJ, Mol BWJ, van Eijndhoven HWF, Roovers JWR, Bongers MY. Laparoscopic sacrocolpopexy compared with open abdominal sacrocolpopexy for vault prolapse repair: a randomised controlled trial. *Int Urogynecol J* 2017; **28**: 1469-1479 [PMID: 28417153 DOI: 10.1007/s00192-017-3296-5]
- 17 Freeman RM, Pantazis K, Thomson A, Frappell J, Bombieri L, Moran P, Slack M, Scott P, Waterfield M. A randomised controlled trial of abdominal vs laparoscopic sacrocolpopexy for the treatment of post-hysterectomy vaginal vault prolapse: LAS study. *Int Urogynecol J* 2013; **24**: 377-384 [PMID: 22864764 DOI: 10.1007/s00192-012-1885-x]
- 18 Sassani JC, Artsen AM, Moalli PA, Bradley MS. Temporal Trends of Urogynecologic Mesh Reports to the U.S. Food and Drug Administration. *Obstet Gynecol* 2020; **135**: 1084-1090 [PMID: 32282600 DOI: 10.1097/AOG.0000000000003805]
- 19 Braga A, Serati M, Salvatore S, Torella M, Pasqualetti R, Papadia A, Caccia G. Update in native tissue vaginal vault prolapse repair. *Int Urogynecol J* 2020; **31**: 2003-2010 [PMID: 32556408 DOI: 10.1007/s00192-020-04368-4]



Published by **Baishideng Publishing Group Inc**  
7041 Koll Center Parkway, Suite 160, Pleasanton, CA 94566, USA

**Telephone:** +1-925-3991568

**E-mail:** [bpgoffice@wjgnet.com](mailto:bpgoffice@wjgnet.com)

**Help Desk:** <https://www.f6publishing.com/helpdesk>

<https://www.wjgnet.com>

