

World Journal of *Clinical Cases*

World J Clin Cases 2023 June 6; 11(16): 3664-3931



Contents

Thrice Monthly Volume 11 Number 16 June 6, 2023

REVIEW

- 3664 Kikuchi-Fujimoto disease: A comprehensive review
Mahajan VK, Sharma V, Sharma N, Rani R
- 3680 Current diagnostic tools and treatment modalities for rectal prolapse
Oruc M, Erol T

MINIREVIEWS

- 3694 Application of laparoscopic surgery in gallbladder carcinoma
Wu X, Li BL, Zheng CJ
- 3706 Current research of idiopathic normal pressure hydrocephalus: Pathogenesis, diagnosis and treatment
Ishida T, Murayama T, Kobayashi S
- 3714 *Helicobacter pylori* plays a key role in gastric adenocarcinoma induced by spasmolytic polypeptide-expressing metaplasia
Li ML, Hong XX, Zhang WJ, Liang YZ, Cai TT, Xu YF, Pan HF, Kang JY, Guo SJ, Li HW
- 3725 Review of deep learning and artificial intelligence models in fetal brain magnetic resonance imaging
Vahedifard F, Adepoju JO, Supanich M, Ai HA, Liu X, Kocak M, Marathu KK, Byrd SE
- 3736 Diabetes more than retinopathy, it's effect on the anterior segment of eye
Morya AK, Ramesh PV, Kaur K, Gurnani B, Heda A, Bhatia K, Sinha A

ORIGINAL ARTICLE

Retrospective Cohort Study

- 3750 Long term outcomes of Cohen's cross trigonal reimplantation for primary vesicoureteral reflux in poorly functioning kidney
Ansari MS, Banthia R, Jain S, Kaushik VN, Danish N, Yadav P

Retrospective Study

- 3756 Dexmedetomidine-induced anesthesia in elderly patients undergoing hip replacement surgery
Li JQ, Yuan H, Wang XQ, Yang M

Observational Study

- 3765 Hypoperfusion context as a predictor of 28-d all-cause mortality in septic shock patients: A comparative observational study
Kataria S, Singh O, Juneja D, Goel A, Bhide M, Yadav D

- 3780** Psychological review of hemodialysis patients and kidney transplant recipients during the COVID-19 pandemic

Gundogmus AG, Oguz EG, Guler-Cimen S, Kocyigit Y, Dogan AE, Ayli MD

- 3791** Incidence and peri-operative risk factors for development of acute kidney injury in patients after cardiac surgery: A prospective observational study

Dimopoulos S, Zagkotsis G, Kinti C, Rouvali N, Georgopoulou M, Mavraki M, Tasouli A, Lyberopoulou E, Roussakis A, Vasileiadis I, Nanas S, Karabinis A

Randomized Controlled Trial

- 3802** Coaxial radiography guided puncture technique for percutaneous transforaminal endoscopic lumbar discectomy: A randomized control trial

Chen LP, Wen BS, Xu H, Lu Z, Yan LJ, Deng H, Fu HB, Yuan HJ, Hu PP

CASE REPORT

- 3813** Blood typing and transfusion therapy in a patient with A2 subtype acute myeloid leukemia M2: A case report

Kuang XC, Zhang SH, Cen YJ, Zhang JB, Liu YS

- 3822** Valve repair after infective endocarditis secondary to perforation caused by *Streptococcus gordonii*: A case report

Qu YF, Yang J, Wang JY, Wei B, Ye XH, Li YX, Han SL

- 3830** *Prevotella oris*-caused meningitis and spinal canal infection: A case report

Zhang WW, Ai C, Mao CT, Liu DK, Guo Y

- 3837** Severe liver trauma with complex portal and common bile duct avulsion: A case report and review of the literature

Mitricof B, Kraft A, Anton F, Barcu A, Barzan D, Haiducu C, Brasoveanu V, Popescu I, Moldovan CA, Botea F

- 3847** TACC diagnosed by transoesophageal endoscopic ultrasonography: A case report

Pu XX, Xu QW, Liu BY

- 3852** Ruptured teratoma mimicking a pelvic inflammatory disease and ovarian malignancy: A case report

Lai PH, Ding DC

- 3858** Purpura annularis telangiectodes of Majocchi: A case report

Pu YJ, Jiang HJ, Zhang L

- 3864** Giant cyst in heterotopic pregnancy: A case report

Kong YY, Chanda K, Ying XY

- 3870** High doses of dextromethorphan induced shock and convulsions in a 19-year-old female: A case report

Shimozawa S, Usuda D, Sasaki T, Tsuge S, Sakurai R, Kawai K, Matsubara S, Tanaka R, Suzuki M, Hotchi Y, Tokunaga S, Osugi I, Katou R, Ito S, Asako S, Mishima K, Kondo A, Mizuno K, Takami H, Komatsu T, Oba J, Nomura T, Sugita M

- 3877** Postpartum ovarian vein thrombosis after cesarean section and vaginal delivery: Two case reports

Zhu HD, Shen W, Wu HL, Sang X, Chen Y, Geng LS, Zhou T

- 3885** Traumatic pancreatic ductal injury treated by endoscopic stenting in a 9-year-old boy: A case report
Kwon HJ, Jung MK, Park J
- 3891** Novel mutation c.2090_2091del in neurodevelopmental-craniofacial syndrome with variable renal and cardiac abnormalities in an 18.5-mo-old boy: A case report
Li Y, Zhou Z, Xu Y, Wang ZR
- 3899** Reading impairment after neonatal hypoglycemia with parieto-temporo-occipital injury without cortical blindness: A case report
Kurahashi N, Ogaya S, Maki Y, Nonobe N, Kumai S, Hosokawa Y, Ogawa C, Yamada K, Maruyama K, Miura K, Nakamura M
- 3907** Unusual clinical presentation of oral pyogenic granuloma with severe alveolar bone loss: A case report and review of literature
Lomeli Martínez SM, Bocanegra Morando D, Mercado González AE, Gómez Sandoval JR
- 3915** Intraoperative photodynamic therapy for tracheal mass in non-small cell lung cancer: A case report
Jung HS, Kim HJ, Kim KW
- 3921** Coexistence of urinary tuberculosis and urothelial carcinoma: A case report
Tsai YC, Li CC, Chen BT, Wang CY

LETTER TO THE EDITOR

- 3929** Symmetric DWI hyperintensities in CMT1X patients after SARS-CoV-2 vaccination should not be classified as stroke-like lesions
Finsterer J

ABOUT COVER

Editorial Board Member of *World Journal of Clinical Cases*, Ashraf F Hefny, MD, MSc, Associate Professor, Surgeon, Department of Surgery, College of Medicine and Health Sciences, UAE University, Al Ain 00000, United Arab Emirates. ahefny@uaeu.ac.ae

AIMS AND SCOPE

The primary aim of *World Journal of Clinical Cases* (WJCC, *World J Clin Cases*) is to provide scholars and readers from various fields of clinical medicine with a platform to publish high-quality clinical research articles and communicate their research findings online.

WJCC mainly publishes articles reporting research results and findings obtained in the field of clinical medicine and covering a wide range of topics, including case control studies, retrospective cohort studies, retrospective studies, clinical trials studies, observational studies, prospective studies, randomized controlled trials, randomized clinical trials, systematic reviews, meta-analysis, and case reports.

INDEXING/ABSTRACTING

The WJCC is now abstracted and indexed in Science Citation Index Expanded (SCIE, also known as SciSearch®), Journal Citation Reports/Science Edition, Current Contents®/Clinical Medicine, PubMed, PubMed Central, Scopus, Reference Citation Analysis, China National Knowledge Infrastructure, China Science and Technology Journal Database, and Superstar Journals Database. The 2022 Edition of Journal Citation Reports® cites the 2021 impact factor (IF) for WJCC as 1.534; IF without journal self cites: 1.491; 5-year IF: 1.599; Journal Citation Indicator: 0.28; Ranking: 135 among 172 journals in medicine, general and internal; and Quartile category: Q4. The WJCC's CiteScore for 2021 is 1.2 and Scopus CiteScore rank 2021: General Medicine is 443/826.

RESPONSIBLE EDITORS FOR THIS ISSUE

Production Editor: Si Zhao; Production Department Director: Xu Guo; Editorial Office Director: Jin-Lei Wang.

NAME OF JOURNAL

World Journal of Clinical Cases

ISSN

ISSN 2307-8960 (online)

LAUNCH DATE

April 16, 2013

FREQUENCY

Thrice Monthly

EDITORS-IN-CHIEF

Bao-Gan Peng, Jerzy Tadeusz Chudek, George Kontogeorgos, Maurizio Serati, Ja Hyeon Ku

EDITORIAL BOARD MEMBERS

<https://www.wjgnet.com/2307-8960/editorialboard.htm>

PUBLICATION DATE

June 6, 2023

COPYRIGHT

© 2023 Baishideng Publishing Group Inc

INSTRUCTIONS TO AUTHORS

<https://www.wjgnet.com/bpg/gerinfo/204>

GUIDELINES FOR ETHICS DOCUMENTS

<https://www.wjgnet.com/bpg/GerInfo/287>

GUIDELINES FOR NON-NATIVE SPEAKERS OF ENGLISH

<https://www.wjgnet.com/bpg/gerinfo/240>

PUBLICATION ETHICS

<https://www.wjgnet.com/bpg/GerInfo/288>

PUBLICATION MISCONDUCT

<https://www.wjgnet.com/bpg/gerinfo/208>

ARTICLE PROCESSING CHARGE

<https://www.wjgnet.com/bpg/gerinfo/242>

STEPS FOR SUBMITTING MANUSCRIPTS

<https://www.wjgnet.com/bpg/GerInfo/239>

ONLINE SUBMISSION

<https://www.f6publishing.com>



Current research of idiopathic normal pressure hydrocephalus: Pathogenesis, diagnosis and treatment

Tetsuro Ishida, Tomonori Murayama, Seiju Kobayashi

Specialty type: Neurosciences

Provenance and peer review:

Invited article; Externally peer reviewed.

Peer-review model: Single blind

Peer-review report's scientific quality classification

Grade A (Excellent): 0

Grade B (Very good): 0

Grade C (Good): C

Grade D (Fair): D

Grade E (Poor): 0

P-Reviewer: Gokce E, Turkey;
Wijaya JH, Indonesia

Received: December 27, 2022

Peer-review started: December 27, 2022

First decision: January 20, 2023

Revised: February 18, 2023

Accepted: May 4, 2023

Article in press: May 4, 2023

Published online: June 6, 2023



Tetsuro Ishida, Department of Psychiatry, Japan Health Care College, Sapporo 062-0053, Hokkaido, Japan

Tomonori Murayama, Department of Psychiatry, Asahikawa Keisenkai Hospital, Asahikawa 078-8208, Hokkaido, Japan

Seiju Kobayashi, Department of Psychiatry, Shinyukai Nakae Hospital, Sapporo 001-0022, Hokkaido, Japan

Corresponding author: Tetsuro Ishida, MD, Chief Doctor, Department of Psychiatry, Japan Health Care College, Higashi 3-11-1-55 Toyohira-ku Tsukisamu, Sapporo 062-0053, Hokkaido, Japan. teturoisida@yahoo.co.jp

Abstract

Idiopathic normal pressure hydrocephalus (iNPH) is caused by impaired cerebrospinal fluid absorption in the elderly; it is a surgically treatable form of dementia. Gait disturbance, dementia, and urinary incontinence are the triad of signs for iNPH. In addition to these clinical findings, imaging studies show characteristic ventricular enlargement. High Evans Index and 'disproportionately enlarged subarachnoid hydrocephalus' are other well-known imaging findings of iNPH. If the tap test shows improved symptoms, shunt surgery is performed. The disease was first described by Hakim and Adams in 1965, followed by the publication of the first, second, and third editions of the guidelines in 2004, 2012, and 2020, respectively. Recent studies signal the glymphatic system and classical cerebrospinal fluid (CSF) absorption from the dural lymphatics as aetiological mechanisms of CSF retention. Research is also underway on imaging test and biomarker developments for more precise diagnosis, shunting technique options with fewer sequelae and complications, and the influence of genetics. Particularly, the newly introduced 'suspected iNPH' in the third edition of the guidelines may be useful for earlier diagnosis. However, less well-studied areas remain, such as pharmacotherapy in non-operative indications and neurological findings other than the triadic signs. This review briefly presents previous research on these and future issues.

Key Words: Review; Idiopathic normal pressure hydrocephalus; Treatable dementia; Shunt surgery; Drug therapy

©The Author(s) 2023. Published by Baishideng Publishing Group Inc. All rights reserved.

Core Tip: Idiopathic normal pressure hydrocephalus (iNPH) presents with gait disturbance, dementia, and urinary incontinence. Improvement in these symptoms by tap testing, and imaging studies showing characteristic ventricular enlargement, are important for the diagnosis. iNPH is a dementia that is treatable by shunt surgery. This review describes recent pathophysiology, diagnosis, and treatment in iNPH.

Citation: Ishida T, Murayama T, Kobayashi S. Current research of idiopathic normal pressure hydrocephalus: Pathogenesis, diagnosis and treatment. *World J Clin Cases* 2023; 11(16): 3706-3713

URL: <https://www.wjgnet.com/2307-8960/full/v11/i16/3706.htm>

DOI: <https://dx.doi.org/10.12998/wjcc.v11.i16.3706>

INTRODUCTION

The initial documentation of idiopathic normal pressure hydrocephalus (iNPH) was made by Hakim and Adams[1] in 1965. In 2004, the first global guidelines for iNPH were published[2]. The guidelines placed the tap test at the centre of the diagnostic algorithm. A second edition of the guidelines was published in 2008[3]. These guidelines emphasised the importance of clinical features such as gait disturbance, urinary incontinence, and cognitive impairment, as well as 'disproportionately enlarged subarachnoid hydrocephalus' (DESH).

PATHOPHYSIOLOGY

Classically, the third circulation theory (bulk flow theory) has been considered the established theory for classical cerebrospinal fluid (CSF) production and absorption. In this theory, CSF is produced from blood in the choroid plexus within the ventricles, and the CSF has a steady flow. CSF flows from the uppermost lateral ventricles and drains through the foramen of Monroe, the third ventricle, the middle cerebral aqueduct, and the fourth ventricle, into the subarachnoid space. In the subarachnoid space, CSF further flows from the posterior cranial fossa through the basilar, sylvian, and cerebral hemispheric fissures to the higher arcuate region in the vicinity of the superior sagittal arteriovenous system. However, more recently, involvement of the glymphatic system and a mechanism of CSF absorption from the dural lymphatics has been considered more appropriate[4,5]. According to these theories, CSF is produced from the interstitial fluid produced by brain cells *via* the glymphatic system. Some CSF drains into the ventricles and has a steady flow, as in the classical theory. However, the majority of CSF is absorbed from the intradural lymphatics by anomalous flow. Future research is needed on the relationship between these new theories and clinical ventricular enlargement mechanisms.

GENETICS

Future research is needed to identify the relationship between these new theories and clinical ventricular enlargement mechanisms. iNPH has been classified as secondary hydrocephalus, with it being secondary to subarachnoid haemorrhage and other conditions, and the actual cause of iNPH may be unknown. Although there have been reports of sibling cases, there are no reports of familial or hereditary hydrocephalus. However, familial normal pressure hydrocephalus (fNPH) has recently been reported, with affected families being reported from Japan in 2011[6], Canada in 2012[7], and Greece in 2014[8]. There is also a family history of shunting in 5% of patients with iNPH in Finland[9]. Thus, fNPH may exist in clinically important numbers. In addition, the gene encoding the protein 'Scm-like with four MBT domains protein1 (SFMBT1)' has been reported as a risk gene for iNPH, and the cilia- and flagella-associated protein 43 (CFAP43) as a causative gene for fNPH in the field of genetic medicine[10,11]. SFMBT1 localises to cells constituting the subarachnoid space, cerebral arteries, veins, and ventricular walls. CFAP43 affects proteins related to villus structure and function. Therefore, research on fNPH may also help in understanding the pathogenesis of iNPH and developing treatment.

KEY POINTS OF THE THIRD EDITION OF THE GUIDELINES

Traditionally, the diagnosis of iNPH was classified into three levels: possible, probable, and definite. However, "suspected iNPH" was added in the third edition of the guidelines. Suspected iNPH is defined by two conditions: (1) An age of 60 years or older; and (2) enlarged ventricles (Evans Index >

0.3) on head imaging. Clinical symptoms such as dementia, gait disturbance, and dysuria are not required. This classification is expected to lead to earlier diagnosis of iNPH and earlier treatment[12]. In the study of asymptomatic iNPH, there is also the concept of asymptomatic ventriculomegaly with features of iNPH on MRI (AVIM)[13]. AVIM characterizes the supplementary observation of constriction in the subarachnoid space and cortical sulci at the peak convexity of the cerebrum, which is added to the classification of suspected iNPH. AVIM may also represent a preclinical stage of iNPH.

IMAGING

In the diagnosis of iNPH, head imaging findings are as important as abnormal neurological findings such as dementia, gait disturbance, and dysuria. It is important to recognize that solely relying on imaging results should not exclude iNPH. Techniques such as diffusion tensor imaging (DTI) and single photon emission computed tomography should also be considered, and fluorodeoxyglucose positron emission tomography imaging are also useful in the diagnosis of iNPH. However, they are omitted from this discussion owing to word count limitations.

Differentiating iNPH from Alzheimer's disease

In the diagnostic process, it's essential to distinguish between Alzheimer's dementia and iNPH, though this can be difficult in real-world situations. Interestingly, iNPH is viewed as a distinct disease in Europe and Japan, while in the United States, it's classified as an Alzheimer's disease subtype[14].

zEI and ventricle ratio 200

In cases of iNPH, the Evans Index typically exceeds 0.3 (Figure 1A). Frequently, the subarachnoid space expands within the sylvian fissure and in a downward direction, accompanied by narrowing in the elevated curvature area[15-18]. DESH is also an important imaging finding, as discussed in 'Changes in iNPH guidelines' (Figure 1B). DESH and cerebral atrophy due to Alzheimer's disease can be differentiated with high sensitivity and specificity[16-18]. DESH can be assessed visually, but previous studies have examined atrophic changes in more detail using voxel-based morphometry[18]. In addition to DESH, other evaluation criteria of interest include the Z-Evans Index (zEI) and brain/ventricle ratio (BVR) (Figure 1C). The (classic) Evans Index is a useful indicator of lateral ventricular enlargement in the horizontal section direction. However, in practice, iNPH patients often have lateral ventricles that show high-convexity tightness visible in the z-axis rather than in the horizontal section. The zEI is defined as the maximum z-axis length of the cranium from the maximum z-axis length of the frontal horn. This index is useful for detecting ventricular enlargement in the z-axis direction rather than in the horizontal sectional direction[19]. Yamada suggested that zEI may be associated with tap-test positivity. BVR is defined as the width of the anterior horn of the lateral ventricle/intracranial width immediately above the lateral ventricle[20]. A BVR < 1.0 in coronal sections on anterior commissure points, or a BVR < 1.5 in coronal sections on posterior commissure points, is considered an indicator of DESH findings [20].

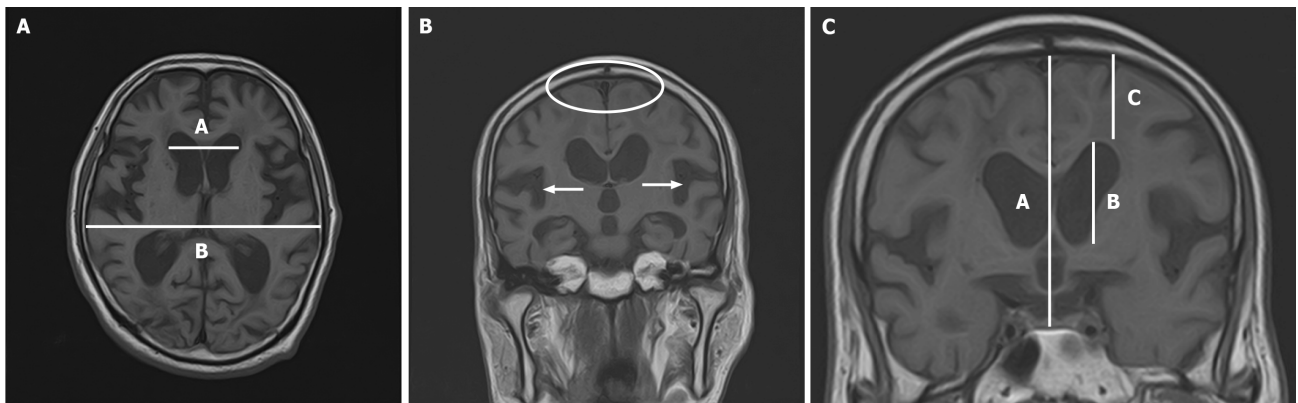
Rad scale

The radiological scale (Rad scale) has a total score of 12 points and is used to assess iNPH over the following seven items: (1) Widening of the ventricular/intracranial cavity width ratio (Evans Index > 3.0); (2) widening of the sylvian fissure; (3) narrowing of the high circumflex and median subarachnoid space; (4) steepening of the cerebral corpuscle angle; (5) focal widening of the cerebral sulci (a pooling phenomenon of cerebrospinal fluid); (6) widening of the lateral subventricular angle; and (7) periventricular hyperintensity[21]. The Rad scale correlates with the severity of iNPH[22]. The Rad scale is also useful for distinguishing subjects with iNPH from healthy elderly people, and for the differential diagnosis between iNPH and cerebrovascular dementia, progressive supranuclear palsy, and multiple system atrophy[23].

BIOMARKERS

Proteins and neuropeptides in cerebrospinal fluid have been studied as biomarkers for iNPH. Previous studies reported comparisons of total tau, phosphorylated tau, and amyloid- β 42 between iNPH and Alzheimer's disease[24-31]. In addition, leucine-rich α 2-glycoprotein (LRG), protein tyrosine phosphatase receptor type Q (PTPRQ), and neurofilament light chain (NfL) are biomarkers that have recently received attention[32-34]. These are useful markers not only for diagnosis, but also for predicting the effect of shunting. In iNPH, total tau and phosphorylated tau are generally lower than in Alzheimer's disease, with higher levels predicting a poor response to shunting.

Amyloid- β 42 is also lower in patients with iNPH than in healthy subjects, and low levels are an indicator of a poor response to shunting procedures. NfL-PTPRQ-LRG is higher in patients with iNPH



DOI: 10.12998/wjcc.v11.i16.3706 Copyright ©The Author(s) 2023.

Figure 1 head magnetic resonance imagines. A: Axial head magnetic resonance imaging of idiopathic normal pressure hydrocephalus. Evans Index (EI) = maximum width of the frontal horns of the lateral ventricles/maximal internal diameter of the skull at the same level (A/B). EI > 0.3 is a significant finding suggestive of idiopathic normal pressure hydrocephalus; B: Coronal head magnetic resonance imaging of idiopathic normal pressure hydrocephalus. This image shows narrowing of the fornix region (white oval) and widening of the bilateral sylvian fissures (white arrows); C: Coronal magnetic resonance imaging at the anterior commissure perpendicular to the line connecting the anterior and posterior commissures. Z-Evans Index (zEI) = width of the frontal horn of the lateral ventricle/median intracranial diameter (B/A). Brain/ventricle ratio (BVR) = intracranial width immediately above the lateral ventricles/anterior horn width of the lateral ventricles (C/B). Scores of zEI > 0.42 and BVR < 1.0 are significant findings suggestive of idiopathic normal pressure hydrocephalus.

than in healthy subjects. High NfL-LRG values are indicative of poor effectiveness of shunting procedures, but the relevance of high PTPRQ is unknown. Future work in this area is likely to focus on whether these biomarkers can be combined to make them more sensitive for diagnosis and prediction of treatment response.

TREATMENTS

Shunting

Shunting procedures for iNPH include ventriculo-peritoneal (VP), lumbo-peritoneal (LP), and ventriculo-atrial (VA) shunts. Of these, VP and LP shunts are the most common, while VA shunts are less common[35]. There is no significant difference in efficacy and complications between LP and VP shunts, and the technique considered most appropriate for each case is selected[36]. LP shunts do not puncture the brain and are considered safe in elderly patients, but are not suitable for patients with scoliosis, peritonitis, severe constipation, or obesity[37].

VP shunts are often chosen when LP shunts cannot be performed for the above reasons. Although VA shunts are used in fewer cases than LP and VP shunts, as described above, it is reported that adverse events and dysfunctions are less common than with VP shunts[38,39]. Endoscopic transtentorial ventriculostomy (ETV), which differs from the above shunting techniques, should also be described. ETV is a procedure to create a short-circuit pathway to avoid an obstruction in the ventricle. Traditionally, ETV has had narrower indications than shunting. However, recent studies have shown that ETV may improve not only CSF outflow, but also the compliance of the periventricular wall parenchyma[40-42]. Thus, iNPH surgeries continue to be investigated according to their theoretical bases and actual results to determine the best method. Although the safety of the above-mentioned shunt surgeries has improved over the years, adverse events are still common. A previous study showed that re-operations due to problems such as infection are more frequently associated with adverse events than first-time shunting procedures[43].

The two main types of shunt valves currently in use are pressure-fixed and pressure-variable valves. Pressure-fixed valves have a simpler mechanism and are cheaper. However, variable-pressure valves allow pressure to be set non-invasively from outside the body after shunt placement. The 2020 Cochrane Systematic Review did not show any superiority or inferiority between these two shunt valves[44]. However, the Japanese Guidelines for Idiopathic Normal Pressure Hydrocephalus, 3rd edition, recommend the use of variable valves for safety reasons[45]. In addition, antimicrobial-impregnated catheters have recently been used in many cases to prevent shunt infection. Previous studies have shown that antimicrobial-impregnated catheters significantly reduce shunt reconstruction associated with infection[46]. Therefore, the use of antimicrobial-impregnated catheters may be beneficial in shunt surgery in infection-prone children and immunocompromised patients.

Pharmacotherapy

As mentioned in the surgery section, surgical intervention carries risks and potential complications. In

cases where a tap test doesn't demonstrate a significant enhancement in cognitive abilities, surgery is not required. If surgery is not performed, the treatment of patients with iNPH is limited to symptomatic treatment. This section describes symptomatic pharmacotherapy.

First, there are anti-dementia drugs. These anti-dementia drugs inhibit the progression of cognitive decline but do not improve cognitive function. Four anti-dementia drugs are used in Japan: donepezil, galantamine, rivastigmine, and memantine. All of these are indicated for Alzheimer's disease, while only donepezil is also indicated for dementia with Lewy bodies. Clinically, these anti-dementia drugs are often prescribed for patients with other types of dementia, including iNPH. However, there is no clear evidence on their efficacy. Therefore, below we introduce the previous case reports. Moriuchi *et al* [47] reported that donepezil was effective in four patients with iNPH with residual cognitive decline after shunting surgery. Takaya[48] reported a case report in which memantine was effective for psychiatric symptoms of iNPH. Basic experiments also suggest that memantine may reduce hydrocephalus-induced neurodegenerative disorders[49]. Goreisan is a herbal medicine that regulates water metabolism and has been reported to be effective in normal pressure hydrocephalus[50]. Nonetheless, there is a lack of established guidelines or extensive research to endorse the application of Goreisan in treating iNPH. Furthermore, low-dose acetazolamide, also a diuretic, was reported to restore periventricular leukomalacia in a small case series of patients with iNPH[51].

EPILEPSY

Lately, attention has been drawn to patients experiencing late-onset epilepsy, who frequently appear in outpatient dementia clinics[52]. Past research indicates that while uncommon, postoperative complications of iNPH can involve seizures, with a mere 0.16% incidence rate in cases[53]. Two case reports have been published on nonsurgical iNPH presenting with seizures. In the first case, hyponatraemia associated with the administration of laxatives following lower gastrointestinal endoscopy triggered an epileptic seizure[54]. In the other case, a change in diagnosis and treatment from donepezil treatment for Alzheimer's disease to levetiracetam treatment for symptomatic epileptic seizures associated with iNPH resulted in improved cognitive function[55].

CONCLUSION

Promptness and individualisation are needed in the treatment of iNPH. In particular, the fact that suspected iNPH is defined solely by age and imaging findings leads to a more rapid diagnosis. Other novel indicators such as z-EL, BVR, and Rad scale have increased the sensitivity and specificity of the diagnosis. In terms of individualisation, research on biomarkers in spinal fluid has also developed. This has enabled the effect of shunting to be predicted preoperatively. In addition, further research is needed on drug therapy in cases where surgery is not expected to improve symptoms. The development of biomarkers for less invasive samples such as urine and blood is also expected in the future.

FOOTNOTES

Author contributions: Ishida T was responsible for the conception and design of the study and writing of the manuscript; Murayama T and Kobayashi S assisted in the critical review and editing of the manuscript; All authors gave their approval for the final version to be submitted.

Conflict-of-interest statement: All the authors declare that they have no conflict of interest.

Open-Access: This article is an open-access article that was selected by an in-house editor and fully peer-reviewed by external reviewers. It is distributed in accordance with the Creative Commons Attribution NonCommercial (CC BY-NC 4.0) license, which permits others to distribute, remix, adapt, build upon this work non-commercially, and license their derivative works on different terms, provided the original work is properly cited and the use is non-commercial. See: <https://creativecommons.org/licenses/by-nc/4.0/>

Country/Territory of origin: Japan

ORCID number: Tetsuro Ishida 0000-0002-8513-2373; Tomonori Murayama 0000-0003-2371-8421; Seiju Kobayashi 0000-0002-1557-1426.

S-Editor: Liu JH

L-Editor: A

P-Editor: Liu JH

REFERENCES

- 1 **Hakim S**, Adams RD. The special clinical problem of symptomatic hydrocephalus with normal cerebrospinal fluid pressure. Observations on cerebrospinal fluid hydrodynamics. *J Neurol Sci* 1965; **2**: 307-327 [PMID: [5889177](#) DOI: [10.1016/0022-510x\(65\)90016-x](#)]
- 2 **Ishikawa M**; Guideline Committee for Idiopathic Normal Pressure Hydrocephalus, Japanese Society of Normal Pressure Hydrocephalus. Clinical guidelines for idiopathic normal pressure hydrocephalus. *Neurol Med Chir (Tokyo)* 2004; **44**: 222-223 [PMID: [15185767](#) DOI: [10.2176/nmc.44.222](#)]
- 3 **Mori E**, Ishikawa M, Kato T, Kazui H, Miyake H, Miyajima M, Nakajima M, Hashimoto M, Kuriyama N, Tokuda T, Ishii K, Kaijima M, Hirata Y, Saito M, Arai H; Japanese Society of Normal Pressure Hydrocephalus. Guidelines for management of idiopathic normal pressure hydrocephalus: second edition. *Neurol Med Chir (Tokyo)* 2012; **52**: 775-809 [PMID: [23183074](#) DOI: [10.2176/nmc.52.775](#)]
- 4 **Iliff JJ**, Wang M, Liao Y, Plogg BA, Peng W, Gundersen GA, Benveniste H, Vates GE, Deane R, Goldman SA, Nagelhus EA, Nedergaard M. A paravascular pathway facilitates CSF flow through the brain parenchyma and the clearance of interstitial solutes, including amyloid β . *Sci Transl Med* 2012; **4**: 147ra111 [PMID: [22896675](#) DOI: [10.1126/scitranslmed.3003748](#)]
- 5 **Louveau A**, Smirnov I, Keyes TJ, Eccles JD, Rouhani SJ, Peske JD, Derecki NC, Castle D, Mandell JW, Lee KS, Harris TH, Kipnis J. Structural and functional features of central nervous system lymphatic vessels. *Nature* 2015; **523**: 337-341 [PMID: [26030524](#) DOI: [10.1038/nature14432](#)]
- 6 **Takahashi Y**, Kawanami T, Nagasawa H, Iseki C, Hanyu H, Kato T. Familial normal pressure hydrocephalus (NPH) with an autosomal-dominant inheritance: a novel subgroup of NPH. *J Neurol Sci* 2011; **308**: 149-151 [PMID: [21704338](#) DOI: [10.1016/j.jns.2011.06.018](#)]
- 7 **McGirr A**, Cusimano MD. Familial aggregation of idiopathic normal pressure hydrocephalus: novel familial case and a family study of the NPH triad in an iNPH patient cohort. *J Neurol Sci* 2012; **321**: 82-88 [PMID: [22921954](#) DOI: [10.1016/j.jns.2012.07.062](#)]
- 8 **Liouta E**, Liakos F, Koutsarnakis C, Katsaros V, Stranjalis G. Novel case of familial normal pressure hydrocephalus. *Psychiatry Clin Neurosci* 2014; **68**: 583-584 [PMID: [24612122](#) DOI: [10.1111/pcn.12176](#)]
- 9 **Huovinen J**, Kastinen S, Komulainen S, Oinas M, Avellan C, Frantzen J, Rinne J, Ronkainen A, Kauppinen M, Lönnrot K, Perola M, Pyykkö OT, Koivisto AM, Remes AM, Soininen H, Hiltunen M, Helisalmi S, Kurki M, Jääskeläinen JE, Leinonen V. Familial idiopathic normal pressure hydrocephalus. *J Neurol Sci* 2016; **368**: 11-18 [PMID: [27538594](#) DOI: [10.1016/j.jns.2016.06.052](#)]
- 10 **Sato H**, Takahashi Y, Kimihira L, Iseki C, Kato H, Suzuki Y, Igari R, Sato H, Koyama S, Arawaka S, Kawanami T, Miyajima M, Samejima N, Sato S, Kameda M, Yamada S, Kita D, Kaijima M, Date I, Sonoda Y, Kayama T, Kuwana N, Arai H, Kato T. A Segmental Copy Number Loss of the SFMBT1 Gene Is a Genetic Risk for Shunt-Responsive, Idiopathic Normal Pressure Hydrocephalus (iNPH): A Case-Control Study. *PLoS One* 2016; **11**: e0166615 [PMID: [27861535](#) DOI: [10.1371/journal.pone.0166615](#)]
- 11 **Morimoto Y**, Yoshida S, Kinoshita A, Satoh C, Mishima H, Yamaguchi N, Matsuda K, Sakaguchi M, Tanaka T, Komohara Y, Imamura A, Ozawa H, Nakashima M, Kurotaki N, Kishino T, Yoshiura KI, Ono S. Nonsense mutation in CFAP43 causes normal-pressure hydrocephalus with ciliary abnormalities. *Neurology* 2019; **92**: e2364-e2374 [PMID: [31004071](#) DOI: [10.1212/WNL.0000000000007505](#)]
- 12 **Yamada S**, Kimura T, Jingami N, Atsuchi M, Hirai O, Tokuda T, Miyajima M, Kazui H, Mori E, Ishikawa M; SINPHONI-2 Investigators. Disability risk or unimproved symptoms following shunt surgery in patients with idiopathic normal-pressure hydrocephalus: post hoc analysis of SINPHONI-2. *J Neurosurg* 2017; **126**: 2002-2009 [PMID: [27419822](#) DOI: [10.3171/2016.5.JNS16377](#)]
- 13 **Iseki C**, Kawanami T, Nagasawa H, Wada M, Koyama S, Kikuchi K, Arawaka S, Kurita K, Daimon M, Mori E, Kato T. Asymptomatic ventriculomegaly with features of idiopathic normal pressure hydrocephalus on MRI (AVIM) in the elderly: a prospective study in a Japanese population. *J Neurol Sci* 2009; **277**: 54-57 [PMID: [18990411](#) DOI: [10.1016/j.jns.2008.10.004](#)]
- 14 **Tan C**, Wang X, Wang Y, Wang C, Tang Z, Zhang Z, Liu J, Xiao G. The Pathogenesis Based on the Glymphatic System, Diagnosis, and Treatment of Idiopathic Normal Pressure Hydrocephalus. *Clin Interv Aging* 2021; **16**: 139-153 [PMID: [33488070](#) DOI: [10.2147/CIA.S290709](#)]
- 15 **Sasaki M**, Honda S, Yuasa T, Iwamura A, Shibata E, Ohba H. Narrow CSF space at high convexity and high midline areas in idiopathic normal pressure hydrocephalus detected by axial and coronal MRI. *Neuroradiology* 2008; **50**: 117-122 [PMID: [17992524](#) DOI: [10.1007/s00234-007-0318-x](#)]
- 16 **Takagi K**, Watahiki R, Machida T, Onouchi K, Kato K, Oshima M. Reliability and Interobserver Variability of Evans' Index and Disproportionately Enlarged Subarachnoid Space Hydrocephalus as Diagnostic Criteria for Idiopathic Normal Pressure Hydrocephalus. *Asian J Neurosurg* 2020; **15**: 107-112 [PMID: [32181182](#) DOI: [10.4103/ajns.AJNS_354_19](#)]
- 17 **Kitagaki H**, Mori E, Ishii K, Yamaji S, Hirono N, Imamura T. CSF spaces in idiopathic normal pressure hydrocephalus: morphology and volumetry. *AJNR Am J Neuroradiol* 1998; **19**: 1277-1284 [PMID: [9726467](#)]
- 18 **Ishii K**, Kawaguchi T, Shimada K, Ohkawa S, Miyamoto N, Kanda T, Uemura T, Yoshikawa T, Mori E. Voxel-based analysis of gray matter and CSF space in idiopathic normal pressure hydrocephalus. *Dement Geriatr Cogn Disord* 2008; **25**: 329-335 [PMID: [18319598](#) DOI: [10.1159/000119521](#)]
- 19 **Yamada S**, Ishikawa M, Yamamoto K. Optimal Diagnostic Indices for Idiopathic Normal Pressure Hydrocephalus Based on the 3D Quantitative Volumetric Analysis for the Cerebral Ventricle and Subarachnoid Space. *AJNR Am J Neuroradiol* 2015; **36**: 2262-2269 [PMID: [26359148](#) DOI: [10.3174/ajnr.A4440](#)]
- 20 **Yamada S**, Ishikawa M, Yamamoto K. Fluid Distribution Pattern in Adult-Onset Congenital, Idiopathic, and Secondary Normal-Pressure Hydrocephalus: Implications for Clinical Care. *Front Neurol* 2017; **8**: 583 [PMID: [29163345](#) DOI: [10.3389/fneur.2017.00583](#)]
- 21 **Kockum K**, Lilja-Lund O, Larsson EM, Rosell M, Söderström L, Virhammar J, Laurell K. The idiopathic normal-pressure

- hydrocephalus Radscale: a radiological scale for structured evaluation. *Eur J Neurol* 2018; **25**: 569-576 [PMID: [29281156](#) DOI: [10.1111/ene.13555](#)]
- 22 **Kockum K**, Virhammar J, Riklund K, Söderström L, Larsson EM, Laurell K. Diagnostic accuracy of the iNPH Radscale in idiopathic normal pressure hydrocephalus. *PLoS One* 2020; **15**: e0232275 [PMID: [32330190](#) DOI: [10.1371/journal.pone.0232275](#)]
- 23 **Fällmar D**, Andersson O, Kilander L, Löwenmark M, Nyholm D, Virhammar J. Imaging features associated with idiopathic normal pressure hydrocephalus have high specificity even when comparing with vascular dementia and atypical parkinsonism. *Fluids Barriers CNS* 2021; **18**: 35 [PMID: [34325703](#) DOI: [10.1186/s12987-021-00270-3](#)]
- 24 **Miyajima M**, Nakajima M, Ogino I, Miyata H, Motoi Y, Arai H. Soluble amyloid precursor protein α in the cerebrospinal fluid as a diagnostic and prognostic biomarker for idiopathic normal pressure hydrocephalus. *Eur J Neurol* 2013; **20**: 236-242 [PMID: [22672777](#) DOI: [10.1111/j.1468-1331.2012.03781.x](#)]
- 25 **Moriya M**, Miyajima M, Nakajima M, Ogino I, Arai H. Impact of cerebrospinal fluid shunting for idiopathic normal pressure hydrocephalus on the amyloid cascade. *PLoS One* 2015; **10**: e0119973 [PMID: [25821958](#) DOI: [10.1371/journal.pone.0119973](#)]
- 26 **Nakajima M**, Miyajima M, Ogino I, Akiba C, Sugano H, Hara T, Fusegi K, Karagiozov K, Arai H. Cerebrospinal fluid biomarkers for prognosis of long-term cognitive treatment outcomes in patients with idiopathic normal pressure hydrocephalus. *J Neurol Sci* 2015; **357**: 88-95 [PMID: [26169158](#) DOI: [10.1016/j.jns.2015.07.001](#)]
- 27 **Akiba C**, Nakajima M, Miyajima M, Ogino I, Motoi Y, Kawamura K, Adachi S, Kondo A, Sugano H, Tokuda T, Irie K, Arai H. Change of Amyloid- β 1-42 Toxic Conformer Ratio After Cerebrospinal Fluid Diversion Predicts Long-Term Cognitive Outcome in Patients with Idiopathic Normal Pressure Hydrocephalus. *J Alzheimers Dis* 2018; **63**: 989-1002 [PMID: [29710721](#) DOI: [10.3233/JAD-180059](#)]
- 28 **Jeppsson A**, Zetterberg H, Blennow K, Wikkelsø C. Idiopathic normal-pressure hydrocephalus: pathophysiology and diagnosis by CSF biomarkers. *Neurology* 2013; **80**: 1385-1392 [PMID: [23486875](#) DOI: [10.1212/WNL.0b013e31828c2fda](#)]
- 29 **Jeppsson A**, Wikkelsø C, Blennow K, Zetterberg H, Constantinescu R, Remes AM, Herukka SK, Rauramaa T, Nagga K, Leinonen V, Tullberg M. CSF biomarkers distinguish idiopathic normal pressure hydrocephalus from its mimics. *J Neurol Neurosurg Psychiatry* 2019; **90**: 1117-1123 [PMID: [31167811](#) DOI: [10.1136/jnnp-2019-320826](#)]
- 30 **Kawamura K**, Miyajima M, Nakajima M, Kanai M, Motoi Y, Nojiri S, Akiba C, Ogino I, Xu H, Kamohara C, Yamada S, Karagiozov K, Ikeuchi T, Kondo A, Arai H. Cerebrospinal Fluid Amyloid- β Oligomer Levels in Patients with Idiopathic Normal Pressure Hydrocephalus. *J Alzheimers Dis* 2021; **83**: 179-190 [PMID: [34275898](#) DOI: [10.3233/JAD-210226](#)]
- 31 **Kokkinou M**, Beishon LC, Smailagic N, Noel-Storr AH, Hyde C, Ukoumunne O, Worrall RE, Hayen A, Desai M, Ashok AH, Paul EJ, Georgopoulou A, Casoli T, Quinn TJ, Ritchie CW. Plasma and cerebrospinal fluid ABeta42 for the differential diagnosis of Alzheimer's disease dementia in participants diagnosed with any dementia subtype in a specialist care setting. *Cochrane Database Syst Rev* 2021; **2**: CD010945 [PMID: [33566374](#) DOI: [10.1002/14651858.CD010945.pub2](#)]
- 32 **Johnson ECB**, Dammer EB, Duong DM, Ping L, Zhou M, Yin L, Higginbotham LA, Guajardo A, White B, Troncoso JC, Thambisetty M, Montine TJ, Lee EB, Trojanowski JQ, Beach TG, Reiman EM, Haroutunian V, Wang M, Schadt E, Zhang B, Dickson DW, Ertekin-Taner N, Golde TE, Petyuk VA, De Jager PL, Bennett DA, Wingo TS, Rangaraju S, Hajjar I, Shulman JM, Lah JJ, Levey AI, Seyfried NT. Large-scale proteomic analysis of Alzheimer's disease brain and cerebrospinal fluid reveals early changes in energy metabolism associated with microglia and astrocyte activation. *Nat Med* 2020; **26**: 769-780 [PMID: [32284590](#) DOI: [10.1038/s41591-020-0815-6](#)]
- 33 **Pfanner T**, Henri-Bhargava A, Borchert S. Cerebrospinal Fluid Biomarkers as Predictors of Shunt Response in Idiopathic Normal Pressure Hydrocephalus: A Systematic Review. *Can J Neurol Sci* 2018; **45**: 3-10 [PMID: [29125088](#) DOI: [10.1017/cjn.2017.251](#)]
- 34 **Agren-Wilsson A**, Lekman A, Sjöberg W, Rosengren L, Blennow K, Bergenheim AT, Malm J. CSF biomarkers in the evaluation of idiopathic normal pressure hydrocephalus. *Acta Neurol Scand* 2007; **116**: 333-339 [PMID: [17922727](#) DOI: [10.1111/j.1600-0404.2007.00890.x](#)]
- 35 **Kuriyama N**, Miyajima M, Nakajima M, Kurosawa M, Fukushima W, Watanabe Y, Ozaki E, Hirota Y, Tamakoshi A, Mori E, Kato T, Tokuda T, Urae A, Arai H. Nationwide hospital-based survey of idiopathic normal pressure hydrocephalus in Japan: Epidemiological and clinical characteristics. *Brain Behav* 2017; **7**: e00635 [PMID: [28293475](#) DOI: [10.1002/brb3.635](#)]
- 36 **Kazui H**, Miyajima M, Mori E, Ishikawa M; SINPHONI-2 Investigators. Lumboperitoneal shunt surgery for idiopathic normal pressure hydrocephalus (SINPHONI-2): an open-label randomised trial. *Lancet Neurol* 2015; **14**: 585-594 [PMID: [25934242](#) DOI: [10.1016/S1474-4422\(15\)00046-0](#)]
- 37 **Miyajima M**, Kazui H, Mori E, Ishikawa M; , on behalf of the SINPHONI-2 Investigators. One-year outcome in patients with idiopathic normal-pressure hydrocephalus: comparison of lumboperitoneal shunt to ventriculoperitoneal shunt. *J Neurosurg* 2016; **125**: 1483-1492 [PMID: [26871203](#) DOI: [10.3171/2015.10.JNS151894](#)]
- 38 **Hung AL**, Vivas-Buitrago T, Adam A, Lu J, Robison J, Elder BD, Goodwin CR, Jusué-Torres I, Rigamonti D. Ventriculoatrial versus ventriculoperitoneal shunt complications in idiopathic normal pressure hydrocephalus. *Clin Neurol Neurosurg* 2017; **157**: 1-6 [PMID: [28347957](#) DOI: [10.1016/j.clineuro.2017.03.014](#)]
- 39 **McGovern RA**, Kelly KM, Chan AK, Morrissey NJ, McKhann GM 2nd. Should ventriculoatrial shunting be the procedure of choice for normal-pressure hydrocephalus? *J Neurosurg* 2014; **120**: 1458-1464 [PMID: [24605842](#) DOI: [10.3171/2014.1.JNS131808](#)]
- 40 **Greitz D**. Paradigm shift in hydrocephalus research in legacy of Dandy's pioneering work: rationale for third ventriculostomy in communicating hydrocephalus. *Childs Nerv Syst* 2007; **23**: 487-489 [PMID: [17370078](#) DOI: [10.1007/s00381-007-0303-z](#)]
- 41 **Tomycz LD**, Hale AT, George TM. Emerging Insights and New Perspectives on the Nature of Hydrocephalus. *Pediatr Neurol* 2017; **52**: 361-368 [PMID: [29131121](#) DOI: [10.1159/000484173](#)]
- 42 **Cinalli G**, Maixner WJ, Sainte-Rose C. Pediatric hydrocephalus. 2nd ed. Cham: Springer, 2019: 784-785

- 43 **Patwardhan RV**, Nanda A. Implanted ventricular shunts in the United States: the billion-dollar-a-year cost of hydrocephalus treatment. *Neurosurgery* 2005; **56**: 139-44; discussion 144 [PMID: [15617596](#) DOI: [10.1227/01.neu.0000146206.40375.41](#)]
- 44 **Garegnani L**, Franco JV, Ciapponi A, Garrote V, Vietto V, Portillo Medina SA. Ventriculo-peritoneal shunting devices for hydrocephalus. *Cochrane Database Syst Rev* 2020; **6**: CD012726 [PMID: [32542676](#) DOI: [10.1002/14651858.CD012726.pub2](#)]
- 45 **Nakajima M**, Yamada S, Miyajima M, Ishii K, Kuriyama N, Kazui H, Kanemoto H, Suehiro T, Yoshiyama K, Kameda M, Kajimoto Y, Mase M, Murai H, Kita D, Kimura T, Samejima N, Tokuda T, Kaijima M, Akiba C, Kawamura K, Atsuchi M, Hirata Y, Matsumae M, Sasaki M, Yamashita F, Aoki S, Irie R, Miyake H, Kato T, Mori E, Ishikawa M, Date I, Arai H; research committee of idiopathic normal pressure hydrocephalus. Guidelines for Management of Idiopathic Normal Pressure Hydrocephalus (Third Edition): Endorsed by the Japanese Society of Normal Pressure Hydrocephalus. *Neurol Med Chir (Tokyo)* 2021; **61**: 63-97 [PMID: [33455998](#) DOI: [10.2176/nmc.st.2020-0292](#)]
- 46 **Mallucci CL**, Jenkinson MD, Conroy EJ, Hartley JC, Brown M, Dalton J, Kearns T, Moitt T, Griffiths MJ, Culeddu G, Solomon T, Hughes D, Gamble C; BASICS Study collaborators. Antibiotic or silver versus standard ventriculoperitoneal shunts (BASICS): a multicentre, single-blinded, randomised trial and economic evaluation. *Lancet* 2019; **394**: 1530-1539 [PMID: [31522843](#) DOI: [10.1016/S0140-6736\(19\)31603-4](#)]
- 47 **Moriuchi S**, Makoto D, Takeshi S, Shogo F, Takanori F, Yasushi H, Takao S. Lumbar-peritoneal shunt followed by donepezil administration for residual cognitive impairment in idiopathic normal pressure hydrocephalus: a case report. *J Neurol Neurophysiol* 2015; **6**: 2 [DOI: [10.4172/2155-9562.1000274](#)]
- 48 **Takaya M**. Memantine treatment for neuropsychiatric symptoms in a patient with probable idiopathic normal pressure hydrocephalus: a case report. *J Med Case Rep* 2013; **7**: 94 [PMID: [23561702](#) DOI: [10.1186/1752-1947-7-94](#)]
- 49 **Köktürk S**, Ceylan S, Etus V, Yasa N. Morinda citrifolia L. (noni) and memantine attenuate periventricular tissue injury of the fourth ventricle in hydrocephalic rabbits. *Neural Regen Res* 2013; **8**: 773-782 [PMID: [25206724](#) DOI: [10.3969/j.issn.1673-5374.2013.09.001](#)]
- 50 **Tanaka T**, Momozaki N, Liu X. Case report: a study of seven cases of chronic subdural haematoma in patients with normal pressure hydrocephalus shunt implantation treated with goreisan (in Japanese). *Science of Kampo Medicine* 2014; **38**: 131-134
- 51 **Alperin N**, Oliu CJ, Bagci AM, Lee SH, Kovanlikaya I, Adams D, Katzen H, Ivkovic M, Heier L, Relkin N. Low-dose acetazolamide reverses periventricular white matter hyperintensities in iNPH. *Neurology* 2014; **82**: 1347-1351 [PMID: [24634454](#) DOI: [10.1212/WNL.0000000000000313](#)]
- 52 **Kawamura M**. Epilepsy and dementia (in Japanese). *Naika* 2017; **120**: 253-256 [DOI: [10.15106/J00974.2017338862](#)]
- 53 **Giordan E**, Palandri G, Lanzino G, Murad MH, Elder BD. Outcomes and complications of different surgical treatments for idiopathic normal pressure hydrocephalus: a systematic review and meta-analysis. *J Neurosurg* 2018; 1-13 [PMID: [30497150](#) DOI: [10.3171/2018.5.JNS1875](#)]
- 54 **Eleftheriou A**, Amezcua S, Nilsson M. Idiopathic normal pressure hydrocephalus presenting with epileptic seizure as a cardinal symptom: a case presentation. *Interdiscip Neurosurg* 2020; **19**: 100618 [DOI: [10.1016/j.inat.2019.100618](#)]
- 55 **Ishida T**, Murayama T, Kobayashi S. A case report of nonsurgical idiopathic normal pressure hydrocephalus differentiated from Alzheimer's dementia: levetiracetam was effective in symptomatic epilepsy. *PCN Rep* 2022; **1**: 43-48 [DOI: [10.1002/pcn5.43](#)]



Published by **Baishideng Publishing Group Inc**
7041 Koll Center Parkway, Suite 160, Pleasanton, CA 94566, USA

Telephone: +1-925-3991568

E-mail: bpgoffice@wjgnet.com

Help Desk: <https://www.f6publishing.com/helpdesk>

<https://www.wjgnet.com>

