

World Journal of *Clinical Cases*

World J Clin Cases 2023 June 6; 11(16): 3664-3931



Contents

Thrice Monthly Volume 11 Number 16 June 6, 2023

REVIEW

- 3664 Kikuchi-Fujimoto disease: A comprehensive review
Mahajan VK, Sharma V, Sharma N, Rani R
- 3680 Current diagnostic tools and treatment modalities for rectal prolapse
Oruc M, Erol T

MINIREVIEWS

- 3694 Application of laparoscopic surgery in gallbladder carcinoma
Wu X, Li BL, Zheng CJ
- 3706 Current research of idiopathic normal pressure hydrocephalus: Pathogenesis, diagnosis and treatment
Ishida T, Murayama T, Kobayashi S
- 3714 *Helicobacter pylori* plays a key role in gastric adenocarcinoma induced by spasmolytic polypeptide-expressing metaplasia
Li ML, Hong XX, Zhang WJ, Liang YZ, Cai TT, Xu YF, Pan HF, Kang JY, Guo SJ, Li HW
- 3725 Review of deep learning and artificial intelligence models in fetal brain magnetic resonance imaging
Vahedifard F, Adepoju JO, Supanich M, Ai HA, Liu X, Kocak M, Marathu KK, Byrd SE
- 3736 Diabetes more than retinopathy, it's effect on the anterior segment of eye
Morya AK, Ramesh PV, Kaur K, Gurnani B, Heda A, Bhatia K, Sinha A

ORIGINAL ARTICLE

Retrospective Cohort Study

- 3750 Long term outcomes of Cohen's cross trigonal reimplantation for primary vesicoureteral reflux in poorly functioning kidney
Ansari MS, Banthia R, Jain S, Kaushik VN, Danish N, Yadav P

Retrospective Study

- 3756 Dexmedetomidine-induced anesthesia in elderly patients undergoing hip replacement surgery
Li JQ, Yuan H, Wang XQ, Yang M

Observational Study

- 3765 Hypoperfusion context as a predictor of 28-d all-cause mortality in septic shock patients: A comparative observational study
Kataria S, Singh O, Juneja D, Goel A, Bhide M, Yadav D

- 3780** Psychological review of hemodialysis patients and kidney transplant recipients during the COVID-19 pandemic

Gundogmus AG, Oguz EG, Guler-Cimen S, Kocyigit Y, Dogan AE, Ayli MD

- 3791** Incidence and peri-operative risk factors for development of acute kidney injury in patients after cardiac surgery: A prospective observational study

Dimopoulos S, Zagkotsis G, Kinti C, Rouvali N, Georgopoulou M, Mavraki M, Tasouli A, Lyberopoulou E, Roussakis A, Vasileiadis I, Nanas S, Karabinis A

Randomized Controlled Trial

- 3802** Coaxial radiography guided puncture technique for percutaneous transforaminal endoscopic lumbar discectomy: A randomized control trial

Chen LP, Wen BS, Xu H, Lu Z, Yan LJ, Deng H, Fu HB, Yuan HJ, Hu PP

CASE REPORT

- 3813** Blood typing and transfusion therapy in a patient with A2 subtype acute myeloid leukemia M2: A case report

Kuang XC, Zhang SH, Cen YJ, Zhang JB, Liu YS

- 3822** Valve repair after infective endocarditis secondary to perforation caused by *Streptococcus gordonii*: A case report

Qu YF, Yang J, Wang JY, Wei B, Ye XH, Li YX, Han SL

- 3830** *Prevotella oris*-caused meningitis and spinal canal infection: A case report

Zhang WW, Ai C, Mao CT, Liu DK, Guo Y

- 3837** Severe liver trauma with complex portal and common bile duct avulsion: A case report and review of the literature

Mitricof B, Kraft A, Anton F, Barcu A, Barzan D, Haiducu C, Brasoveanu V, Popescu I, Moldovan CA, Botea F

- 3847** TACC diagnosed by transoesophageal endoscopic ultrasonography: A case report

Pu XX, Xu QW, Liu BY

- 3852** Ruptured teratoma mimicking a pelvic inflammatory disease and ovarian malignancy: A case report

Lai PH, Ding DC

- 3858** Purpura annularis telangiectodes of Majocchi: A case report

Pu YJ, Jiang HJ, Zhang L

- 3864** Giant cyst in heterotopic pregnancy: A case report

Kong YY, Chanda K, Ying XY

- 3870** High doses of dextromethorphan induced shock and convulsions in a 19-year-old female: A case report

Shimozawa S, Usuda D, Sasaki T, Tsuge S, Sakurai R, Kawai K, Matsubara S, Tanaka R, Suzuki M, Hotchi Y, Tokunaga S, Osugi I, Katou R, Ito S, Asako S, Mishima K, Kondo A, Mizuno K, Takami H, Komatsu T, Oba J, Nomura T, Sugita M

- 3877** Postpartum ovarian vein thrombosis after cesarean section and vaginal delivery: Two case reports

Zhu HD, Shen W, Wu HL, Sang X, Chen Y, Geng LS, Zhou T

- 3885** Traumatic pancreatic ductal injury treated by endoscopic stenting in a 9-year-old boy: A case report
Kwon HJ, Jung MK, Park J
- 3891** Novel mutation c.2090_2091del in neurodevelopmental-craniofacial syndrome with variable renal and cardiac abnormalities in an 18.5-mo-old boy: A case report
Li Y, Zhou Z, Xu Y, Wang ZR
- 3899** Reading impairment after neonatal hypoglycemia with parieto-temporo-occipital injury without cortical blindness: A case report
Kurahashi N, Ogaya S, Maki Y, Nonobe N, Kumai S, Hosokawa Y, Ogawa C, Yamada K, Maruyama K, Miura K, Nakamura M
- 3907** Unusual clinical presentation of oral pyogenic granuloma with severe alveolar bone loss: A case report and review of literature
Lomeli Martínez SM, Bocanegra Morando D, Mercado González AE, Gómez Sandoval JR
- 3915** Intraoperative photodynamic therapy for tracheal mass in non-small cell lung cancer: A case report
Jung HS, Kim HJ, Kim KW
- 3921** Coexistence of urinary tuberculosis and urothelial carcinoma: A case report
Tsai YC, Li CC, Chen BT, Wang CY

LETTER TO THE EDITOR

- 3929** Symmetric DWI hyperintensities in CMT1X patients after SARS-CoV-2 vaccination should not be classified as stroke-like lesions
Finsterer J

ABOUT COVER

Editorial Board Member of *World Journal of Clinical Cases*, Ashraf F Hefny, MD, MSc, Associate Professor, Surgeon, Department of Surgery, College of Medicine and Health Sciences, UAE University, Al Ain 00000, United Arab Emirates. ahefny@uaeu.ac.ae

AIMS AND SCOPE

The primary aim of *World Journal of Clinical Cases* (WJCC, *World J Clin Cases*) is to provide scholars and readers from various fields of clinical medicine with a platform to publish high-quality clinical research articles and communicate their research findings online.

WJCC mainly publishes articles reporting research results and findings obtained in the field of clinical medicine and covering a wide range of topics, including case control studies, retrospective cohort studies, retrospective studies, clinical trials studies, observational studies, prospective studies, randomized controlled trials, randomized clinical trials, systematic reviews, meta-analysis, and case reports.

INDEXING/ABSTRACTING

The WJCC is now abstracted and indexed in Science Citation Index Expanded (SCIE, also known as SciSearch®), Journal Citation Reports/Science Edition, Current Contents®/Clinical Medicine, PubMed, PubMed Central, Scopus, Reference Citation Analysis, China National Knowledge Infrastructure, China Science and Technology Journal Database, and Superstar Journals Database. The 2022 Edition of Journal Citation Reports® cites the 2021 impact factor (IF) for WJCC as 1.534; IF without journal self cites: 1.491; 5-year IF: 1.599; Journal Citation Indicator: 0.28; Ranking: 135 among 172 journals in medicine, general and internal; and Quartile category: Q4. The WJCC's CiteScore for 2021 is 1.2 and Scopus CiteScore rank 2021: General Medicine is 443/826.

RESPONSIBLE EDITORS FOR THIS ISSUE

Production Editor: Si Zhao; Production Department Director: Xu Guo; Editorial Office Director: Jin-Lei Wang.

NAME OF JOURNAL

World Journal of Clinical Cases

ISSN

ISSN 2307-8960 (online)

LAUNCH DATE

April 16, 2013

FREQUENCY

Thrice Monthly

EDITORS-IN-CHIEF

Bao-Gan Peng, Jerzy Tadeusz Chudek, George Kontogeorgos, Maurizio Serati, Ja Hyeon Ku

EDITORIAL BOARD MEMBERS

<https://www.wjgnet.com/2307-8960/editorialboard.htm>

PUBLICATION DATE

June 6, 2023

COPYRIGHT

© 2023 Baishideng Publishing Group Inc

INSTRUCTIONS TO AUTHORS

<https://www.wjgnet.com/bpg/gerinfo/204>

GUIDELINES FOR ETHICS DOCUMENTS

<https://www.wjgnet.com/bpg/GerInfo/287>

GUIDELINES FOR NON-NATIVE SPEAKERS OF ENGLISH

<https://www.wjgnet.com/bpg/gerinfo/240>

PUBLICATION ETHICS

<https://www.wjgnet.com/bpg/GerInfo/288>

PUBLICATION MISCONDUCT

<https://www.wjgnet.com/bpg/gerinfo/208>

ARTICLE PROCESSING CHARGE

<https://www.wjgnet.com/bpg/gerinfo/242>

STEPS FOR SUBMITTING MANUSCRIPTS

<https://www.wjgnet.com/bpg/GerInfo/239>

ONLINE SUBMISSION

<https://www.f6publishing.com>



Postpartum ovarian vein thrombosis after cesarean section and vaginal delivery: Two case reports

Hong-Dan Zhu, Wei Shen, He-Li Wu, Xia Sang, Yun Chen, Li-Shu Geng, Tao Zhou

Specialty type: Obstetrics and gynecology

Provenance and peer review:

Unsolicited article; Externally peer reviewed.

Peer-review model: Single blind

Peer-review report's scientific quality classification

Grade A (Excellent): 0
Grade B (Very good): 0
Grade C (Good): C, C
Grade D (Fair): 0
Grade E (Poor): 0

P-Reviewer: Mohey NM, Egypt;
Shariati MBH, Iran

Received: March 10, 2023

Peer-review started: March 10, 2023

First decision: April 10, 2023

Revised: April 18, 2023

Accepted: May 6, 2023

Article in press: May 6, 2023

Published online: June 6, 2023



Hong-Dan Zhu, Wei Shen, He-Li Wu, Xia Sang, Yun Chen, Li-Shu Geng, Tao Zhou, Department of Obstetrics and Gynecology, Affiliated Xiaoshan Hospital, Hangzhou Normal University, Hangzhou 311200, Zhejiang Province, China

Corresponding author: Tao Zhou, Doctor, Occupational Physician, Department of Obstetrics and Gynecology, Affiliated Xiaoshan Hospital, Hangzhou Normal University, No. 728 Yucai North Road, Xiaoshan District, Hangzhou 311200, Zhejiang Province, China.

zhoutao1417@163.com

Abstract

BACKGROUND

Postpartum ovarian vein thrombosis (POVT) is a rare puerperal complication. It is easily missed or misdiagnosed due to its insidious onset and lack of specific clinical symptoms and signs. This paper reports two patients who developed right ovarian vein thrombosis after cesarean section and vaginal delivery, respectively.

CASE SUMMARY

Case 1 was a 32-year-old female who underwent a cesarean section in labor at 40 wk of gestation due to fetal distress. The patient was persistently febrile after the operation and escalated antibiotic treatment was ineffective. POVT was diagnosed by abdominal computed tomography (CT) and was treated by increasing the dose of low molecular weight heparin (LMWH). Case 2 was a 21-year-old female with a spontaneous vaginal delivery at 39 wk of gestation. The patient developed fever and abdominal pain 3 days after delivery. POVT was promptly identified by abdominal CT, and the condition was quickly controlled after treatment with LMWH and antibiotics.

CONCLUSION

These two cases occurred after cesarean section and vaginal delivery, respectively. The diagnosis was mainly based on imaging examination due to the unspecific clinical symptoms and signs, the CT scan provided an especially high diagnostic value. Comparing these two cases, escalating antibiotics alone did not provide significant therapeutic benefit, but the early escalation of anticoagulant dosage seemed to shorten the disease course. Therefore, early diagnosis by CT followed by aggressive anticoagulation might have a positive effect on improving the prognosis of the disease.

Key Words: Postpartum ovarian vein thrombosis; Computed tomography; Anticoagulation;

Anti-infection; Case report

©The Author(s) 2023. Published by Baishideng Publishing Group Inc. All rights reserved.

Core Tip: Postpartum ovarian vein thrombosis (POVT) is a rare puerperal complication. It is easily missed or misdiagnosed due to its insidious onset and lack of specific clinical symptoms and signs. Retrospective literature showed that anticoagulation and anti-infection agents constituted the main treatment modalities for this disease, and the definite diagnosis before treatment mainly depended on imaging diagnosis, especially computed tomography (CT) scans. This paper reports two cases in which early diagnosis and timely treatment likely led to a shorter disease course. Therefore, for patients in whom POVT is suspected, an early CT scan can assist in the early diagnosis. Of course, in view of radiation and other side effects, the clinical overuse of CT scans should still be avoided.

Citation: Zhu HD, Shen W, Wu HL, Sang X, Chen Y, Geng LS, Zhou T. Postpartum ovarian vein thrombosis after cesarean section and vaginal delivery: Two case reports. *World J Clin Cases* 2023; 11(16): 3877-3884

URL: <https://www.wjgnet.com/2307-8960/full/v11/i16/3877.htm>

DOI: <https://dx.doi.org/10.12998/wjcc.v11.i16.3877>

INTRODUCTION

Postpartum ovarian vein thrombosis (POVT) is a relatively rare puerperal complication with an incidence of 0.01%-0.18%[1-3], and is more common after cesarean delivery than vaginal delivery[4]. However, the condition is easily missed or misdiagnosed due to its unspecific clinical symptoms and signs. Delayed diagnosis and treatment may lead to serious complications such as inferior vena cava thrombosis and pulmonary embolism and even endanger maternal life. Therefore, prompt diagnosis and treatment are particularly important. This paper reports two cases of postpartum ovarian vein thrombosis and reviews the relevant literature to provide a reference for the clinical diagnosis and treatment of this condition.

CASE PRESENTATION

Chief complaints

Case 1: A 32-year-old G2P0 female who underwent a cesarean section in labor at 40 wk of gestation due to fetal distress. However, she developed persistent abdominal pain and fever after the operation.

Case 2: A 21-year-old G1P0 female with a spontaneous vaginal delivery at 39 wk of gestation. She also had symptoms such as abdominal pain and fever after delivery.

History of present illness

Case 1: The patient was hospitalized at 40 wk of gestation with possible fetal macrosomia. She had a height of 156 cm, a weight of 72 kg, and a body mass index (BMI) of 29.5 kg/m². The patient was administered 0.5% oxytocin (2.5 IU oxytocin added to 500 mL 0.9% sodium chloride injection) by intravenous drip to induce labor. On the same day, frequent late fetal heart deceleration was observed. As the uterine orifice was dilated to only 7 cm, an emergency cesarean section (C-section) of the lower uterine section was performed due to fetal distress. A male newborn with a birthweight of 4130 g and an APGAR score of 10-10/1-5 min was delivered. The operation lasted 32 min and went smoothly, with 300 mL of intraoperative bleeding.

The patient was administered cefuroxime at 1.5 g q8h after the C-section. Referring to the Queensland Clinical Guidelines for Venous thromboembolism (VTE) in pregnancy and the puerperium[5], her risk score was 3 (cesarean section in labor). The patient was administered low molecular weight heparin (LMWH) at 4100 IU qd for standard prophylaxis 12 h after C-section and was informed to mobilize early and move frequently to reduce the risk of thrombosis.

On postoperative day 1, the patient had a fever with a body temperature of 38.2°C and no abdominal pain. The white blood cell (WBC) count was $16.40 \times 10^9/L$ with a neutrophil percentage (NEUT%) of 88.7%, and the high sensitive C-reactive protein (hs-CRP) level was 67.49 mg/L. On postoperative day 2, she developed right-sided abdominal pain, and the physical examination showed tenderness on the right edge of the uterus. The body temperature was 38.3°C, and the laboratory examinations were repeated, revealing a WBC count of $16.19 \times 10^9/L$, NEUT% of 91.5%, and hs-CRP of 174.52 mg/L.

Therefore, she was diagnosed with a pelvic infection, and the antibiotic was changed to cefoperazone sulbactam at 2.0 g q8h. On postoperative day 4, the patient showed no improvement in abdominal pain, and the temperature was still 38.2°C, with a WBC count of $12.15 \times 10^9/L$, NEUT% of 83.4 %, and hs-CRP of 129.11 mg/L. However, the ultrasound of the lower abdomen and vascular ultrasound of both lower extremities showed no significant abnormalities. On postoperative day 6, the body temperature was 37.9 °C, and the right-sided abdominal pain was still present. The WBC count was $12.90 \times 10^9/L$, with a NEUT% of 82.7%, and an hs-CRP level of 199.22 mg/L. Considering that the abdominal pain and fever had not subsided and the significant increase in hs-CRP, the antibiotic regimen was switched to linezolid at 0.6 g q12h and piperacillin-tazobactam at 4.5 g q8h.

Case 2: The patient was hospitalized for labor at 39 wk of gestation. Her height was 156 cm, her weight was 65 kg, and her BMI was 26.7 kg/m². On the night of admission, a male newborn was delivered vaginally with a birth weight of 3450 g and an APGAR score of 10-10/1-5 min. The birth process went smoothly, with a total labor time of 16 h and 200 mL of hemorrhage.

Referring to the Queensland Clinical Guidelines for VTE in pregnancy and the puerperium[5], her risk score was 0. Therefore, the patient was not administered LMWH but was also informed to mobilize early and frequently move to reduce the risk of thrombosis. Two days after delivery, her body temperature was normal, and the recovery was smooth. The WBC count was $12.57 \times 10^9/L$, the NEUT% was 84.4%, and the hs-CRP level was 57.0 mg/L.

On postpartum day 3, the patient developed a fever of 38.3°C, accompanied by right-sided lower abdominal pain. The physical examination showed tenderness in the right lower abdomen. The WBC count was $12.04 \times 10^9/L$, the NEUT% was 84.5%, and the hs-CRP level was 167.91 mg/L. Her signs and symptoms were similar to those in case 1.

History of past illness

Case 1: In January 2019, the patient underwent curettage for hydatidiform mole, and the postoperative follow-up was uneventful. She had regular menstrual cycles.

Case 2: The patient had no previous medical history or any surgical interventions in the past.

Personal and family history

Case 1 and Case 2: The personal and family history was unremarkable.

Physical examination

Not applicable.

Laboratory examinations

Not applicable.

Imaging examinations

Case 1: On postoperative day 7, the body temperature was 37.8°C, and an abdominal computed tomography (CT) scan was performed, revealing a strip of high-density shadow in the meridian area of the right ovarian vein (Figure 1A and B), which was highly indicative of venous thrombosis.

Case 2: On postpartum day 3, an abdominal CT scan showed a twisted strip of shadow from the lower pole of the right kidney to the right side of the uterus, which raised suspicions of venous thrombosis. On the next day, a CT enhancement scan revealed a tortuous vascular shadow in the right adnexal area and confirmed the diagnosis of right ovarian vein thrombosis (OVT) (Figure 1C and D).

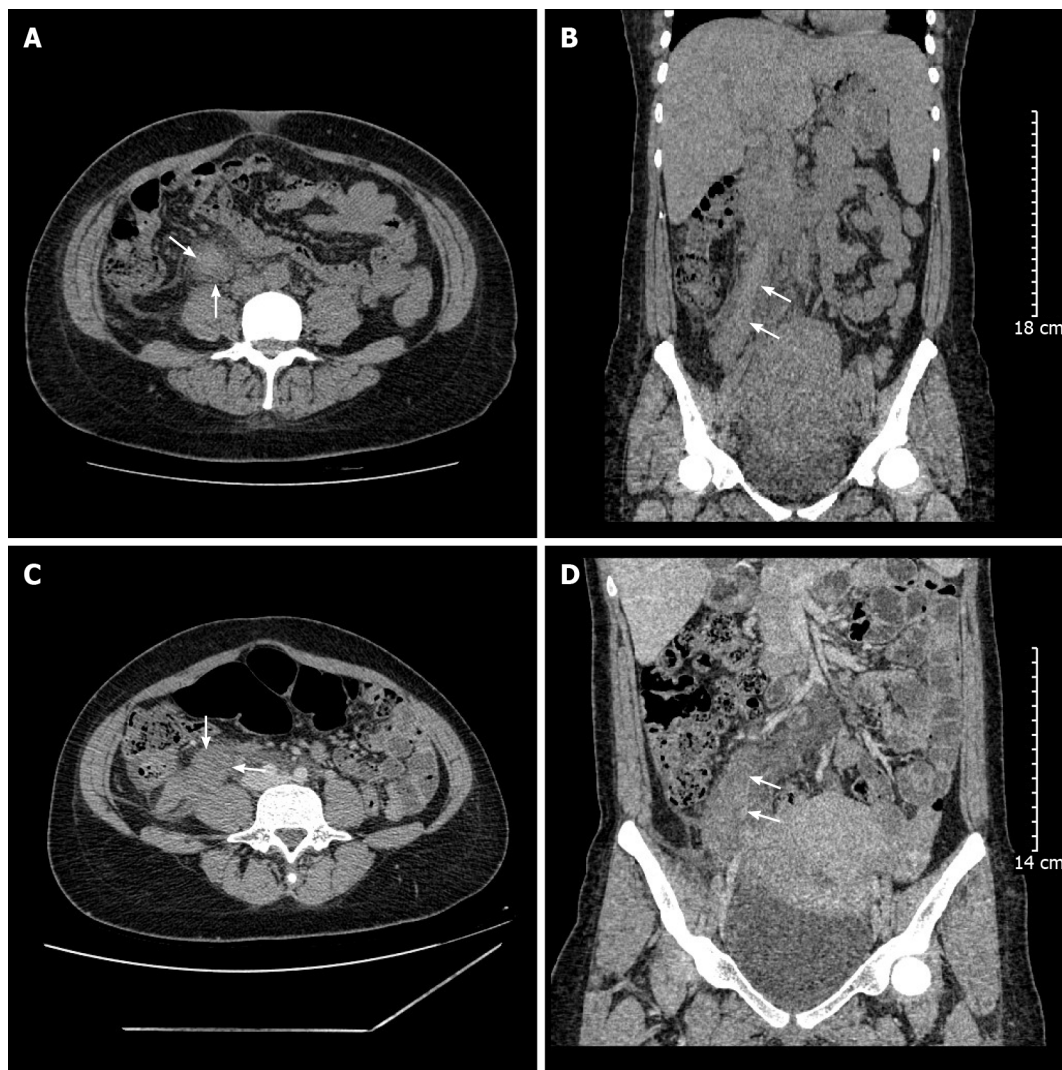
FINAL DIAGNOSIS

Based on CT scans, both patients were diagnosed with right OVT.

TREATMENT

Case 1: After POVT was diagnosed, the anticoagulation treatment was immediately changed to LMWH 4100 IU q12h. On postoperative day 9, the abdominal pain was significantly relieved, and piperacillin-tazobactam was stopped. On postoperative day 11, the body temperature returned to normal, abdominal pain had disappeared, and linezolid was stopped. On postoperative day 12, she was discharged from the hospital and treated with LMWH at 4100 IU q12h for 3 mo.

Case 2: After right OVT was diagnosed, LMWH was administered at 4100 IU q12h for anticoagulation and cefoperazone sulbactam at 2.0 g q8h for anti-infection. With the above treatment, her abdominal



DOI: 10.12998/wjcc.v11.i16.3877 Copyright ©The Author(s) 2023.

Figure 1 Computed tomography image showing right ovarian vein thrombosis in case 1 and case 2. A: Axial view (arrows); B: Coronal view (arrows); C: Axial view (arrows); D: Coronal view (arrows).

pain was gradually relieved. On postpartum day 7, the body temperature returned to normal, with minimal abdominal pain. On postpartum day 9, the antibiotics were discontinued, and the patient was discharged. LMWH at 4100 IU q12h was administered for 3 mo.

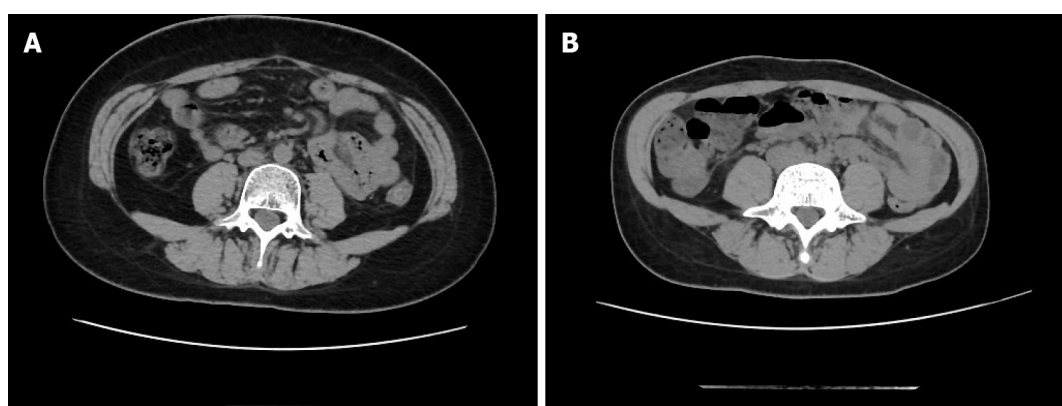
OUTCOME AND FOLLOW-UP

Case 1: The repeat CT scan 42 days after the C-section revealed that the right OVT had disappeared (Figure 2A).

Case 2: The CT scan 42 days after delivery also revealed that the right OVT had disappeared (Figure 2B).

DISCUSSION

This paper reports two patients with POVT (the timeline from diagnosis to treatment is displayed in Figure 3), one after C-section and the other after vaginal delivery. In case 1, the disease was initially misdiagnosed, which resulted in delayed treatment and slow recovery. Having learned from case 1, our team promptly diagnosed and treated case 2, leading to a quick recovery. Therefore, the literature related to this disease was reviewed and summarized.



DOI: 10.12998/wjcc.v11.i16.3877 Copyright ©The Author(s) 2023.

Figure 2 Computed tomography image. A: The image of follow up computed tomography (CT) in case 1; B: The image of follow up CT in case 2.

A higher incidence has been reported after C-section than after vaginal delivery[2,6], and the right ovarian vein is also significantly more commonly affected than the left, with 80% to 90% of cases involving the right ovarian vein[7]. This finding may be attributed to the right ovarian vein being longer than the left, and the right ovarian vein is compressed by the right rotation of the enlarged uterus in late pregnancy. The two cases reported also developed thrombosis in the right ovarian vein.

POVT has an insidious onset and atypical clinical symptoms. Its most common symptom is lower quadrant abdominal pain, usually on the side of the thrombosed vein[3,8]. Other signs include fever and palpable abdominal mass[9,10]. As the ovarian veins have a deep anatomical location, positive signs on physical examination are also difficult to detect. Hence, the disease is easily missed and misdiagnosed and can lead to serious and fatal complications such as pulmonary embolism[11,12]. According to the literature[13], the peak onset of POVT is 2 d after delivery, and about 90% of cases occurred within 10 d of delivery. In the current study, the 2 cases both developed within 3 d of delivery, which is also consistent with relevant reports. The differential diagnoses include puerperal pelvic infections, ovarian tumor torsion, acute appendicitis, pyelonephritis, and renal calculi. Furthermore, both cases presented with fever and abdominal pain as the main symptoms, with no other specific manifestations. Due to the rarity of the disease and our lack of clinical experience, case 1 was misdiagnosed as a puerperal pelvic infection. However, we learned from the experience, and case 2 was diagnosed early.

The changes observed in the laboratory examination of POVT are also not specific, mostly characterized by an increase in infectious indicators such as WBC count, NEUT%, hs-CRP, and procalcitonin, while urine culture and blood culture are usually negative[14]. These are consistent with the cases reported in this paper.

Imaging examination is of great value in the diagnosis of POVT. Ultrasound has a sensitivity of 63% and a specificity of 78%, while CT has a sensitivity of 100% and a specificity of 90%, and magnetic resonance imaging (MRI) has a sensitivity of 92% and a specificity of 100%[11]. Although ultrasound is more economical and radiation-free, its application is limited by factors such as abdominal distention, resulting in low diagnostic sensitivity and specificity. MRI is radiation-free but costs much more than CT. Although CT involves radiation, it is still used as the preferred choice in diagnosing POVT due to its high sensitivity, specificity, and lower cost compared to MRI. The cases we reported confirmed that CT has higher sensitivity than ultrasound and also has high specificity.

Currently, there are no guidelines or treatment standards for POVT, and the main treatments include anticoagulation and anti-infection agents. However, the optimal treatment remains controversial.

Khishfe *et al*[15] suggested that POVT patients with fever and elevated WBC count be treated with broad-spectrum antibiotics for 7-10 d. Bannow *et al*[11] also recommended antibiotics for POVT patients with suspected infection but did not recommend a specific duration of treatment. Both cases showed signs of infection, such as fever, elevated WBC count, and hs-CRP levels, and both were treated with antibiotics.

POVT should be considered when antibiotics alone are ineffective, and the symptoms persist or even worsen[16]. In case 1, escalating antibiotics yielded unsatisfactory results, and the condition improved significantly after switching to LMWH q12h. In case 2, broad-spectrum antibiotics were administered after prompt diagnosis, with LMWH q12h, resulting in a significantly shorter disease duration than in case 1. Therefore, our cases support the majority of literature, demonstrating that anticoagulation is necessary for POVT patients, even though there are still no guidelines recommending specific anticoagulant drugs, dosage, and course[17]. In the two cases we reported, the anticoagulant treatment with LMWH at 4100 IU q12h was effective, but case 1 also reflected that the treatment with LMWH at 4100 IU qd was not effective. The duration of anticoagulation is inconclusive, and some literature suggested a mean duration of treatment of 3 mo[3,8,11]. Other authors suggested referring to the clinical management of thromboembolism in pregnancy in the absence of clear evidence[18]. Both cases

Timeline	Case 1	Case 2
Day of delivery	<ul style="list-style-type: none"> 32-year-old G2P0; 40 weeks cesarean section in labor 4130 g male infant; APGAR10/10/10 300 mL intraoperative blood loss 	<ul style="list-style-type: none"> 21-year-old G1P0; 39 weeks vaginal delivery 3450 g male infant; APGAR10/10/10 200 ml intrapartum blood loss
Postpartum Day 1	<ul style="list-style-type: none"> body temperature 38.2 °C LMWH 4100 IU q d WBC $16.4 \times 10^9/L$, NEUT% 88.7 %, hs-CRP 67.49 mg/L 	<ul style="list-style-type: none"> body temperature 36.9 °C no LMWH WBC $12.57 \times 10^9/L$, NEUT% 84.4 %, hs-CRP 57.0 mg/L
Postpartum Day 2	<ul style="list-style-type: none"> body temperature 38.3 °C, right abdominal pain WBC $16.19 \times 10^9/L$, NEUT% 91.5 %, hs-CRP 174.52 mg/L cefoperazone sulbactam anti-inflammatory 	<ul style="list-style-type: none"> body temperature 36.8 °C
Postpartum Day 3	<ul style="list-style-type: none"> body temperature 38.0 °C 	<ul style="list-style-type: none"> body temperature 37.9 °C; lower right abdominal pain WBC $12.04 \times 10^9/L$, NEUT% 84.5 %, hs-CRP 167.91 mg/L CT scan revealed suspicious right OVT LMWH 4100 IU q 12 h cefoperazone sulbactam anti-inflammatory
Postpartum Day 4	<ul style="list-style-type: none"> body temperature 38.2 °C WBC $12.15 \times 10^9/L$, NEUT% 83.4 %, hs-CRP 129.11 mg/L 	<ul style="list-style-type: none"> body temperature 38.0 °C right OVT confirmed by CT enhancement scan
Postpartum Day 6	<ul style="list-style-type: none"> body temperature 37.9 °C WBC $12.9 \times 10^9/L$, NEUT% 82.7 %, hs-CRP 199.29 mg/L linezolid + piperacillin tazobactam instead 	<ul style="list-style-type: none"> body temperature 38.0 °C
Postpartum Day 7	<ul style="list-style-type: none"> body temperature 37.8 °C CT scan indicated right OVT LMWH 4100 IU q 12 h 	<ul style="list-style-type: none"> body temperature 37.3 °C abdominal pain disappeared
Postpartum Day 9	<ul style="list-style-type: none"> body temperature 38.0 °C abdominal pain was relieved significantly stopped piperacillin tazobactam 	<ul style="list-style-type: none"> body temperature 37.0 °C stopped cefoperazone sulbactam discharge; LMWH 4100 IU q 12 h
Postpartum Day 11	<ul style="list-style-type: none"> body temperature 37.3 °C abdominal pain disappeared stopped linezolid 	<ul style="list-style-type: none"> non
Postpartum Day 12	<ul style="list-style-type: none"> body temperature 37.1 °C discharge; LMWH 4100 IU q 12 h 	<ul style="list-style-type: none"> non
Postpartum Day 42	<ul style="list-style-type: none"> out-patient follow-up: OVT disappeared 	<ul style="list-style-type: none"> out-patient follow-up: OVT disappeared

DOI: 10.12998/wjcc.v11.i16.3877 Copyright ©The Author(s) 2023.

Figure 3 Time of events and findings. LMWH: Low molecular weight heparin; WBC: White blood cell; NEUT%: Neutrophil percentage; hs-CRP: High sensitive C-reactive protein; CT: Computed tomography; OVT: Ovarian vein thrombosis.

reported in this study were anticoagulated for 3 mo, and the CT scan on postpartum day 42 revealed that the thrombus had disappeared.

CONCLUSION

In conclusion, POVT is a rare and insidious postpartum disease with non-specific symptoms and signs. However, early and definitive diagnosis and treatment are particularly important to shorten the course of the disease and reduce the occurrence of potentially serious complications, such as pulmonary embolism. POVT should be considered in postpartum women with unexplained fever and abdominal pain, especially when antibiotics alone are not effective. CT scan has a high diagnostic value and allows the early diagnosis of suspected POVT patients. Early aggressive anticoagulation and anti-infection agents should have a definite effect. However, in view of radiation and other side effects, the clinical overuse of CT scans should still be avoided.

ACKNOWLEDGEMENTS

We would like to thank these two patients for allowing us to share their cases and using their picture and we are also grateful to all of our team members who were involved in the management of the cases.

FOOTNOTES

Author contributions: Zhu HD and Shen W collected data and drafted the manuscript. Wu HL and Sang X analyzed and interpreted the data; Geng LS and Chen Y contributed to the design of the study and the revision of the manuscript; Zhou T reviewed and approved the final manuscript; All authors have read and approved the final manuscript.

Informed consent statement: Informed written consent was obtained from the patient for publication of this report and any accompanying images.

Conflict-of-interest statement: All the authors declare that they have no conflict of interest to disclose.

CARE Checklist (2016) statement: The authors have read the CARE Checklist (2016), and the manuscript was prepared and revised according to the CARE Checklist (2016).

Open-Access: This article is an open-access article that was selected by an in-house editor and fully peer-reviewed by external reviewers. It is distributed in accordance with the Creative Commons Attribution NonCommercial (CC BY-NC 4.0) license, which permits others to distribute, remix, adapt, build upon this work non-commercially, and license their derivative works on different terms, provided the original work is properly cited and the use is non-commercial. See: <https://creativecommons.org/licenses/by-nc/4.0/>

Country/Territory of origin: China

ORCID number: Tao Zhou [0000-0003-1197-9843](#).

S-Editor: Liu JH

L-Editor: A

P-Editor: Liu JH

REFERENCES

- 1 **Brown TK**, Munsick RA. Puerperal ovarian vein thrombophlebitis: a syndrome. *Am J Obstet Gynecol* 1971; **109**: 263-273 [PMID: [5539122](#) DOI: [10.1016/0002-9378\(71\)90874-x](#)]
- 2 **Dunniho DR**, Gallaspy JW, Wise RB, Otterson WN. Postpartum ovarian vein thrombophlebitis: a review. *Obstet Gynecol Surv* 1991; **46**: 415-427 [PMID: [1876354](#) DOI: [10.1097/00006254-199107000-00002](#)]
- 3 **Rottenstreich A**, Da'as N, Kleinstern G, Spectre G, Amsalem H, Kalish Y. Pregnancy and non-pregnancy related ovarian vein thrombosis: Clinical course and outcome. *Thromb Res* 2016; **146**: 84-88 [PMID: [27614189](#) DOI: [10.1016/j.thromres.2016.09.001](#)]
- 4 **Brown CE**, Stettler RW, Twickler D, Cunningham FG. Puerperal septic pelvic thrombophlebitis: incidence and response to heparin therapy. *Am J Obstet Gynecol* 1999; **181**: 143-148 [PMID: [10411810](#) DOI: [10.1016/s0002-9378\(99\)70450-3](#)]
- 5 **Health Q**. Queensland clinical guidelines (No.MN14.9-V5-R19): venous thromboembolism (VTE) in pregnancy and the puerperium [EB/OL]. 2020 [DOI: [10.35940/ijrte.b1088.0982s1119](#)]
- 6 **Salomon O**, Dulitzky M, Apter S. New observations in postpartum ovarian vein thrombosis: experience of single center. *Blood Coagul Fibrinolysis* 2010; **21**: 16-19 [PMID: [19587586](#) DOI: [10.1097/MBC.0b013e32832f2ada](#)]
- 7 **Kodali N**, Veytsman I, Martyr S, Lu K. Diagnosis and management of ovarian vein thrombosis in a healthy individual: a case report and a literature review. *J Thromb Haemost* 2017; **15**: 242-245 [PMID: [27930855](#) DOI: [10.1111/jth.13584](#)]
- 8 **Labropoulos N**, Malgor RD, Comito M, Gasparis AP, Pappas PJ, Tassiopoulos AK. The natural history and treatment outcomes of symptomatic ovarian vein thrombosis. *J Vasc Surg Venous Lymphat Disord* 2015; **3**: 42-47 [PMID: [26993679](#) DOI: [10.1016/j.jvsv.2014.07.008](#)]
- 9 **Sinha D**, Yasmin H, Samra JS. Postpartum inferior vena cava and ovarian vein thrombosis--a case report and literature review. *J Obstet Gynaecol* 2005; **25**: 312-313 [PMID: [16147754](#) DOI: [10.1080/01443610500106835](#)]
- 10 **Akinbiyi AA**, Nguyen R, Katz M. Postpartum ovarian vein thrombosis: two cases and review of literature. *Case Rep Med* 2009; **2009**: 101367 [PMID: [19809519](#) DOI: [10.1155/2009/101367](#)]
- 11 **Bannow BTS**, Skeith L. Diagnosis and management of postpartum ovarian vein thrombosis. *Hematology Am Soc Hematol Educ Program* 2017; **2017**: 168-171 [PMID: [29222252](#) DOI: [10.1182/asheducation-2017.1.168](#)]
- 12 **Fei Z**, Peng A, Wang L, Zhang L. Pulmonary embolism caused by postpartum ovarian vein thrombophlebitis after vaginal delivery: Case report and brief review of the literature. *J Clin Ultrasound* 2020; **48**: 291-293 [PMID: [31930727](#) DOI: [10.1002/jcu.22814](#)]
- 13 **Klima DA**, Snyder TE. Postpartum ovarian vein thrombosis. *Obstet Gynecol* 2008; **111**: 431-435 [PMID: [18238984](#) DOI: [10.1097/AOG.0b013e318162f6c0](#)]

- 14 **Djakovic I**, Mustapic M, Marleku F, Grgic O, Djakovic Z, Kosec V. Ovarian vein thrombosis--a case report. *Acta Clin Belg* 2015; **70**: 445-446 [PMID: [26790557](#) DOI: [10.1080/17843286.2015.1107202](#)]
- 15 **Khishfe BF**, Sankovsky A, Nasr I. Idiopathic ovarian vein thrombosis: a rare cause of abdominal pain. *Am J Emerg Med* 2016; **34**: 935.e1-935.e2 [PMID: [26475360](#) DOI: [10.1016/j.ajem.2015.09.022](#)]
- 16 **Salomon O**, Apter S, Shaham D, Hiller N, Bar-Ziv J, Itzhak Y, Gitel S, Rosenberg N, Strauss S, Kaufman N, Seligsohn U. Risk factors associated with postpartum ovarian vein thrombosis. *Thromb Haemost* 1999; **82**: 1015-1019 [PMID: [10494756](#)]
- 17 **Cao W**, Ni X, Wang Q, Li J, Li Y, Chen T, Wang X. Early diagnosis and precision treatment of right ovarian vein and inferior vena cava thrombosis following caesarean section: A case report. *Exp Ther Med* 2020; **19**: 2923-2926 [PMID: [32256777](#) DOI: [10.3892/etm.2020.8548](#)]
- 18 **American College of Obstetricians and Gynecologists' Committee on Practice Bulletins—Obstetrics**. ACOG Practice Bulletin No. 196: Thromboembolism in Pregnancy. *Obstet Gynecol* 2018; **132**: e1-e17 [PMID: [29939938](#) DOI: [10.1097/AOG.0000000000002706](#)]



Published by **Baishideng Publishing Group Inc**
7041 Koll Center Parkway, Suite 160, Pleasanton, CA 94566, USA

Telephone: +1-925-3991568

E-mail: bpgoffice@wjgnet.com

Help Desk: <https://www.f6publishing.com/helpdesk>

<https://www.wjgnet.com>

