

World Journal of *Clinical Cases*

World J Clin Cases 2023 June 26; 11(18): 4210-4457



REVIEW

- 4210 Should gastroenterologists prescribe cannabis? The highs, the lows and the unknowns
Samuel S, Michael M, Tadros M

MINIREVIEWS

- 4231 Application of artificial intelligence in trauma orthopedics: Limitation and prospects
Salimi M, Parry JA, Shahrokhi R, Mosalamiaghili S
- 4241 Weight loss maintenance after bariatric surgery
Cho YH, Lee Y, Choi JI, Lee SR, Lee SY
- 4251 Bicuspid aortic valve with associated aortopathy, significant left ventricular hypertrophy or concomitant hypertrophic cardiomyopathy: A diagnostic and therapeutic challenge
Sopek Merkaš I, Lakušić N, Predrijevac M, Štambuk K, Hrabak Paar M
- 4258 Application experience and research progress of different emerging technologies in plastic surgery
Yang B, Yang L, Huang WL, Zhou QZ, He J, Zhao X

ORIGINAL ARTICLE**Case Control Study**

- 4267 Multimodal integrated intervention for children with attention-deficit/hyperactivity disorder
Lv YB, Cheng W, Wang MH, Wang XM, Hu YL, Lv LQ

Retrospective Study

- 4277 Portal vein computed tomography imaging characteristics and their relationship with bleeding risk in patients with liver cirrhosis undergoing interventional therapy
Song XJ, Liu JL, Jia SY, Zhang K

Observational Study

- 4287 Wrist-ankle acupuncture combined with pain nursing for the treatment of urinary calculi with acute pain
Wu LM, Liu Q, Yin XH, Yang LP, Yuan J, Zhang XQ, Wang YL

CASE REPORT

- 4295 Coexistence of diffuse large B-cell lymphoma, acute myeloid leukemia, and untreated lymphoplasmacytic lymphoma/waldenström macroglobulinemia in a same patient: A case report
Zhang LB, Zhang L, Xin HL, Wang Y, Bao HY, Meng QQ, Jiang SY, Han X, Chen WR, Wang JN, Shi XF
- 4306 Collagen fleece (Tachosil®) for treating testis torsion: A case report
Kim KM, Kim JH

- 4313** Morphological features and endovascular repair for type B multichanneled aortic dissection: A case report
Lu WF, Chen G, Wang LX
- 4318** Hepatic inflammatory myofibroblastic tumor: A case report
Tong M, Zhang BC, Jia FY, Wang J, Liu JH
- 4326** Endometriosis of the lung: A case report and review of literature
Yao J, Zheng H, Nie H, Li CF, Zhang W, Wang JJ
- 4334** Delayed dislocation of the radial head associated with malunion of distal radial fracture: A case report
Kim KB, Wang SI
- 4341** Synchronous endometrial and ovarian cancer: A case report
Žilovič D, Čiurlienė R, Šidlovská E, Vaicekauskaitė I, Sabaliauskaitė R, Jarmalaitė S
- 4350** Nivolumab-induced tumour-like gastritis: A case report
Cijauskaite E, Kazenaite E, Strainiene S, Sadauskaite G, Kurlinkus B
- 4360** Solitary thyroid gland metastasis from rectal cancer: A case report and review of the literature
Chen Y, Kang QS, Zheng Y, Li FB
- 4368** Anesthesia for extracorporeal membrane oxygenation-assisted thoracoscopic lower lobe subsegmental resection in a patient with a single left lung: A case report
Wang XF, Li ZY, Chen L, Chen LX, Xie F, Luo HQ
- 4377** Indium chloride bone marrow scintigraphy for hepatic myelolipoma: A case report
Sato A, Saito K, Abe K, Sugimoto K, Nagao T, Sukeda A, Yunaiyama D
- 4384** Fibromatosis-like metaplastic carcinoma of the breast: Two case reports
Bao WY, Zhou JH, Luo Y, Lu Y
- 4392** Perforating and ophthalmic artery variants from the anterior cerebral artery: Two case reports
Mo ZX, Li W, Wang DF
- 4397** Diagnostic use of superb microvascular imaging in evaluating septic arthritis of the manubriosternal joint: A case report
Seskute G, Kausaite D, Chalkovskaja A, Bulotaite E, Butrimiene I
- 4406** Primary prostate Burkitt's lymphoma resected with holmium laser enucleation of the prostate: A rare case report
Wu YF, Li X, Ma J, Ma DY, Zeng XM, Yu QW, Chen WG
- 4412** Pancreatitis, panniculitis and polyarthritides syndrome: A case report
Pichler H, Stumpner T, Schiller D, Bischofreiter M, Ortmaier R
- 4419** Acute neck tendonitis with dyspnea: A case report
Wu H, Liu W, Mi L, Liu Q

- 4425** Next-generation sequencing technology for the diagnosis of *Pneumocystis* pneumonia in an immunocompetent female: A case report
Huang JJ, Zhang SS, Liu ML, Yang EY, Pan Y, Wu J
- 4433** Superior laryngeal nerve block for treatment of throat pain and cough following laryngeal herpes zoster: A case report
Oh J, Park Y, Choi J, Jeon Y
- 4438** Removal of unexpected schwannoma with superficial parotidectomy using modified-Blair incision and superficial musculoaponeurotic system folding: A case report
Nam HJ, Choi HJ, Byeon JY, Wee SY
- 4446** Simultaneously metastatic cholangiocarcinoma and small intestine cancer from breast cancer misdiagnosed as primary cholangiocarcinoma: A case report
Jiao X, Zhai MM, Xing FZ, Wang XL

LETTER TO THE EDITOR

- 4454** Erroneous presentation of respiratory-hemodynamic disturbances and postsurgical inflammatory responses in patients having undergone abdominal cavity cancer surgery
Idrissov KS, Mynbaev OA

ABOUT COVER

Editorial Board Member of *World Journal of Clinical Cases*, Guoping Zheng, MD, PhD, Associate Professor, Faculty of Medicine and Health, Sydney Medical School-Westmead Clinical School, The University of Sydney, Sydney 2145, Australia. guoping.zheng@sydney.edu.au

AIMS AND SCOPE

The primary aim of *World Journal of Clinical Cases* (WJCC, *World J Clin Cases*) is to provide scholars and readers from various fields of clinical medicine with a platform to publish high-quality clinical research articles and communicate their research findings online.

WJCC mainly publishes articles reporting research results and findings obtained in the field of clinical medicine and covering a wide range of topics, including case control studies, retrospective cohort studies, retrospective studies, clinical trials studies, observational studies, prospective studies, randomized controlled trials, randomized clinical trials, systematic reviews, meta-analysis, and case reports.

INDEXING/ABSTRACTING

The WJCC is now abstracted and indexed in Science Citation Index Expanded (SCIE, also known as SciSearch®), Journal Citation Reports/Science Edition, Current Contents®/Clinical Medicine, PubMed, PubMed Central, Reference Citation Analysis, China National Knowledge Infrastructure, China Science and Technology Journal Database, and Superstar Journals Database. The 2022 Edition of Journal Citation Reports® cites the 2021 impact factor (IF) for WJCC as 1.534; IF without journal self cites: 1.491; 5-year IF: 1.599; Journal Citation Indicator: 0.28; Ranking: 135 among 172 journals in medicine, general and internal; and Quartile category: Q4.

RESPONSIBLE EDITORS FOR THIS ISSUE

Production Editor: *Ying-Yi Yuan*; Production Department Director: *Xu Guo*; Editorial Office Director: *Jin-Lei Wang*.

NAME OF JOURNAL

World Journal of Clinical Cases

ISSN

ISSN 2307-8960 (online)

LAUNCH DATE

April 16, 2013

FREQUENCY

Thrice Monthly

EDITORS-IN-CHIEF

Bao-Gan Peng, Jerzy Tadeusz Chudek, George Kontogeorgos, Maurizio Serati, Ja Hyeon Ku

EDITORIAL BOARD MEMBERS

<https://www.wjgnet.com/2307-8960/editorialboard.htm>

PUBLICATION DATE

June 26, 2023

COPYRIGHT

© 2023 Baishideng Publishing Group Inc

INSTRUCTIONS TO AUTHORS

<https://www.wjgnet.com/bpg/gerinfo/204>

GUIDELINES FOR ETHICS DOCUMENTS

<https://www.wjgnet.com/bpg/GerInfo/287>

GUIDELINES FOR NON-NATIVE SPEAKERS OF ENGLISH

<https://www.wjgnet.com/bpg/gerinfo/240>

PUBLICATION ETHICS

<https://www.wjgnet.com/bpg/GerInfo/288>

PUBLICATION MISCONDUCT

<https://www.wjgnet.com/bpg/gerinfo/208>

ARTICLE PROCESSING CHARGE

<https://www.wjgnet.com/bpg/gerinfo/242>

STEPS FOR SUBMITTING MANUSCRIPTS

<https://www.wjgnet.com/bpg/GerInfo/239>

ONLINE SUBMISSION

<https://www.f6publishing.com>



Next-generation sequencing technology for the diagnosis of *Pneumocystis* pneumonia in an immunocompetent female: A case report

Jing-Ji Huang, Song-Song Zhang, Man-Li Liu, En-Yu Yang, Yu Pan, Jing Wu

Specialty type: Critical care medicine

Provenance and peer review: Unsolicited article; Externally peer reviewed.

Peer-review model: Single blind

Peer-review report's scientific quality classification

Grade A (Excellent): 0
Grade B (Very good): 0
Grade C (Good): C, C
Grade D (Fair): 0
Grade E (Poor): 0

P-Reviewer: Lee YJ, Taiwan;
Palmirotta R, Italy

Received: April 4, 2023

Peer-review started: April 4, 2023

First decision: May 12, 2023

Revised: May 25, 2023

Accepted: May 30, 2023

Article in press: May 30, 2023

Published online: June 26, 2023



Jing-Ji Huang, The Second Clinical Medical College, Guizhou University of Traditional Chinese Medicine, Guiyang 550000, Guizhou Province, China

Song-Song Zhang, Man-Li Liu, En-Yu Yang, Yu Pan, Jing Wu, Intensive Care Unit, Guizhou Provincial People's Hospital, Guiyang 550000, Guizhou Province, China

Corresponding author: Jing Wu, PhD, Associate Professor, Intensive Care Unit, Guizhou Provincial People's Hospital, No. 83 Zhongshan East Road, Guiyang 550000, Guizhou Province, China. saidiny1120@qq.com

Abstract

BACKGROUND

Pneumocystis pneumonia (PCP) is a serious fungal infection usually seen in patients with human immunodeficiency virus, and it is more frequently found and has a high fatality rate in immunocompromised people. Surprisingly, it rarely occurs in immunocompetent patients. However, the clinical diagnosis of this pathogen is made more difficult by the difficulty of obtaining accurate microbiological evidence with routine tests. This case reports a PCP patient with normal immune function who was diagnosed through next-generation sequencing (NGS).

CASE SUMMARY

A 23-year-old female who had no special disease in the past was admitted to the hospital with a persistent fever and cough. Based on the initial examination results, the patient was diagnosed with bipulmonary pneumonia, and empirical broad-spectrum antibiotic therapy was administered. However, due to the undetermined etiology, the patient's condition continued to worsen. She was transferred to the intensive care unit because of acute respiratory failure. After the diagnosis of *Pneumocystis jirovecii* infection through NGS in bronchoalveolar lavage fluid and treatment with trimethoprim/sulfamethoxazole and caspofungin, the patient gradually recovered and had a good prognosis.

CONCLUSION

This case emphasizes that, for patients with normal immune function the possibility of PCP infection, although rare, cannot be ignored. NGS plays an important role in the diagnosis of refractory interstitial pneumonia and acute respiratory failure.

Key Words: *Pneumocystis* pneumonia; *Pneumocystis jirovecii*; Next-generation sequencing; Immunocompetent; Trimethoprim/Sulfamethoxazole; Case report

©The Author(s) 2023. Published by Baishideng Publishing Group Inc. All rights reserved.

Core Tip: Although *Pneumocystis* pneumonia (PCP) in immunocompetent patients is rare, it should be considered in infected patients with sudden onset of respiratory failure. However, using routine clinical examination, it can be challenging to differentiate between colonizing bacteria and subclinical infections. Instead of traditional laboratory techniques, next-generation sequencing (NGS) was used to make the diagnosis in the current case report. Early diagnosis and fast treatment helped to avoid ineffective treatments and improve the prognosis. This case emphasized that PCP can arise in immunocompetent patients, and NGS may be an effective test method for the quick and accurate diagnosis of PCP.

Citation: Huang JJ, Zhang SS, Liu ML, Yang EY, Pan Y, Wu J. Next-generation sequencing technology for the diagnosis of *Pneumocystis* pneumonia in an immunocompetent female: A case report. *World J Clin Cases* 2023; 11(18): 4425-4432

URL: <https://www.wjgnet.com/2307-8960/full/v11/i18/4425.htm>

DOI: <https://dx.doi.org/10.12998/wjcc.v11.i18.4425>

INTRODUCTION

Pneumocystis pneumonia (PCP) is an opportunistic fungal infection caused by the invasion of the single-celled fungus *Pneumocystis jirovecii*, and it is more common in patients with human immunodeficiency virus (HIV) infection[1]. According to the most recent data, there are still over 500000 instances of PCP worldwide annually, with a death rate of up to 30%, although the incidence of HIV has decreased and can now be effectively prevented due to the deployment of highly active antiretroviral therapy[2,3]. Additionally, as the use of immunosuppressants has increased in recent years, PCP is more frequently found in patients with organ transplantation, malignant tumors, autoimmune diseases, and long-term corticosteroids, leading to an increase in nonHIV PCP immunocompromised individuals and eventually surpassing that of HIV patients[4]. Nonetheless, in the clinic, PCP without immunosuppression is incredibly rare[5]. In this case, a patient with a normal immune system developed severe pneumonia and acute progressive respiratory failure. Sputum cultures were negative many times, and treatment with conventional antibiotics was ineffective. Finally, PCP infection was detected in alveolar lavage fluid using next-generation sequencing (NGS) of bronchoalveolar lavage fluid (BALF). This case suggests that the possibility of PCP infection should not be ignored and the value of NGS in the diagnosis of refractory respiratory failure in patients with normal immune function and severe pneumonia.

CASE PRESENTATION

Chief complaints

A 23-year-old woman presented with a persistent fever (up to 40.5°C) accompanied by cough and sputum for a week.

History of present illness

The symptoms began 1 wk before the onset of the disease with recurrent fever due to cold with cough and sputum.

History of past illness

No particular disease was noted for the patient history.

Personal and family history

No personal or family history of infectious disease, genetic disease, or other particular disease was noted.

Physical examination

The vital signs were as follows: Body temperature, 38.0°C; blood pressure, 96/63 mmHg; heart rate, 130

beats per min; and respiratory rate, 20 breaths per min. No other positive signs except slightly coarse breath sounds as well as moist rales in both lower lungs were observed during auscultation.

Laboratory examinations

Laboratory tests showed that the main inflammatory parameters and (1-3)- β -D-glucan test (G test) level increased significantly (Table 1). Liver and kidney function, especially the lactate dehydrogenase (LDH) levels, deteriorated (Table 2). The results of the galactomannan test (GM test), purified protein derivative test, initial screening test for HIV antigens/antibodies and tests for other common respiratory pathogens, such as *Mycoplasma pneumoniae*, *Chlamydia pneumoniae*, parainfluenza virus, Epstein-Barr virus, and influenza A and B, were negative. Based on the positive results of the G-test, increased inflammatory indicators, and elevated LDH levels, we preliminarily considered that the patient might have fungal infection. However, we could not determine the cause of respiratory failure and the specific source of infection with routine testing. Treatment with broad-spectrum antibiotics and ventilators could not prevent disease progression. To diagnose and save the patient more quickly and accurately, we conducted bronchoscopy examination and collected BALF specimens for NGS with the PMseq pathogen high-throughput sequencing platform MGISEQ-2000 for metagenomic sequencing of RNA pathogenic microorganisms at Complete Genomics (BGI, Shenzhen, China). With a sequencing depth of 31 M, BALF-NGS identified one fungus, *Pneumocystis jirovecii* (Table 3). The number of sequences was 12152.

Imaging examinations

Chest imaging suggested inflammatory infiltration in both lungs (Figures 1 and 2).

FINAL DIAGNOSIS

According to the patient's medical history, clinical characteristics, laboratory examinations and imaging results, we determined that *Pneumocystis jirovecii* was the causative pathogenic microorganism. The final diagnoses were bilateral interstitial pneumonia (*Pneumocystis pneumonia*), acute respiratory failure and multiple organ dysfunction syndrome.

TREATMENT

Based on the initial test results, cefoperazone sulbactam (2.0 g, q12 h, intravenous drip) together with voriconazole (200 mg, q12 h, intravenous drip) were given. After being transferred to the intensive care unit (ICU), the patient was tracheally intubated and underwent prone ventilation (AC mode, FIO₂ 90%, PEEP 10 cm H₂O). Broad-spectrum antibiotic therapies were administered, including meropenem (1 g, q8 h, intravenous drip), vancomycin (0.5 g, q6 h, intravenous drip), voriconazole (200 mg, q12 h, intravenous drip), and oseltamivir phosphate (75 mg, q12 h, oral administration). When the etiology was identified as *Pneumocystis jirovecii*, the antifungal therapies were adjusted to trimethoprim/sulfamethoxazole (TMP/SMX, TMP 0.8 g/SMX 0.4 g, q6 h, oral administration) and caspofungin intravenously (50 mg, qd, intravenous drip).

OUTCOME AND FOLLOW-UP

After 14 d of standard anti-PCP and respiratory support treatments, the patient's temperature returned to normal, and her respiratory condition improved significantly (SpO₂ over 98%, PaO₂/FIO₂ 452 mmHg). She was removed from the ventilator successfully. With almost all laboratory indicators returning to normal, the patient was transferred to the general ward for further treatments. Chest computed tomography indicated the basic absorption of inflammation at discharge. Follow-up indicated a good prognosis for the patient.

DISCUSSION

PCP is a serious, potentially fatal opportunistic illness that frequently applies to patients with compromised immune systems[6], and the incidence of PCP infection in non-HIV patients has increased recently. However, PCP in people with normal immune function is rare and difficult to clearly diagnose by permanent routine methods. Thus, the first startling aspect of this case is that PCP can arise in immunocompetent patients. Second, for bilateral interstitial pneumonia and acute respiratory failure, for which the etiology is difficult to determine, NGS may be an effective test method for quick and

Table 1 Main inflammatory parameters

Item	Result on admission	Results at ICU	Reference range
WBC ($\times 10^9$)	4.31	2.64	3.5-10
RBC ($\times 10^{12}$)	2.49	2.10	3.5-5.5
HGB (g/L)	84	69	114-163
NEUT ($\times 10^9$)	3.65	2.42	1.8-6.3
%NEUT	84.8	91.7	40-75
MONO ($\times 10^9$)	0.04	0.04	0.1-0.6
%MONO	0.9	1.5	3-10
LYMBP ($\times 10^9$)	0.60	0.17	1.1-3.2
%LYMBP	13.9	6.4	20-50
PLT ($\times 10^9$)	114	69	125-350
CRP (mg/L)	7.51	37.69	0-5
ESR (mm/h)	47	120	0-20
PCT (ng/mL)	0.75	> 100	0-0.046
IL-6 (pg/mL)	6.33	33.64	< 7
G test (pg/mL)	572.42		< 60

ICU: Intensive care unit; WBC: White blood cells; RBC: Red blood cells; HGB: Hemoglobin; NEUT: Neutrophils; MONO: Monocytes; LYMBP: Lymphocytes; PLT: Platelets; CRP: C-reactive protein; ESR: Erythrocyte sedimentation rate; PCT: Procalcitonin; IL-6: Interleukin-6; G test: (1-3)- β -D-glucan test.

Table 2 Liver and renal function results

Item	Result on admission	Results at ICU	Reference range
TBIL ($\mu\text{mol/L}$)	12.8	64.9	3.6-20.5
TP (g/L)	65.3	46.3	65-85
ALB (g/L)	37.3	22.2	40-55
ALT (U/L)	42	61	9-50
AST (U/L)	37	39	15-40
sCrea ($\mu\text{mol/L}$)	76	307	57-97
Urea (mmol/L)	8.53	31.25	3.1-8
UA ($\mu\text{mol/L}$)	314	629	210-420
LDH(U/L)	852		94-250

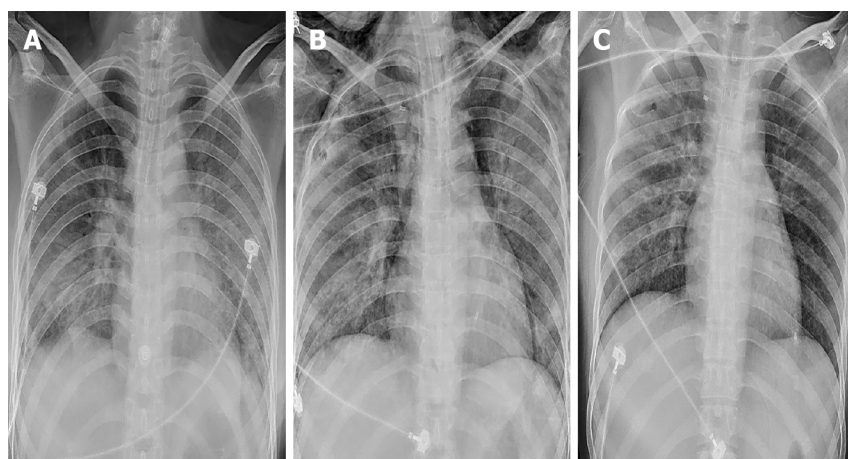
Blood was collected for liver and renal function. ICU: Intensive care unit; TBIL: Total bilirubin; TP: Total protein; ALB: Serum albumin; ALT: Alanine aminotransferase; AST: Aspartate aminotransferase; sCrea: Serum creatinine; UA: Uric acid; LDH: Lactate dehydrogenase.

Table 3 Next-generation sequencing gene detection of bronchoalveolar lavage fluid

Genus	Number of sequences	Species	Number of sequences
<i>Pneumocystis</i>	12297	<i>Pneumocystis jirovecii</i>	12152

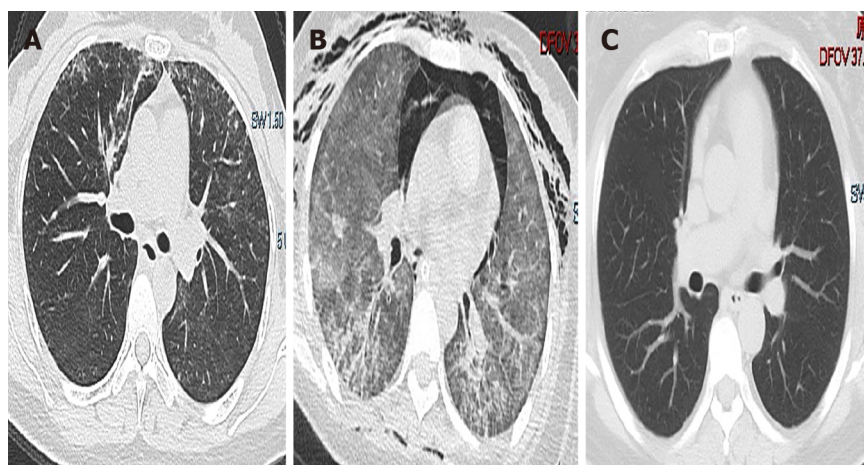
accurate diagnosis such that patients can receive appropriate treatments.

PCP is rarely found in immunocompetent patients, and the clinical manifestations of PCP in HIV and non-HIV patients are similar but different. First, most PCP patients experience fever, followed by chest tightness, shortness of breath, a dry cough, and less sputum as their chief complaints. As the disease progresses, hypoxia gradually worsens and eventually leads to progressive dyspnea; however, the



DOI: 10.12998/wjcc.v11.i18.4425 Copyright ©The Author(s) 2023.

Figure 1 Chest X-ray of patient. A: Chest X-ray findings on admission, increased texture in both lungs and hyperdense shadows in both lungs with an unclear border; B: Chest radiograph results at intensive care unit, bilateral lung exudation increased compared with the previous one, complicated by pneumothorax; C: Chest X-ray images at discharge. The exudate was partially absorbed in both lungs.



DOI: 10.12998/wjcc.v11.i18.4425 Copyright ©The Author(s) 2023.

Figure 2 Chest computed tomography scans of patient. A: Computed tomography (CT) images on admission, diffuse stripes and cords in both lungs with increased density and fuzzy edges; B: CT results in the intensive care unit, consolidation, aerothorax and ground-glass opacities in both lungs; C: CT findings at discharge, the marked resolution of ground-glass opacities and consolidation.

pulmonary signs frequently do not correspond to the severity of symptoms[7]. PCP primarily has a subacute course in HIV-positive patients, whereas in non-HIV-positive patients the symptoms quickly progress to respiratory failure[8]. In this case, a PCP patient without HIV infection also experienced high fever, cough, shortness of breath, interstitial pneumonia, and rapid progression of respiratory failure. Second, in addition to differences in clinical manifestations, the severity of the disease and the proportion of patients who even need endotracheal intubation and mechanical ventilation between HIV and non-HIV PCP patients are different. In one cohort study, approximately 41% of patients with PCP needed to be admitted to the ICU, among whom 36% needed mechanical breathing[9]. With a mortality rate of 53% in non-HIV patients compared with 15% in HIV patients, 28% in HIV patients requiring invasive mechanical ventilation, and up to 60% in non-HIV invasive mechanical ventilation patients[10, 11]. In general, HIV patients are admitted to the ICU less frequently than non-HIV patients. In addition to the rapidly progressing bilateral interstitial pneumonia, the acute exacerbation of respiratory failure was the main reason for the patient being transferred to the ICU in our case. Anti-PCP therapy and respiratory support therapy (tracheal intubation and prone ventilation) were the main effective treatments for this patient.

Except for the difference in clinical manifestations, it is challenging to make an early diagnosis of non-HIV PCP patients[12,13]. The gold standard for diagnosing PCP often uses microscopy for the detection of *Pneumocystis jirovecii* cysts or trophozoites in BALF by special staining and immunofluorescence methods. Because *Pneumocystis jirovecii* cannot be cultivated in vitro, BALF is particularly recommended clinically[14]. However, the sensitivity of special staining and immunofluorescence staining is not high,

at approximately 50%, which is lower than that of the polymerase chain reaction (PCR) method. PCR is a simple and fast method for the clinical detection of *Pneumocystis jirovecii* in BALF and sputum specimens. However, due to its high sensitivity of 98%, it cannot easily differentiate between colonization and subclinical infection, leading to a limited number of true-positive results[15]. G test, which is a part of many fungal walls, is highly sensitive for the diagnosis of HIV PCP patients, but the specificity is not high in nonHIV PCP patients. Other invasive fungal infections, such as *Candida*, *Aspergillus pneumoneum*, and *Fusarium* infection, also present G test positivity. In our case, because the patient had no history of immune deficiency, a positive G test was more likely to be considered a common fungal infection rather than PCP infection. PCP diagnosis using traditional assays is still exceedingly difficult.

With the rapid advancement of molecular detection technology in recent years, BALF-NGS has emerged as a new diagnostic technique that is used in clinical settings for its high sensitivity and specificity (97.4% and 85.12%, respectively), particularly for the detection of special pathogen infections and mixed infections in immunosuppressed and immunocompetent patients[16]. It has the important advantages of being quicker, more accurate, and safer. Additionally, NGS was demonstrated to be significantly more sensitive than immunofluorescence staining (25%) and the G test (67.4%) in a retrospective study. It is important to note that the two were consistent in detecting *Pneumocystis jirovecii* when NGS was conducted separately using BALF and blood samples from the same patient[17]. In this case, the patient developed bilateral interstitial pneumonia and rapidly aggravated respiratory failure. In addition to a positive G test, increased inflammatory indicators and elevated levels of LDH, we did not obtain more effective laboratory positive test results. The pathogen causing pulmonary infection and respiratory failure has not been found, resulting in poor effects of antibiotics and respiratory support treatments. The results identified one fungus, *Pneumocystis jirovecii*, which was confirmed to be the pathogenic microorganism. After been diagnosed of PCP and given anti-PCP treatment, the patient recovered and had a good prognosis. No pneumocystis-specific analysis was performed for our case, which might be a limitation.

The standard suggested dose of meperidine 15-20 mg/kg/d and sulfamethoxazole 75-100 mg/kg/d given in 4 separate doses for 21 d is now the first-line treatment for PCP in all populations[18]. NonHIV PCP patients still experience high mortality rates and a high frequency of adverse events, such as rash, fever, gastrointestinal discomfort, leukopenia, hepatotoxicity, and renal insufficiency[19]. To remedy these problems, various complementary and alternative therapies are urgently needed. Caspofungin has received much attention as a novel class of echinocandin antifungal medication because it inhibits the synthesis of G test, which affects the creation of *Pneumocystis jirovecii* cell wall and ultimately causes *Pneumocystis jirovecii* death[20]. Despite the lack of prospective research, certain case reports have shown caspofungin's significant efficacy when used either alone or in conjunction with other treatments, and it can be used to treat PCP[21]. In this case, although the patient had no history of HIV infection, immune deficiency, hormone use or other diseases, we immediately administered standard anti-PCP treatment after the diagnosis of PCP through BALF-NGS. The patient's renal function and urinalysis were both normal at the time of admission, but with the aggravation of the disease, the patient's organ function, especially renal function, became abnormal. Considering the abnormality of renal function, in addition to the first-line treatment (TMP/SMX), we also used caspofungin as one of the anti-PCP treatments that has little impact on organ function, as reported in the literature[22]. Diseases of the immune system are a prominent factor in PCP.

In the past, studies have suggested corticosteroids as an adjuvant medication in addition to antibiotics. Research has revealed that corticosteroids dramatically lower mortality in HIV PCP patients [23]. However, it is debatable whether to treat nonHIV PCP with corticosteroids because the majority of patients are already taking them prior to the onset of pneumonia and because prolonged use of corticosteroids can cause immune deficiency, which is a significant contributing factor to non-HIV patients' susceptibility to PCP. Currently, the recommended course of treatment is a combination of corticosteroids and immunosuppressants based on supportive therapy. However, this course of treatment will also cause varying degrees of damage to the immune system, greatly increasing the risk of infection by pathogens such as fungi and bacteria. Therefore, corticosteroids and immunosuppressants were not administered in our case. Instead, supportive care was used to slow the progression of the disease.

CONCLUSION

In conclusion, we observed nonHIV PCP in individuals evaluated for the lack of underlying risk factors, which are rare and sometimes overlooked. Early application of NGS can help to quickly identify pathogens and buy time for patients who have sudden respiratory failure or a particular, atypical suspected infection. NGS is important in the identification of clinical infectious diseases.

FOOTNOTES

Author contributions: Huang JJ and Wu J contributed to manuscript writing; Zhang SS and Liu ML contributed to collection of clinical data; Yang EY and Pan Y contributed to data analysis and production of charts; all authors have read and approved the final manuscript.

Supported by the National Natural Science Foundation of China, No. 81860273; the Guizhou Provincial Science and Technology Projects, No. QKHJC-ZK[2022]-260; the Science and Technology Fund of Guizhou Provincial Health Commission, No. gzwkj2021-320; and Guizhou Provincial People's Hospital National Natural Science Foundation, No. [2018]5764-09.

Informed consent statement: Informed written consent was obtained from the patient for publication of this report and any accompanying images.

Conflict-of-interest statement: The authors declare that they have no conflict of interest to disclose.

CARE Checklist (2016) statement: The authors have read the CARE Checklist (2016), and the manuscript was prepared and revised according to the CARE Checklist (2016).

Open-Access: This article is an open-access article that was selected by an in-house editor and fully peer-reviewed by external reviewers. It is distributed in accordance with the Creative Commons Attribution NonCommercial (CC BY-NC 4.0) license, which permits others to distribute, remix, adapt, build upon this work non-commercially, and license their derivative works on different terms, provided the original work is properly cited and the use is non-commercial. See: <https://creativecommons.org/licenses/by-nc/4.0/>

Country/Territory of origin: China

ORCID number: Jing-Ji Huang 0009-0008-0170-3919; Song-Song Zhang 0000-0002-5826-2009; Man-Li Liu 0000-0002-4288-3927; En-Yu Yang 0009-0000-5918-4789; Yu Pan 0000-0003-1478-9359; Jing Wu 0000-0001-7455-7766.

S-Editor: Liu JH

L-Editor: A

P-Editor: Liu JH

REFERENCES

- 1 Sokulska M, Kicia M, Wesolowska M, Hendrich AB. *Pneumocystis jirovecii*--from a commensal to pathogen: clinical and diagnostic review. *Parasitol Res* 2015; **114**: 3577-3585 [PMID: 26281787 DOI: 10.1007/s00436-015-4678-6]
- 2 Bongomin F, Gago S, Oladele RO, Denning DW. Global and Multi-National Prevalence of Fungal Diseases-Estimate Precision. *J Fungi (Basel)* 2017; **3** [PMID: 29371573 DOI: 10.3390/jof3040057]
- 3 Limper AH, Adenis A, Le T, Harrison TS. Fungal infections in HIV/AIDS. *Lancet Infect Dis* 2017; **17**: e334-e343 [PMID: 28774701 DOI: 10.1016/S1473-3099(17)30303-1]
- 4 Liu Y, Su L, Jiang SJ, Qu H. Risk factors for mortality from pneumocystis carinii pneumonia (PCP) in non-HIV patients: a meta-analysis. *Oncotarget* 2017; **8**: 59729-59739 [PMID: 28938676 DOI: 10.18632/oncotarget.19927]
- 5 Jacobs JL, Libby DM, Winters RA, Gelmont DM, Fried ED, Hartman BJ, Laurence J. A cluster of *Pneumocystis carinii* pneumonia in adults without predisposing illnesses. *N Engl J Med* 1991; **324**: 246-250 [PMID: 1985246 DOI: 10.1056/NEJM199101243240407]
- 6 Roux A, Gonzalez F, Roux M, Mehrad M, Menotti J, Zahar JR, Tadros VX, Azoulay E, Brillet PY, Vincent F; Groupe de recherche respiratoire en réanimation en onco-hématologie (Grrr-OH). Update on pulmonary *Pneumocystis jirovecii* infection in non-HIV patients. *Med Mal Infect* 2014; **44**: 185-198 [PMID: 24630595 DOI: 10.1016/j.medmal.2014.01.007]
- 7 Krajicek BJ, Thomas CF Jr, Limper AH. *Pneumocystis pneumonia*: current concepts in pathogenesis, diagnosis, and treatment. *Clin Chest Med* 2009; **30**: 265-278, vi [PMID: 19375633 DOI: 10.1016/j.ccm.2009.02.005]
- 8 Mikaelsson L, Jacobsson G, Andersson R. *Pneumocystis pneumonia*--a retrospective study 1991-2001 in Gothenburg, Sweden. *J Infect* 2006; **53**: 260-265 [PMID: 16403575 DOI: 10.1016/j.jinf.2005.06.014]
- 9 Schmidt JJ, Lueck C, Ziesing S, Stoll M, Haller H, Gottlieb J, Eder M, Welte T, Hoepfer MM, Scherag A, David S. Clinical course, treatment and outcome of *Pneumocystis pneumonia* in immunocompromised adults: a retrospective analysis over 17 years. *Crit Care* 2018; **22**: 307 [PMID: 30454031 DOI: 10.1186/s13054-018-2221-8]
- 10 Fillatre P, Decaux O, Jouneau S, Revest M, Gacouin A, Robert-Gangneux F, Fresnel A, Guiguen C, Le Tulzo Y, Jégo P, Tattevin P. Incidence of *Pneumocystis jirovecii* pneumonia among groups at risk in HIV-negative patients. *Am J Med* 2014; **127**: 1242.e11-1242.e17 [PMID: 25058862 DOI: 10.1016/j.amjmed.2014.07.010]
- 11 Guo F, Chen Y, Yang SL, Xia H, Li XW, Tong ZH. *Pneumocystis pneumonia* in HIV-infected and immunocompromised non-HIV infected patients: a retrospective study of two centers in China. *PLoS One* 2014; **9**: e101943 [PMID: 25029342 DOI: 10.1371/journal.pone.0101943]
- 12 Cillóniz C, Domínguez C, Álvarez-Martínez MJ, Moreno A, García F, Torres A, Miro JM. *Pneumocystis pneumonia* in the twenty-first century: HIV-infected vs HIV-uninfected patients. *Expert Rev Anti Infect Ther* 2019; **17**: 787-801 [PMID: 30811111 DOI: 10.1080/14737175.2019.1644444]

- 31550942 DOI: [10.1080/14787210.2019.1671823](https://doi.org/10.1080/14787210.2019.1671823)]
- 13 **Li WJ**, Guo YL, Liu TJ, Wang K, Kong JL. Diagnosis of pneumocystis pneumonia using serum (1-3)- β -D-Glucan: a bivariate meta-analysis and systematic review. *J Thorac Dis* 2015; **7**: 2214-2225 [PMID: [26793343](https://pubmed.ncbi.nlm.nih.gov/26793343/) DOI: [10.3978/j.issn.2072-1439.2015.12.27](https://doi.org/10.3978/j.issn.2072-1439.2015.12.27)]
- 14 **Thomas CF Jr**, Limper AH. Pneumocystis pneumonia. *N Engl J Med* 2004; **350**: 2487-2498 [PMID: [15190141](https://pubmed.ncbi.nlm.nih.gov/15190141/) DOI: [10.1056/NEJMra032588](https://doi.org/10.1056/NEJMra032588)]
- 15 **Fan LC**, Lu HW, Cheng KB, Li HP, Xu JF. Evaluation of PCR in bronchoalveolar lavage fluid for diagnosis of *Pneumocystis jirovecii* pneumonia: a bivariate meta-analysis and systematic review. *PLoS One* 2013; **8**: e73099 [PMID: [24023814](https://pubmed.ncbi.nlm.nih.gov/24023814/) DOI: [10.1371/journal.pone.0073099](https://doi.org/10.1371/journal.pone.0073099)]
- 16 **Sun H**, Wang F, Zhang M, Xu X, Li M, Gao W, Wu X, Han H, Wang Q, Yao G, Lou Z, Xia H, Shi Y, Li Q. Diagnostic Value of Bronchoalveolar Lavage Fluid Metagenomic Next-Generation Sequencing in *Pneumocystis jirovecii* Pneumonia in Non-HIV Immunosuppressed Patients. *Front Cell Infect Microbiol* 2022; **12**: 872813 [PMID: [35463643](https://pubmed.ncbi.nlm.nih.gov/35463643/) DOI: [10.3389/fcimb.2022.872813](https://doi.org/10.3389/fcimb.2022.872813)]
- 17 **Jiang J**, Bai L, Yang W, Peng W, An J, Wu Y, Pan P, Li Y. Metagenomic Next-Generation Sequencing for the Diagnosis of *Pneumocystis jirovecii* Pneumonia in Non-HIV-Infected Patients: A Retrospective Study. *Infect Dis Ther* 2021; **10**: 1733-1745 [PMID: [34244957](https://pubmed.ncbi.nlm.nih.gov/34244957/) DOI: [10.1007/s40121-021-00482-y](https://doi.org/10.1007/s40121-021-00482-y)]
- 18 **Limper AH**, Knox KS, Sarosi GA, Ampel NM, Bennett JE, Catanzaro A, Davies SF, Dismukes WE, Hage CA, Marr KA, Mody CH, Perfect JR, Stevens DA; American Thoracic Society Fungal Working Group. An official American Thoracic Society statement: Treatment of fungal infections in adult pulmonary and critical care patients. *Am J Respir Crit Care Med* 2011; **183**: 96-128 [PMID: [21193785](https://pubmed.ncbi.nlm.nih.gov/21193785/) DOI: [10.1164/rccm.2008-740ST](https://doi.org/10.1164/rccm.2008-740ST)]
- 19 **White PL**, Price JS, Backx M. Therapy and Management of *Pneumocystis jirovecii* Infection. *J Fungi (Basel)* 2018; **4** [PMID: [30469526](https://pubmed.ncbi.nlm.nih.gov/30469526/) DOI: [10.3390/jof4040127](https://doi.org/10.3390/jof4040127)]
- 20 **Wyder MA**, Johnston LQ, Kaneshiro ES. Evidence for DNA synthesis in *Pneumocystis carinii* trophozoites treated with the beta-1,3-glucan synthesis inhibitor pneumocandin L-693,989. *J Eukaryot Microbiol* 2010; **57**: 447-448 [PMID: [20738464](https://pubmed.ncbi.nlm.nih.gov/20738464/) DOI: [10.1111/j.1550-7408.2010.00502.x](https://doi.org/10.1111/j.1550-7408.2010.00502.x)]
- 21 **Lee WS**, Hsueh PR, Hsieh TC, Chen FL, Ou TY, Jean SS. Caspofungin salvage therapy in *Pneumocystis jirovecii* pneumonia. *J Microbiol Immunol Infect* 2017; **50**: 547-548 [PMID: [27094385](https://pubmed.ncbi.nlm.nih.gov/27094385/) DOI: [10.1016/j.jmii.2016.03.008](https://doi.org/10.1016/j.jmii.2016.03.008)]
- 22 **Wu HH**, Fang SY, Chen YX, Feng LF. Treatment of *Pneumocystis jirovecii* pneumonia in non-human immunodeficiency virus-infected patients using a combination of trimethoprim-sulfamethoxazole and caspofungin. *World J Clin Cases* 2022; **10**: 2743-2750 [PMID: [35434110](https://pubmed.ncbi.nlm.nih.gov/35434110/) DOI: [10.12998/wjcc.v10.i9.2743](https://doi.org/10.12998/wjcc.v10.i9.2743)]
- 23 **Wieruszewski PM**, Barreto JN, Frazee E, Daniels CE, Tosh PK, Dierkhising RA, Mara KC, Limper AH. Early Corticosteroids for *Pneumocystis* Pneumonia in Adults Without HIV Are Not Associated With Better Outcome. *Chest* 2018; **154**: 636-644 [PMID: [29705221](https://pubmed.ncbi.nlm.nih.gov/29705221/) DOI: [10.1016/j.chest.2018.04.026](https://doi.org/10.1016/j.chest.2018.04.026)]



Published by **Baishideng Publishing Group Inc**
7041 Koll Center Parkway, Suite 160, Pleasanton, CA 94566, USA

Telephone: +1-925-3991568

E-mail: bpgoffice@wjgnet.com

Help Desk: <https://www.f6publishing.com/helpdesk>

<https://www.wjgnet.com>

