

World Journal of *Clinical Cases*

World J Clin Cases 2023 June 26; 11(18): 4210-4457



REVIEW

- 4210 Should gastroenterologists prescribe cannabis? The highs, the lows and the unknowns
Samuel S, Michael M, Tadros M

MINIREVIEWS

- 4231 Application of artificial intelligence in trauma orthopedics: Limitation and prospects
Salimi M, Parry JA, Shahrokhi R, Mosalamiaghili S
- 4241 Weight loss maintenance after bariatric surgery
Cho YH, Lee Y, Choi JI, Lee SR, Lee SY
- 4251 Bicuspid aortic valve with associated aortopathy, significant left ventricular hypertrophy or concomitant hypertrophic cardiomyopathy: A diagnostic and therapeutic challenge
Sopek Merkaš I, Lakušić N, Predrijevac M, Štambuk K, Hrabak Paar M
- 4258 Application experience and research progress of different emerging technologies in plastic surgery
Yang B, Yang L, Huang WL, Zhou QZ, He J, Zhao X

ORIGINAL ARTICLE

Case Control Study

- 4267 Multimodal integrated intervention for children with attention-deficit/hyperactivity disorder
Lv YB, Cheng W, Wang MH, Wang XM, Hu YL, Lv LQ

Retrospective Study

- 4277 Portal vein computed tomography imaging characteristics and their relationship with bleeding risk in patients with liver cirrhosis undergoing interventional therapy
Song XJ, Liu JL, Jia SY, Zhang K

Observational Study

- 4287 Wrist-ankle acupuncture combined with pain nursing for the treatment of urinary calculi with acute pain
Wu LM, Liu Q, Yin XH, Yang LP, Yuan J, Zhang XQ, Wang YL

CASE REPORT

- 4295 Coexistence of diffuse large B-cell lymphoma, acute myeloid leukemia, and untreated lymphoplasmacytic lymphoma/waldenström macroglobulinemia in a same patient: A case report
Zhang LB, Zhang L, Xin HL, Wang Y, Bao HY, Meng QQ, Jiang SY, Han X, Chen WR, Wang JN, Shi XF
- 4306 Collagen fleece (Tachosil®) for treating testis torsion: A case report
Kim KM, Kim JH

- 4313** Morphological features and endovascular repair for type B multichanneled aortic dissection: A case report
Lu WF, Chen G, Wang LX
- 4318** Hepatic inflammatory myofibroblastic tumor: A case report
Tong M, Zhang BC, Jia FY, Wang J, Liu JH
- 4326** Endometriosis of the lung: A case report and review of literature
Yao J, Zheng H, Nie H, Li CF, Zhang W, Wang JJ
- 4334** Delayed dislocation of the radial head associated with malunion of distal radial fracture: A case report
Kim KB, Wang SI
- 4341** Synchronous endometrial and ovarian cancer: A case report
Žilovič D, Čiurlienė R, Šidlovská E, Vaicekauskaitė I, Sabaliauskaitė R, Jarmalaitė S
- 4350** Nivolumab-induced tumour-like gastritis: A case report
Cijauskaite E, Kazenaite E, Strainiene S, Sadauskaite G, Kurlinkus B
- 4360** Solitary thyroid gland metastasis from rectal cancer: A case report and review of the literature
Chen Y, Kang QS, Zheng Y, Li FB
- 4368** Anesthesia for extracorporeal membrane oxygenation-assisted thoracoscopic lower lobe subsegmental resection in a patient with a single left lung: A case report
Wang XF, Li ZY, Chen L, Chen LX, Xie F, Luo HQ
- 4377** Indium chloride bone marrow scintigraphy for hepatic myelolipoma: A case report
Sato A, Saito K, Abe K, Sugimoto K, Nagao T, Sukeda A, Yunaiyama D
- 4384** Fibromatosis-like metaplastic carcinoma of the breast: Two case reports
Bao WY, Zhou JH, Luo Y, Lu Y
- 4392** Perforating and ophthalmic artery variants from the anterior cerebral artery: Two case reports
Mo ZX, Li W, Wang DF
- 4397** Diagnostic use of superb microvascular imaging in evaluating septic arthritis of the manubriosternal joint: A case report
Seskute G, Kausaite D, Chalkovskaja A, Bulotaite E, Butrimiene I
- 4406** Primary prostate Burkitt's lymphoma resected with holmium laser enucleation of the prostate: A rare case report
Wu YF, Li X, Ma J, Ma DY, Zeng XM, Yu QW, Chen WG
- 4412** Pancreatitis, panniculitis and polyarthritides syndrome: A case report
Pichler H, Stumpner T, Schiller D, Bischofreiter M, Ortmaier R
- 4419** Acute neck tendonitis with dyspnea: A case report
Wu H, Liu W, Mi L, Liu Q

- 4425** Next-generation sequencing technology for the diagnosis of *Pneumocystis* pneumonia in an immunocompetent female: A case report
Huang JJ, Zhang SS, Liu ML, Yang EY, Pan Y, Wu J
- 4433** Superior laryngeal nerve block for treatment of throat pain and cough following laryngeal herpes zoster: A case report
Oh J, Park Y, Choi J, Jeon Y
- 4438** Removal of unexpected schwannoma with superficial parotidectomy using modified-Blair incision and superficial musculoaponeurotic system folding: A case report
Nam HJ, Choi HJ, Byeon JY, Wee SY
- 4446** Simultaneously metastatic cholangiocarcinoma and small intestine cancer from breast cancer misdiagnosed as primary cholangiocarcinoma: A case report
Jiao X, Zhai MM, Xing FZ, Wang XL

LETTER TO THE EDITOR

- 4454** Erroneous presentation of respiratory-hemodynamic disturbances and postsurgical inflammatory responses in patients having undergone abdominal cavity cancer surgery
Idrissov KS, Mynbaev OA

ABOUT COVER

Editorial Board Member of *World Journal of Clinical Cases*, Guoping Zheng, MD, PhD, Associate Professor, Faculty of Medicine and Health, Sydney Medical School-Westmead Clinical School, The University of Sydney, Sydney 2145, Australia. guoping.zheng@sydney.edu.au

AIMS AND SCOPE

The primary aim of *World Journal of Clinical Cases* (*WJCC*, *World J Clin Cases*) is to provide scholars and readers from various fields of clinical medicine with a platform to publish high-quality clinical research articles and communicate their research findings online.

WJCC mainly publishes articles reporting research results and findings obtained in the field of clinical medicine and covering a wide range of topics, including case control studies, retrospective cohort studies, retrospective studies, clinical trials studies, observational studies, prospective studies, randomized controlled trials, randomized clinical trials, systematic reviews, meta-analysis, and case reports.

INDEXING/ABSTRACTING

The *WJCC* is now abstracted and indexed in Science Citation Index Expanded (SCIE, also known as SciSearch®), Journal Citation Reports/Science Edition, Current Contents®/Clinical Medicine, PubMed, PubMed Central, Reference Citation Analysis, China National Knowledge Infrastructure, China Science and Technology Journal Database, and Superstar Journals Database. The 2022 Edition of Journal Citation Reports® cites the 2021 impact factor (IF) for *WJCC* as 1.534; IF without journal self cites: 1.491; 5-year IF: 1.599; Journal Citation Indicator: 0.28; Ranking: 135 among 172 journals in medicine, general and internal; and Quartile category: Q4.

RESPONSIBLE EDITORS FOR THIS ISSUE

Production Editor: *Ying-Yi Yuan*; Production Department Director: *Xu Guo*; Editorial Office Director: *Jin-Lei Wang*.

NAME OF JOURNAL

World Journal of Clinical Cases

ISSN

ISSN 2307-8960 (online)

LAUNCH DATE

April 16, 2013

FREQUENCY

Thrice Monthly

EDITORS-IN-CHIEF

Bao-Gan Peng, Jerzy Tadeusz Chudek, George Kontogeorgos, Maurizio Serati, Ja Hyeon Ku

EDITORIAL BOARD MEMBERS

<https://www.wjgnet.com/2307-8960/editorialboard.htm>

PUBLICATION DATE

June 26, 2023

COPYRIGHT

© 2023 Baishideng Publishing Group Inc

INSTRUCTIONS TO AUTHORS

<https://www.wjgnet.com/bpg/gerinfo/204>

GUIDELINES FOR ETHICS DOCUMENTS

<https://www.wjgnet.com/bpg/GerInfo/287>

GUIDELINES FOR NON-NATIVE SPEAKERS OF ENGLISH

<https://www.wjgnet.com/bpg/gerinfo/240>

PUBLICATION ETHICS

<https://www.wjgnet.com/bpg/GerInfo/288>

PUBLICATION MISCONDUCT

<https://www.wjgnet.com/bpg/gerinfo/208>

ARTICLE PROCESSING CHARGE

<https://www.wjgnet.com/bpg/gerinfo/242>

STEPS FOR SUBMITTING MANUSCRIPTS

<https://www.wjgnet.com/bpg/GerInfo/239>

ONLINE SUBMISSION

<https://www.f6publishing.com>

Superior laryngeal nerve block for treatment of throat pain and cough following laryngeal herpes zoster: A case report

Jinyoung Oh, Youngje Park, Jeongkyu Choi, Younghoon Jeon

Specialty type:

Otorhinolaryngology

Provenance and peer review:

Unsolicited article; Externally peer reviewed.

Peer-review model: Single blind**Peer-review report's scientific quality classification**

Grade A (Excellent): 0
Grade B (Very good): B
Grade C (Good): C
Grade D (Fair): 0
Grade E (Poor): 0

P-Reviewer: Higa K, Japan; Melek L, Egypt

Received: April 5, 2023

Peer-review started: April 5, 2023

First decision: May 8, 2023

Revised: May 17, 2023

Accepted: May 22, 2023

Article in press: May 22, 2023

Published online: June 26, 2023



Jinyoung Oh, Department of Anesthesiology and Pain Medicine, School of Medicine, Kyungpook National University, Daegu 41944, South Korea

Youngje Park, Jeongkyu Choi, Department of Anesthesiology and Pain Medicine, Kyungpook National University Hospital, Daegu 41944, South Korea

Younghoon Jeon, Department of Anesthesiology and Pain Medicine, School of Dentistry, Kyungpook National University, Daegu 41944, South Korea

Corresponding author: Younghoon Jeon, MD, PhD, Academic Editor, Professor, Department of Anesthesiology and Pain Medicine, School of Dentistry, Kyungpook National University, 130 Dongdeok-ro, Jung-gu, Daegu 41944, South Korea. jeon68@gmail.com

Abstract

BACKGROUND

Herpes zoster is caused by reactivation of latent varicella-zoster virus infection within the sensory nerve ganglion of the spinal or cranial nerves. Laryngeal herpes zoster is rare and involves superior laryngeal nerve, which leads to several complications such as throat pain, and cough.

CASE SUMMARY

Patient concerns: A 52-year old woman presented with a 70 d history of throat pain and a 67 d history of non-productive cough. Three days after onset of pain, she was diagnosed with laryngeal herpes zoster. Flexible nasolaryngoscopy revealed multiple white ulcerated lesions on the left hemi epiglottis and the left supraglottic area. She was prescribed with 750 mg famciclovir a day for 7 d, and 150 mg pregabalin, 100 mg tramadol and 10 mg nortriptyline a day for 67 d. However, despite of these medications, she complained of pain and persistent cough. Therefore, superior laryngeal nerve block under ultrasound guidance was performed. Three days after the intervention, the throat pain and cough disappeared. The patient remained symptom-free at 3 mo follow-up.

CONCLUSION

A superior laryngeal nerve block can be an effective option for treatment of pain and cough following laryngeal herpes zoster.

Key Words: Cough; Herpes zoster; Larynx; Neuralgia; Pain; Superior laryngeal nerve; Case report

Core Tip: Laryngeal herpes zoster is rare, leading to several complications such as throat pain, and cough. A superior laryngeal nerve block can be an effective option for treatment of pain and cough following laryngeal herpes zoster.

Citation: Oh J, Park Y, Choi J, Jeon Y. Superior laryngeal nerve block for treatment of throat pain and cough following laryngeal herpes zoster: A case report. *World J Clin Cases* 2023; 11(18): 4433-4437

URL: <https://www.wjgnet.com/2307-8960/full/v11/i18/4433.htm>

DOI: <https://dx.doi.org/10.12998/wjcc.v11.i18.4433>

INTRODUCTION

Herpes zoster is caused by reactivation of latent varicella-zoster virus infection within the sensory nerve ganglion of the spinal or cranial nerves[1]. Herpes zoster is characterized by acute pain and erythematous maculopapular rash in the affected dermatome and most commonly involves the thoracic dermatome. Laryngeal herpes zoster is rare and involves superior laryngeal nerve, which leads to several complications such as throat pain, and cough[2]. Here, we present a case of a 52-year-old woman with a 70-d history of throat pain and a 67 d history of non-productive cough following herpes zoster on the left hemi-epiglottis and the left supraglottic area. The pain and cough were successfully treated with left superior laryngeal nerve block with lidocaine and triamcinolone under ultrasonography guidance.

CASE PRESENTATION

Chief complaints

A 52-year-old female with throat pain and non-productive cough was referred to the pain management center from otolaryngology department.

History of present illness

Her throat pain occurred 70 d prior to presentation. Three days after onset of pain, she noticed non-productive cough.

History of past illness

She was diagnosed with laryngeal herpes zoster by an otolaryngologist 67 d prior to presentation.

Personal and family history

She had no significant medical history and family history.

Physical examination

Three days after onset of pain, a flexible nasolaryngoscopy revealed multiple mucosal eruptions and swelling on the left hemi-epiglottis and the left supraglottic area (Figure 1). The vocal movements were bilaterally normal.

Laboratory examinations

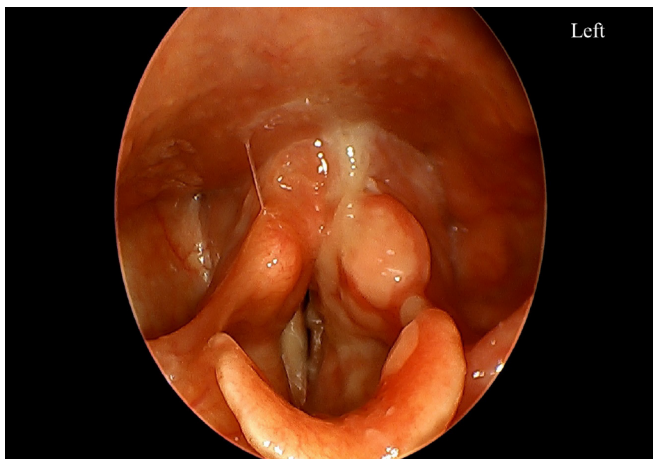
Blood laboratory tests including leukocyte count, C-reactive protein, and erythrocyte sedimentation rate showed no abnormalities.

Imaging examinations

Chest radiography showed no abnormalities.

FINAL DIAGNOSIS

She was diagnosed with throat pain and cough following laryngeal herpes zoster.



DOI: 10.12998/wjcc.v11.i18.4433 Copyright ©The Author(s) 2023.

Figure 1 Three days after onset of throat pain, flexible nasolaryngoscopy revealed white ulcerated lesion on the left hemi-epiglottis and the left supraglottic area.

TREATMENT

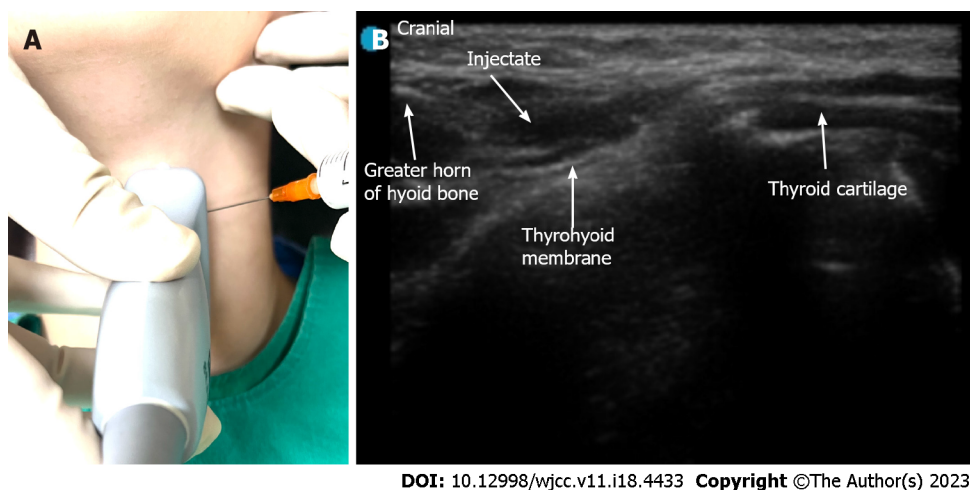
The patient was diagnosed with laryngeal herpes zoster by an otolaryngologist 67 d prior to presentation and 750 mg famciclovir once daily for 7 d was initially prescribed. In addition, she suffered from throat pain of 8 using the numerical analog scale (NRS) from 0 (no pain) to 10 (worst pain imaginable) and therefore, was treated with 75 mg pregabalin twice daily, 50 mg tramadol twice daily and 10 mg nortriptyline once at bedtime for 67 d. However, despite of these medications, the throat pain was 4 on the NRS. In addition, she complained of no improvement of cough. The patient suffered from mild constipation and dizziness due to medications and was reluctant to increase the dose. Her herpetic lesion was on the left supraglottic area, which are innervated by the internal branch of superior laryngeal nerve. Therefore, we decided to perform superior laryngeal nerve block under ultrasound guidance (Sonosite Edge 2, Fujifilm sonosite, Bothell, United States). The patient was placed in a supine position with the neck extension. The high frequency linear probe was placed over submandibular area in a longitudinal orientation. The greater horn of hyoid bone and thyroid cartilage were hyperechoic signals on sonography. Thyrohyoid muscle and thyrohyoid muscle were identified between two structures (Figure 2). Using out of plane approach, 2 mL of 50:50 mixture of 1% lidocaine and triamcinolone (40 mg/mL) was injected into the area of the posterior thyrohyoid membrane. After the procedure, the throat pain decreased to 1 on the NRS score, and the cough was greatly improved. Consent for publication of this case report was obtained from the patient.

OUTCOME AND FOLLOW-UP

Three days after the intervention, the pain and cough had completely disappeared. The patient remained symptom-free at a 3 mo follow-up.

DISCUSSION

Herpes zoster involves the sensory ganglion of spinal or cranial nerve, which subsequently, spreads along the peripheral nerves to the skin, leading to several complications such as rash, acute pain and postherpetic neuralgia (PHN)[1]. The diagnosis of herpes zoster is usually made on the history and examination findings. In this case, antibody titer to varicella zoster virus was not measured and the patient was diagnosed with laryngeal herpes zoster on the basis of the clinical presentation. The herpes zoster most commonly affects the thoracic region, followed by the ophthalmic branch of the trigeminal nerve[1]. Laryngeal herpes zoster is rare, involving the sensory of vagus nerve[2]. The sensory distribution of the vagus nerve includes superior laryngeal nerve and auricular nerve. The internal branch of the superior laryngeal nerve enters the thyrohyoid membrane and provides sensation of supraglottis above the vocal cord whereas the auricular branch of the vagus supplies part of the external auditory meatus[3]. In the present case, herpes zoster involved the left side of supraglottic region including the epiglottis, and vallecular, leading to unilateral throat pain.



DOI: 10.12998/wjcc.v11.i18.4433 Copyright ©The Author(s) 2023.

Figure 2 Superior laryngeal nerve block. A: The high frequency linear probe was placed over submandibular area in a longitudinal orientation; B: Using out of plane approach, 2 mL of 50:50 mixture of 1% lidocaine and triamcinolone (40 mg/mL) was injected into the area of the anterior thyrohyoid membrane.

Generally, the herpes zoster rash resolves within 2-4 wk. Administration of antiviral agents including acyclovir and famciclovir within 72 h after onset of herpes zoster effectively decreases acute pain, promotes lesion healing and prevents PHN[1,4]. However, PHN can occur due to nerve tissue injury during an outbreak of herpes zoster. Several inflammatory materials were released from the injured tissue including substance P, histamine and bradykinin, resulting in peripheral sensitization[5,6]. These excitatory materials increase ectopic discharge of C fibers and lead to spontaneous pain, allodynia, and hyperalgesia[7].

In the present case, three days after onset of throat pain, the patient noticed non-productive cough, easily triggered by speaking, which mildly affected the patient's daily life.

When cough lasts more than 8 wk without clear external stimuli to the cough mechanism, neurogenic cough is considered, which is associated with hypersensitivity of the superior laryngeal nerve[8]. It was reported that chronic cough occurs as a sequela to sensory nerve damage during laryngeal herpes zoster[2,8].

The anti-convulsant such as gabapentin or pregabalin and anti-depressant including tricyclic antidepressants represent first-line treatment options for neuropathic pain[1,9]. Postherpetic cough is associated with neurogenic hypersensitivity and is analogue to PHN. Therefore, medical treatment with pregabalin and amitriptyline can be considered to be effective to treat pain and cough following herpes zoster[2,8]. However, such complications associated with herpes zoster are often resistant to medical treatments[1,2,8]. In the present case, the patient complained of throat pain at a 4 on the NRS and cough despite medication with pregabalin, nortriptyline and tramadol.

Administration of local anesthetic plus steroid around nerve affected by herpes zoster is effective in treating zoster pain and preventing PHN[1,10,11]. It was reported that the superior laryngeal nerve with local anesthetic and steroid was effective to treat chronic neurogenic cough after post-viral neuropathy [12,13]. Steroids, a strong anti-inflammatory agent, can decrease the perineural inflammatory response and reduce ectopic discharge in the involved nerve[14,15]. In addition, it can help hasten recovery of the injured nerve[14]. In the present case, the pain and cough following herpes zoster was completely resolved with superior laryngeal nerve block under ultrasonography guidance.

CONCLUSION

In conclusion, laryngeal herpes zoster is a rare form of herpes zoster. It can cause several complications such as throat pain and cough. A superior laryngeal nerve block with steroid can be an effective option for treatment of persistent pain and cough following laryngeal herpes zoster. Clinicians should be aware of this entity to provide appropriate treatments.

FOOTNOTES

Author contributions: Oh J drafted the manuscript; Choi J and Park Y collected data; Jeon Y reviewed the literature and edited the manuscript; all authors agreed to be accountable for all aspects of the work, and issued final approval for the version to be submitted.

Informed consent statement: Informed written consent was obtained from the patient for publication of this report and any accompanying images.

Conflict-of-interest statement: The authors declare no conflicts of interest.

CARE Checklist (2016) statement: The authors have read the CARE Checklist (2016), and the manuscript was prepared and revised according to the CARE Checklist (2016).

Open-Access: This article is an open-access article that was selected by an in-house editor and fully peer-reviewed by external reviewers. It is distributed in accordance with the Creative Commons Attribution NonCommercial (CC BY-NC 4.0) license, which permits others to distribute, remix, adapt, build upon this work non-commercially, and license their derivative works on different terms, provided the original work is properly cited and the use is non-commercial. See: <https://creativecommons.org/licenses/by-nc/4.0/>

Country/Territory of origin: South Korea

ORCID number: Jinyoung Oh 0000-0003-3562-908X; Youngje Park 0000-0001-8204-096X; Jeongkyu Choi 0000 0003 3436 5879; Younghoon Jeon 0000-0002-7168-4214.

S-Editor: Liu JH

L-Editor: A

P-Editor: Liu JH

REFERENCES

- 1 Jeon YH. Herpes Zoster and Postherpetic Neuralgia: Practical Consideration for Prevention and Treatment. *Korean J Pain* 2015; **28**: 177-184 [PMID: 26175877 DOI: 10.3344/kjp.2015.28.3.177]
- 2 Ling B, Novakovic D, Sulica L. Cough after laryngeal herpes zoster: a new aspect of post-herpetic sensory disturbance. *J Laryngol Otol* 2014; **128**: 209-211 [PMID: 24480649 DOI: 10.1017/S0022215113003642]
- 3 Monkhouse S. Clinical anatomy: a core text with self-assessment: Elsevier Health Sciences, 2001 [DOI: 10.1002/ca.1073]
- 4 Lilie HM, Wassilew S. The role of antivirals in the management of neuropathic pain in the older patient with herpes zoster. *Drugs Aging* 2003; **20**: 561-570 [PMID: 12795624 DOI: 10.2165/00002512-200320080-00002]
- 5 Truini A, Galeotti F, Haanpaa M, Zucchi R, Albanesi A, Biasiotta A, Gatti A, Cruccu G. Pathophysiology of pain in postherpetic neuralgia: a clinical and neurophysiological study. *Pain* 2008; **140**: 405-410 [PMID: 18954941 DOI: 10.1016/j.pain.2008.08.018]
- 6 Mannion RJ, Costigan M, Decosterd I, Amaya F, Ma QP, Holstege JC, Ji RR, Acheson A, Lindsay RM, Wilkinson GA, Woolf CJ. Neurotrophins: peripherally and centrally acting modulators of tactile stimulus-induced inflammatory pain hypersensitivity. *Proc Natl Acad Sci U S A* 1999; **96**: 9385-9390 [PMID: 10430952 DOI: 10.1073/pnas.96.16.9385]
- 7 Fields HL, Rowbotham M, Baron R. Postherpetic neuralgia: irritable nociceptors and deafferentation. *Neurobiol Dis* 1998; **5**: 209-227 [PMID: 9848092 DOI: 10.1006/nbdi.1998.0204]
- 8 Altman KW, Noordzij JP, Rosen CA, Cohen S, Sulica L. Neurogenic cough. *Laryngoscope* 2015; **125**: 1675-1681 [PMID: 25647253 DOI: 10.1002/lary.25186]
- 9 Gierthmühlen J, Baron R. Neuropathic Pain. *Semin Neurol* 2016; **36**: 462-468 [PMID: 27704502 DOI: 10.1055/s-0036-1584950]
- 10 Kim HJ, Ahn HS, Lee JY, Choi SS, Cheong YS, Kwon K, Yoon SH, Leem JG. Effects of applying nerve blocks to prevent postherpetic neuralgia in patients with acute herpes zoster: a systematic review and meta-analysis. *Korean J Pain* 2017; **30**: 3-17 [PMID: 28119767 DOI: 10.3344/kjp.2017.30.1.3]
- 11 Lee H, Jeon Y. Treatment of herpes zoster with ultrasound-guided superficial cervical plexus block. *J Dent Anesth Pain Med* 2015; **15**: 247-249 [PMID: 28879287 DOI: 10.17245/jdapm.2015.15.4.247]
- 12 Simpson CB, Tibbetts KM, Loochtan MJ, Dominguez LM. Treatment of chronic neurogenic cough with in-office superior laryngeal nerve block. *Laryngoscope* 2018; **128**: 1898-1903 [PMID: 29668037 DOI: 10.1002/lary.27201]
- 13 Amin MR, Koufman JA. Vagal neuropathy after upper respiratory infection: a viral etiology? *Am J Otolaryngol* 2001; **22**: 251-256 [PMID: 11464321 DOI: 10.1053/ajot.2001.24823]
- 14 Johansson A, Bennett GJ. Effect of local methylprednisolone on pain in a nerve injury model. A pilot study. *Reg Anesth* 1997; **22**: 59-65 [PMID: 9010948 DOI: 10.1016/s1098-7339(06)80057-x]
- 15 Devor M, Govrin-Lippmann R, Raber P. Corticosteroids suppress ectopic neural discharge originating in experimental neuromas. *Pain* 1985; **22**: 127-137 [PMID: 4047699 DOI: 10.1016/0304-3959(85)90173-3]



Published by **Baishideng Publishing Group Inc**
7041 Koll Center Parkway, Suite 160, Pleasanton, CA 94566, USA

Telephone: +1-925-3991568

E-mail: bpgoffice@wjgnet.com

Help Desk: <https://www.f6publishing.com/helpdesk>

<https://www.wjgnet.com>

