

World Journal of *Clinical Cases*

World J Clin Cases 2023 July 6; 11(19): 4458-4733



Contents

Thrice Monthly Volume 11 Number 19 July 6, 2023

REVIEW

- 4458 Molecular signalling during cross talk between gut brain axis regulation and progression of irritable bowel syndrome: A comprehensive review
Singh SV, Ganguly R, Jaiswal K, Yadav AK, Kumar R, Pandey AK
- 4477 Diffusion tensor imaging in the courtroom: Distinction between scientific specificity and legally admissible evidence
van Velkinburgh JC, Herbst MD, Casper SM

MINIREVIEWS

- 4498 Inequity in the global distribution of monkeypox vaccines
Tovani-Palone MR, Doshi N, Pedersini P
- 4504 Long-term effectiveness, outcomes and complications of bariatric surgery
Gulinac M, Miteva DG, Peshevska-Sekulovska M, Novakov IP, Antovic S, Peruhova M, Snegarova V, Kabakchieva P, Assyov Y, Vasilev G, Sekulovski M, Lazova S, Tomov L, Velikova T

ORIGINAL ARTICLE

Retrospective Cohort Study

- 4513 Age, blood tests and comorbidities and AIMS65 risk scores outperform Glasgow-Blatchford and pre-endoscopic Rockall score in patients with upper gastrointestinal bleeding
Morarasu BC, Sorodoc V, Haisan A, Morarasu S, Bologa C, Haliga RE, Lionte C, Marciuc EA, Elsiddig M, Cimpoesu D, Dimofte GM, Sorodoc L

Retrospective Study

- 4531 Application of cross-migration theory in limb rehabilitation of stroke patients with hemiplegia
Lu YH, Fu Y, Shu J, Yan LY, Shen HJ
- 4544 Analysis of characteristic features in ultrasound diagnosis of fetal limb body wall complex during 11-13⁺ weeks
Ye CH, Li S, Ling L
- 4553 Network pharmacology and molecular docking-based analyses to predict the potential mechanism of Huangqin decoction in treating colorectal cancer
Li YJ, Tang DX, Yan HT, Yang B, Yang Z, Long FX
- 4567 Assessment of functional prognosis of anterior cruciate ligament reconstruction in athletes based on a body shape index
Wang YJ, Zhang JC, Zhang YZ, Liu YH

EVIDENCE-BASED MEDICINE

- 4579** Network pharmacology and molecular docking to explore Polygoni Cuspidati Rhizoma et Radix treatment for acute lung injury

Zheng JL, Wang X, Song Z, Zhou P, Zhang GJ, Diao JJ, Han CE, Jia GY, Zhou X, Zhang BQ

ORIGINAL ARTICLE**Randomized Controlled Trial**

- 4601** Ulinastatin in the treatment of severe acute pancreatitis: A single-center randomized controlled trial

Wang SQ, Jiao W, Zhang J, Zhang JF, Tao YN, Jiang Q, Yu F

- 4612** Fecal microbiota transplantation in patients with metabolic syndrome and obesity: A randomized controlled trial

da Ponte Neto AM, Clemente ACO, Rosa PW, Ribeiro IB, Funari MP, Nunes GC, Moreira L, Sparvoli LG, Cortez R, Taddei CR, Mancini MC, de Moura EGH

SYSTEMATIC REVIEWS

- 4625** Combined medial patellofemoral ligament and medial patellotibial ligament reconstruction in recurrent patellar instability: A systematic review and meta-analysis

Abbaszadeh A, Saeedi M, Hoveidaei AH, Dadgostar H, Razi S, Razi M

CASE REPORT

- 4635** Unique Roberts syndrome with bilateral congenital glaucoma: A case report

Almulhim A, Almoallem B, Alsirhy E, Osman EA

- 4640** CK5/6-positive, P63-positive lymphoepithelioma-like hepatocellular carcinoma: A case report and literature review

Tang HT, Lin W, Zhang WQ, Qian JL, Li K, He K

- 4648** Edaravone administration and its potential association with a new clinical syndrome in cerebral infarction patients: Three case reports

Yang L, Xu X, Wang L, Zeng KB, Wang XF

- 4655** CDKN1C gene mutation causing familial Silver-Russell syndrome: A case report and review of literature

Li J, Chen LN, He HL

- 4664** Hypothetical hypoxia-driven rapid disease progression in hepatocellular carcinoma post transarterial chemoembolization: A case report

Yeo KF, Ker A, Kao PE, Wang CC

- 4670** Metastatic colon cancer treated using traditional Chinese medicine combined with chemotherapy: A case report

Deng CG, Tang MY, Pan X, Liu ZH

- 4677** Rare cause of cerebral venous sinus thrombosis: Spontaneous intracranial hypotension syndrome: A case report

Huang P

- 4684** Integrated Chinese and Western medicine in the treatment of a patient with podocyte infolding glomerulopathy: A case report
Chang MY, Zhang Y, Li MX, Xuan F
- 4692** Morbihan disease misdiagnosed as senile blepharoptosis and successfully treated with short-term minocycline and ketotifen: A case report
Na J, Wu Y
- 4698** With two episodes of right retromandibular angle subcutaneous emphysema during right upper molar crown preparation: A case report
Bai YP, Sha JJ, Chai CC, Sun HP
- 4707** Poststroke rehabilitation using repetitive transcranial magnetic stimulation during pregnancy: A case report
Jo J, Kim H
- 4713** Tuberculosis-induced aplastic crisis and atypical lymphocyte expansion in advanced myelodysplastic syndrome: A case report and review of literature
Sun XY, Yang XD, Xu J, Xiu NN, Ju B, Zhao XC
- 4723** Posterior reversible encephalopathy syndrome following uneventful clipping of an unruptured intracranial aneurysm: A case report
Hwang J, Cho WH, Cha SH, Ko JK

ACADEMIC WRITING

- 4729** Revitalizing case reports: Standardized guidelines and mentorship
Jeyaraman M, Ramasubramanian S, Jeyaraman N, Nallakumarasamy A, Sharma S

ABOUT COVER

Editorial Board Member of *World Journal of Clinical Cases*, Miroslav Vujasinovic, MD, PhD, Associate Professor, Department of Upper Abdominal Diseases, Karolinska University Hospital, Stockholm 14186, Sweden. mvujas@gmail.com

AIMS AND SCOPE

The primary aim of *World Journal of Clinical Cases* (WJCC, *World J Clin Cases*) is to provide scholars and readers from various fields of clinical medicine with a platform to publish high-quality clinical research articles and communicate their research findings online.

WJCC mainly publishes articles reporting research results and findings obtained in the field of clinical medicine and covering a wide range of topics, including case control studies, retrospective cohort studies, retrospective studies, clinical trials studies, observational studies, prospective studies, randomized controlled trials, randomized clinical trials, systematic reviews, meta-analysis, and case reports.

INDEXING/ABSTRACTING

The WJCC is now abstracted and indexed in Science Citation Index Expanded (SCIE, also known as SciSearch®), Journal Citation Reports/Science Edition, Current Contents®/Clinical Medicine, PubMed, PubMed Central, Reference Citation Analysis, China National Knowledge Infrastructure, China Science and Technology Journal Database, and Superstar Journals Database. The 2023 Edition of Journal Citation Reports® cites the 2022 impact factor (IF) for WJCC as 1.1; IF without journal self cites: 1.1; 5-year IF: 1.3; Journal Citation Indicator: 0.26; Ranking: 133 among 167 journals in medicine, general and internal; and Quartile category: Q4.

RESPONSIBLE EDITORS FOR THIS ISSUE

Production Editor: Si Zhao; Production Department Director: Xiang Li; Editorial Office Director: Jin-Lei Wang.

NAME OF JOURNAL

World Journal of Clinical Cases

ISSN

ISSN 2307-8960 (online)

LAUNCH DATE

April 16, 2013

FREQUENCY

Thrice Monthly

EDITORS-IN-CHIEF

Bao-Gan Peng, Jerzy Tadeusz Chudek, George Kontogeorgos, Maurizio Serati, Ja Hyeon Ku

EDITORIAL BOARD MEMBERS

<https://www.wjgnet.com/2307-8960/editorialboard.htm>

PUBLICATION DATE

July 6, 2023

COPYRIGHT

© 2023 Baishideng Publishing Group Inc

INSTRUCTIONS TO AUTHORS

<https://www.wjgnet.com/bpg/gerinfo/204>

GUIDELINES FOR ETHICS DOCUMENTS

<https://www.wjgnet.com/bpg/GerInfo/287>

GUIDELINES FOR NON-NATIVE SPEAKERS OF ENGLISH

<https://www.wjgnet.com/bpg/gerinfo/240>

PUBLICATION ETHICS

<https://www.wjgnet.com/bpg/GerInfo/288>

PUBLICATION MISCONDUCT

<https://www.wjgnet.com/bpg/gerinfo/208>

ARTICLE PROCESSING CHARGE

<https://www.wjgnet.com/bpg/gerinfo/242>

STEPS FOR SUBMITTING MANUSCRIPTS

<https://www.wjgnet.com/bpg/GerInfo/239>

ONLINE SUBMISSION

<https://www.f6publishing.com>



Unique Roberts syndrome with bilateral congenital glaucoma: A case report

Amar Almulhim, Basamat Almoallem, Ehab Alsirrhy, Essam A Osman

Specialty type: Medicine, research and experimental

Provenance and peer review: Unsolicited article; Externally peer reviewed.

Peer-review model: Single blind

Peer-review report's scientific quality classification

Grade A (Excellent): 0
Grade B (Very good): B, B
Grade C (Good): 0
Grade D (Fair): 0
Grade E (Poor): 0

P-Reviewer: Malik S, Pakistan;
Morya AK, India

Received: December 29, 2022

Peer-review started: December 29, 2022

First decision: February 17, 2023

Revised: March 19, 2023

Accepted: April 20, 2023

Article in press: April 20, 2023

Published online: July 6, 2023



Amar Almulhim, Basamat Almoallem, Ehab Alsirrhy, Essam A Osman, Department of Ophthalmology, King Saud University, Riyadh 11411, Saudi Arabia

Basamat Almoallem, King Saud University Medical City (KSUMC), Riyadh, Saudi

Corresponding author: Amar Almulhim, MD, Academic Fellow, Department of Ophthalmology, King Saud University, King Abdullah Road, Riyadh 11411, Saudi Arabia.
dr.ammam1412@gmail.com

Abstract

BACKGROUND

Congenital glaucoma associated with Roberts syndrome (RS) is an unusual and unique condition. No previous report describes this association. A multidisciplinary approach including molecular studies were conducted to reach the final diagnosis.

CASE SUMMARY

We present a rare case of a 1-wk-old male with RS associated with bilateral congenital glaucoma, left ectopic kidney, and left-hand rudimentary digits. A comprehensive approach was applied by which bilateral non-penetrating glaucoma surgery was performed with good control of intraocular pressure for more than 6 mo. Cytogenetic and molecular testing were conducted and revealed normal measurements.

CONCLUSION

This report described a case of a male baby with clinical features of RS but with a negative molecular analysis, presenting with left-hand rudimentary digits, bilateral congenital glaucoma, and left ectopic kidney. To the best of our knowledge, this is the first case reported with phocomelia, bilateral congenital glaucoma, and unilateral ectopic kidney.

Key Words: Roberts syndrome; Roberts-SC phocomelia syndrome; Phocomelia; Congenital glaucoma; Karyotype; Whole exome sequencing; Case report

©The Author(s) 2023. Published by Baishideng Publishing Group Inc. All rights reserved.

Core Tip: Roberts syndrome (RS) is an extremely rare disease characterized by a combination of deformities in the lower and/or upper extremities in association with other organ abnormalities. We provide here the first reported case of RS associated with bilateral congenital glaucoma. Bilateral non-penetrating glaucoma surgery was performed to control intraocular pressure and the outcome was excellent.

Citation: Almulhim A, Almoallem B, Alsirrhy E, Osman EA. Unique Roberts syndrome with bilateral congenital glaucoma: A case report. *World J Clin Cases* 2023; 11(19): 4635-4639

URL: <https://www.wjgnet.com/2307-8960/full/v11/i19/4635.htm>

DOI: <https://dx.doi.org/10.12998/wjcc.v11.i19.4635>

INTRODUCTION

Phocomelia with ocular and internal organ abnormalities are reported as part of Roberts syndrome (RS). RS (OMIM #268300; also known as Roberts-SC phocomelia syndrome) was reported by John Roberts in 1919 and is an autosomal recessive condition characterized by prenatal and postnatal growth retardation, skeletal malformation including tetraphocomelia or mesomelia, mental retardation, and craniofacial dysmorphic features[1].

The clinical presentation is widely variable, from mild cases that can be difficult to confirm without a molecular test to the severe spectrum of diseases that present with a typical phenotype. Babies born with severe RS usually die *in utero* or shortly postpartum, while mildly affected people can survive to middle age[2].

Herein, we report an unusual case of a male baby with clinical features of RS but with a negative molecular analysis, presenting with left-hand rudimentary digits, bilateral congenital glaucoma, and left ectopic kidney.

CASE PRESENTATION

Chief complaints

A 1-wk-old male baby was referred to our hospital in June 2021 with a picture of bilateral congenital glaucoma.

History of present illness

According to the parents, the deformed left hand with bilateral cloudy cornea were noticed immediately after birth.

Personal and family history

The baby was the second child of a healthy non-consanguineous couple and a product of an uneventful pregnancy with spontaneous vaginal delivery at 40 wk. Birth weight was 3 kg. There was neither a family history of similar conditions nor a prenatal history of exposure to any known teratogenic medication.

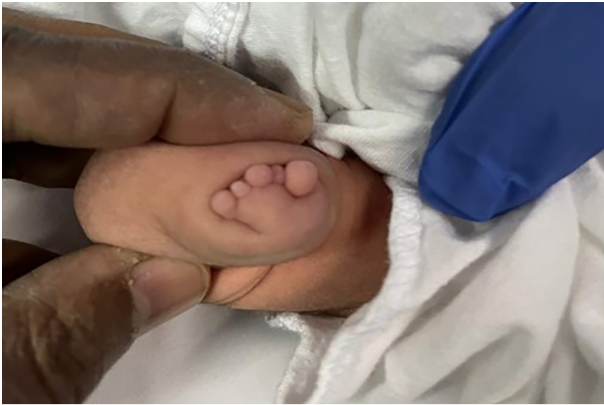Physical examination

On physical examination, left-hand rudimentary digits were noticed (Figure 1). The child was active and sucking well. Examinations of the central nervous system, cardiovascular system, abdomen, and genitalia showed all to be normal.

An ocular examination was performed under general anesthesia and showed bilateral buphthalmos (Figure 2), significant corneal edema, and corneal diameter of 11 mm right/11.5 mm left. The patient was treated with travaprost and combined dorzolamide and timolol, and the intraocular pressure (IOP) was 25 mmHg right/39 mmHg left. Fundus examination showed a cup disc ratio of about 0.2 in both eyes. Central corneal thickness ranged between 900 microns and 930 microns in both eyes.

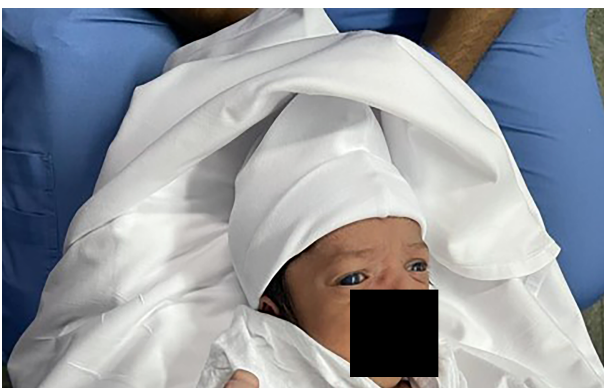Imaging examinations

Echocardiogram findings were normal. Abdominal ultrasound showed a left ectopic kidney located in the ipsilateral pelvic region and not in the lumbar area (Figure 3). Both kidneys appeared normal in size and echogenicity.



DOI: 10.12998/wjcc.v11.i19.4635 Copyright ©The Author(s) 2023.

Figure 1 Left-hand rudimentary digits.



DOI: 10.12998/wjcc.v11.i19.4635 Copyright ©The Author(s) 2023.

Figure 2 Bilateral buphthalmos and corneal haze.

FURTHER DIAGNOSTIC WORK-UP

Based on the given detailed ophthalmological and medical assessment, we applied comprehensive genetic testing by performing karyotyping and chromosomal microarray analysis. Karyotype showed normal male (46, XY) with no evidence of clinically significant numerical or structural chromosome abnormalities. Moreover, we performed whole-exome sequencing (WES) that allowed us to screen the whole exome and to focus in particular on the *ESCO2* gene that is known to be linked with RS and other genes related to primary congenital glaucoma such as the *CYP11B1* and *LTBP2* genes. Despite our detailed review of the WES data, negative results were found, with no observed genetic variants or incidental findings.

Differential diagnoses

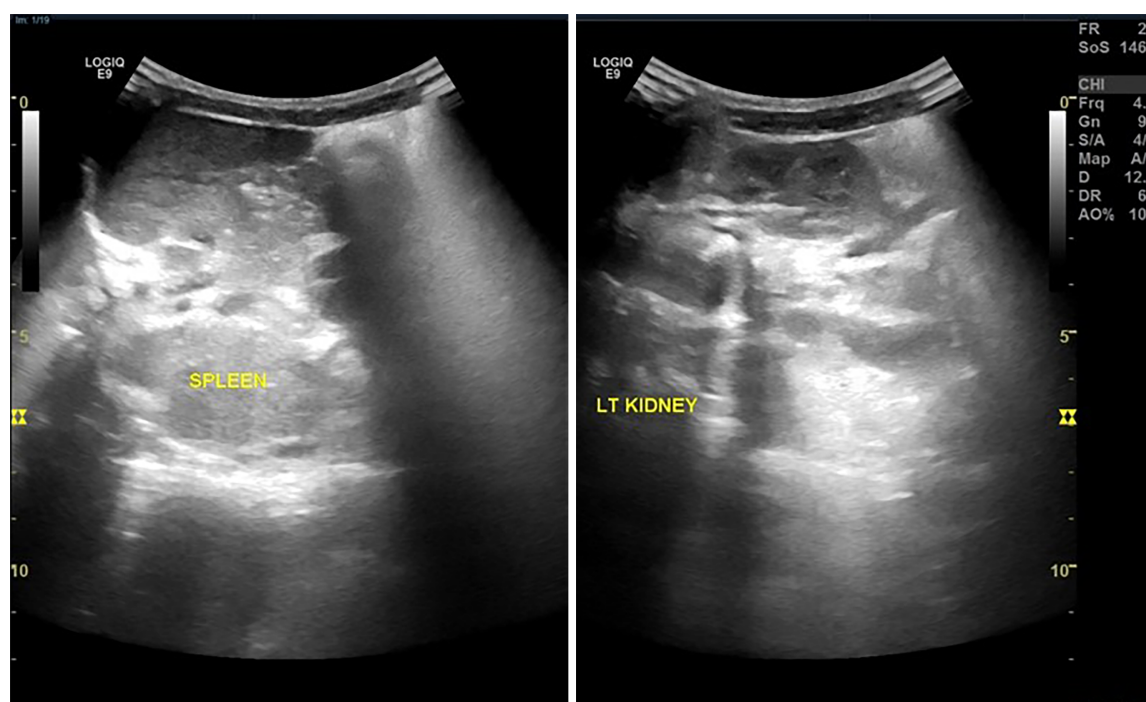
Thalidomide-induced phocomelia; Holt-Oram syndrome; Thrombocytopenia with absent radius syndrome; sporadic phocomelia.

FINAL DIAGNOSIS

Based on the clinical and diagnostic findings, the final diagnosis was RS with bilateral congenital glaucoma and left ectopic kidney.

TREATMENT

Bilateral non-penetrating deep sclerectomy plus mitomycin C was applied. The IOP was stable for more than 6 mo postoperatively.



DOI: 10.12998/wjcc.v11.i19.4635 Copyright ©The Author(s) 2023.

Figure 3 Abdominal ultrasound. The left ectopic kidney was located in the ipsilateral pelvic region (instead of the normal lumbar region).

Written informed consent was obtained from the parents of the baby. The Institutional Review Board reviewed and approved this study. Permission to publish photographs was also obtained.

OUTCOME AND FOLLOW-UP

At 6 mo, 9 mo, and 1 year postoperatively, the IOP was stable without anti-glaucoma medication.

DISCUSSION

RS is an extremely rare autosomal recessive condition that presents with widely variable prenatal and postnatal growth retardation, skeletal malformation, and mental retardation. It was first described by Roberts in 1919 in two children of consanguineous parents. The children presented with upper and lower limb anomalies, skull deformity, exophthalmos, cleft lip, and palate bilaterally[3]. In 1969, Afifi *et al*[1] reported a syndrome with milder features and labeled it as SC phocomelia syndrome.

A systematic review and severity scoring system was published by Van Den Berg and Francke[3] in 1993 that included 100 cases. Goh *et al*[2] and Zhou *et al*[4] conducted a review of the literature on RS in adult patients. None of the previously reported cases were associated with congenital glaucoma. Ocular manifestations reported in the literature to date have been hypertelorism in 86.7% of patients, exophthalmia in 69.4% of patients, cloudy cornea in 68.1% of patients, optic nerve cavernous hemangioma in 1 patient, and blue sclera with bilateral macular dysfunction in 1 patient. Renal abnormalities were reported in 50% of patients[1-4].

Worldwide about 157 cases of RS have been reported, and the most recent case was published in October 2020 regarding a 30-wk gestation stillborn male who had the typical phenotype of RS with a normal molecular analysis[5].

In our case, we applied comprehensive genetic testing by performing karyotyping and chromosomal microarray analysis. Chromosomal analysis revealed normal male (46, XY) without any detected abnormalities. WES revealed no abnormalities in the *ESCO2* gene (linked to RS) or the *CYP11B1* and *LTBP2* genes (linked to primary congenital glaucoma). Although this patient had normal molecular study findings, the diagnosis of RS can be established based on the phenotype because RS cases without any molecular abnormality have been reported in the literature[5].

CONCLUSION

This report describes a case of a male baby with clinical features of RS but with a negative molecular analysis. He presented with left-hand rudimentary digits, bilateral congenital glaucoma, and left ectopic kidney. To the best of our knowledge, this is the first reported case of RS with a combination of phocomelia, congenital glaucoma, and ectopic kidney without any detected molecular abnormality.

FOOTNOTES

Author contributions: Almulhim A and Almoallem B contributed to manuscript writing and editing; Osman E and Alsirrhy E contributed to conceptualization and supervision; and all authors have read and approved the final manuscript.

Informed consent statement: Informed written consent was obtained from the parents for publication of this report and any accompanying images.

Conflict-of-interest statement: All the authors report no relevant conflicts of interest for this article.

CARE Checklist (2016) statement: The authors have read the CARE Checklist (2016), and the manuscript was prepared and revised according to the CARE Checklist (2016).

Open-Access: This article is an open-access article that was selected by an in-house editor and fully peer-reviewed by external reviewers. It is distributed in accordance with the Creative Commons Attribution NonCommercial (CC BY-NC 4.0) license, which permits others to distribute, remix, adapt, build upon this work non-commercially, and license their derivative works on different terms, provided the original work is properly cited and the use is non-commercial. See: <https://creativecommons.org/licenses/by-nc/4.0/>

Country/Territory of origin: Saudi Arabia

ORCID number: Amar Almulhim 0000-0003-4957-514x.

S-Editor: Liu XF

L-Editor: A

P-Editor: Chen YX

REFERENCES

- 1 Afifi HH, Abdel-Salam GM, Eid MM, Tosson AM, Shousha WG, Abdel Azeem AA, Farag MK, Mehrez MI, Gaber KR. Expanding the mutation and clinical spectrum of Roberts syndrome. *Congenit Anom (Kyoto)* 2016; **56**: 154-162 [PMID: 26710928 DOI: 10.1111/cga.12151]
- 2 Goh ES, Li C, Horsburgh S, Kasai Y, Kolomietz E, Morel CF. The Roberts syndrome/SC phocomelia spectrum--a case report of an adult with review of the literature. *Am J Med Genet A* 2010; **152A**: 472-478 [PMID: 20101700 DOI: 10.1002/ajmg.a.33261]
- 3 Van Den Berg DJ, Francke U. Roberts syndrome: a review of 100 cases and a new rating system for severity. *Am J Med Genet* 1993; **47**: 1104-1123 [PMID: 8291532 DOI: 10.1002/ajmg.1320470735]
- 4 Zhou J, Yang X, Jin X, Jia Z, Lu H, Qi Z. Long-term survival after corrective surgeries in two patients with severe deformities due to Roberts syndrome: A Case report and review of the literature. *Exp Ther Med* 2018; **15**: 1702-1711 [PMID: 29434756 DOI: 10.3892/etm.2017.5592]
- 5 Salari B, Dehner LP. Pseudo-Roberts Syndrome: An Entity or Not? *Fetal Pediatr Pathol* 2022; **41**: 396-402 [PMID: 33026893 DOI: 10.1080/15513815.2020.1827320]



Published by **Baishideng Publishing Group Inc**
7041 Koll Center Parkway, Suite 160, Pleasanton, CA 94566, USA

Telephone: +1-925-3991568

E-mail: bpgoffice@wjgnet.com

Help Desk: <https://www.f6publishing.com/helpdesk>

<https://www.wjgnet.com>

